



# Lecture Title:

**ANATOMY AND INVESTIGATIONS OF NERVOUS SYSTEM ..**

(RAD 366, Radiology)

**Lecturer name: Dr. fahad albadr**

**Lecture Date: Jan 2019**

# Lecture Objectives..



## Students at the end of the lecture will be able to:

- Identify the different radiological modalities used for evaluation of CNS
- Identify the indication and contraindication for each modality
- Identify the radiological anatomy of brain and its vasculatures in different modalities.

# The Radiological Investigation Used For Evaluation of The Brain and Skull



- **1.Plain x-ray Skull**
- **2.CT Scan**
- **3.MRI**
- **4.MRA , MRV & CTA**
- **5.Catheter angiogram**
- **6.Duplex U/S of carotid arteries**
- **7.Ultrasound for neonatal brain**

# The Radiological Investigation Used For Evaluation of The Brain and Skull



The newer imaging modalities have had a great impact on the diagnosis of diseases of the central nervous system.

CT and MRI have become the standard investigations for disorders of the brain.

Plain films are still the initial investigation for disorders of the bones of the skull – particularly fractures, but otherwise have limited uses.

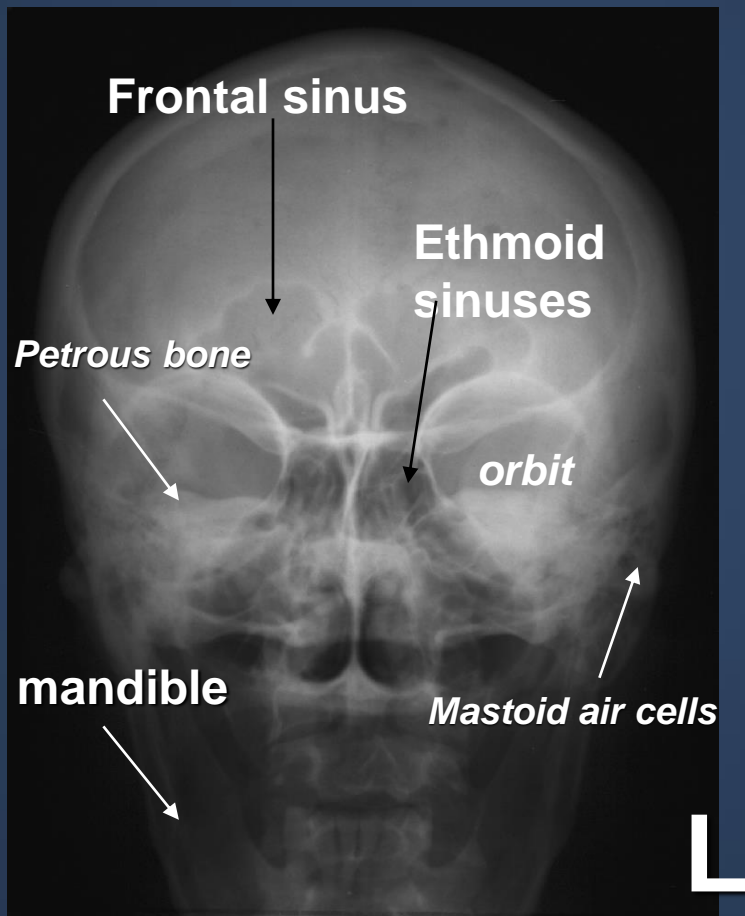
# Plain x-ray skull



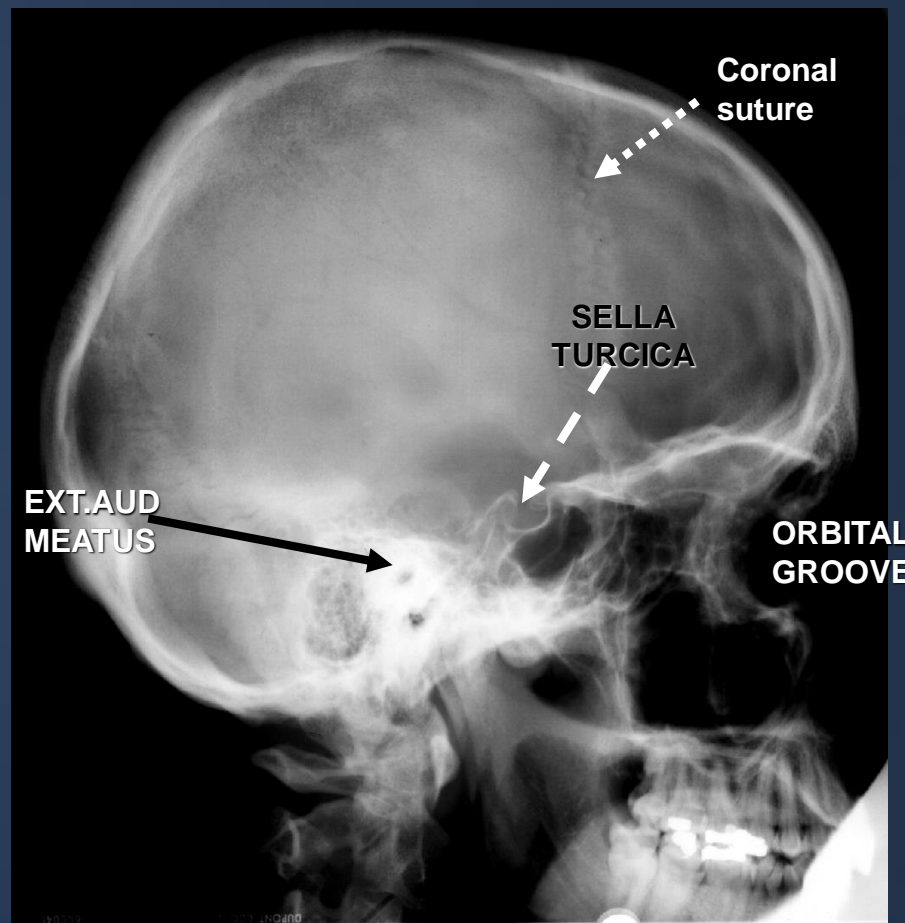
## Indications:

- trauma
- congenital
- calcification: normal or abnormal (vascular ,neoplasm)
- metastasis: lytic /sclerotic
- multiple myeloma
- metabolic disorders

# Plain x-ray skull

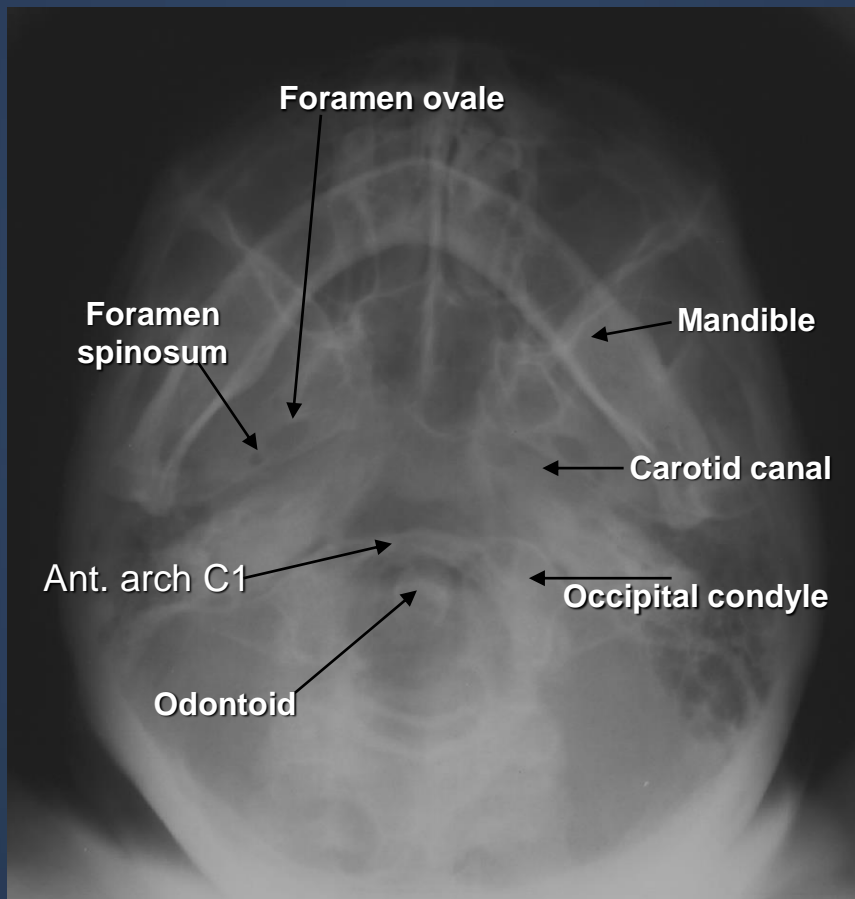


SKULL PA VIEW

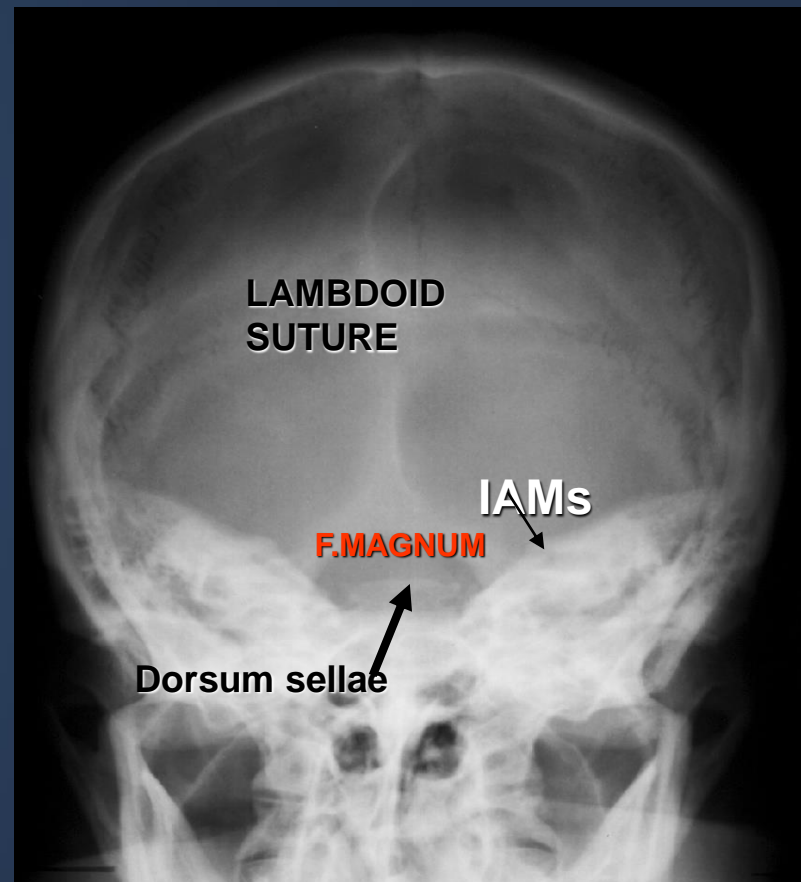


Skull X-RAY LAT. VIEW

# Plain x-ray skull

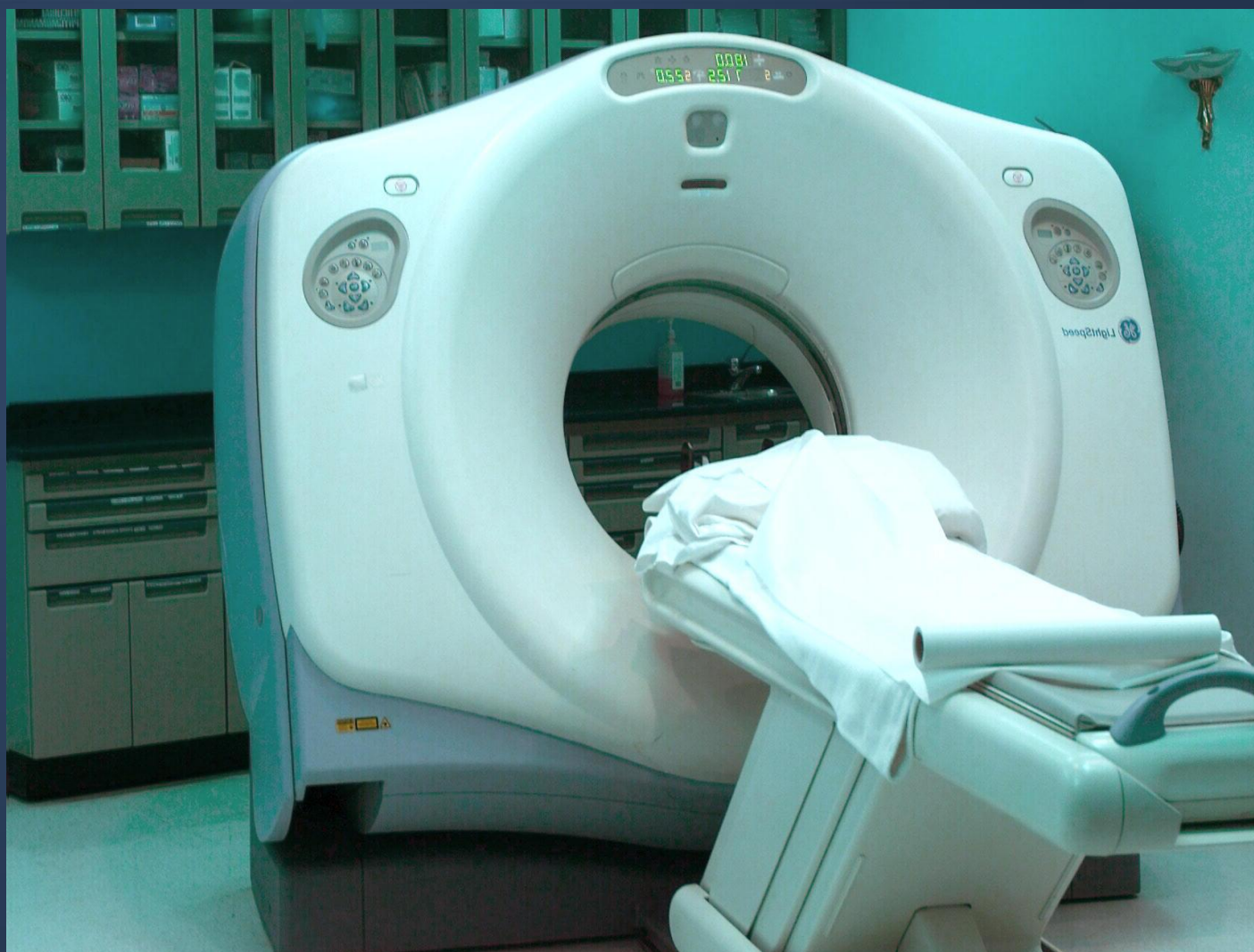

**submentovertical VIEW**



**TOWENS VIEW (AP)**

# CT SCAN ..





# CT SCAN..



- **Using ionizing radiation**
- **Spiral CT can perform a head scan in 15 minutes pre & post contrast scans.**
- **The scan itself can take as little as 10 seconds.**
- **Patient preparation: nil**
- **Type of the contrast medium: iodinated contrast**
- **(non ionic L.O.C.M)**

# CT SCAN..



## Indications:

- **Trauma**
- **detection of blood**
- **strokes**
- **tumours**
- **infection**
- **Vascular disorders**

## Contraindications

## Disadvantages

# CT SCAN..



- The axial plane is the routine projection but it is sometimes possible to obtain direct coronal scans.
- The window settings are selected for the brain, but may be altered to show the bones.

# CT SCAN..



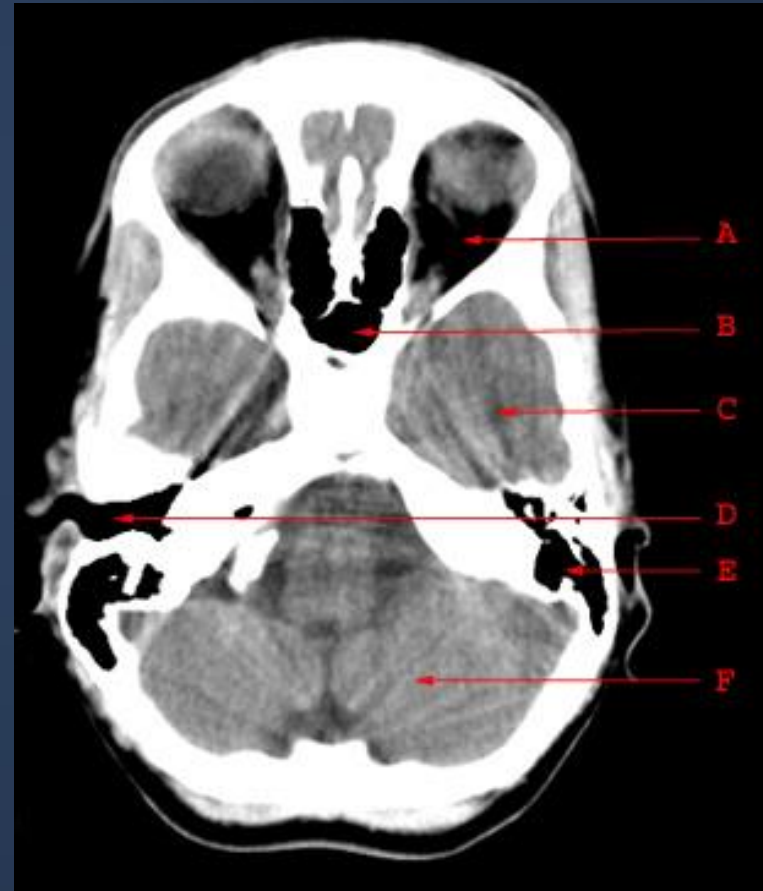## NORMAL CT BRAIN

- CSF is seen as water density (black) within ventricular system and subarachnoid space.
- Grey matter is differentiated from white matter (white matter is relatively darker than grey matter).
- The falx is denser than the brain.
- Large arteries and venous sinuses can be recognized when opacified by contrast medium.
- Posterior fossa may be obscured by artifacts from overlying temporal and occipital bone.

# CT SCAN..



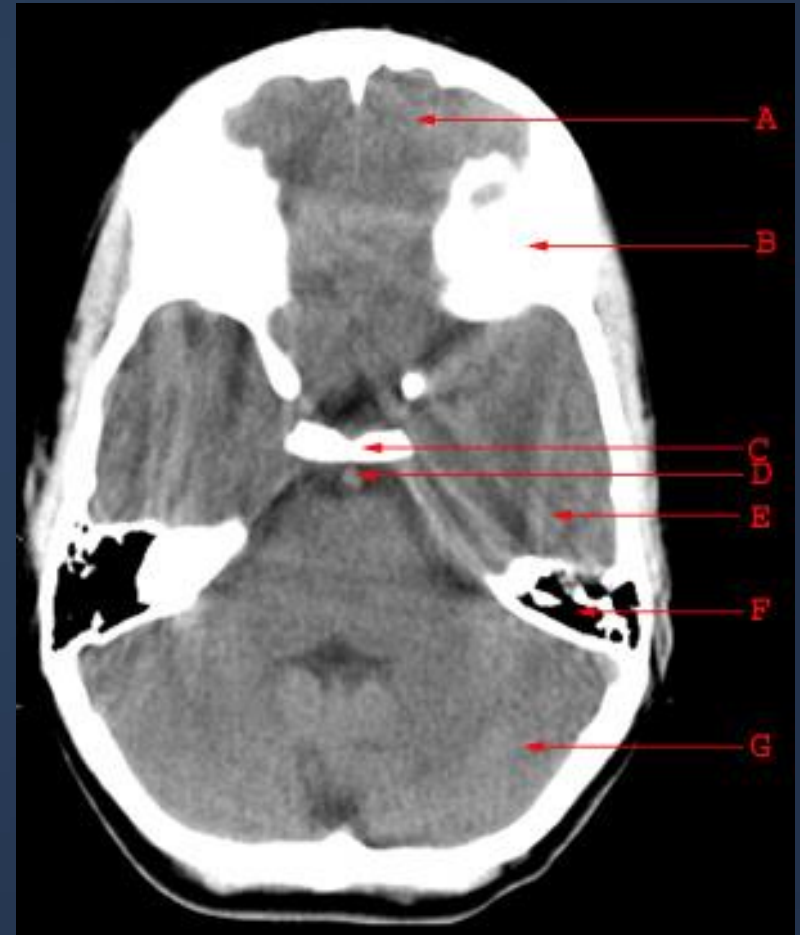- A. Orbit
- B. Sphenoid Sinus
- C. Temporal Lobe
- D. External Auditory Canal
- E. Mastoid Air Cells
- F. Cerebellar Hemisphere



# CT SCAN..



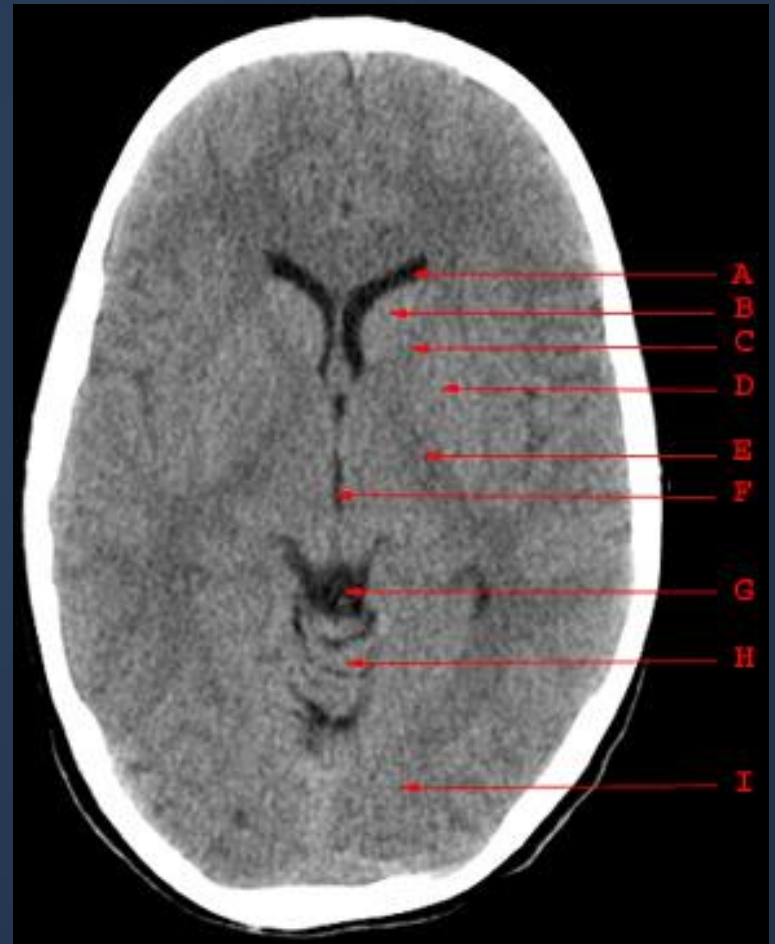- A. Frontal Lobe
- B. Frontal Bone (Superior Surface of Orbital Part)
- C. Dorsum Sellae
- D. Basilar Artery
- E. Temporal Lobe
- F. Mastoid Air Cells
- G. Cerebellar Hemisphere



# CT SCAN..



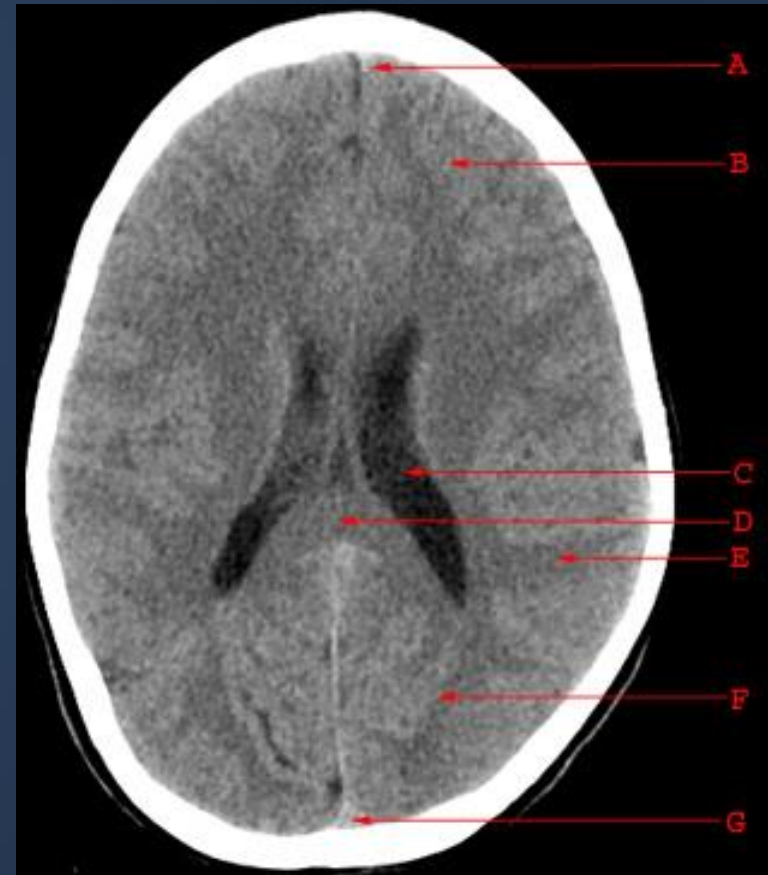- A. Anterior Horn of the Lateral Ventricle
- B. Caudate Nucleus
- C. Anterior Limb of the Internal Capsule
- D. Putamen and Globus Pallidus
- E. Posterior Limb of the Internal Capsule
- F. Third Ventricle
- G. Quadrigeminal Plate Cistern
- H. Cerebellar Vermis
- I. Occipital Lobe



# CT SCAN..



- A. Falx Cerebri
- B. Frontal Lobe
- C. Body of the Lateral Ventricle
- D. Splenium of the Corpus Callosum
- E. Parietal Lobe
- F. Occipital Lobe
- G. Superior Sagittal Sinus

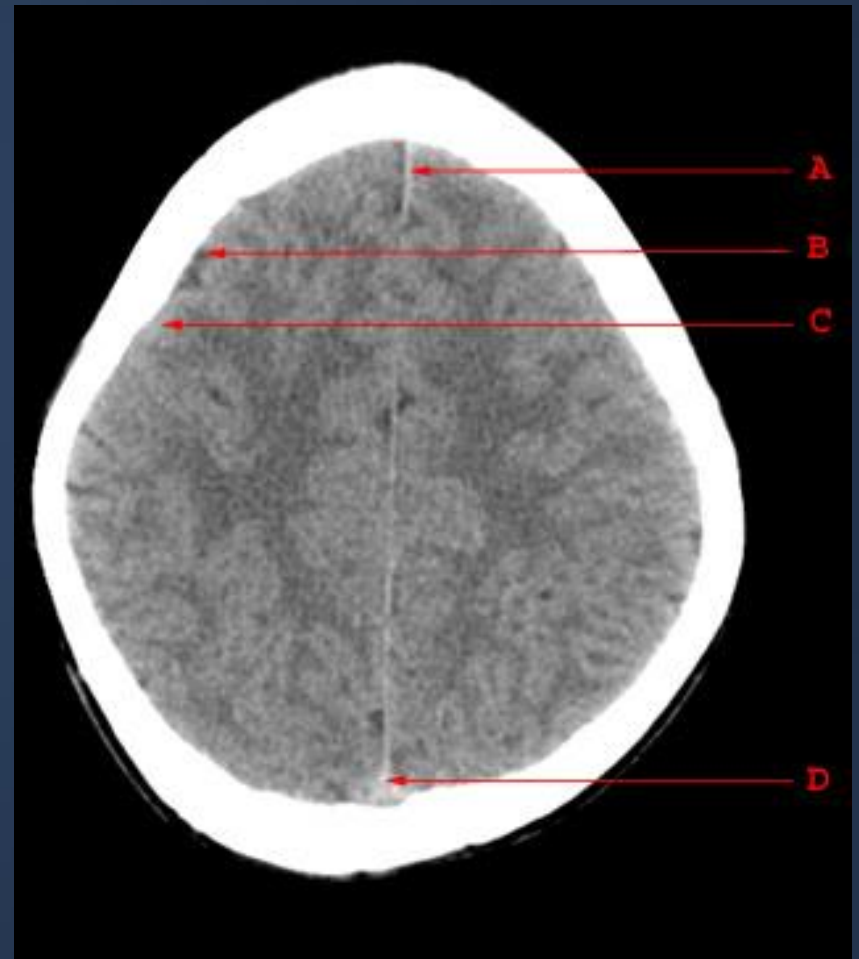




# CT SCAN..



- A. Falx Cerebri
- B. Sulcus
- C. Gyrus
- D. Superior Sagittal Sinus



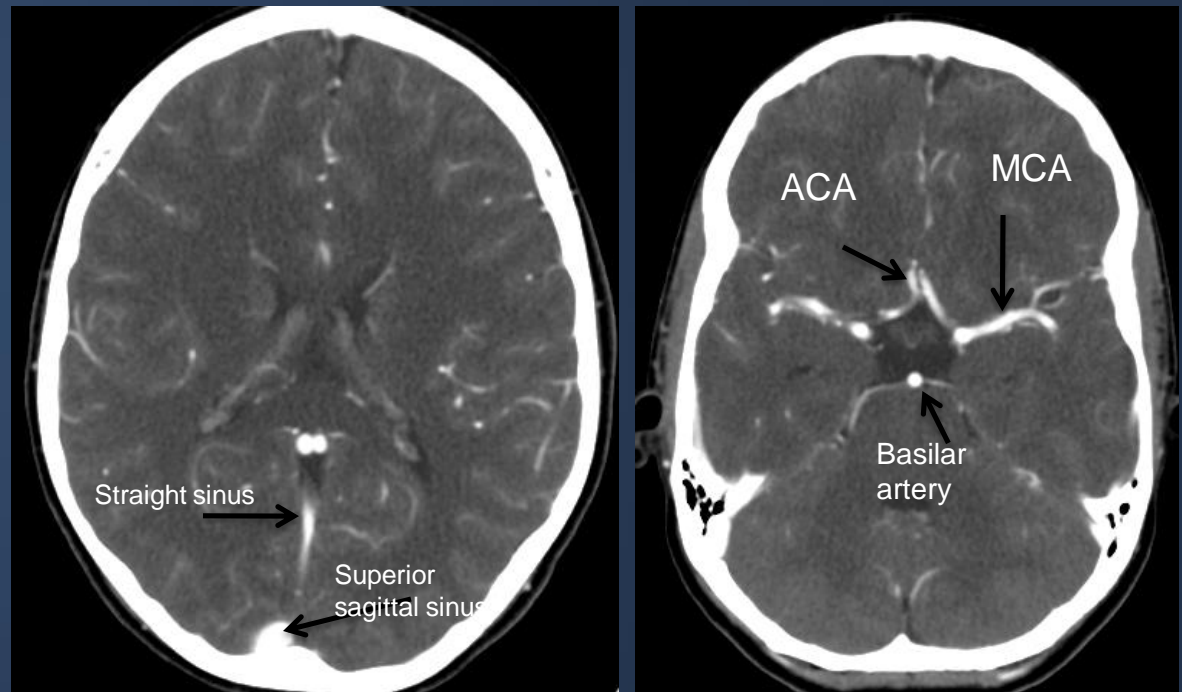
# CT SCAN..



## Contrast enhanced CT:

IV injection of contrast medium is often given because the abnormality not seen in pre contrast scans may be rendered visible following contrast enhancement (consequence of breakdown of blood brain barrier allowing contrast to enter the lesion particularly in neoplasm, infection, inflammation and certain stage of ischemia).

Also it is helpful in demonstrating blood vessels

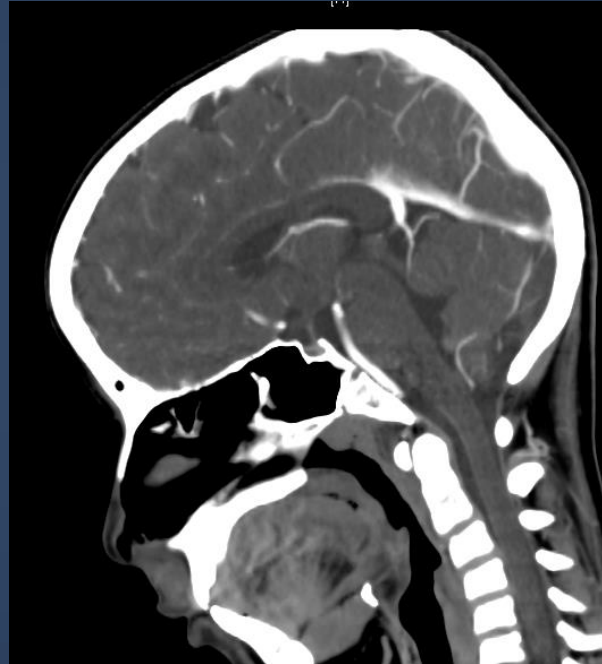

**Contrast enhanced CT**

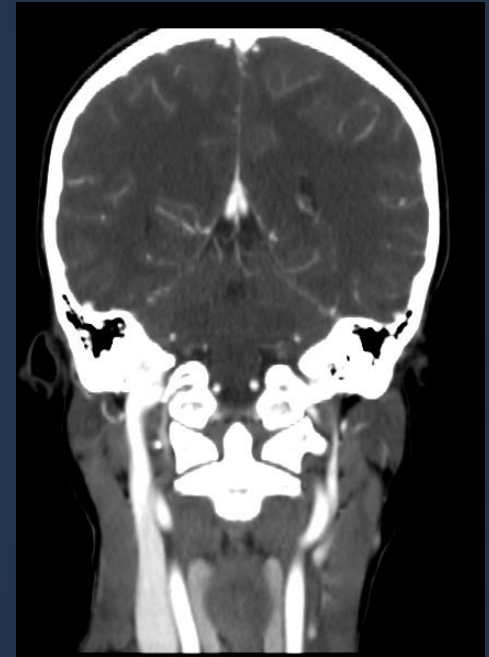# CT SCAN..



Computer reconstructions can in selected circumstances be made from the axial sections which then provide images in coronal or sagittal planes.



Sagittal reconstruction

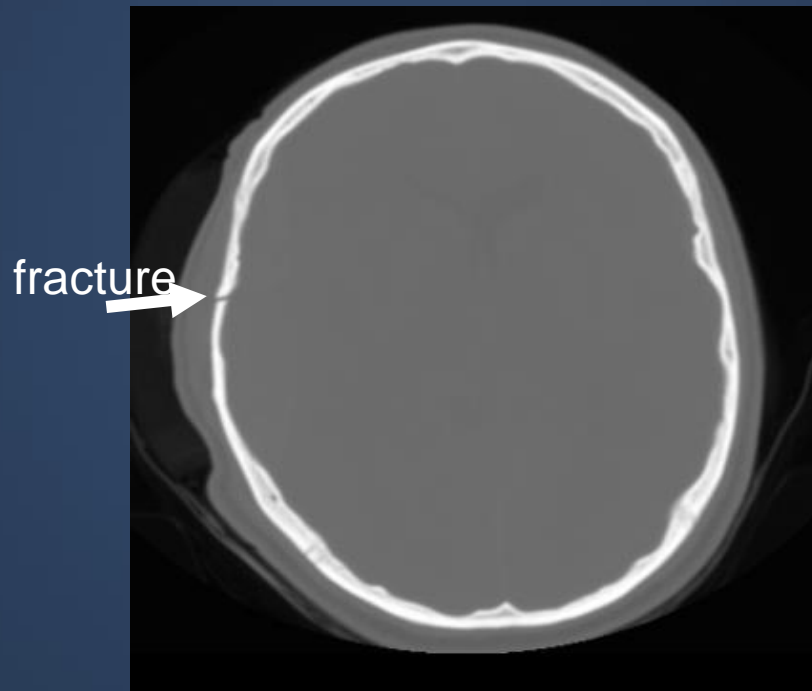


Coronal reconstruction

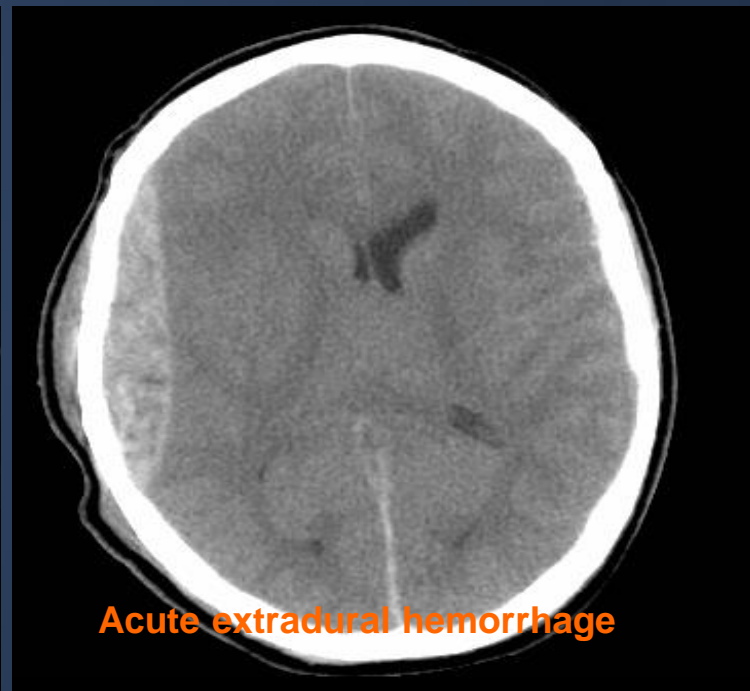# CT SCAN..



**Bone window**



**Brain window**

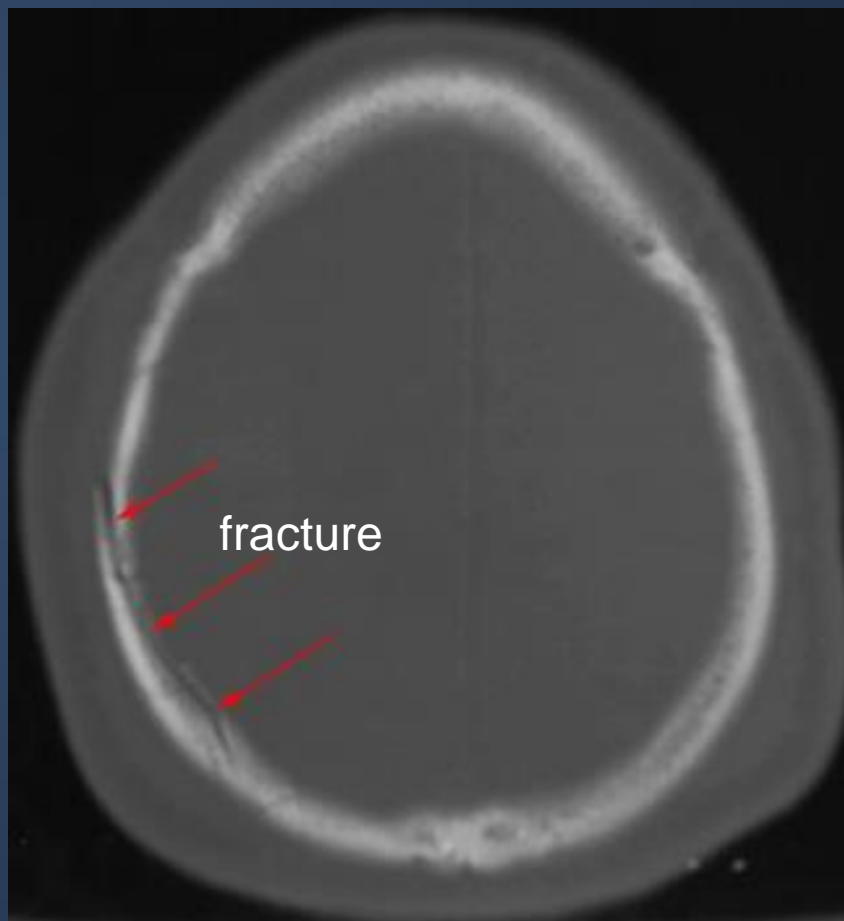


The window settings are selected for the brain, but may be altered to show the bones.

# CT SCAN..



**Bone window**

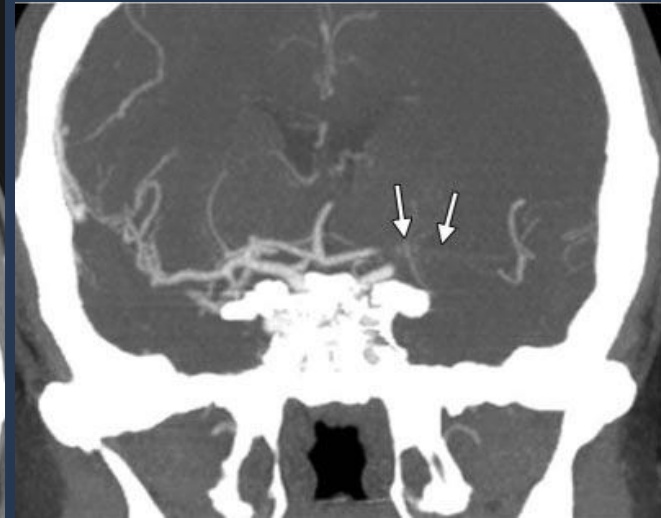
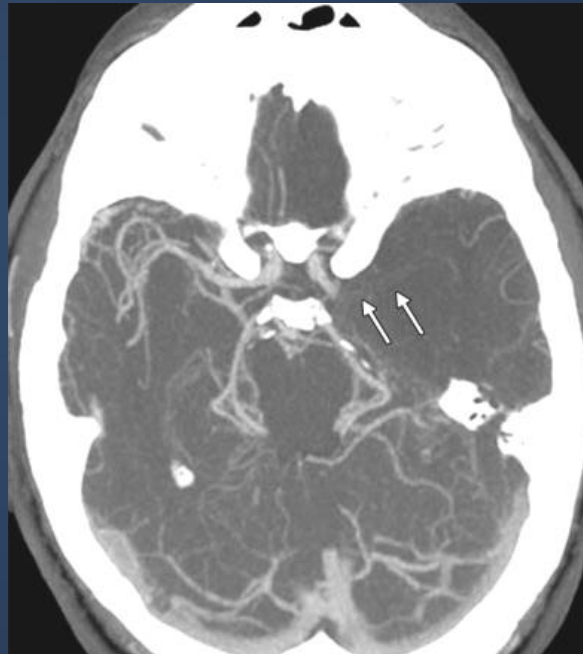

# CT SCAN..



## CTA

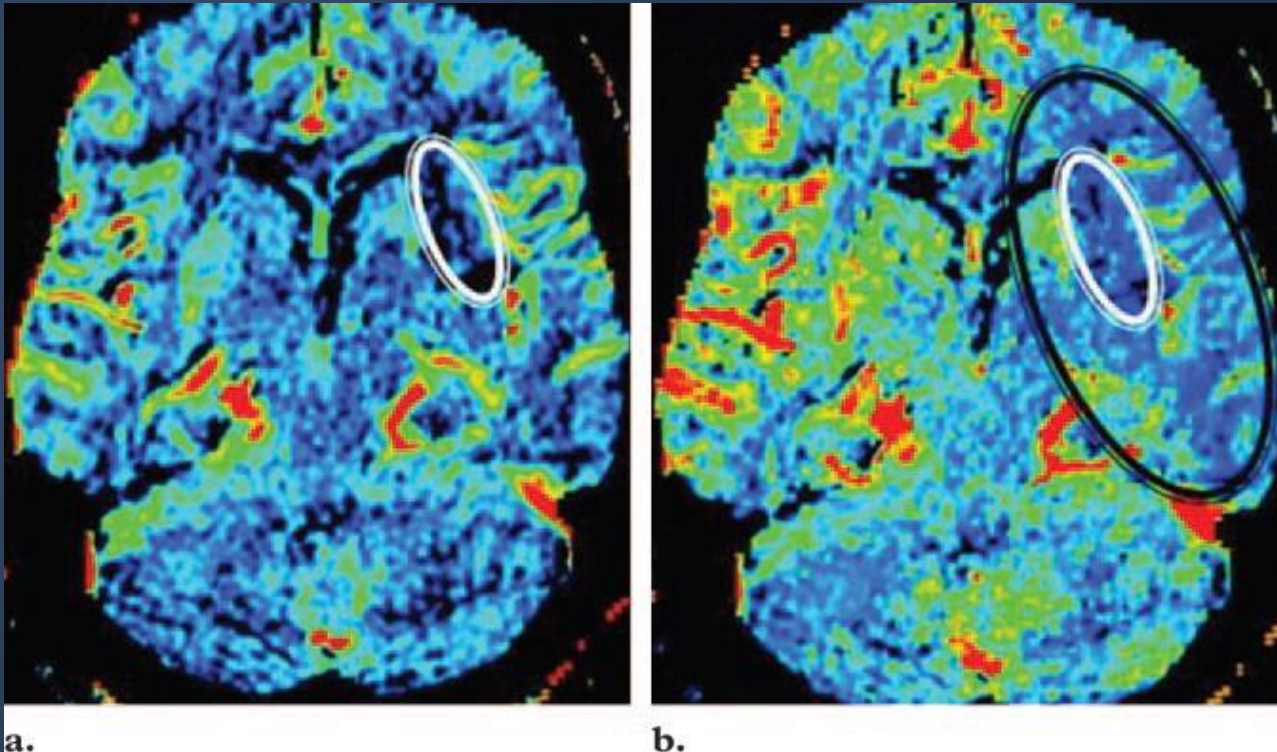
CT angiography is helpful in diagnosis of vascular diseases and abnormalities such as stenosis, occlusion or vascular malformation



Occlusion of left middle cerebral artery

# CT SCAN..

## CT PERFUSION



cerebral blood volume

cerebral blood flow

# CT SCAN..



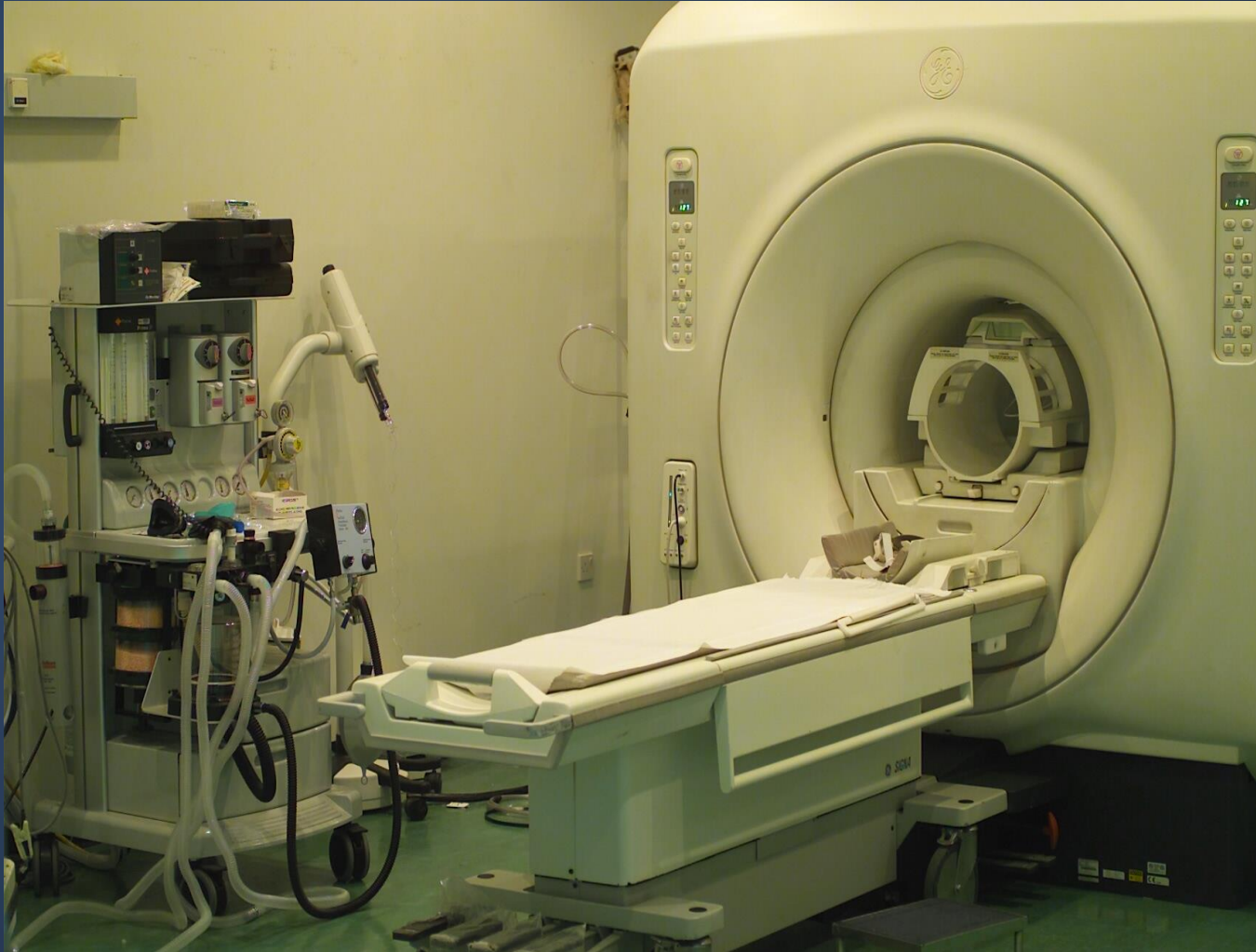## CT PERFUSION

In acute stroke, very early cranial CT may be normal. Perfusion CT shows great promise in refining the selection of patients suitable for thrombolysis, as it can accurately determine infarct core from potentially salvageable ischaemic penumbra.

Some cerebral tumours are associated with angiogenesis and a breakdown of the blood-brain barrier. Angiogenesis can be detected as an increase in flow and volume parameters, and blood-brain barrier breakdown can be quantified as contrast accumulates in the interstitial space. Such aggressive features can distinguish malignant from benign tumours when standard imaging may not.



# MRI..



# MRI..



- No ionizing radiation
- Patient preparation: Nil unless fasting for general anaesthesia.
- Contrast medium: Gadolinium
- Indications:
  - strokes
  - tumours
  - infection
  - Vascular disorders
  - white matter disease
  - some cases of trauma

# MRI..



## Contraindications

**intraocular ferrous foreign body**

**neurostimulators ???/**

**pregnancy (1<sup>st</sup> trimester) ????**

**claustrophobia ?????**

**cardiac pacemaker, cochlear implants,  
ocular prostheses**

# MRI..

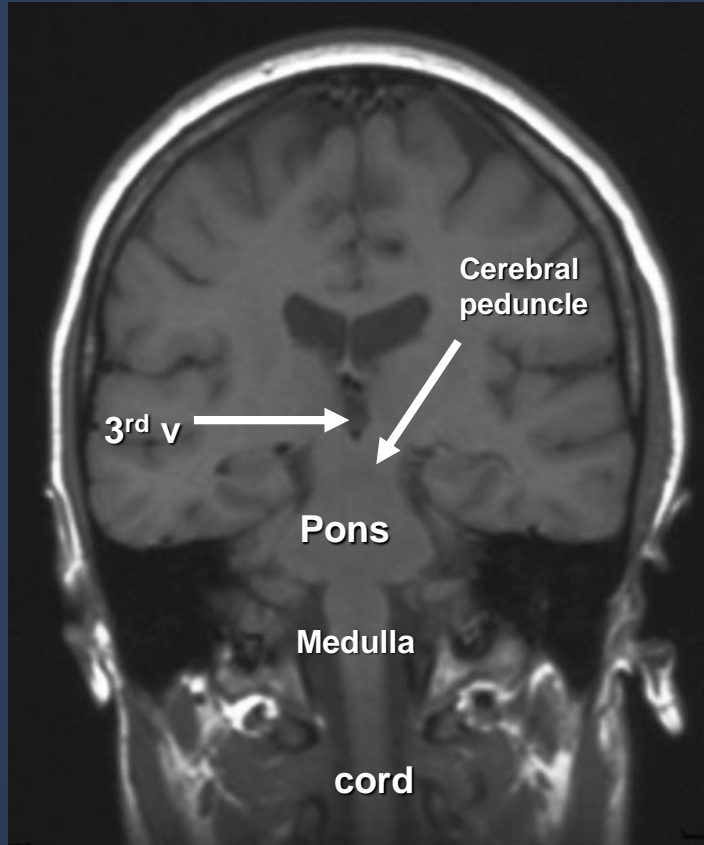


MRI is a multi planar technique (can produce images in Sagittal, axial and coronal planes) which is useful for assessment of extent of brain tumors and for better visualization of structures of posterior fossa and cranio-cervical junction.

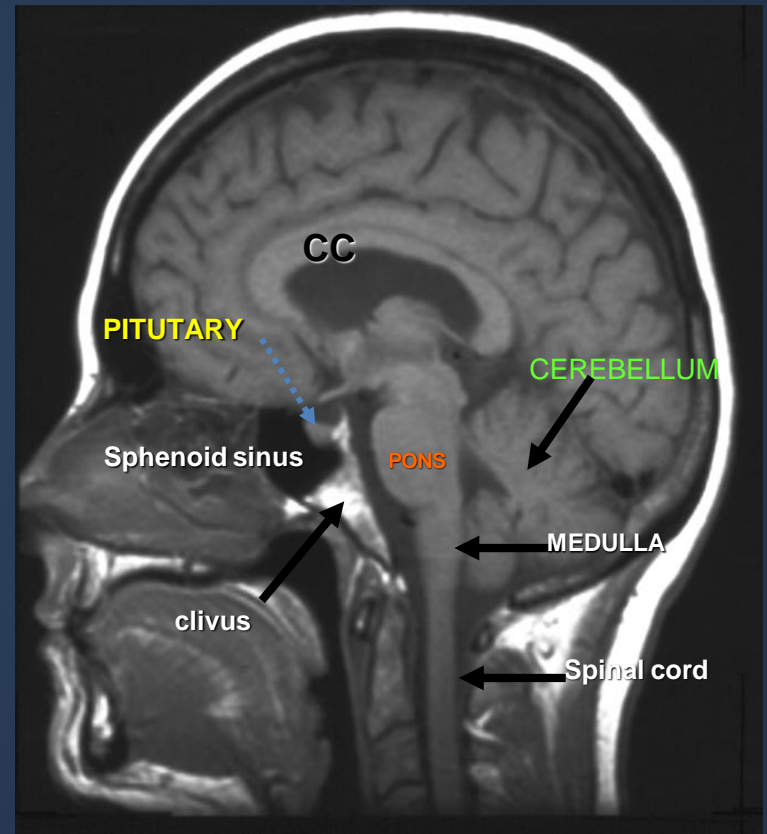
MRI is a multi sequential technique (can create images in T1WI, T2WI, FLAIR, gradient and other sequences).

It is possible to recognize flowing blood and therefore large arteries and veins stand out clearly without the need for contrast medium injection.

# MRI..

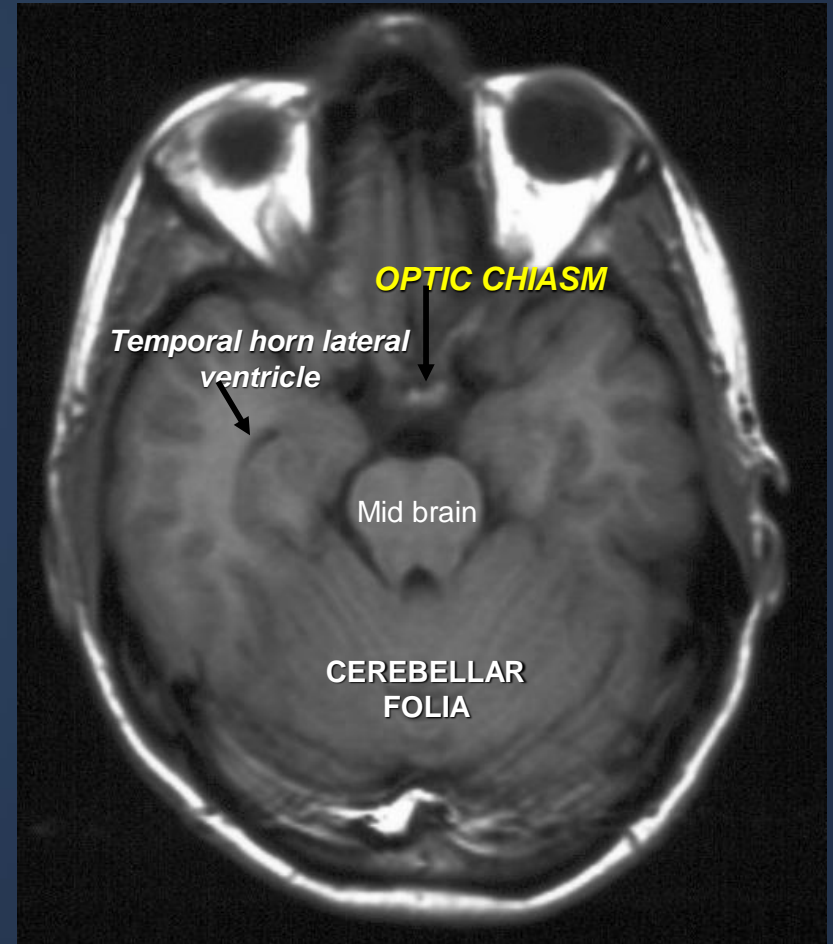
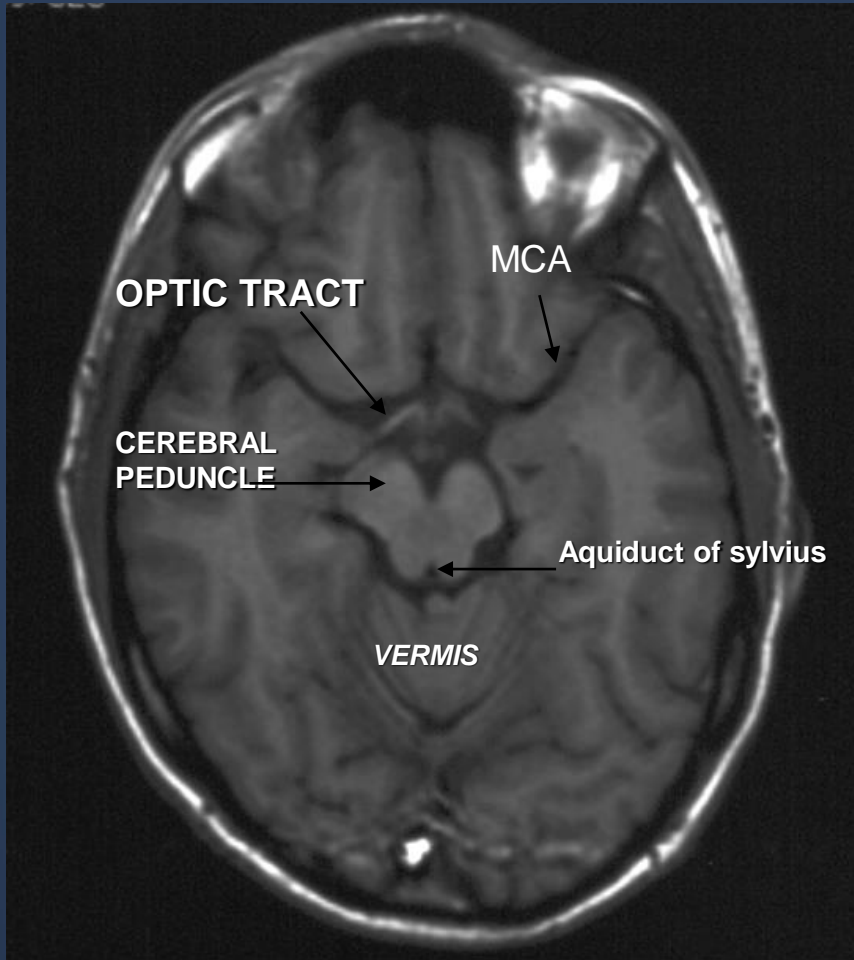


MRI BRAIN (CORONAL T1WI)



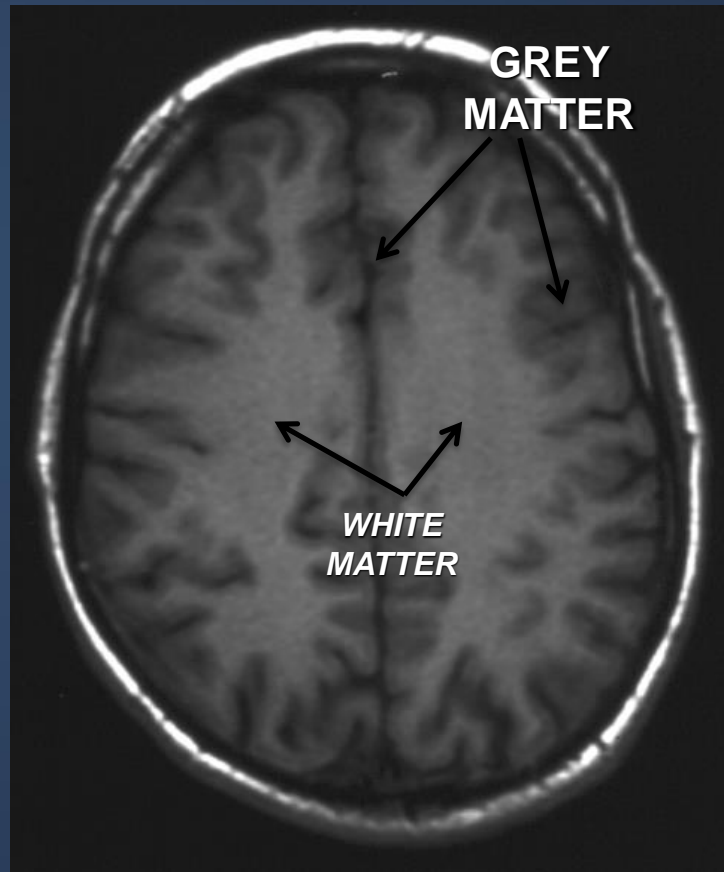
MRI BRAIN (SAGITTAL T1WI)

# MRI..



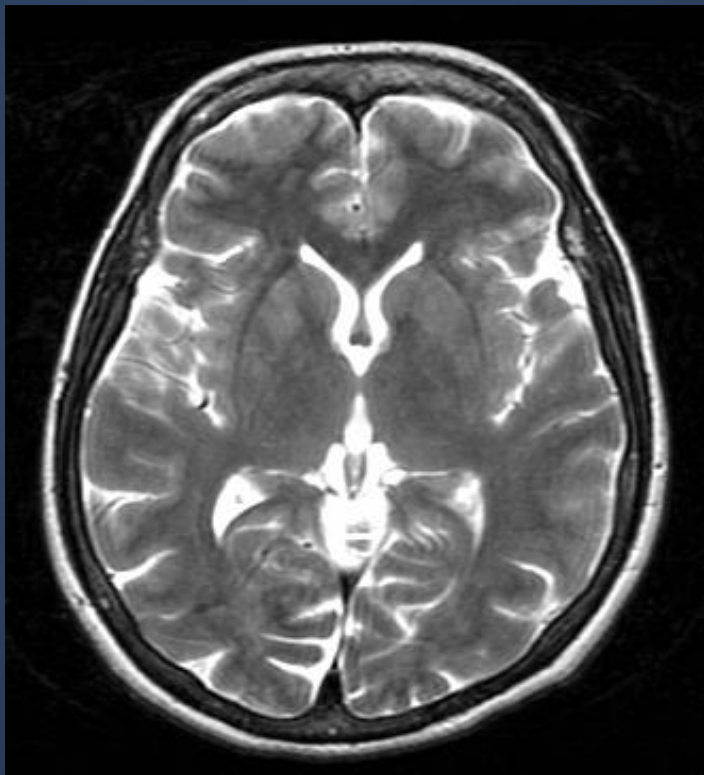
MRI BRAIN (AXIAL T1WI)

# MRI..

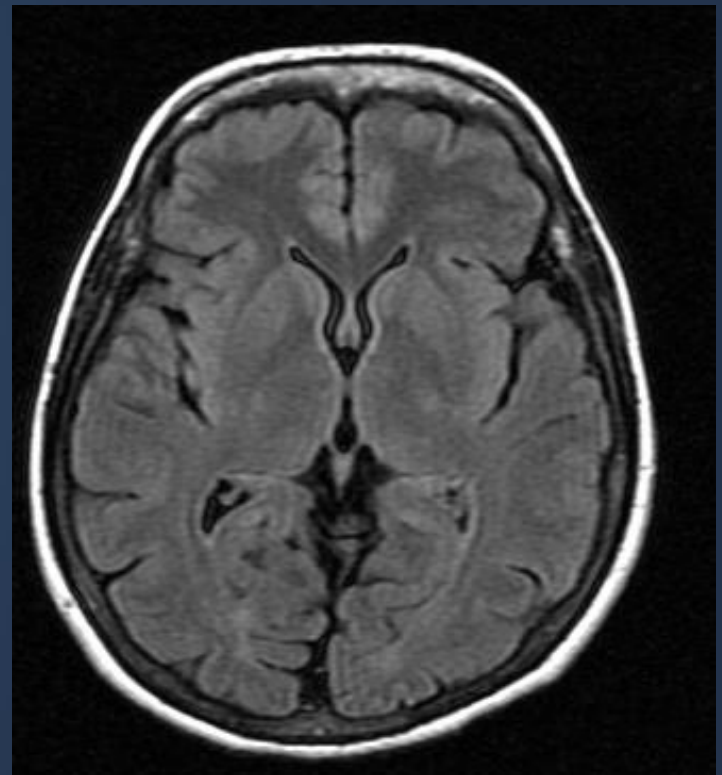


**MRI BRAIN (AXIAL T1WI)**

# MRI..



**T2WI**



**FLAIR**



# MRI..



The Characteristic signal intensity of brain structures in different MRI sequences:

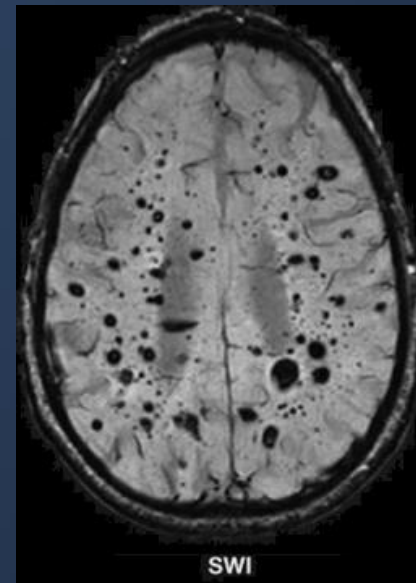
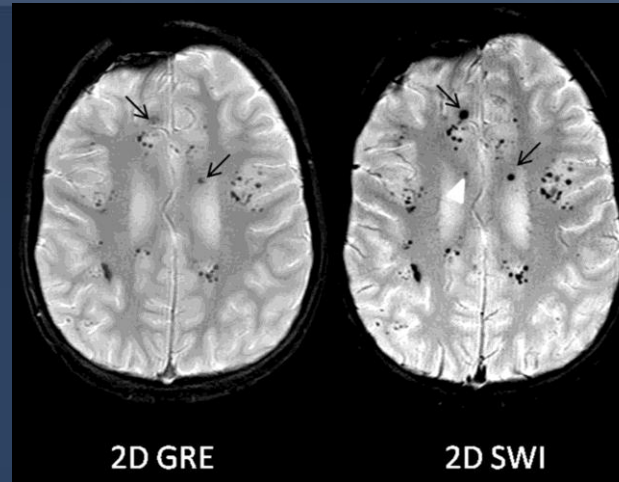
	Grey matter	White matter	CSF
T1WI	grey	light	dark
T2WI	light	dark	white
FLAIR	light	dark	dark

# MRI..

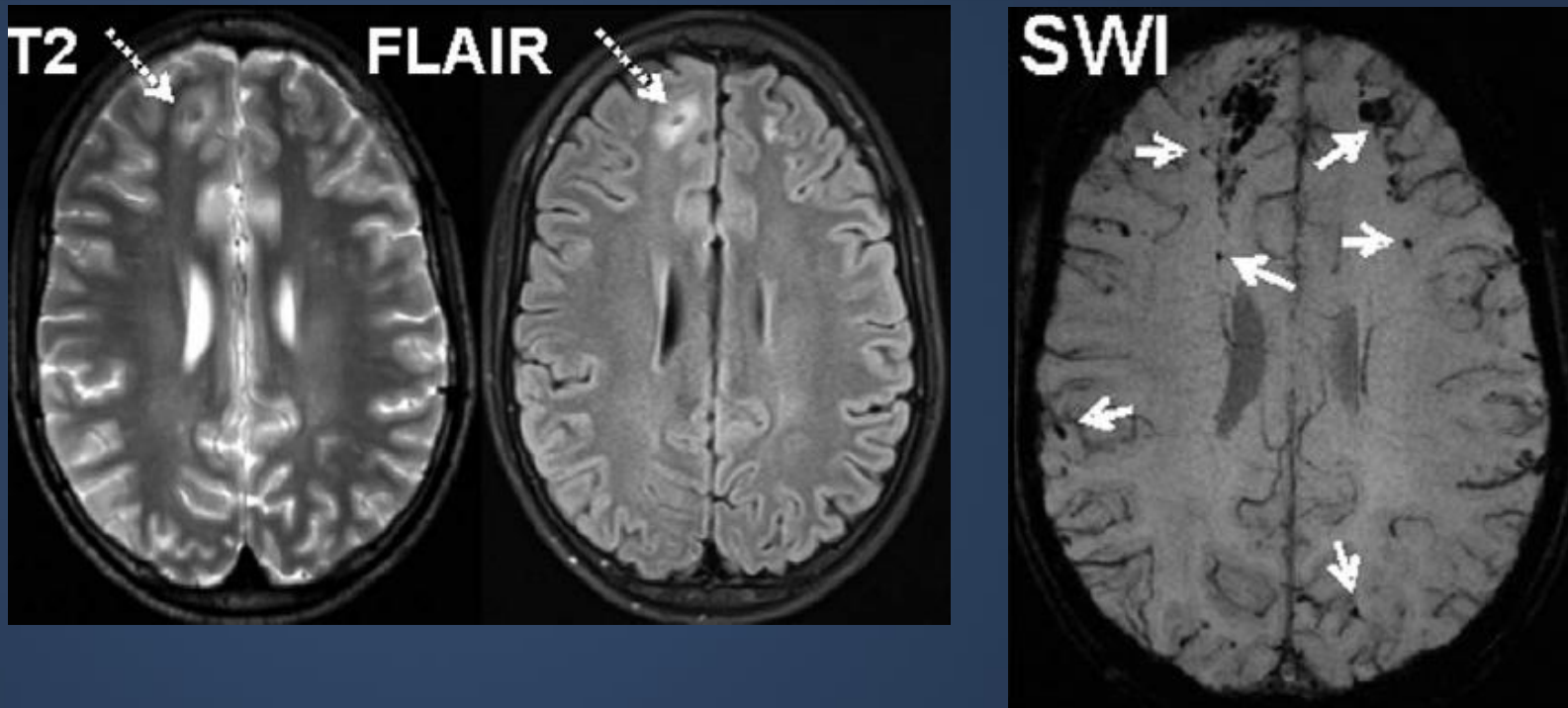
## Susceptibility Weighted Sequence

Signal loss due to

- Paramagnetic
- Diamagnetic
- Calcium
- Blood



# MRI..



Patient post RTA with diminished level of consciousness the SWI shows multiple foci of dark signal intensity (blooming) at grey-white matter interface (not seen in T2WI and FLAIR) representing hemorrhagic diffuse axonal injuries.

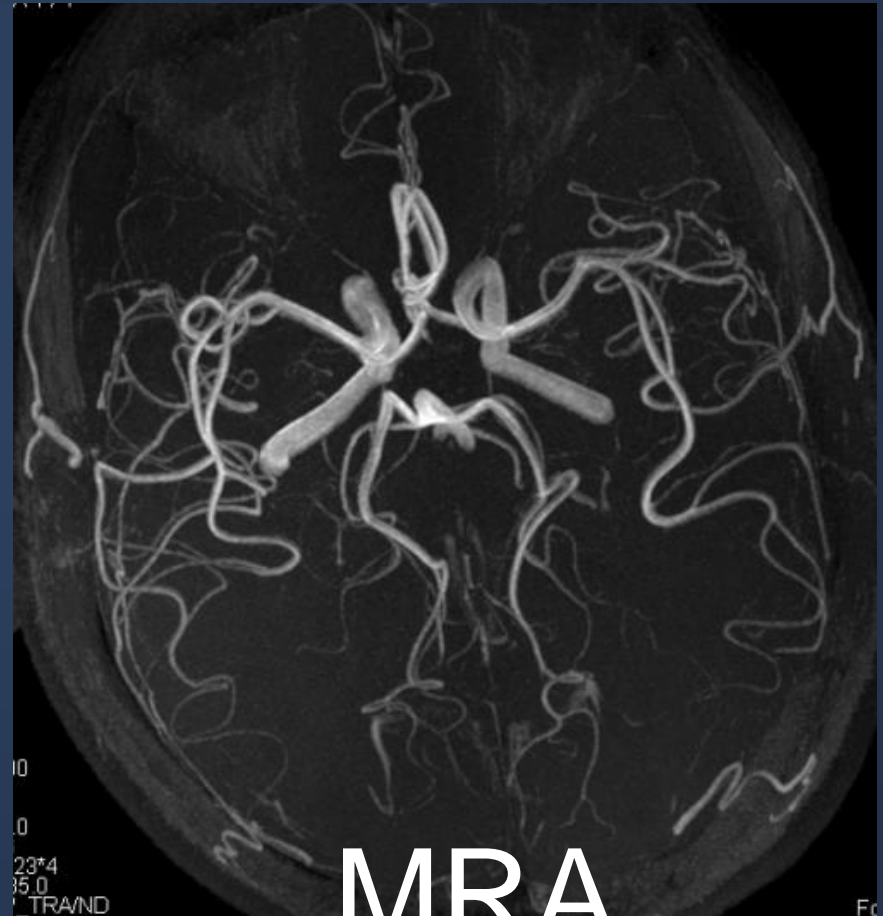
# MR Angiography..



## MRA

Can be done without injection of contrast medium using time of flight technique.

Can be used to assess intra and extra cranial arteries for any vascular abnormalities such as stenosis, occlusion or vascular malformation.



MRA

10  
0  
23\*4  
35.0  
TR/ND

Fc

# MR Venography..

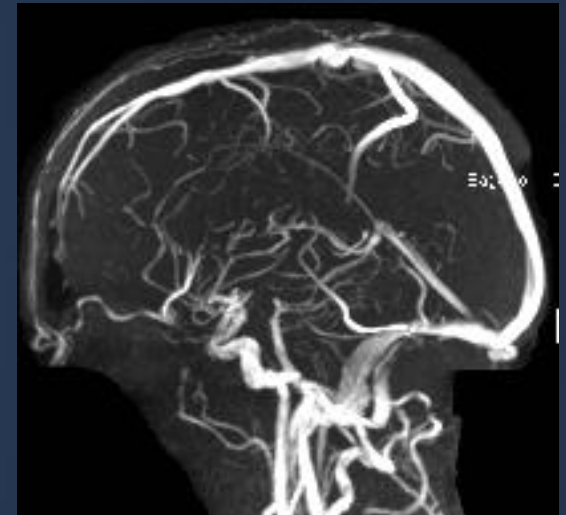
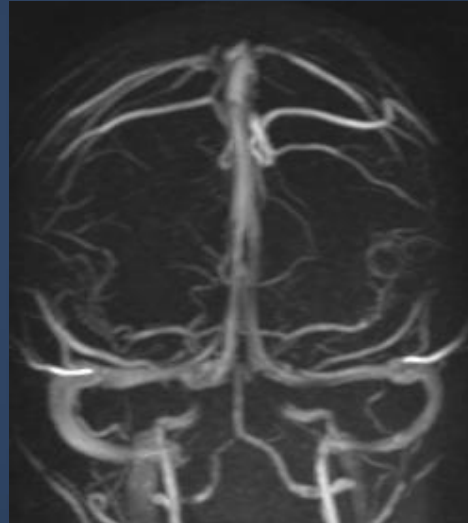


## MRV

Can be done either with or without injection of contrast medium.

Assess venous dural sinuses superficial and deep venous system.

Can confirm presence of venous thrombosis



## MRV

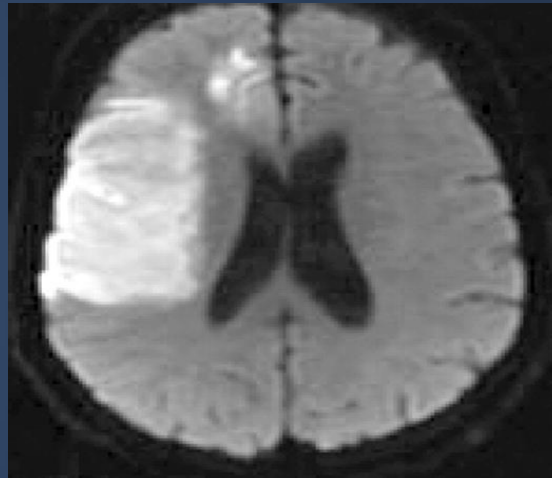# MRI Diffusion..



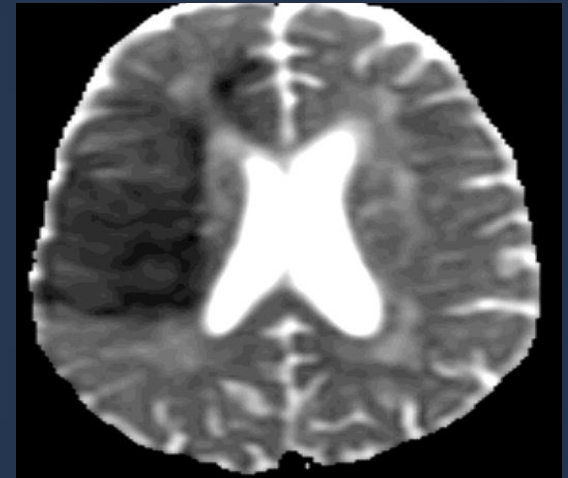
## MR diffusion

Very helpful in assessment of:

- Early brain infarction.
- Brain abscess.
- Certain types of brain tumor.



DWI

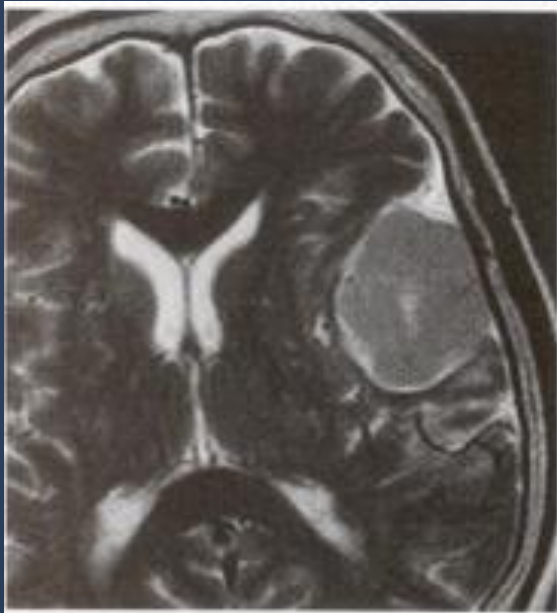


ADC map

# MRI..

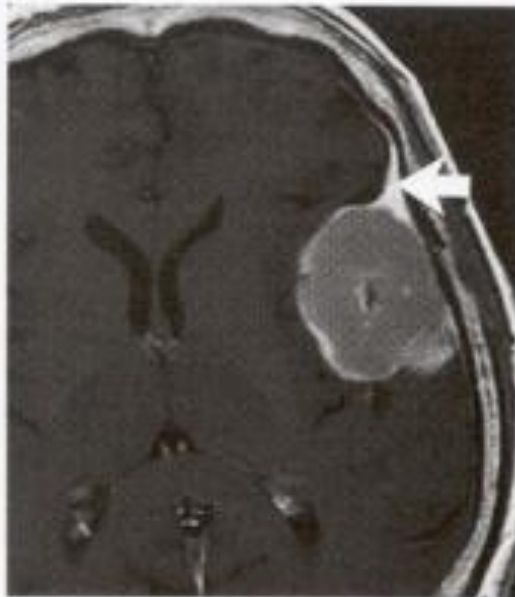


## Meningioma



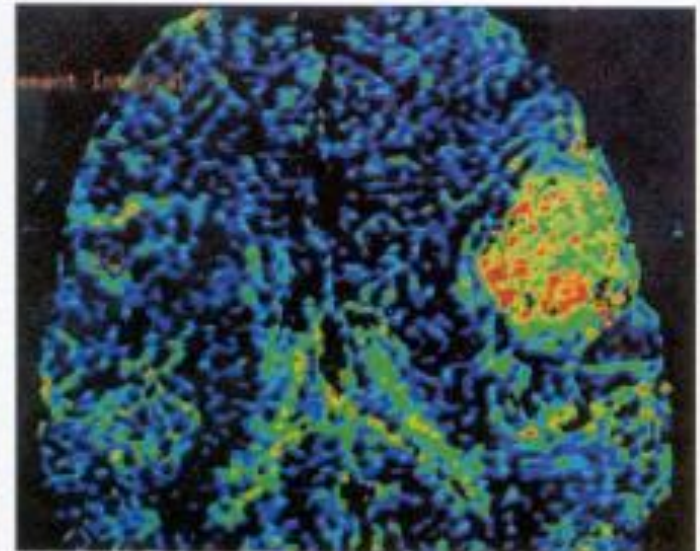
A

T2



B

Contrasted T1



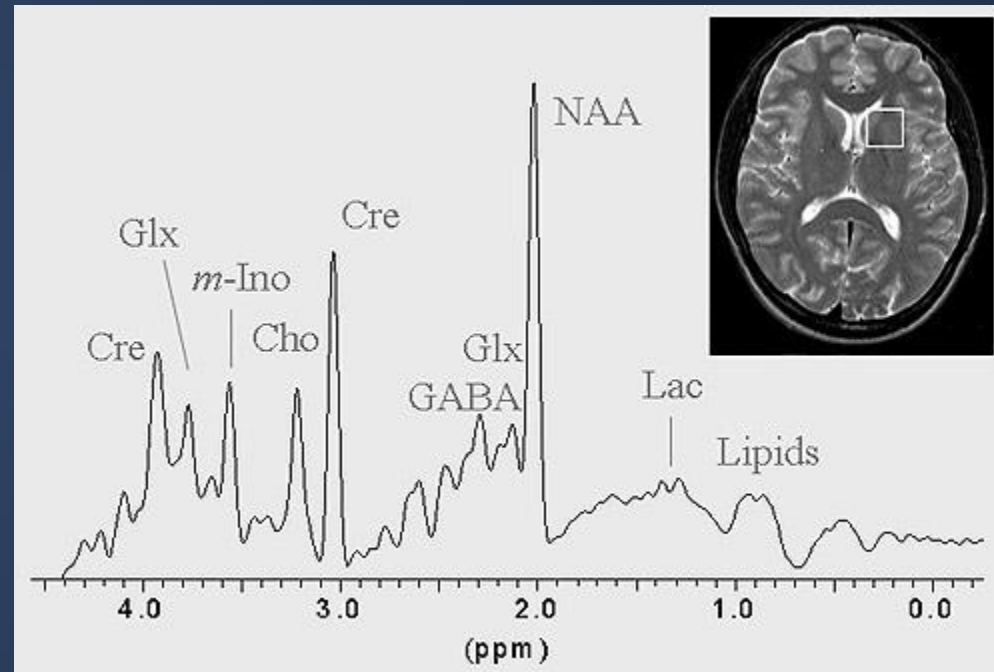
C

Perfusion-Weighted

# MR Spectroscopy..



Unlike MRI, the technique of MRS does not generally produce images, instead creating spectra (see figure). Each peak in the spectrum arises from different brain metabolite (NAA, N-acetylaspartate; Cre, Creatine; Cho, Choline; *myo*, *myo*-Inositol; Lac, lactate; Glx, Glutamate and Glutamine; GABA, gamma amino butyric acid). The height of each peak is an indication of metabolite concentrations. The NAA peak arises from the neurons in the brain. Loss of this metabolite indicates damage or loss of neurons.



Investigations of brain injury by magnetic resonance imaging (MRI) and spectroscopy (MRS)

Prof Andrew M. Blamire

Newcastle Magnetic Resonance Centre Newcastle University, Campus for Ageing & Vitality Newcastle upon Tyne, NE4 5PL United Kingdom.



# MR Spectroscopy..

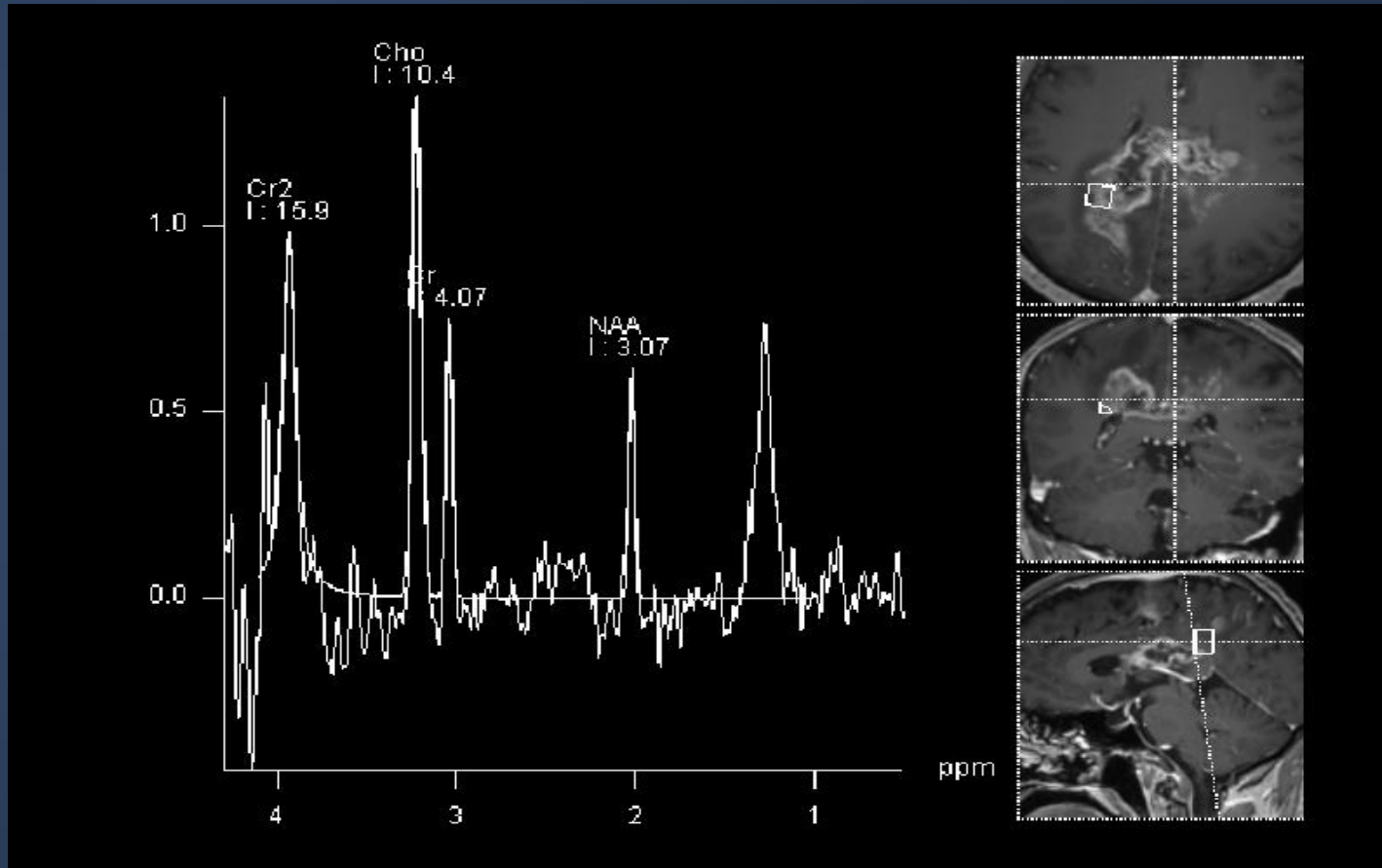


## MR Spectroscopy

Very helpful in:

- Differentiating neoplastic from non neoplastic processes.
- Differentiating benign from malignant tumors.
- Determination of certain types of tumors.
- Assessment of white matter diseases
- Assessment of neurodegenerative diseases

# MR Spectroscopy..



MR Spectroscopy in GBM

# CEREBRAL ANGIOGRAM..



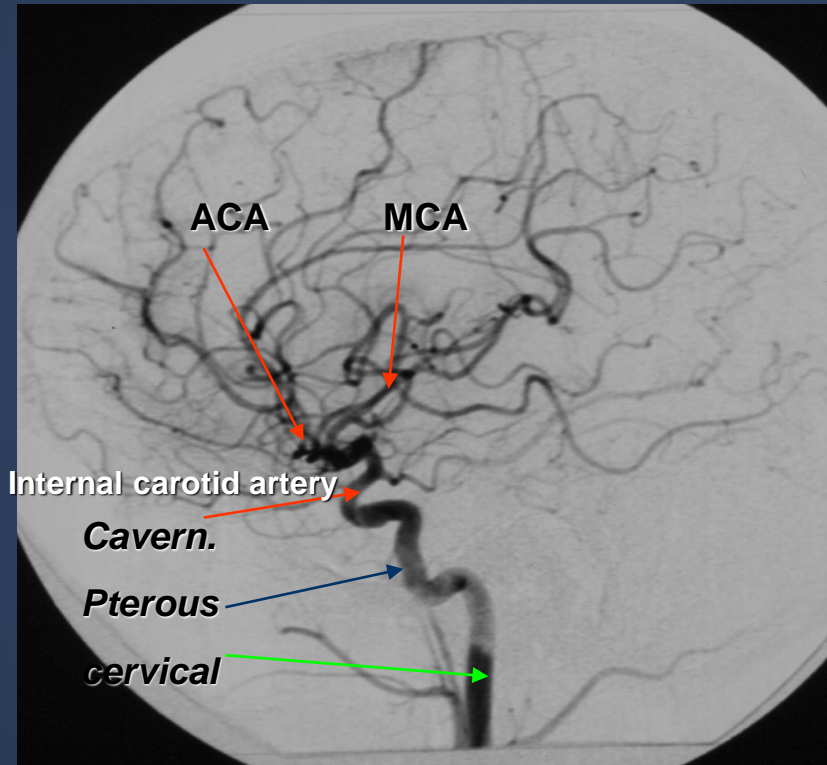
It is the gold standard technique for assessment of intra and extra cranial vessels.

It can demonstrate different vascular diseases (stenosis, occlusion, vascular malformation and blood supply of brain tumors).

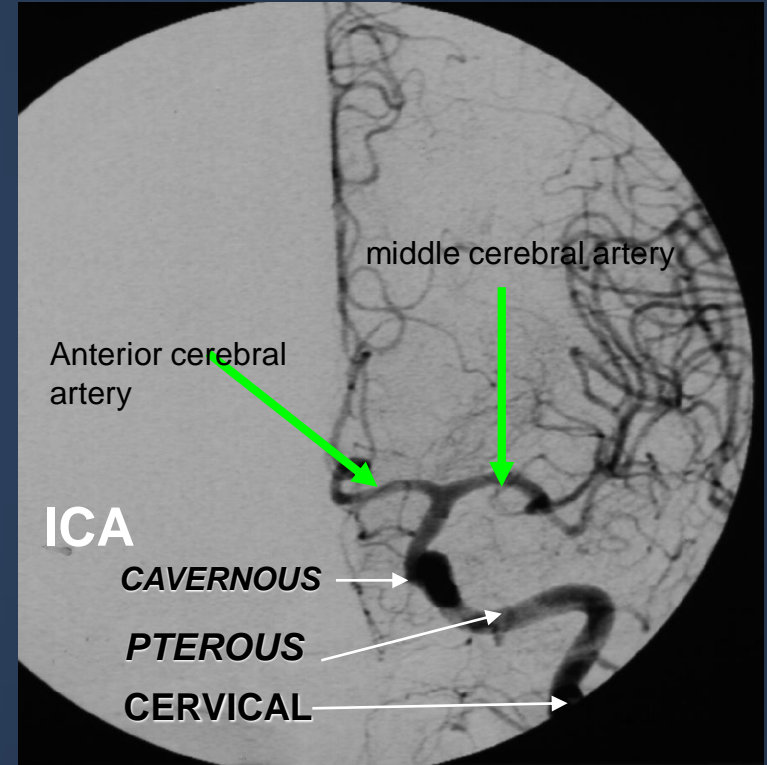
It is an invasive technique.

Recently its main role for intervention purposes such as treatment of vascular malformation (aneurysm/arterovenous malformation) or pre operative embolization of vascular supply of tumor.

# CEREBRAL ANGIOGRAM..

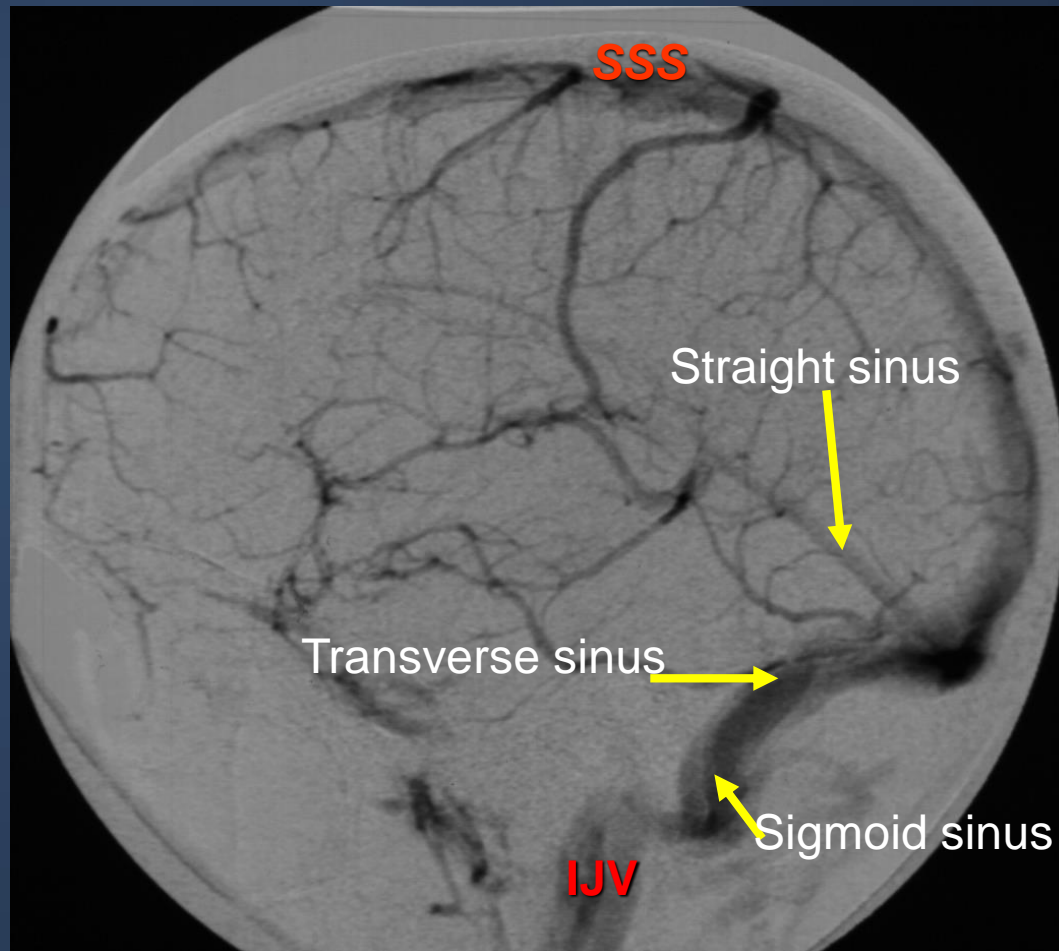


Internal carotid angiogram lateral view

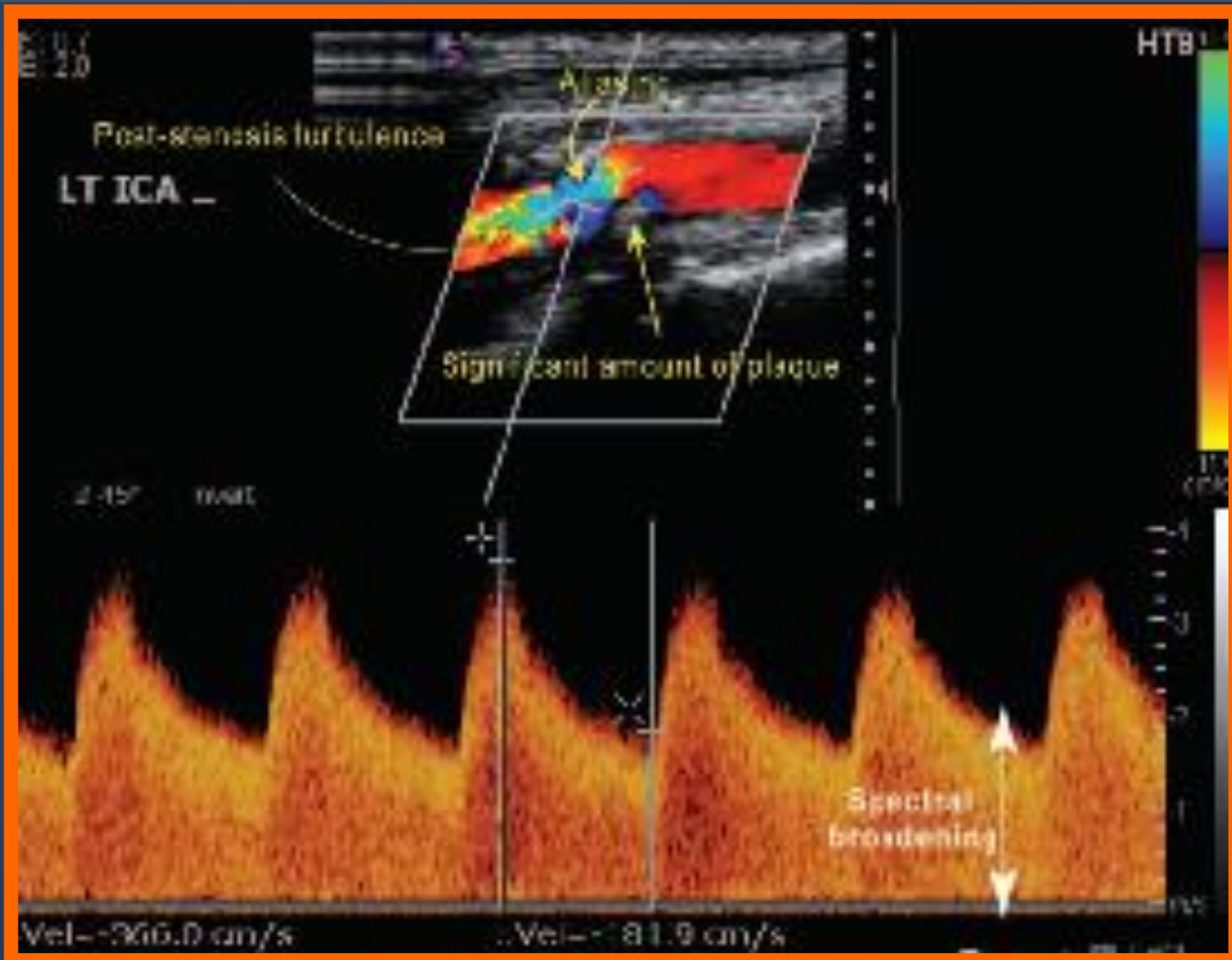


Internal carotid angiogram AP

# VENOUS PHASE CEREBRAL ANGIOGRAM..



# CAROTID DOPPLER..



# ULTRASOUND NEONATAL BRAIN..



**It is a simple and easy way to scan the head of neonates and young babies.**

**Not using ionizing radiation**

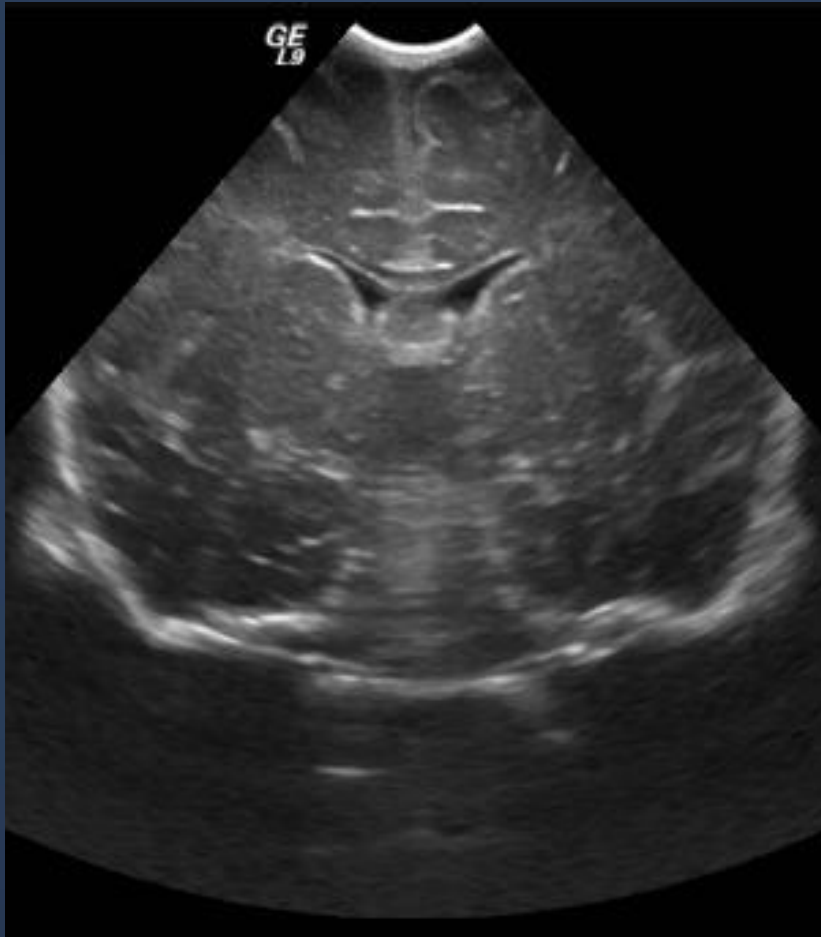**Scanning is best done through an open fontanelle.**

**Little discomfort to the baby.**

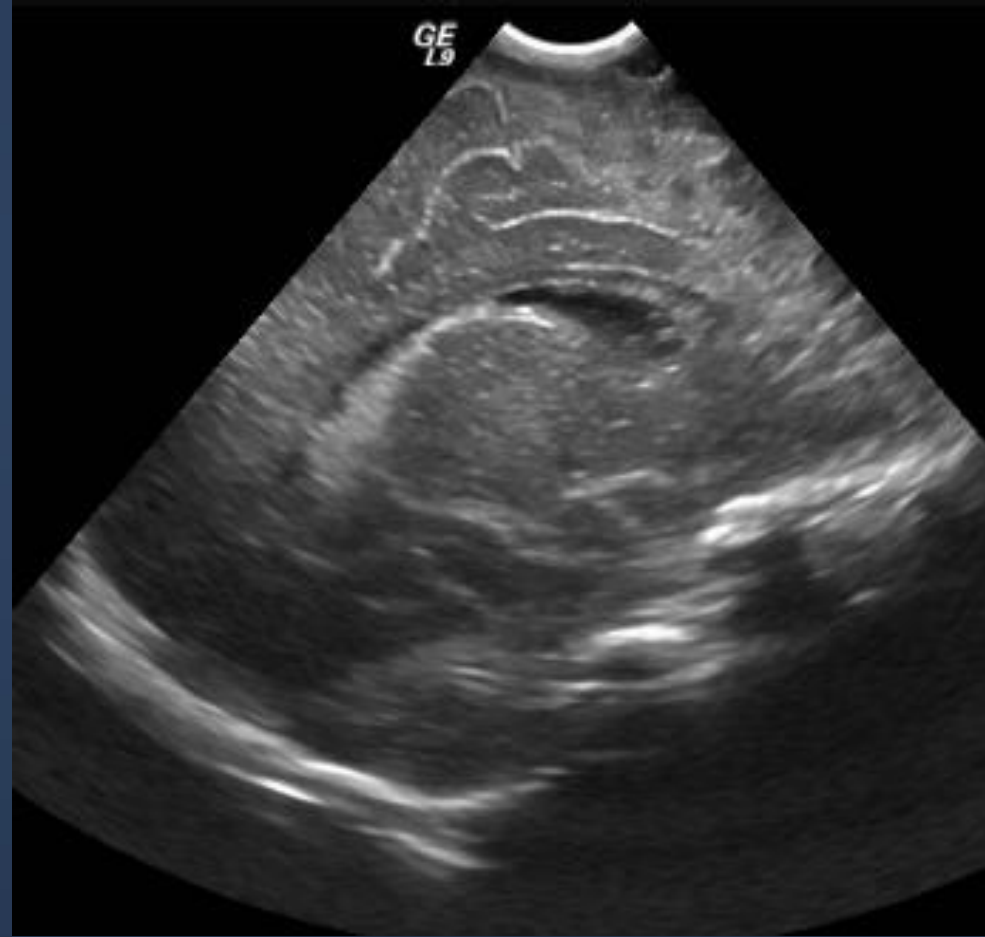
**Readily carried out even on ill babies in intensive care units.**

**It has proved particular useful in detecting ventricular dilatation (hydrocephalus), intracerebral hemorrhage and congenital abnormality of the brain**

# ULTRASOUND NEONATAL BRAIN..



CORONAL



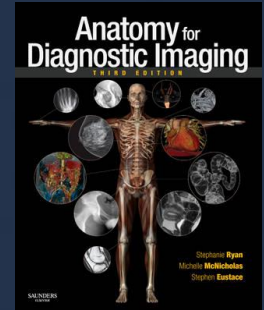
SAGITTAL



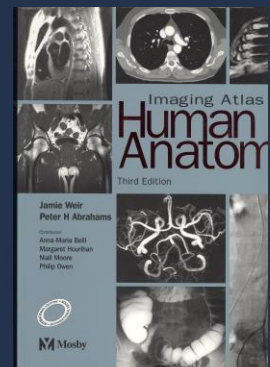
# Reference book and the relevant page numbers..



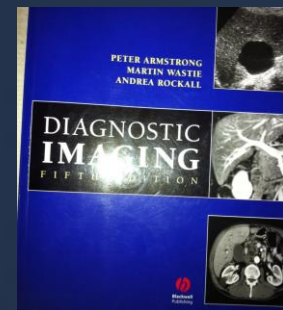
- Stephanie Ryan, “Anatomy for Diagnostic imaging”, 2<sup>nd</sup> Edition, Pages 61-66



- Jamie Weir, Peter Abraham, “Imaging Atlas of Human Anatomy” 3rd Edition, Pages 34-41



- Peter Armstrong, “diagnostic imaging”, 5<sup>th</sup> Edition, Pages (396-404)





# Thank You 😊

(Rad 366, Radiology)

Dr. fahad albadr