



Pleural Effusion

Objectives:

- Describe the pathophysiology of a pleural effusion
- Describe the main causes of a pleural effusion
- Differentiate among the manifestations of fluid collections
- Describe the signs and symptoms of a pleural effusion
- Explain diagnostic methods
- Describe the various treatment options

Team Members: Khalid Aleisa, Hanin Bashaikh, Abdulmalik Alhadlaq, Ghada AlMazrou

Team Leaders: Nora AlSahli

Revised by: Maha AlGhamdi

Resources: 436 Slides, 435 team, Davidson, Kumar, Step up to medicine

- [Editing File](#)
- [Feedback](#)

● Definition:

○ Pleura:

- Serous fluid [5-15 ml] that allows for the parietal pleura (outer lining) and visceral pleura (inner lining) to glide over each other without separation.
- **Produced** by the parietal Pleura, **absorbed** and **drained** by visceral Pleura
- **100-200ml** of fluid circulates through the pleural space within a 24-hour period
- Function: Pleural fluid helps in lubrication and prevents atelectasis¹.
- $\geq 250\text{ ml}$ of pleural fluid is pathological (below it is acceptable).
- Patients with pleural effusion will present with: Chest pain and SOB.
- What are the physical signs of pleural effusion?
 - 1- Dullness on percussion.
 - 2- Shifted trachea to the other side.
 - 3- Asymmetrical chest expansion.
 - 4- Decreased tactile fremitus.

Pleural Effusion

● Pleural Effusion:

Pleural effusion is an excessive accumulation of **serous fluid** within the **pleural space**, which can be detected on PA X-ray when $\geq 300\text{ ml}$ of fluid is present and clinically when $\geq 500\text{ ml}$ is present.

It is most commonly a unilateral effusion.

○ The accumulation of:

- **frank² pus** is termed **empyema**,
- **blood** is **haemothorax**,
- **chyle³** is a **chylothorax⁴**.

○ This accumulation can be caused by one of the following mechanisms:

- Increased production of fluid by cells in the pleural space.
- Increased drainage of fluid into pleural space.
- Decreased drainage fluid from the pleural space.

¹ the collapse or closure of a lung resulting in reduced or absent gas exchange

² unmistakable; obvious

³ A milky fluid containing fat droplets which drains from the lacteals of the small intestine into the lymphatic system during digestion.

⁴ It results from lymph formed in the digestive system called chyle accumulating in the pleural cavity due to either disruption or obstruction of the thoracic duct.

● **Pleural Effusion types:**

	Transudative pleural effusion⁵	Exudative pleural effusion⁶
<p>Pathophysiology (don't bother about it, just know that there are different mechanisms for pleural effusion)</p>	<p>→ Due to elevated capillary hydrostatic pressure in visceral or parietal pleura (e.g., CHF)</p> <p>→ Due to decreased plasma oncotic pressure (e.g., hypoalbuminemia)</p> <p>→ Due to increased intrapleural pressure (eg. atelectasis).</p>	<p>→ ↓ lymphatic flow from pleural surface due to a damage to pleural membranes or vasculature.</p> <p>→ ↑ capillary permeability (eg. Pneumonia)</p> <p>→ ↑ pleural membrane permeability (eg. malignancy)</p> <p>→ Thoracic Duct rupture (eg. Chylothorax)</p> <p>→ Lymphatic Obstruction (eg. malignancy)</p>
<p>Main causes and types of fluid</p>	<p>The causes of the majority of pleural effusions are identified by a thorough history, examination and relevant investigations.</p>	
	<p style="text-align: center;">The Big Organs</p> <ol style="list-style-type: none"> Cardiac failure: Serous fluid, straw-coloured Liver: Cirrhosis: Movement of ascitic fluid from the peritoneal cavity into the pleural space through diaphragmatic defects. Renal: Nephrotic syndrome. Thyroid: Hypothyroidism. <p>Others: ovarian tumours producing right-sided pleural effusion - Meigs' syndrome.</p> <p>Pulmonary embolism can cause both exudate and transudate (doctor said this is for your information)</p>	<ol style="list-style-type: none"> Bacterial Infections: <ol style="list-style-type: none"> Tuberculosis (chronic): <ul style="list-style-type: none"> - Fluid is serous, usually amber-coloured, - Fluid contains predominantly Lymphocytes (The diagnostic test for pleural TB is pleural biopsy) Pneumonia (acute): Parapneumonic effusion⁷ may lead to empyema Malignancy: <ul style="list-style-type: none"> - Serous, often blood stained, - Serosal cells and lymphocytes, - Often clumps of malignant cells. Inflammatory Diseases: Collagen Vascular Disease (also called connective tissue disease) <ul style="list-style-type: none"> - Rheumatoid Disease, - SLE وأخواتها (Serous, Lymphocytes are the predominant cells) Pulmonary infarction: <ul style="list-style-type: none"> - Serous, or blood stained, - Fluid contains: Red blood cells and Eosinophils Viral infection. Others: idiopathic pleural effusion, drugs (hydralazine).
<p>★ Light's criteria for distinguishing pleural transudate from exudate: (Important). 98% sensitive and 83% specific for exudative effusion using Light's criteria. Exudative effusions have <u>at least one</u> of the following (<i>transudates have none of these</i>):</p> <ul style="list-style-type: none"> ● Protein (pleural)/protein (serum) >0.5 for example, you have a pleural fluid with protein level 40, and serum with protein level 20, the total is 0.5 and it is exudative pleural effusion because it should exceeds 0.5. ● LDH (pleural)/LDH (serum) >0.6 ● LDH > two-thirds the upper limit of normal serum LDH (same concept in point 2) 		

⁵ The protein content is less than 30 g/L and the lactic dehydrogenase is less than 200 IU/L and/or the fluid to serum ratio is <0.6.

⁶ The protein content of exudates is > 30 g/L and the lactic dehydrogenase is > 200 IU/L. (e.g, Bacterial pneumonia, tuberculosis (TB), Malignancy, metastatic disease, Viral infection)

⁷ pleural effusion in the presence of pneumonia



○ **The most common causes are:**

1. **CHF** is most common cause.
2. **Pneumonia** (bacterial)
3. **Malignancies**: lung (36%), breast (25%), lymphoma (10%)
4. **Pulmonary embolism** (PE)
5. Viral diseases
6. Cirrhosis with ascites

Manifestations of Fluid Collections

(To differentiate between empyema and complicated parapneumonic effusion look at the color; empyema has pus (~yellow) while parapneumonic effusion is turbid)

THE 5 C's: (very important)

(when I have pleural effusion, I will get the fluid and look for the 5C's)

1. **Cytology**: to tell you if there's **malignancy** or not e.g. cells of **metastatic** adenoma from the breast.

2. **Culture**: for diagnosis of **Parapneumonic** effusion, **Empyema**, **TB**

3. **Cell count**: look for the **DDx depending on the predominant** cells (not the total number of WBC):

Lymphocytes (chronic) (think about the causes for red color)	<u>Malignancy, TB, Connective tissue disease</u> (e.g. sarcoidosis, SLE) & trauma or bleeding. Predominant (>60%) lymphocytes = red color
--	--

Neutrophils (PMN) (acute)	<u>Parapneumonic (Acute infection), Empyema, Rheumatoid</u> or Pulmonary infarction
----------------------------------	---

Eosinophils	<u>Lymphatic obstruction, Fungal Infection, Allergy, Drugs</u> (e.g. hydralazine). Others: Trauma, pneumothorax, CA, Asbestos, parasites, Pneumonia Predominant eosinophils = Green color
--------------------	--

RBC > 100,000/mm	Malignancy, Trauma, Pulmonary infarction
----------------------------	--

4. Color/Character: pleural fluid is normally colorless (transparent)

Red (Important)	Exudative effusions that are primarily lymphocytic: Blood (Hemorrhagic effusion/trauma), Malignancy, TB (chronic infection), Connective tissue disease. How to know if this blood is hemothorax or iatrogenic? We divide the hematocrit level in the pleura by the hematocrit level in the blood, if it is $\geq 50\%$ = hemothorax (blunt)
------------------------	---

Green	Fungal infection
--------------	-------------------------

White/Milky	Lymphatic obstruction as in Lymphoma, Thoracic duct injury, Chylothorax (lymph in the pleural space)
--------------------	--

Yellow	Any of the mentioned causes above can cause yellow "it's the most common color".
---------------	---

Turbid بالعربي عكر	Acute infection = Pneumonia (Parapneumonic effusion)
---------------------------	---

زي الطباشير	Acute infection will give you turbid while chronic infection (TB) will give you red
Black	Aspergillus niger and Rhizopus oryzae, metastatic melanoma, Read more
Brown/Roasted	→ Pus → Empyema . So how to differentiate between Empyema and Parapneumonic effusion? By appearance and color: Parapneumonic = Turbid empyema = PUS
5. Chemistry: To minimize your DDX.	
PH (< 7.2), Glucose, Protein & LDH (for light's criteria)	In general, pleural fluids with a low glucose level also have low pH and high LDH⁸ levels (Exudate), as in infections (parapneumonic effusion or empyema), connective tissue disease, TB and malignancies, esophageal rupture, pancreatitis.
Amylase	Elevated pleural fluid amylase : esophageal rupture, pancreatitis, malignancy.

Pleural fluid pearls	
Condition	Suggests
Elevated pleural fluid amylase	Esophageal rupture, pancreatitis, malignancy.
Milky, opalescent fluid	Chylothorax (lymph in the pleural space)
Frankly purulent fluid	Empyema (pus in the pleural space)
Bloody Effusion	Malignancy
Exudative effusions that are primarily lymphocytic	TB
pH < 7.2 (most important indication for inserting chest drain)	Parapneumonic effusion⁹ or empyema

- **Empyema:** (pus within the pleural space)

Exudative pleural effusions **-if left untreated-** can lead to empyema, which means the pleural effusion is **infected**.

- The Pus may be as thin as **serous fluid** or so **thick** that it is impossible to aspirate
- **Most cases** occur as a **complication of bacterial pneumonia¹⁰** (parapneumonic effusion).
- Empyema may involve the whole pleural space or only part of it ('loculated' or 'encysted' empyema).

- ◆ **Clinical features:** The clinical features are those of the underlying disease (most commonly pneumonia).
- ◆ **Diagnosis:** CXR¹¹ and CT scan of the chest are the recommended tests.
- ◆ **Treatment:** aggressive drainage of the pleura (via thoracentesis) and antibiotic therapy.

- If the condition is not adequately treated, pus may rupture into a bronchus, causing a bronchopleural fistula and pyopneumothorax.

To differentiate empyema from complicated parapneumonic effusion we look at the color. If it is pus (usually very yellow, but not always) then it is empyema. If it is Turbid, then it is parapneumonic.

19.17 Clinical features of empyema	
Systemic features	
<ul style="list-style-type: none"> • Pyrexia, usually high and remittent • Rigors, sweating, malaise and weight loss • Polymorphonuclear leucocytosis, high CRP 	
Local features	
<ul style="list-style-type: none"> • Pleural pain; breathlessness; cough and sputum, usually because of underlying lung disease; copious purulent sputum if empyema ruptures into a bronchus (bronchopleural fistula) • Clinical signs of pleural effusion 	

⁸ Lactate dehydrogenase

⁹ A parapneumonic effusion is a non infected pleural effusion secondary to bacterial pneumonia.

¹⁰ Over 40% of patients with community- acquired pneumonia develop an associated pleural effusion ('parapneumonic' effusion)

¹¹ Chest X-ray appearances may be indistinguishable from those of pleural effusion.

Signs & Symptoms of Pleural Effusion

● Clinical Features: (important)

○ History / Symptoms: (Often asymptomatic)

1. Symptoms of pleural effusion:

- Pleuritic chest pain (on inspiration and coughing) (defined as pain in the lung)
- Cough
- Dyspnea (ALL patient with Pleural Effusion will present with pain and dyspnea)

2. Symptoms of the underlying cause, e.g. in CHF: Peripheral edema, orthopnea, paroxysmal nocturnal dyspnea. Or Sx related to malignancy.

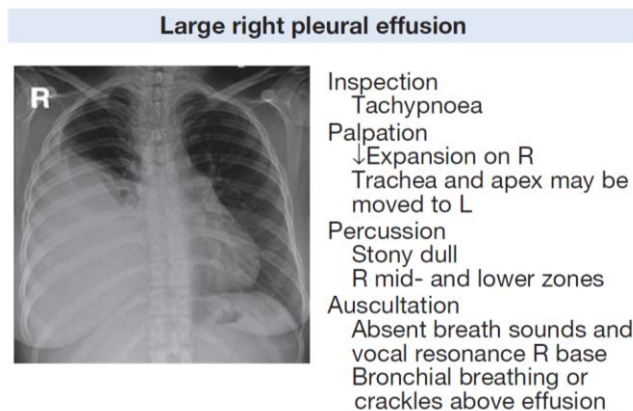
e.g. if related to pneumonia or aspiration then cough.

SLE patient: classical symptoms of SLE (rash, fatigue) + (musculoskeletal pain – joint pain) + chest pain, shortness of breath.

○ Physical examination / Signs: (very important)

(Findings usually present for effusions > 300 mL)

- **Stony dullness** to Percussion¹².
- **Reduced** tactile fremitus¹³
- Asymmetrical **chest wall expansion** → **reduced** in affected side. The side containing the fluid moves slower.
- **Decreased vesicular breath sounds** over the effusion.
- Egophony¹⁴ above the effusion.
- **Trachea will shift away** from the affected side.
- Palpation of apex beat → if the effusion was on the left side apex beat will be displaced, or if it was on the right side but there was cardiomegaly.



[Physiological & pathological breath sounds](#) 6 :03 minutes

Diagnosis

● Diagnosis:

1- History & 2- Physical examination → give 85% of diagnosis.

3- **Chest x-ray: Initial diagnostic test for pleural effusion.** (Very simple and non-invasive)

- **Postero-anterior:** Around 250-500 mL of pleural fluid must accumulate before an effusion can be detected. Look for: **blunting of costophrenic angle**¹⁵

¹² Characteristic for pleural effusion. في محاضرة الـ investigations ركز عليها الدكتور.

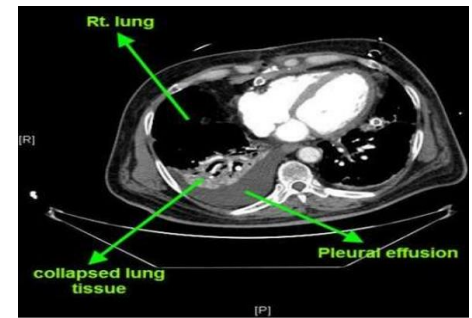
¹³ Tactile fremitus is a vibration that you can feel with the palm of your hands when someone says "blue moon" or "99". increased fremitus is a sign of consolidation. Decreased fremitus is a sign of pneumothorax or pleural effusion.

¹⁴ Is an increased resonance of voice sounds heard when auscultating the lungs, often caused by lung consolidation and fibrosis. This finding is referred to in clinical contexts as the "E to A transition."

- **Lateral decubitus films** (patient lying on one side): very sensitive, can detect effusions as small as 50 mL. (it is old, not used anymore)

4- CT scan: What's the indication for CT in pleural effusion?

- CT scanning is indicated where **malignant disease** is suspected.
- Better characterization of underlying lung parenchyma and certain processes that may be obscured on radiographs by large pleural effusions. E.g. consolidation or masses. More reliable than CXR for detecting effusions.
- To detect the underlying cause, PE, ovary masses could cause pleural effusion (meigs syndrome)¹⁶
- Gold standard for detecting loculated pleural effusion.
- Fluid is darker than solid. Solid can be pus (empyema), consolidation (pneumonia), Tumor, atelectasis (mucus bands that adhere to the lung tissue and appears like pus).



5- Ultrasound: What are the advantages of ultrasound?

- **More sensitive and specific**¹⁷ and it can detect minimal fluid.
- It will help you to rule out others like pneumothorax and fluid collection.
- A very important step in diagnosing the patient.
- Cheap and available at bedside
- Can help identify free vs. loculated effusions. Disadvantage: Operator dependent. Usually a pulmonologist will perform it and not a radiologist.

6- Thoracentesis¹⁸: It's aspiration of fluid **facilitated by ultrasound guidance**

Has two aims: diagnostic & therapeutic

- Thoracentesis is not immediately indicated if there is an obvious explanation for pleural effusion without atypical features. E.g. a patient with CKD and on hemodialysis, we don't need to do thoracentesis as we already know the cause. Or a patient known for HF and regularly comes with pulmonary edema and pleural effusion.
- Indications for thoracentesis:
 - o NEW Pleural effusion of **unknown** etiology, with >10mm depth on lateral decubitus CXR or Ultrasound
 - o **Therapeutically for symptomatic relief**
 - o Concern for empyema
 - o Air fluid level in pleural space¹⁹
- Pneumothorax is a complication seen in 10% to 15% of thoracenteses. - After you get the fluid send it for analysis.
- Pleural effusion on CT or CXR can't show the nature of the effusion whether it's blood, pus or any other type, so thoracentesis helps identifying the nature of the effusion.

¹⁵ Need to be larger than 500 mL to cause much more than blunting of the costophrenic angle. On an erect film they produce a characteristic shadow with a curved upper edge rising into the axilla. If very large, the whole of one side of the thorax may be opaque, with shift of the mediastinum to the opposite side.

¹⁶ **Meigs syndrome** is defined as the triad of benign ovarian tumor with ascites and pleural effusion

¹⁷ More accurate than plain chest X-ray for determining the presence of fluid.

¹⁸ an invasive procedure to remove fluid or air from the pleural space

¹⁹ The pleural effusion behaves according to basic fluid dynamics. If the pleural space contains both air and fluid, then an air-fluid level that is horizontal will be present, instead of conforming to the lung space.

Cell Count

Lymphocytic > 50%	<ul style="list-style-type: none"> ● CA (30-35%) ● TB (15-20%) ● Sarcoidosis
PMNs	<ul style="list-style-type: none"> ● Empyema ● Parapneumonic ● Rheumatoid ● Pulmonary infarction
PMN or Lymphocytic	<ul style="list-style-type: none"> ● PE ● Conn tissue disease ● Post-cardiac injury
Eosinophilic > 10%	<ul style="list-style-type: none"> ● Trauma ● PTX ● CA ● Asbestos, parasites ● Pneumonia
RBC > 100,000/mm	<ul style="list-style-type: none"> ● CA ● Trauma ● Pulmonary infarction

Treatment

Treatment: (one sentence: Treat the underlying cause)

Thoracentesis – then treat underlying disease

- **Uncomplicated pneumonia:** antibiotics.
- **Hemothorax involved/empyema:** tube thoracostomy²⁰ +/- VATS²¹
- **Malignant effusion:** chest tube +/- pleurodesis (sclerosants)²² / VATS

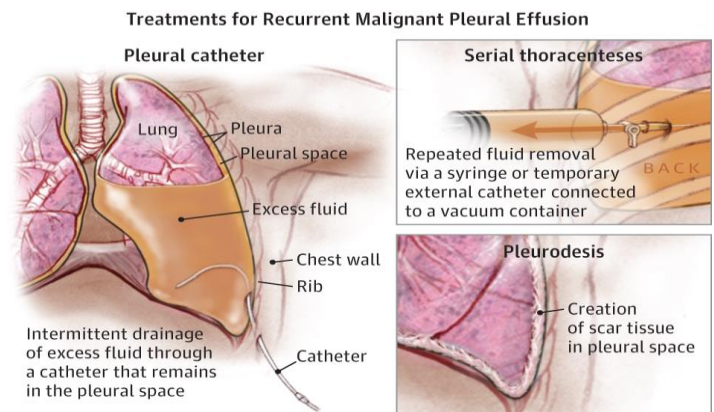
(Chest tube is the **first step** in treating **empyema (drain)**)

Drain is optional for symptomatic relieve, but its **mandatory for empyema.**

1- Transudative effusion:

- Diuretics and sodium restriction.
- Therapeutic thoracentesis (in massive effusion).

2- Exudative effusion treat underlying cause.



²⁰ Tube thoracostomy is the insertion of a tube (chest tube) into the pleural cavity to drain air, blood, bile, pus, or other fluids. [How is it different from thoracentesis?](#)

²¹ Video-assisted thoracoscopic surgery (VATS) is a type of thoracic surgery performed using a small video camera that is introduced into the patient's chest via small incisions.

²² Pleurodesis is a medical procedure in which the pleural space is artificially obliterated. It involves the adhesion of the two pleurae.

3- Parapneumonic effusions:

- Uncomplicated: antibiotics alone.
- Complicated or empyema:
 - Chest tube drainage and antibiotics.
 - Intrapleural injection of thrombolytic agents (streptokinase or urokinase); may accelerate the drainage.
 - Surgical lysis of adhesions may be required.

A patient came to the ER with SOB, weight loss and CXR showed massive pleural effusion, what's the next step?

- Ultrasound?
- Thoracentesis?
- CT?

The right step is to perform **Thoracentesis**, since the patient came to ER your aim should be to relieve his symptoms and approach to diagnose him, and that will be done through aspirating the fluid (Relieve) and sending it to Pathology (Diagnose)

Summary

- **Pleural effusion** is an excessive accumulation of **serous fluid** within the **pleural space**.
If it is: - **Frank pus** > **empyema**, - **blood** > **haemothorax**, - chyle > chylothorax.
- Types: 1) Exudative. 2) Transudative.
- **Light's criteria:** Exudative effusions have at least one of the following:
 - 1- Protein (pleural)/protein (serum) >0.5
 - 2- LDH (pleural)/LDH (serum) >0.6
 - 3- LDH >2/3 the upper limit of normal serum LDH

Manifestations of Fluid Collections <u>THE 5 C's:</u>		4. <u>C</u> olor/ <u>C</u> harter:	
1. <u>C</u> ytology:	2. <u>C</u> ulture:	Red	Blood (Hemorrhagic effusion), Malignancy, TB
3. <u>C</u> ell count:		Green	Fungal infection
Lymphocytes	Malignancy, TB, Connective tissue disease	White/Milky	Thoracic duct injury, Chylothorax
Neutrophils	Parapneumonic (Acute infection), Empyema,	Yellow	Any causes
Eosinophils	Lymphatic obstruction, Fungal Infection, Allergy, Drugs	Turbid	(Parapneumonic effusion)
RBC > 100,000/mm	Malignancy, Trauma, Pulmonary infarction	Brown/Roasted	→ Pus → Empyema.
5. <u>C</u> hemistry:	PH (< 7.2), Glucose, Protein & LDH (for light's criteria)		

- **Clinical Features:** chest pain \ Cough \ Dyspnea \ Stony dullness \ Decreased vesicular breath sounds \ Trachea will shift **away** from the affected side \ Reduced tactile fremitus.
- **Diagnosis:** Initial diagnostic test > Chest x-ray
- **Treatment:** Thoracentesis – then treat underlying disease

19.15 Pleural effusion: main causes and features				
Cause	Appearance of fluid	Type of fluid	Predominant cells in fluid	Other diagnostic features
Tuberculosis	Serous, usually amber-coloured	Exudate	Lymphocytes (occasionally polymorphs)	Positive tuberculin test Isolation of <i>M. tuberculosis</i> from pleural fluid (20%) Positive pleural biopsy (80%) Raised adenosine deaminase
Malignant disease	Serous, often blood-stained	Exudate	Serosal cells and lymphocytes Often clumps of malignant cells	Positive pleural biopsy (40%) Evidence of malignancy elsewhere
Cardiac failure	Serous, straw-coloured	Transudate	Few serosal cells	Other signs of cardiac failure Response to diuretics
Pulmonary infarction	Serous or blood-stained	Exudate (rarely transudate)	Red blood cells Eosinophils	Evidence of pulmonary infarction Obvious source of embolism Factors predisposing to venous thrombosis
Rheumatoid disease	Serous Turbid if chronic	Exudate	Lymphocytes (occasionally polymorphs)	Rheumatoid arthritis: rheumatoid factor and anti-CCP antibodies Cholesterol in chronic effusion; very low glucose in pleural fluid
SLE	Serous	Exudate	Lymphocytes and serosal cells	Other signs of SLE Antinuclear factor or anti-DNA positive
Acute pancreatitis	Serous or blood-stained	Exudate	No cells predominate	Higher amylase in pleural fluid than in serum
Obstruction of thoracic duct	Milky	Chyle	None	Chylomicrons

(anti-CCP = anti-cyclic citrullinated peptide; SLE = systemic lupus erythematosus)

Questions

1) A 55-year-old man presents with progressive shortness of breath. Other than a history of heavy smoker, the patient has no significant past medical history. Breath sounds are absent two-thirds of the way up on the left side of the chest. Percussion of the left chest reveals stony dullness, the trachea appears to be deviated toward the right. Which of the following diagnoses is most likely? (From the doctor's lecture)

- A. Bacterial pneumonia
- B. Viral pneumonia
- C. Bronchial obstruction
- D. Pleural effusion
- E. Pneumothorax

The correct answer is **D**

2) A 59-year-old male presents with a community acquired pneumonia complicated by pleural effusion. A thoracentesis is performed, but the results are not currently available. Which characteristic of the pleural fluid is most suggestive complicated parapneumonic pleural effusion? (From the doctor's lecture)

- A. Presence of more than 30% polymorphonucleocytes (PMNs)
- B. Glucose less than 150 mg/dl
- C. Presence of more than 100 white blood cells
- D. pH less than 7.20
- E. Lactate dehydrogenase (LDH) more than two-thirds of the normal upper limit for serum

The correct answer is **D**

(In this question, which answer (feature) says that it is parapneumonic? (A) is wrong because neutrophils must be more than 60%. (B) is wrong because glucose is very high. (C) is wrong because the total number of WBC is not needed here. (D) is correct because of low pH. (E) is wrong because LDH levels are specifically used to indicate if the fluid is exudate or transudate.)

3) A 50 year old lady presents to the emergency department with increased shortness of breath on exertion over the past 3 months. She has a past history of breast cancer 10 years previously treated with mastectomy and no known recurrence. Oxygen saturations are 94% on air and PO₂ of 9 kPa on arterial blood sampling. Chest X-ray shows a large right-sided pleural effusion. The next appropriate investigation would be: (Kumar)

- A. Chest CT
- B. Chest drain insertion
- C. Pleural aspiration

- D. Peak expiratory flow rate
- E. Exercise tests

The correct answer is **C**

4) A 59 year old man with shortness of breath is brought to the emergency department for evaluation. He has a past medical history of hepatitis B, cirrhosis, and recurrent pulmonary infections. A chest x-ray is obtained and reveals a large, right-sided pleural effusion. Thoracentesis is undertaken, which reveals that the ratio of pleural protein to serum protein is >0.5 . What is the most likely explanation for these findings? (step-up)

- A. Pulmonary infarction
- B. Atelectasis
- C. Hypoalbuminemia
- D. Cirrhosis
- E. Pneumonia

The correct answer is **E**

Explanation: This patient has an exudative pleural effusion as suggested by the pleural effusion found on chest x-ray. Thoracentesis reveals that the pleural protein/serum protein ratio is >0.5 , which is characteristic, based on Light's criteria rule, for an exudative effusion. The differential diagnosis of an exudative effusion includes bacterial pneumonia, TB, malignancy, viral infection, pulmonary embolism, and collagen vascular diseases. Atelectasis and cirrhosis are both common causes of transudative pleural effusion; in these patients, the pleural protein/serum protein ratio is <0.5 . Hypoalbuminemia is also common cause of a transudative pleural effusion with a pleural protein/serum protein ratio <0.5 ; further, the pleural LDH/serum LDH ratio is <0.6 . Pulmonary embolism, not pulmonary infarct, is associated with formation of transudative pleural effusion. In these patients, the pleural protein/serum protein ratio is <0.5 .

5) A 55 year old man presents to the emergency department with shortness of breath and chest pain. Physical examination suggested the presence of pleural effusion in the right side of the chest. A PA chest X-ray was taken. What is the most likely finding in the X-ray?

- A. Hyperinflation of the lungs.
- B. Blunting of the right costophrenic angle.
- C. Flattening of the diaphragm.
- D. Normal chest X-ray.

The correct answer is **B**

6) Thoracentesis was done to a patient who's physical exam and chest X-ray were positive for pleural effusion. Cell count showed predominant PMNs. What is the most likely cause for this patient's pleural effusion?

- A. Malignancy.
- B. Tuberculosis.
- C. Parapneumonic.
- D. Fungal infection.

The correct answer is **C**

7) A 57 year old man with bacterial pneumonia is hospitalized on the medical service. He has a left-sided pleural effusion and underwent thoracentesis. The pleural LDH/serum LDH is >0.6 . One week later, he reaccumulates the effusion, and chest X-ray shows a large left-sided pleural effusion. What is the most appropriate course of action to take? (Step-up)

- A. Antibiotics, oral.
- B. Consideration for rib resection with open drainage.
- C. Antibiotics, intravenous.
- D. Lung lobectomy.
- E. Corticosteroid infusion.

The correct answer is **B**

Explanation: This patient has empyema. Most cases are a complication of bacterial pneumonia, but it can also occur with mediastinitis or abscess. This condition should be treated with open drainage since the patient has failed treatment with thoracentesis. Recurrent exudative pleural effusion is best treated more aggressively than simply with antibiotics.

Corticosteroids may suppress the immune system and worsen the empyema. Lung lobectomy should not be required; once the exudative effusion is removed, the lung should heal.

8) A 38 years old female who have been smoking Shisha daily for 20 years, came to the ER with severe shortness of breath exacerbating with lying down. On history, the patient mentioned loss of 10 kg on the last 3 months. On clinical examination there was asymmetrical chest expansion. Chest X-Ray showed massive pleural effusion on the left lung. Thoracocentesis was performed and red colored effusion was shown. What is the first DDx comes to your mind?

- A. Fungal infection.
- B. Pneumonia.
- C. Tuberculosis.
- D. Trauma.
- E. Malignancy.

The correct answer is **E**

7) Abnormality in which organ can affect the amount of the fluid in pleural space?

- A. Lungs.
- B. Brain.
- C. Ovaries.
- D. Testes.
- E. Liver.

The correct answer is **C**

8) Which procedure can relieve symptoms but can't treat the primary cause?

- A. CT angiogram.
- B. Thoracocentesis.
- C. Treating the underlying disease.
- D. B&C.
- E. None of the above.

The correct answer is **B**

9) Which one of the following is considers the most common cause of pleural effusion?

- A. Primary lung cancer.
- B. Congestive heart failure.
- C. Mesothelioma.
- D. Trauma.
- E. Pneumonia.

The correct answer is **B**

10) Choose the clinical signs that matches a patient with sever pleural effusion.

- A. Chest inflation > 5cm, resonant on percussion.
- B. Infraclavicular dullness, sharp costophrenic angles on CXR.
- C. Stony dullness on percussion, asymmetrical chest expansion.
- D. B&C.
- E. None of the above.

The correct answer is **C**