



Interactive Lecture

Radiology of endocrine diseases

Done By

Team Leaders:



Khalid Alshehri



Hanin Bashaikh

Team Members:



Khalid Alhusainan



Abdulaziz Alsalman



Maha Alissa



Mohammed bin Nasif

Revised by:



Yara Aldigi

Color Coding

[Important](#) | [Notes](#) | [Extra](#)

Important note:

There were no questions or scenarios in the lecture, only pictures with lab results.

The doctor was discussing the cases with us.

We tried our best to figure out the appropriate questions by the help of 435 teamwork.

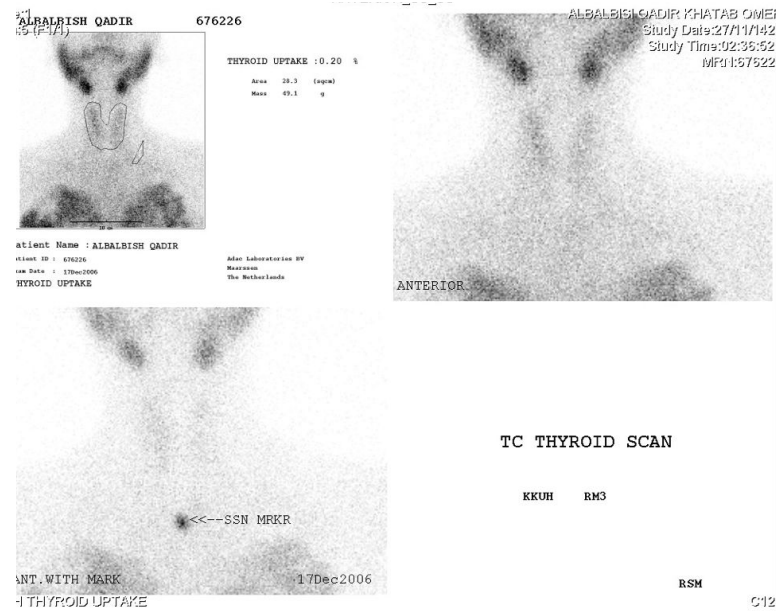
[Editing](#)
[File](#)





CASE (1)

25 year old female presented with thyrotoxic symptoms 2 weeks after delivery.
Lab: Elevated T4 and suppressed TSH.



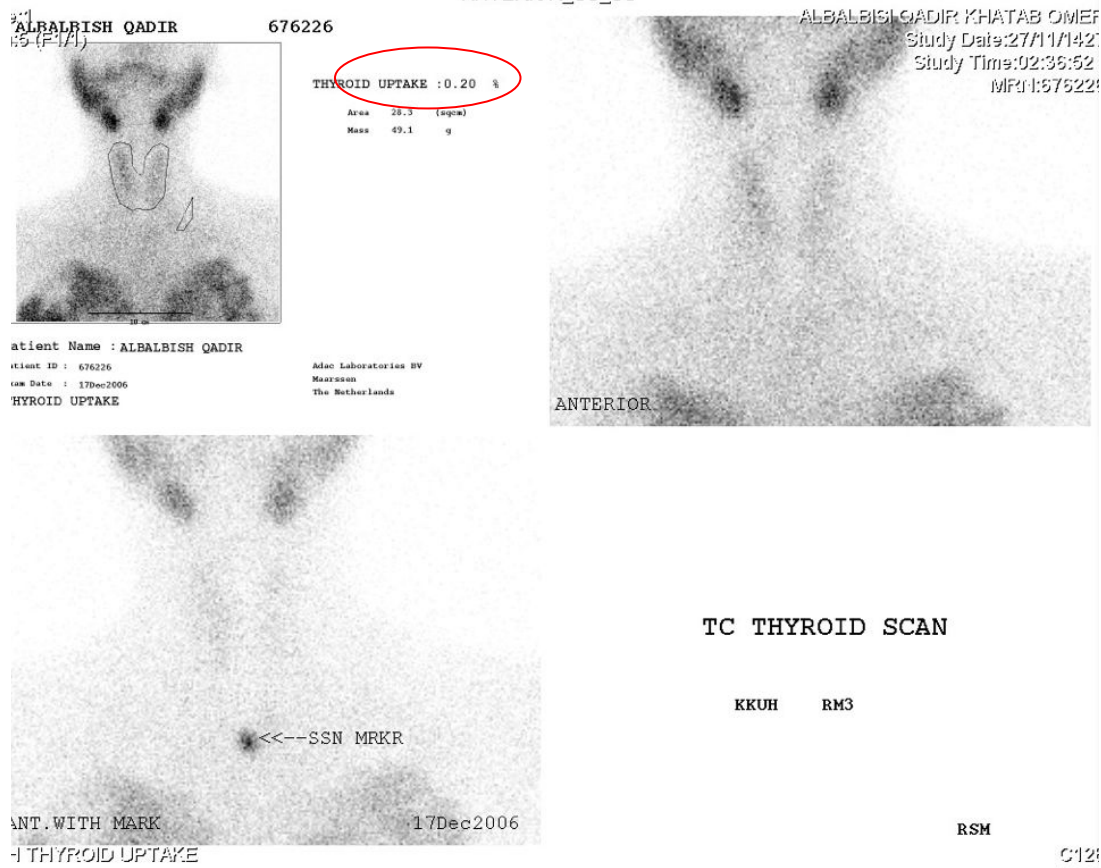
- What is the study?
- What is the agent used?
- What are the imaging findings?
- What is the most likely diagnosis?
- What is the treatment?



CASE (1)

25 year old female presented with thyrotoxic symptoms 2 weeks after delivery.

Lab: Elevated T4 and suppressed TSH. (Thyrotoxicosis = Elevated T4, if it was from the thyroid it is hyperthyroidism)



- **What is the study?**

Nuclear scan of the thyroid.

- **What is the agent used?**

Tc-99m Pertechnetate.

- **What are the imaging findings?**

Decreased uptake in both lobes 0.20% (thyroiditis).
(Normal 0.5%-4%).

- **What is the most likely diagnosis?**

Subacute Thyroiditis (postpartum thyroiditis).

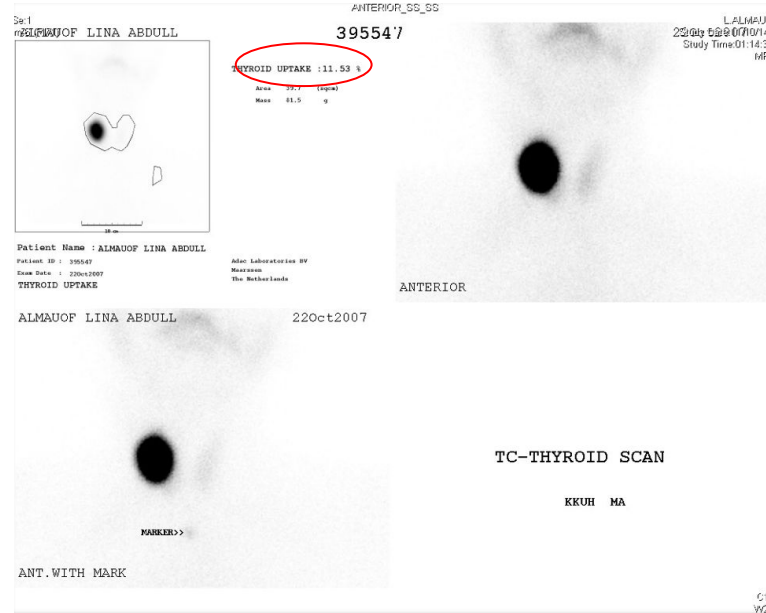
- **What is the treatment?**

Symptomatic treatment give beta blockers.



CASE (3)

25 year old female presented with thyrotoxic symptoms 2 weeks after delivery.
Lab: Elevated T4 and suppressed TSH (Thyrotoxicosis).

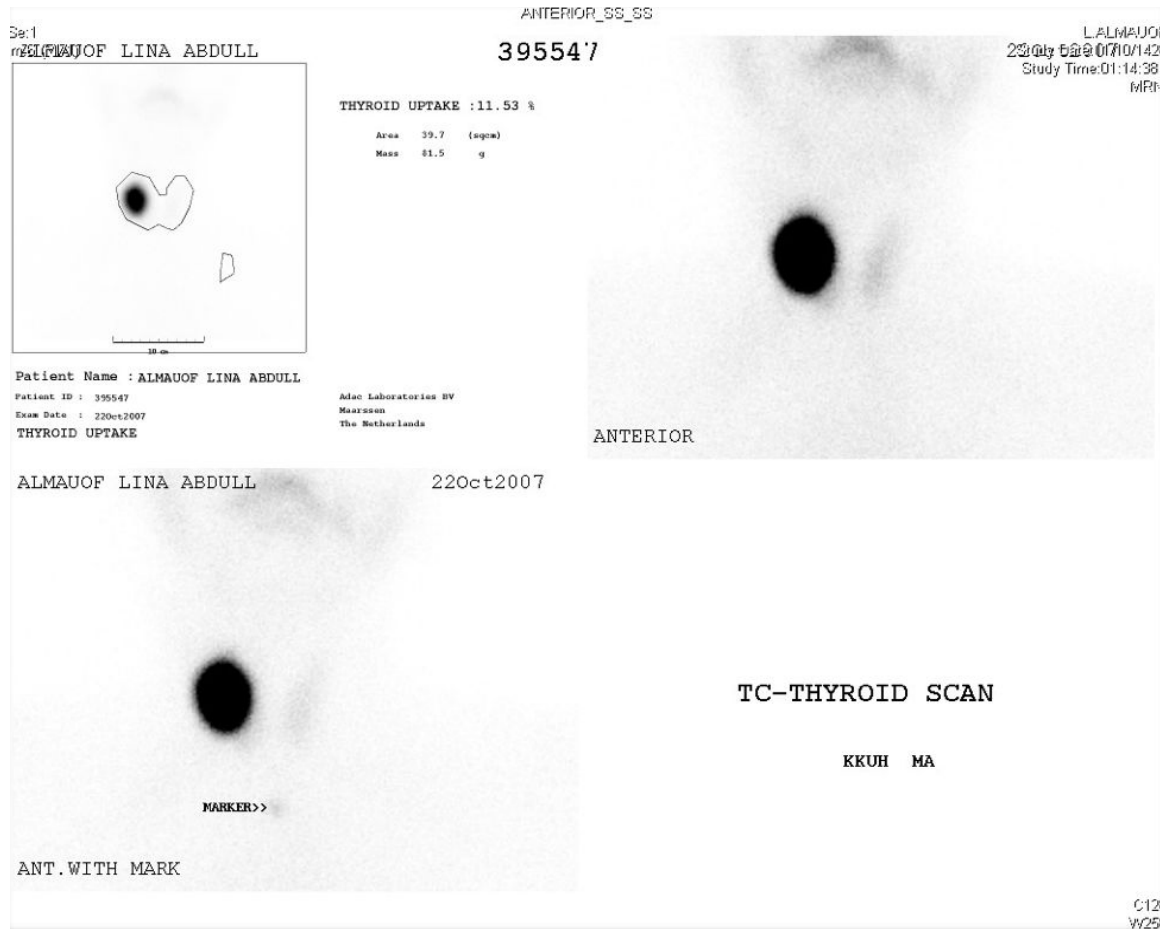


- What is the study?
- What is the agent used?
- What are the imaging findings?
- What is the most likely diagnosis?
- What is the treatment?
- What are the chances of this nodule being malignant?



CASE (3)

**25 year old female presented with thyrotoxic symptoms 2 weeks after delivery.
Lab: Elevated T4 and suppressed TSH.**



- **What is the study?**

Nuclear scan of the thyroid.

- **What is the agent used?**

Tc-99m Pertechnetate.

- **What are the imaging findings?**

Hot nodule on the right lobe suppressing the left
Elevated uptake 11.53% (Normal 0.5%-4%)

- **What is the most likely diagnosis?**

Single toxic nodule.

- **What is the treatment?**

1st option: RAI (Iodine 131) **1st line therapy.**

2nd option: surgery.

- **What is the chances of this nodule of being malignant?**

low chance of being malignant < 5%.

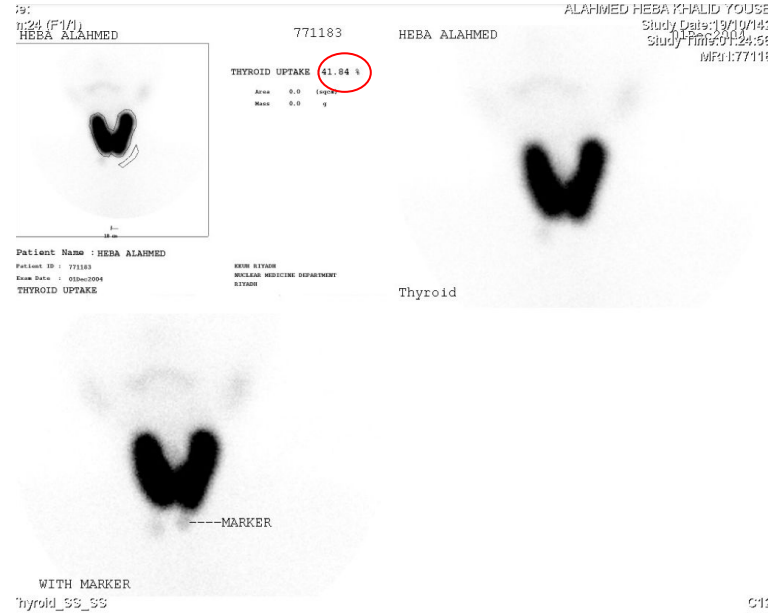


Teaching Points

In patients with thyrotoxicosis, thyroid scan is used to differentiate thyrotoxicosis with hyperthyroidism from thyrotoxicosis without hyperthyroidism.

 CASE (4)

**2 year old female presented with hypothyroidism symptoms.
Lab showed elevated TSH and low T4.**

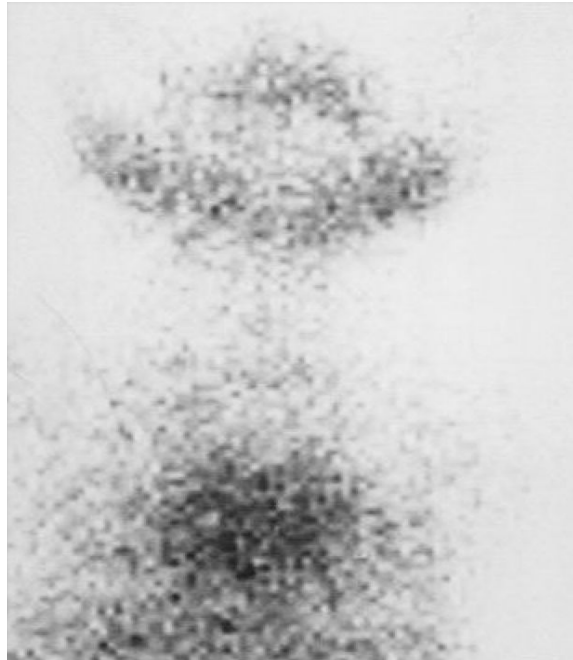


- What is the study?
- What is the agent used?
- What are the imaging findings?
- What is the most likely diagnosis?



CASE (5)

**Young patient presented with hypothyroidism symptoms.
Lab showed elevated TSH and low T4.**

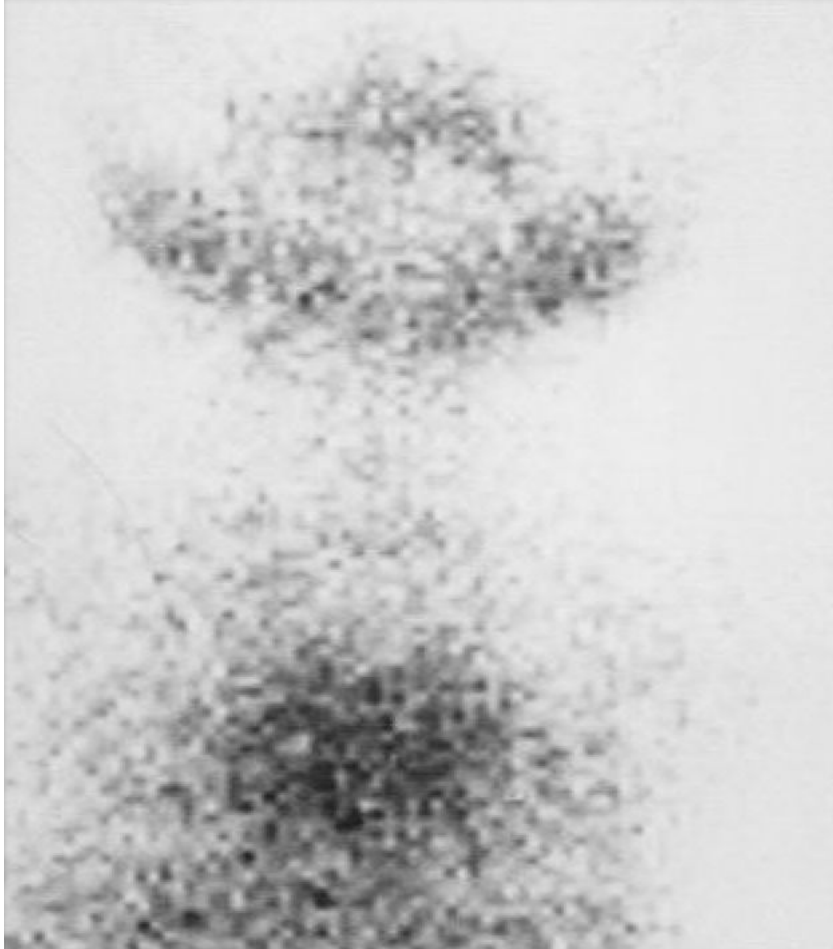

- **What is the study?**
- **What is the agent used?**
- **What are the imaging findings?**
- **What is the most likely diagnosis?**
- **What is the treatment?**



CASE (5)

Young patient presented with hypothyroidism symptoms.
Lab showed elevated TSH and low T4.



- **What is the study?**

Nuclear scan of the thyroid (for a child).

- **What is the agent used?**

Tc-99m Pertechnetate.

- **What are the imaging findings?**

Absence of thyroid gland.

- **What is the most likely diagnosis?**

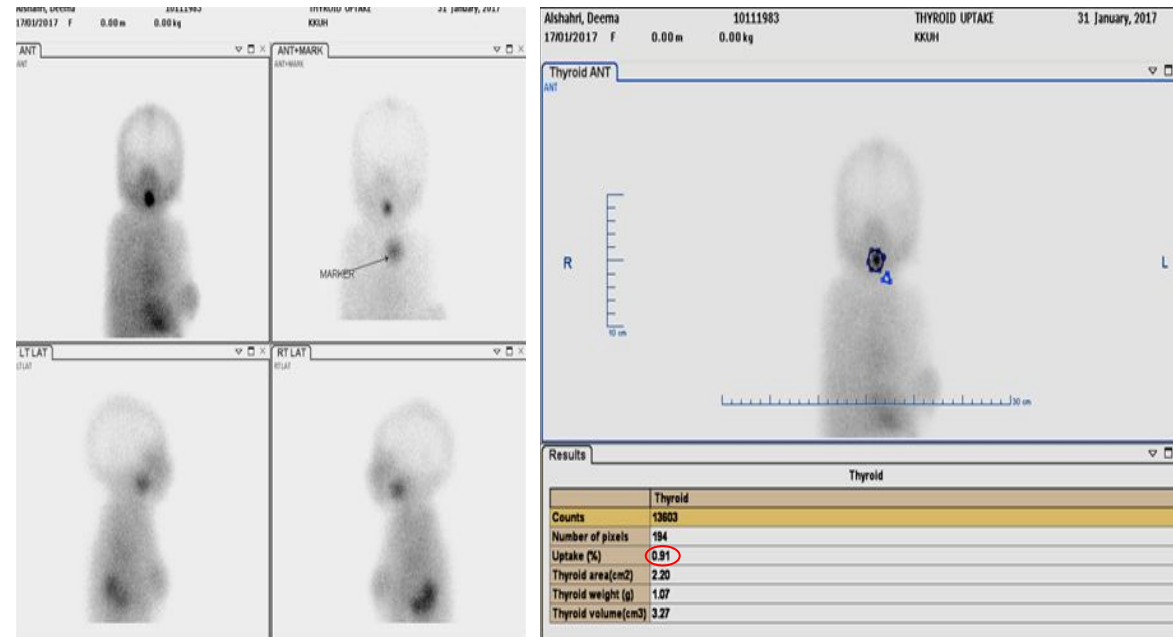
Agensis. (Congenitally absent gland)

What is the treatment?

Thyroxin.

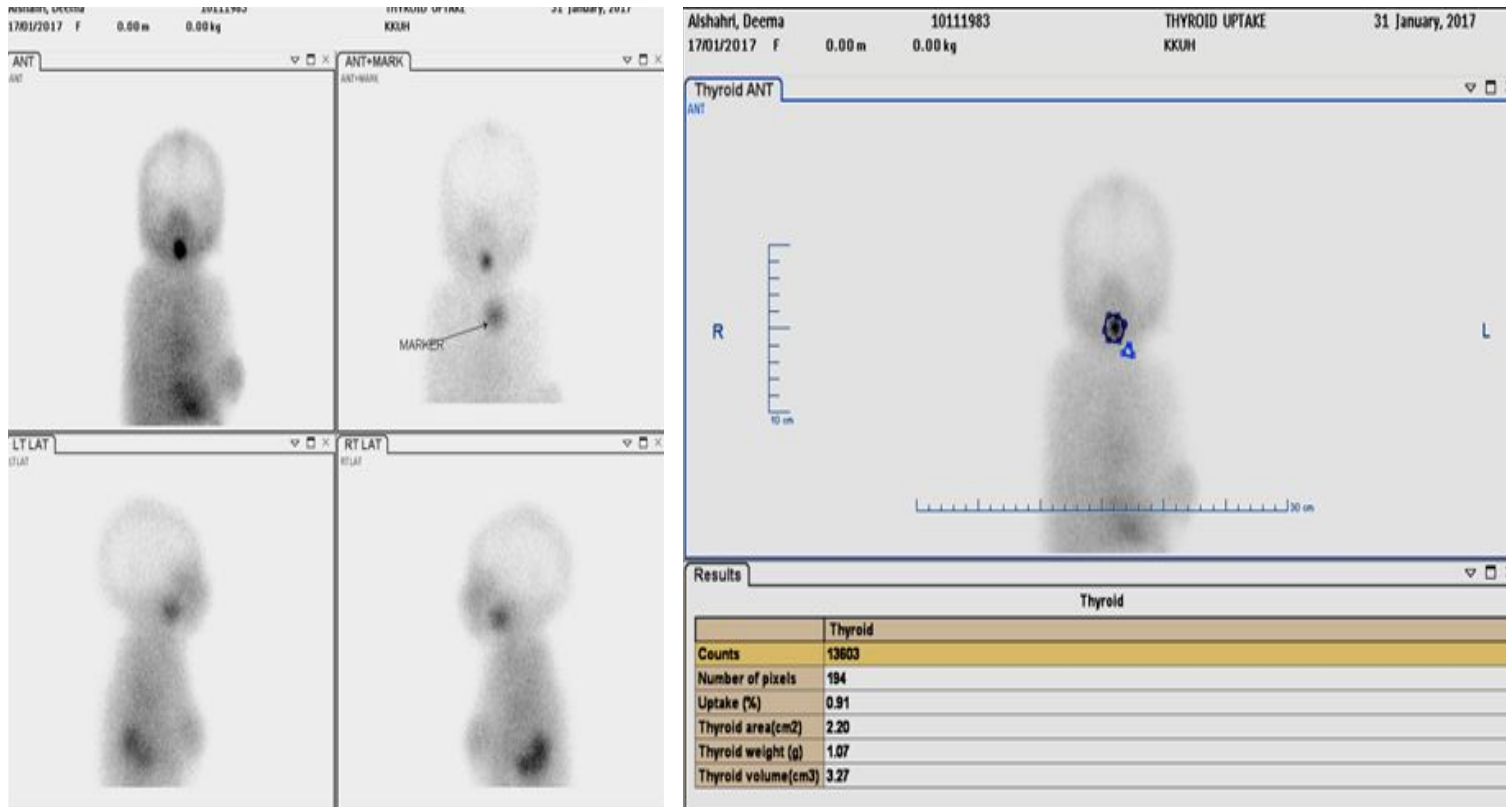


CASE (6)



- What is the study?
- What is the agent used?
- What are the imaging findings?
- What is the most likely diagnosis?
- What is the treatment?

 CASE (6)



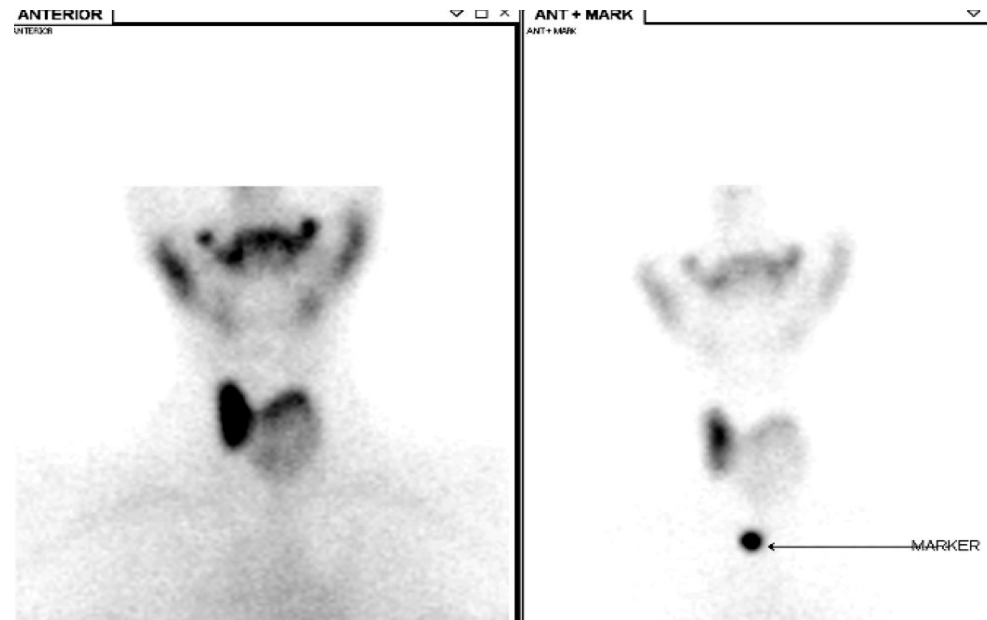
- **What is the study?**
Nuclear scan of the thyroid
- **What are the imaging findings?** Sublingual thyroid (ectopic thyroid).
- **What is the most likely diagnosis?**
Sublingual thyroid (ectopic thyroid).
- **What is the treatment?**
- The uptake here = 0.91% (normal).
- Normal range 0.5-4%.

 Teaching Points

- In patients with neonatal hypothyroidism, thyroid scan is used to differentiate dysmorphogenesis from ectopic thyroid and thyroid aplasia.

 CASE (7)

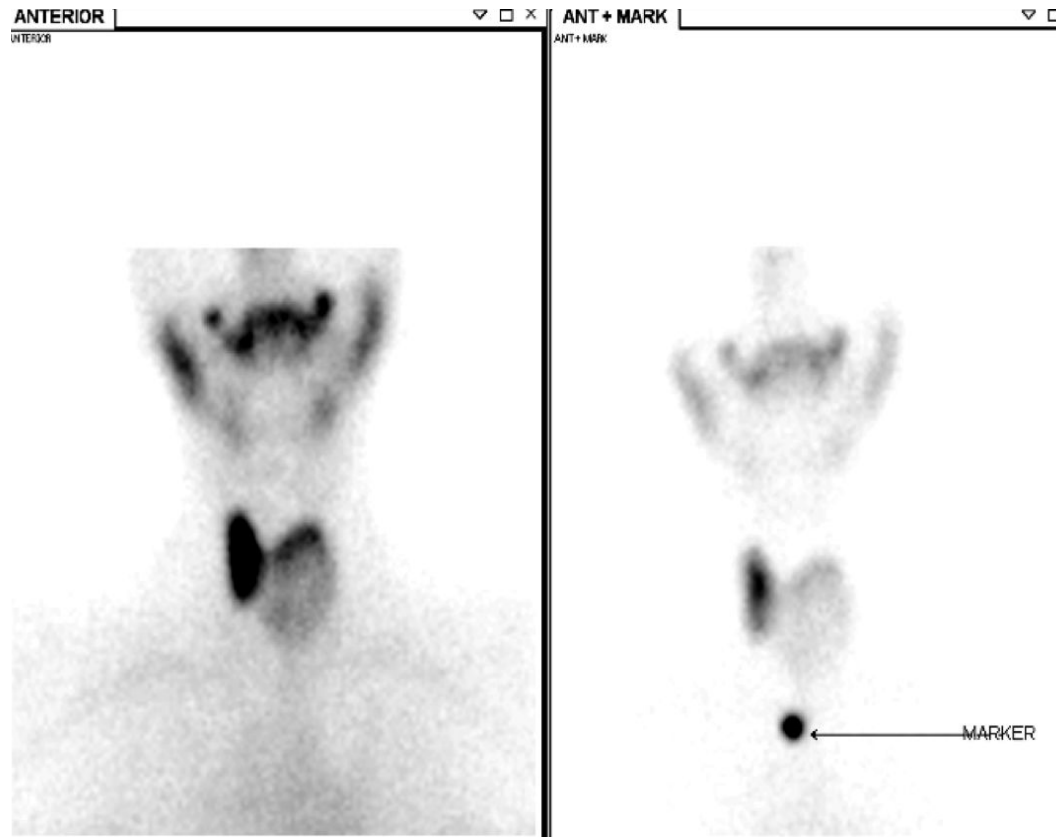A patient presented with a palpable neck mass.



- What is the study?
- What is the agent used?
- What are the imaging findings?
- What is the most likely diagnosis?
- What is the treatment?

 CASE (7)

A patient presented with a palpable neck mass.



- **What is the study?**

Nuclear scan of the thyroid.

- **What is the agent used?**

Tc-99m Pertechnetate.

- **What are the imaging findings?**

Enlarged cold nodule on the left with low uptake.

- **What is the most likely diagnosis?**

Mass on the left side with 15%-20% chance to be malignant.

- **What is the treatment?**

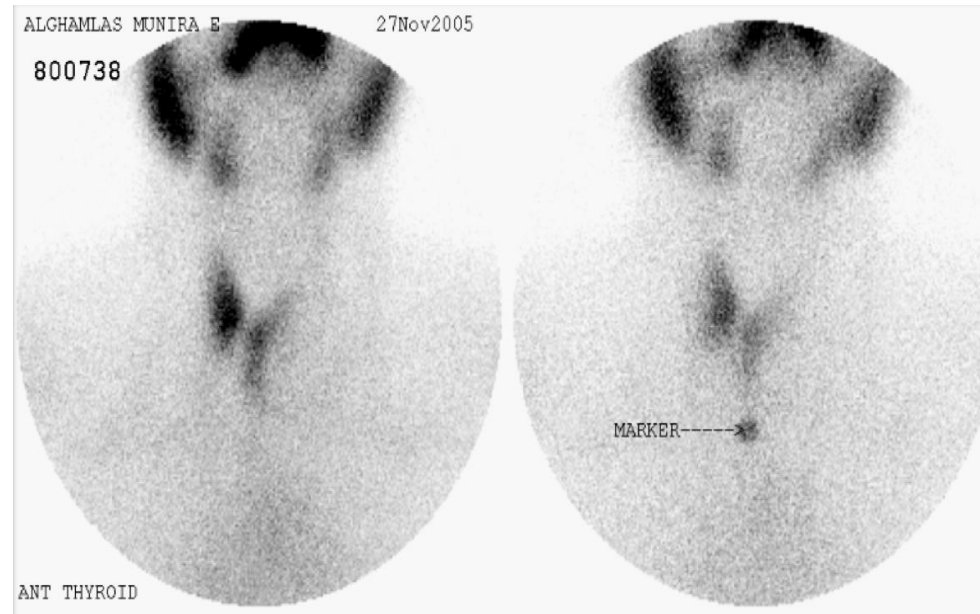
FNA to confirm.

If it turns malignant next step is surgery to remove it.



CASE (8)

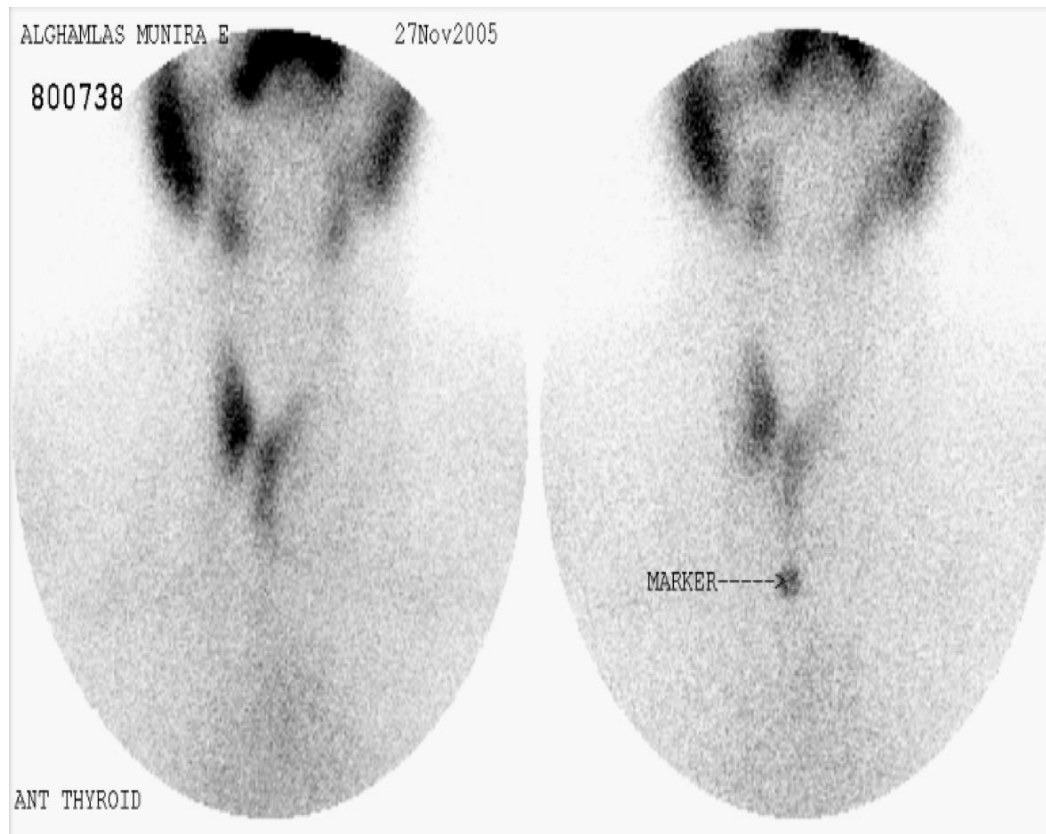
A patient presented with a palpable neck mass.



- What is the study?
- What is the agent used?
- What are the imaging findings?
- What is the most likely diagnosis?
- What are the chance of this nodule to be malignant?
- What is the treatment?

 CASE (8)

A patient presented with a palpable neck mass.



- **What is the study?**

Nuclear scan of the thyroid.

- **What is the agent used?**

Tc-99m Pertechnetate.

- **What are the imaging findings?**

Decrease uptake in left thyroid lobe (**Cold nodule**).

A mass in the left lobe **pushing** the thyroid to right.

(marker is useful here to tell if there is tracheal shift because it is always below the isthmus. here it is under the nodule so it is pushed).

To confirm the tracheal deviation do X-Ray.

- **What is the most likely diagnosis?**

Mass on the left side.

- **What are the chance of this nodule to be malignant?**

15%-20%.

- **What is the treatment?**

FNA to confirm.

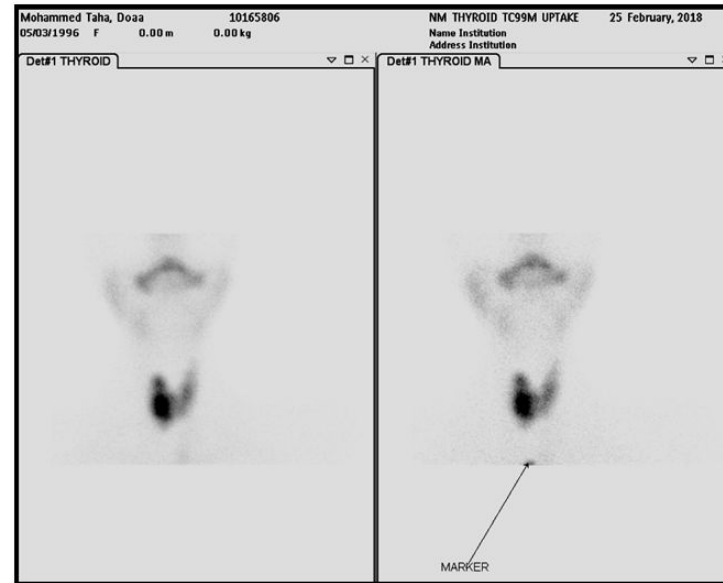
If it turns malignant next step is surgery to remove it.

- **Name some compression symptoms?**

1-Dysphagia 2-Hoarseness of voice 3- Dyspnea.

 CASE (9)

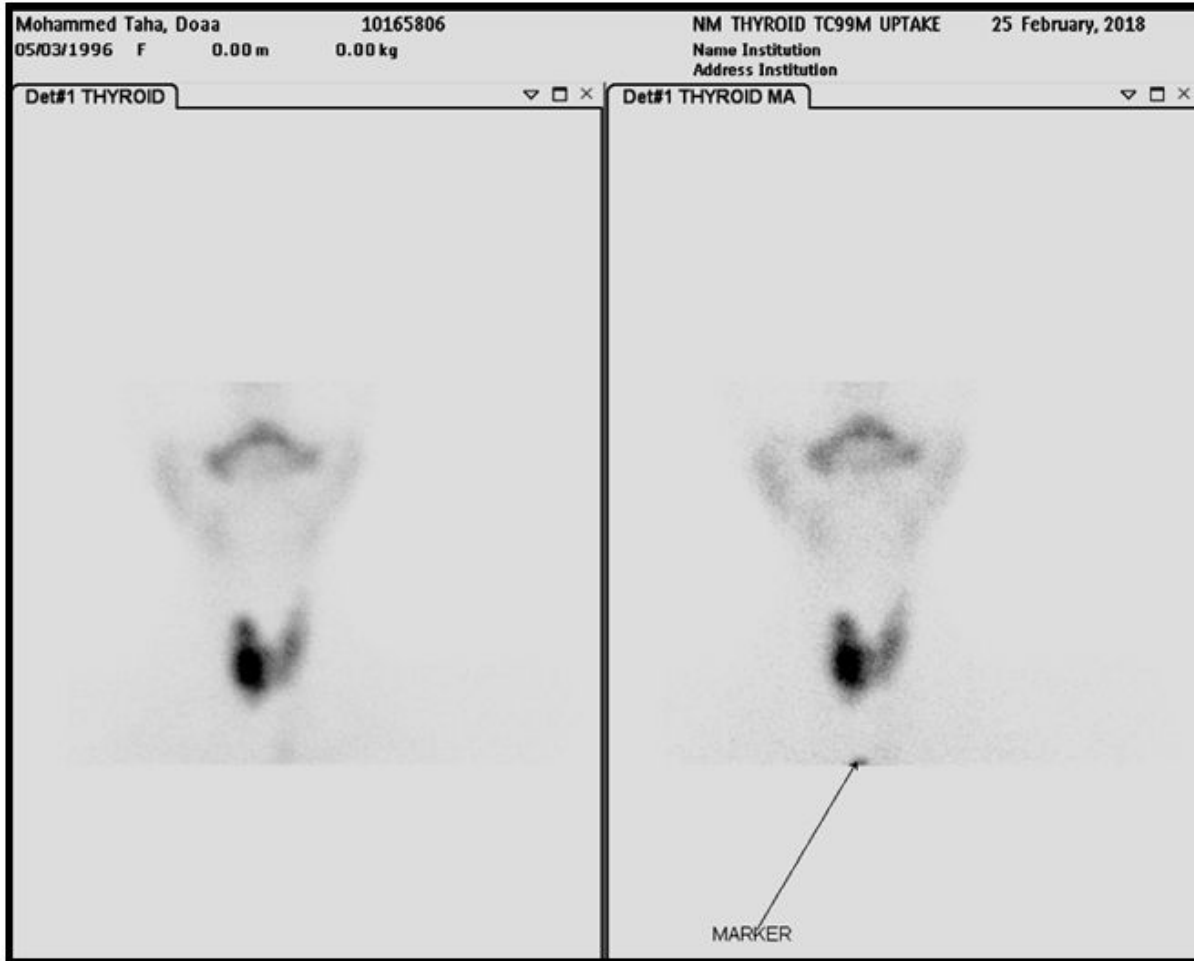
A patient presented with a palpable neck mass.



- What is the study?
- What are the imaging findings?
- What is the most likely diagnosis?
- What are the chance of this nodule to be malignant?

 CASE (9)

A patient presented with a palpable neck mass.



- **What is the study?**
Nuclear scan.
- **What are the imaging findings?**
Warm nodule (because we can see normal thyroid).
- **What are the chance of this nodule to be malignant?**
Less than 5%.

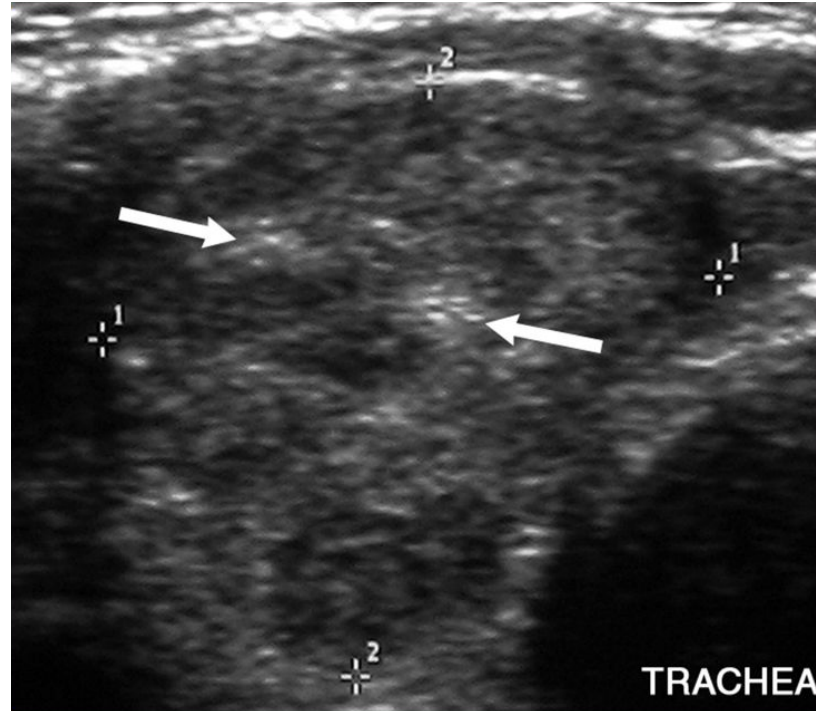


Teaching Points

In patients with neck mass, thyroid scan is used to differentiate cold from hot thyroid nodules.

 CASE (10)

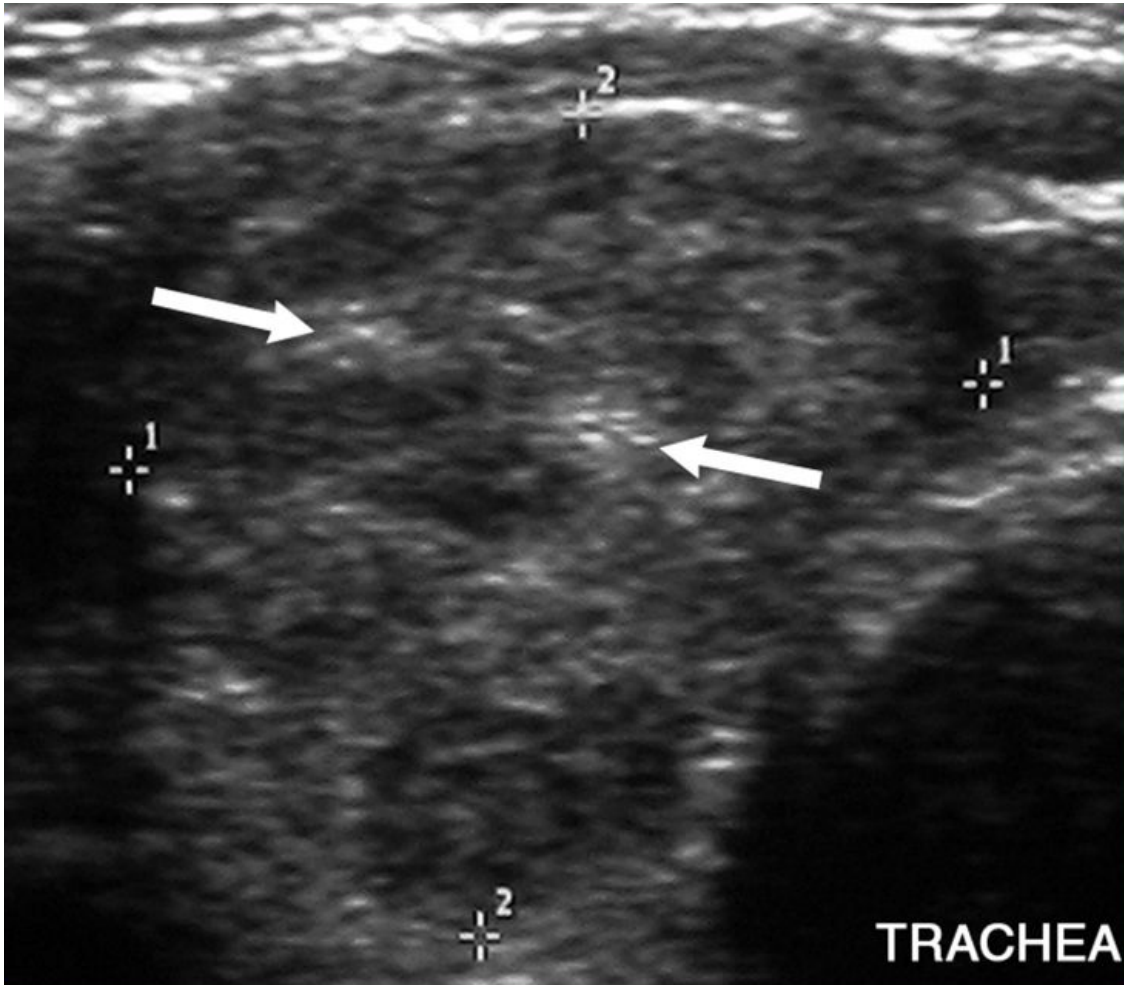42 year old man presented with Right Thyroid mass?



- What is the study?
- What are the imaging findings?
- What is the most likely diagnosis?

 CASE (10)

42 year old man presented with Right Thyroid mass?



- **What is the study?**

Sonogram (Ultrasound).

- **What are the imaging findings?**

Transverse sonogram of the right lobe of the thyroid demonstrates:

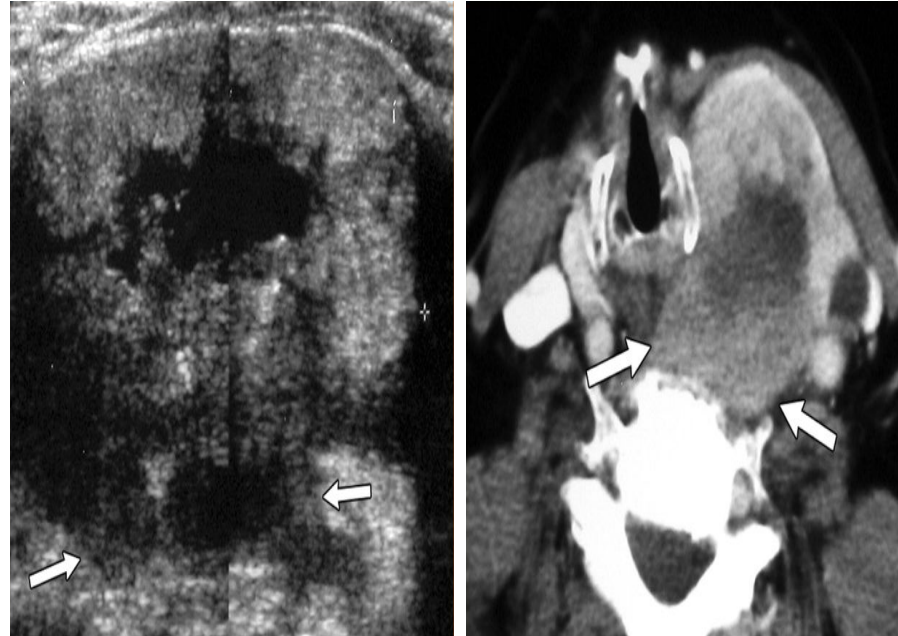
Punctate echogenic foci without posterior acoustic shadowing, findings indicative of **microcalcifications** (arrows).

- **What is the most likely diagnosis?**

Thyroid carcinoma, do FNA to confirm.

 CASE (11)

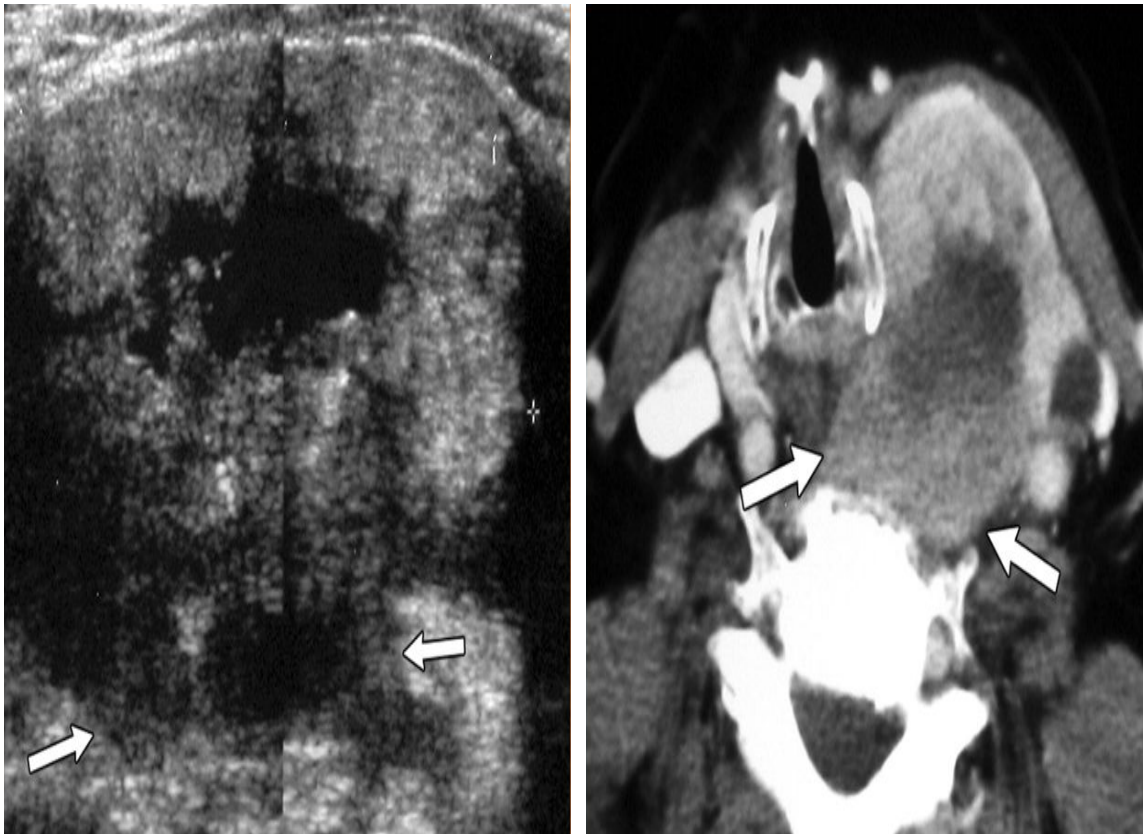
84 year old female presented with goiter.



- What is the study?
- What are the imaging findings?
- What is the most likely diagnosis?

 CASE (11)

84 year old female presented with goiter.



- **What is the study?**

Ultrasound (Left) & Contrast-enhanced CT (Right).

- **What are the imaging findings?**

Transverse sonogram of the left lobe of the thyroid shows an **advanced tumor** with infiltrative posterior margins (arrows) and invasion of prevertebral muscle.

Axial contrast-enhanced CT image shows a **large tumor** that has invaded the prevertebral muscle (arrows).

- **What is the most likely diagnosis?**

You need FNA to confirm but most likely it's **Anaplastic** thyroid carcinoma (anaplastic is very aggressive it usually **invades the surrounding tissue**).

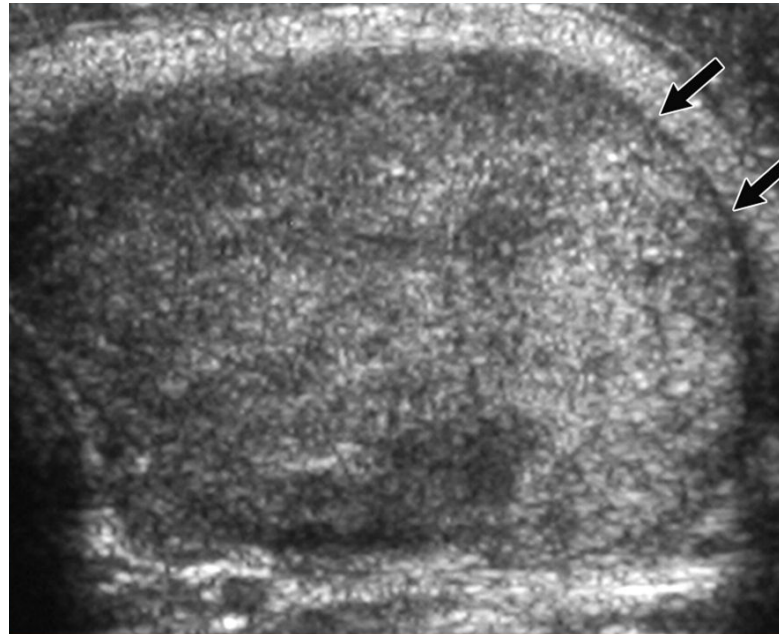
- **General notes:**

In the CT, the capsule invaded. We think it is anaplastic carcinoma which has bad prognosis. Invasion indicates malignancy.

In the US, the mass has irregular margins.

 CASE (12)

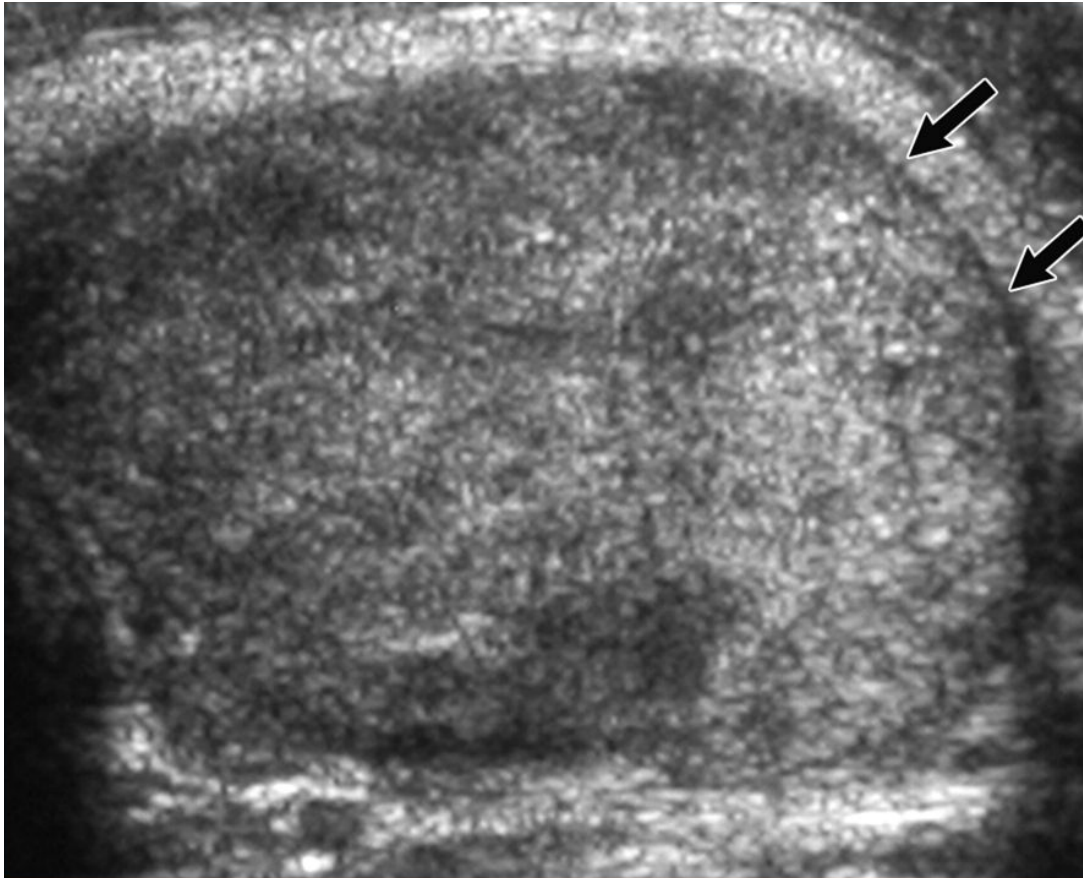
30 year old woman presented with a neck mass.



- **What is the study?**
- **What are the imaging findings?**
- **What is the most likely diagnosis?**

 CASE (12)

30 year old woman presented with a neck mass.



- **What is the study?**

Sonogram (Ultrasound).

- **What are the imaging findings?**

Transverse sonogram of the left lobe of the thyroid shows a follicular adenoma with a **hypoechoic halo** (arrows).

- **What is the most likely diagnosis?**

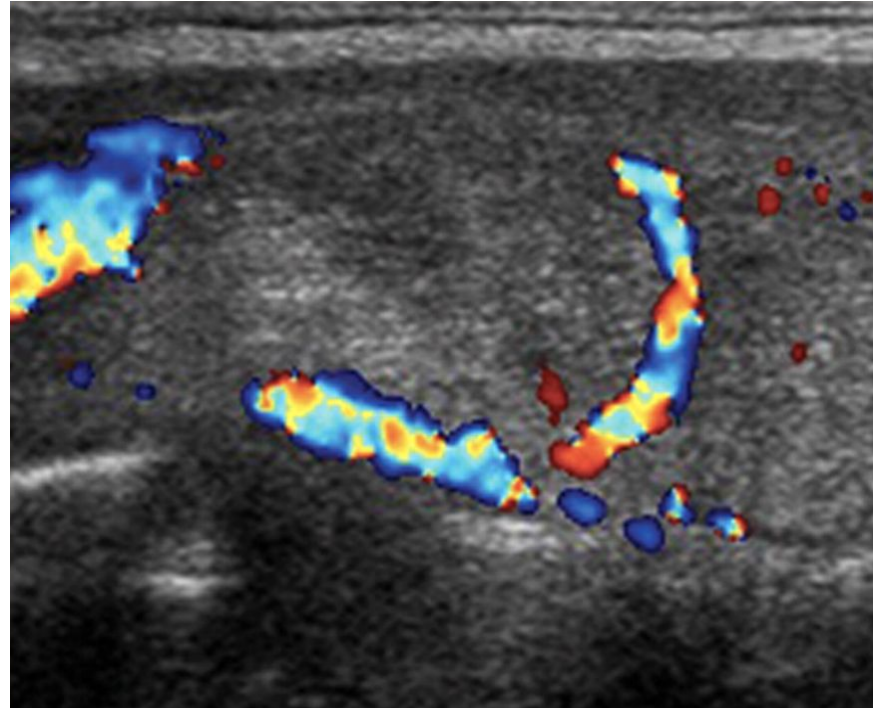
Follicular adenoma, FNA to confirm.

- **Note:**

Halo shows smooth regular margins, indicating benign condition.

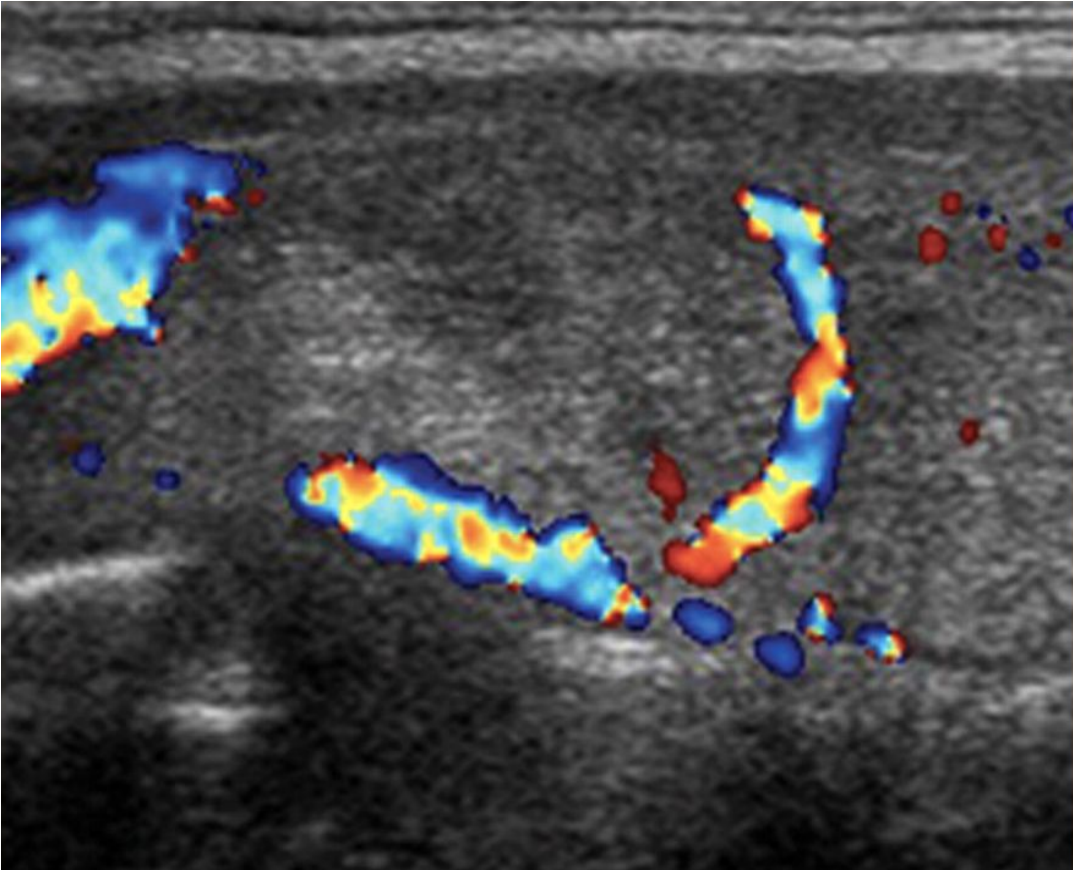
 CASE (13)

36 year old woman presented with a neck mass.



- **What is the study?**
- **What are the imaging findings?**
- **What is the most likely diagnosis?**

36 year old woman presented with a neck mass.



- **What is the study?**

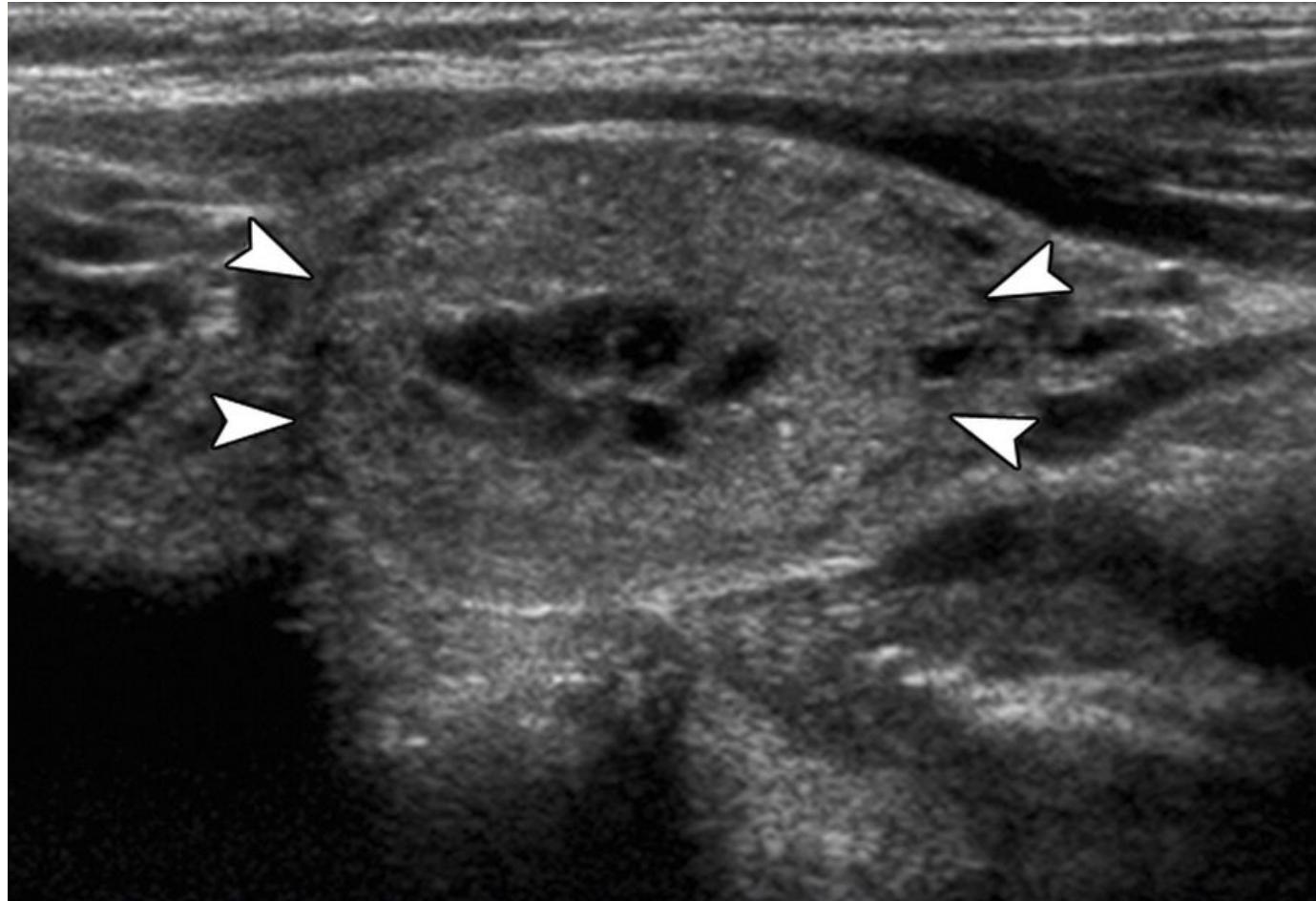
Doppler ultrasound.

- **What are the imaging findings?**

Longitudinal color Doppler sonogram of the right lobe of the thyroid shows perinodular blood flow around a follicular adenoma (benign nodules are less vascular than malignant nodules).

- **What is the most likely diagnosis?**

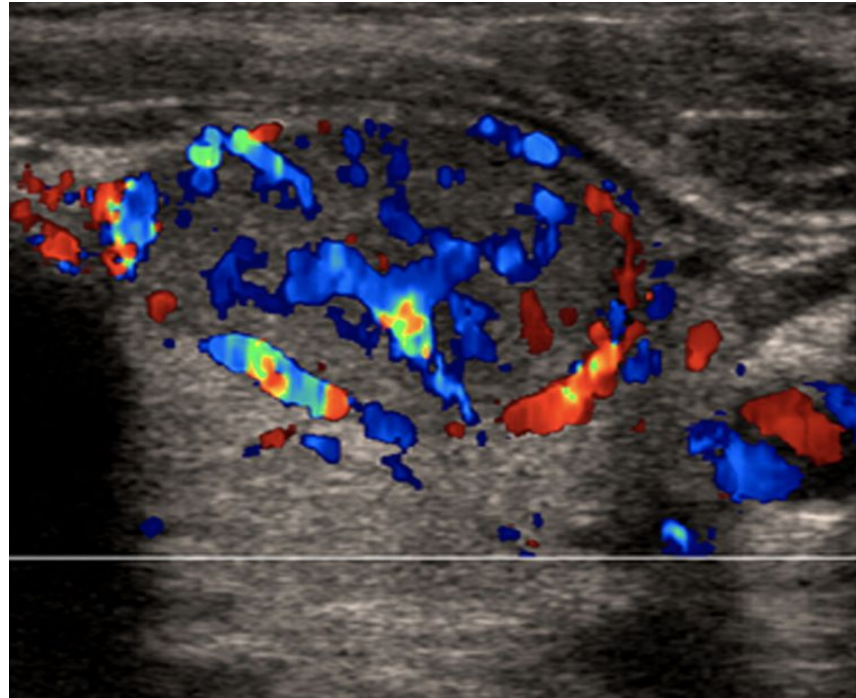
Follicular adenoma, do FNA to confirm.



US images of thyroid nodules of varying parenchymal composition (**Solid to cystic = Mixed**). Halo indicates no invasion. no microcalcifications. Proved to be benign by cytologic exam “No psammoma bodies”.

 CASE (14)

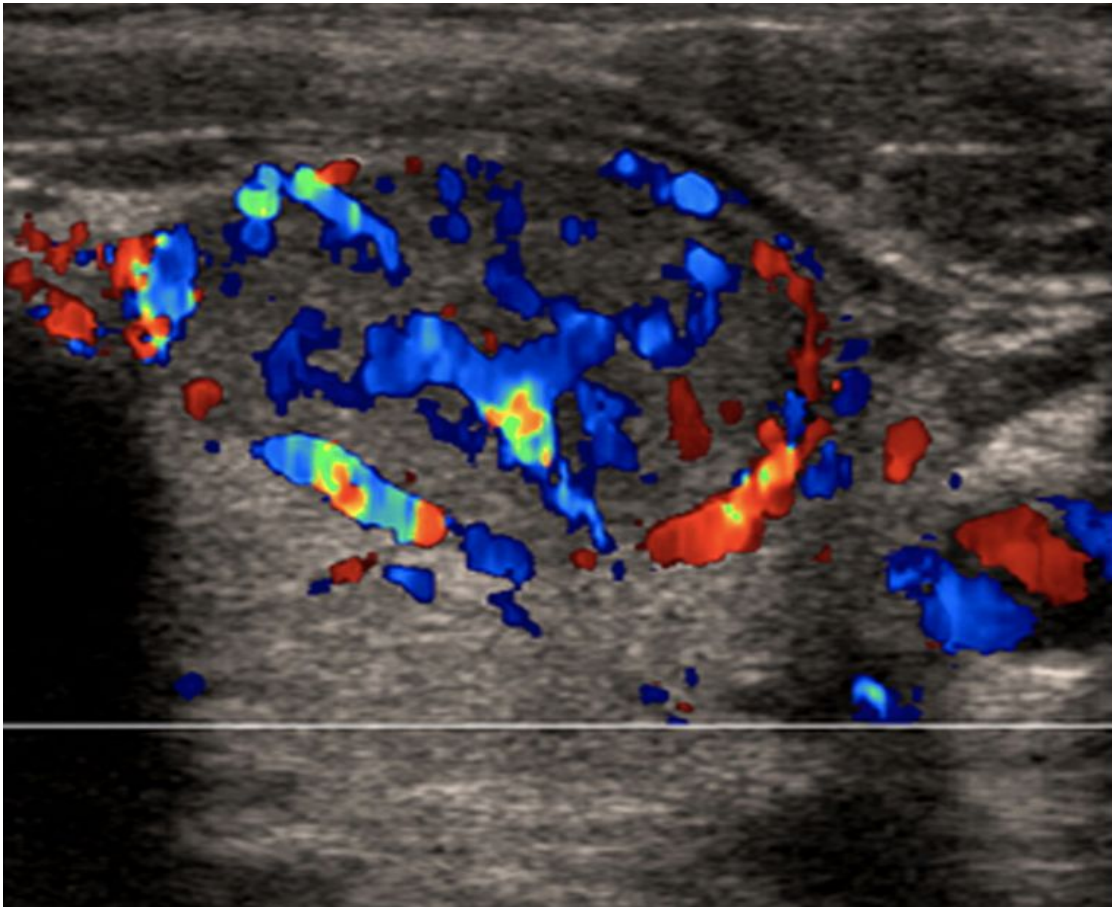
36 year old woman presented with a neck mass.



- **What is the study?**
- **What are the imaging findings?**
- **What is the most likely diagnosis?**

 CASE (14)

36 year old woman presented with a neck mass.



- **What is the study?**

Doppler ultrasound.

- **What are the imaging findings?**

Colour Doppler mode shows **marked internal vascularity**, indicating increased likelihood that the nodule is malignant.

- **What is the most likely diagnosis?**

Proved to be **papillary carcinoma** at cytologic examination.



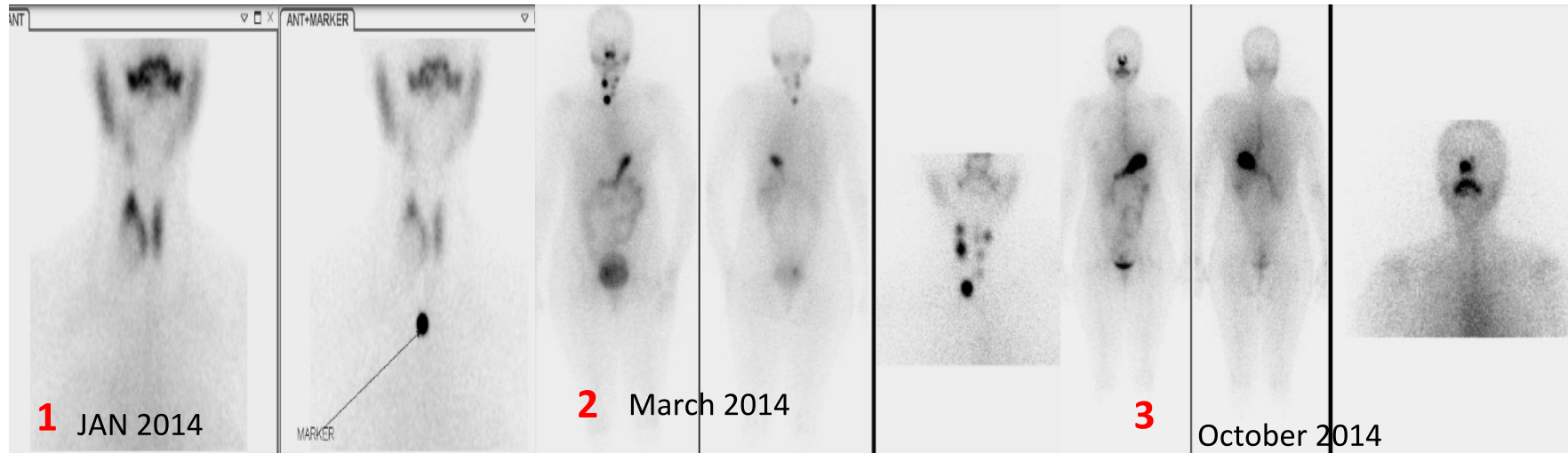
Teaching Points

In patients with thyroid nodules ultrasound and color doppler is used to:

1. Determine number of nodules.
2. Differentiate solid from cystic nodules.
3. Characterize thyroid nodule : Benign versus malignant.
4. Assess for regional associate lymph node involvement.

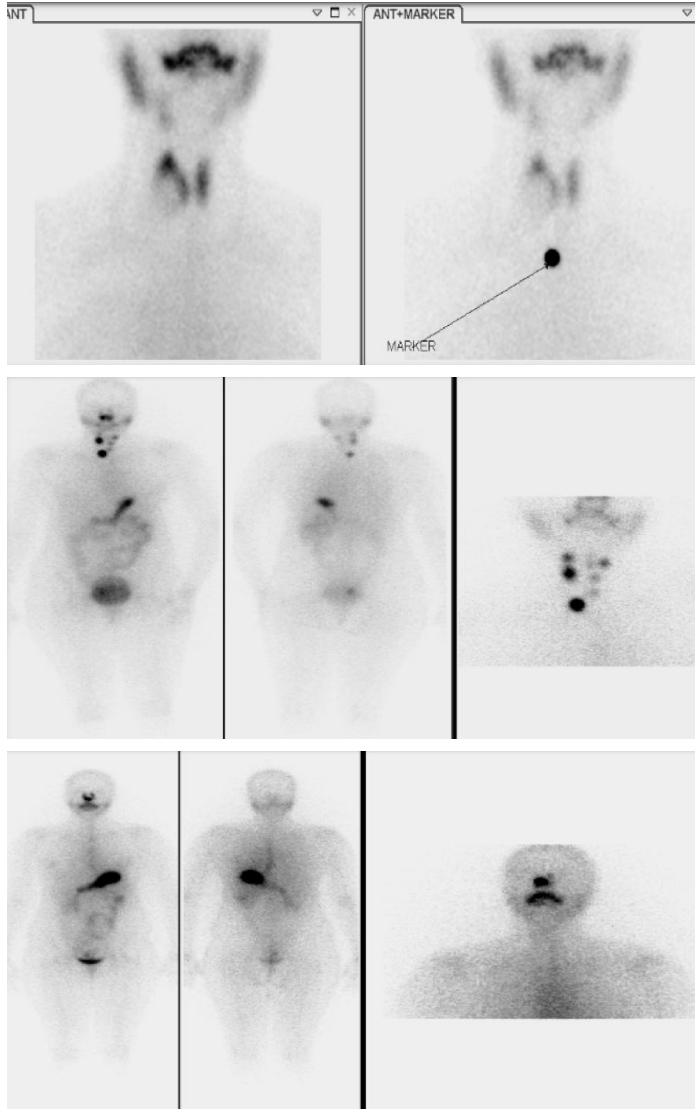
 CASE (15)

32 year old female patient presented with neck swelling.



- **What is the study?**
- **What is the agent used?**
- **What are the imaging findings?**
- **What is the most likely diagnosis?**
- **Prognosis?**
- **What is the marker for well-differentiated thyroid tumors?**
- **What is the marker for Medullary carcinoma?**

32 years old female patient presented with neck swelling.



- **What is the study?**

Nuclear thyroid scan.

- **What is the agent used?**

I-123 isotope.

- **What are the imaging findings?**

In Jan 2014 (Upper picture) we have **cold nodule with low uptake** in the right lower lobe of thyroid (**Next step? FNA**) We did thyroidectomy. we didn't operate on lymph node. On March 2014 (Middle picture) We see **multiple hot nodules** that **spread locally** in the neck **to lymph nodes** we suspect this patient to have papillary carcinoma (Due to mode of transmission) we give her **radiation therapy with iodine-131** 100 mg. Oct 2014 (Lower picture) we do scan to exclude any remnant. The patient responds to treatment.

- **What is the most likely diagnosis?**

Papillary carcinoma.

- **Prognosis?**

It is good because papillary has only lymph node metastasis, **so usually it spreads locally.** (**Follicular has hematogenous metastasis -bad prognosis-**)

- **What is the marker for well-differentiated thyroid tumors?**

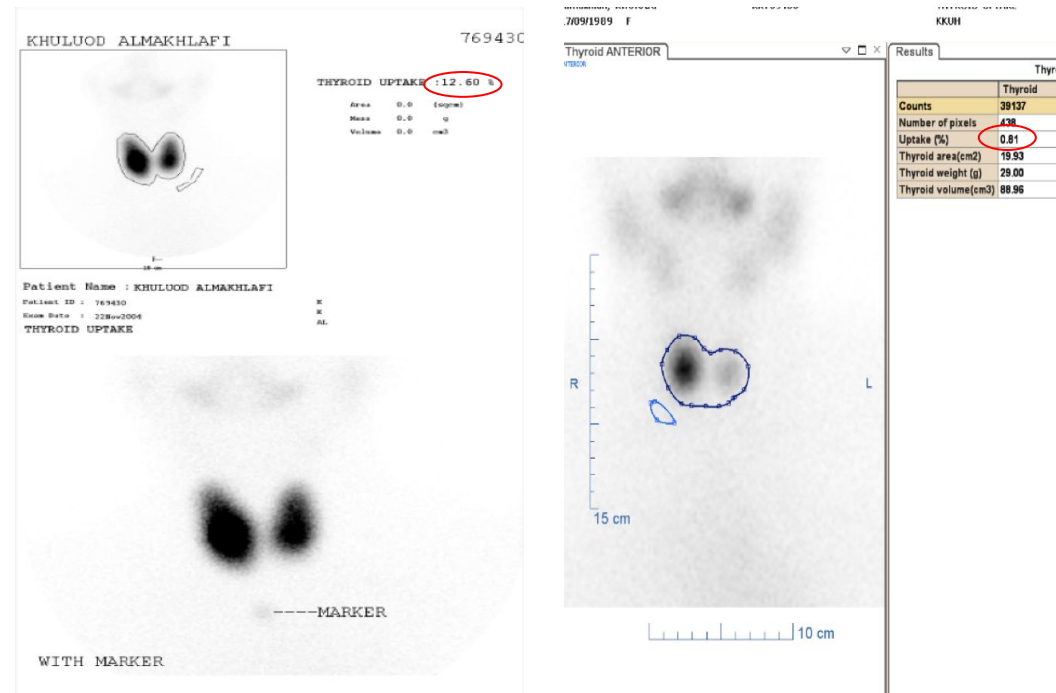
Thyroglobulin.

- **What is the marker for Medullary carcinoma?**

Calcitonin.

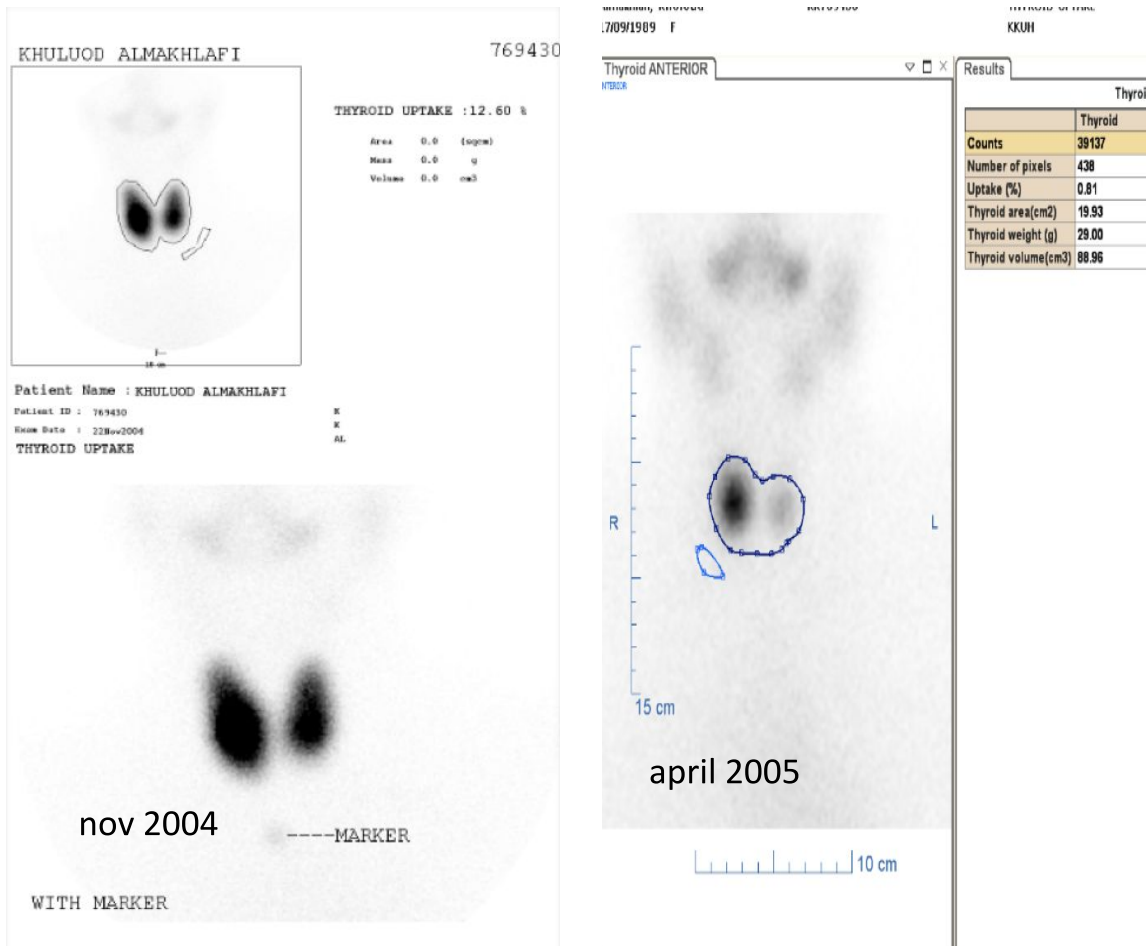
 CASE (16)

26 year old female patient presented with thyrotoxicosis symptoms.



- What is the study?
- What is the agent used?
- What are the imaging findings?
- What is the most likely diagnosis?
- What is the main side effect of iodine 131?

26 years old female patient presented with thyrotoxicosis symptoms.



- What is the study?

Nuclear scan of the thyroid.

- What is the agent used?

Tc-99m Pertechnetate.

- What are the imaging findings?

Diffuse enlargement with Increased uptake 12.6%. In (November 2004 left picture) patient received treatment and had a good response. In (April 2005 right picture) another image taken found to have a decrease in uptake with 0.81%.

- What is the most likely diagnosis?

Graves (November). treated with iodine-131, 5-15 mg.

- what is the main side effect of iodine 131?

Hypothyroidism (April).

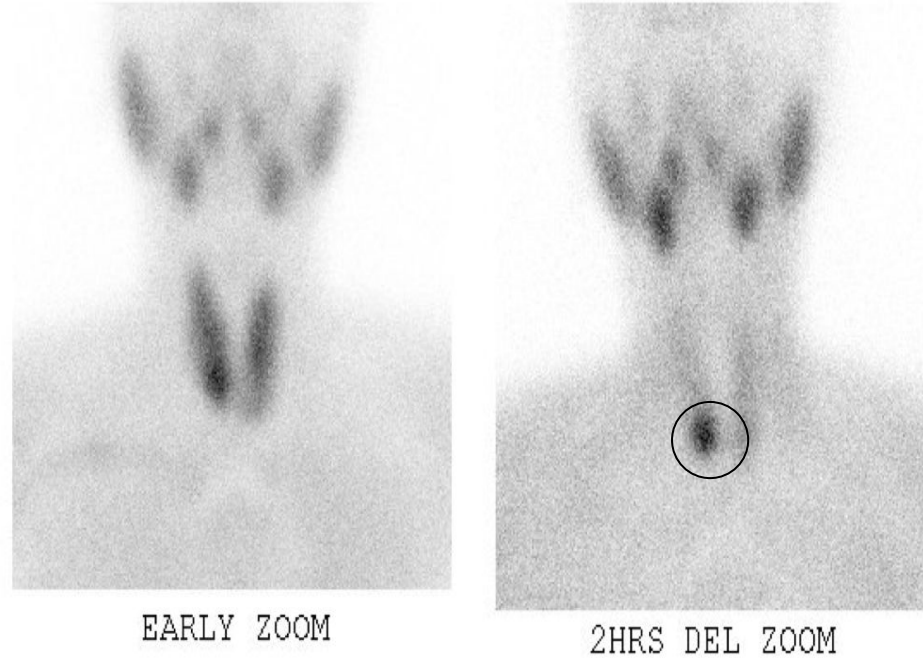


Teaching Points

Iodine 131 is used to treat thyroid disorders including thyroid cancer and hyperthyroidism.

 CASE (17)

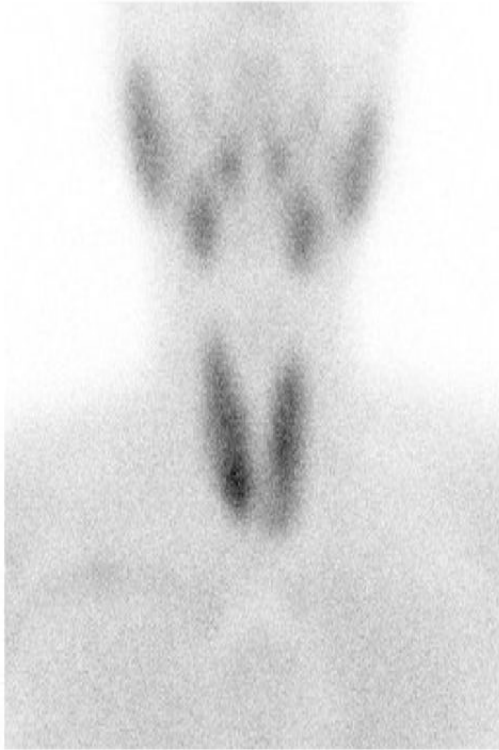A patient with High PTH and High Ca.



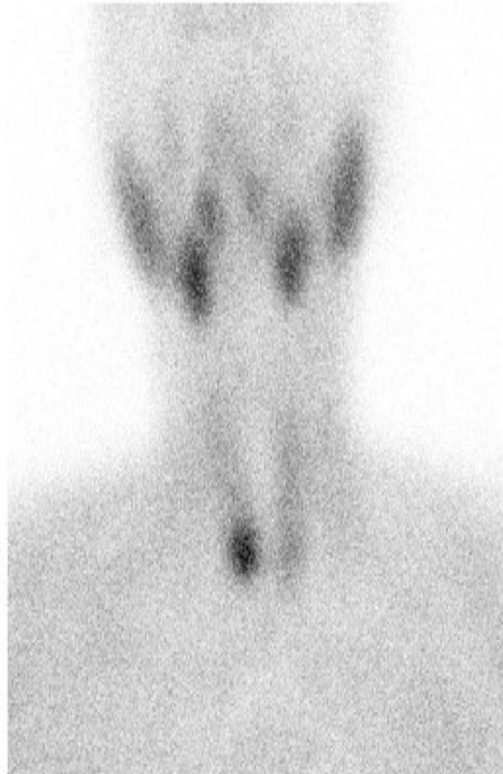- **What is the study?**
- **What is the agent used?**
- **What are the imaging findings?**
- **What is the most likely diagnosis?**

 CASE (17)

A patient with High PTH and High Ca.



EARLY ZOOM

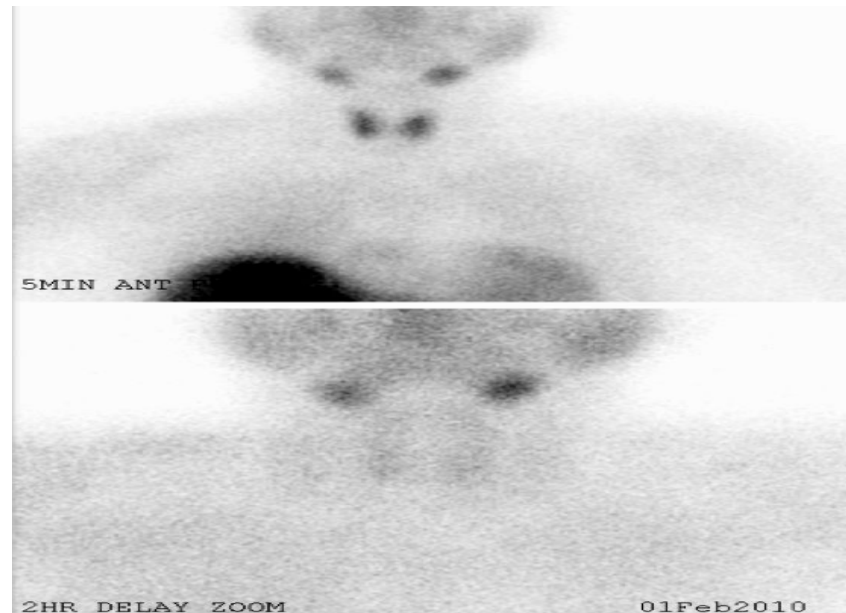


2HRS DEL ZOOM

- **What is the study?**
Parathyroid scan.
- **What is the agent used?**
Tc-99m **Sestamibi** (Dual Phase).
- **What are the imaging findings?**
Right lower parathyroid nodule.
- **What is the most likely diagnosis?**
Parathyroid adenoma.

 CASE (18)

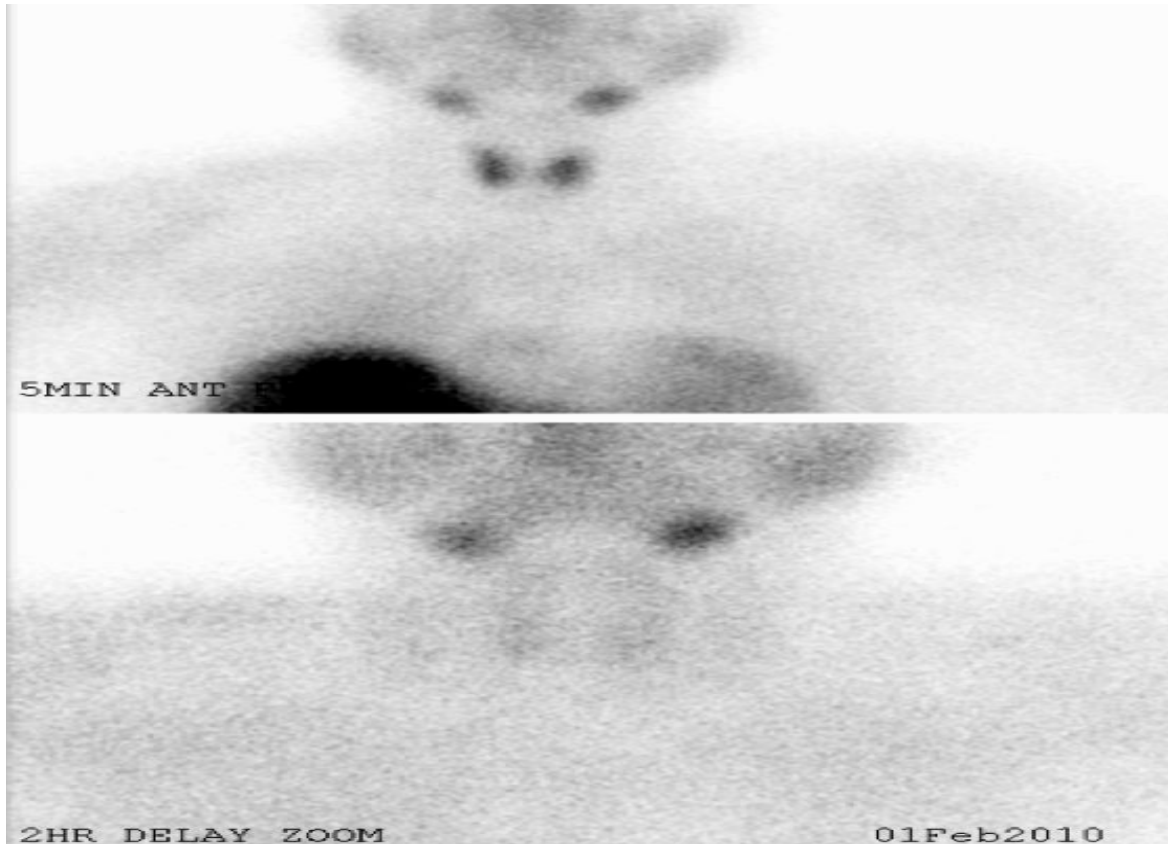
A patient with High PTH and High Ca.



- **What is the study?**
- **What is the agent used?**
- **What are the imaging findings?**
- **What is the most likely diagnosis?**

 CASE (18)

A patient with High PTH and High Ca.



- **What is the study?**

Parathyroid scan. ask for MRI if you can not tell.

- **What is the agent used?**

Tc-99m Sestamibi (Dual Phase), which usually concentrates in cells with mitochondria.

- **What are the imaging findings?**

False negative because it is from the clear cells which have no mitochondria.

- **What is the most likely diagnosis?**

Parathyroid adenoma.

- **Remember:**

Sestamibi is taken up by mitochondria in parathyroid.

Parathyroid has two types of cells: Chief cells with no mitochondria and Oxyphil cells (Rich in mitochondria)

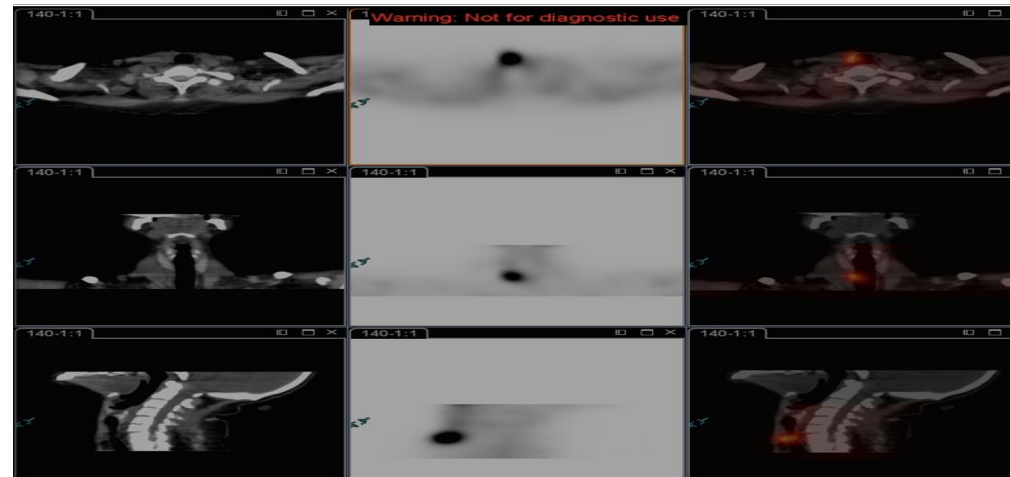
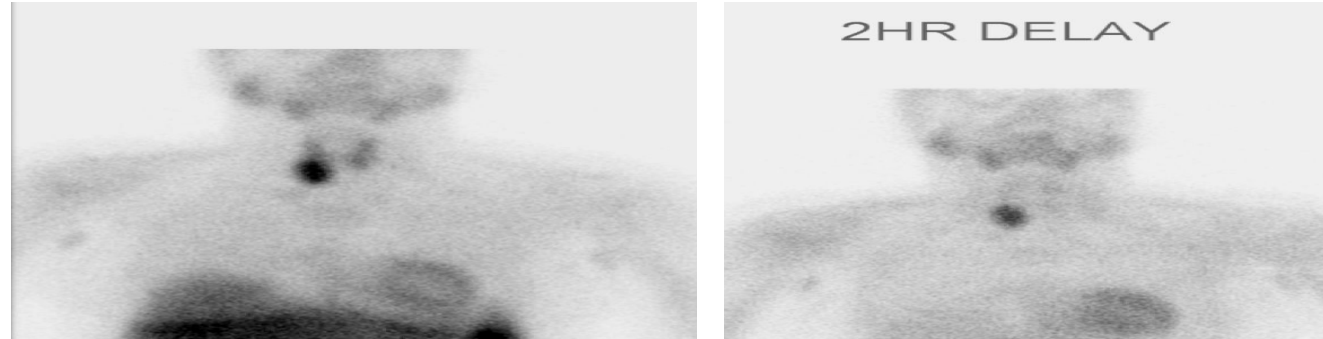
Low mitochondria = Low uptake

- **Next step?**

CT to locate the site of adenoma.

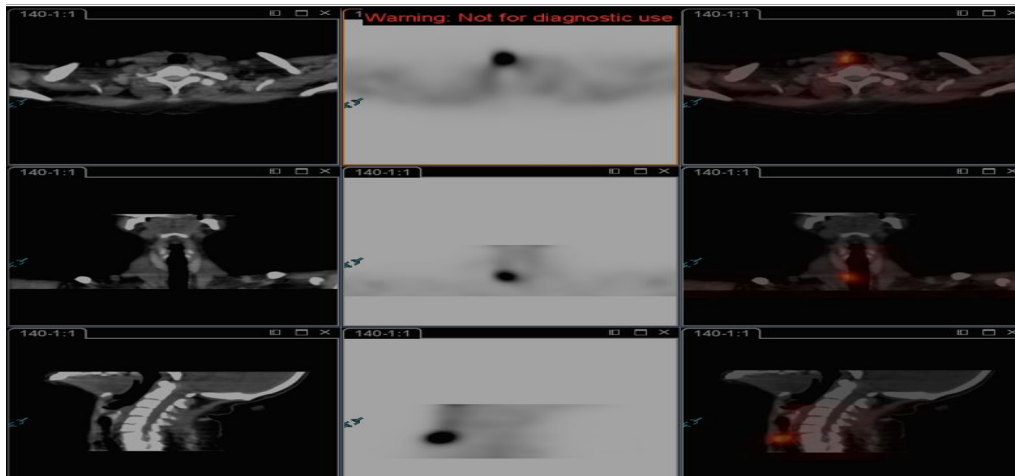
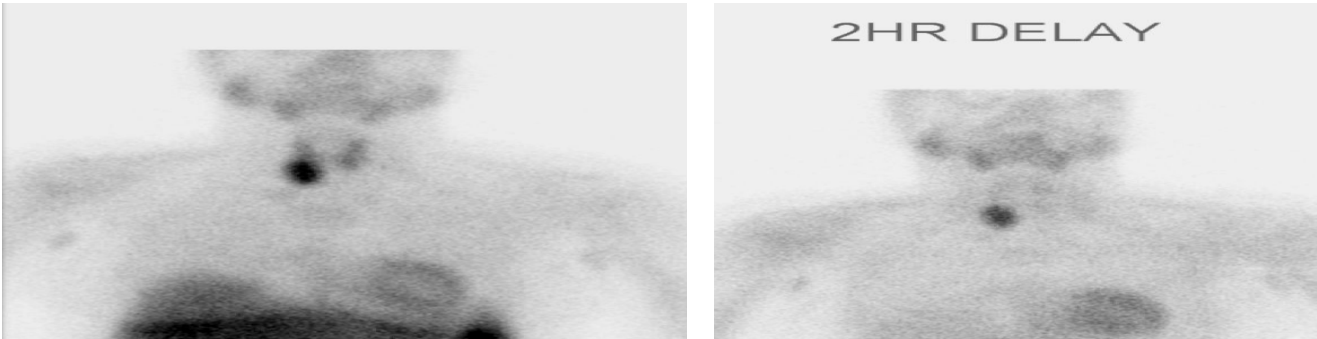
 CASE (19)

A patient with High PTH and High Ca.



- What is the study?
- What is the agent used?
- What are the imaging findings?
- What is the most likely diagnosis?

A patient with High PTH and High Ca.



- **What is the study?**

Parathyroid scan & SPECT CT.

- **What is the agent used?**

Tc-99m Sestamibi (Dual Phase).

- **What are the imaging findings?**

Adenoma anterolateral to the trachea approved by SPECT CT. (Adenoma close to the the skin. Superficial on sagittal view).

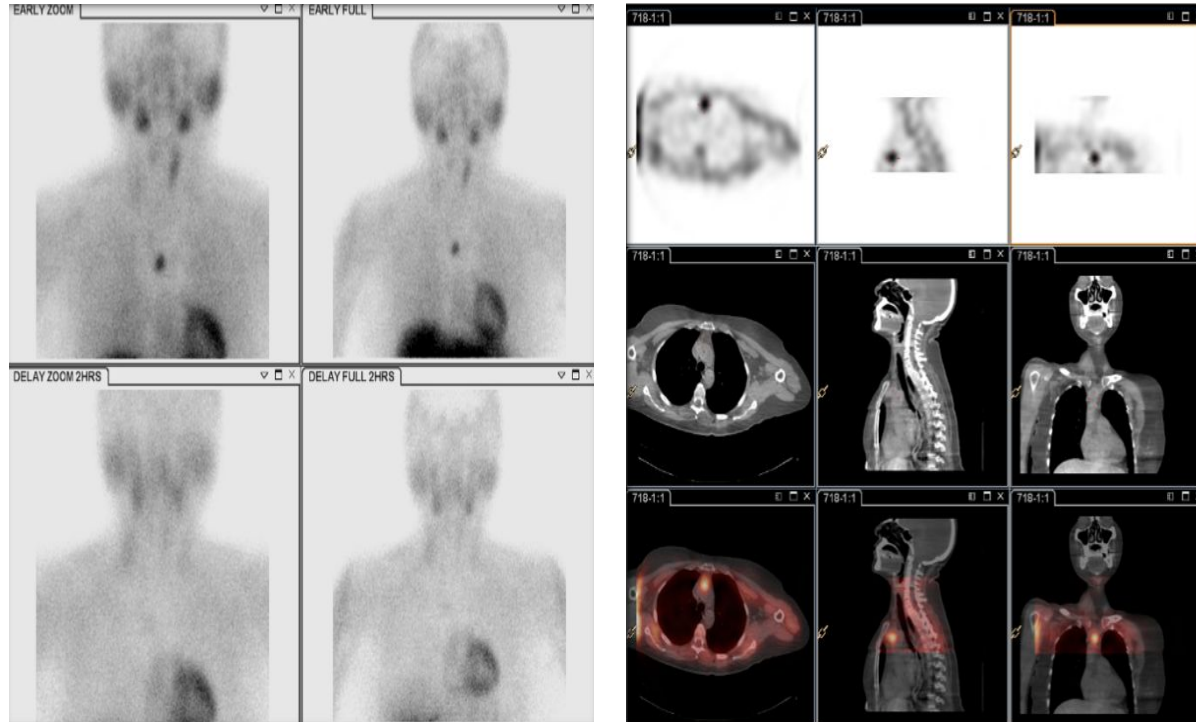
- **What is the most likely diagnosis?**

Eutopic Parathyroid adenoma.

To help the surgeon we order SPECT CT to localize tumor.

 CASE (20)

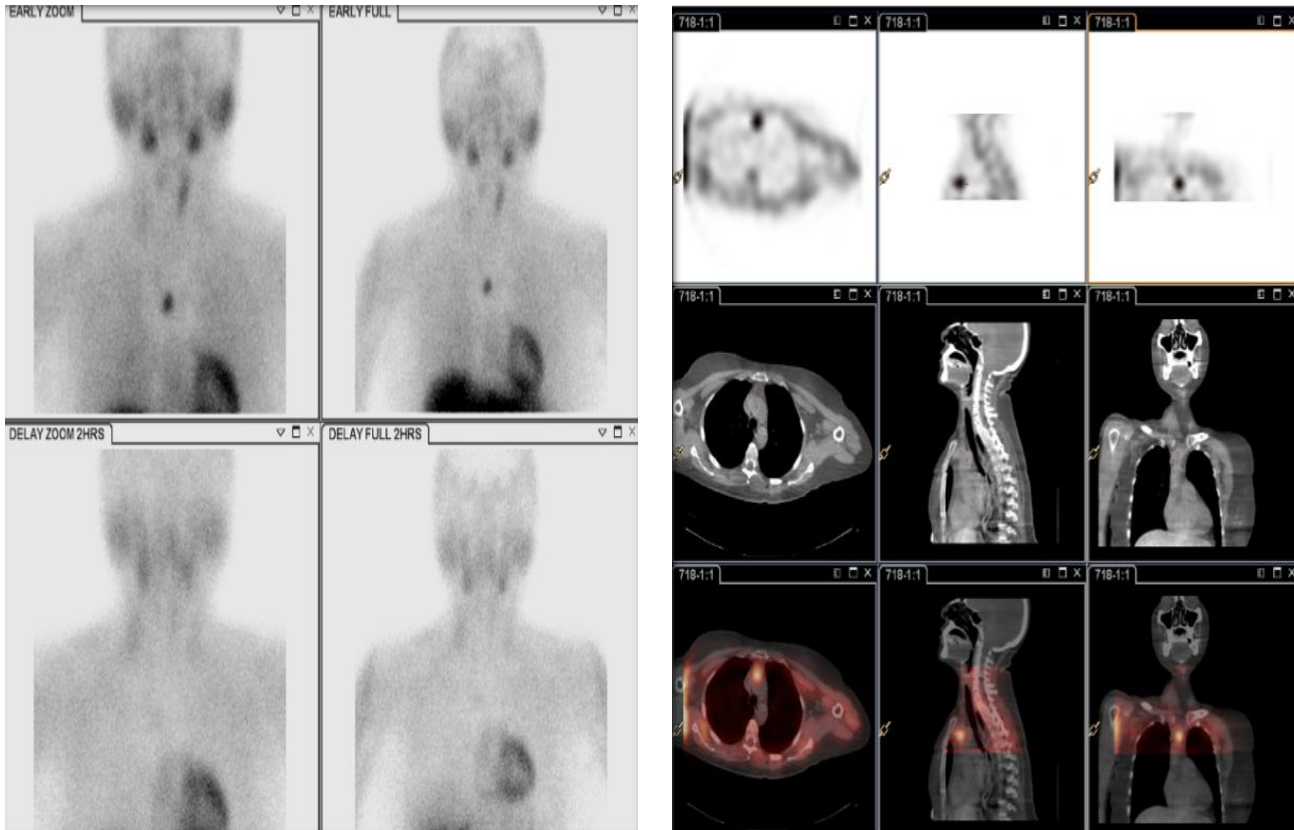
30 year old male patient with suspected hyperparathyroidism.



- What is the study?
- What is the agent used?
- What are the imaging findings?
- What is the plan of treatment?

CASE (20)

30 year old male patient with suspected hyperparathyroidism.



- **What is the study?**
Parathyroid scan and SPECT CT.
- **What is the agent used?**
Tc-99m Sestamibi (Dual Phase), (SPECT CT).
- **What are the imaging findings?**
Ectopic retrosternal nodule (PT adenoma).
- **What is the plan of treatment?**
Both Thoracic and endocrine surgeons need to be involved in this surgery.

Teaching Points



In patients with hyperparathyroidism, parathyroid scan is used to detect and localize eutopic and ectopic parathyroid adenoma.

End of the lecture, best of luck.
Don't forget to give us your feedback.

WE NEED
YOUR
FEEDBACK

Three vertical icons representing writing instruments: a blue pen on the left, a yellow pencil in the middle, and another blue pen on the right.