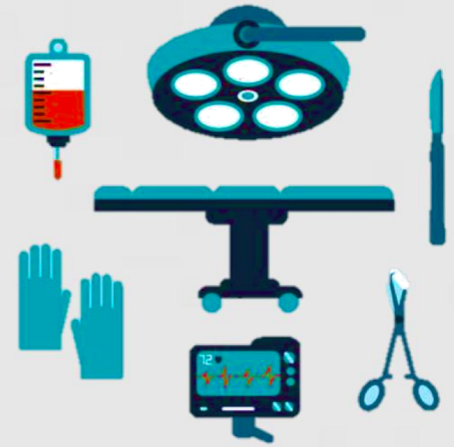
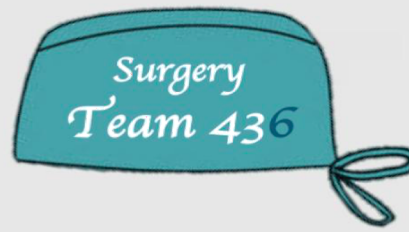


Acute Abdomen

Objectives:

- Define acute abdomen.
- Describe a general approach to acute abdomen.
- Discuss common causes of acute abdomen through case scenarios.

Resources:

- Davidson's (Chapter 12 pg 159).
- 436 doctors slides.
- 435's teamwork.
- Surgical Recall.

Done by: Nada Alsomali, Rawan Alqahtani, Ruba Barnawi

Leaders: Heba Alnasser, Jawaher Abanumy, Mohammed Habib, Mohammad Al-Mutlaq

Revised by: Maha AlGhamdi

COLOR INDEX:

NOTES , IMPORTANT , EXTRA , DAVIDSON'S

[EDITING FILE](#)

[FEEDBACK](#)

Acute Abdomen

Definition: Acute abdomen denotes any **sudden, spontaneous** (not influenced by something else), **non-traumatic** disorder in the abdominal area that requires **urgent surgery** in **most cases** (not all acute abdomens are managed surgically, some are medical ex: pancreatitis, also bowel obstruction can be treated conservatively 50% of the time).

[Full list of possible causes of acute abdominal pain](#) (extra from the book)

Pathophysiology:

Visceral Pain	Somatic (parietal) Pain
<ul style="list-style-type: none"> Visceral pain is insensitive to mechanical, thermal, or chemical stimulation, <u>therefore can be handled, cut or cauterized painlessly</u>. However, they are sensitive to tension (whether due to overdistension or traction), visceral muscle spasm and ischaemia. Visceral pain is typically described as dull and deep-seated, and is usually localised vaguely to the area occupied by the viscus during development*. 	<ul style="list-style-type: none"> The parietal peritoneum is sensitive to <u>mechanical, thermal</u> or <u>chemical</u> stimulation, so when irritated, a reflex contraction of muscles, causing guarding¹ and hyperaesthesia² of skin. Somatic pain is classically described as sharp, and is usually well localized. Peripheral diaphragmatic irritation leads to tenderness and rigidity, & when irritated Centrally, pain is referred shoulder area.

*The abdominal organs (mainly GIT) develop from 3 structures:

- Foregut (esophagus → second part of duodenum)
- Midgut (third part of duodenum → proximal 2/3 of transverse colon)
- Hindgut (distal 1/3 of transverse colon → upper part of anal canal)

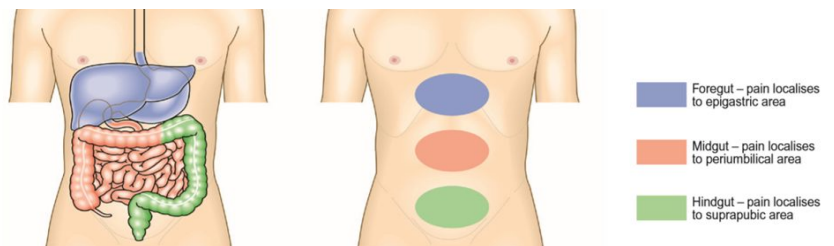


Fig. 8.5 Abdominal pain. Perception of visceral pain is localised to the epigastric, umbilical or suprapubic region, according to the embryological origin of the affected organ.

The underlying pathological process of abdominal pain may be:

Inflammation	Infarction / Ischemia	Perforation	Obstruction
<ul style="list-style-type: none"> Acute inflammation of an intra-abdominal organ or the peritoneum as a result of an irritant. Broadly categorized into infective and non-infective No matter what the trigger of the inflammation, the subsequent pathological process is the same. <u>Example: IBD, acute appendicitis, acute diverticulitis, acute cholecystitis, peritonitis.</u> 	<ul style="list-style-type: none"> An infarct is an area of ischaemic necrosis caused either by an occlusion of the arterial supply or the venous drainage in a particular tissue, or by a generalized hypoperfusion in the context of shock. In acute abdominal pain, intestinal infarction is most common cause. Acute mesenteric (bowel) ischemia may be caused by acute mesenteric arterial embolism due to underlying cardiac cause (AF, post-MI, prosthetic valve) or abdominal / thoracic aneurysm. 	<ul style="list-style-type: none"> Spontaneous perforation of an intra-abdominal viscus may be the result of weakening of the wall of the viscus, due to degeneration, inflammation, infection or ischaemia, will predispose to perforation, as will peptic ulceration, acute appendicitis and acute diverticulitis. Perforation can also be iatrogenic. 	<ul style="list-style-type: none"> Obstruction refers to impedance of the normal flow of material through a hollow viscus. It may be caused by the presence of a lesion within the lumen of the viscus, an abnormality in its wall, or a lesion outside the viscus causing extrinsic compression. The smooth muscle in the viscus will contract reflexly to overcome the impedance. This reflex contraction produces 'colicky abdominal pain'.

¹ rigidity of the abdominal wall

² excessive physical sensitivity,

General Approach to Acute Abdomen

SOAP (these notes are used to approach an emergency condition or as progress note in wards or clinics)

- **Subjective** – History Taking (what the patients says ex: “I’m feeling hot”)
- **Objective** - Physical Examination + **Vital Signs** (ex: “temp = 38” , “tenderness on examination”)
- **Assessment** – Investigations (to limit and narrow the differentials which has been obtained from history and examination)
- **Plan** - Treatment

1- History taking:

- Age , gender , occupation (it is important to know who you are dealing with)
- **Chief complaint:** pain*, vomiting, distention, defecation, fever.
- Past history (ex: history of **peptic ulcer** and now presents with acute abdomen most likely **perforation**)
- Past family + Social history + Allergies + Medication

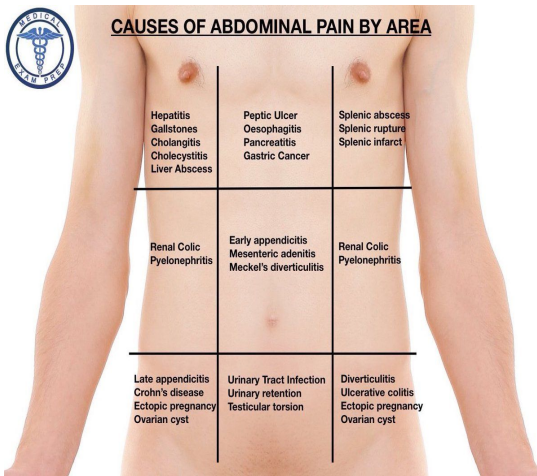
*Most of the time patient will present with pain (**SOCRATES**):

Site	(see the pictures in the next page)
Onset	Usually sudden. (sudden= perforation, gradual= Inflammation)
Character	Colicky, stabbing, burning, grabbing, gripping
Radiation	<p>Radiation vs shifting:</p> <ul style="list-style-type: none"> ● Radiation means pain extends directly from one place to another, while usually remains present at the site of onset , it usually means that other structures are becoming involved. It usually follows nerve dermatomes. <u>Ex</u> : pain from acute pancreas radiates to the back, cholecystitis pain radiates to the right shoulder, and duodenal ulcer may radiate through to the back ● Shifting means it started in one place but “ disappeared “ and moved to include a new area. <u>Ex</u> : acute appendicitis , its starts in the periumbilical area then it shift to right lower quadrant (what is the mechanism behind this? First the pain is visceral so it is dull and vague to the periumbilical area, then as the inflammation reaches the parietal peritoneum it becomes somatic and the pain becomes sharper and more localised to the right iliac fossa) so in summary it was visceral then became parietal/somatic (started vaguely then shifted to the right lower quadrant.
Associated Symptoms	Vomiting, diarrhea or constipation, fever
Time	
Exacerbating & Relieving Factors	Patients who have ureteric stones will move a lot to find a comfortable position while patients who have appendicitis (or peritonitis) will lie very still because movement increases their pain.
Severity	Rated on a scale of 0 - 10 (0 no pain & 10 the worst pain you experienced) 1 - 3 (mild) / 4 - 6 (moderate) / 7 - 10 (severe)

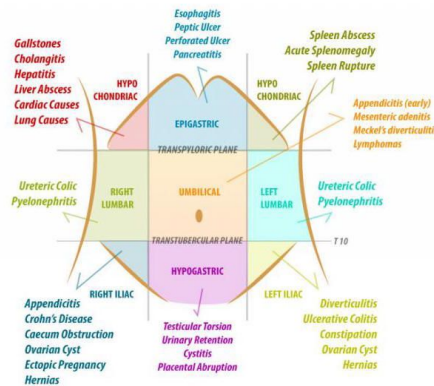
Evaluation of pain might lead you to the correct diagnosis!
Good history will give you the diagnosis in 70% of cases.



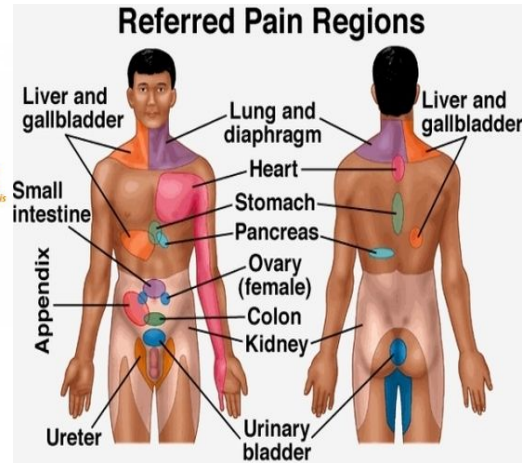
CAUSES OF ABDOMINAL PAIN BY AREA



QUADRANTS OF ABDOMEN
DIFFERENTIAL DIAGNOSIS (PAIN)



Referred Pain Regions



These pictures are **EXTRA** to help you understand.

2- Physical

- General Look (they look very sick)
- **Vital Signs:** usually abnormal (febrile, tachycardic, hypotensive)
 - If abnormal **stabilize and resuscitate the patient first (A, B, C's)** then continue your examination because if you don't the patient might collapse and arrest.
- Head & Neck
- Chest → why do I check the chest in acute abdomen?
 - To rule out other causes that can be a cause of acute abdomen but originate from the chest Ex:
 1. Acute epigastric pain might originate from the **heart (ischemic heart disease)**.
 2. **Basal pneumoniae** (can be reflected into the upper abdomen or spleen)
- Abdomen ([Table from Davidson](#) summarizing findings in examination)
- Rectal Examination → look for blood, tumor/mass, tenderness.
- Vaginal Examination → rule out **pelvic inflammatory disease "PID"** (ex: salpingitis , or oophoritis)
- Specific clinical signs in acute abdominal pain:

Sign	Explanation	Dx	Picture
Murphy's sign	taking a deep breath elicits acute pain while pressing downwards into the RUQ	acute cholecystitis	
Boas's sign	pain radiates to the tip of the scapula and there is a hyperaesthesia just below the scapula	acute cholecystitis	
Grey turner's sign	bruising and discoloration in the left flank	severe acute pancreatitis.	
Cullen's sign	bruising and discoloration around the umbilicus		

**Proper History + Physical will give you the diagnosis in 90% of cases.
For the remaining 10% we need to order investigations.**

Investigations: (Why do we investigate? To narrow the differentials) Depends on the case

Labs:

- Complete Blood Count → look for leukocytosis + anemia
- Electrolytes, BUN, Creatinine → check for electrolyte disturbances, or dehydration in cases of vomiting or diarrhea
- LFTs → look for hepatitis, cholangitis, acute cholecystitis which may cause acute abdomen
- Serum Amylase + Lipase → acute **pancreatitis**.
- Serum Lactate → To rule out **ischemia** and gangrene
- ABGs → **monitor the acid-base status** make sure the patient has no metabolic or respiratory acidosis or alkalosis.
- Glucose : if we suspect DKA

Imaging:

- CXR → to rule out **pneumoniae**, perforation = abdominal gases (free **air under the diaphragm**)
- AXR (Abdominal x-ray) – KUB , air fluid level = bowel obstruction , calcification = chronic pancreatitis + renal stones + aneurysm (calcification of aorta).
- Abdominal Ultrasound gallbladder, hepatobiliary diseases and sometimes renal stones
- Abdominal **CT** → acute **appendicitis**, tumor, distention, perforation, site of obstruction, etc.
- Angiography / Duplex Scanning (not usually done, only if you suspect **bowel ischemia**)
- Nuclear scan: in case of acute cholecystitis that US could not find stones on it , to diagnose **acalculous cholecystitis**.

Others:

- ERCP: interventional endoscopic injection of a dye into common bile duct to see if there is a stone there leading to cholangitis.
- MRCP: (similar to ERCP but non invasive to visualize the biliary tree and locate possible obstruction).
- Colonoscopy: obstruction
- Gastroscopy: if there is **bleeding**.

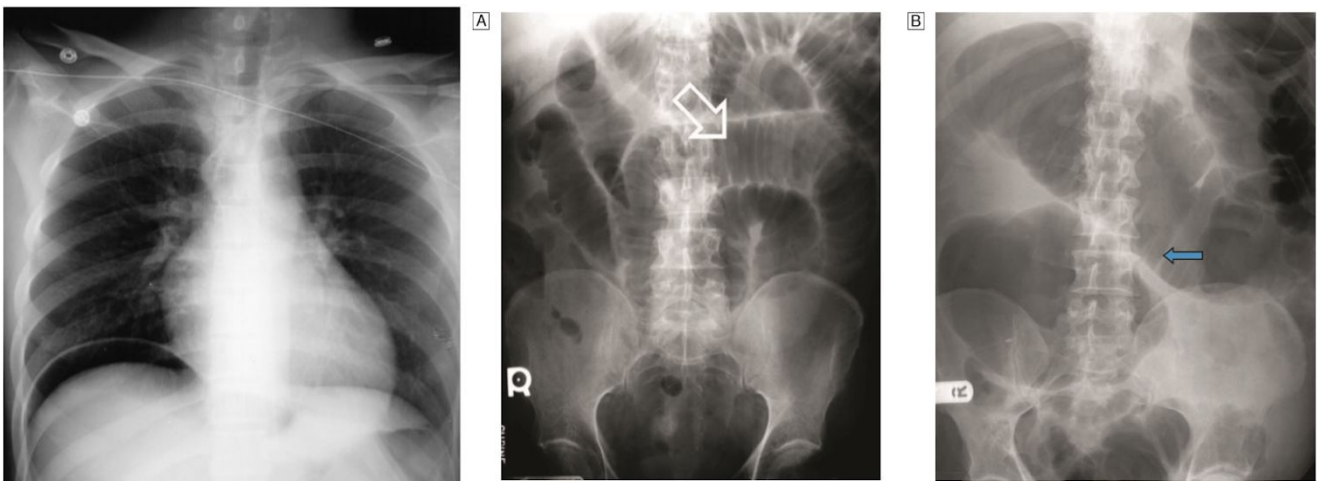


Fig. 12.6 Gas under the diaphragm seen on the erect chest X-ray in a patient with a perforated peptic ulcer.

Fig. 12.7 Abdominal X-rays in bowel obstruction. [A] Supine film in a patient with small bowel obstruction showing valvulae comitantes. [B] X-ray demonstrating large bowel obstruction with arrow at a haustration.

These pictures are **EXTRA** from Davidson.

Diagnosis

- Acute Abdomen + Shock*(hypotension tachycardia) – Acute Pancreatitis/ Ruptured AAA
- Generalized Peritonitis (whole abdomen is tender and rigid) – Ruptured/perforated Viscus (Example perforated peptic ulcer disease, or perforated small bowel, or perforated colon)
- Localized Peritonitis - according to location, ex:
 - Right iliac fossa could be Acute Appendicitis or in young female rupture of ovarian cyst or salpingitis (PID)
 - Right upper quadrant acute tenderness → cholecystitis
 - Mid portion of abdomen → pancreatitis, or peptic ulcer
 - Left upper quadrant → splenic disease (infection, abscess)
 - Left lower quadrant → sigmoid disease like **diverticulitis**
 - Flank region → kidneys
- **Bowel Obstruction** and ascites present with **distention** (to differentiate do percussion: in ascites dullness, in obstruction tympanic)
- **Medical Causes (Lobar Pneumonia, Acute Inferior MI)**

*What do we mean by shock? When a patient is tachycardic + hypotensive.

What are the usual causes of shock in acute abdomen? Pancreatitis, ruptured aortic aneurysm.

Management

Category 1	Need immediate operation (patient may die or arrest) Best <u>example</u> : ruptured AAA (abdominal aortic aneurysm)
Category 2 “urgent”	Preoperative preparation and emergency operation within 6 hours . Like category 1 but we have to resuscitate them before surgery (can't take hypotensive pt to OR) we still have some time. Why resuscitate? Because if we don't they complication rate becomes higher. Why don't we resuscitate AAA? Because we can't → whatever we give them will not reach the organs since the aorta is ruptured. <u>Ex</u> : peritonitis , ischemia, etc...
Category 3 “semi-urgent”	Urgent operation within 24 hours It can wait but it has to be operated on <u>ex</u> : acute appendicitis.

Not all acute abdomen need surgery:

- Conservative treatment:
 - Ex: **acute pancreatitis**
 - What are the causes? **1.** Biliary pancreatitis (caused by obstruction) **2.** Trauma during ERCP³ (gallstone removal) **3.** Dyslipidemia (hypercholesterolemia) **4.** Idiopathic
 - Managed non-surgically 90% of times, the remaining 10% it becomes complicated → **necrotizing pancreatitis** (when it is severe and causes abscess or necrosis in pancreas) and requires surgical intervention.
- Observation
 - Sometimes we can't identify the cause. so we just observe (ex: يصير التواء في الأمعاء وتفك) and if the patient gets better we ask him to go home and come back if the pain (or disorder) returns.
 - **Early appendicitis** can confuse us, because history could be typical of appendicitis but examination and investigation would be normal. So we admit and observe and they either recover completely (with antibiotics) or they get worse and we operate.
- Discharge

³ Endoscopic retrograde cholangiopancreatography (the most common complication of ERCP is pancreatitis)



Recall: (EXTRA)

What are peritoneal signs in acute abdomen?

Signs of peritoneal irritation: extreme tenderness, percussion tenderness, rebound tenderness, voluntary guarding, motion pain, involuntary guarding/ rigidity (late)

Define the following terms:

Rebound tenderness: Pain upon releasing the palpating hand pushing on the abdomen

Voluntary guarding: Abdominal muscle contraction with palpation of the abdomen

Involuntary guarding: Rigid abdomen as the muscles “guard” involuntarily

Colic: Intermittent severe pain (usually because of intermittent contraction of a hollow viscus against an obstruction)

What conditions can mask abdominal pain? Steroids, diabetes, paraplegia

What is the best way to have a patient localize abdominal pain? “point with **one** finger where the pain is worse”

What are the differential diagnoses by quadrant?

RUQ:

Cholecystitis, hepatitis, PUD, perforated ulcer, pancreatitis, liver tumors, gastritis, hepatic abscess, choledocholithiasis, cholangitis, pyelonephritis, nephrolithiasis, appendicitis (**especially during pregnancy**), thoracic causes (e.g. pleurisy/pneumoniae), PE, pericarditis, MI (especially inferior MI).

LUQ:

PUD, perforated ulcer, gastritis, splenic injury, abscess, reflux, dissecting aortic aneurysm, thoracic causes, pyelonephritis, nephrolithiasis, hiatal hernia (strangulated paraesophageal hernia), Boerhaave’s syndrome, Mallory-Weiss tear, splenic artery aneurysm, colon disease

LLQ:

Diverticulitis, sigmoid volvulus, perforated colon, colon cancer, urinary tract infection, small bowel obstruction, inflammatory bowel disease, nephrolithiasis, pyelonephritis, fluid accumulation from aneurysm or perforation, referred hip pain, gynecologic causes, appendicitis (rare)

RLQ:

Appendicitis! And same as LLQ; also mesenteric lymphadenitis, cecal diverticulitis, Meckel’s diverticulum, intussusception

What is the differential diagnosis of epigastric pain?

PUD, gastritis, MI, pancreatitis, biliary colic, gastric volvulus, Mallory-Weiss tear

What are nonsurgical causes of abdominal pain?

Gastroenteritis, DKA, sickle cell crisis, rectus sheath hematoma, acute porphyria, PID, kidney stone, pyelonephritis, hepatitis, pancreatitis, pneumonia, MI, C. difficile colitis

What is the unique differential diagnosis for the patient with AIDS and abdominal pain?

In addition to all common abdominal conditions:

CMV (most Common)---Kaposi’s sarcoma---Lymphoma---TB---MAI (Mycobacterium Avium Intracellulare)

What is the classic position of a patient with peritonitis? Motionless (often with knees flexed)

What is the classic position of a patient with kidney stones? Cannot stay still, restless, writhing in pain

Classically, what endocrine problems can cause abdominal pain?

1. Addison crisis
2. DKA (Diabetic KetoAcidosis)

Note: These topics were not covered in the lecture but were mentioned in the book chapter.

Acute Appendicitis [Video\(05:11\)](#)

Anatomy:

- The appendix is a worm-shaped blind-ending tube that arises from the posteromedial wall of the caecum 2 cm below the ileocaecal valve. It varies in length from 2 to 25 cm, but is most commonly 6–9 cm long.
- On the surface of the abdomen, this point lies one-third of the way along a line drawn between the right anterior superior iliac spine and the umbilicus (**McBurney's point**).

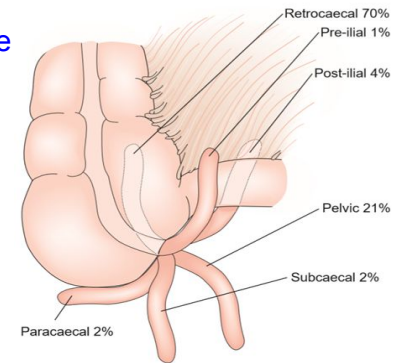


Fig. 12.15 Variations in the position of the appendix.

Etiology:

despite its prevalence, the etiology of acute appendicitis remains unclear.

Pathogenesis:

Obstruction of the lumen of the appendix is thought to play the main role in the initiation of inflammation.

Clinical Features:

- Only 50% of patients with acute appendicitis give a typical history.
- Most common in the under 40s with peak incidence between **8 and 14 years of age**.

History:

- Classically, the onset of acute appendicitis is associated with the gradual onset of poorly localized **central abdominal pain (umbilical)**.
- After a variable amount of time, the pain **moves to the right iliac fossa** and changes in character, to become sharper, constant and well localized (when the parietal peritoneum overlying the appendix becomes involved in the inflammatory process).
- It is aggravated by movement and coughing. And associated with anorexia and occasional **vomiting**.

Examination:

- The patient with established acute appendicitis looks unwell, the temperature is usually only mildly elevated (37.3–38.5°C) and there is often a tachycardia.
- Classically, the area of maximal **tenderness** is over **McBurney's point**, with **guarding** and **rebound tenderness**.

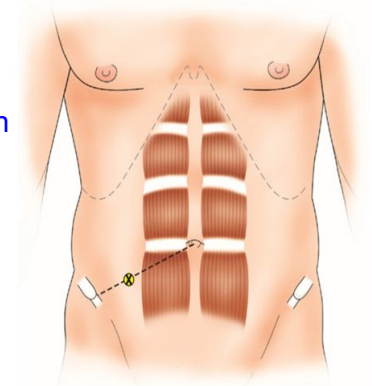


Fig. 12.14 McBurney's point.

Peritonitis

- Inflammation of the peritoneum is a common feature of the acute abdomen. It can be classified as acute or chronic, septic or aseptic, and primary or secondary.
 - **Primary peritonitis:** In adults, spontaneous bacterial peritonitis (SBP) may occur in patients with the **nephrotic syndrome**, but is more frequently seen in those with liver cirrhosis or **chronic renal failure** (particularly in patients on peritoneal dialysis). Classically, diffuse peritonitis with **generalized abdominal tenderness and rigidity** develops within 24 hours. **Fever and leukocytosis** occur early.
 - **Secondary peritonitis:** Acute suppurative peritonitis secondary to visceral disease is the most common form of peritonitis in surgical practice.



Recall: (EXTRA)

What is acute appendicitis?

Obstruction of the appendiceal lumen (fecalith, lymphoid hyperplasia), producing a closed loop with resultant inflammation that can lead to necrosis and perforation.

What is its claim to fame?

Most common surgical disease requiring emergency surgery in children

What is the usual presentation?

Onset of referred or periumbilical pain followed by anorexia, nausea, and vomiting (Note: Unlike gastroenteritis, pain precedes vomiting, then migrates to the RLQ, where it intensifies from local peritoneal irritation) If the patient is hungry and can eat, seriously question the diagnosis of appendicitis

How is the diagnosis made? >> History and physical exam

What are the signs/symptoms?

Signs of peritoneal irritation may be present—guarding, muscle spasm, rebound tenderness, obturator and Psoas signs; low-grade fever rising to high grade if perforation occurs

What is the differential diagnosis?

Intussusception, volvulus, Meckel's diverticulum, Crohn's disease, ovarian torsion, cyst, tumor, perforated ulcer, pancreatitis, PID, ruptured ectopic pregnancy, mesenteric lymphadenitis

What are the associated lab findings with appendicitis?

Increased WBC (>10,000 per mm³ in > 90% of cases, with a left shift in most)

What is the role of urinalysis?

To evaluate for possible pyelonephritis or renal calculus, but mild hematuria and pyuria are common in appendicitis because of ureteral inflammation

What is the "hamburger" sign?

Ask patients with suspected appendicitis if they would like a hamburger or favorite food; if they can eat, SERIOUSLY question the diagnosis

What radiographic studies may be performed?

Often none; CXR to rule out RML or RLL pneumonia; abdominal films are usually nonspecific, but calcified fecalith is present in 5% of cases; U/S, CT

What is the treatment?

Nonperforated: prompt appendectomy and cefoxitin to avoid perforation

Perforated—triple antibiotics, fluid resuscitation, and prompt appendectomy; all pus is drained and cultures obtained, with postoperative antibiotics continued for 5 to 7 days, +/- drain

How long should antibiotics be administered if nonperforated? >> 24 hours

How long if perforated? >> Usually 5 to 7 days or until WBCs are normal and patient is afebrile

What is the approximate risk of perforation?

~ 25% after 24 hours from onset of symptoms

~50% by 36 hours

~75% by 48 hours



Scenarios

(Answers from team 435)

Scenario 1

A 35 year-old male presented to the ER with 2 days history of abdominal pain. He took antacids but did not help him at all!

DDx: Acute appendicitis - PUD - Bowel obstruction.

- S** - 35 year old, male, 2 days history of abdominal pain. He took antacids but there is no effect on him
- O** - When you examine the patient try to avoid the painful area in the beginning of the examination.
- A** - CBC , Electrolytes, Chest x-ray.
- P** - IV antibiotics / Surgery Appendectomy (Category C)

Scenario 2

A 55 year-old business man presented to the ER with severe abdominal pain since 6 hours when he felt something like a burst in his abdomen. He is known with PUD and H-pylori but he was not taking his medications regularly.

DDx: Perforated duodenal ulcer - peritonitis

- S** - 55 year old, male, known case PUD and H-pylori. Presented to the ER with severe abdominal pain for 6 hours.
- O** - On abdominal examination the patient is uncomfortable and in pain.
- A** - CBC, Electrolytes, Chest x-ray
- P** - Stabilize patient, Aggressive fluid resuscitation, Antibiotics to eradicate H. pylori, Surgery (Category B)

Scenario 3

A 73 year-old male developed atrial fibrillation while recovering from an acute MI in the medical ward. The surgery team was consulted to evaluate a new onset of severe mid-abdominal pain.

DDx: Acute mesenteric ischemia - Cholangitis - Cholecystitis - Ileus - Gastric Volvulus

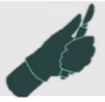- S** - 73 year old, Male, History of an acute MI complicated by Afib, complaining of new onset severe mid abdominal pain.
- O** - pain with subjective symptoms disproportionate to their objective findings.
- A** - Any patient with an arrhythmia such as atrial fibrillation who complains of abdominal pain is highly suspected of having embolization to the superior mesenteric artery until proved otherwise, As soon as AMI is suspected:
 1. Surgical consultation
 2. CT angiography
- P** - Surgical revascularization (Category B), Vascular interventional radiological thrombolytic medical treatment.

Scenario 4

A 54 year-old lady presented to the ER complaining of generalized abdominal pain associated with vomiting, constipation for 2 days, and abdominal distention. She had an emergency Cesarean Section for her 5th baby 5 years back.

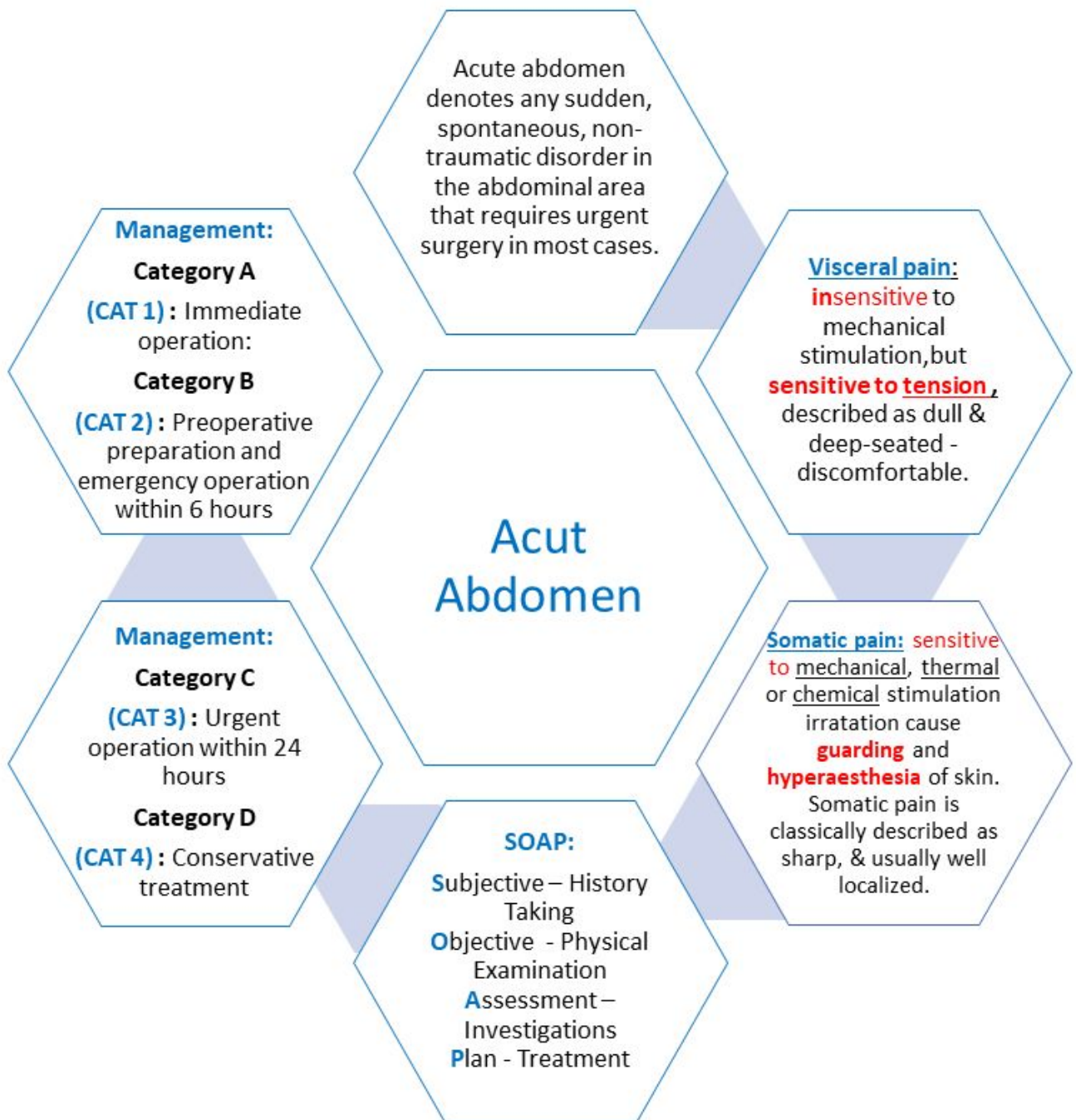
DDx: Small bowel obstruction - Incarcerated groin hernia - Hernia - Malignant tumor

- S** - 54 year old, Female, C.C. of generalized abdominal pain with vomiting, constipation and abdominal distention for 2 days, came through ER, had an emergency cesarean Section for her 5th baby 5 years back.
- O** - Abdominal distention is present. Hyperactive bowel sounds occur early as GI contents attempt to overcome the obstruction; hypoactive bowel sounds occur late. Exclude incarcerated hernias of the groin, femoral triangle, and obturator foramina. Proper genitourinary and pelvic examinations are essential.
Check for symptoms commonly believed to be more diagnostic of intestinal ischemia, including the following:
 1. Fever
 2. Tachycardia
 3. Peritoneal signs



- A** - Serum chemistries, Blood urea nitrogen (BUN) level, Creatinine Complete blood count (CBC), Lactate dehydrogenase tests, Urinalysis, Type and crossmatch, Phosphate level, Creatine kinase level. Abdominal X-ray: Dilated small-bowel loops with (more than six) air-fluid levels in supine and erect abdominal radiographs
- P** - Aggressive fluid resuscitation, Bowel decompression, Administration of analgesia and antiemetic, Early surgical consultation, Administration of antibiotics. (Antibiotics are used to cover against gram -ve and anaerobic organisms), Blood pressure and cardiac monitoring.

Summary





Questions

Q1: What is the most common cause of shock in acute abdomen ?

A.Chronic pancreatitis. B. Ruptured Aortic aneurysm. C.Splenic rupture.

Q2: Which one of the following may lead to generalized peritonitis ?

A.Perforated peptic ulcer. B. Perforated duodenal ulcer. C. Both of them.

Q3: Which one of the following cause right iliac fossa pain in young female ?

A.Ruptured ovarian cysts. B. Salpingitis. C. Both of them.

Q4: what is the cause of right upper quadrant acute tenderness and localized peritonitis ?

A.Pancreatitis. B.Cholecystitis C. Both of them.

Q5: What is the cause of epigastric region acute tenderness and localized peritonitis ?

A.Pancreatitis. B.Peptic ulcer. C. Both of them.

Q6: What is the cause of left upper quadrant acute tenderness and localized peritonitis ?

A. Splenic abscesses. B. Splenic rupture. C. Both of them.

Q7: What is the cause of left lower quadrant acute tenderness and localized peritonitis ?

A.Diverticulitis in sigmoid. B.Cholecystitis. C. Both of them.

Q8:What is the most likely cause of abdominal distention ?

A.Ascitis. B. bowel obstruction. C. Both of them.

Q9: Which one of the following is under category-B(CAT-2) ?

A. Ruptured Aortic aneurysm. B. Acute appendicitis. C. Peritonitis.

Q10: Not all cases of acute abdomen need surgery, best example for that is :

A.Acute pancreatitis. B. Diverticulitis. C. Chronic appendicitis.

Q11: Which structure can be injured after ERCP ?

A. Sigmoid. B. Pyloric sphincter. C. Pancreas.

Q12: Which one of the following surgical intervention may lead to traumatic pancreatitis ?

A. cholecystectomy. B. ERCP. C. Sigmoidoscopy.

Answers:

1:B 2:C 3:C 4:B 5:C 6:C 7:A 8:C 9:C 10:A 11:C 12:B