



Common neck swellings

Objectives:

Not Given

Resources:

- Davidson's.
- 436 doctors slides.
- Surgical recall.
- 435' team work

Done by: Abdullah Almana, Talal Altukhaim, Ghada AlSkait, Ashwaq Almajed

Leaders: Heba Alnasser, Jawaher Abanumy, Mohammed Habib, Mohammad Al-Mutlaq

Revised by: Yara Aldigi

COLOR INDEX:

NOTES , IMPORTANT , EXTRA , DAVIDSON'S

EDITING FILE

FEEDBACK



Basic review:

Anatomy of the neck:

- The investing layer of deep cervical fascia lies deep to the skin. The layer between them is the platysma (it assists the muscles of facial expression).
- The cervical branch of the facial nerve supplies the platysma.
- Other than Subcutaneous Lipoma and Sebaceous cysts, most neck swellings lie deep to platysma.
- The sternocleidomastoid muscle (which is supplied by the spinal accessory nerve) divides the front of the neck into anterior and posterior triangles.

- The anterior triangle is further subdivided into:

1-Submental triangle: contains nodes draining central portion of the lips and tip of the tongue.

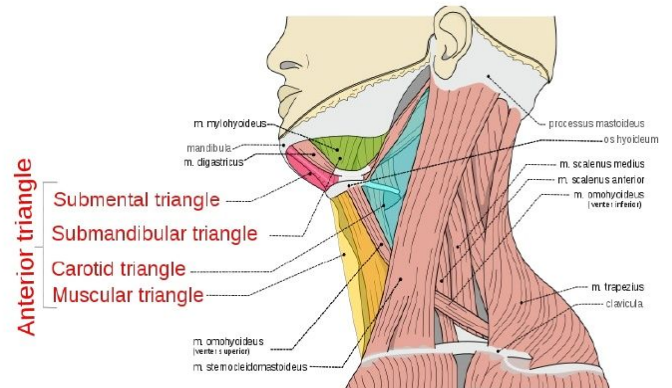
2- Submandibular triangle: contains submandibular gland and lymph nodes. The floor of this triangle is formed by the hyoglossus muscle with the hypoglossal nerve lying on it.

3- Carotid triangle: contains the common carotid artery, internal jugular vein, vagus nerve. Branchial cysts and carotid body tumors are common in the carotid triangle.

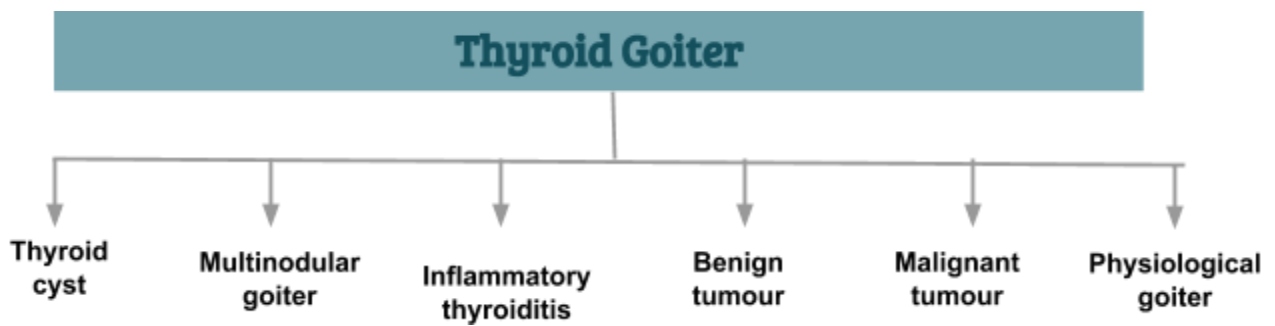
4- The muscular triangle: contains infrahyoid muscles, thyroid gland, larynx, trachea oesophagus, recurrent laryngeal nerve, inferior laryngeal artery and external laryngeal nerve.

Most neck masses are painless, but may be painful due to infection and malignant diseases. Rapid enlargement makes malignant disease more likely. Salivary gland swelling, caused by duct obstruction, enlarges when patient eats.

Anterior Triangle



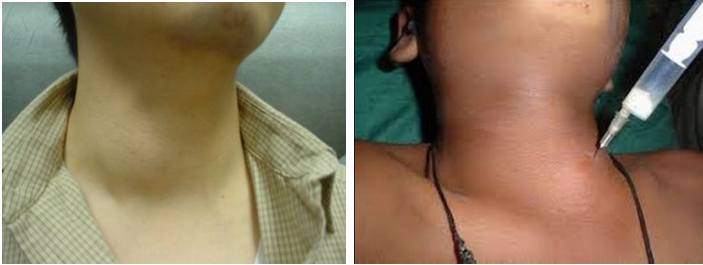
Common neck swellings



Don't mix up goiter "swelling" with **dysfunction**!! they are different: we can have one **without** the other.

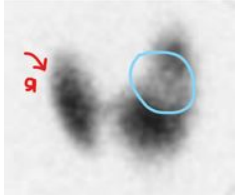
CAUSES OF GOITER: Types of swellings:

1. Thyroid cyst :

Features	Simple accumulation of fluids. Benign, painless . Normal function of the thyroid.
Diagnosis	Ultrasound and FNA "fine needle aspiration" . - Thyroid gland is located behind a fascia "pretracheal fascia", so it is difficult to differentiate solid mass or cyst by examination " Ultrasound and FNA " are the best options to differentiate between them. FNA can be both diagnostic and therapeutic.
Treatment	Aspiration . If it reoccurs up to two times → aspirate cyst again, but the 3rd time surgery is indicated. (lobectomy)
Pics	



2. Multinodular goiter (Simple goiter):

What is it?	Functional problem, it's Hyperplasia of the cells . It is solid and locally causing dysphagia, dyspnea, stridor or hoarseness. It is the most common thyroid disease. 80-90% of cases. 80% euthyroidism (that's why it's called "simple"), 10% hypothyroidism, hyperthyroidism
Causes	The hyperplasia of cells is because of: 1. iodine deficiency¹ 2. side effect of "lithium" 3. problem in the synthesis (idiopathic).
Clinical features	Starts as a simple goiter then becomes nodular (but the function stays normal). After years in about 5% of patients, some of the nodules will produce excessive amounts of thyroxine; we call it toxic multinodular goiter and will cause symptoms of hyperthyroidism. So simple multinodular goiter may eventually turn into toxic. - simple multinodular goiter is the most common cause of single nodule (هو الوحيد المحسوس بينهم). - indication for surgical intervention → if the multinodular goiter restrict the respiration or dysphagia.
Diagnosis	- Ultrasound and FNA then nuclear (warm) scan . - Warm scan is <u>normal</u> : like the lobe on the right side of the picture - abnormal either: Hot ² (overtaking iodine hyperactive). Or Cold (circled area): it means that area is not uptaking iodine hence it is no longer thyroid tissue, indicative of <u>malignancies</u> in 15% of patients.  - or
Presentation	The goiter presents incidentally : either: 1-Toxic goiter: Associated with hyperthyroidism . E.g. Graves disease, toxic multinodular goiter (Plummer's disease), and toxic adenoma. 2-Nontoxic goiter: Asymptomatic goiter but can cause compression symptoms, thyroid function is normal . It may be diffuse or multinodular.

3. Inflammatory (thyroiditis):

¹ Common in iodine deficiency area.

² In nuclear scan: hot nodule: the nodule uptake the iodine and produce thyroxine more than surrounding tissue, and cold nodule: it doesn't uptake iodine (hence it appears lighter in the image) and not functioning.



Note	Here we are NOT talking about infection (pyogenic) we are talking about autoimmune inflammation.
Types	<p>1- Acute Autoimmune thyroiditis : is extremely rare especially pyogenic (bacterial³) inflammation.</p> <p>2- Sub-acute Autoimmune thyroiditis:⁴ is rare. noninfectious either de Quervain's disease (hyperthyroidism) that is associated with an influenza-like illness (virus) and painful diffuse swelling of the gland, or Riedel's thyroiditis (hypothyroidism) which is a very rare cause of painless thyroid.</p> <p>3- Chronic (Hashimoto's thyroiditis): Most common inflammation. It is difficult to differentiate between inflammatory and simple goiter clinically, you need to do FNA. (Even by US they look alike) usually mixed with simple goiter (painless diffuse swelling), no signs of inflammation like redness. Starts slightly⁵ hyperthyroidism → then eufunction → lastly hypothyroidism. Surgically removed if the patient is symptomatic (dysphagia , dyspnea) Or if we're not 100% sure that there is no malignancy.</p>
Diagnosis	By serological markers and biopsy which shows lymphocytes that confirms the diagnosis, monocytes, etc.

4. Benign tumor :	5. Malignant tumor :
Types: 1-Papillary Carcinoma 2- Follicular Carcinoma 3- Medullary 4- Undifferentiated 5- Lymphoma	
<ul style="list-style-type: none"> - Usually Follicular adenoma. - 90% of tumors. - Difficult to differentiate between it and malignancy with histology. So as a RULE we have to remove any benign tumor of the thyroid. - It can start secreting thyroxine and cause hyperthyroidism. - A multinodular goiter may have one nodule that is a tumour. (the nodule is usually not diffused) Presentation: Painless swelling (nodule).	<p>Less than 10% of tumors.</p> <p>"Painless swelling"</p>

6. Physiological goiter (simple diffuse swelling): Happens as a result of increase in the demand (like in puberty - due to growth - and in pregnancy...etc), the body needs thyroxine and the gland will try to

³ sudden onset of severe neck pain, fever, and chills. It usually follows an acute URTI; most often by strep/staph/pneumo cocci or coliforms. Maybe associated with pyriform sinus fistula. Barium swallow is therefore recommended in recurrences.

⁴ thyroid swelling, head and chest pain, fever, palpitations, and weight loss. Some have no pain (silent thyroiditis), in which case the condition must be distinguished from Graves disease.

⁵ Slightly, not high like graves disease.



compensate by swelling up. It's usually not extremely enlarged.
Fast growth → increased need of thyroxine → thyroid hypertrophy.

Remember: Normal thyroid function in: Thyroid cyst - Simple multinodular - Malignant tumor - physiological goiter - Inflammatory.

Case: Ahmed (28 year-old) came to the Outpatient clinic **complaining of** nervousness, palpitations, sweating, and weight loss. Clinical examination revealed **the presence of a goiter**. Hyperthyroidism Thyrotoxicosis can be a manifestation of a number of thyroid conditions, but the most common are:

1. Grave's disease: autoimmune disease (inflammatory) causes thyrotoxicosis and it has a direct affect on the eyes. Eye signs in grave's disease are very obvious(lid retraction and exophthalmos). Usually affects the young.
2. Toxic multinodular goiter: It starts as a simple goiter, but sometimes with time these nodules may turn into toxic nodules (which secrete thyroxine).
In nuclear scan, you will see hot nodules. And sometimes only one nodule becomes toxic on nuclear scan.

Causes of a solitary thyroid nodule:

- 1- **Thyroid cyst.**
- 2- **Dominant nodule in a multinodular goiter (most common cause).**
- 3- **Degeneration or hemorrhage into a colloid cyst or nodule.**
- 4- **Benign tumor.**
- 5- **malignancy.**

Malignant tumors of the thyroid:

ESSENTIALS OF DIAGNOSIS :

- 1- **Painless enlarging nodule** لما يقول البيشنت عندي ألم أفرح افحصوا اللمف نودز بالاوسكي
- 2- **Lymphadenopathy** ⇒ specially ipsilateral cervical, there's a high chance of malignancy (specific for, but not sensitive)⁶. **More than 95% of the malignancy conditions don't have lymphadenopathy.** Lymphadenopathy is very uncommon in malignancy **BUT Lymphadenopathy + thyroid swelling is malignancy until proven otherwise.**
- 3- **Hoarseness of voice** → **recurrent laryngeal nerve involvement:** malignancy or iatrogenic. (also specific 99%, but not Sensitive) Swelling in the neck and hoarseness of voice is highly suggestive of malignancy why? Because the only reason for hoarseness of voice is injury to the recurrent laryngeal nerve either by malignancy or by a surgeon.
- 4- **Dysphagia** (because of the size).
- 5- **Function in malignancy is usually normal** لحد يقول لي بالاختبار تايروتوكسيكوسس

⁶ Which means that if lymphadenopathy is present → very suggestive for malignancy, but you can't exclude malignancy if it's not present.



6- Investigation: Whenever you see **cold nodule (nuclear)** or nodule **stippled with microcalcifications (U/S)** ⇒ **Suspect malignancy**

7- Family history of thyroid cancer.

- 99% of cases of thyroid cancer do not have lymphadenopathy or hoarseness because it's usually caught early before involvement of lymph nodes or the recurrent laryngeal nerve.

TYPES OF THYROID CANCER:

Remember: Papillary + Follicular are the **differentiated** malignant tumors (the cells are **well formed**), while anaplastic tumors are called **undifferentiated** malignant tumors.

1. Papillary carcinoma⁷:

Occurrence	<ul style="list-style-type: none"> - Female:Male ratio ⇒ 3:1 (more common in females). - occurs in young age ⇒ any <20 y/o patient with a single thyroid nodule should be considered as a case of papillary carcinoma until proven otherwise. imp - Most common endocrine cancer is thyroid cancer (and Papillary accounts about 85% of thyroid cancers). - Appears in early adult life (Painless). - Incidence increases with exposure to radiation & in familial types. + due to better diagnostic measures. <p style="text-align: right;">زمان كانوا يعالجون الـacne بالـlow radiation وفيما بعد لاحظوا ان هالاشخاص جايم papillary thyroid carcinoma.</p>
Spread and metastases	<ul style="list-style-type: none"> - Lymphatic spread. Imp <p>Any malignancy in the body with lymph nodes involvement → worse prognosis, EXCEPT papillary, the prognosis doesn't change we can still cure the patient. (the spread through the lymphatics doesn't make the stage higher)</p> <ul style="list-style-type: none"> - Metastasizes to lung & bone.
Management	Total thyroidectomy (because it is multifocal) is the optimal surgical procedure. Chemotherapy is not used.
Prognosis	Usually good prognosis. Patients with this type of malignancy usually die with the disease not from it.

2. Follicular carcinoma:

⁷ A BRAF mutation is the most common mutation in papillary thyroid cancer and is associated with lymph node metastases and a higher recurrence rate.



Occurrence	<ul style="list-style-type: none"> - In 30–50 year age group (later than papillary). - Accounts for about 10% of thyroid cancers.
Spread and metastases	<ul style="list-style-type: none"> - Blood spread. Doesn't spread to lymph. - Metastasizes to lung & bone (functional metastasis, bone and lung starts uptaking radionuclear iodine and producing thyroxine by themselves). - Hürthle cell carcinoma is a clinical variant of follicular carcinoma. It is more likely to be multifocal and involve lymph nodes. Like follicular carcinoma, it makes thyroglobulin, however it does not usually take up radioiodine.
Management	Treatment consists of total thyroidectomy with preservation of the parathyroids. But metastasis should be treated by radionuclear radiation containing iodine isotopes so once the bone metastases has uptaken it it'll burn the cells.
Prognosis	Not as good as papillary carcinoma.

3. Medullary carcinoma⁸:

Origin	<p>It's solid, containing amyloid, nodular tumor that does not take up radioiodine and secretes calcitonin since it Arises from C-Cells in pancreas and adrenals. Hence, radioiodine is not as good in the investigation or treatment of this condition.</p> <ul style="list-style-type: none"> - Accounts for about 7% of thyroid cancers. - 25% is familial (hereditary) type of medullary carcinoma (Associated with MEN 2a/2b syndrome). <p>Most aggressive in MEN2B patients.</p>
Management	<ul style="list-style-type: none"> - It's better to do thyroidectomy and remove surrounding lymphs before it progresses. - Preoperative CT CAP is advised as well as exclusion of pheochromocytoma (MEN2).
Prognosis	Prognosis is not good, especially if it's part of MEN ⇒ that's why we screen families.

4. Undifferentiated (Anaplastic):

⁸ MEN IIa: medullary carcinoma, pheochromocytoma, hyperparathyroidism,
 MEN IIb: Medullary carcinoma, pheochromocytoma, mucosal neuromas and marfanoid shape



Occurrence	- Usually in Elderly. - Accounts for about 1% of thyroid cancers.
Features	- Rapidly growing. - Usually evolves from papillary or follicular neoplasm. - Locally invasive → causing compression (dyspnea) and hoarseness of voice, and may cause Horner's syndrome (miosis-ptosis-anhidrosis) ⁹
Spread & metastases	Cervical lymphadenopathy and pulmonary metastases are common
Management	Both resection and chemotherapy don't show any value, external beam radiation may be of value. The idea is to relieve compression.
Prognosis	the worst; Rarely cured and recurrence is high.

5. Lymphoma

Occurrence	- More common in our part of the world. - Higher risk in Hashimoto's. - Accounts for about < 5% of all thyroid cancers.
Diagnosis	Usually diagnosed post-op by pathology, but if diagnosed before → send to oncology for treatment.
Management	Chemo & radiotherapy.

Investigations:

1 **Ultrasound** → **1st diagnostic method.**

2- **Fine Needle Aspiration (FNA)** → **Most important method.**

3- **Percutaneous needle biopsy** → **The most cost-effective diagnostic test.**

along with ultrasound, Needle biopsy is not as helpful in patients with a history of irradiation to the neck.

Because radiation-induced tumors are often multifocal and a negative biopsy may therefore be unreliable.

4- **Thyroid uptake scan** (basically nuclear medicine). **We give the patients radioactive iodine and the cells that secrete thyroxine will take up the RAI and appear black. If the area did not uptake it we call it cold nodule and areas with high uptake are called hot nodules.**

5- **FNA/Bethesda System** → **The main diagnostic method.**

The Bethesda System for Reporting Thyroid Cytopathology (TBSRTC) established a standardized, category-based reporting system for thyroid fine-needle aspiration (FNA) specimens.

Indications for Thyroidectomy¹⁰ Extra

⁹ سندروم تجي بسبب ضرر على السمباتك ترك، احفظوها انها ثلاث تضيقات (البؤبؤ، العين و فتحات التعرق)

¹⁰ Surgery is often the preferred treatment, because it's more rapid and has more certain control of the disease than radioiodine.



U CAN SKIP this part, but we always get asked about the indications in OSCE :).

- 1- in the presence of a very large goiter or a multinodular goiter **with** relatively low radioactive iodine uptake.
- 2- if there is a suspicious or malignant thyroid nodule.
- 3- for patients with ophthalmopathy.
- 4- for the treatment of pregnant patients or children.
- 5- for the treatment of women who wish to become pregnant within 1 year after treatment.
- 6- for patients with amiodarone-induced hyperthyroidism.
- 7- compressive symptoms e.g. Dysphagia, dyspnea and/or hoarseness.

Branchial cyst and fistula: Extra

- Swellings lying laterally in the upper neck may be branchial cysts. They are thought to be remnants of the second and third branchial arches yet often present in young adults. The cysts contain opaque fluid with cholesterol crystals. Lymphoid tissue is found in their walls. They may become infected and usually require excision.
- Branchial fistula may occur between the skin surface, low in the neck, and the tonsil or lower pharynx internally. Infection often occurs and excision is usually required.

Other cystic swellings: Extra

Cystic hygroma Is a rare, benign lymphangioma of the neck, which usually presents in early life. Complete excision is difficult, leading to frequent recurrence.

Dermoid cysts May also occur in the upper neck, usually in the midline or submandibular area, in younger children. They contain skin appendages unlike sebaceous cysts.

Laryngoceles Occur as a result of herniation of laryngeal mucosa laterally into the neck. They distend with air during the Valsalva manoeuvre and may become infected. Excision is usually required.

General considerations

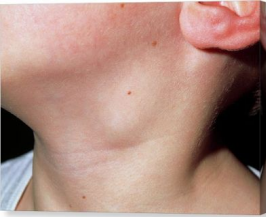


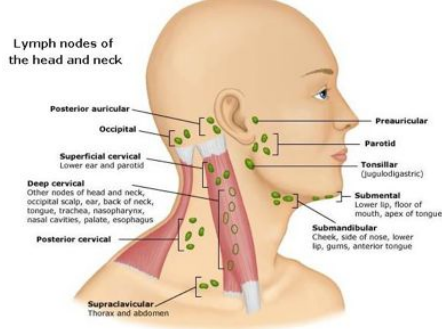
Thyrotoxicosis: is the clinical condition of presence of high levels of thyroid hormones in Blood by any cause. **Hyperthyroidism**: is **over activity** of the thyroid gland, thus it causes thyrotoxicosis.

Hyperthyroidism	Hypothyroidism
<ul style="list-style-type: none"> 1-GRAVE'S 2-Toxic multinodular goiter 3-early Hashimoto's 4- single toxic nodule (commonly Follicular Adenoma). 	<ul style="list-style-type: none"> 1-Surgical removal of thyroid gland 2-Late Hashimoto's

Lymph node swelling

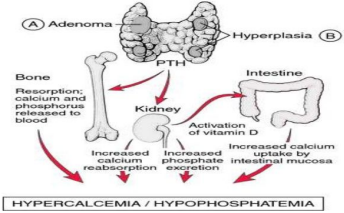
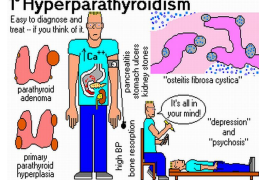


- Majority of lymphadenopathy occur in the posterior triangle .

Inflammatory	Neoplastic
<p>1- Acute: Tonsillitis. Treat the cause</p>  <p>1- Chronic:</p> <ul style="list-style-type: none"> - Non specific - TB: Tuberculosis must be ruled out. It usually presents as swelling of a group of lymph nodes. There can be signs of inflammation or cold abscess. You treat like TB anywhere else in the body. 	<p>1- Primary</p> <ul style="list-style-type: none"> - Lymphoma, Either hodgkin or non-hodgkin lymphoma. They are discrete (not mated) and rubbery.  <p>2- Secondary</p> <ul style="list-style-type: none"> - Metastasis: Usually from the head and neck , Brain , Larynx , Pharynx , Sinuses -Supraclavicular Lymph nodes: usually the causes are infraclavicular, Gastro , Pulmo , Breast, and testicular tumors. 

Parathyroid swelling

Primary Hyperparathyroidism (PHPT): (Dr. didn't explain it but asked us to read about it)

Occurrence	<ul style="list-style-type: none"> - 2-3 times more in females than males. - Uncommon in children. - No evidence for geographical variation. - 0.1 - 0.5 % Prevalence rate
Due to & results in	<ul style="list-style-type: none"> - In 84% of patients, primary hyperparathyroidism is due to an adenoma¹¹, in 15% it results from hyperplasia¹², and in less than 1% it results from parathyroid carcinoma. - The most common cause of hypercalcemia. <li style="color: green;">Most common cause of hypercalcemia in hospitals → malignancy. <li style="color: green;">Most common cause in community → primary hyperparathyroidism. - (All causes of high Calcium leads to high Phosphate except this condition → causes high Chloride).
Clinical presentation	<ul style="list-style-type: none"> - In the west 60-70% detected by routine screening. - Many are asymptomatic.
Clinical manifestations	<ol style="list-style-type: none"> 1- Renal stones. Due to hypercalcemia لما يجيك بيشنت ريكرننت او بايلاترال ستونز افحص الباراثايرويد 2- Bone loss and joint pain. العظم ينكسر من ابسط ضربة 3- Abdominal groans. 4- Psychic moans.¹³ 5- Fatigue overtones. 6- Moth Eaten appearance of the skull¹⁴. 7- Peptic ulcer <div style="text-align: right; margin-top: 10px;"> <p>CLINICAL FEATURES</p> <p>• The signs and symptoms of primary hyperparathyroidism are those of hypercalcemia.</p>  </div>
Investigations	<ol style="list-style-type: none"> 1- Serum Calcium. (High) 2- PTH. (High) <li style="color: red;">3- Serum Phosphate. (Low) <li style="color: red;">4- Raised Chloride. 5- Decreased bone density. <p>- High Serum Calcium + PTH ⇒ enough to confirm the Dx of 1ry hyperparathyroidism</p>
Management	<ul style="list-style-type: none"> - All symptomatic patients should be treated. - The aim is to remove all hyperactive parathyroid tissue. <li style="color: green;">In adenoma → remove the enlarged gland. <li style="color: green;">In hyperplasia → remove 3.5 glands, leave only half a gland for the patient to maintain the function. <div style="text-align: right; margin-top: 10px;"> <p>1st Hyperparathyroidism</p> <p>Easy to diagnose and treat - if you think of it.</p>  </div>

Thyroglossal cyst:

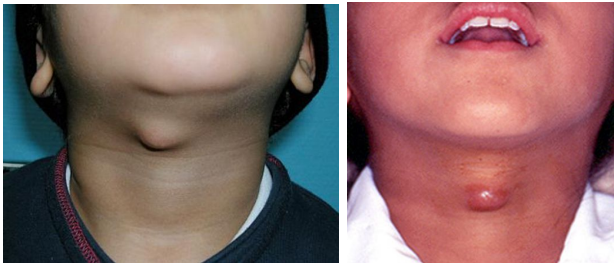
¹¹ In adenoma, usually only 1 parathyroid gland is enlarged.

¹² In hyperplasia, all 4 glands are usually affected.

¹³ كانوا يروحون للسايكاتري ويلقون مرضى منومين وسبب تنويمهم كان **increased parathyroid hormone** بس /:

¹⁴ multiple small endosteal lucent lesions or holes, often with poorly defined margins, with sparing of the cortex.



Pathophysiology	The thyroid gland begins its embryological development in the tongue base and as it descends a duct forms and then gets obliterated. A cyst may develop with improper obliteration. Common in children.
Note	If we see a lump, how can we tell if it is a thyroid lump? Ask the patient to swallow. If it doesn't move with swallowing then it is not a thyroid disease (could be dermoid cyst, lipoma, lymph Node). If it moves then it is one of two: Thyroid lump "goiter" or Thyroglossal cyst. Then you ask the patient to stick his tongue out and if the lump moves then it is a thyroglossal cyst. Because Thyroglossal cysts extend to the tongue.
Treatment	Surgical excision
Pics	

Neck swellings:

Lateral neck swellings	Anterior neck swellings
Lymph nodes	Lymph nodes
Lipoma	Lipoma
Sebaceous cyst	Sebaceous cyst
Hemangioma	Hemangioma
Aneurysm	Aneurysm
Submandibular gland	Thyroid
Tail of parotid gland	Thyroglossal Cyst
Carotid body tumor	Dermoid Cyst
Laryngocele	
Pharyngeal diverticulum	
Branchial cyst	
Cystic hygroma	
Others	

Recall : THYROID

1. Identify the following structures: 1. Pyramidal lobe 2. Right lobe 3. Isthmus 4. Left lobe

2. Define the arterial blood supply to the thyroid:

- Superior thyroid artery (first branch of the external carotid artery)
- Inferior thyroid artery (branch of the thyrocervical trunk) (IMA artery rare)

3. What is the venous drainage of the thyroid?

- Superior thyroid vein 2. Middle thyroid vein 3. Inferior thyroid vein

4. Name the lymph node group around the pyramidal thyroid lobe? Delphian lymph node group

5. What is the thyroid isthmus? Midline tissue border between the left and right thyroid lobes

6. Which ligament connects the thyroid to the trachea? Ligament of Berry (remember mazen berry)

7. Which paired nerves must be carefully identified during a thyroidectomy?

Recurrent laryngeal nerves, behind the cricothyroid muscle; damage one causes hoarseness, if bilateral = airway obstruction.

8. What is TRH? Thyrotropin-Releasing Hormone released from the hypothalamus; causes release of TSH **what is it?** Thyroid-Stimulating Hormone released by the anterior pituitary; causes release of thyroid hormones from the thyroid.. **What are they?** T3(active) and T4(levothyroxine).

9. What is the differential diagnosis of a thyroid nodule?

Multinodular goiter /Hyperfunctioning adenoma/ Cyst/ thyroiditis/ Carcinoma/lymphoma

10. What are the indications for a scintiscan? 1. Nodule with multiple "nondiagnostic" FNAs with low TSH 2. Nodule with thyrotoxicosis and low TSH

11. In evaluating a thyroid nodule, which of the following suggest thyroid carcinoma: History?

- Neck radiation 2. Family history (thyroid cancer, MEN-II) 3. Young age 4. Male>female

Signs?

- Single nodule 2. Cold nodule 3. Increased calcitonin levels 4. Lymphadenopathy 5. Hard, immobile nodule

Symptoms?

- Voice change (vocal cord paralysis) 2. Dysphagia 3. Discomfort (in neck) 4. Rapid enlargement

12. What is the most common cause of thyroid enlargement? Multinodular goiter

13. What are indications for surgery with multinodular goiter? Cosmetic deformity, compressive symptoms, cannot rule out cancer

14. Anaplastic Carcinoma What is it also known as?

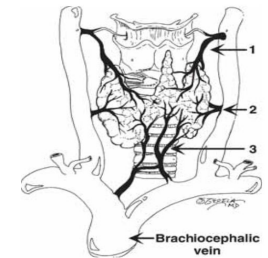
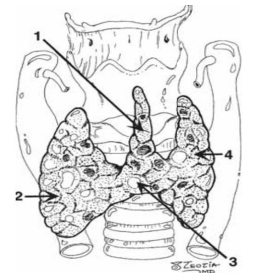
Undifferentiated cancer arising in 75% of previously differentiated thyroid cancers (most commonly, follicular carcinoma)

15. How can the differences between etiologies of ACUTE and SUBACUTE thyroiditis be remembered?

Alphabetically: A before S, B before V (i.e., Acute before Subacute and Bacterial before Viral, and thus: Acute Bacterial and Subacute Viral)

16. What are the common causative bacteria in acute suppurative thyroiditis? Staph and streptococcus

17. What are the two types of chronic thyroiditis? 1. Hashimoto's thyroiditis 2. Riedel's thyroiditis (subacute sometimes)





Summary

Goiter (thyroid swelling)

Thyroid cyst	Multinodular goiter (Simple goiter)	Inflammatory (thyroiditis)
<ul style="list-style-type: none"> Painless Normal thyroid function Diagnosis : <ul style="list-style-type: none"> Ultrasound and FNA Treatment: <ul style="list-style-type: none"> Aspiration. 	<ul style="list-style-type: none"> Benign condition 80% normal thyroid function If it starts to secrete thyroxine we called (toxic multinodular goiter) Treatment : Surgery if only symptomatic	- Autoimmune inflammation (Hashimoto's thyroiditis) Caused by: Chronic thyroiditis Diagnosis: FNA Treatment : Surgery only if: symptomatic or to R/O malignancy)
Lymph node swelling (Majority occur in the posterior triangle)	1. Inflammatory: <ul style="list-style-type: none"> Acute (tonsillitis) Chronic (TB) 	2. Neoplastic <ul style="list-style-type: none"> Primary (Lymphoma) Secondary (Metastasis)

Thyroid tumor

Clinical Features	1. Painless 2. Hoarseness of voice 3. Dysphagia	4. Lymphadenopathy 5. normal thyroid function
Investigations:	1 Ultrasound 1st diagnostic method. 2- Fine Needle Aspiration (FNA) Most important method.	



Types of Thyroid tumor

Types of Thyroid tumor		
1. Papillary carcinoma	2. Follicular carcinoma	
<ul style="list-style-type: none"> ● Young age (children) ● Most common endocrine cancer is thyroid cancer ● Increases risk with exposure to radiation ● Lymphatic spread. ● Metastasizes to lung & bone. ● Good prognosis ● Treatment : thyroidectomy, chemotherapy is not used. 	<ul style="list-style-type: none"> ● 30–50 year age group ● Blood spread. Doesn't spread to lymph. ● Management : Treatment consists of total thyroidectomy with preservation of the parathyroids (radionuclear iodine radiation for metastasis) 	
3. Medullary carcinoma	4. Undifferentiated (Anaplastic)	5. Lymphoma
<ul style="list-style-type: none"> ● Associated with MEN 2 ● (important to investigate pheochromocytoma) ● Poor prognosis. 	<ul style="list-style-type: none"> ● Elderly age. ● Locally invasive → causing compression (dyspnea) and hoarseness of voice ● the worst prognosis. ● Rarely cured 	<ul style="list-style-type: none"> ● Higher risk in Hashimoto's.

Questions



1- 45 years old female presented with right flank pain, associated with fever and bloody urine. She gave a history of a recent hip fracture.

On general inspection you noticed a neck swelling. Upon examination there was a palpable solid mass.

What is the most likely cause of the swelling?

- A. Thyroid goiter
- B. Lung carcinoma metastasized to the bone and cervical lymph nodes
- C. Primary hyperparathyroidism
- D. Cervical lymphoma

2- 24 years old male presented to the clinic with a neck swelling. Patient denies having any symptoms of hyper/hypothyroidism and has not noticed such swelling before. Physical exam was done and the swelling was described as hard and resembles a solid mass.

FNA was performed and the swelling disappeared after the procedure. What is the best next step?

- A. Reassure the patient and send him home
- B. Do an Ultrasound
- C. Thyroidectomy
- D. Check thyroid function

3- 29 years old pregnant female presented with a painless mild neck swelling. She denies having any hyper/hypothyroidism symptoms. Thyroid function test was normal.

The physician reassured the patient and explained that pregnancy can be a cause of physiological goitre. What other condition is known to cause a physiological goitre?

- A. Puberty
- B. Aging
- C. Obesity
- D. Sedentary lifestyle

4- Which of the following can result due to altered thyroid function?

- A. Thyroid cyst
- B. Papillary carcinoma
- C. Simple multinodular goitre
- D. Follicular carcinoma

5- 33 years old obese male with a history of depression and on lithium, presented with difficulty in swallowing solids. on physical exam a large nodular thyroid was palpable. Thyroid function tests was normal. FNA was done no serological marker or inflammatory cells were present. Ultrasound showed enlarged thyroid. Nuclear scan showed a normal warm tissue. How would you manage this patient?

- A. Treat with thyroxine
- B. Aspirate the swelling
- C. Reassurance and physiological support
- D. Surgery is indicated

6- What is the appropriate management of a benign follicular adenoma?

- A. Chemotherapy
- B. Radiotherapy
- C. Anti thyroid medication and monitoring
- D. Lobectomy



7- 39 years old female presented with progressive neck swelling for the past 8 months. On physical exam there was a nodule in the left lobe and lymphadenopathy was present. Thyroid function was normal. What is the most likely diagnosis?

- A. Simple nodular goitre
- B. Toxic nodular goitre
- C. Follicular adenoma
- D. Thyroid malignancy

Answers:

1: C 2: A 3: A 4: C 5: D 6: D 7: D