

Bronchiectasis

Dr R Nadama MD MRCP(lond) MRCP(UK),
FRCP(Lond), EDARM, FCCP


Bronchiectasis

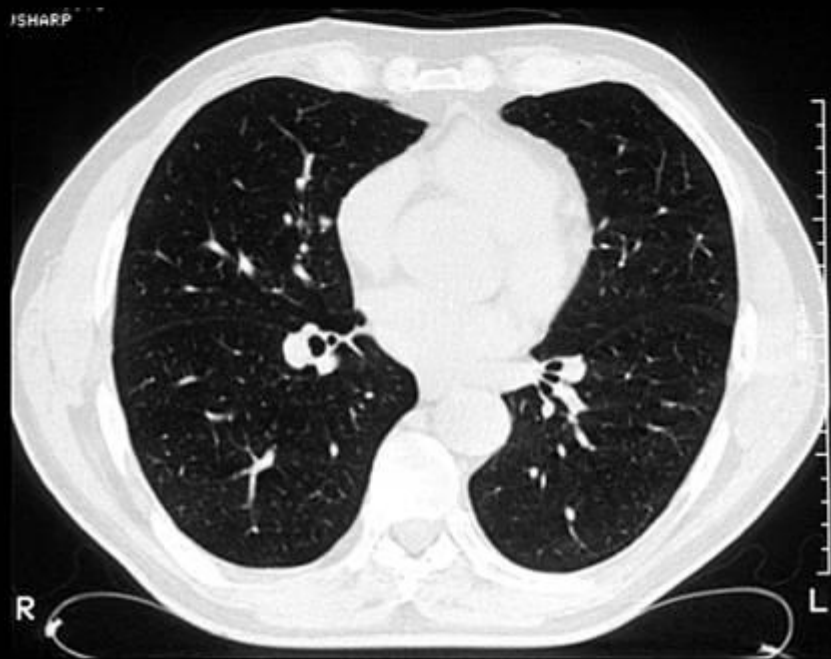
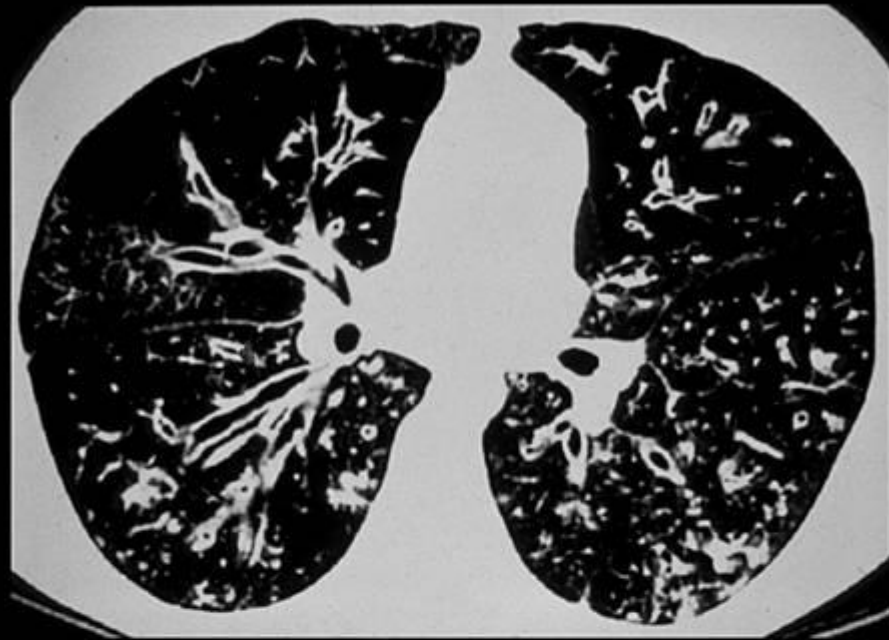Originally described by Laennec in 1819

- Chronic
- Debilitating

Characterised

- persistent cough
- excessive sputum production
- recurrent chest infection

- 
- Permanent abnormal dilatation
 - impaired mucociliary clearance
 - bacterial colonisation
 - excessive airways inflammation



Bronchiectasis

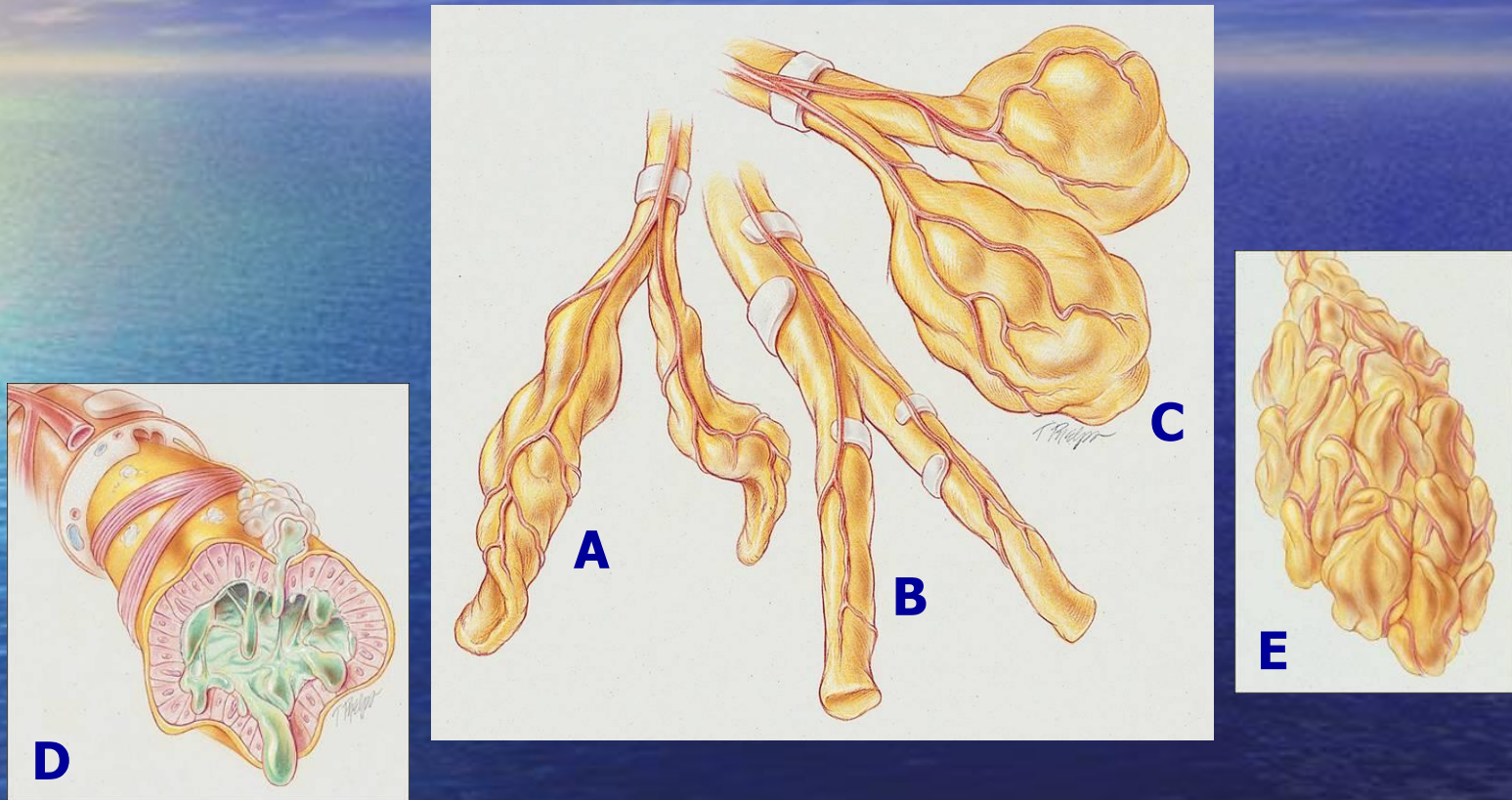
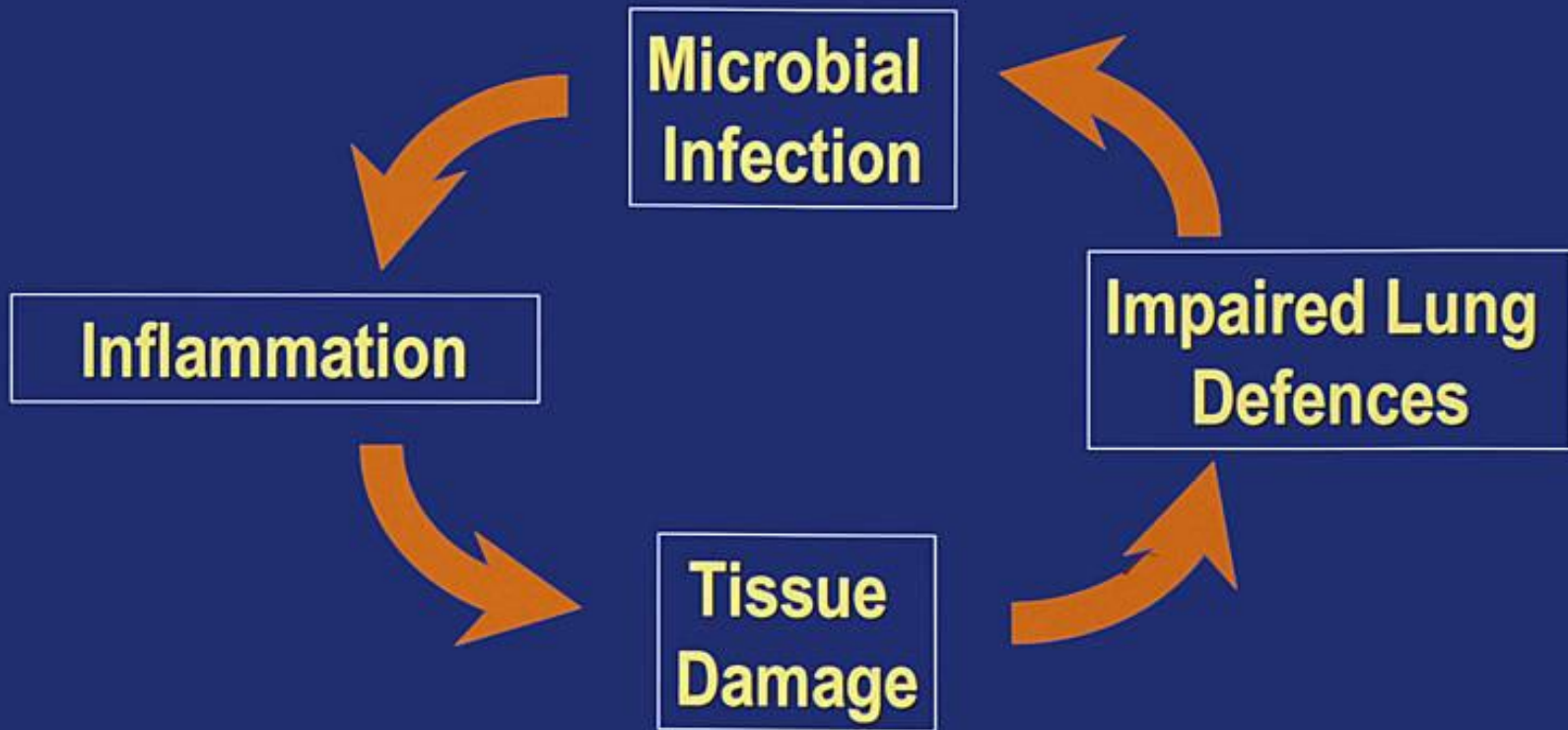


Figure 14–1. Bronchiectasis. A, Varicose bronchiectasis. B, Cylindrical bronchiectasis. C, Saccular bronchiectasis. Also illustrated are excessive bronchial secretions (D) and atelectasis (E), which are both common anatomic alterations of the lungs in this disease.

A VICIOUS CYCLE OF INFECTION AND INFLAMMATION



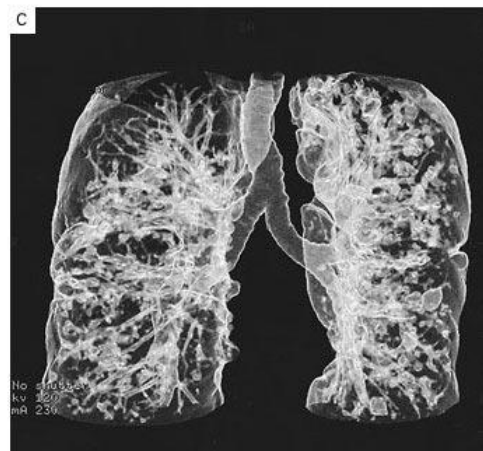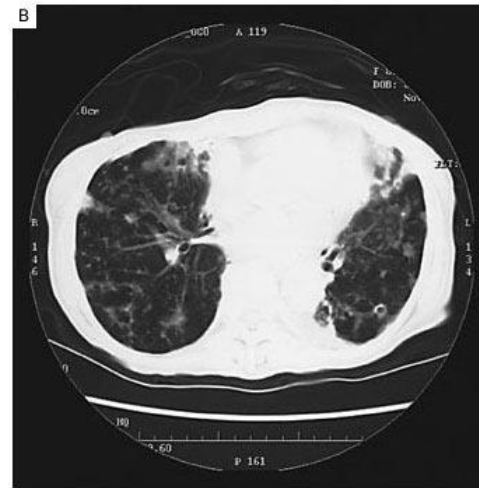
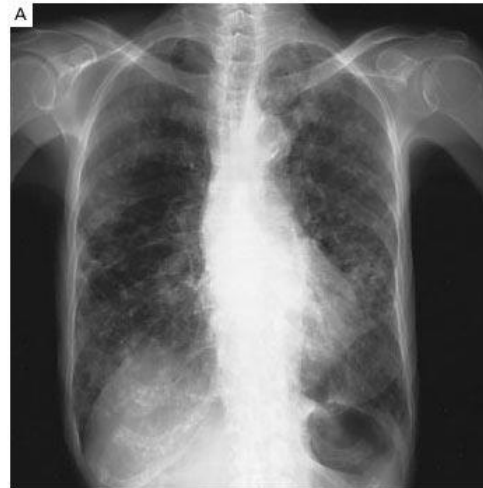
Etiology

- Acquired bronchiectasis
 - Recurrent pulmonary infection
 - Bronchial obstruction
 - Childhood infection e.g measles, pertussis
 - Aspiration
- Congenital bronchiectasis
 - Kartagener's syndrome
 - Hypogammaglobulinemia
 - Cystic fibrosis
 - Abnormal cartilage formation

Aetiology of bronchiectasis

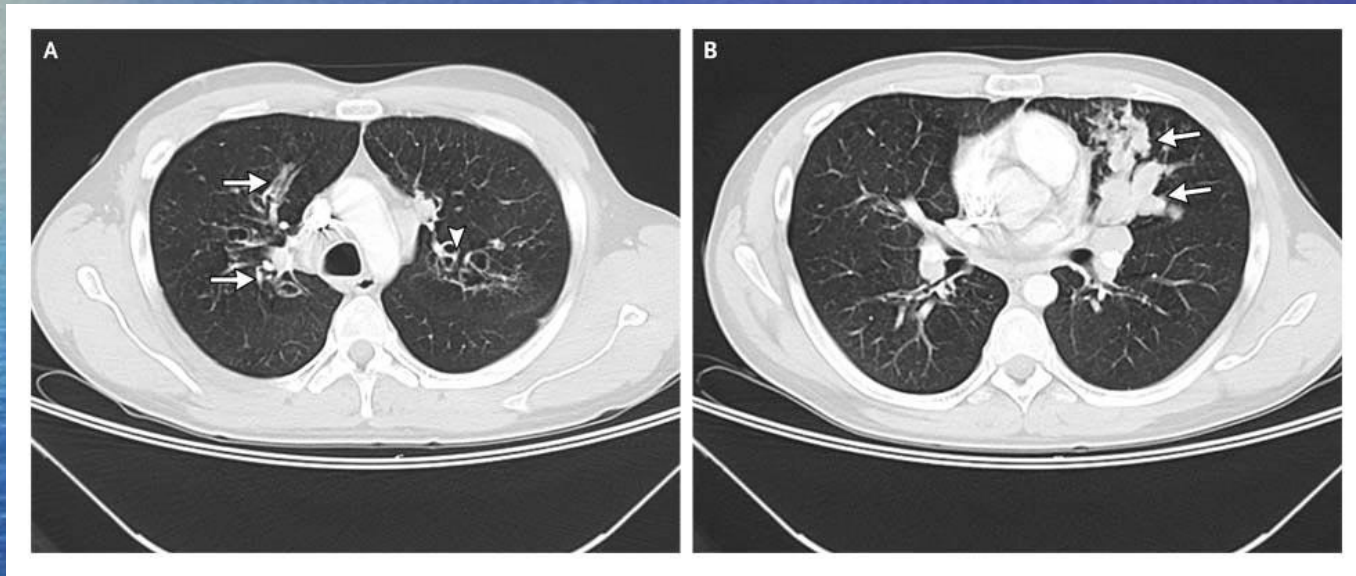
Cause	n (% of study)
Post infection	51 (32)
Idiopathic	42 (26)
PCD	17 (11)
ABPA	13 (8)
Immune deficiency	9 (6)
Ulcerative colitis	5 (3)
Young's syndrome	5 (3)
Pan bronchiolitis	4 (3)
Yellow nail syndrome	4 (3)
Mycobacterium infection	4 (3)
Rheumatoid arthritis	3 (2)
Aspiration	2 (1)
CF variant	2 (1)
Total	161

An 81-year-old woman was admitted with weight loss (18 kg in 27 months), hemoptysis, and tubular and diffuse granular shadows on her chest radiograph (Panel A)



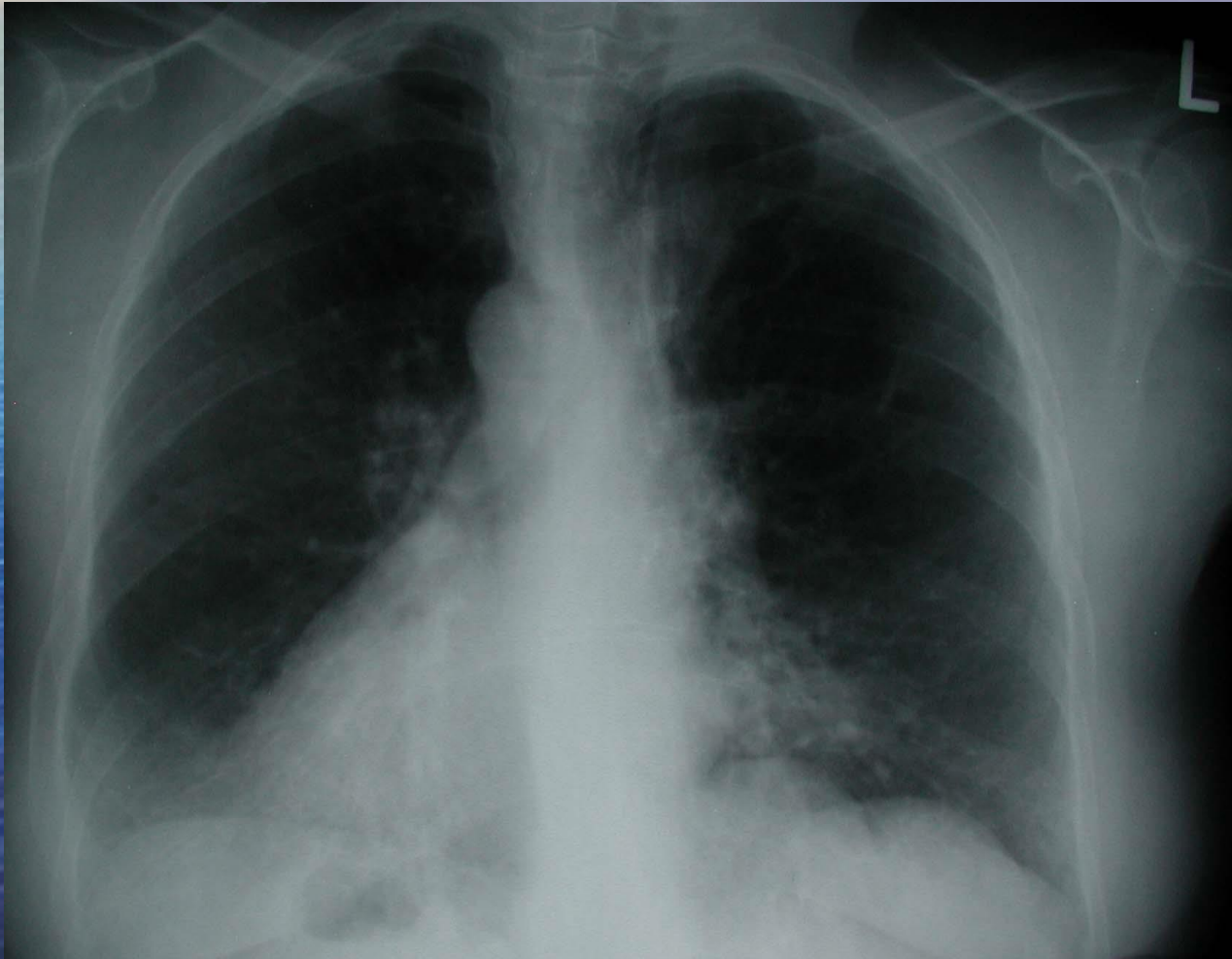
**Final diagnosis:
MAC infection
of bronchiectasis**

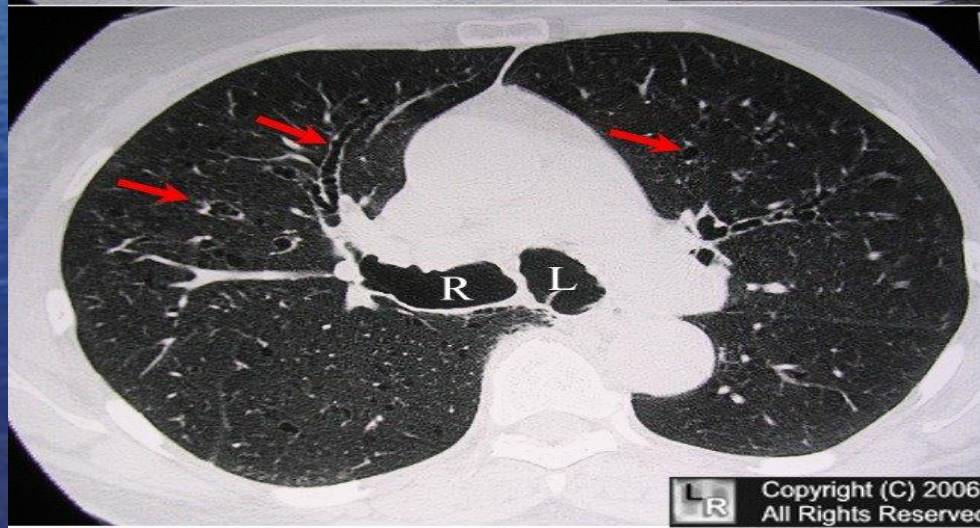
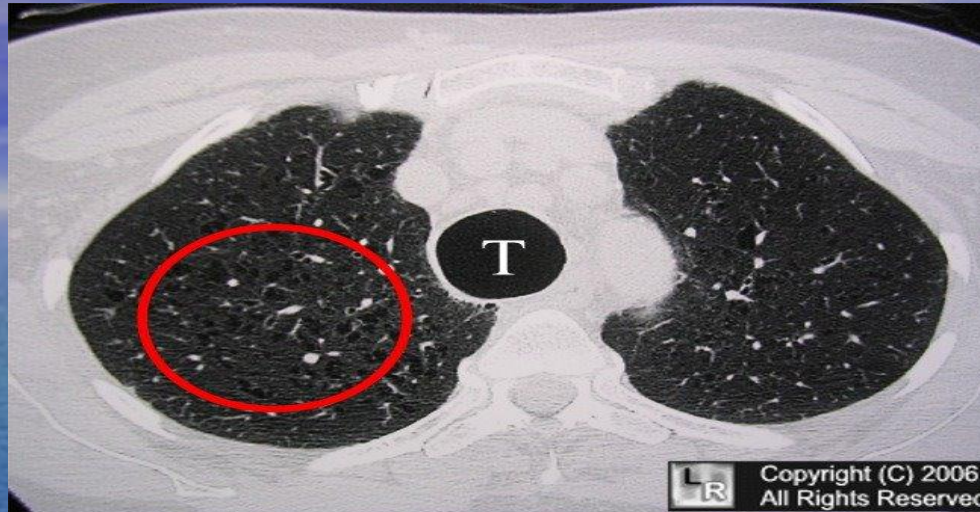
A 26-year-old man who smoked and had a long history of poorly controlled asthma and severe environmental allergies was admitted for an exacerbation of asthma



Final diagnosis: ABPA

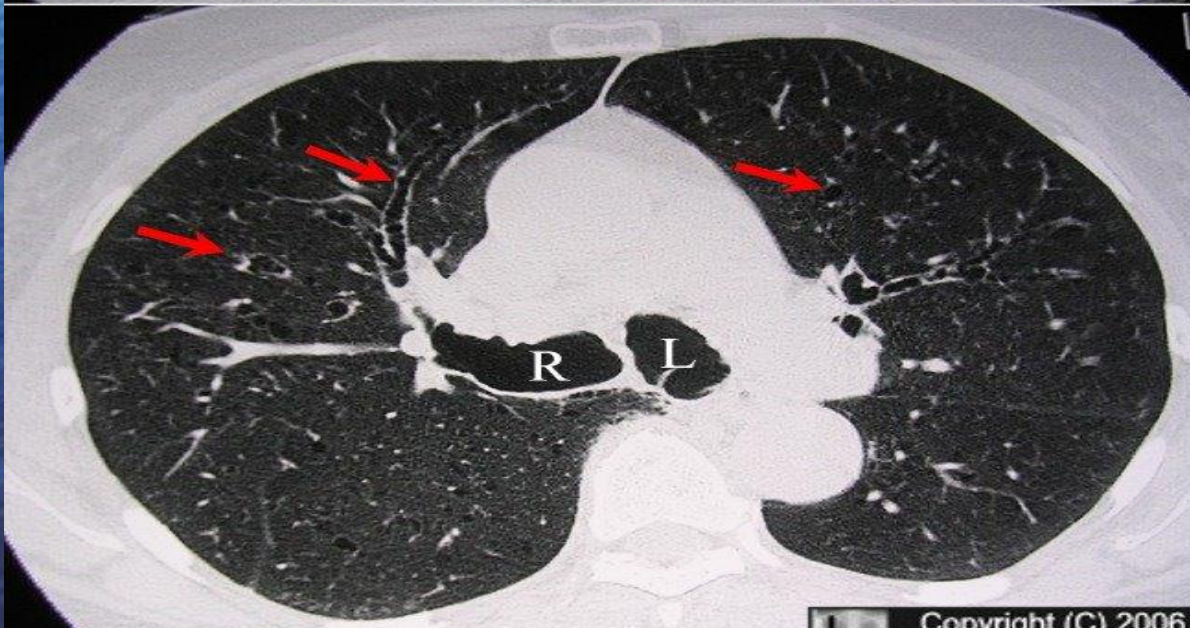
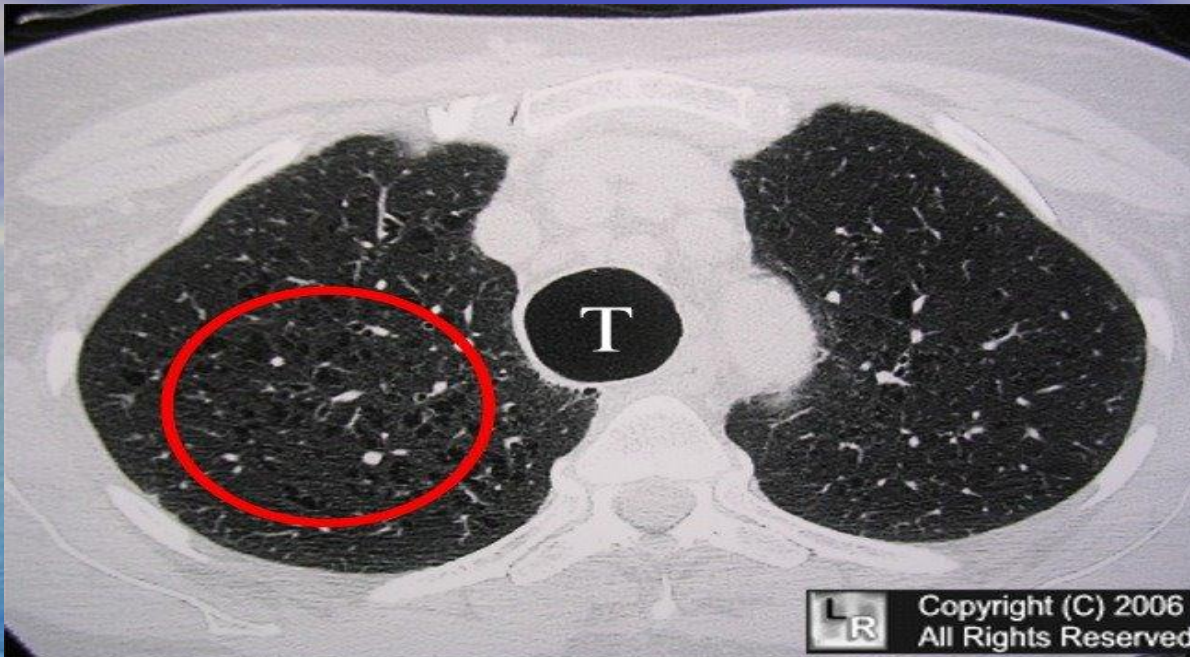
PCD Katergener's





Mounier-Kuhn P. Dilatation de la trachee: Constatations radiographiques et bronchoscopiques. Lyon Medical. 1932;150:106–9.

Mounier-kuhn





Bronchiectasis

Adults

Who to suspect

Persistent productive cough

- young age at presentation
- symptoms over many years
- absence of smoking history
- daily expectoration of large volumes of sputum
- haemoptysis

Unexplained

- haemoptysis
- non-productive cough

After excluding other causes

HISTORY WHICH SHOULD LEAD TO SUSPICION OF BRONCHIECTASIS

- **Recurrent LRTI**
- **Chronic productive cough**
- **Breathlessness, wheeze**
- **Haemoptysis**
- **Chest pain**
- **Tiredness**
- **(ENT, infertility, GI, ILD)**

Thought to have COPD

- COPD with Bronchiectasis
- no history of smoking
- there is slow recovery from lower respiratory tract infections
- recurrent exacerbations
- Sputum growth/colonised with *Pseudomonas aeruginosa*

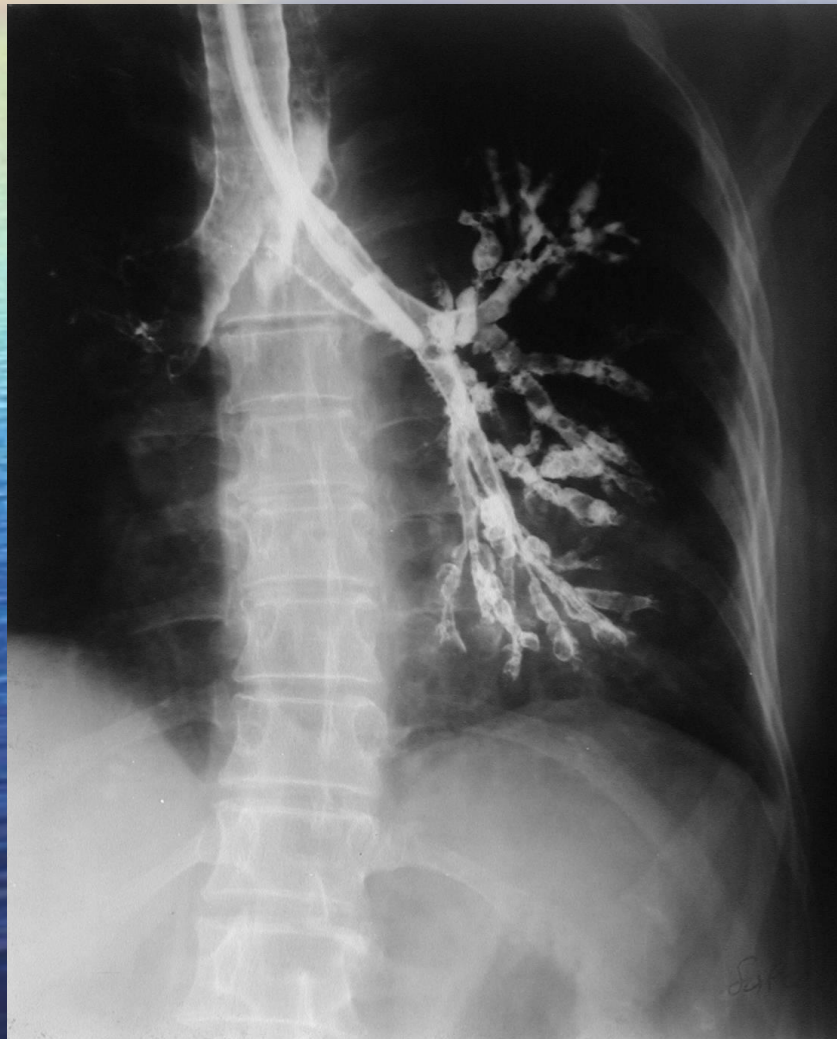Investigations

- Cxray
- HRCT

- Sputum MCS
 1. When stable
 2. Onset exacerbating

- Spirometry

Radiology

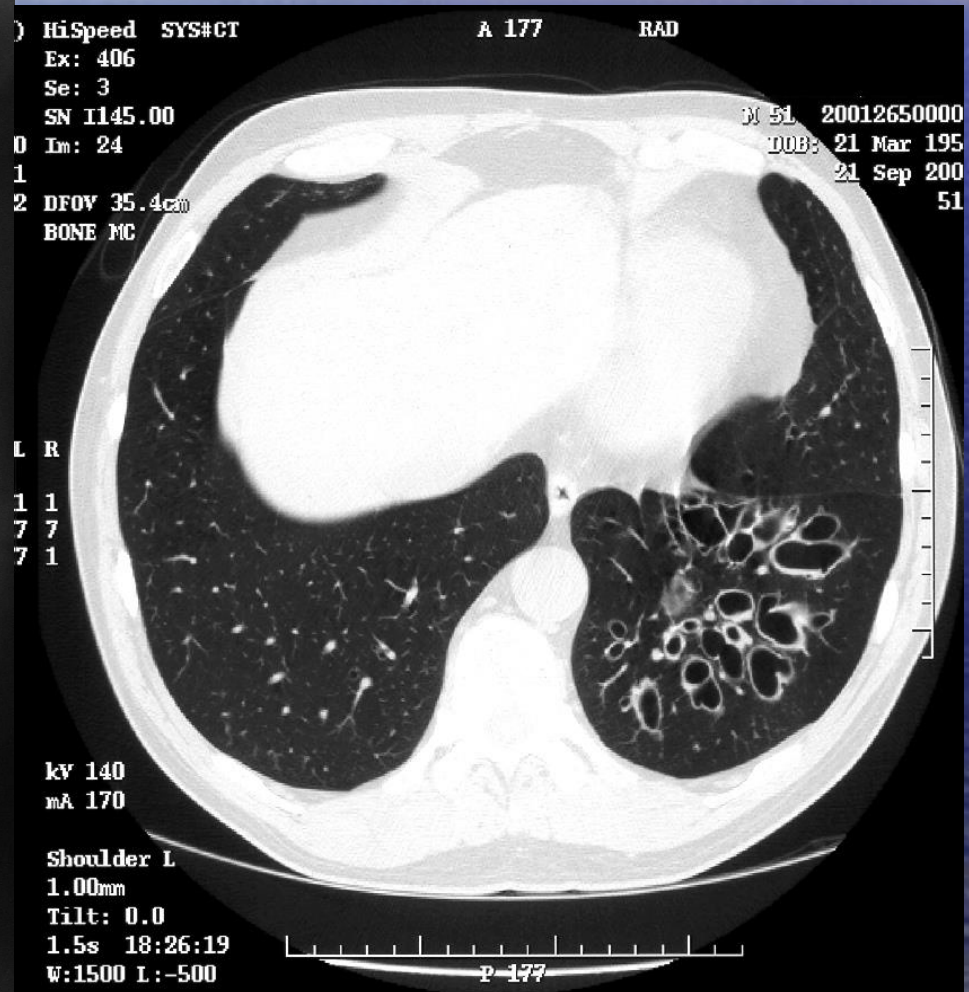


) HiSpeed SYS#CT
Ex: 406
Se: 3
SN 1145.00
0 Im: 24
1
2 DFOV 35.4cm
BONE MC

L R
1 1
7 7
7 1

kv 140
mA 170

Shoulder L
1.00mm
Tilt: 0.0
1.5s 18:26:19
W:1500 L:-500



A 177 RAD

01 20012650000
DOB: 21 Mar 195
21 Sep 200
51

P-177

Exacerbations

- Is it an exacerbation
- ?Antibiotics required
 1. Deterioration over days
 2. Increasing Cough
 3. Increased sputum volume or change of viscosity
 4. increased sputum purulence + increasing wheeze & breathlessness
 5. haemoptysis
 6. systemic upset
 7. Non specific
- Antibiotic Choice, Dose and Duration

Admit

- Development of cyanosis or confusion
- Breathlessness with a respiratory rate >25 /minute
- Circulatory failure, respiratory failure, cyanosis or confusion
- Temperature $>38^{\circ}\text{C}$
- Patient unable to take oral therapy
- Patient unable to cope at home
- Haemoptysis $>25\text{mls/day}$
- Intravenous therapy required in patients with clinical failure after oral antibiotics

Common organisms associated with acute exacerbation of bronchiectasis and suggested antimicrobial agents

Streptococcus pneumoniae

Amoxicillin 500 mg tds
Clarithromycin 500 mg bd 14 days

Haemophilus influenzae (b-lactamase negative)

Amoxicillin 500 mg tds
Amoxicillin 1 g tds
Amoxicillin 3 g bd
Clarithromycin 500 mg bd

Haemophilus influenzae (b-lactamase positive)

Co-amoxiclav 625 mg tds
Clarithromycin 500 mg bd
Ciprofloxacin 500 mg bd

Moraxella catarrhalis

Co-amoxiclav 625 mg tds
Ciprofloxacin 500 mg bd

Staphylococcus aureus (MSSA)

Flucloxacillin 500 mg qds
Clarithromycin 500 mg bd

MRSA

Coliforms

Ciprofloxacin

Pseudomonas

Empiric therapy

- Amoxicillin 500mg tds 14days
- Clarithromycin 500 bd
- Severe Bronchiectasis/colonised with H influenzae

Amoxicillin 1g tds/ 3g bd

- Pseudomonas colonised patients
Ciprofloxacin 500/750 bd.

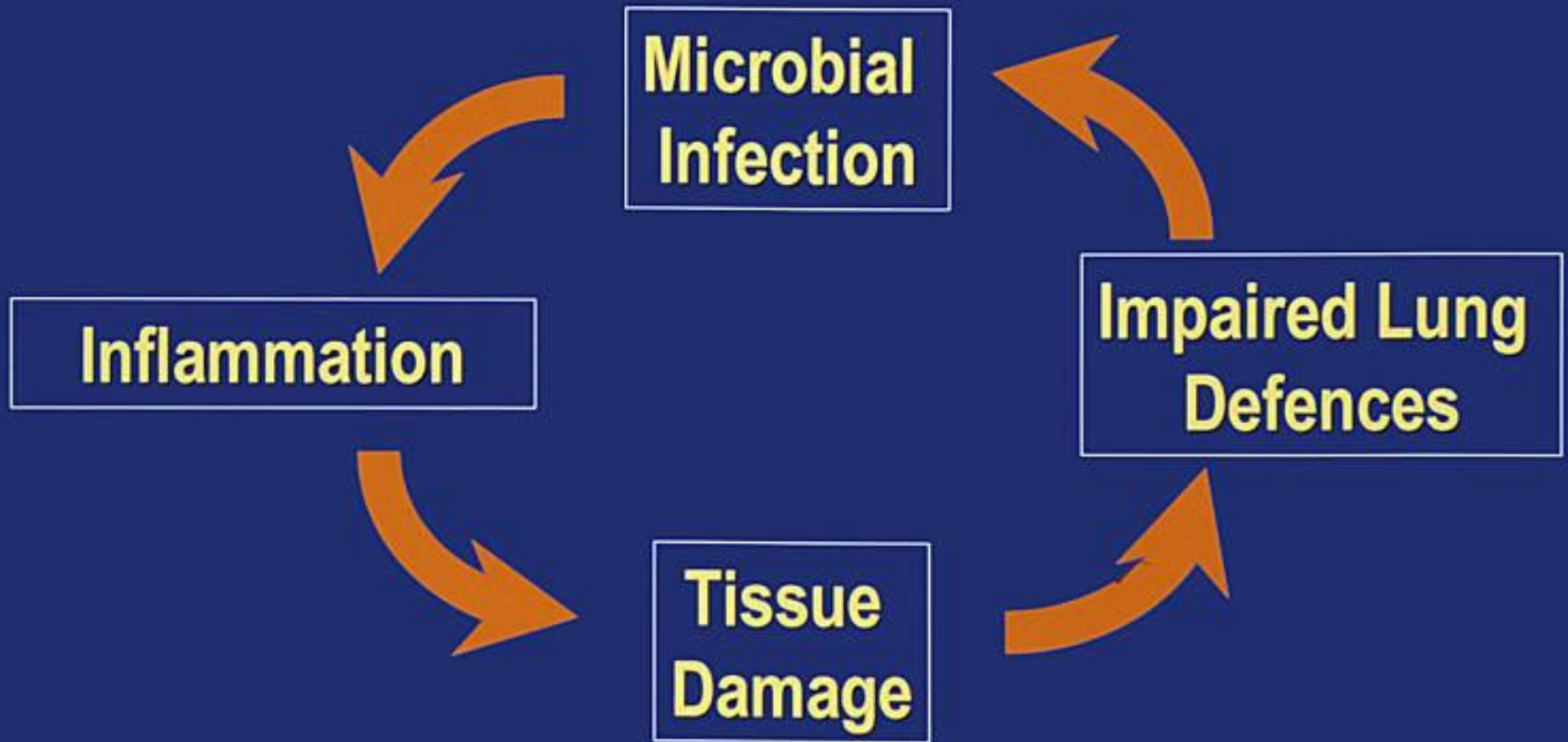
Long Term antibiotics

- =>3 Exacerbations/yr
- Fewer Exacerbation but significant morbidity
- Nebulised antibiotics
Gent/tobramycin/colistin
- Long term Macrolides

Management

- Physiotherapy
- Immunisation
- Bronchodilators
- Mucolytics
- Nebulised saline

A VICIOUS CYCLE OF INFECTION AND INFLAMMATION



Monitoring

- Symptom
- Sputum Volume 24hrs/Purulence
- Frequency of Exacerbations/yr
- Frequency of Antibiotic use
- FEV1 FVC PEF annually
- Cxray only if indicated

Self Management Plan

BTS Bronchiectasis Self Management Plan

My Usual Symptoms day to day when stable- (not during a chest infection) please tick or answer

Cough

- I normally cough most days of the week
- I normally cough one or two days of the week
- I normally cough a few days per month
- I normally cough only with chest infections

Sputum

- I normally cough up sputum most days of the week
- I normally cough up sputum one or two days of the week
- I normally cough up sputum a few days per month
- I normally cough up sputum only with chest infections

What colour is it?

- clear white light yellow or green dark yellow or green

How much do you cough day to day?

- 1 teaspoon 1 tablespoonful half a sputum pot 1 sputum pot

Is your sputum?

- watery sticky

Breathlessness

- I normally get breathless walking around the home
- I normally get breathless walking outside on the level
- I normally get breathless walking up a flight of stairs
- I normally get breathless playing sports
- I only get breathless with chest infections
- I never get breathless

Other usual symptoms e.g. wheezing, tiredness, fatigue _____

Chest infections

Signs (you may have some or all of these)

- Feeling generally unwell
- Coughing up more sputum or sputum more sticky
- Worsening colour to your sputum (clear to light or dark yellow or green Or light to dark yellow or green)
- Worsening breathlessness

Action

- Clear your chest more often (at least twice daily).
- Take your medication and inhalers.
- Drink plenty of fluids.
- Collect sputum sample and hand to GP as soon as possible (if cannot get to surgery that day, keep the sample in fridge overnight).
- Some colds get better without needing antibiotics. If there is no change in the amount or colour of your sputum **do not start** your antibiotics.
- Seek help if needed

Day to day

- Clear your chest as advised by your physiotherapist.
- Take your medication and inhalers, if on them, as prescribed.
- Never allow medicines to run out.
- Keep a rescue antibiotic course at home.
- Drink plenty of fluids, eat a healthy diet and take regular exercise.
- Don't smoke. Ask for help from your practice nurse if needed.
- Get your annual flu vaccination.
- Avoid visiting anyone who is unwell with a cold, flu or chest infection.
- Keep a supply of sputum pots in the house.
- Know how much sputum you have and its colour.

Recommended chest treatment day to day

- 1.
- 2.
- 3.
- 4.
- 5.
- 6.
- 7.
- 8.
- 9.
- 10.

Recommendation treatment for chest infections

- 1.
- 2.
- 3.
- 4.
- 5.
- 6.
- 7.
- 8.
- 9.
- 10.

Name _____

Date of Birth _____

Hospital/NHS Number _____

Date _____

When to seek help

Rescue GP

- When? If you feel your bronchiectasis is worse but no change in the amount or stickiness or colour of your sputum and no improvement within 48 hours, make an appointment to see your GP
- Action. Take sputum sample to your GP - do not start antibiotics until you have seen your GP

Light GP

- When? All chest infections where you feel unwell with coughing up more sputum and worsening colour to your sputum or worsening breathlessness OR
- If coughing up blood OR
- If chest pain breathing in
- Action. Collect sputum sample and then start the antibiotics recommended immediately without waiting for the sputum result

Emergency GP or 999

- When? You are confused or drowsy OR
- Coughing up large amounts of blood OR
- Severely breathlessness or breathless whilst talking
- Action. Call the emergency GP first
- Collect sputum sample if feasible and then start the antibiotics recommended immediately without waiting for the sputum result

Contact Numbers

GP
Community respiratory team
Hospital respiratory team



A VICIOUS CYCLE OF INFECTION AND INFLAMMATION

