Valvular Heart Disease

Nouf Alanazi

Assistant Professor & Consultant Interventional Cardiologist

King Saud University

Sep 29th 2019

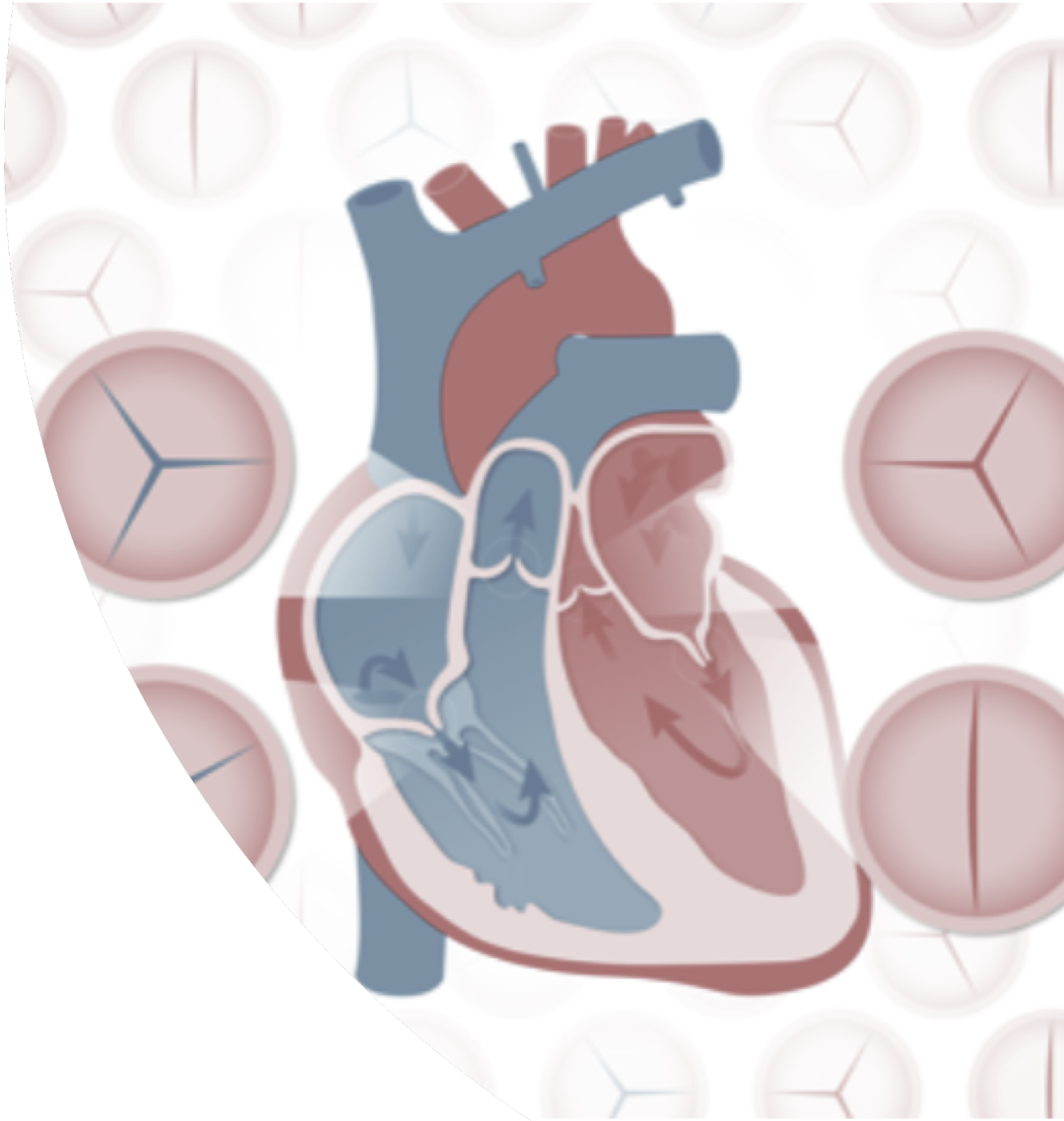

Objectives

- Describe the etiology, pathology, and natural history of valvular heart disease.
- Describe the clinical symptoms and signs of valvular heart disease.
- Explain the clinical examination findings of particular valvular problems.
- Determine the role of echocardiograms in valvular heart disease, both in diagnosis and prognosis.
- Discuss the long-term systemic consequences of valvular heart disease.
- Describe the management and identify the indications of surgical intervention for particular valvular heart diseases.

Agenda

- What are heart valves
- Anatomy
- Native and prosthetic heart valves
- Definition of valvular heart disease
- Types of pathology
- Pathophysiology
- Stages of VHD
- Diagnosis & Workup
- Prophylaxis with RF & IE.
- Overview of the main pathologies
- Management

What are heart valves?

- Cardiac structures that maintain continuous free forward blood flow without backward leakage.

- **There are four main cardiac valves divided into 2 groups:**

❑ **Atriventricular valves:**

✓ Mitral valve

✓ Tricuspid valve

❑ **Semilunar valves**:

✓ Aortic valve

✓ Pulmonic valve

Anatomy

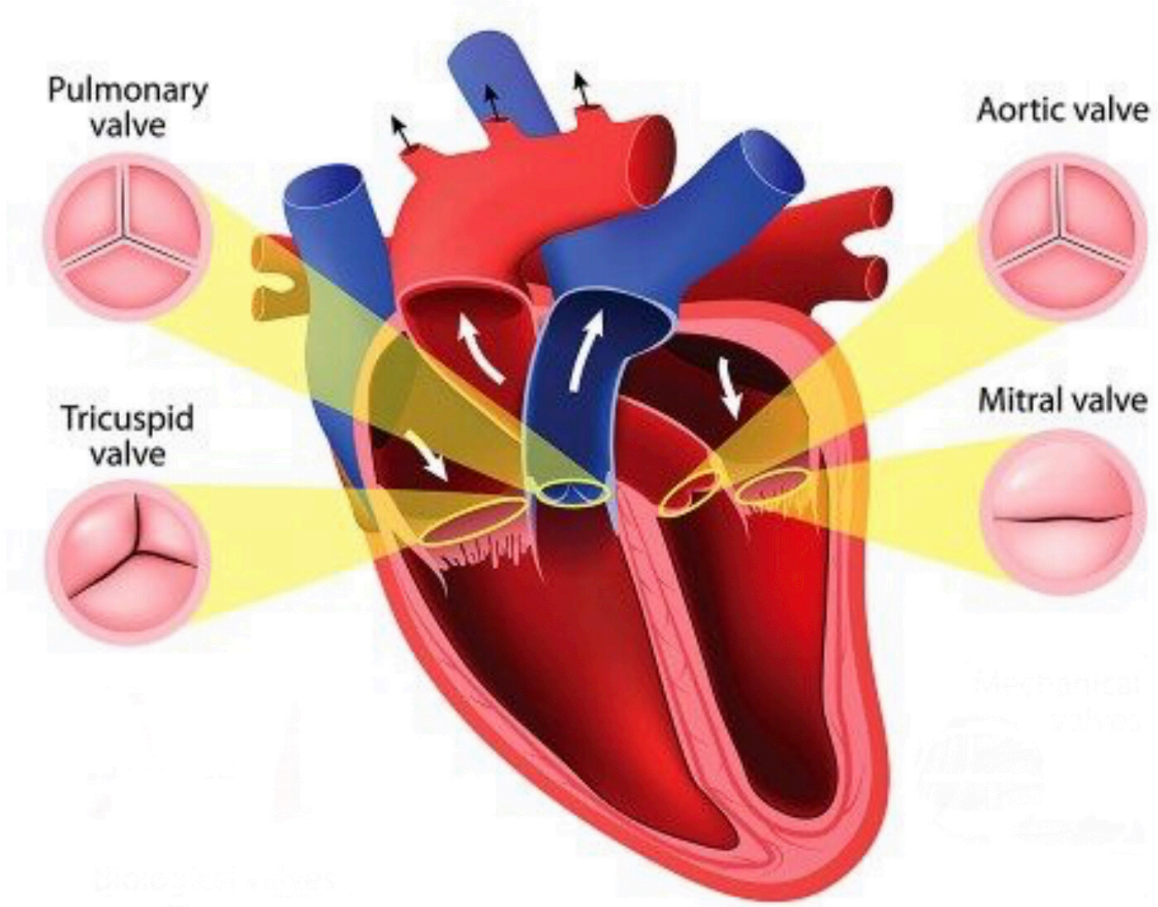

Nouf Alanazi 2019

Anatomy

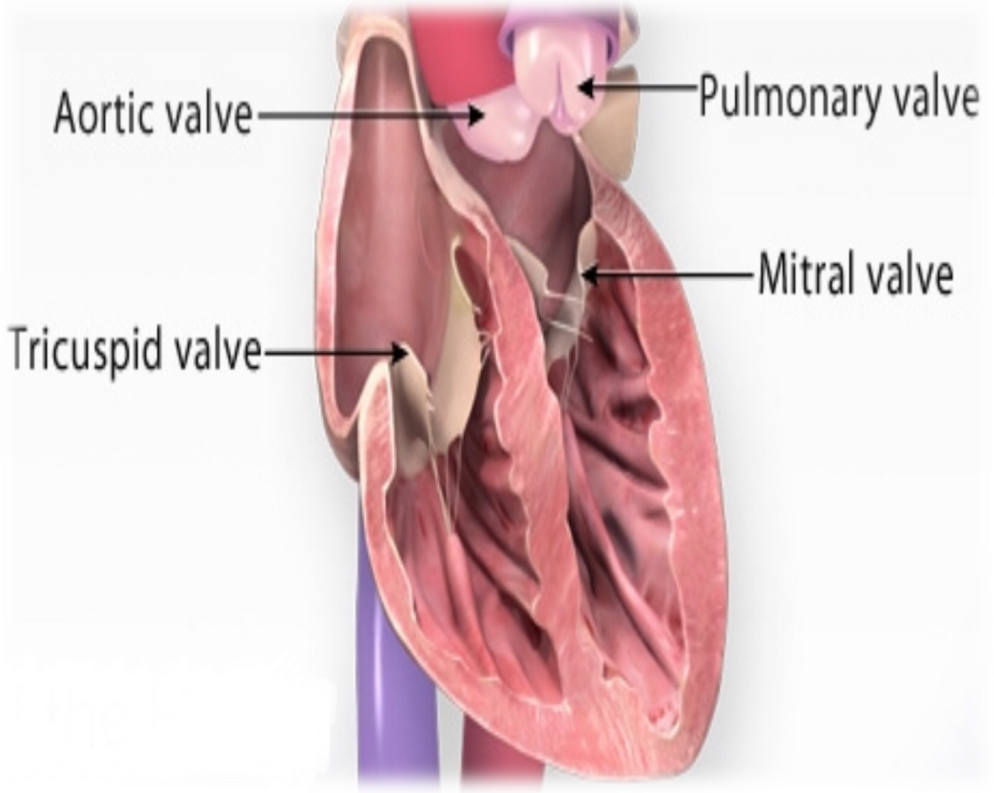

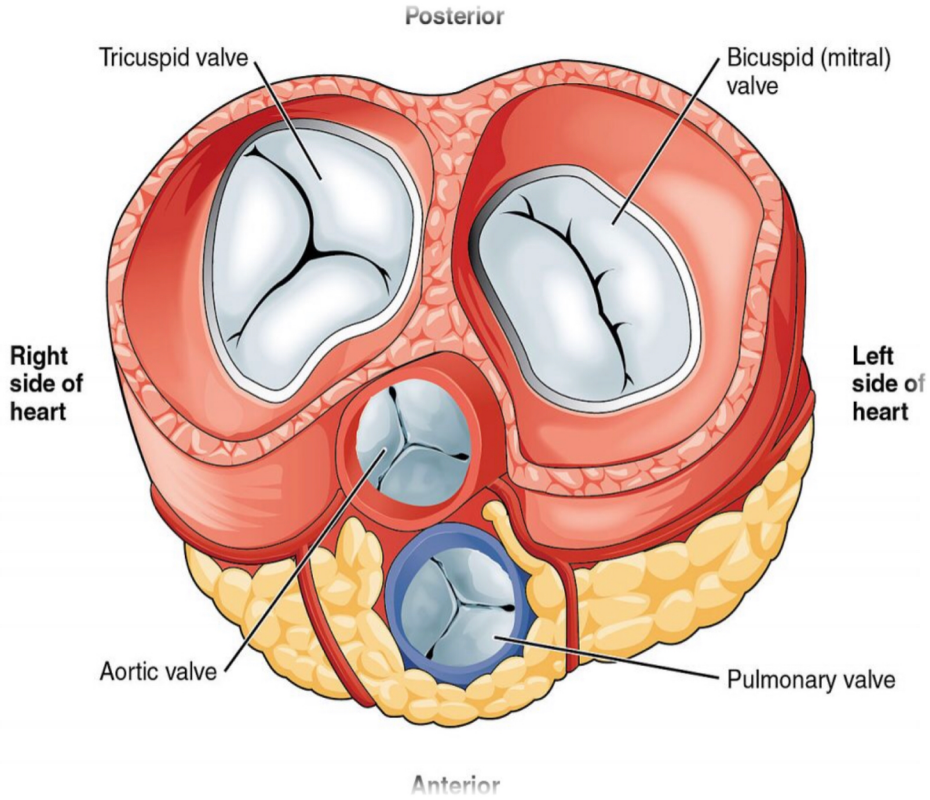

Nouf Alanazi 2019

Valve function

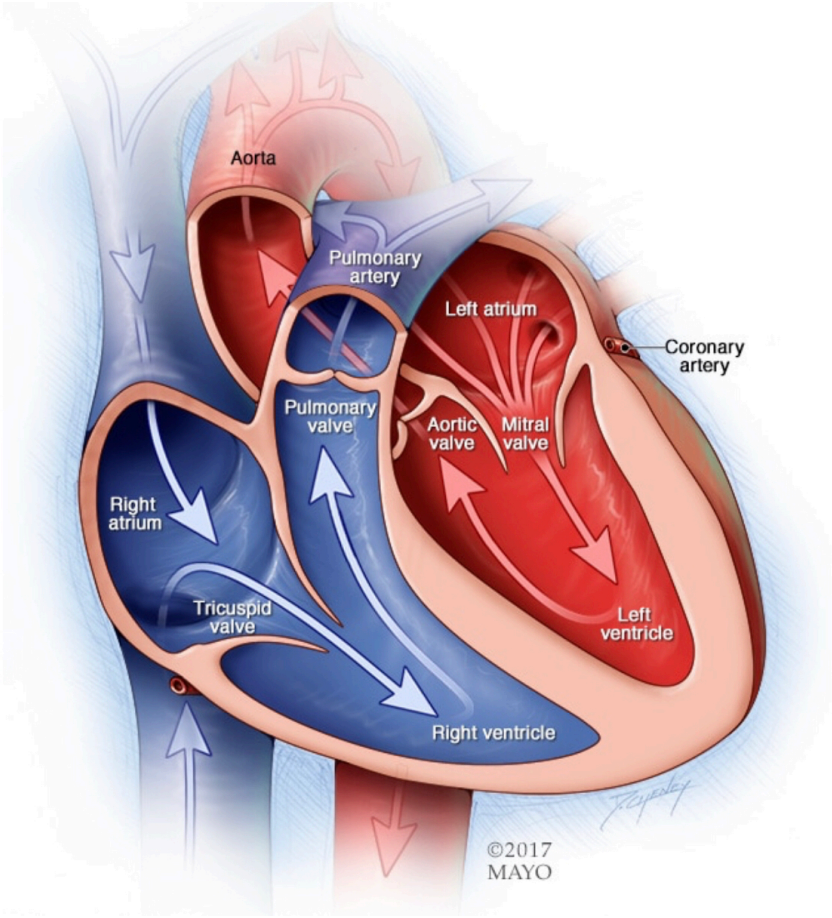

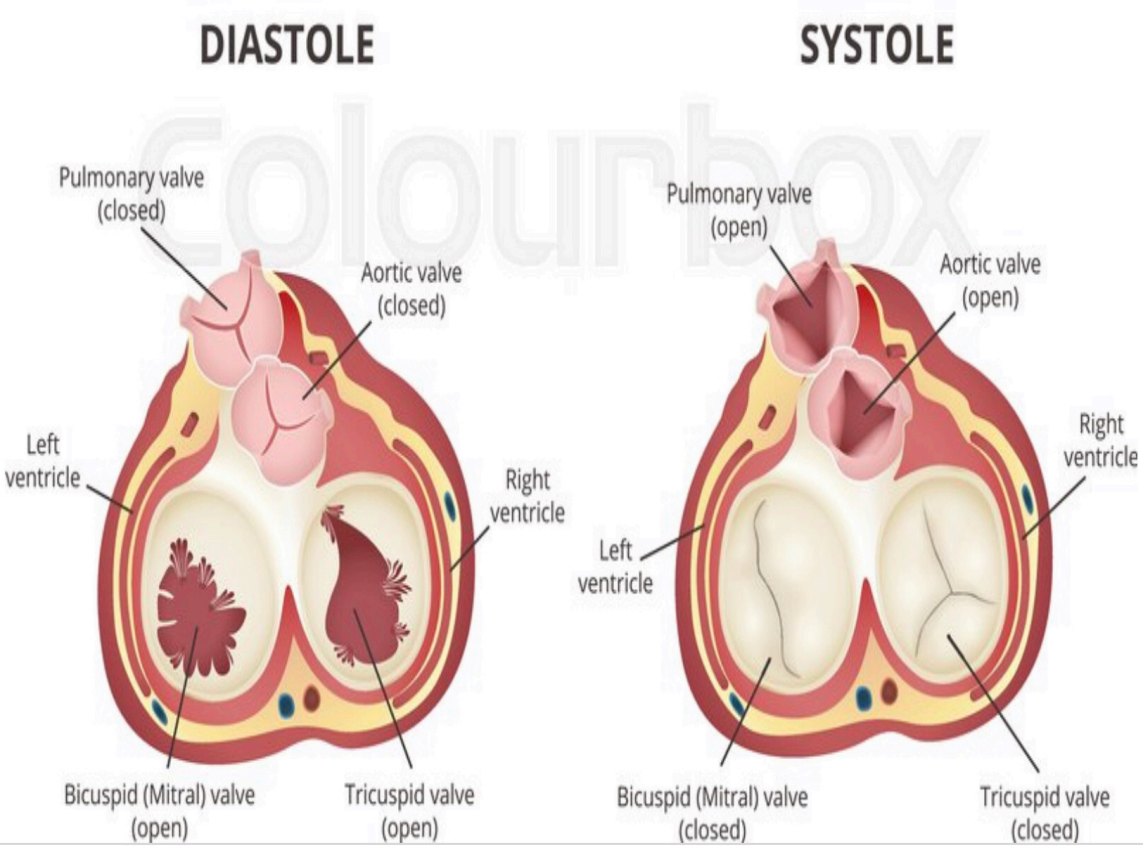

Nouf Alanazi 2019

Native & prosthetic valves

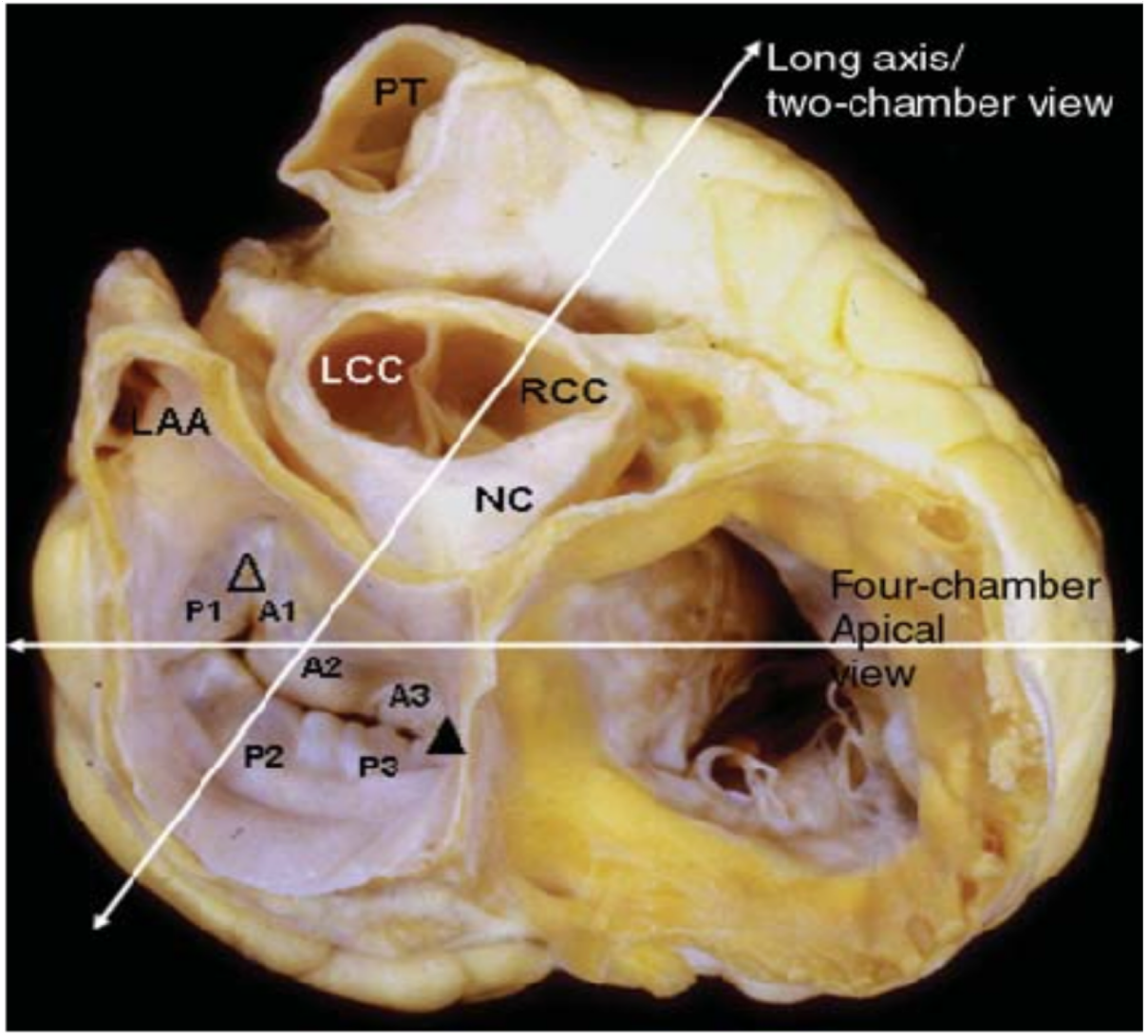

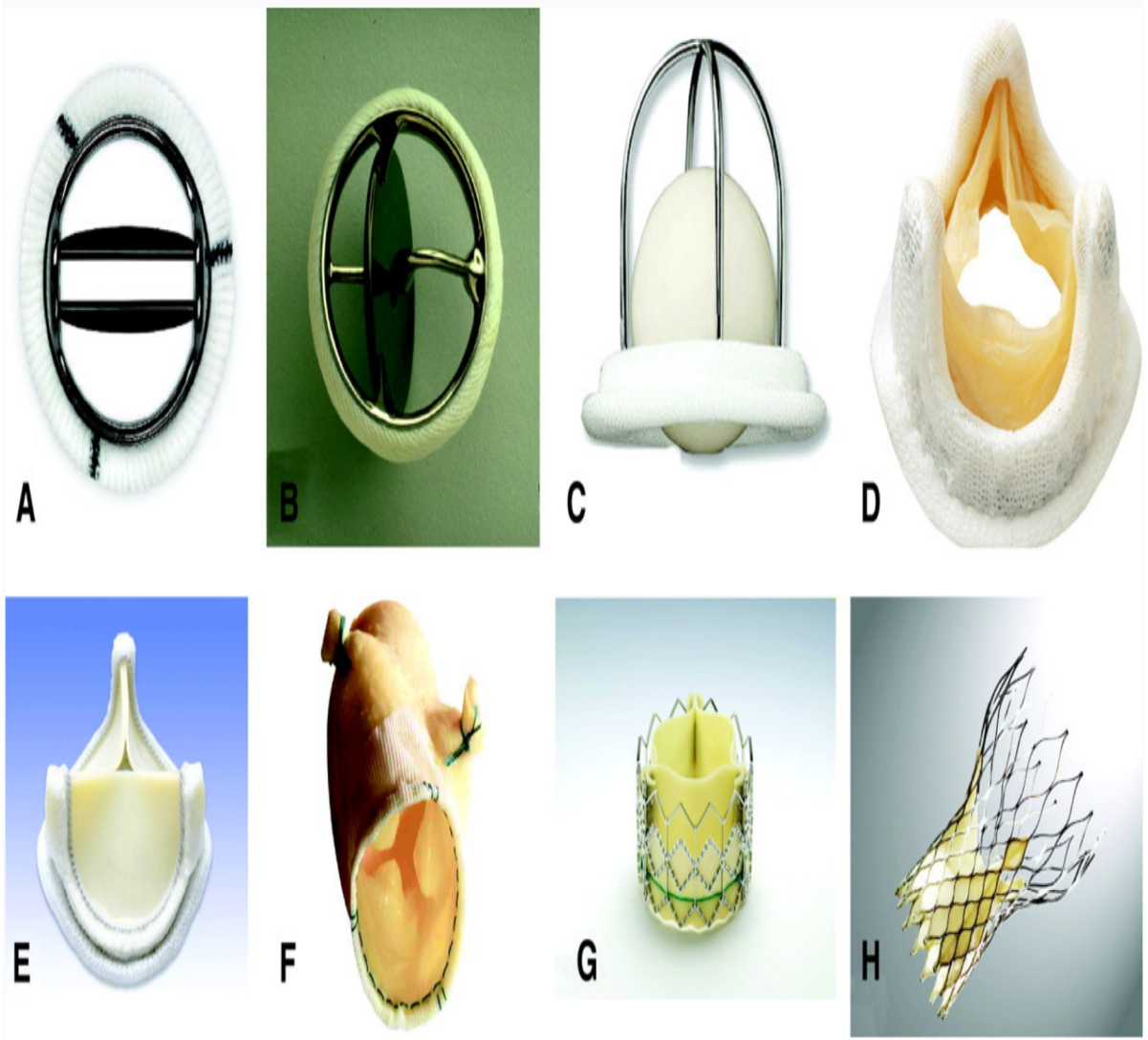

What is Valvular Heart Disease (VHD) ?

Acquired or congenital cardiac abnormality of the heart valves that interfere with their normal function

Types of pathology

Stenosis

- Narrowing that leads to obstruction of flow

Regurgitation

- Backward leakage of blood

Etiology of VHD

Stenosis	Regurgitation
Congenital	Congenital
Rheumatic	Rheumatic
Degenerative / Senile	Degenerative e.g myxomatous, calcification
Drugs	Infective endocarditis
Radiation	Valve ring dilatation e.g Dilated Cardiomyopathy
	Infections e.g syphilis
	Traumatic
	Ischemia

Stages of VHD

Stage	Definition	Description
A	At risk	Patients with risk factors for development of VHD
B	Progressive	Patients with progressive VHD (Mild-Moderate) (Asymptomatic)
C	Asymptomatic Severe	Asymptomatic but reached the criteria of severe VHD C1: Asymptomatic with compensated cardiac function C2: Asymptomatic but decompensated cardiac function.
D	Symptomatic Severe	Developed symptoms secondary to VHD

Types of Presentations

Acute	Chronic
e.g Acute mitral regurgitation due to eg acute myocardial infarction acute chordea tendineae rupture	e.g Chronic mitral regurgitation due to eg RHRUMATIC fever . Mitral valve Prolapse . e.g Chronic aortic regurgitation due to eg Bicuspid Aortic valve

Hemodynamic consequences

Pressure Overload	Volume Overload
Aortic stenosis Left Ventricular hypertrophy Mitral stenosis Left Atrial hypertrophy & dilatation	Chronic mitral regurgitation Dilated left ventricle & left atria Chronic tricuspid regurgitation Dilated right ventricle & right atria

Presentation

Symptoms	Signs
Dyspnea , paroxysmal nocturnal dyspnea orthopnea .	Abnormal look (Mitral facies)
Palpitations	Abnormal pulse (AF)
Chest pain	Abnormal JVP
Dizziness, presyncope, syncope	Apex beat abnormality
Edema, ascites	Parasternal heave
Cough	Thrill
Fatigue	Abnormal heart sounds
Hemoptysis	Extra heart sounds
Symptoms of thromboembolic complications	Murmurs (systolic or diastolic)

Dx & workup

- ECG .
- CXR .
- Echocardiography
- Holter monitor.
- MRI .
- Cardiac catheterization.
- Exercise test.

Echocardiography

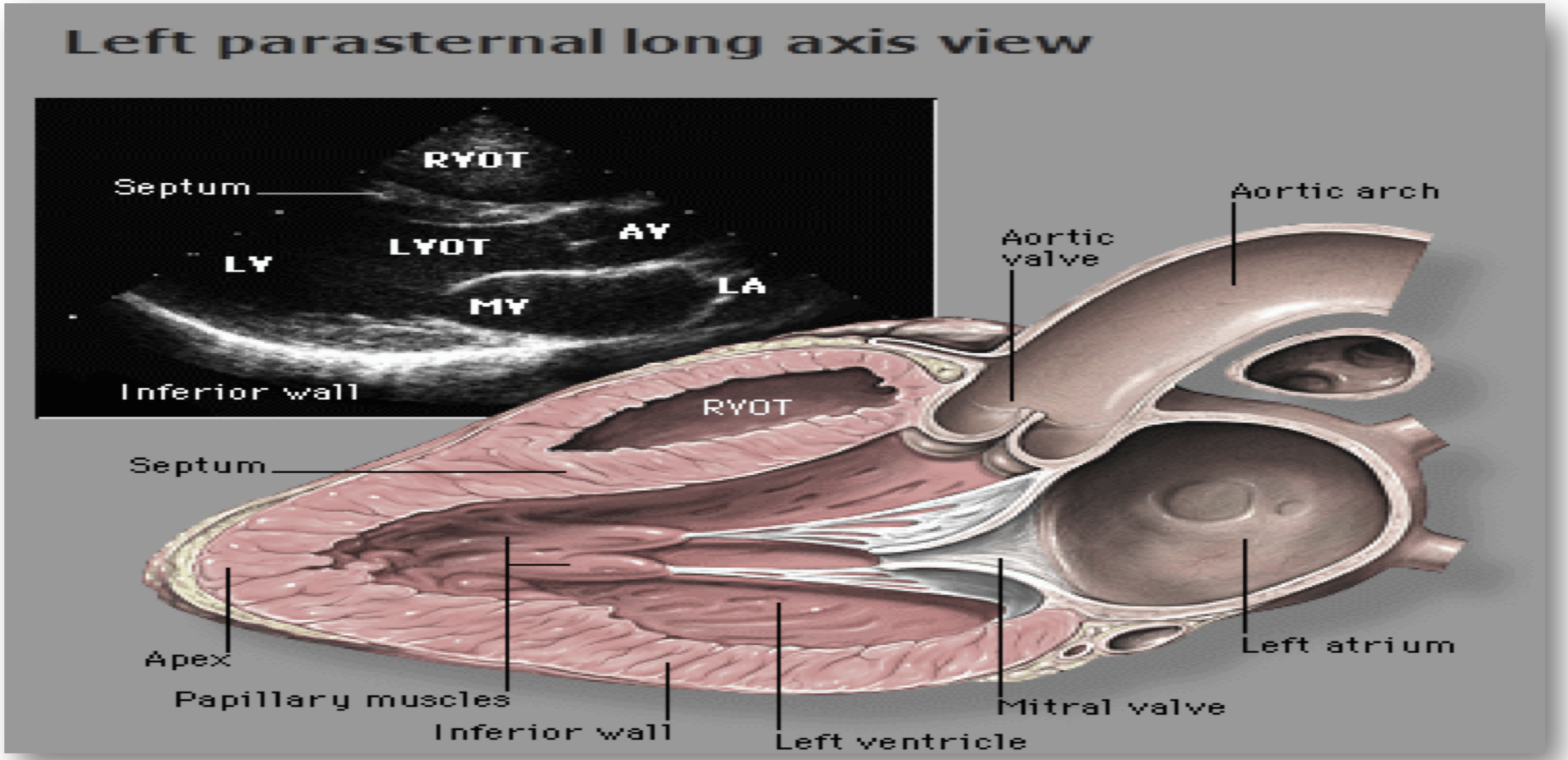

Nouf Alanazi 2019

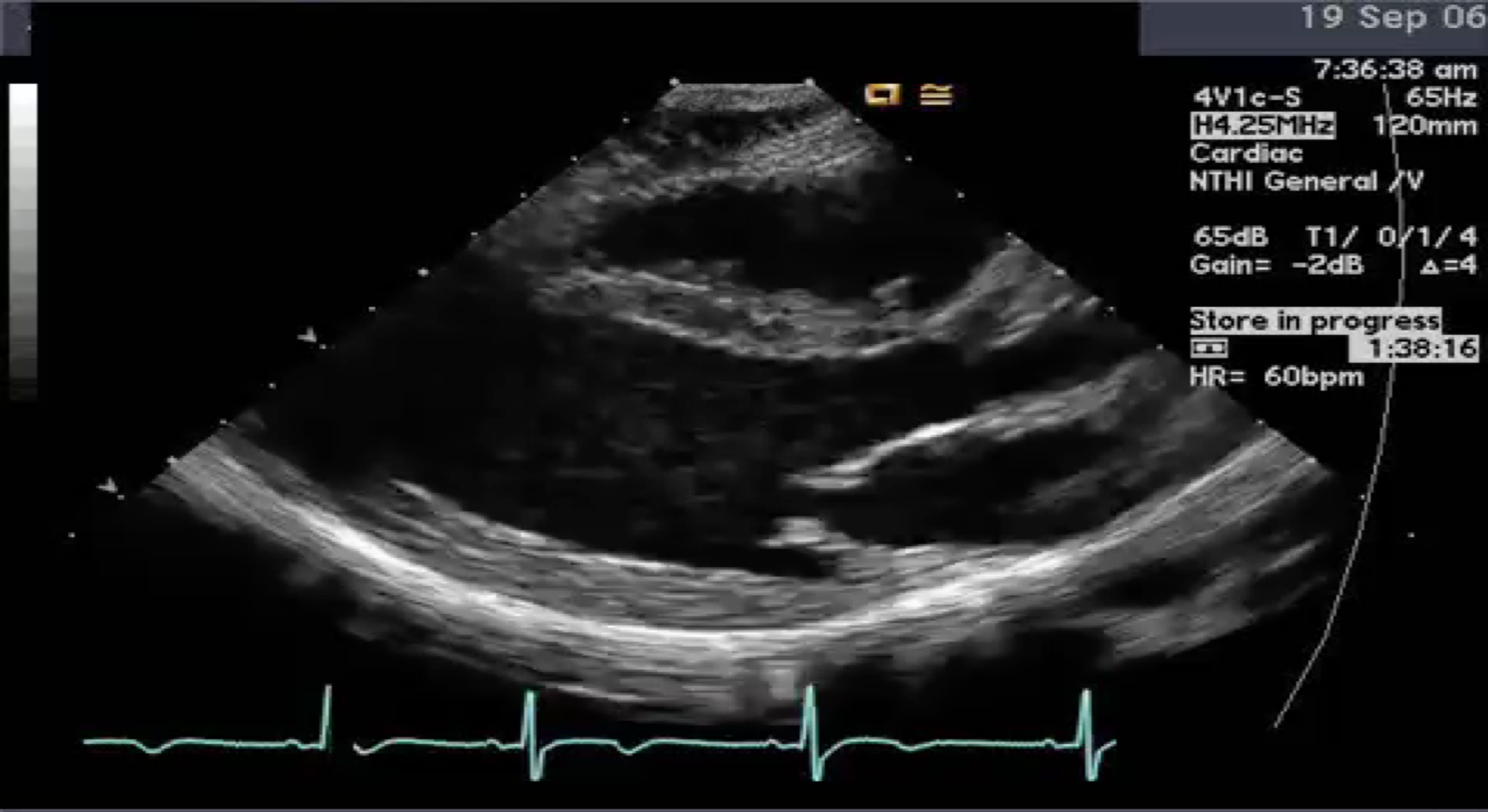
19 Sep 06
7:36:38 am
4V1c-S
65Hz
H4.25MHz
120mm
Cardiac
NTHI General /V
65dB T1/ 0/1/ 4
Gain= -2dB Δ=4
Store in progress
1:38:16
HR= 60bpm

Frequency of Echocardiograms in Asymptomatic Patients With VHD and Normal Left Ventricular Function

Stage	Valve Lesion			
Stage	**Aortic Stenosis***	**Aortic Regurgitation**	**Mitral Stenosis**	**Mitral Regurgitation**
Progressive (stage B)	Every 3–5 y (mild severity V_{max} 2.0–2.9 m/s) Every 1–2 y (moderate severity V_{max} 3.0–3.9 m/s)	Every 3–5 y (mild severity) Every 1–2 y (moderate severity)	Every 3–5 y (MVA >1.5 cm^2)	Every 3–5 y (mild severity) Every 1–2 y (moderate severity)
Severe (stage C)	Every 6–12 mo ($V_{max} \geq 4$ m/s)	Every 6–12 mo Dilating LV: more frequently	Every 1–2 y (MVA 1.0–1.5 cm^2) Once every year (MVA <1.0 cm^2)	Every 6–12 mo Dilating LV: more frequently

Nouf Alanazi 2019

Secondary Prevention of Rheumatic Fever

Agent	Dosage
Penicillin G benzathine	1.2 million units IM every 4 wk*
Penicillin V potassium	250 mg orally BID
Sulfadiazine	1 g orally once daily
Macrolide or azalide antibiotic (for patients allergic to penicillin and sulfadiazine)†	Varies

*Administration every 3 wk is recommended in certain high-risk situations.

†Macrolide antibiotics should not be used in persons taking other medications that inhibit cytochrome *P450 3A*, such as azole antifungal agents, HIV protease inhibitors, and some selective serotonin reuptake inhibitors.

Adapted from Gerber et al. (50).

BID indicates twice daily; HIV, human immunodeficiency virus; and IM, intramuscularly.

Nouf Alanazi 2019

Duration of Secondary Prophylaxis for Rheumatic Fever

Type	Duration After Last Attack
Rheumatic fever with carditis and residual heart disease (persistent VHD*)	10 y or until patient is 40 y of age (whichever is longer)
Rheumatic fever with carditis but no residual heart disease (no valvular disease*)	10 y or until patient is 21 y of age (whichever is longer)
Rheumatic fever without carditis	5 y or until patient is 21 y of age (whichever is longer)

*Clinical or echocardiographic evidence.
Adapted from Gerber et al. (50).
VHD indicates valvular heart disease.

Nouf Alanazi 2019

Prophylaxis against IE

Patients at highest risk for adverse outcomes from IE before dental procedures that involve manipulation of *gingival tissue, manipulation of the periapical region of teeth, or perforation of the oral mucosa*:

1. Patients with PHV.
2. Patients with previous IE
3. Cardiac transplant recipients with valve regurgitation due to a structurally abnormal valve.
4. Patients with CHD with:
   - ✓ Unrepaired cyanotic CHD, including palliative shunts and conduits;
   - ✓ Completely repaired CHD repaired with prosthetic material or device, whether placed by surgery or catheter intervention, during the first 6 M after the procedure.
   - ✓ Repaired CHD with residual defects at the site or adjacent to the site of a prosthetic patch or prosthetic device.

Overview of the main valvular pathologies

- Aortic stenosis
- Aortic insufficiency (Acute & chronic)
- Mitral stenosis
- Mitral regurgitation (Acute & chronic)
- Tricuspid and pulmonic valves
- Prosthetic valve dysfunction

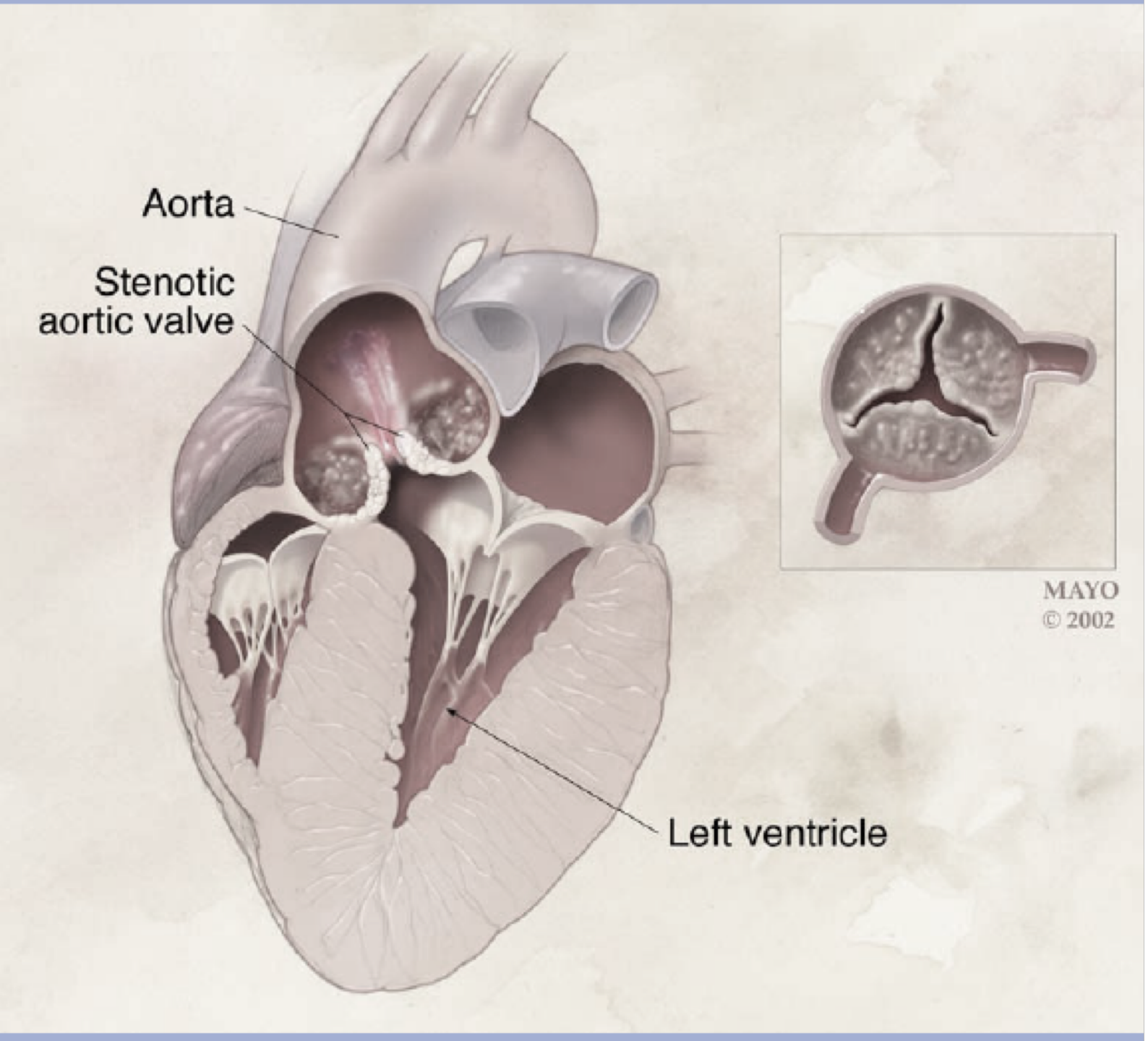

Aortic stenosis (AS)

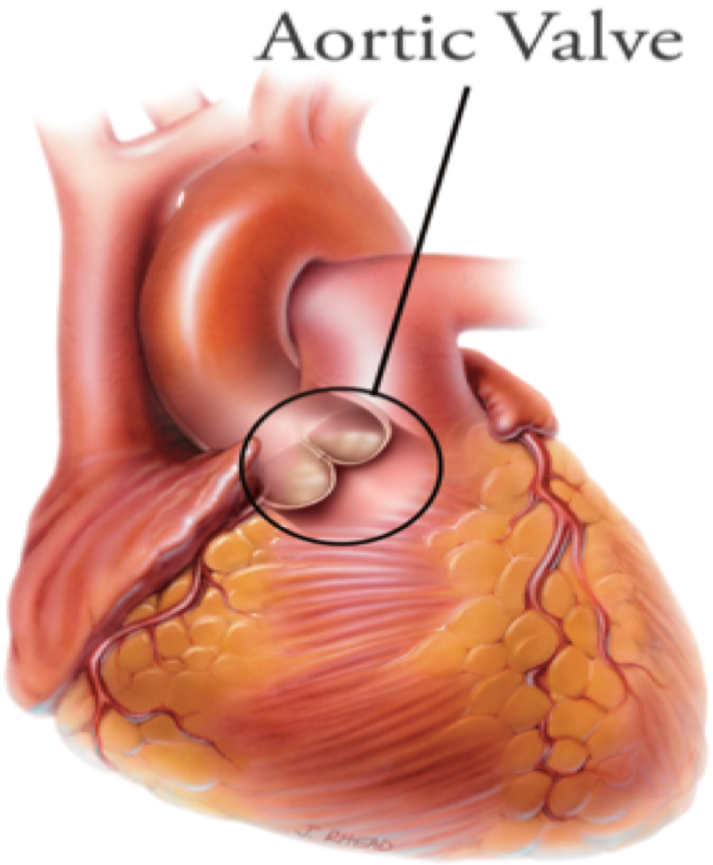

Narrowing of the aortic valve

HEALTHY AORTIC VALVE

Open

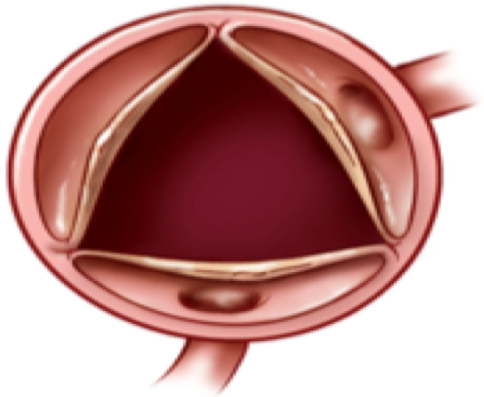

Closed

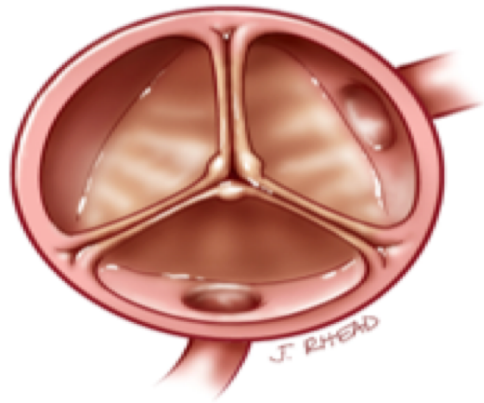

AORTIC VALVE STENOSIS

Open

Closed

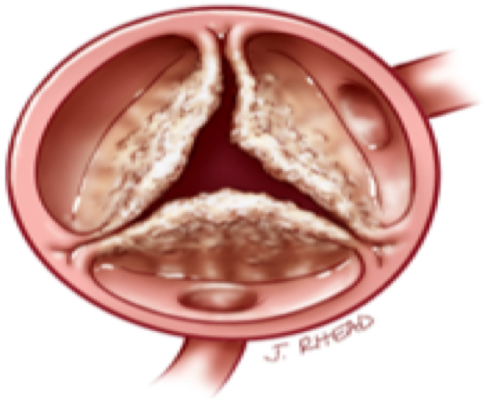

Etiology

- **Degenerative calcific AS (Most common in elderly)**
  - ✓ A degenerative condition caused by inflammation and progressive calcificationwhich limits movement of the aortic valve.
  - ✓ Most common cause (80%).
  - ✓ Affects patients later in life (>65).
  - ✓ Risk factors: hypercholesterolaemia, hypertension, smoking and diabetes.

- **Congenital: Bicuspid aortic valve (Most common in young)**
  - ✓ The most common congenital abnormality of the heart occurring with a frequency of 1-2%, with males more commonly affected.
  - ✓ Valves predisposed to becoming stenotic.
  - ✓ Stenosis tends to appear at a younger age (<65).

- **Rheumatic**
- **CTD e.g Rheumatoid**

Differential Diagnosis

- Supravalvular stenosis
- Subvalvular stenosis
- Hypertrophic cardiomyopathy (HCM)

Degenerative

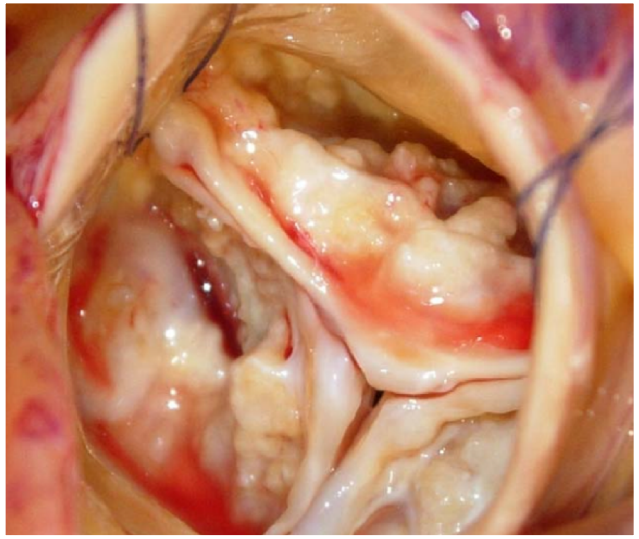

Bicuspid

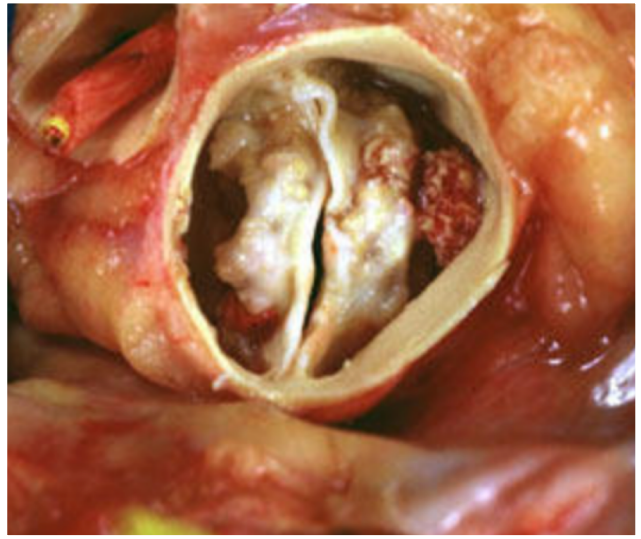

Rheumatic

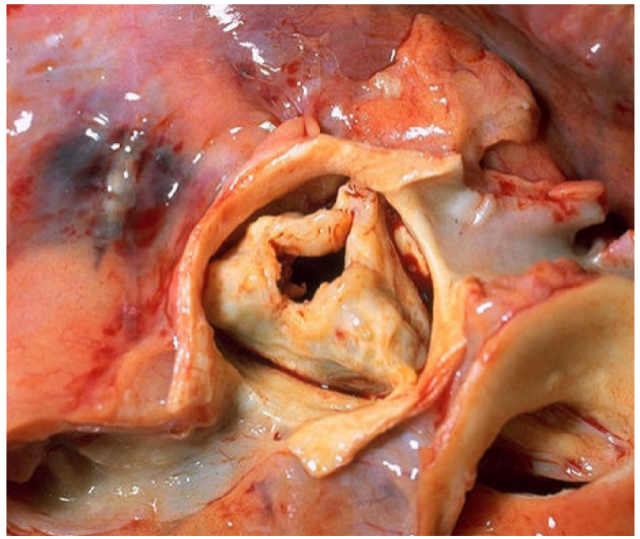

Nouf Alanazi 2019

Bicuspid Aortic Valve

- 1-2% of the population
- 70-80% fusion of the right & left coronary and non-coronary leaflets
- 20-30% fusion of the right & non-coronary leaflets
- Fusion of the non coronary & left coronary leaflets is rare
- One commissure

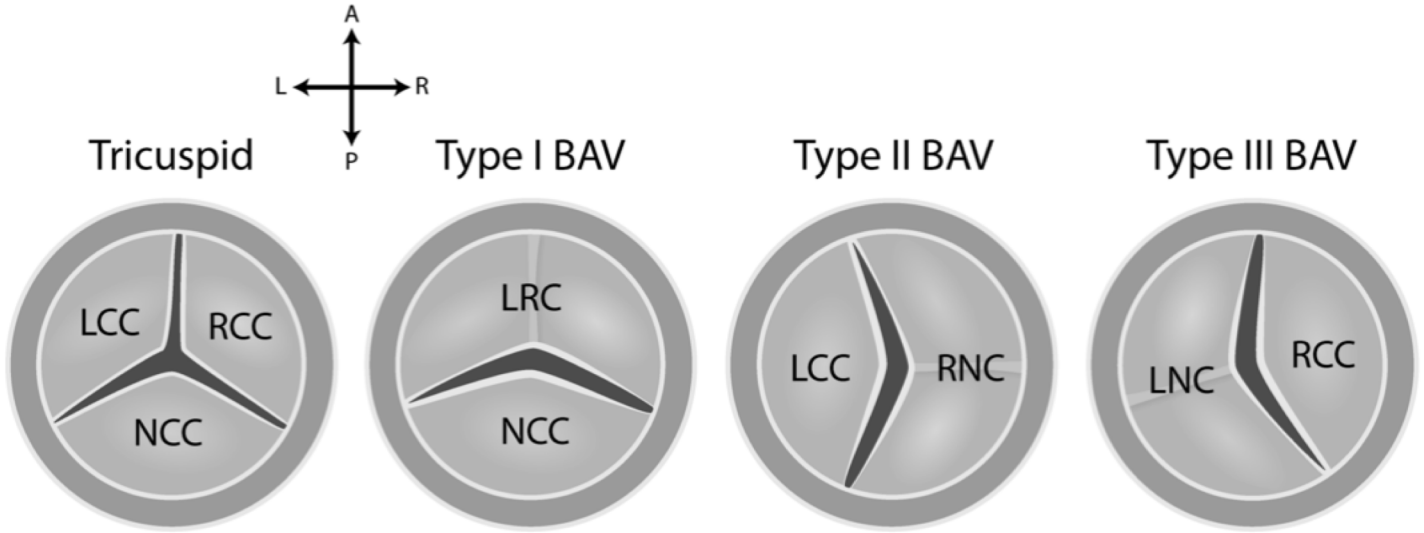

Nouf Alanazi 2019

Bicuspid Aortic Valve

- Associated aortopathy (Medial degeneration) : aneurysm, dissection.
- Requires annual imaging if aorta > 4.5 cm
- Beta blockers in absence of significant AI

Asc A replacement if:

✓ Aorta > 5.5 cm

✓ Aorta > 4.5 cm if AVR indicated

✓ Aorta >5 cm with risk factors for dissection e.g FHX or progression of >0.5 cm/y

Nouf Alanazi 2019

Stages of AS

Stage	Definition	Valve Anatomy	Valve Hemodynamics	Hemodynamic Consequences	Symptoms
A	At risk of AS	• Bicuspid aortic valve (or other congenital valve anomaly) • Aortic valve sclerosis	• Aortic V_{max} <2 m/s	• None	• None
B	Progressive AS	• Mild-to-moderate leaflet calcification of a bicuspid or trileaflet valve with some reduction in systolic motion or • Rheumatic valve changes with commissural fusion	• Mild AS: Aortic V_{max} 2.0–2.9 m/s or mean ΔP <20 mm Hg • Moderate AS: Aortic V_{max} 3.0–3.9 m/s or mean ΔP 20–39 mm Hg	• Early LV diastolic dysfunction may be present • Normal LVEF	• None
C: Asymptomatic severe AS					
C1	Asymptomatic severe AS	• Severe leaflet calcification or congenital stenosis with severely reduced leaflet opening	• Aortic V_{max} ≥4 m/s or mean ΔP ≥40 mm Hg • AVA typically is ≤1.0 cm^2 (or AVAi ≤0.6 cm^2/m^2) • Very severe AS is an aortic V_{max} ≥5 m/s or mean ΔP ≥60 mm Hg	• LV diastolic dysfunction • Mild LV hypertrophy • Normal LVEF	• None: Exercise testing is reasonable to confirm symptom status
C2	Asymptomatic severe AS with LV dysfunction	• Severe leaflet calcification or congenital stenosis with severely reduced leaflet opening	• Aortic V_{max} ≥4 m/s or mean ΔP ≥40 mm Hg • AVA typically ≤1.0 cm^2 (or AVAi ≤0.6 cm^2/m^2)	• LVEF <50%	• None

Pathophysiology

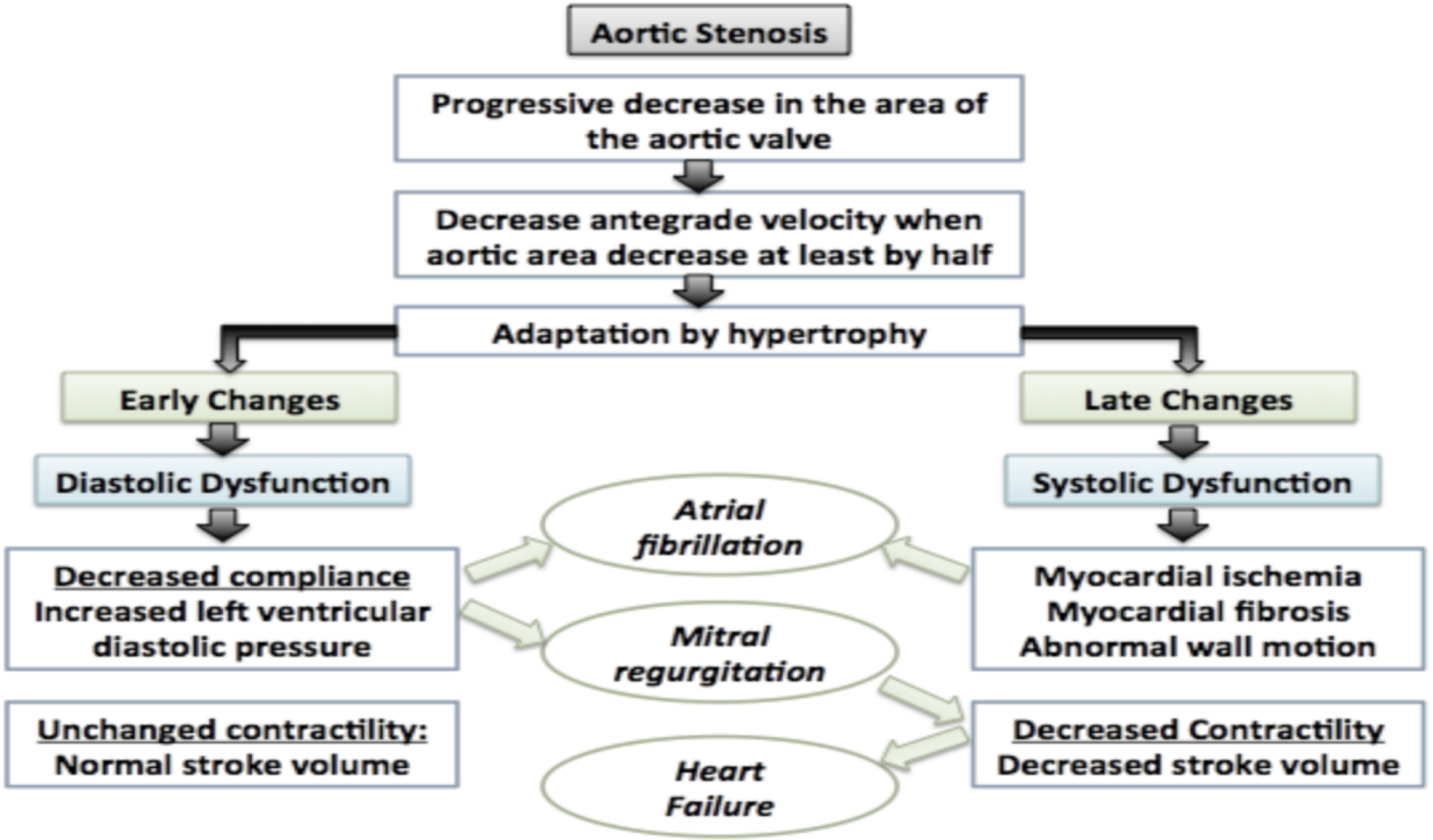

Nouf Alanazi 2019

Natural history

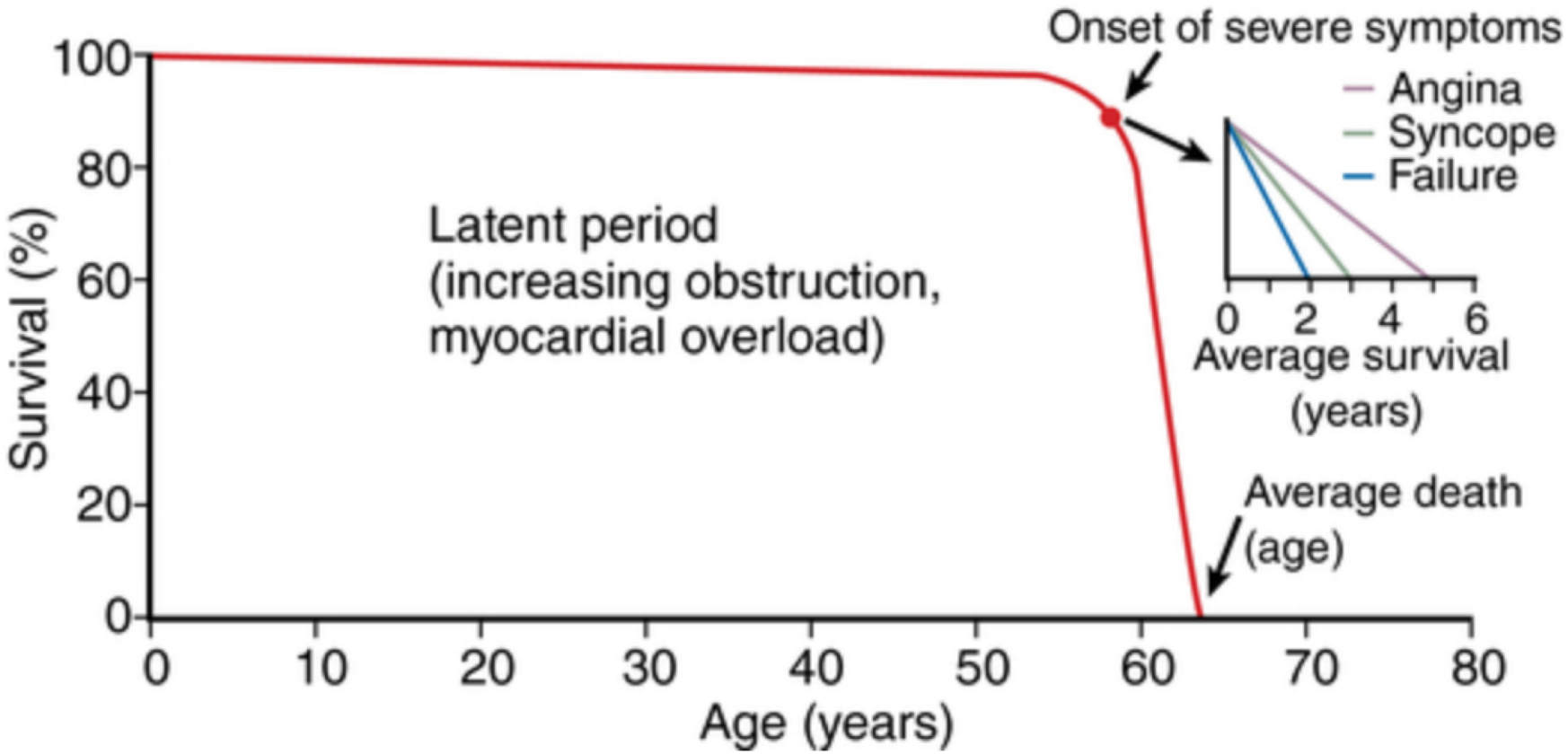

Nouf Alanazi 2019

Grades of AS

	Aortic sclerosis	Mild AS	Moderate AS	Severe AS
Peak Velocity (m/s)	≤ 2.5 m/s	2.6– 2.9	3.0 – 4.0	**≥ 4.0**
Mean gradient (mmHg)	-	< 20	20 - 40	**≥ 40**
AVA (cm2)	-	>1.5	1.0 – 1.5	**< 1**
Indexed AVA (cm2/m2)	-	> 0.85	0.60 – 0.85	**< 0.6**

Nouf Alanazi 2019

Clinical Presentation (Symptoms)

Classical triad:
1. Syncope (exertional)
2. Angina
3. Dyspnoea

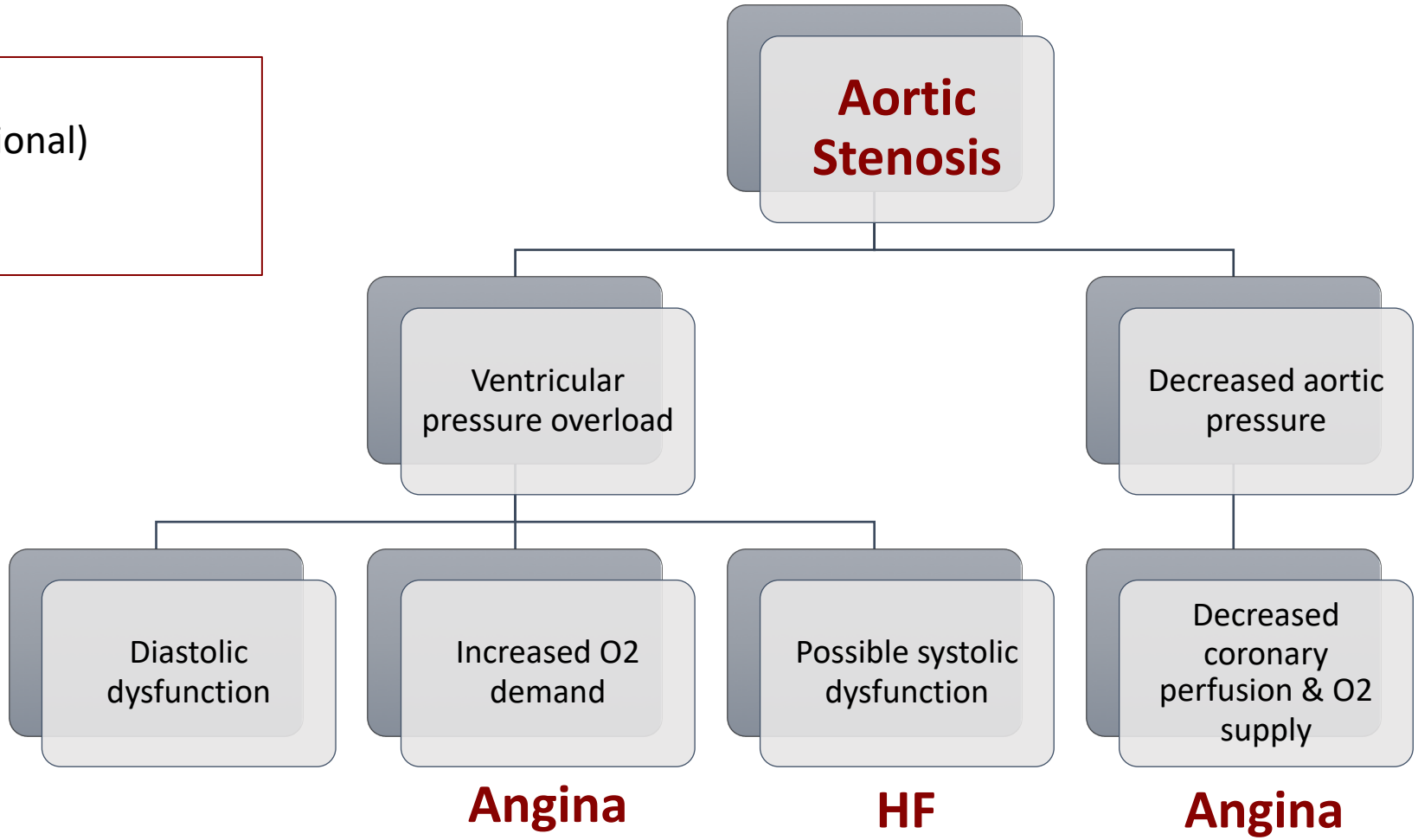

Syncope

Nouf Alanazi 2019

Physical exam & clinical signs:

- **Pulse:**

✓ Low volume, slow-rising, delayed upstroke carotid pulse ***(pulsus parvus et tardus)***

✓ Brachioradial delay

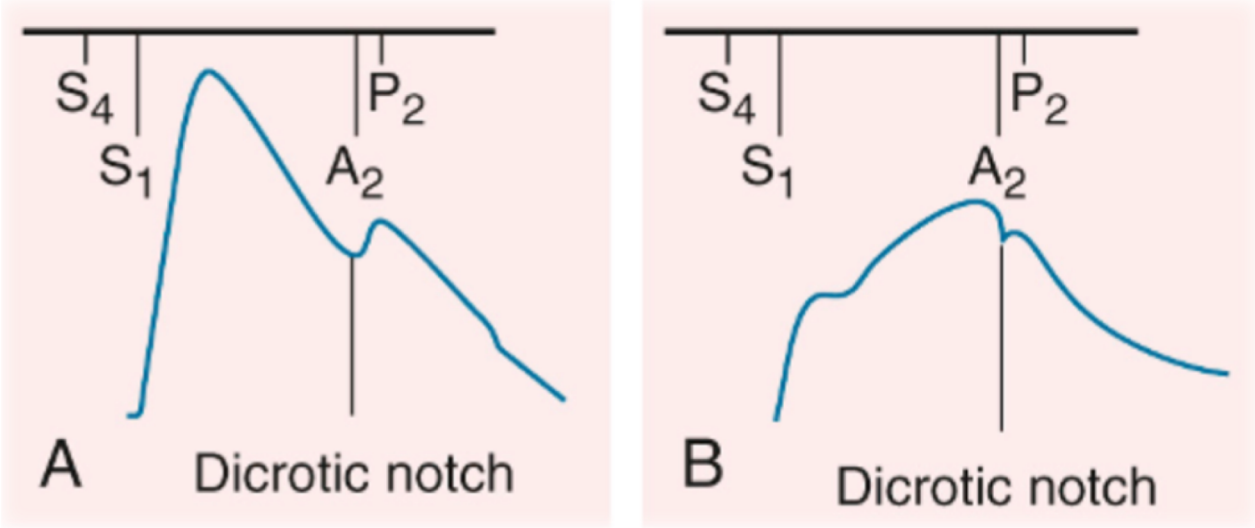

Physical exam & clinical signs:

- **BP:** Narrow pulse pressure
- **Apex:** Sustained beat
- **HS:** Soft S2, reversed splitting, single S2.
- **Extra-HS:** S4

Physical exam & clinical signs:

- **Murmurs:**

✓ Loud mid- to late-peaking ejection systolic murmur in the right intercostal space radiating to carotids

✓ Gallavardin phenomenon:

High-pitched musical components of the murmur of aortic stenosis heard at the apex

HS & Murmur of AS

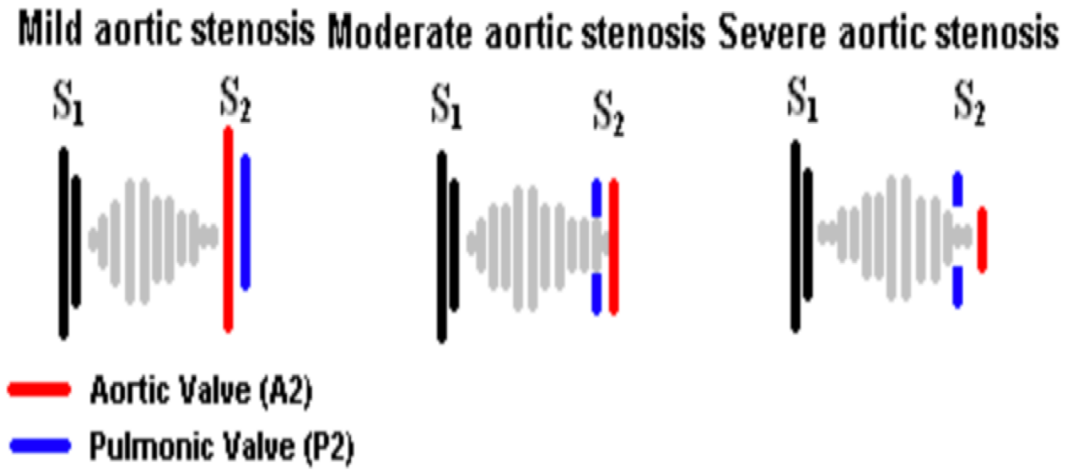

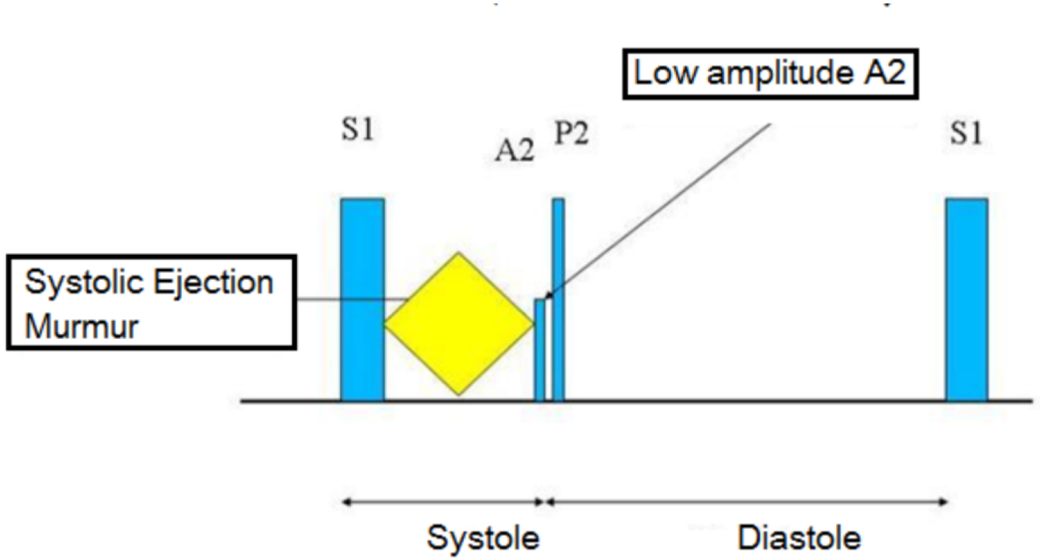

Nouf Alanazi 2019

Investigations & Diagnosis

- Bedside assessment & observation of syndromic features
- Blood pressure
- ECG
  - ✓ Left ventricular hypertrophy (deep S-waves in V1 and V2, tall R-waves in V5 and V6) & strain pattern
  - ✓ Normal axis or LAD
  - ✓ LAE

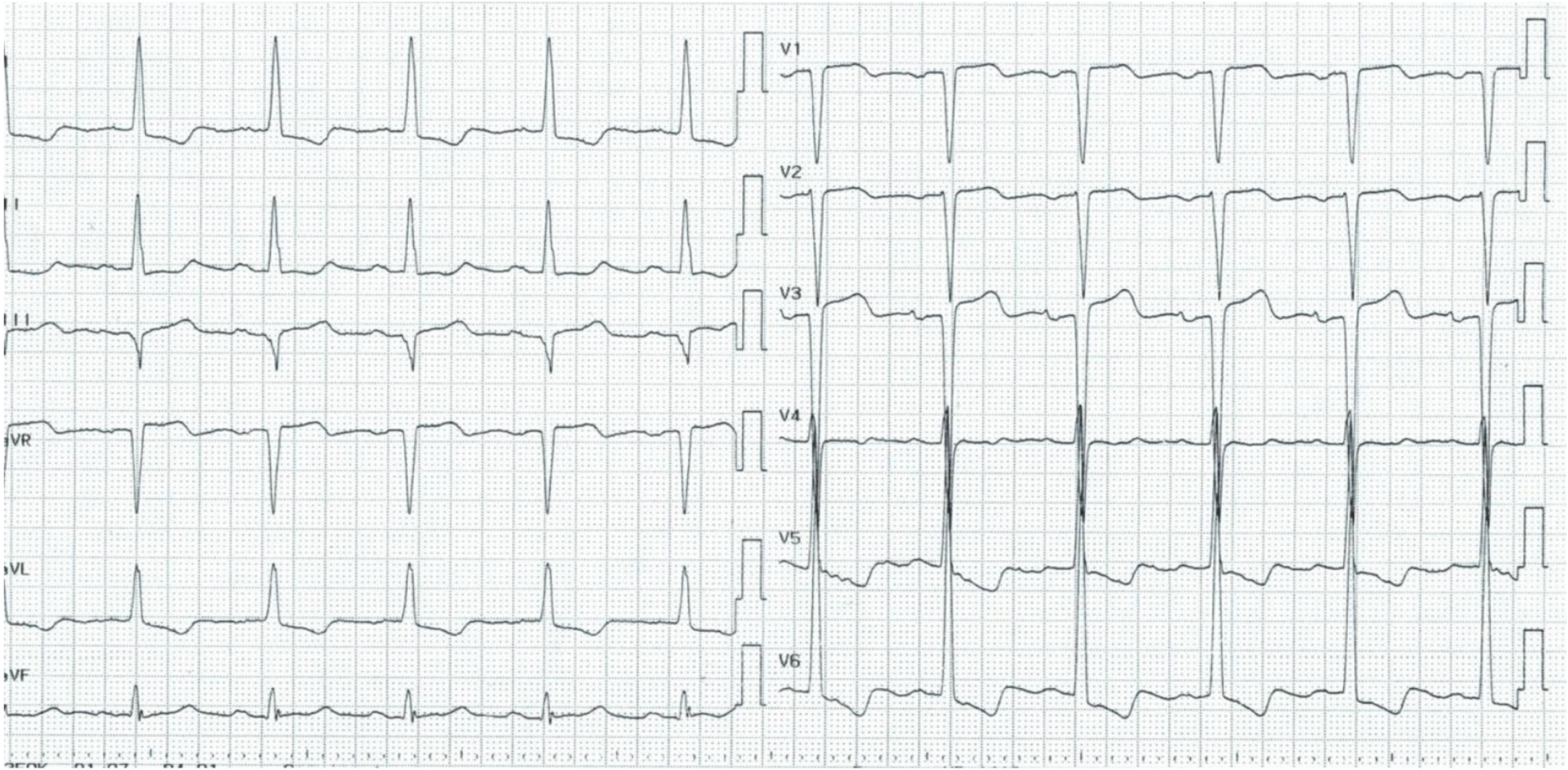
V1
V2
V3
V4
V5
V6

Investigations & Diagnosis

Blood tests:

- CBC
- U&Es
- Lipid profile
- Coagulation profile

Imaging:

- Echocardiogram
  - Allows assessment the valve area, ejection fraction and ventricular hypertrophy, see below.
- CXR
  - Typically demonstrates a small heart; cardiomegaly occurs if heart failure develops.
  - Dilated ascending aorta.

Special:

- Cardiac MRI
- Cardiac catheterisation
- ECG exercise stress testing
  - May be used in asymptomatic patients. A positive test may be indicated by the onset of symptoms, ECG changes, or an abnormal BP response.

CXR

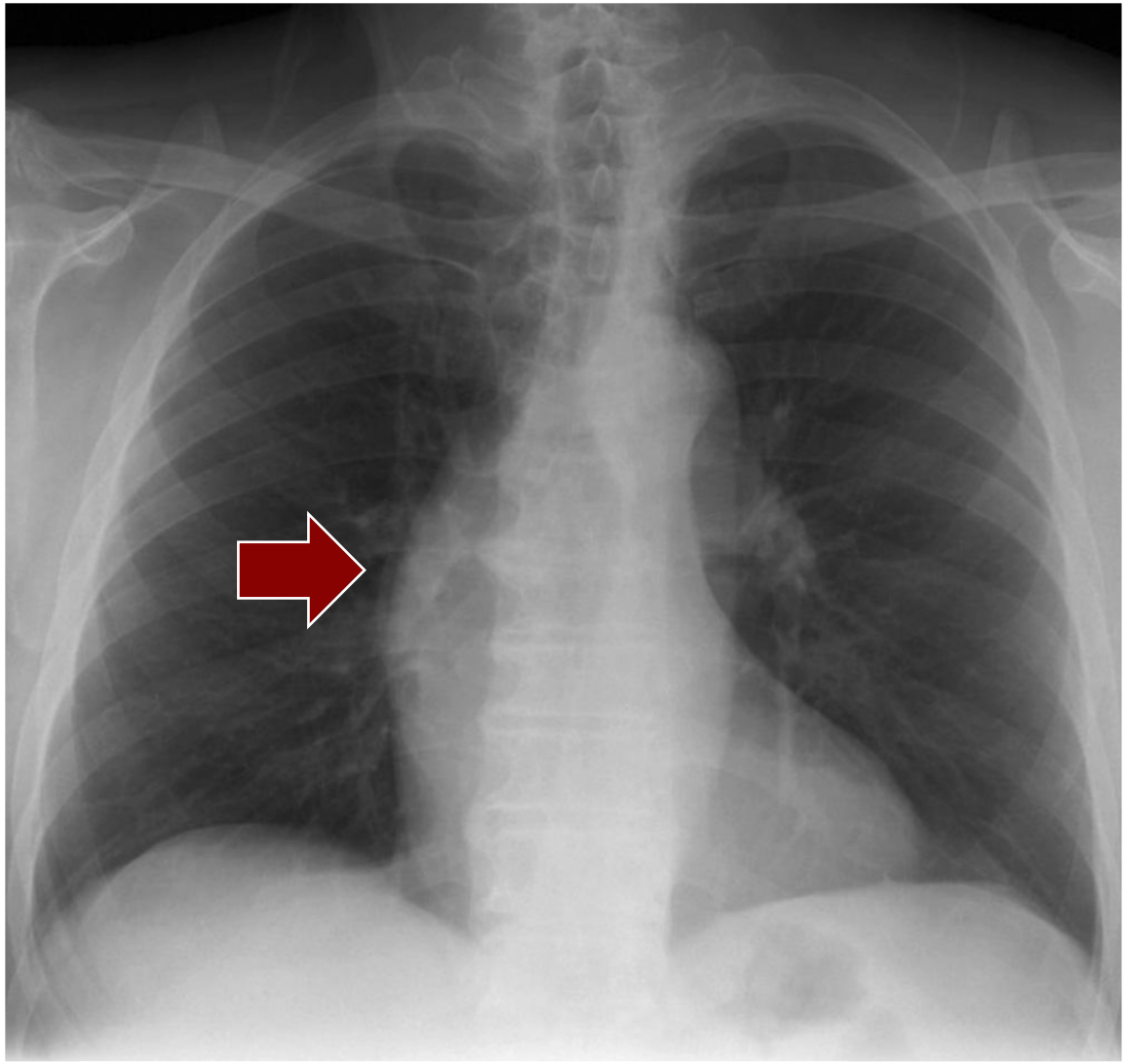

Echo

Nouf Aldhazi 2019

Management

Depends on:

- Severity of the stenosis
- Presence of symptoms

Severe symptomatic cases need surgical (SAVR) or percutaneous (TAVR) intervention

HTN is common (Cautious use of vasodilators due to afterload reduction)

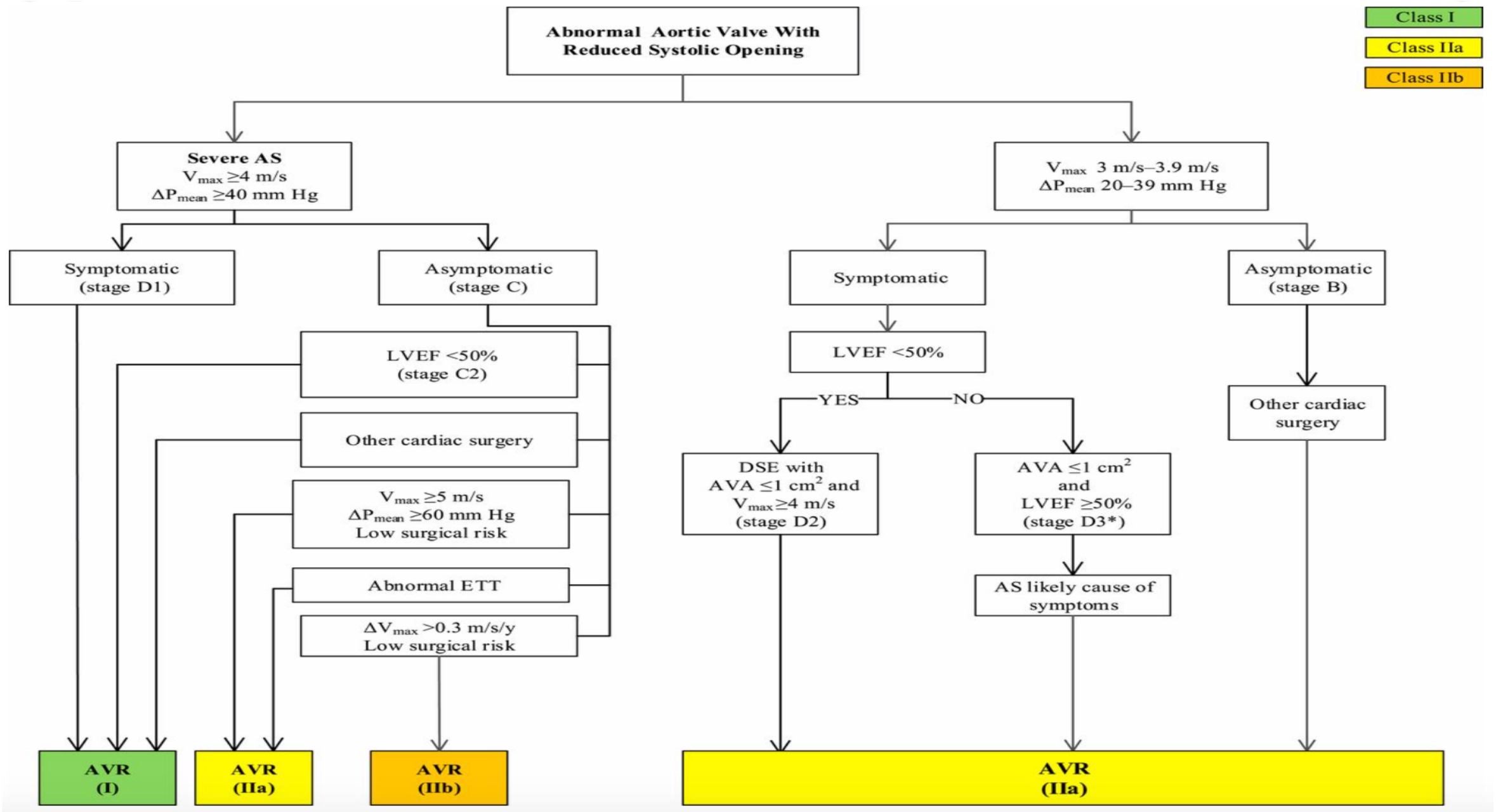

Nouf Alanazi 2019

TAVR
Transfemoral (TF) and Transapical (TA)

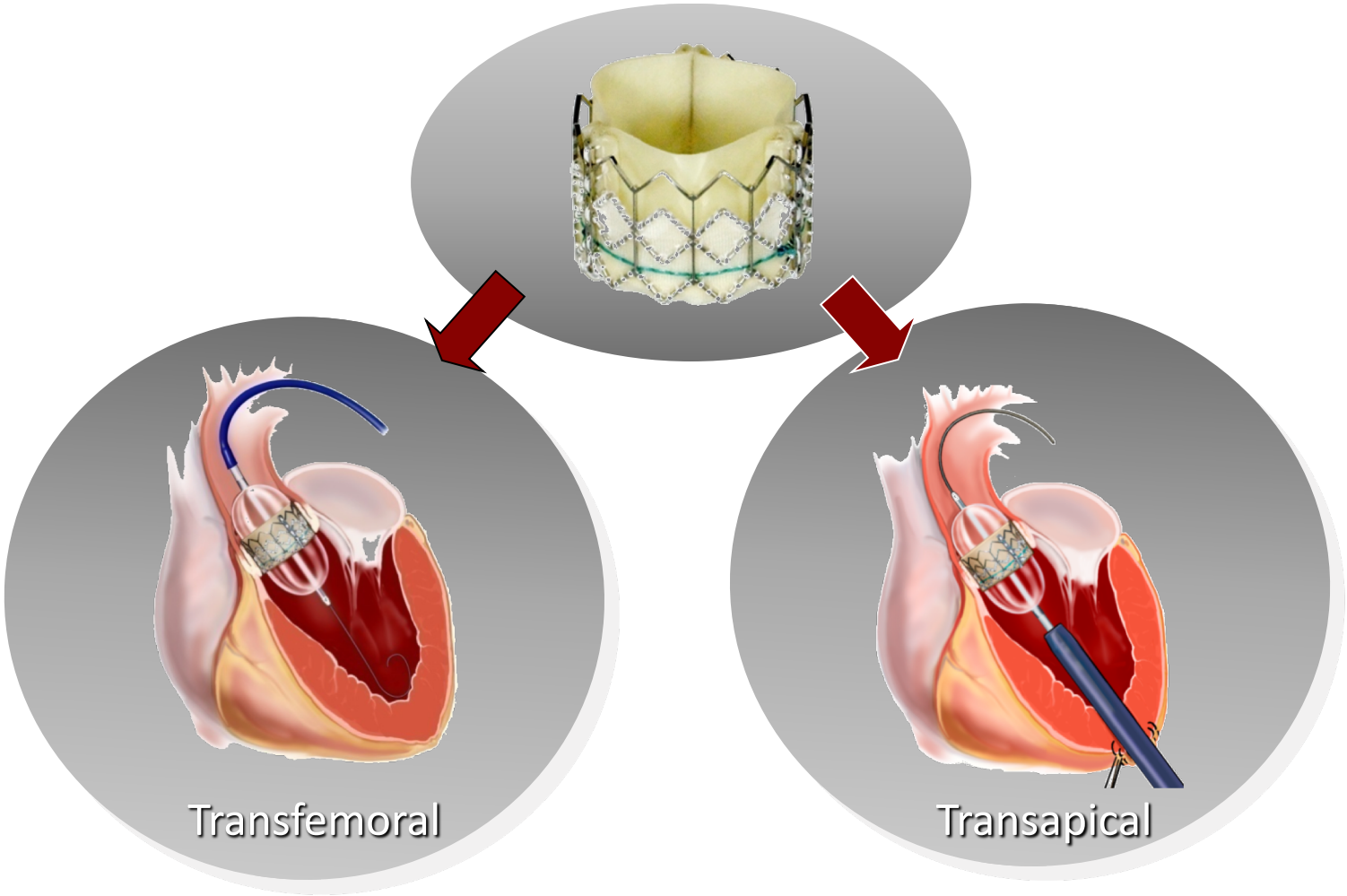

Nouf Alanazi 2019

SAVR vs TAVR

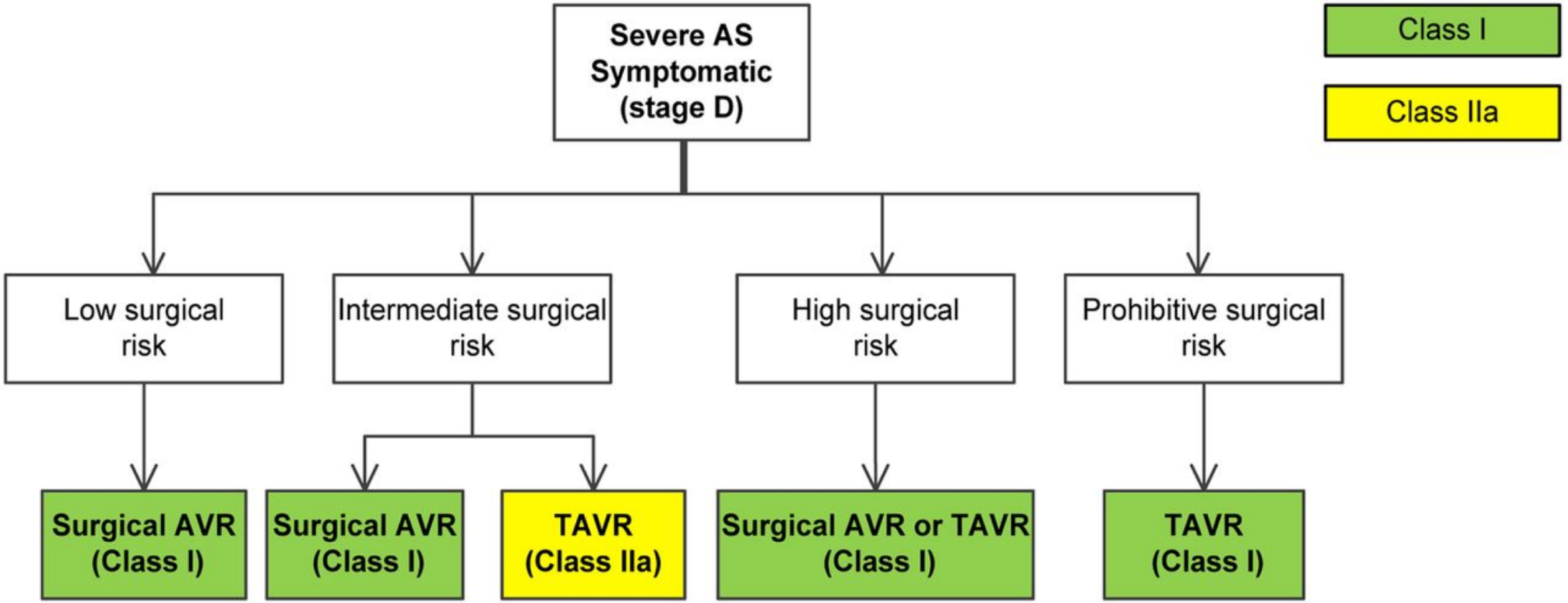

Nouf Alanazi 2019

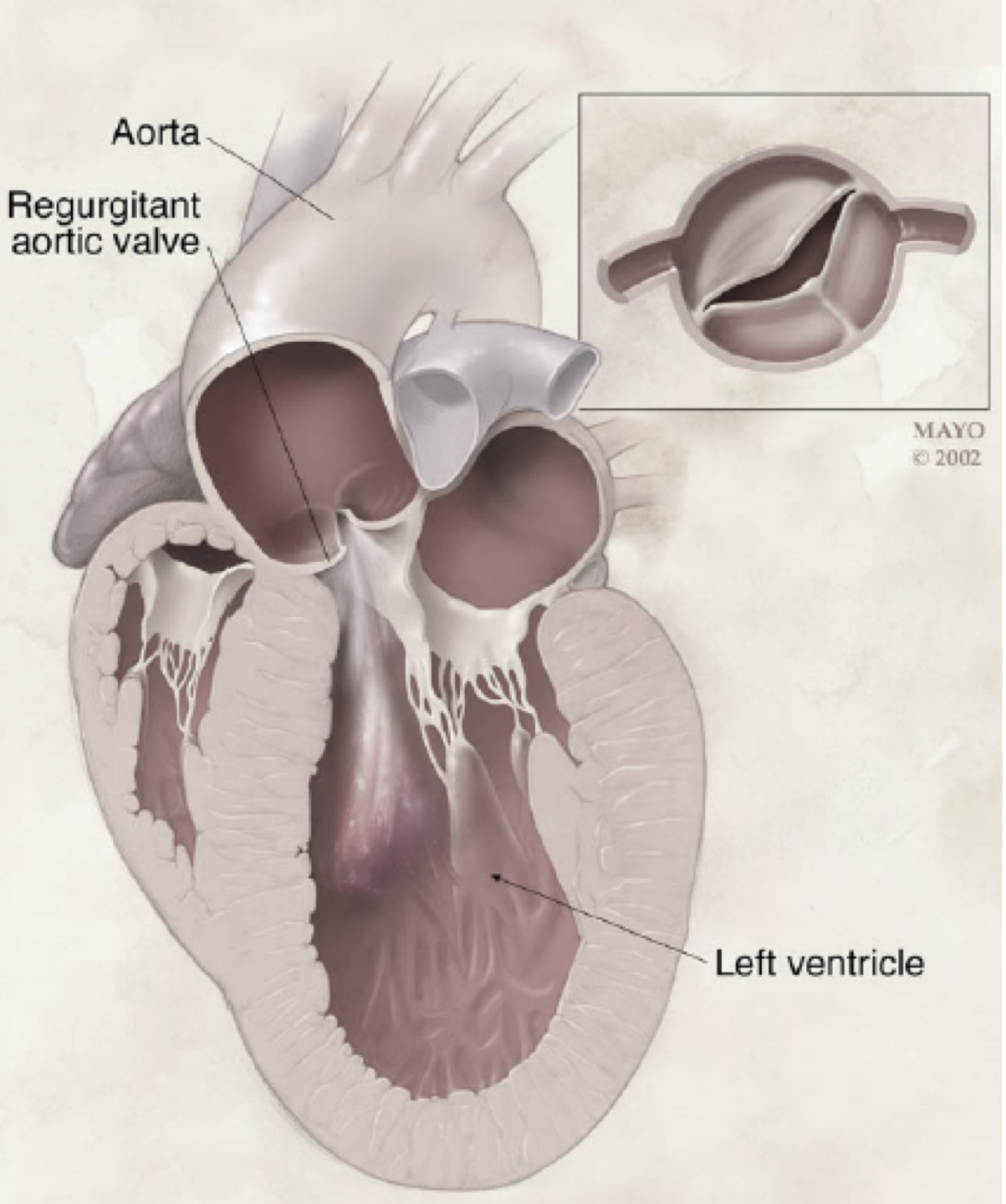

Aortic Regurgitation/Insufficiency AR/AI

Nouf Alanazi 2019

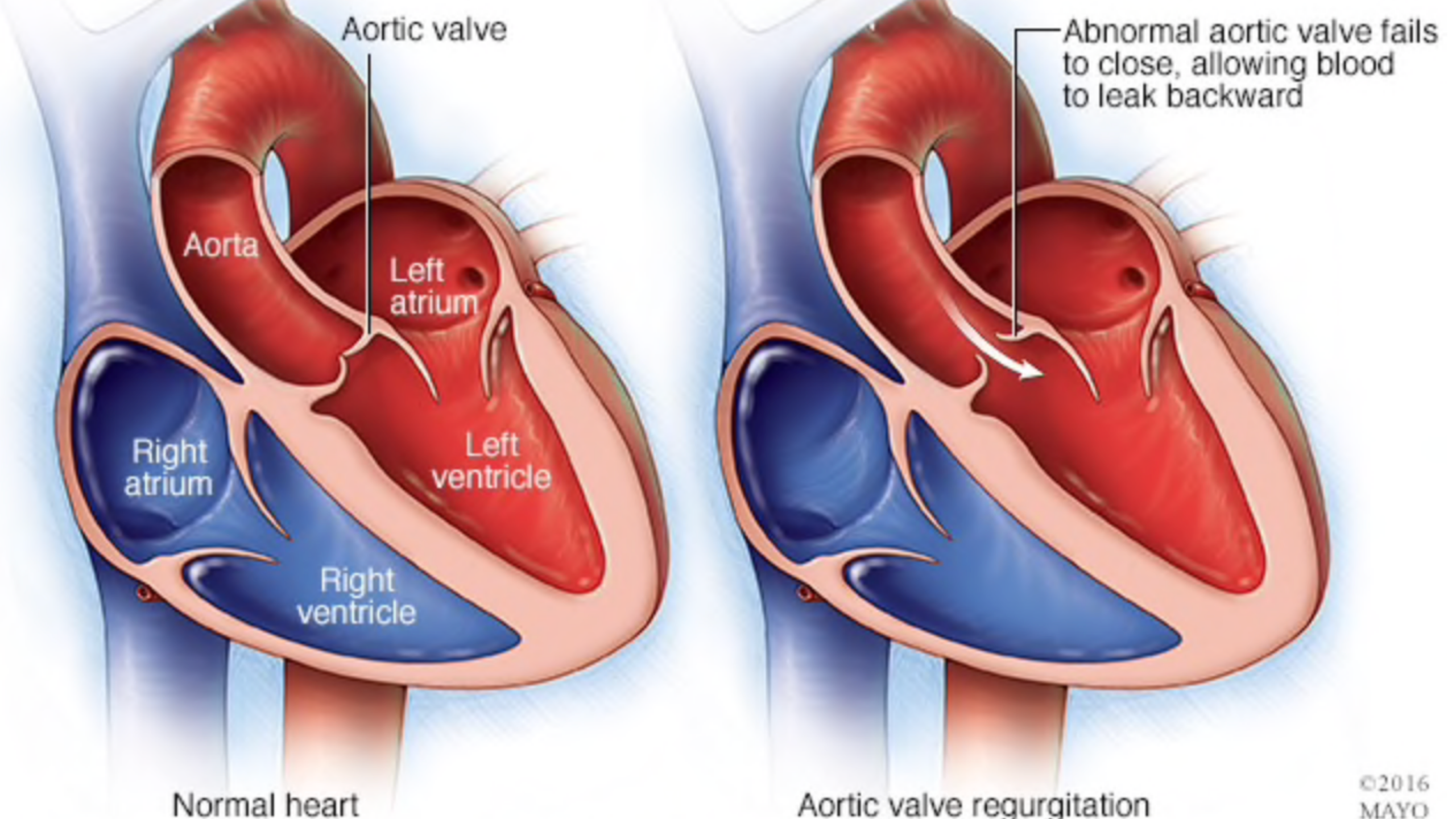
Aortic valve
Aorta
Left atrium
Right atrium
Left ventricle
Right ventricle
Abnormal aortic valve fails to close, allowing blood to leak backward
Normal heart
Aortic valve regurgitation
©2016 MAYO

Aortic Regurgitation/Insufficiency (AR/AI)

- Aortic regurgitation results from an incompetent aortic valve causing a regurgitant flow of blood in diastole.
- Usually presents 4th-6th decades of life.
- Affects males 3 times more commonly than women.
- Severe disease is seen in < 1% of the population.
- The most common causes are degenerative disease & congenital bicuspid valve.

Etiology

Valvular (aortic valve cusps)	Non-valvular (aortic root)
Infectious: IE, RF	Marfan
Congenital: BAV, Marfan	syphilis
Inflammatory: SLE, RA, Behcet	Ankylosing spondylitis
Degenerative: Myxomatous AV, calcific AV	Idiopathic aortitis
Trauma	Ehler danlos syndrome
Postaortic valvuloplasty	Aortic dissection
Drug induced: Fenfluramine	Trauma
	VSD
Acute	Chronic
AD	Calcific degeneration
IE	Aortic root dilatation
Rupture of AV leaflet (trauma)	RF
PV dysfunction	Autoimmune diseases/CTD

Nouf Alanazi 2019

Pathophysiology

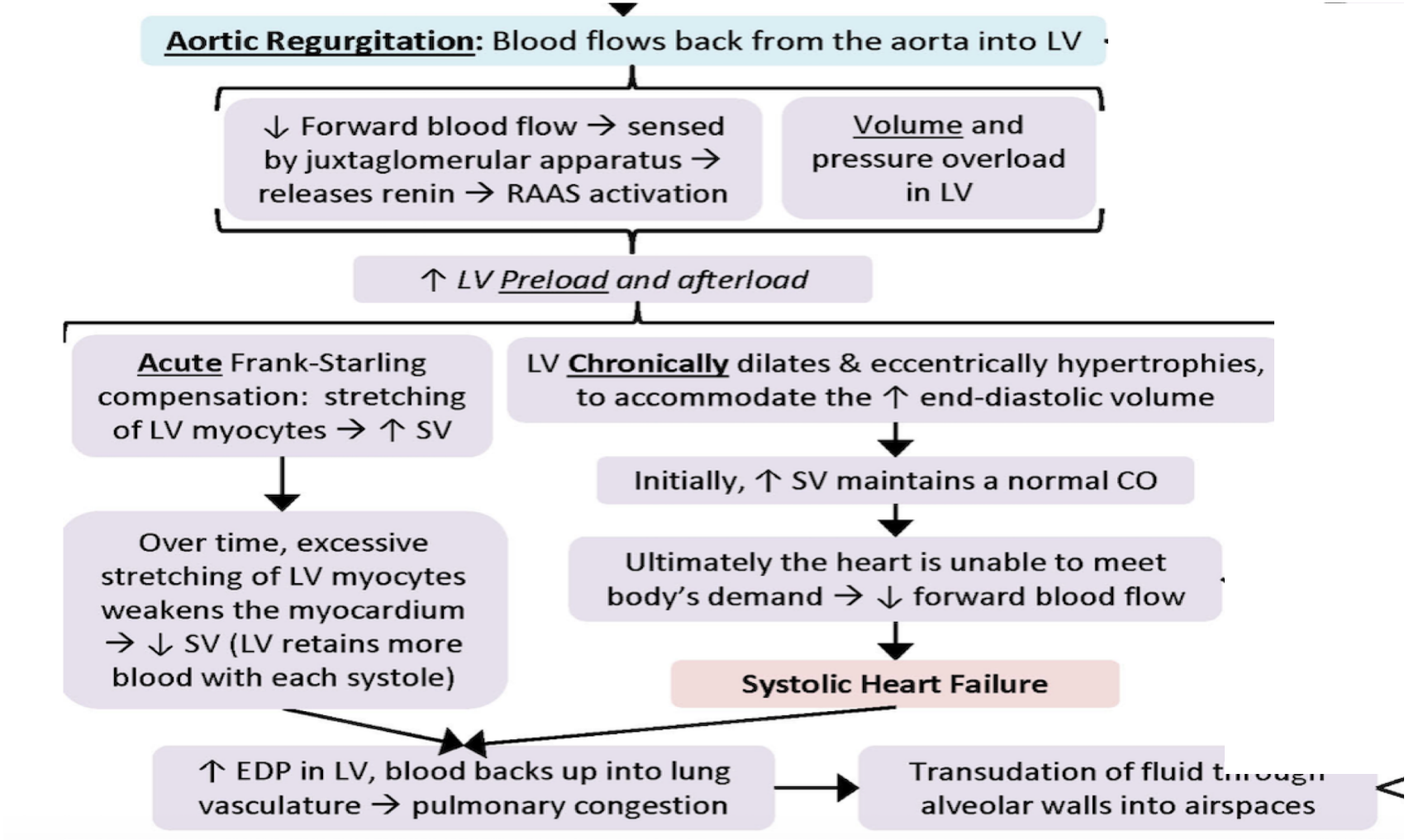

Nouf Alanazi 2019

Acute AI

- A medical emergency
- The compensatory changes seen in chronic disease do not have time to develop
- *Presents with pulmonary oedema & cardiogenic shock.*

- **2 Main consequences:**

1. Reduced coronary flow - the coronaries fill predominantly during diastole, regurgitant flow at this time reduces filling. Results in angina or in severe cases myocardial ischaemia.
2. Increased EDP- causes increased pulmonary pressures with resulting pulmonary oedema and dyspnoea. In severe cases, cardiogenic shock may occur.

Chronic AI

- Patients may remain asymptomatic for many decades.

- **Develops slowly with compensatory changes:**
  - ✓ Increase in the left ventricular end-diastolic volume (essentially the preload).
  - ✓ Increased stroke volume compensating for regurgitant flow supported by the ventricular hypertrophy to maintain ejection fraction, with a greater preload leading to greater contractility *(frank- starling law)*
  - ✓ Eventually further increases in preload cannot be met by greater contractility and heart failure develops.

Clinical Presentation (Acute AI)

Symptoms	Signs
Dyspnea	Cardiogenic shock & Heart failure: Hypotension, tachycardia, elevated JVP…etc
Chest pain	Peripheral signs of chronic AI are usually absent
Symptoms of low cardiac output & HF	S3+ Murmur is early, short, faint and may be absent

Clinical Presentation (Chronic AI)

Symptoms	Signs
Dyspnea	**Pulse:** Pulsus Bisferience/ collapsing/ water hammer
Chest pain	**BP:** Elevated with wide pulse pressure
	Apex: Diffuse & Displaced
	HS: Soft S1 & S2
	Murmurs: Decrescendo early Diastolic & Austin flint murmur

Pulsus Bisferiens

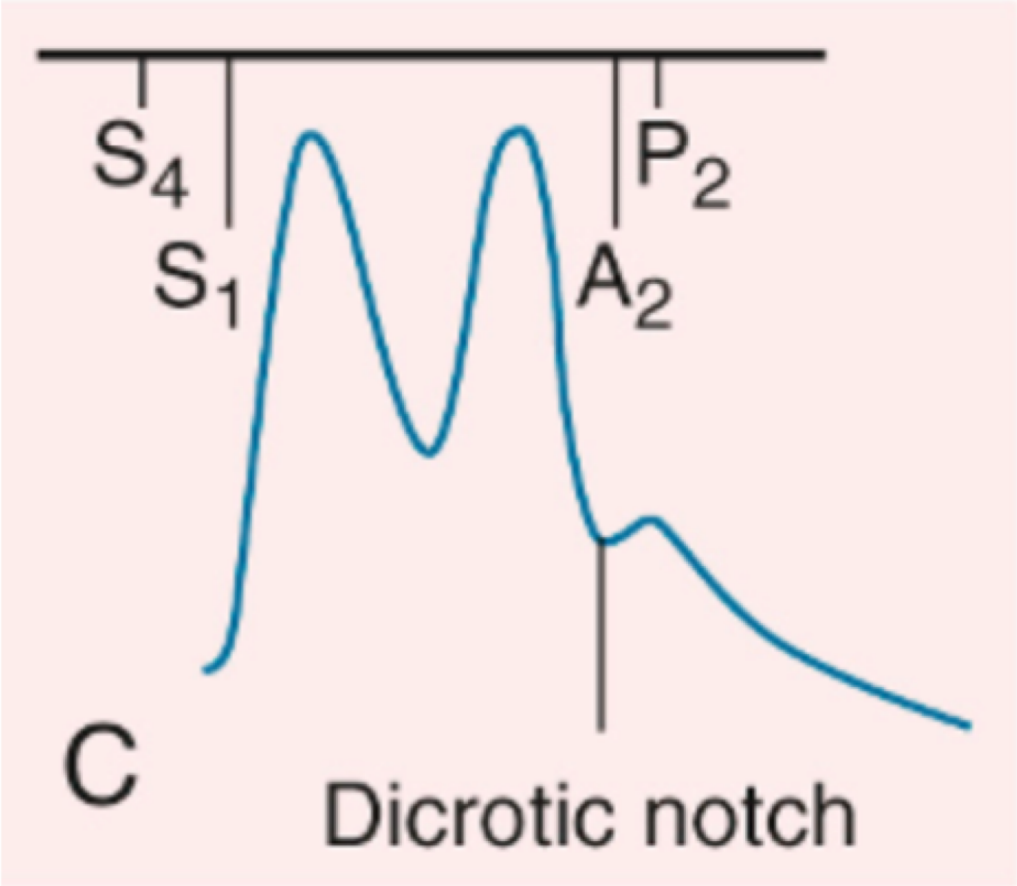

Water- hammer /collapsing pulse

(Large volume sudden collapsing pulse)

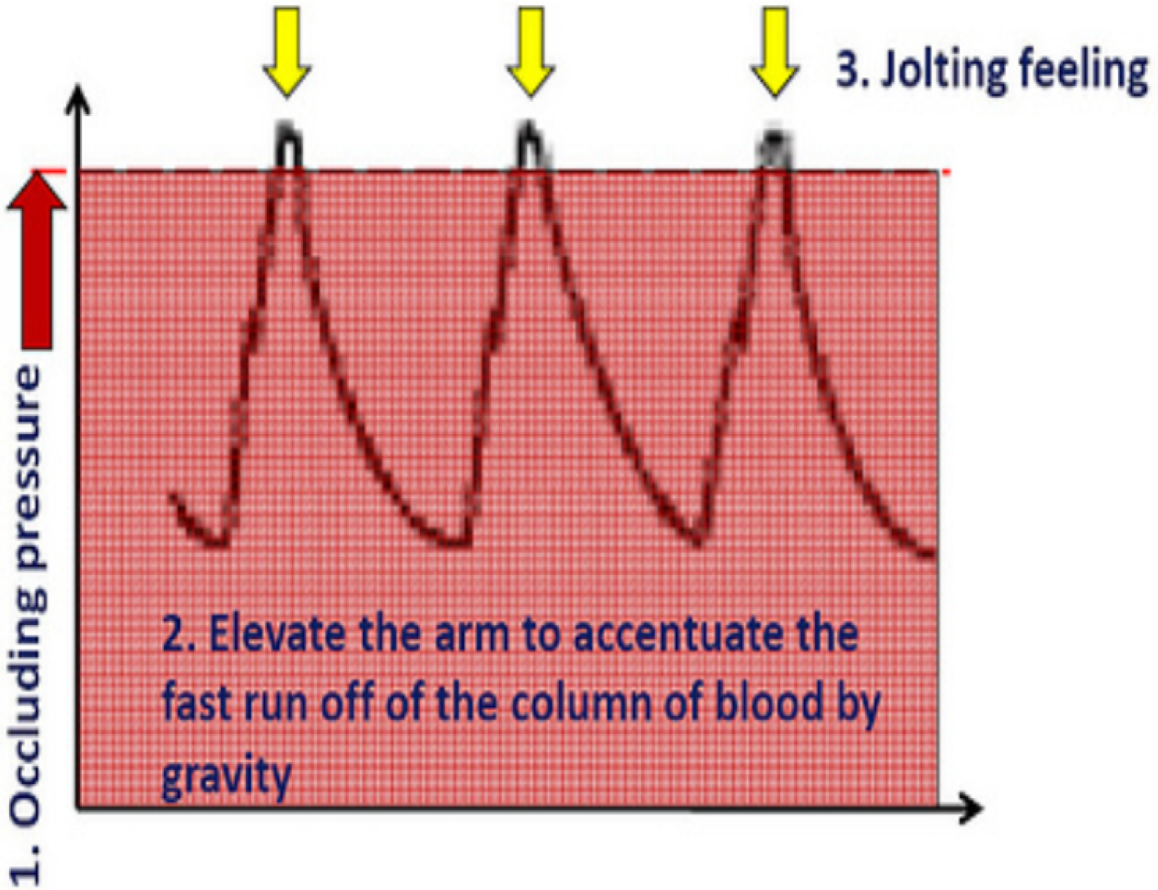

Nouf Alanazi 2019

Decrescendo Diastolic murmur

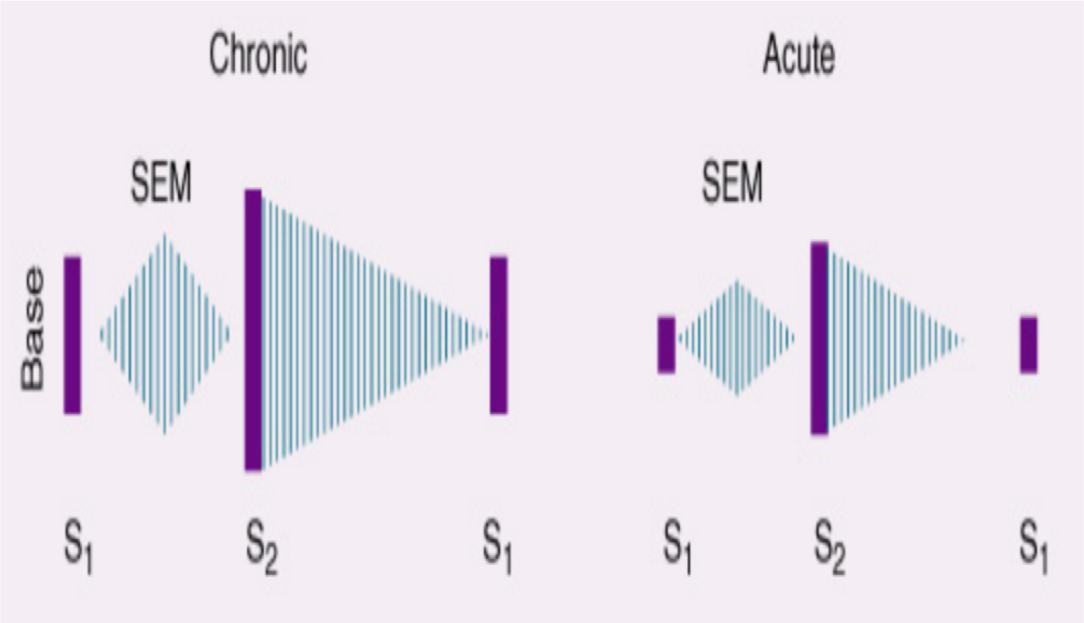

Austin- flint murmur

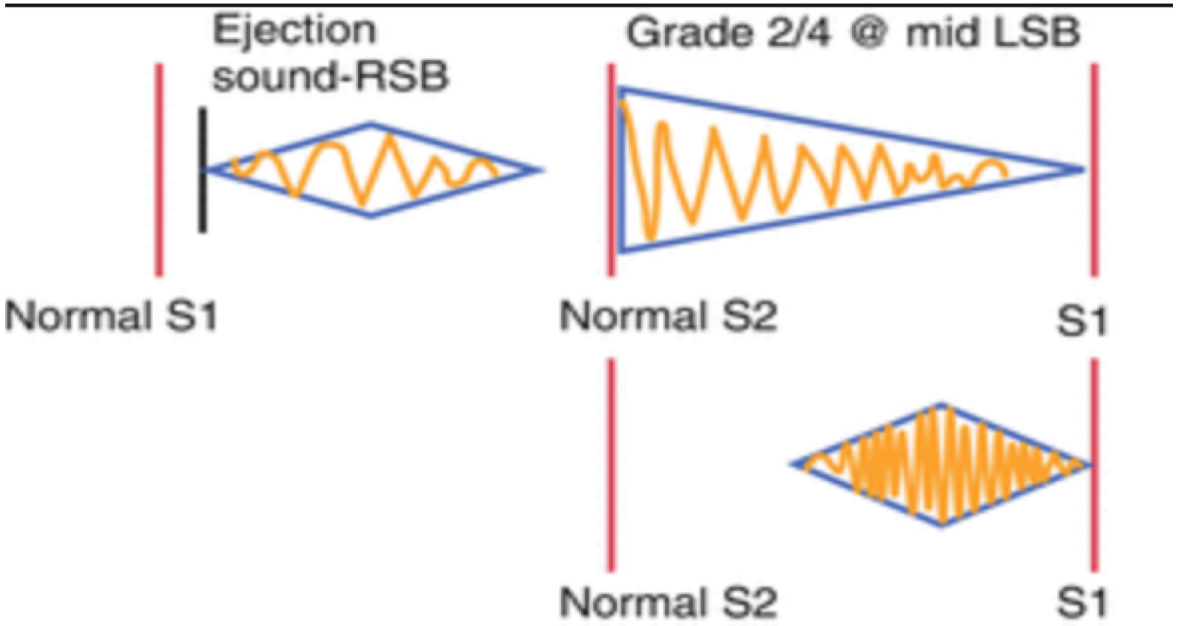

Nouf Alanazi 2019

Peripheral signs of AR

The relevance of these signs in clinical practice today is questionable:

- **De Musset's** - systolic nodding of the head.
- **Quincke's** - capillary pulsation of nail beds.
- **Corrigan's sign** – abrupt distension with prominent pulse then rapid collapse.
- **Traube's (pistol shot femoral)** – systolic & diastolic bruit in the femoral artery
- **Duroziez's** - systolic bruit in the FA with proximal compression and diastolic sound with distal compression using the stethoscope.
- **Müller's** - systolic pulsation of uvula.
- **Hill's sign** – SBP in legs > 20 mmHg higher than SBA in arms.

Investigations & diagnosis

- Bedside assessment & observation of syndromic features
- Blood pressure
- ECG
  - Left ventricular hypertrophy (deep S-waves in V1 and V2, tall R-waves in V5 and V6).
  - Left ventricular strain may be seen in severe disease.
- Bloods
- FBC
- U&Es
- Cholesterol
- Clotting

Investigations & diagnosis

- **Imaging**

A. Echocardiogram

  - Allows visualisation of the origin of regurgitant jet and its width, detection of aortic valve pathology and ventricular hypertrophy.

B. CXR

  - May demonstrate cardiomegaly.
  - Dilated ascending aorta.
  - Calcification may be seen.

- **Special**

  - ✓ Cardiac MRI
  - ✓ Cardiac catheterisation
  - ✓ ECG exercise stress testing

Management

- **Acute AR:**

Emergency AVR

- **Chronic AR:**

A. Medical treatment:

- Treat HTN
- ACE inhibitors/ARBs are reasonable in patients with severe symptomatic AR and/or LV dysfunction when surgery is not performed because of comorbidities.

B. Surgical treatment:

- AVR

Indications for AVR for Chronic AR

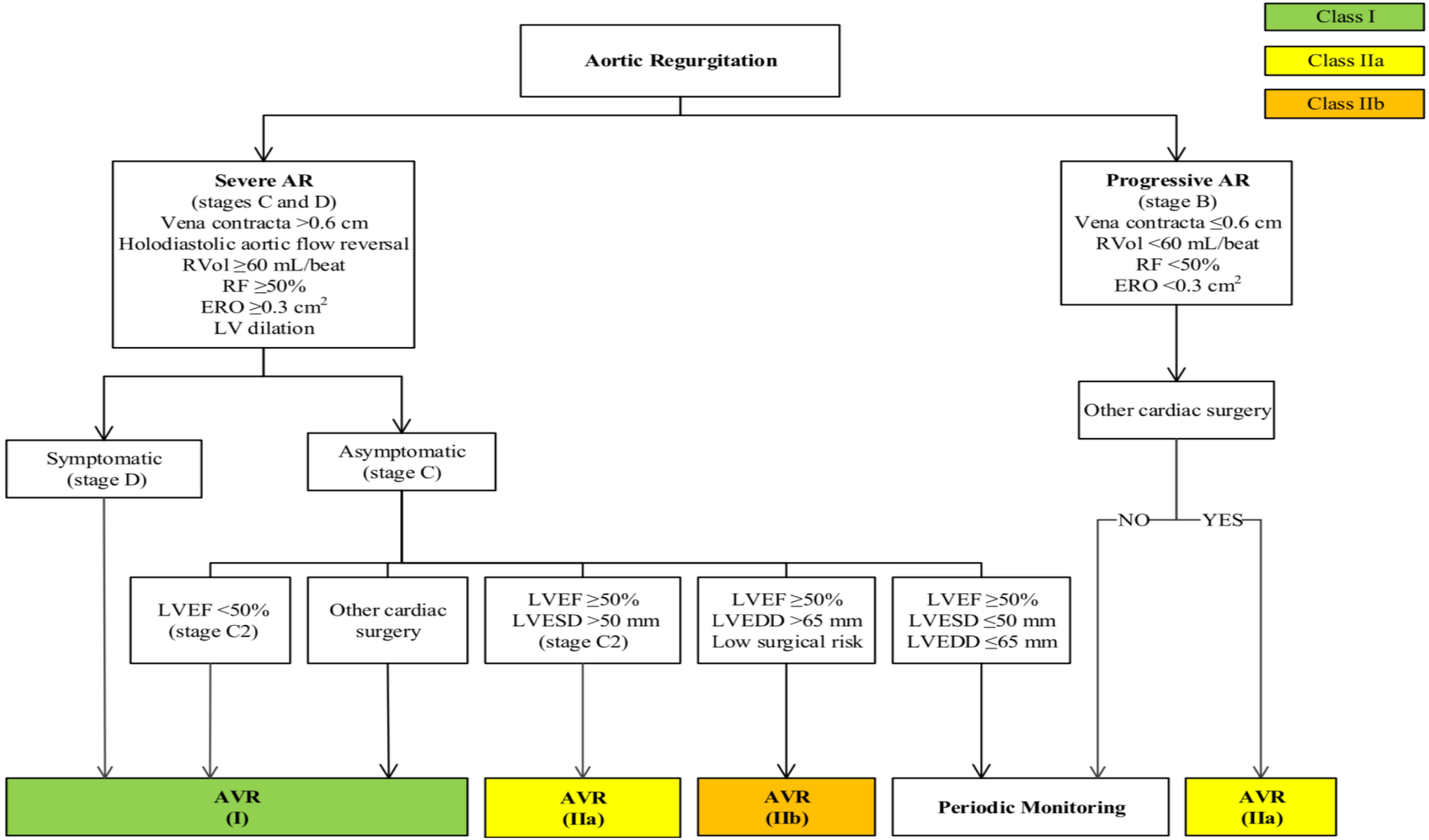

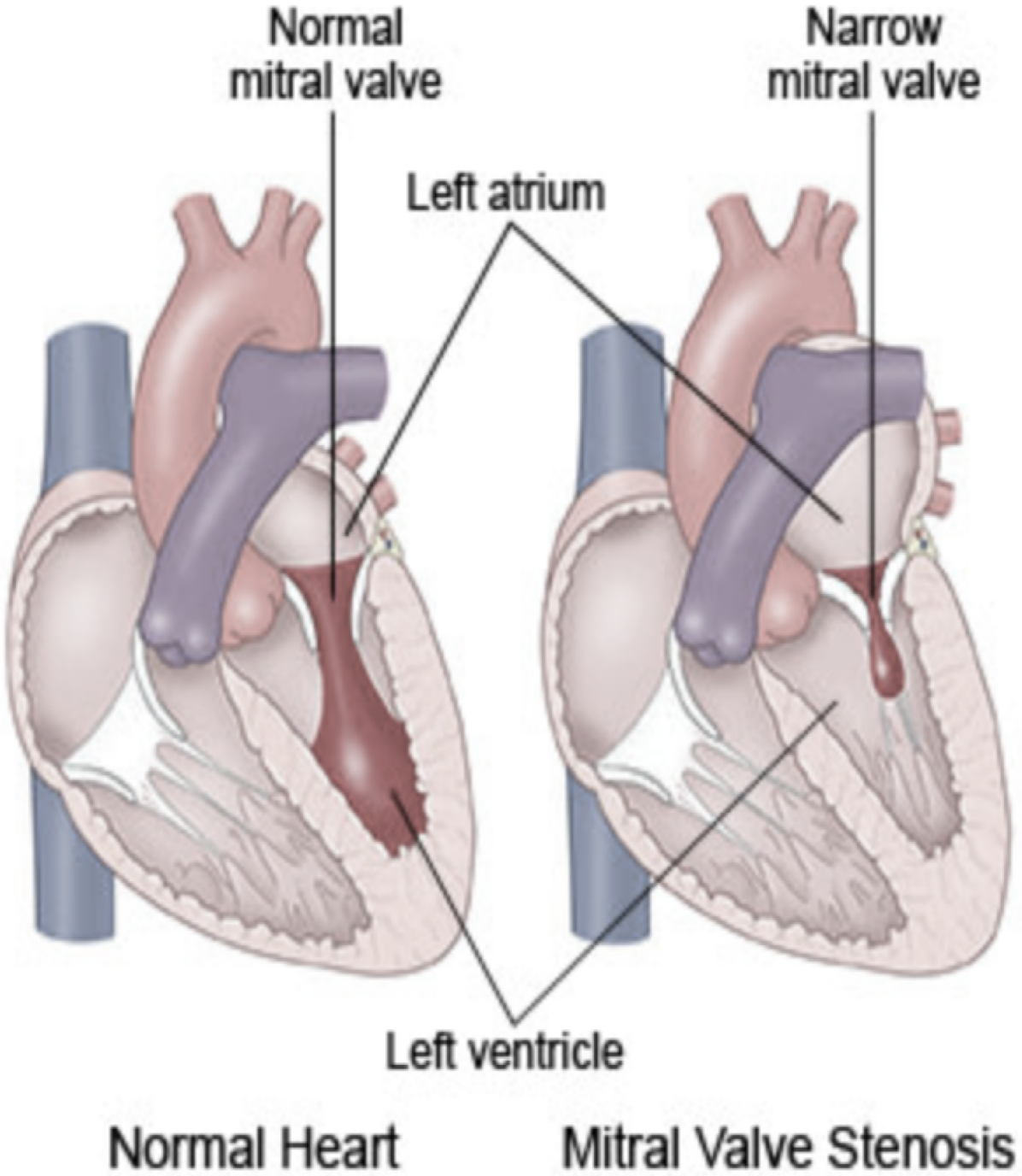

Mitral Stenosis (MS)

Nouf Alanazi 2019

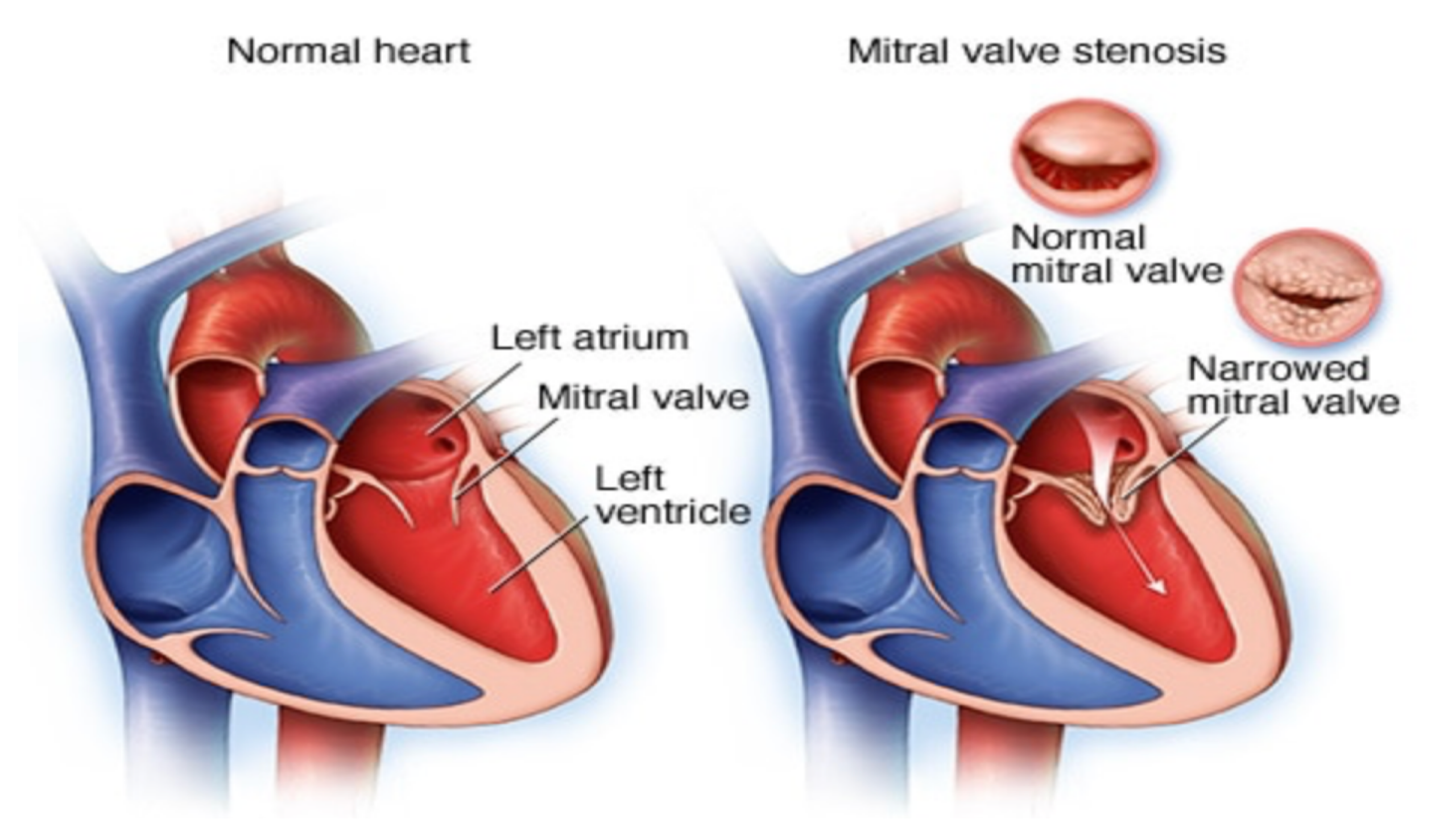
Normal heart
Left atrium
Mitral valve
Left ventricle
Mitral valve stenosis
Normal mitral valve
Narrowed mitral valve

Mitral Valve Structure

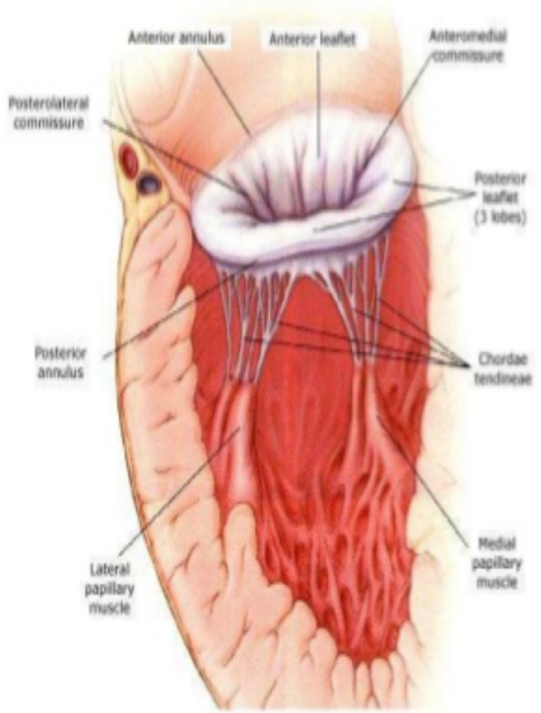

- The mitral valve connects the left atrium (LA) and the left ventricle (LV).
- The mitral valve opens during diastole to allow the blood flow from the LA to the LV.
- During ventricular systole, the mitral valve closes and prevents backflow to the LA.

The mitral apparatus is composed of

1. the left atrial wall
2. the annulus
3. the leaflets
4. the chordae tendineae
5. the papillary muscles
6. the left ventricular wall

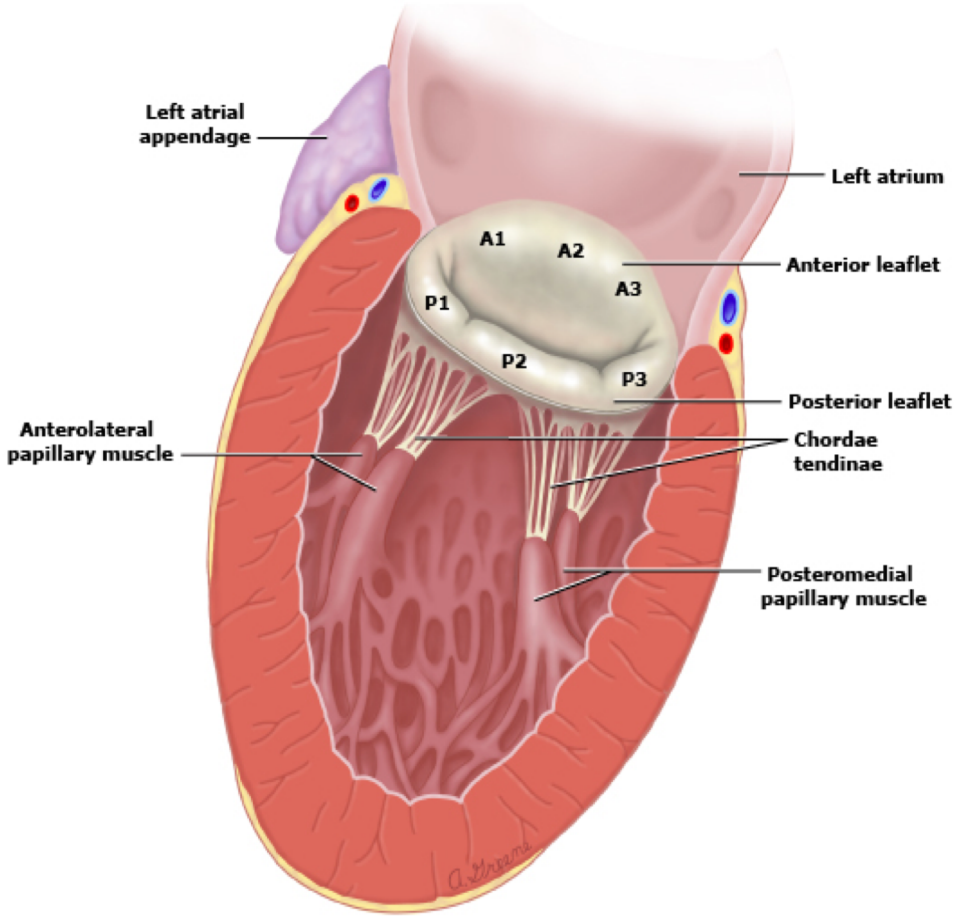

Nouf Alanazi 2019

Etiology

Rheumatic (leading cause of MS)
25% isolated
40% associated MR
35% AV disease
6% TV disease

Congenital
(Shone syndrome)

CTD RA/SLE

Drug induced e.g methysergide

Radiation induced

Rare conditions include Fabry's disease, Whipple's disease, mucopolysaccharidosis, Carcinoid with lung mets or PFO

Calcific (age related)

Nouf Alanazi 2019

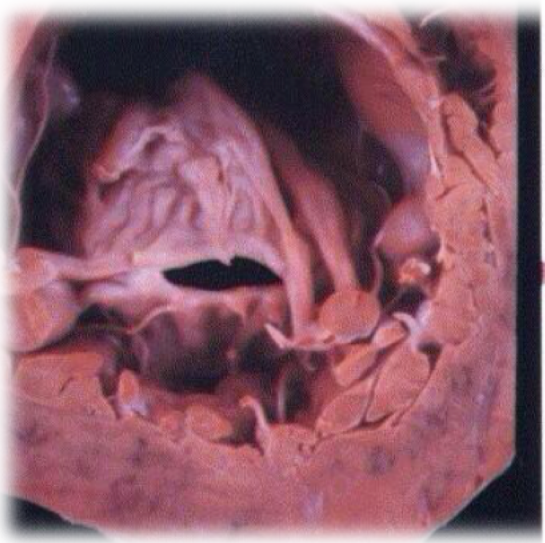



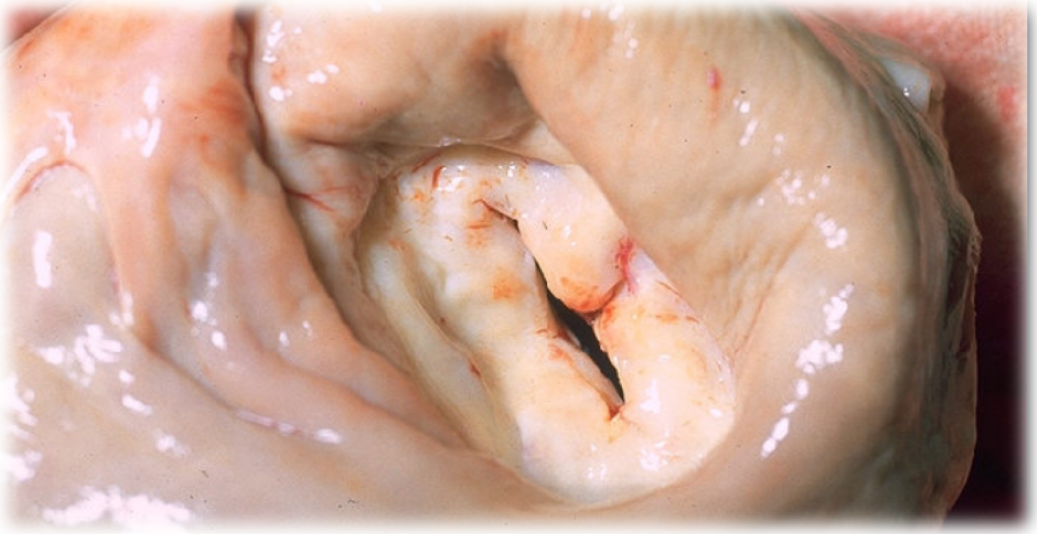

Stages

Stage	Definition	Valve Anatomy	Valve Hemodynamics	Hemodynamic Consequences	Symptoms
A	At risk of MS	• Mild valve doming during diastole	• Normal transmitral flow velocity	• None	• None
B	Progressive MS	• Rheumatic valve changes with commissural fusion and diastolic doming of the mitral valve leaflets • Planimetered MVA >1.5 cm^2	• Increased transmitral flow velocities • MVA >1.5 cm^2 • Diastolic pressure half-time <150 ms	• Mild-to-moderate LA enlargement • Normal pulmonary pressure at rest	• None
C	Asymptomatic severe MS	• Rheumatic valve changes with commissural fusion and diastolic doming of the mitral valve leaflets • Planimetered MVA ≤1.5 cm^2 • (MVA ≤1.0 cm^2 with very severe MS)	• MVA ≤1.5 cm^2 • (MVA ≤1.0 cm^2 with very severe MS) • Diastolic pressure half-time ≥150 ms • (Diastolic pressure half-time ≥220 ms with very severe MS)	• Severe LA enlargement • Elevated PASP >30 mm Hg	• None
D	Symptomatic severe MS	• Rheumatic valve changes with commissural fusion and diastolic doming of the mitral valve leaflets • Planimetered MVA ≤1.5 cm^2	• MVA ≤1.5 cm^2 • (MVA ≤1.0 cm^2 with very severe MS) • Diastolic pressure half-time ≥150 ms • (Diastolic pressure half-time ≥220 ms with very severe MS)	• Severe LA enlargement • Elevated PASP >30 mm Hg	• Decreased exercise tolerance • Exertional dyspnea

Nouf Alanazi 2019

Pathophysiology

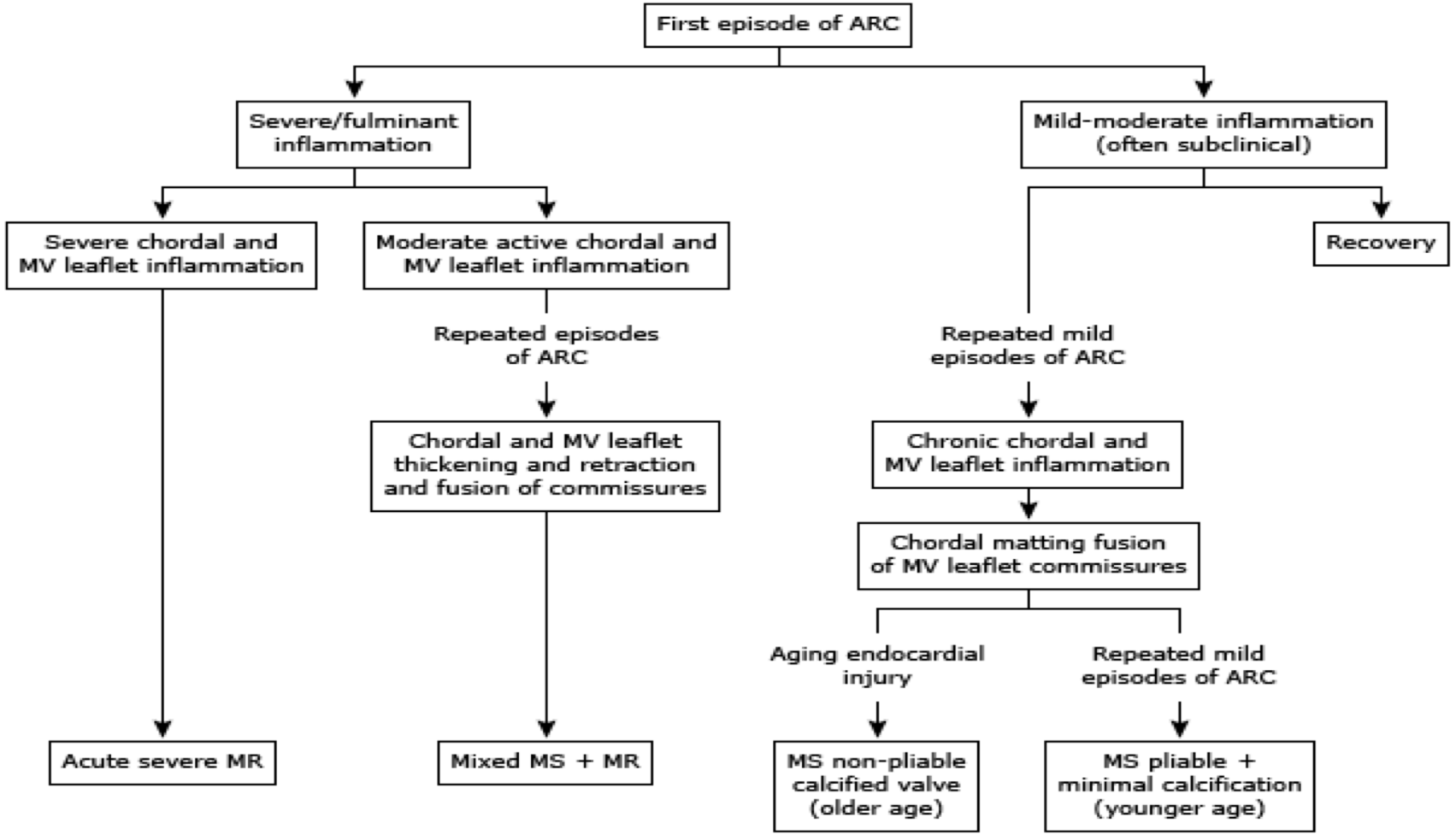

Nouf Alanazi 2019

Hemodynamic consequences

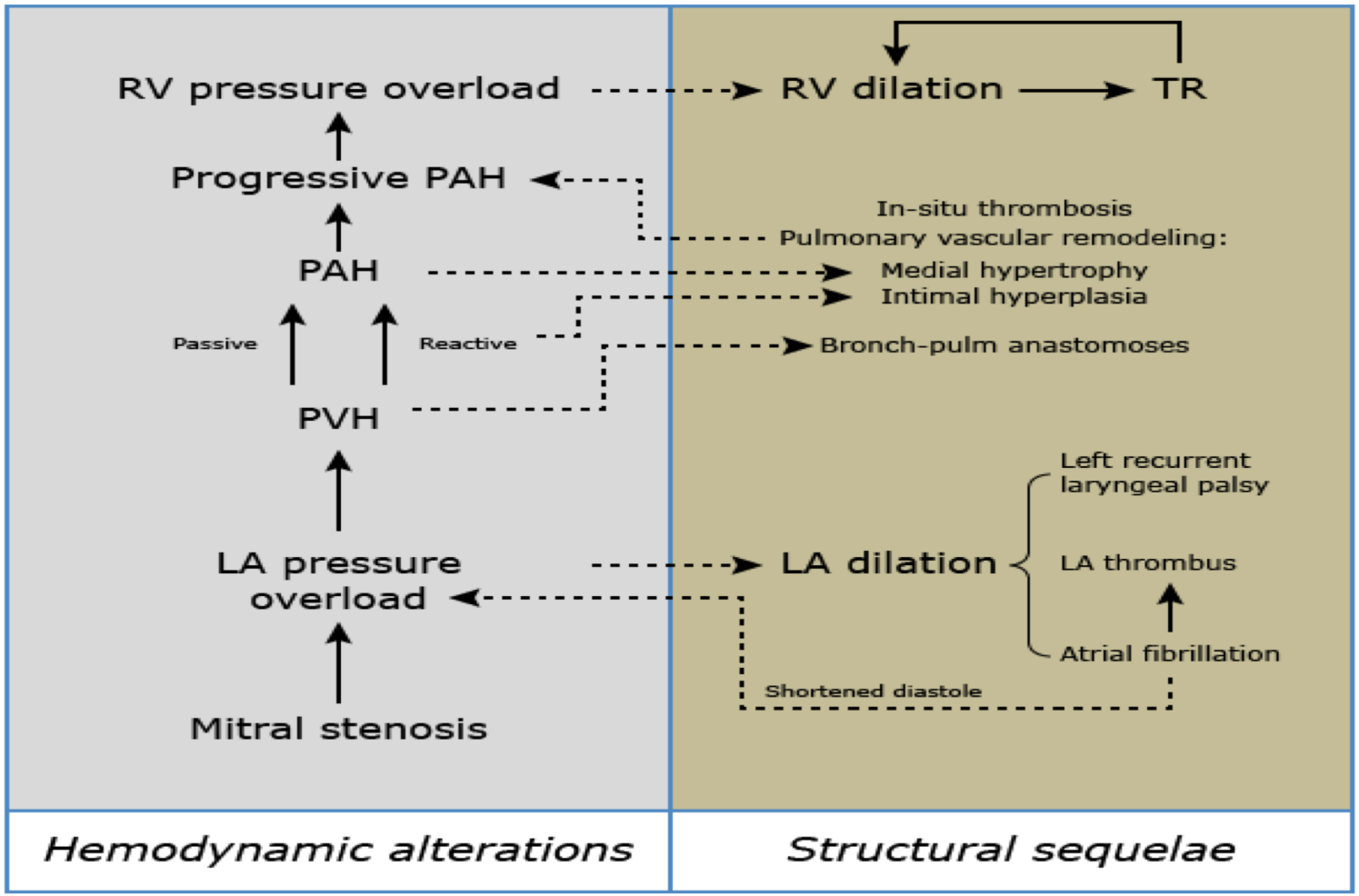

Nouf Alanazi 2019

Natural history

- Progressive lifelong disease
- Slow and stable initially then progressive acceleration years later
- Long latent period post RF (years)

Clinical presentation

Symptoms

- Dyspnea
- Poor exercise tolerance
- Orthopnea
- PND
- PHT symptoms: RHF, hemoptysis
- Palpitation
- Peripheral embolism secondary to AF
- Ortner’s syndrome recurrent laryngeal nerve compression by dilated LA

Physical exam

- **Face:** Mitral faces pink purple plaques on cheeks (due to systemic VC)
- **Pulse:** regular (sinus), irregular with AF, low volume
- **Apex:** Tapping beat (palpable S1)
- **JVP:** Prominent a wave in sinus rhythm
- **HS:** Loud S1 when leaflets are still pliable
- **Extra HS:** Opening snap (OS) early in diastole, can mimic a split second heart sound. caused by thickened valve leaflets as they open (Earlier OS indicates severe MS)
- **Murmur:** **L**ow pitched mid diastolic rumble at the apex with presystolic accentuation
- No S3
- Signs of PHTN

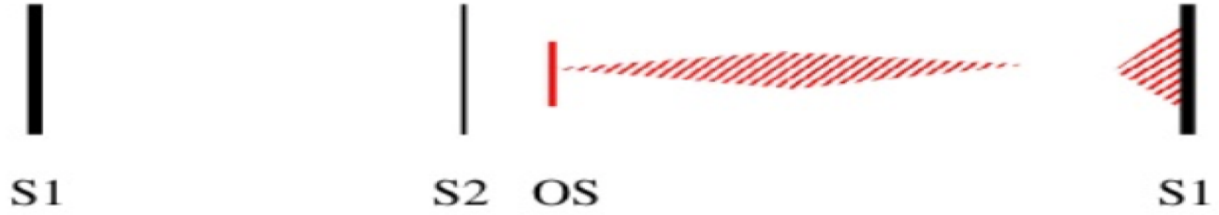

Nouf Alanazi 2019

Mitral faces

Nouf Alanazi 2019

Investigations & Diagnosis

- Bedside assessment & observation of syndromic features.
- Bloods
- FBC
- U&Es
- Cholesterol
- Clotting
- **ECG:**

AF, LAE, RVH

ECG with MS

Left Atrial enlargement

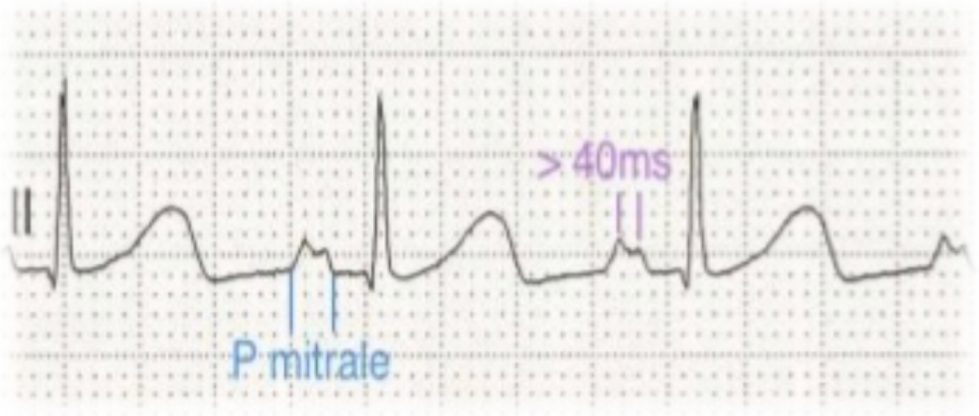

Atrial Fibrillation

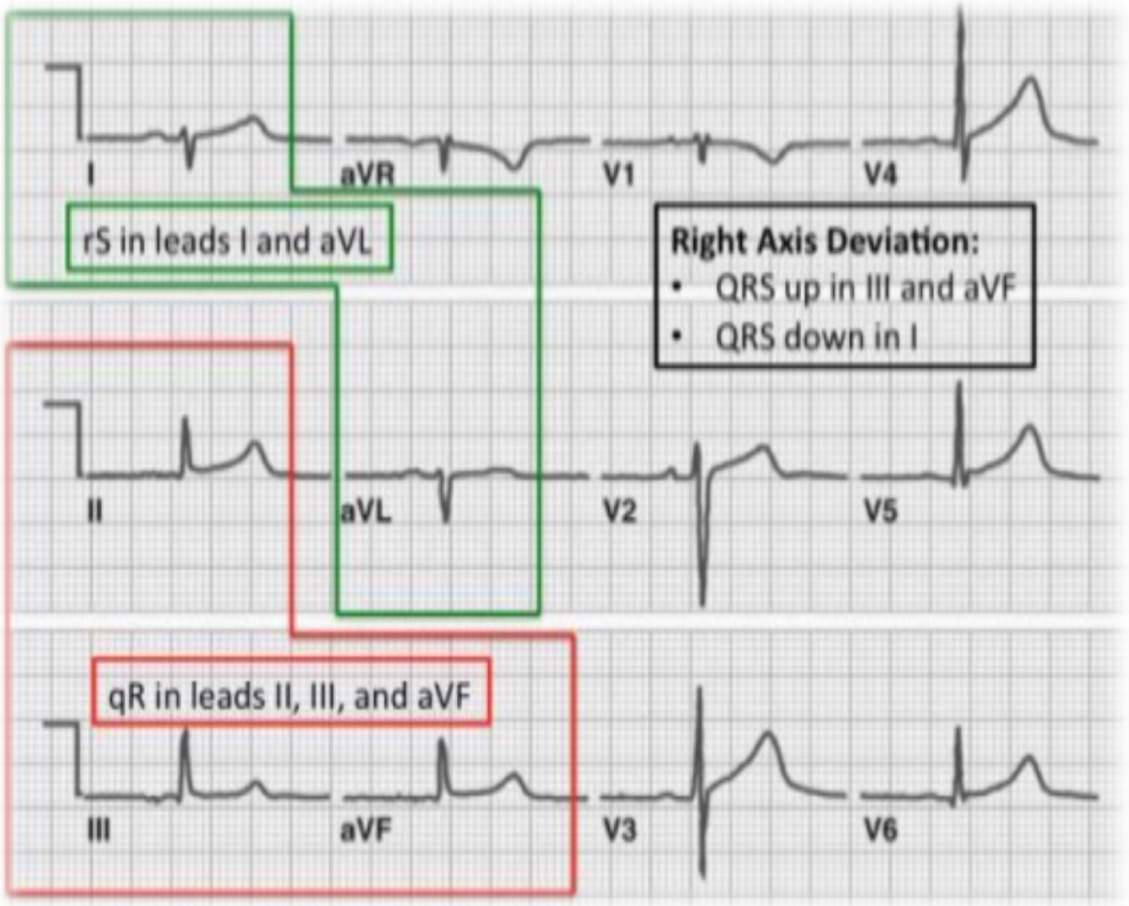

Nouf Alanazi 2019

35 y/o female with S1 & mid diastolic murmur

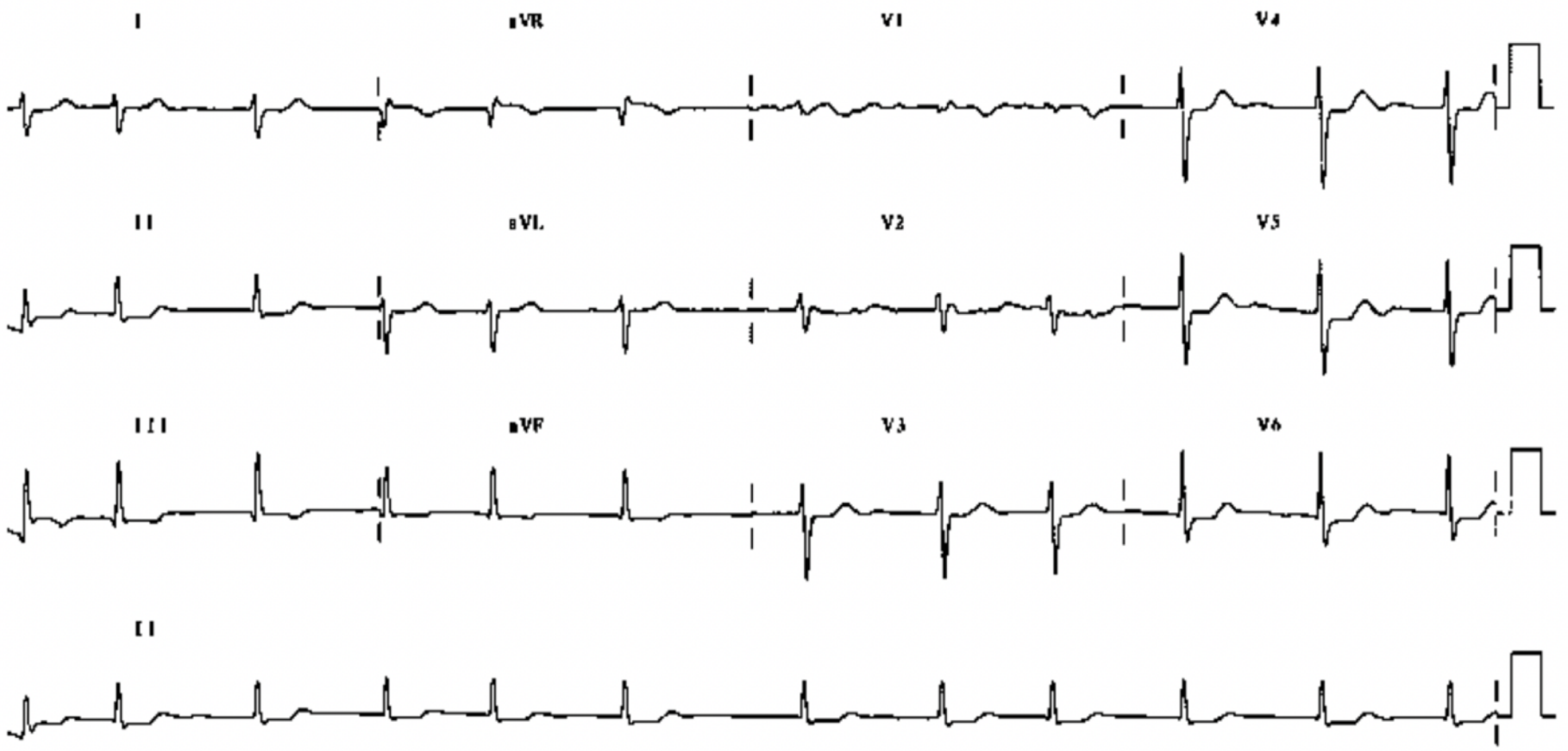

Nouf Alanazi 2019

Investigations & Diagnosis

Imaging

1. Echocardiogram
    - Gold standard
2. CXR:
    - LAE: straitening of the left heart border
    - Pulmonary congestion and prominent PA
    - Calcified MV

Special

- Cardiac catheterisation
- ECG exercise stress testing

CXR with MS

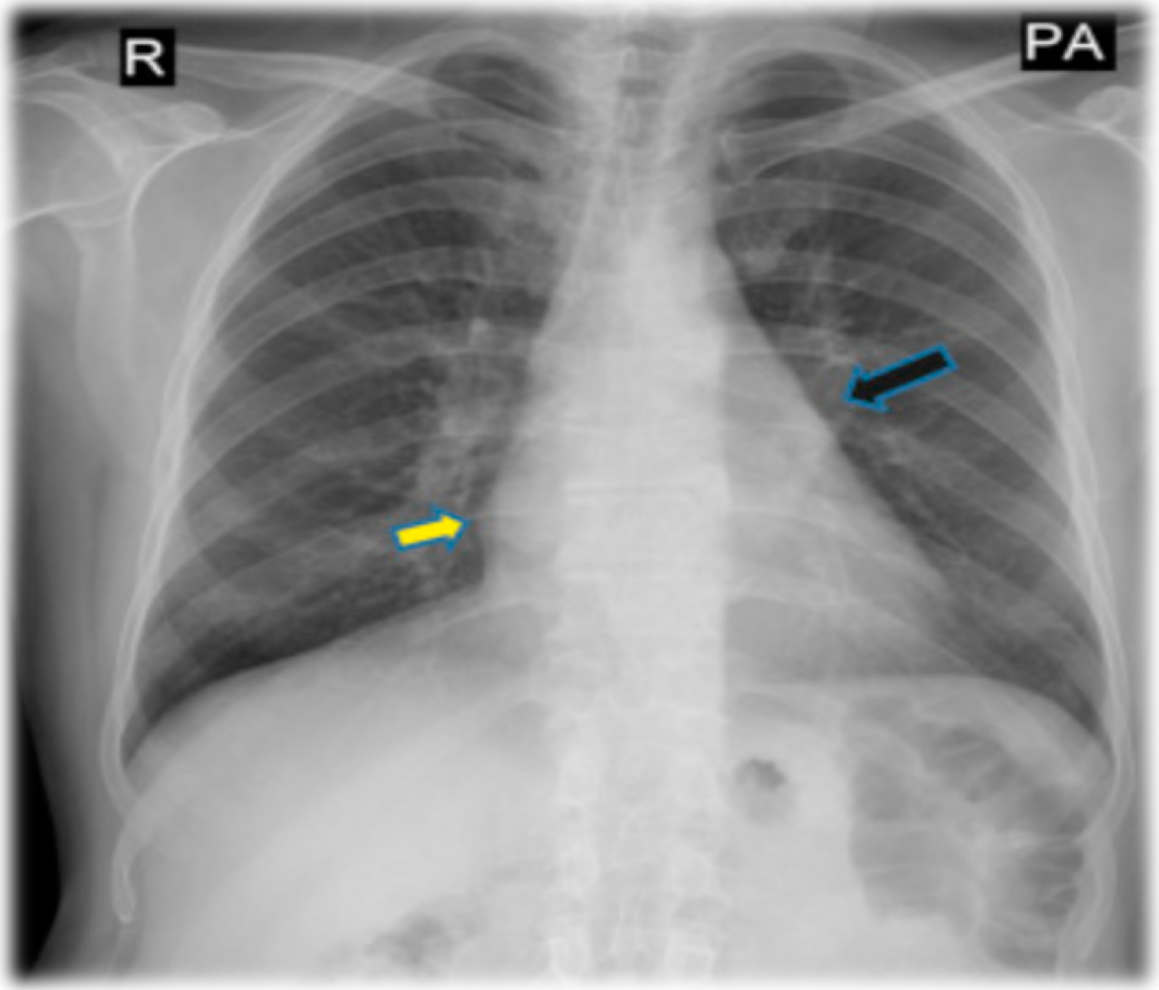

Nouf Alanazi 2019

Echo (MS)

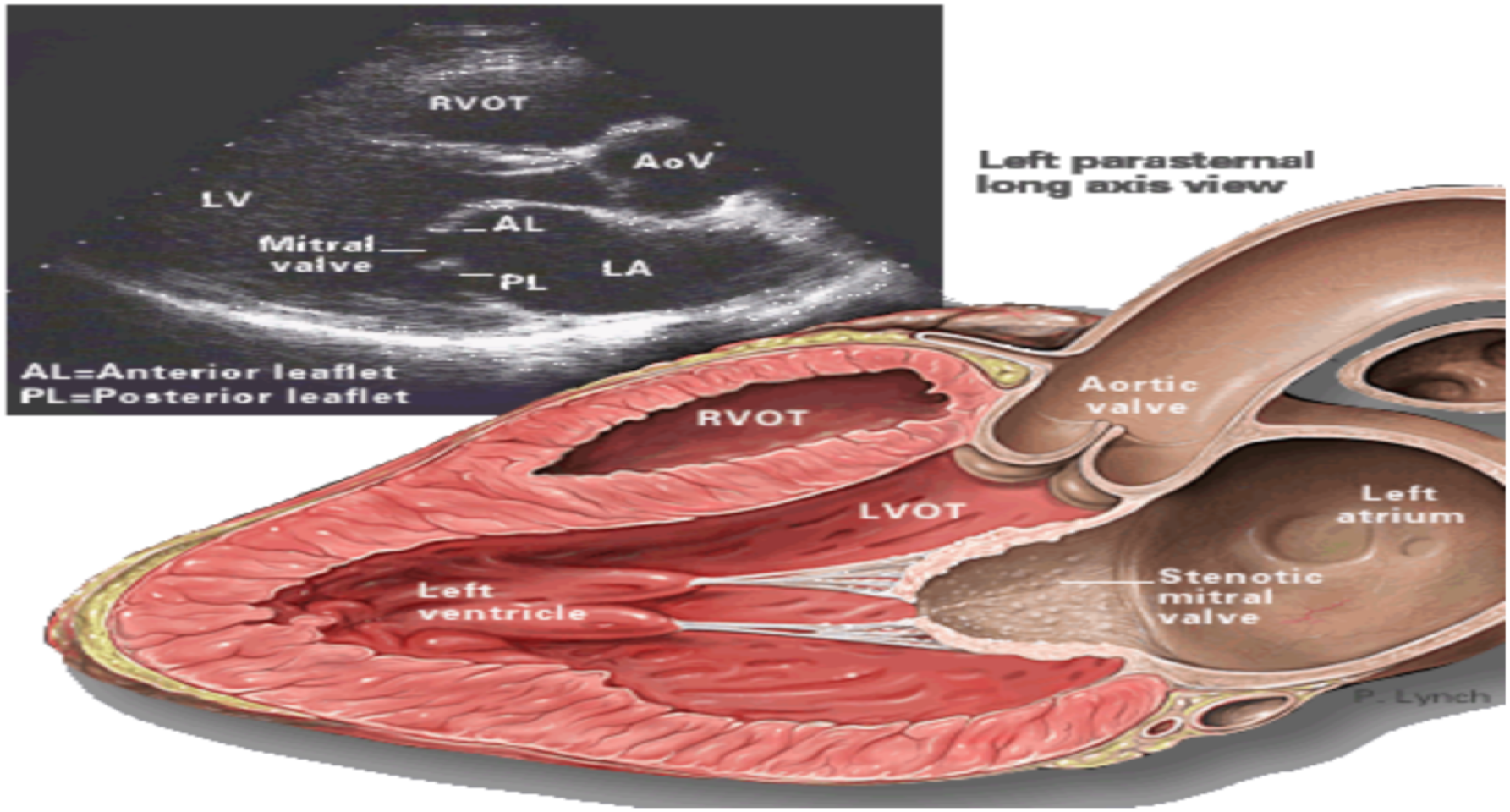

Nouf Alanazi 2019

Management

Medical

- Diuretics
- BB
- Anticoagulation

Percutaneous or Surgical intervention

- Mitral balloon valvuloplasty (percutaneous mitral balloon commissurotomy, PMBC)
- MVR

Mitral Balloon Valvuloplasty

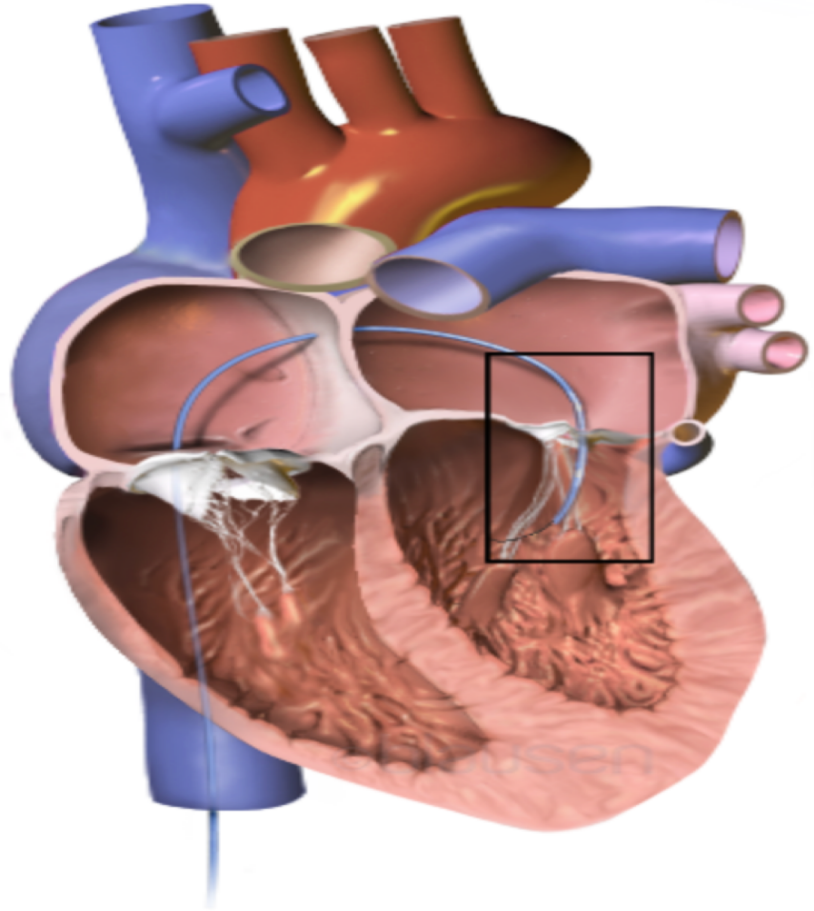

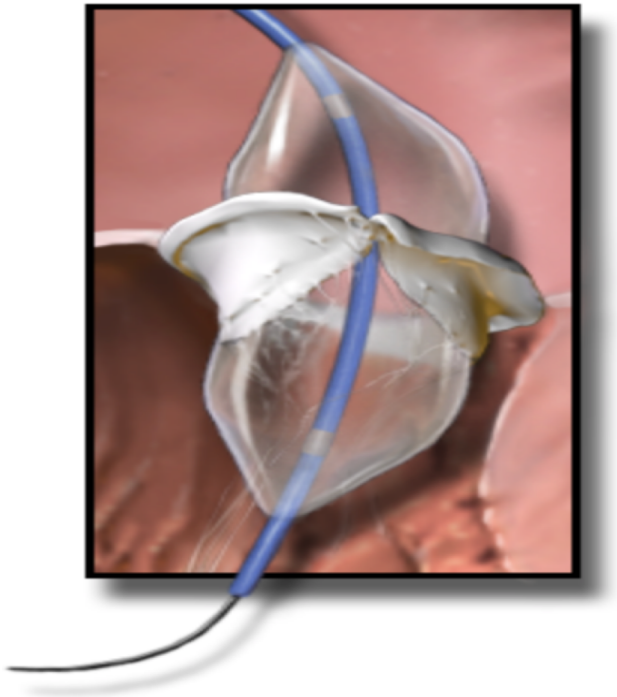

Nouf Alanazi 2019

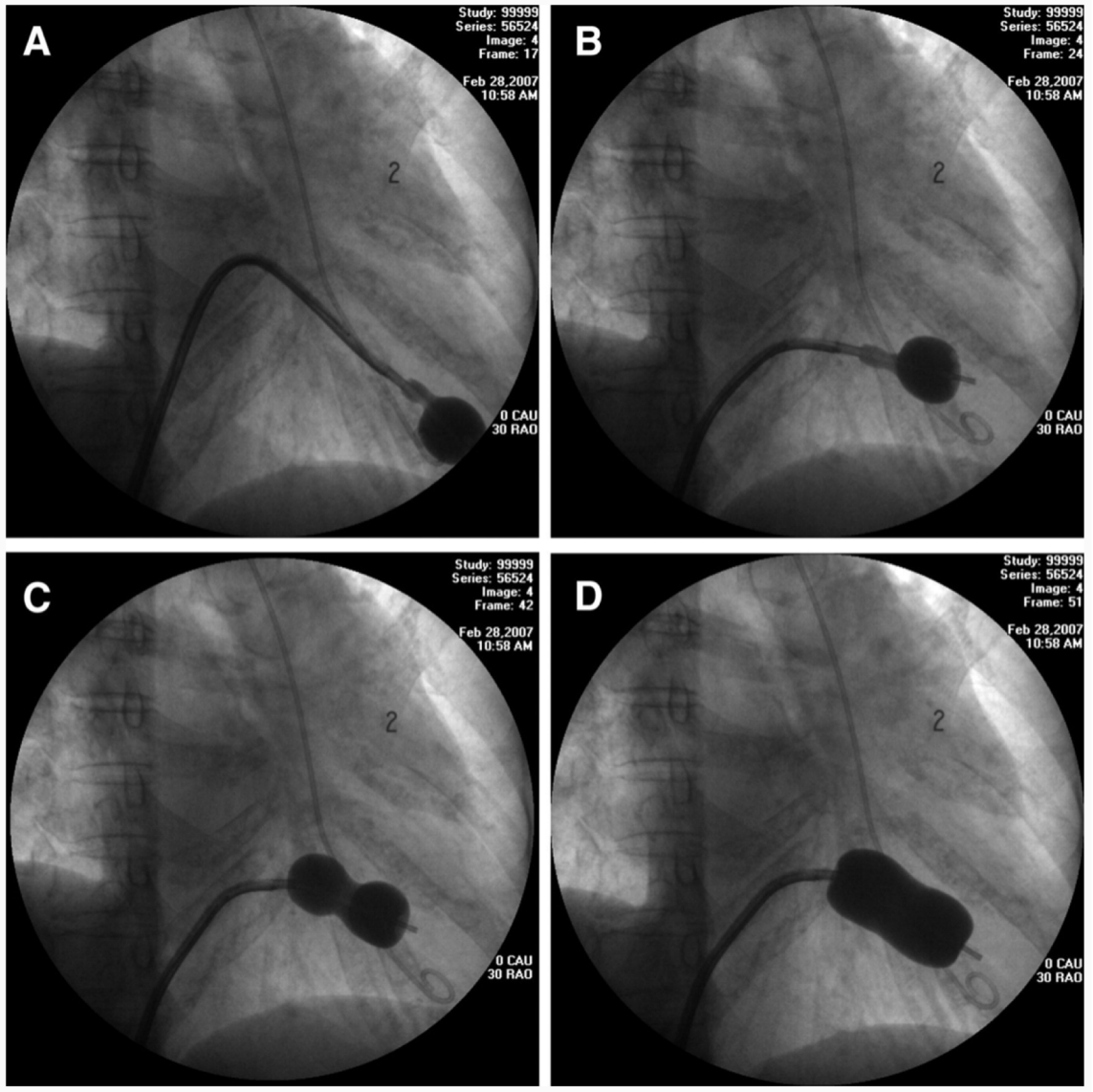

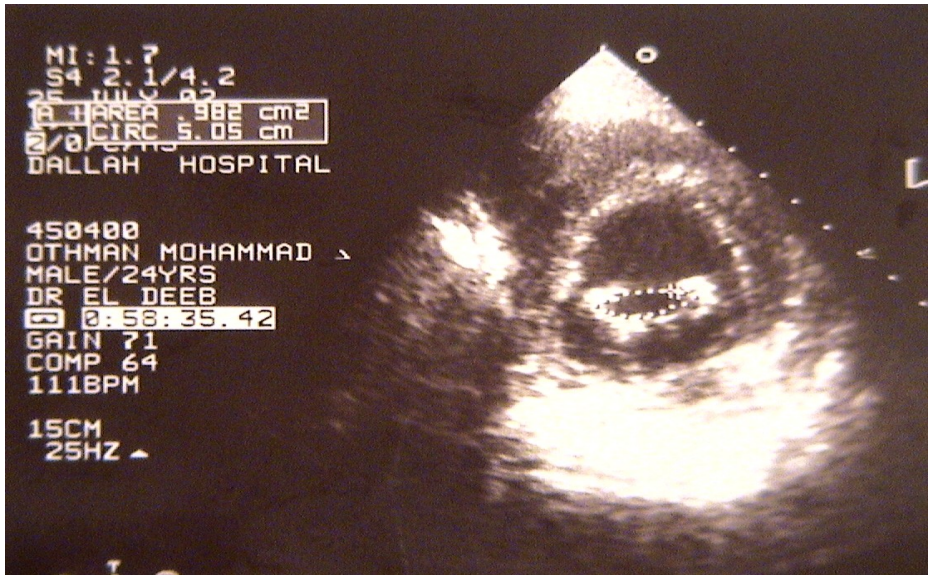

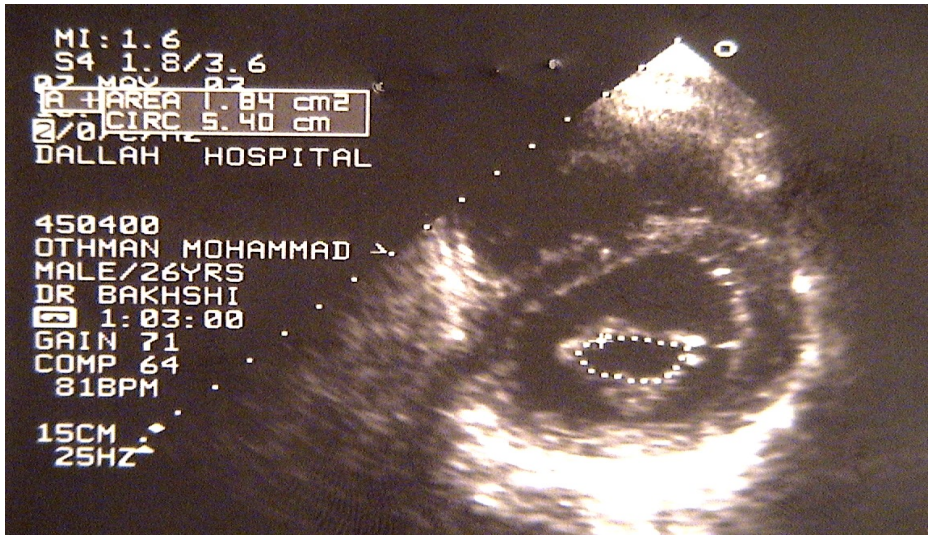

Nouf Alanazi 2019

Mitral Valve Replacement (MVR)

Mechanical Valve

Tissue Valve

Nouf Alanazi 2019

Indications for Intervention for Rheumatic MS

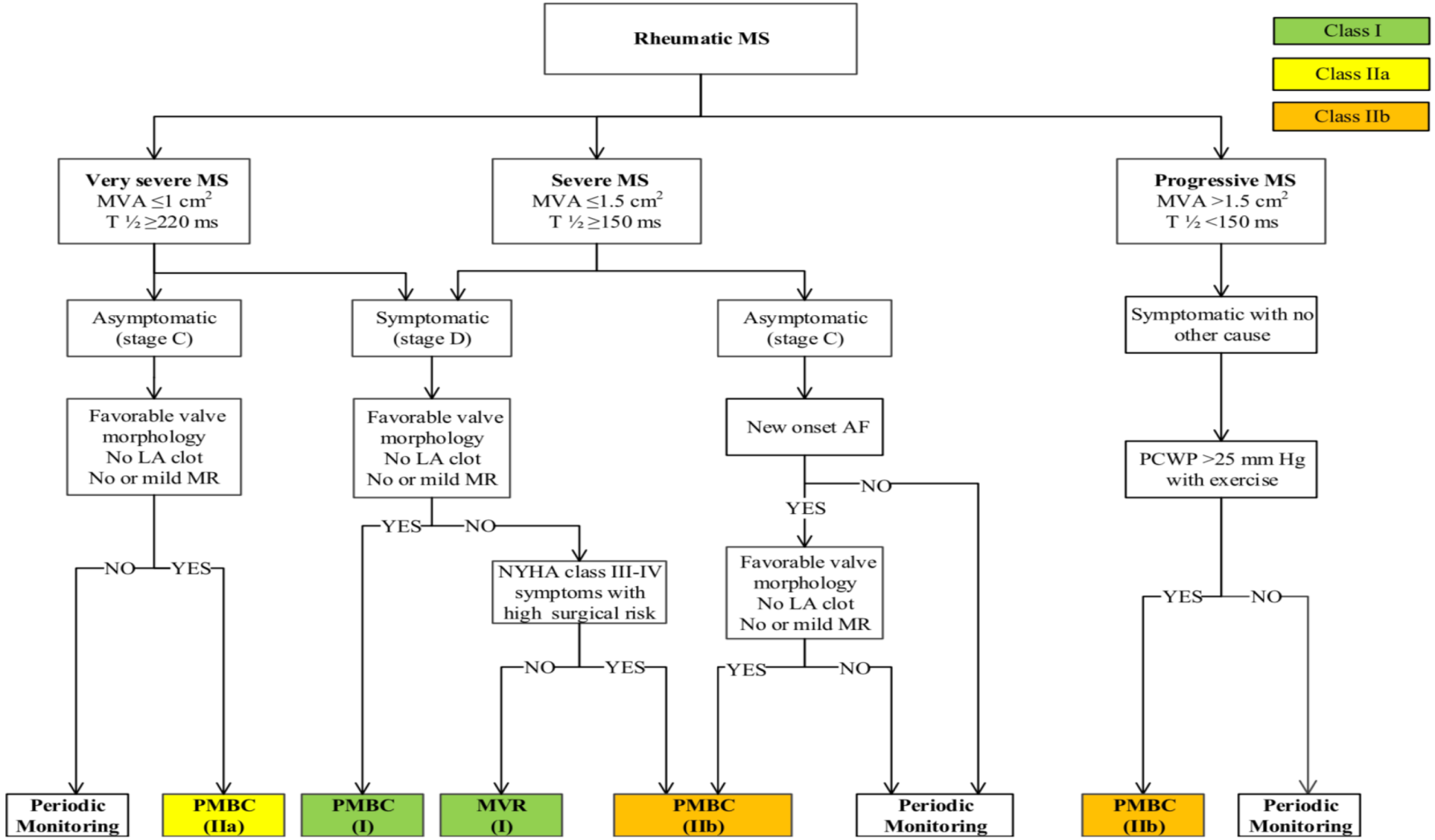

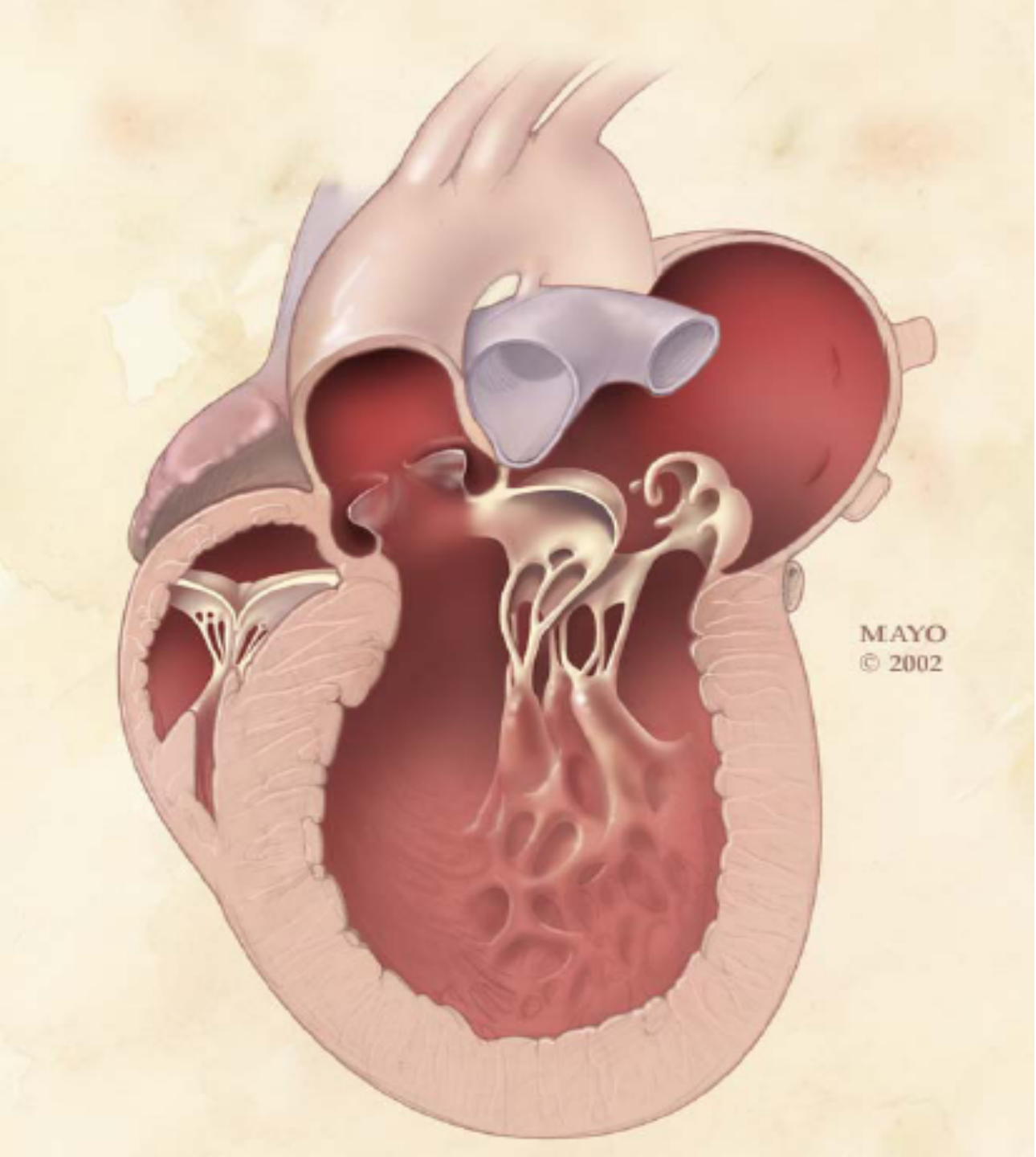

Mitral Regurgitation (MR)

Nouf Alanazi 2019

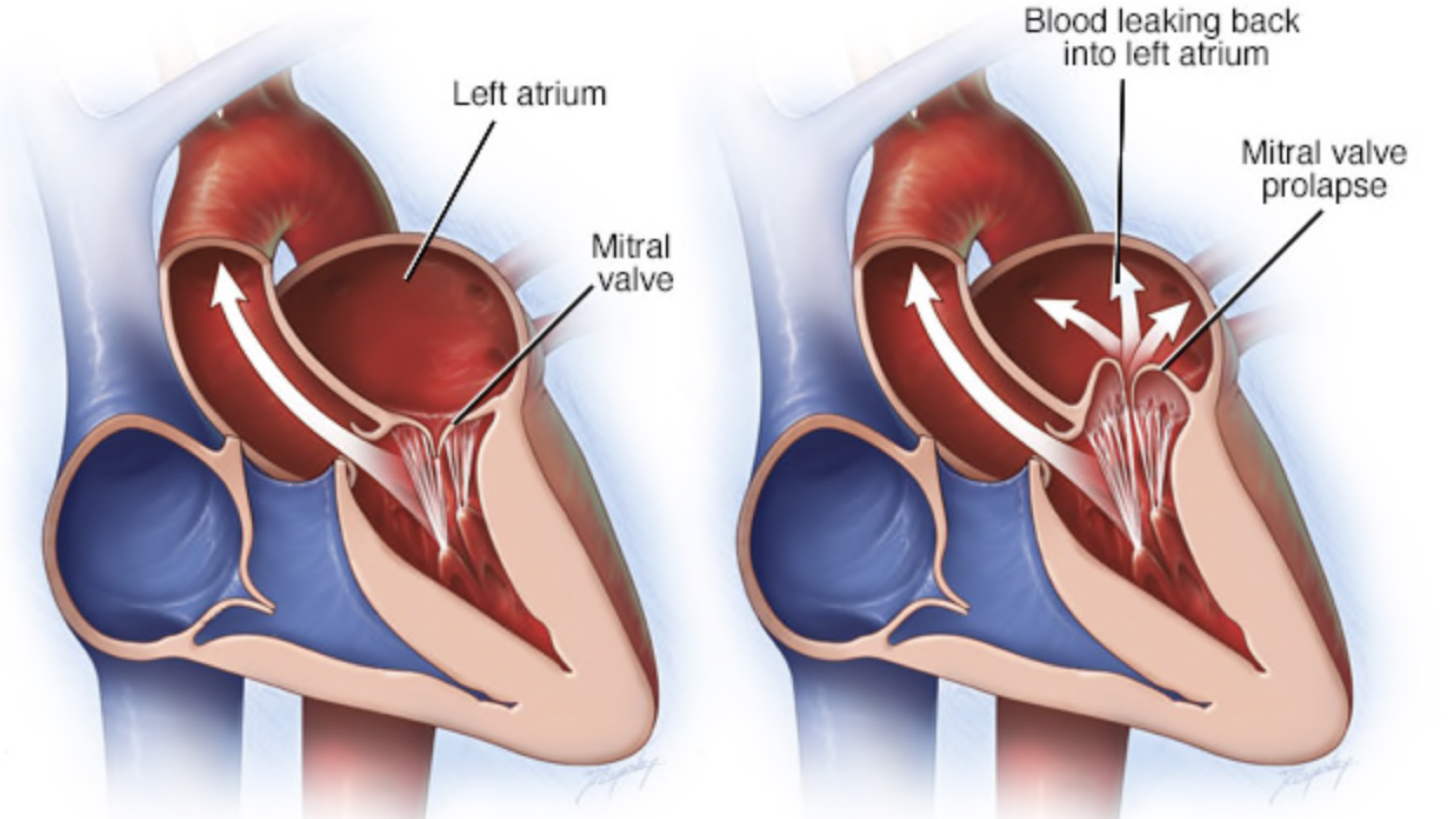
Left atrium
Mitral valve
Blood leaking back into left atrium
Mitral valve prolapse

Etiology

Acute MR	Chronic Primary MR
Endocarditis	Myxomatous (MVP)
Papillary muscle rupture (post MI)	Rheumatic Fever
Trauma	Endocarditis (Healed)
Chordal rupture/leaflet flail (MVP,IE)	Mitral annular calcifications
	Congenital (Cleft,AV canal)/ HOCM with SAM
	Radiation
	Chronic secondary MR
	Ischemic (LV remodeling)
	Dilated Cardiomyopathy

The abnormal & dilated LV causes Pap muscle displacement which in turn results in leaflet tethering with associated annular dilation that prevents coaptation

Classification of the Etiology of MR

	Carpentier Type I	Carpentier Type II	Carpentier Type IIIa	Carpentier Type IIIb
	(normal leaflet motion and position)	(excess leaflet motion)	(restricted leaflet motion in systole and diastole)	(restricted leaflet motion in systole)
PRIMARY MR	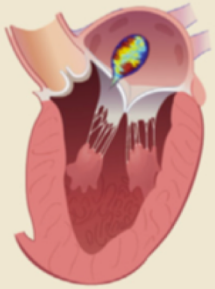 Leaflet Perforation Cleft	Mitral Valve Prolapse	Rheumatic Valve Disease Mitral Annular Calcification Drug Induced MR	
SECONDARY MR	Atrial MR 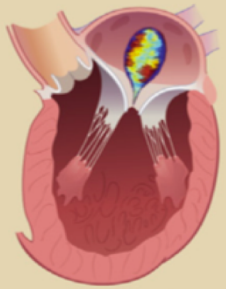 Nonischemic Cardiomyopathy			Ischemic Cardiomyopathy

El Sabbagh, A. et al. J Am Coll Cardiol Img. 2018;11(4):628–43.

Nouf Alanazi 2019

Stages of Chronic MR

Grade	Definition	Valve Anatomy	Valve Hemodynamics*	Hemodynamic Consequences	Symptoms
A	At risk of MR	• Mild mitral valve prolapse with normal coaptation • Mild valve thickening and leaflet restriction	• No MR jet or small central jet area <20% LA on Doppler • Small vena contracta <0.3 cm	• None	• None
B	Progressive MR	• Severe mitral valve prolapse with normal coaptation • Rheumatic valve changes with leaflet restriction and loss of central coaptation • Prior IE	• Central jet MR 20%–40% LA or late systolic eccentric jet MR • Vena contracta <0.7 cm • Regurgitant volume <60 mL • Regurgitant fraction <50% • ERO <0.40 cm^2 • Angiographic grade 1–2+	• Mild LA enlargement • No LV enlargement • Normal pulmonary pressure	• None
C	Asymptomatic severe MR	• Severe mitral valve prolapse with loss of coaptation or flail leaflet • Rheumatic valve changes with leaflet restriction and loss of central coaptation • Prior IE • Thickening of leaflets with radiation heart disease	• Central jet MR >40% LA or holosystolic eccentric jet MR • Vena contracta ≥0.7 cm • Regurgitant volume ≥60 mL • Regurgitant fraction ≥50% • ERO ≥0.40 cm^2 • Angiographic grade 3–4+	• Moderate or severe LA enlargement • LV enlargement • Pulmonary hypertension may be present at rest or with exercise • **C1:** LVEF >60% and LVESD <40 mm • **C2:** LVEF ≤60% and LVESD ≥40 mm	• None
D	Symptomatic severe MR	• Severe mitral valve prolapse with loss of coaptation or flail leaflet • Rheumatic valve changes with leaflet restriction and loss of central coaptation • Prior IE • Thickening of leaflets with radiation heart disease	• Central jet MR >40% LA or holosystolic eccentric jet MR • Vena contracta ≥0.7 cm • Regurgitant volume ≥60 mL • Regurgitant fraction ≥50% • ERO ≥0.40 cm^2 • Angiographic grade 3–4+	• Moderate or severe LA enlargement • LV enlargement • Pulmonary hypertension present	• Decreased exercise tolerance • Exertional dyspnea

Acute MR Pathophyiology

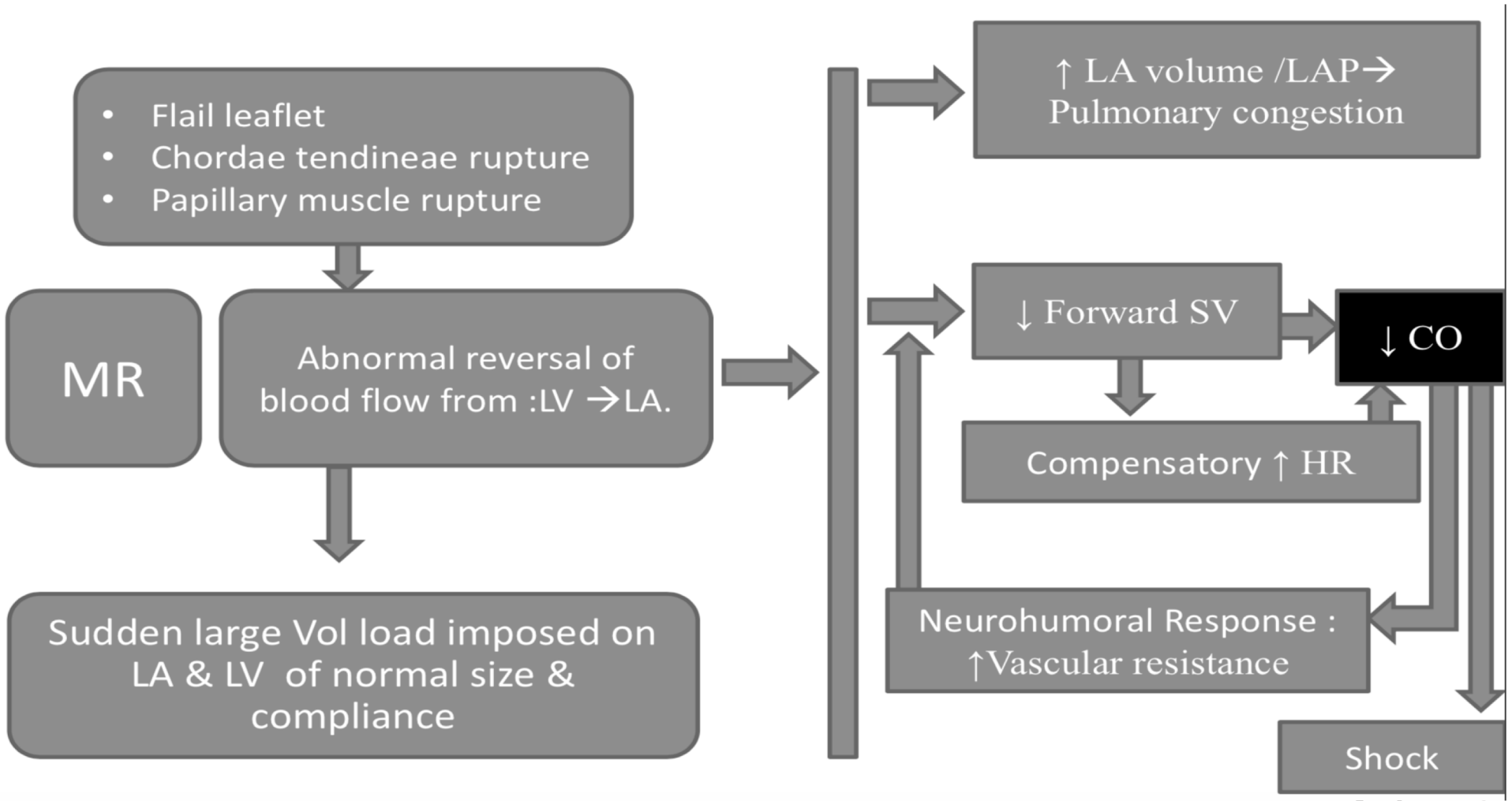

Nouf Alanazi 2019

Chronic MR Pathophysiology

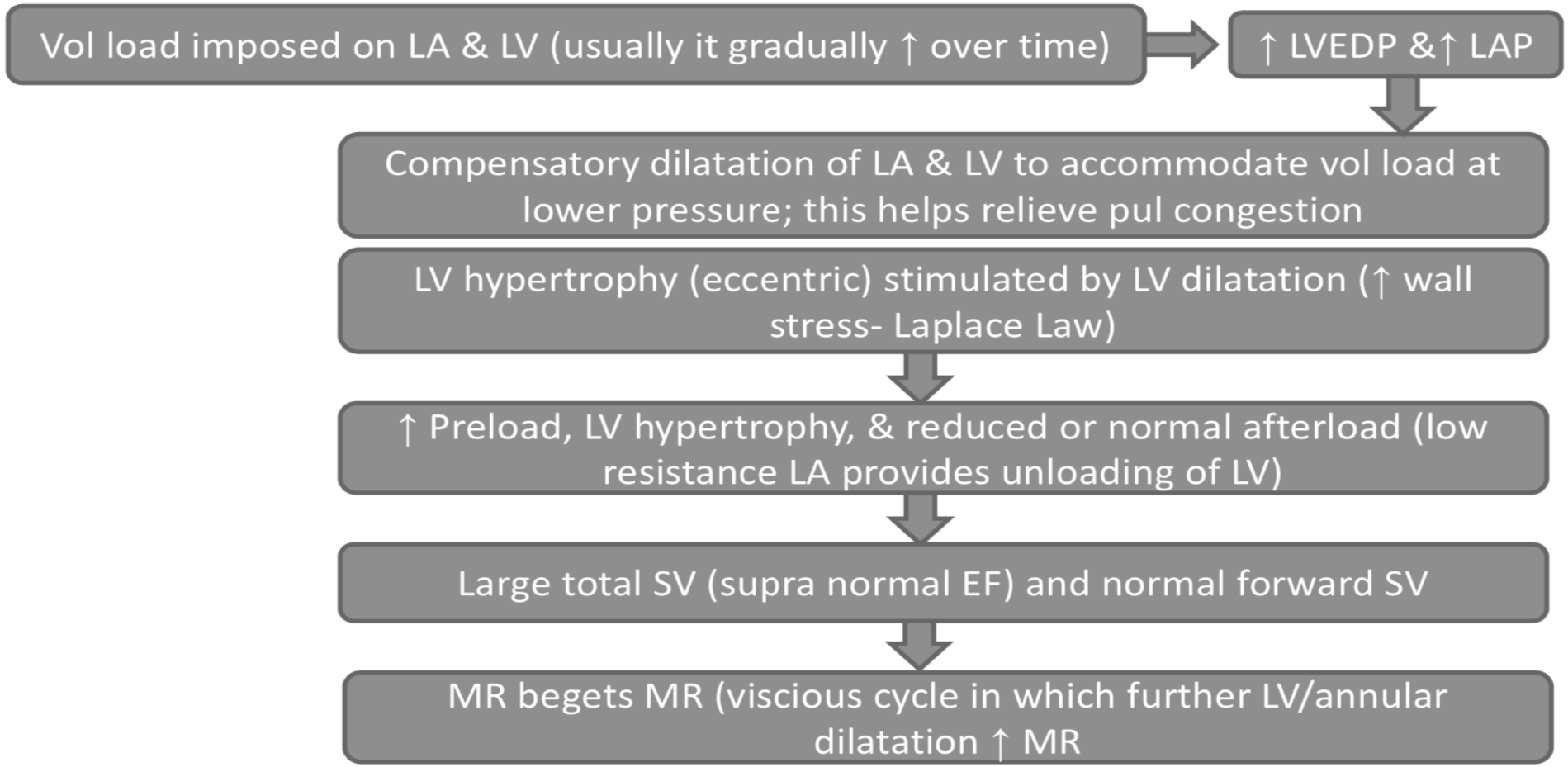

Nouf Alanazi 2019

Chronic MR pathophysiology

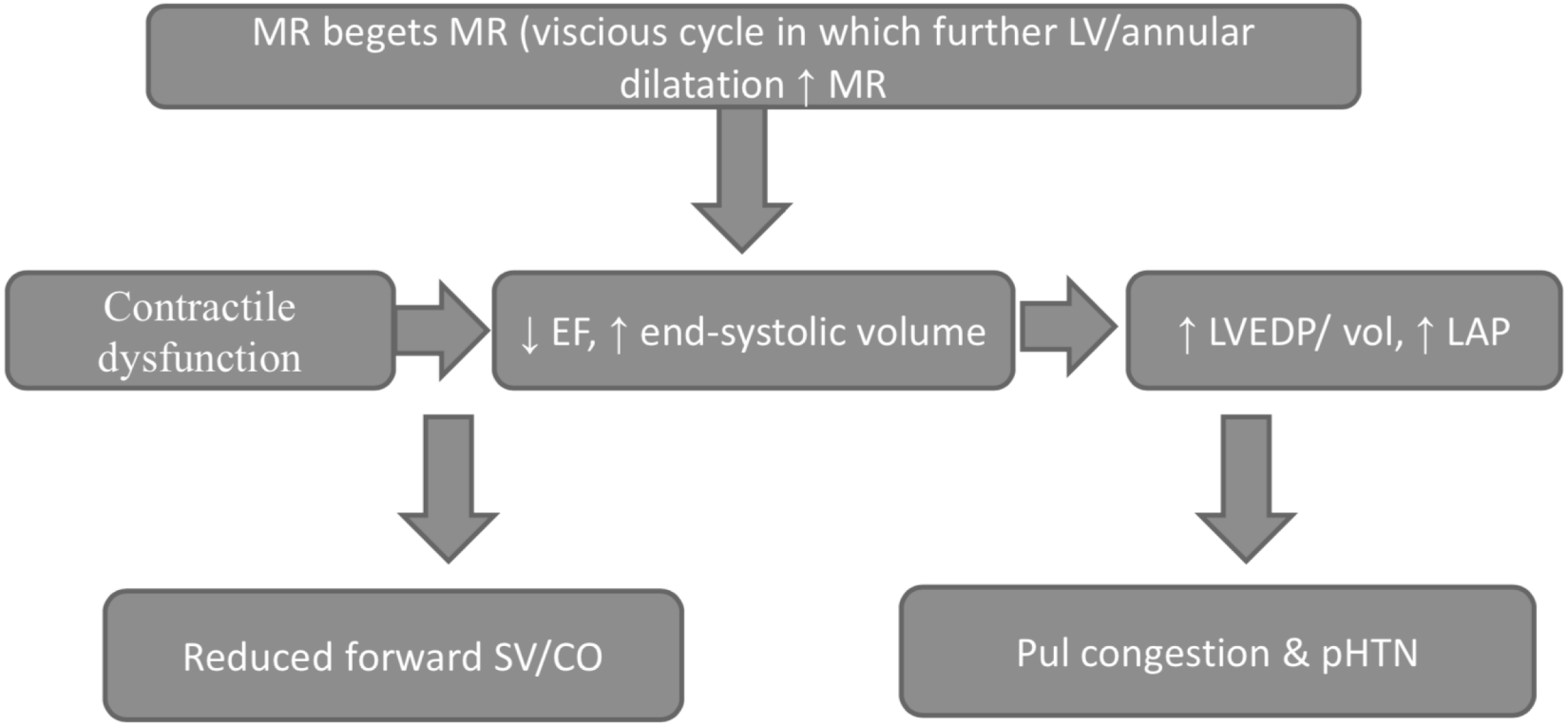

Nouf Alanazi 2019

Laplace law

Laplace Law

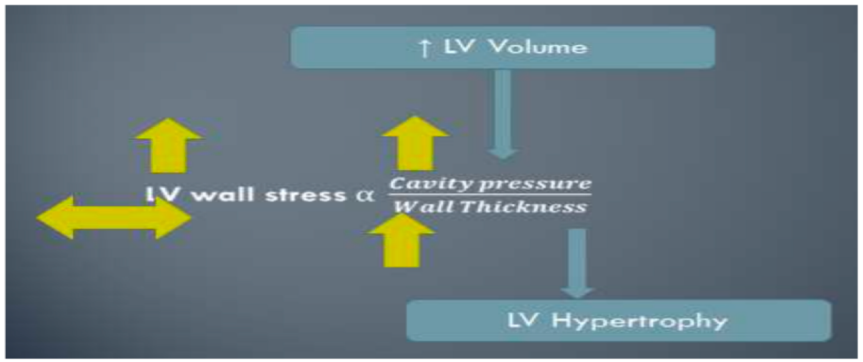

As stated by Laplace law: LV wall stress is directly proportional to the cavity pressure and inversely proportional to wall thickness. Due to the added regurgitant vol there is ↑ in LV volume that leads to an ↑ in LV cavity pressure and it causes an ↑in wall stress.
If a hypertrophic response occurs, ↑↑ thickness can return wall stress to N.

- The hemodynamic changes in acute MR are more severe than those in chronic MR due in part to the lack of time for the left atrium and left ventricle to adapt to the MR.
- This is in contrast to chronic MR where these adaptations have time to develop and typically preserve hemodynamic stability.

Frank-starling law

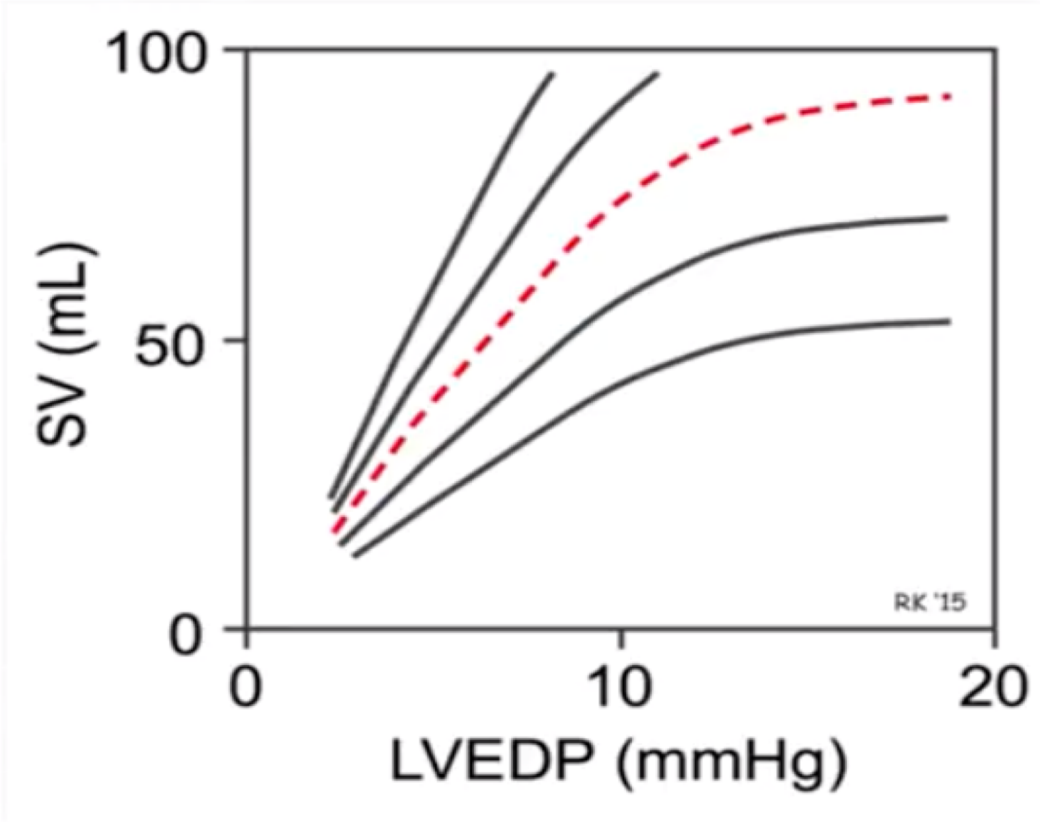

$$CO = SV \times HR$$

↑ Contraction = ↑ SV

↑ LVEDP = ↑ SV

Nouf Alanazi 2019

Natural History of Primary MR

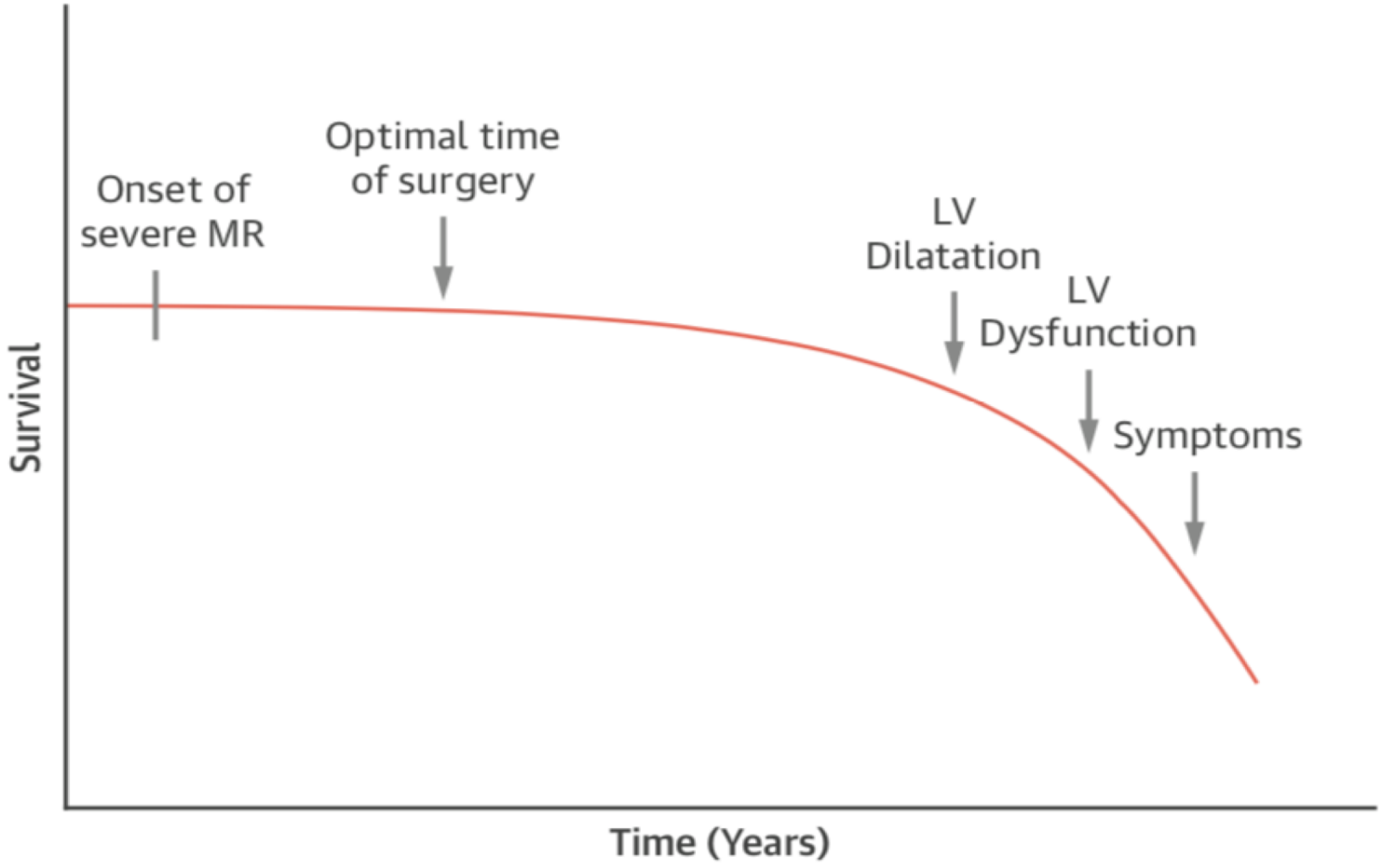

Nouf Alanazi 2019

Clinical Presentation

Symptoms:

Acute MR:

- ✓ Decompensated HF symptoms: Dyspnea, orthopnea, PND)
- ✓ Low cardiac output state
- ✓ Cardiogenic shock

Chronic MR:

- ✓ Initially asymptomatic
- ✓ HF symptoms (Dyspnea, orthopnea, PND, LL edema)
- ✓ Decreased exercise tolerance
- ✓ Palpitation with AF if present
- ✓ PHTN symptoms if present

Physical exam & Clinical signs:

Pulse: Large Volume Collapsing

JVP: prominent V wave

Apex: Diffuse with Lateral displacement +/- palpable thrill

HS: Normal or Soft S1, S2 physiological split or wide split due to premature AV closure.

Extra HS: S3

Murmurs: Pansystolic (holosystolic) louder at the apex & radiates to axilla

Acute vs Chronic MR

Acute MR	Chronic NR
Tachycardia (sinus)	Normal HR (sinus AF may be present)
Low BP	N or high BP
S4	S3
Short early systolic	Holosystolic

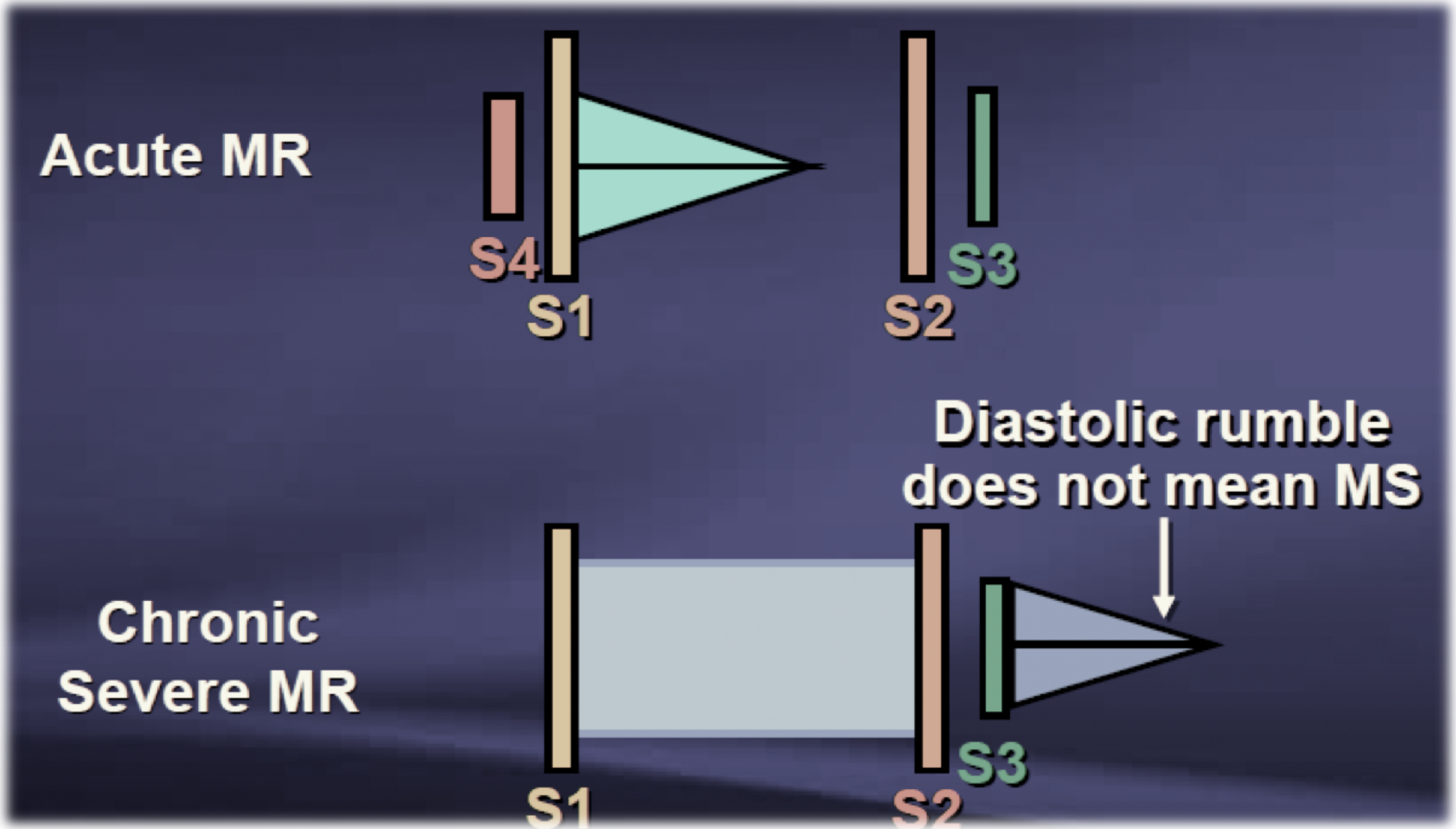

Nouf Alanazi 2019

Investigations & Diagnosis

- Bedside assessment & observation of syndromic features.
- Bloods
- FBC
- U&Es
- Cholesterol
- Clotting
- ECG:

LAE, LVH, PHT findings, AF

Investigations & Diagnosis

Imaging

- Echocardiogram
- CXR

Special

- Cardiac catheterisation
- Exercise test

Management

Medical:

- HF medications with LV dysfunction if surgical intervention not possible.

- **Surgical/Percutaneous intervention:**
- Mitral valve repair or replacement.
- Mitral clip

Mitral Valve Replacement

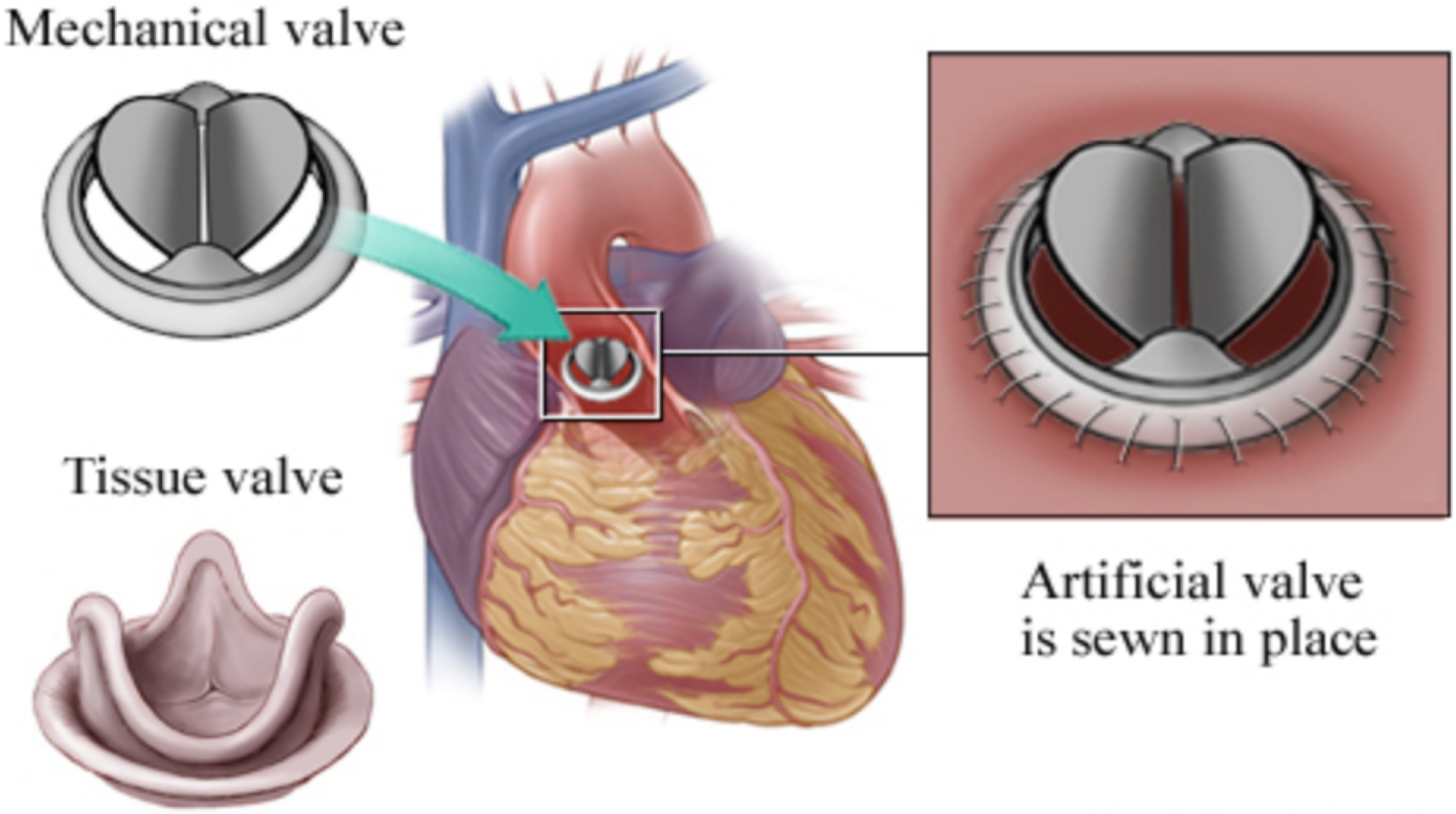

Mitral Valve Repair

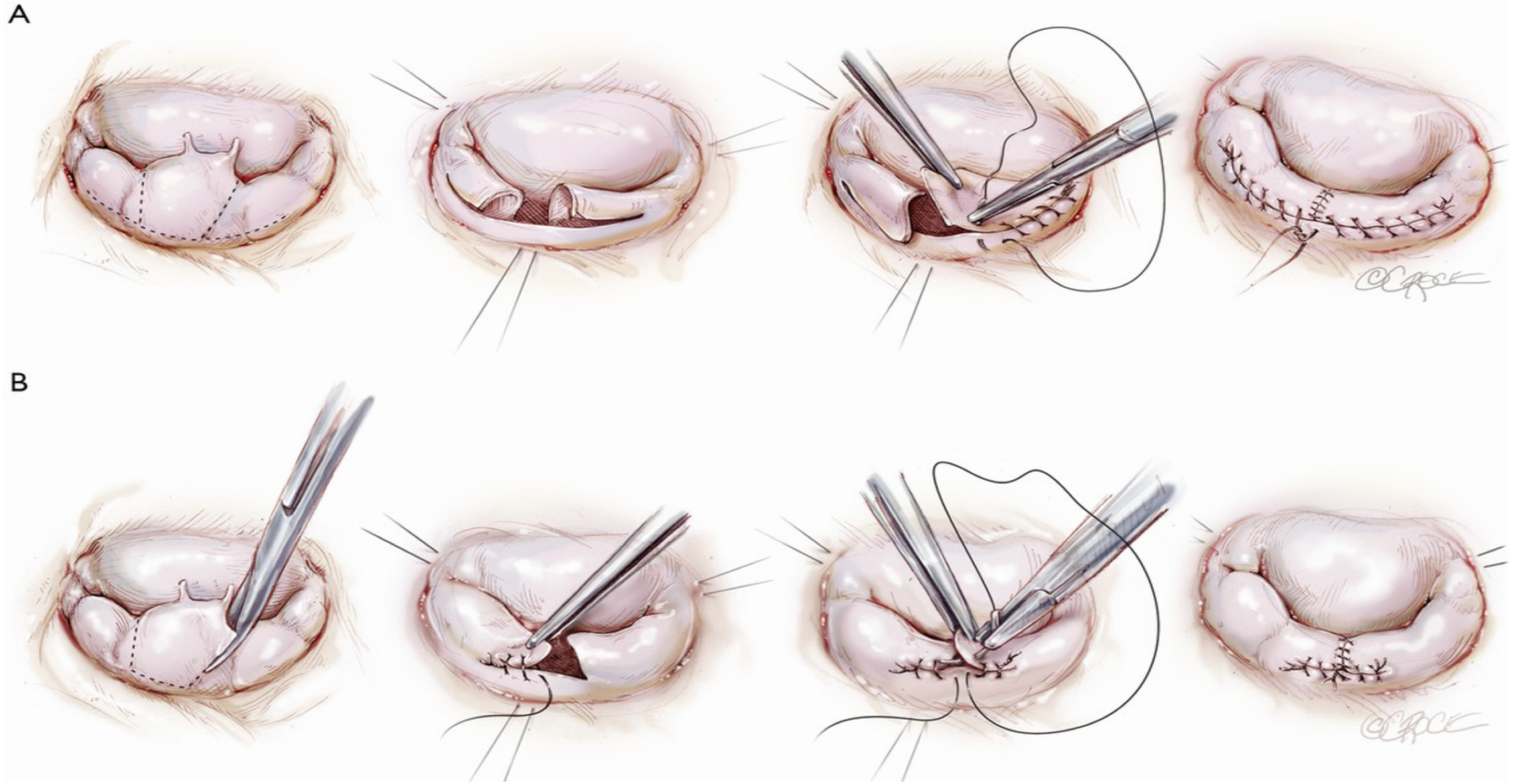

Nouf Alanazi 2019

Transcatheter MVR

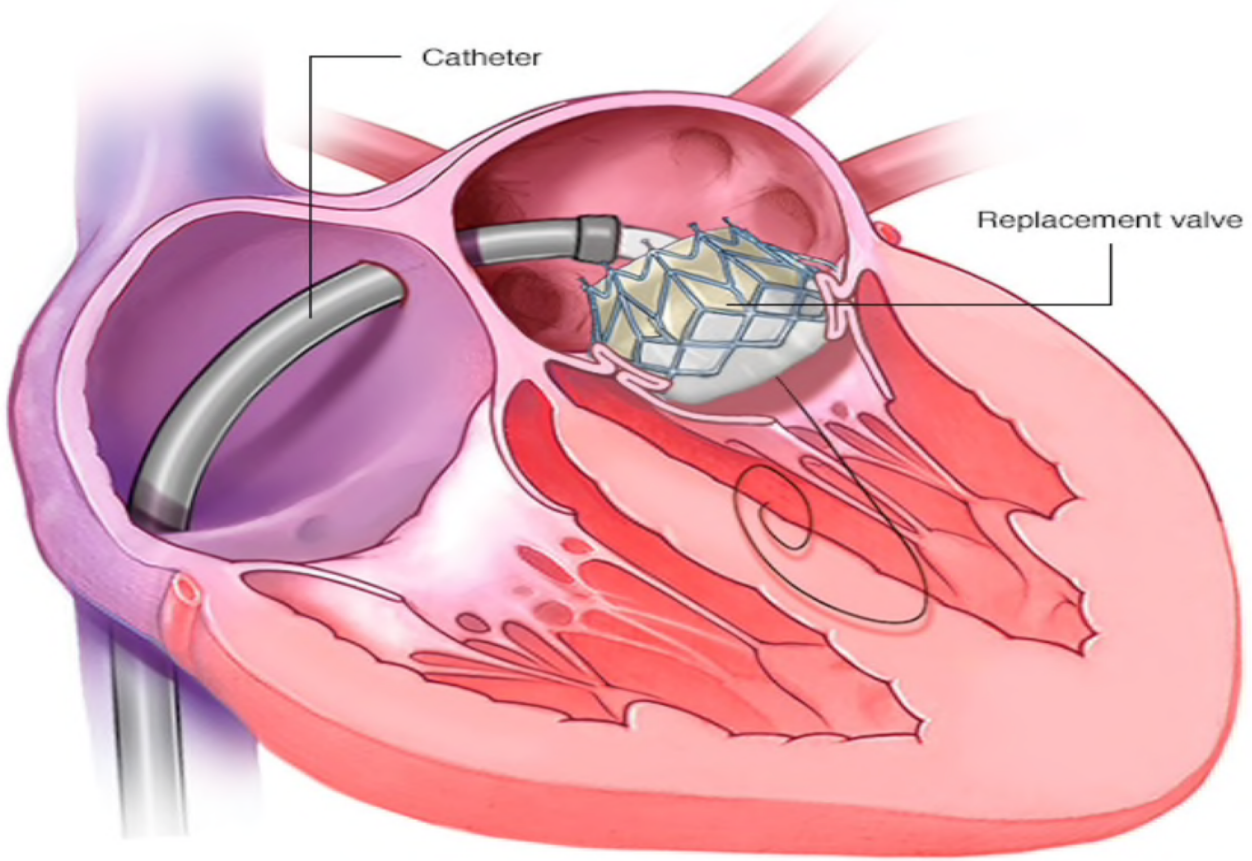

Nouf Alanazi 2019

Mitral Clip

Nouf Alanazi 2019

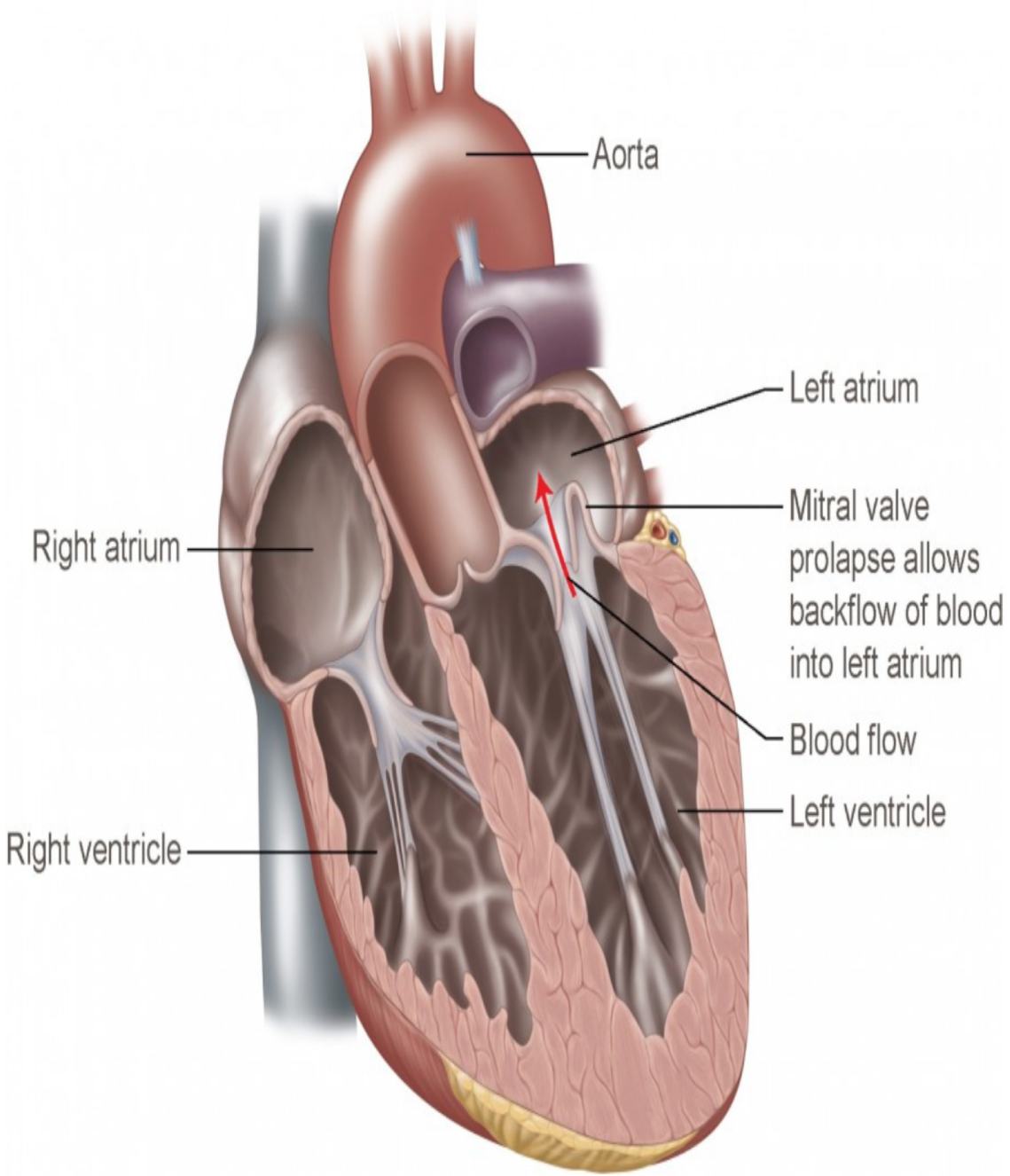

Mitral Valve Prolapse (MVP)

Nouf Alanazi 2019

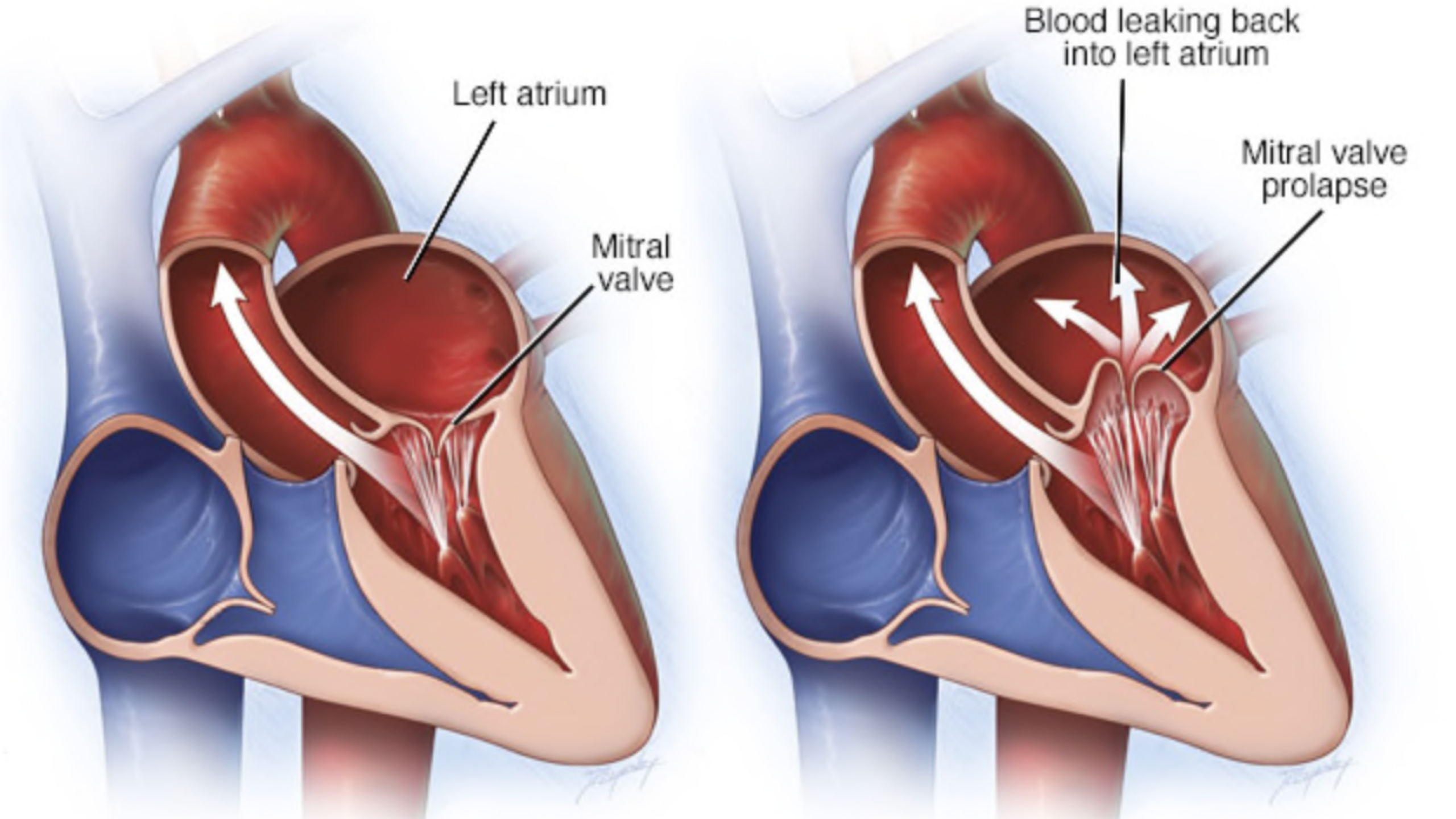
Left atrium
Mitral valve
Blood leaking back into left atrium
Mitral valve prolapse

MVP

- 2.4% of the population
- Female predominance
- Etiologies:

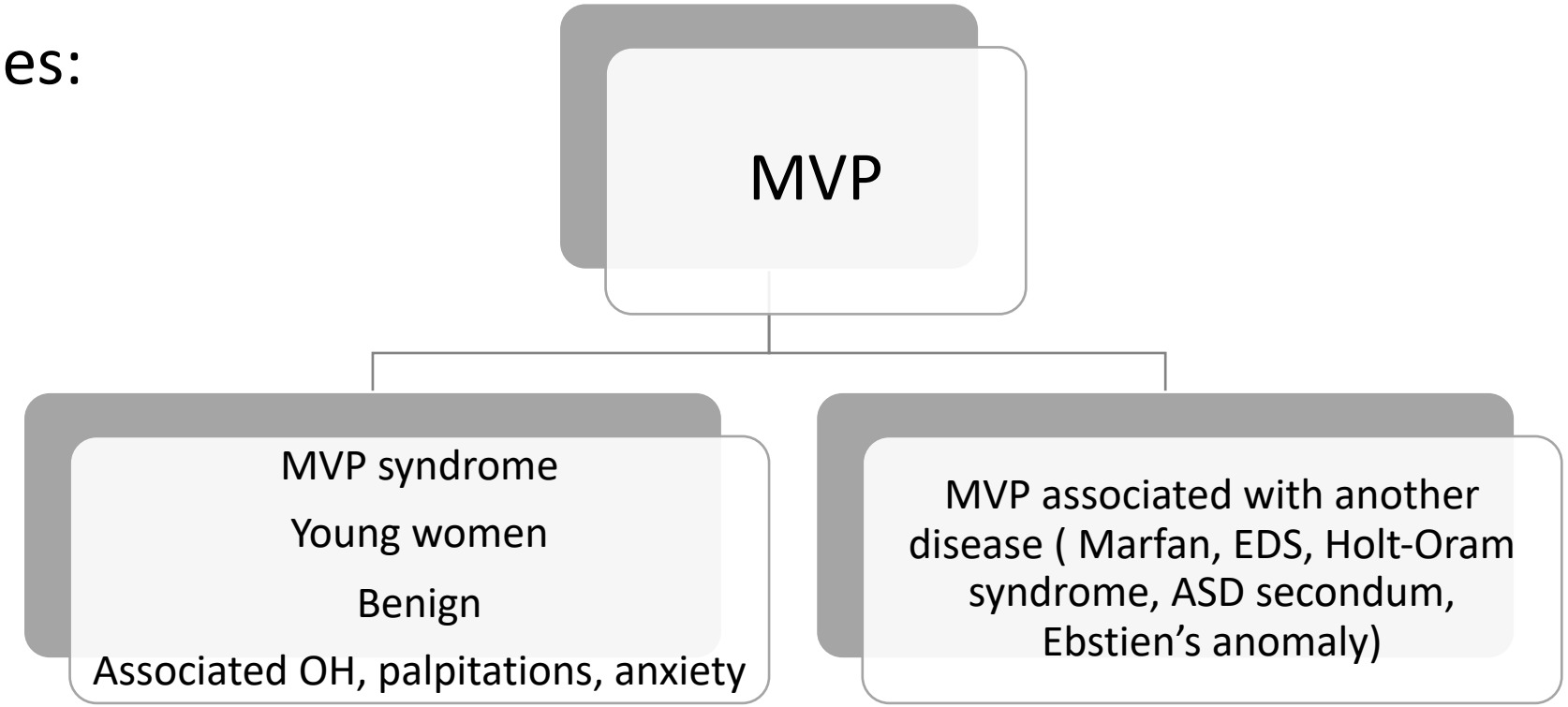

Clinical presentation

- *Atypical chest pain* is the most common symptom .

- *Palpitations* may be experienced because of the abnormal ventricular contraction or because of the atrial and ventricular arrhythmias.

Physical exam

- The most common sign is a ***mid-systolic click*** .
  - ✓ Produced by the sudden prolapse of the valve and the tensing of the chordae tendineae that occurs during systole .
- A late systolic murmur
- Normal S1
- Role of **Dynamic auscultation**

Dynamic auscultation with MVP

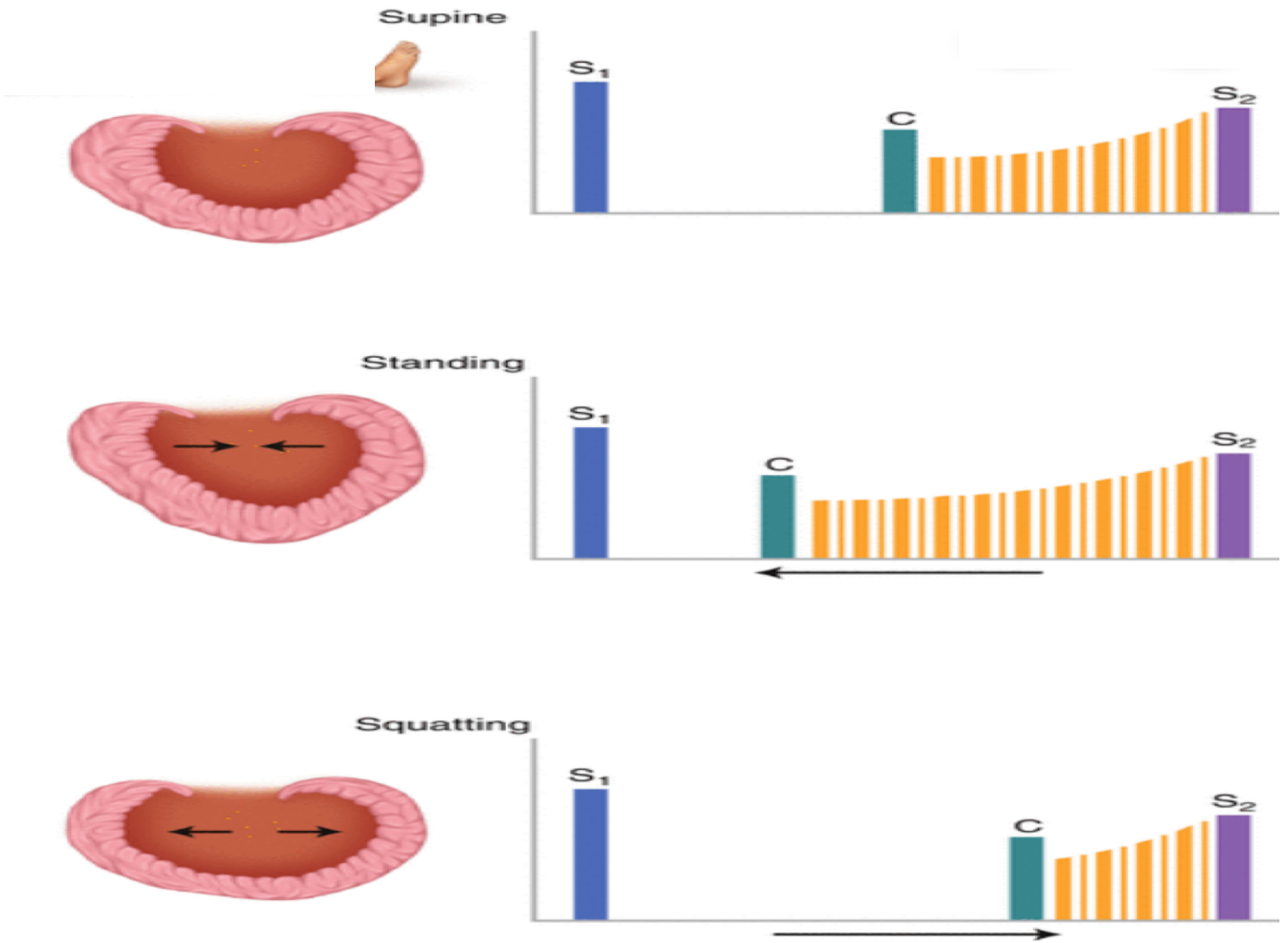

Nouf Alanazi 2019

Away from the affected leaflet Posterior radiates to the base and anterior radiates to axilla & back

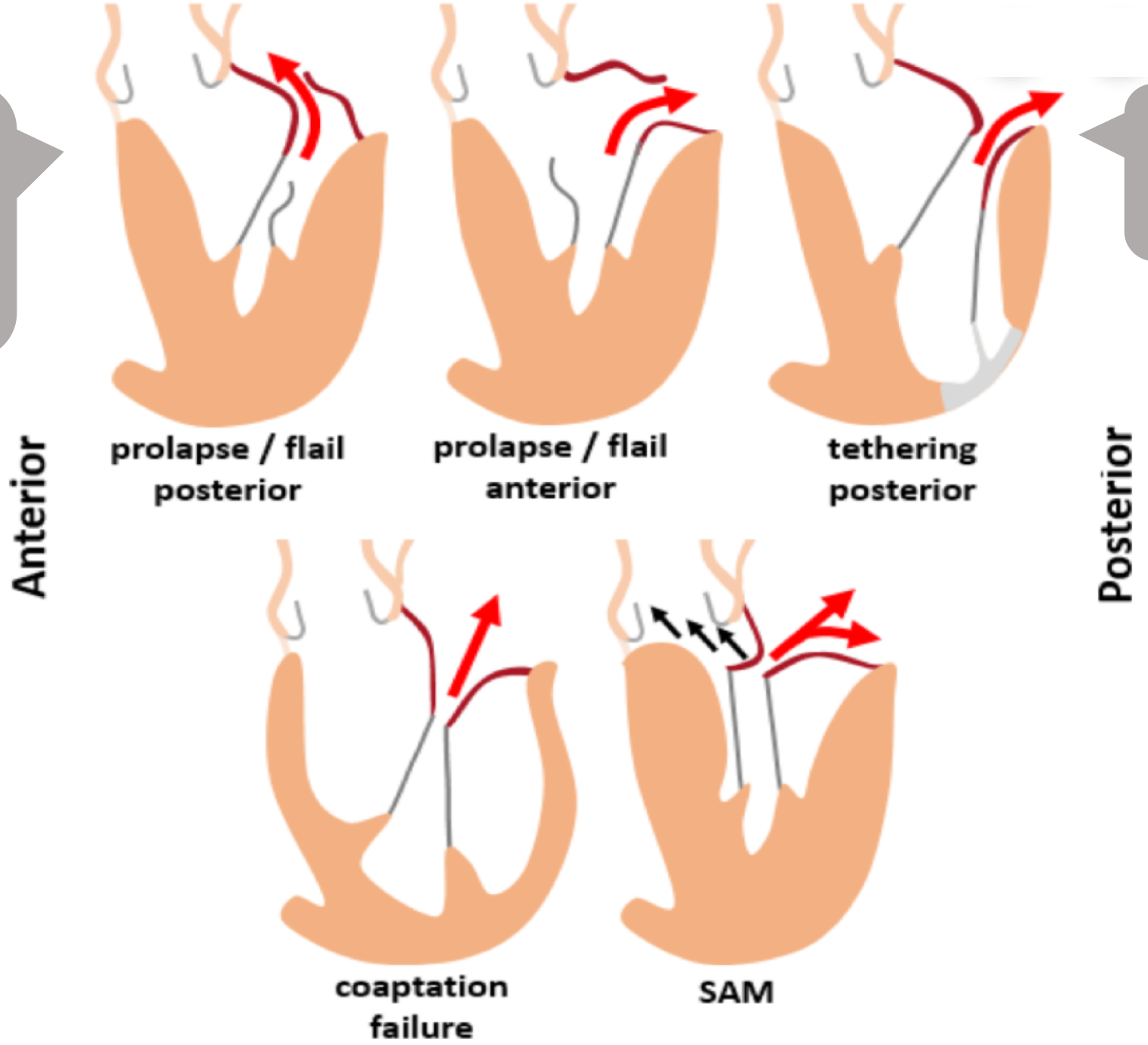

Towards the affected leaflet

Ilanazi 2019

Management

- Beta-blockade is effective for the treatment of the atypical chest pain and palpitations.

- Mitral valve prolapse associated with significant mitral regurgitation and atrial fibrillation, anticoagulation is advised to prevent thromboembolism.

- Surgical intervention (repair versus replacement)

Other Valve pathologies

- Tricuspid stenosis/regurgitation.
- Pulmonary stenosis/regurgitation
- Prosthetic valve dysfunction

Take home message

Over the lifetime of a patient with valvular heart disease (VHD), the most important aspects of medical care are:

- An accurate diagnosis of the cause and severity of VHD
- Measures to prevent further valve dysfunction through prevention of rheumatic fever and endocarditis
- Education about the natural history of disease, including anticipated type and timing of symptom onset
- Interval medical evaluation and imaging to monitor disease progression
- Prompt recognition and treatment of associated cardiac conditions, including (AF), HTN, (CAD), IE, and aortic dilation
- Optimal timing of surgical or transcatheter intervention to correct or ameliorate valve dysfunction.

Nouf Alanazi 2019
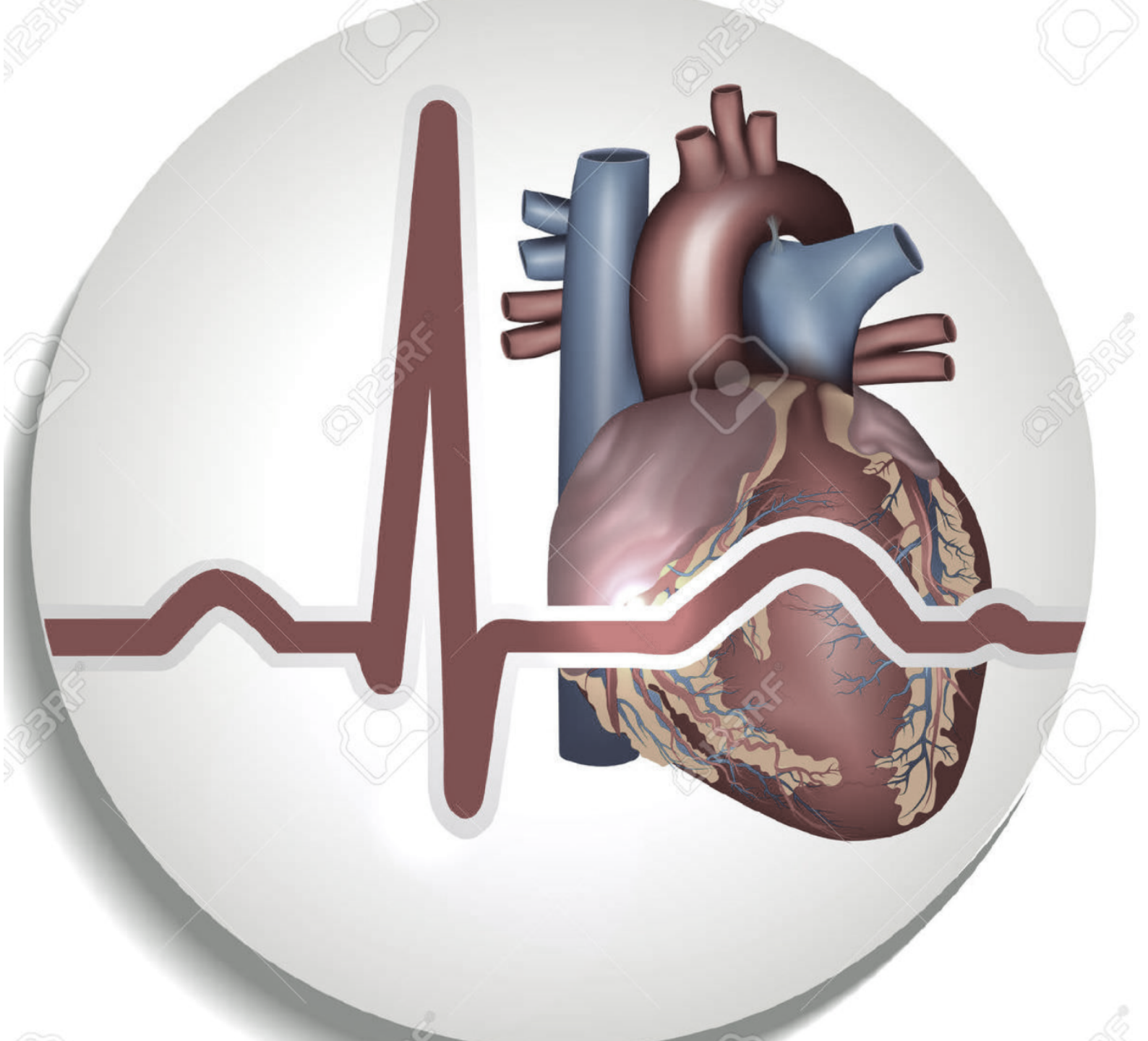
Thank You