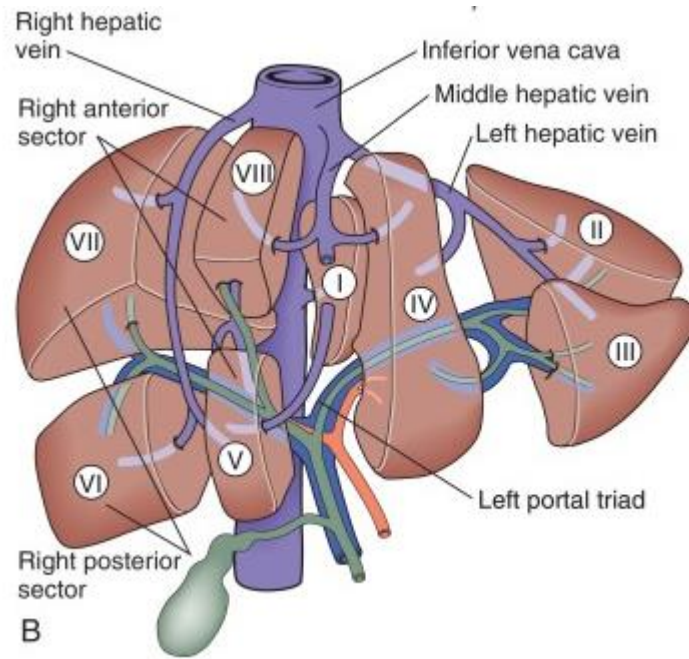
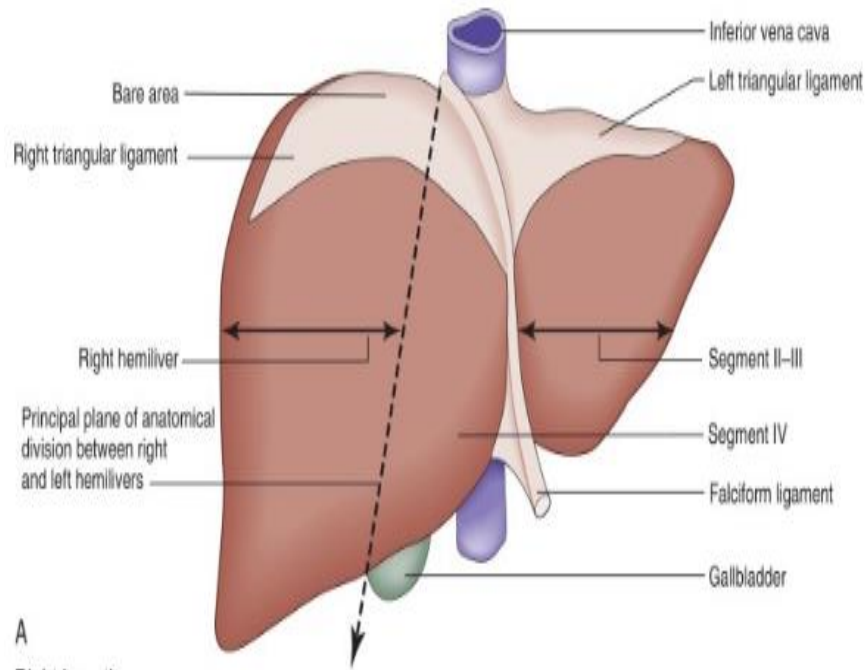


Common surgical disease of the
liver and portal hypertension



Liver function:

- Responsible for storing
 - glucose as glycogen, or converting it to lactate
- Utilization of:
 - Amino acids for hepatic and plasma protein synthesis or catabolised to urea.
- Metabolism of :
 - lipids, bilirubin and bile salts, drugs and alcohol.
- Production of the coagulation factors
 - I, V, XI,
 - Vit. K-dependent factors: II, VII, IX and X as well as proteins C and S and antithrombin.
- Largest reticuloendothelial organ:
 - Kupffer cells : remove damaged red blood cells, bacteria, viruses and endotoxin

Radiology:

- US:
 - Noninvasive
 - It assess intra- and extrahepatic bile duct dilatation or gallbladder distension
It detect space occupying lesion in the liver and pancreas
 - It evaluate vascular system of the liver
 - It detect gallstones

- CT:
 - Identify and stage hepatic, bile duct and pancreatic tumours
 - It demonstrates the:
 - Dilated biliary tree to the level of the obstruction,
 - Vascular abnormality or invasion
 - Lymphadenopathy or distant metastasis
- Positron emission tomography (PET-CT)
 - Tumor staging
 - Distant Metastasis

- MRI:
 - Identify and stage hepatic, bile duct and pancreatic tumours
 - It demonstrates the:
 - Dilated biliary tree to the level of the obstruction,
 - Vascular abnormality or invasion
 - Lymphadenopathy or distant metastasis
 - Liver biopsy
 - Liver disease
 - Liver mass

Congenital abnormality:

- **Liver Cyst**
- **Cavernous haemangiomas**

Liver Cyst

Histology:

- lined by biliary epithelium and contain serous fluid
- Dose not communicate with biliary system

Incidence:

- Sporadic or Polycystic disease

Symptoms : rare

- Due mass effect on surrounding structure

Diagnosis:

- US , CT or MRI

Traetment: symptomatic only

- Surgical : deroofing or resection
- Aspiration

Cavernous haemangiomas

Histology:

- made of cavernous vascular spaces lined by flattened endothelium

Prevalence:

- Most common benign tumours of the liver
- W:M, 6:1

Symptoms: rare

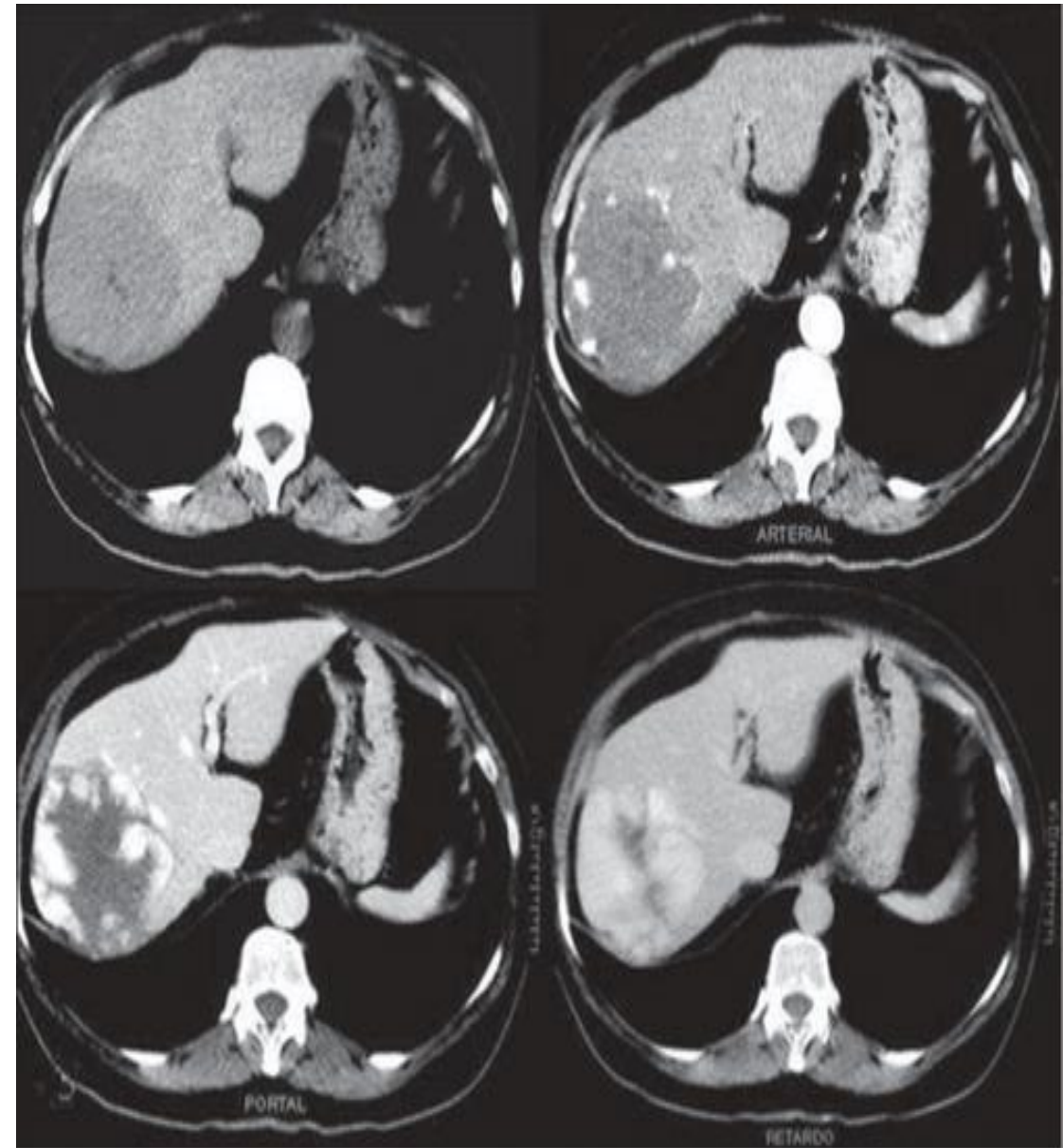
- Due mass effect on surrounding structure

Diagnosis:

- US , CT or MRI
- Centripetal 'filling in' of contrast during dynamic imaging with CT or MRI

Treatment:

- Observation
- Symptomatic:
 - Surgical : resection
 - Rupture: Angioembolization



Hepatic infections

- Pyogenic liver abscess
- Amoebic liver abscess
- Hydatid disease

Pyogenic liver abscess:

Source of infection:

- **Biliary system**
 - Cholelithiasis, Benign strictures, Acute cholangitis, Periapillary tumors
- **Portal vein**
 - Abdominal sepsis
 - Anorectal abscess, Pelvic abscess, Postoperative sepsis, Intestinal perforation, Pancreatic abscess, appendicitis or diverticulitis
- **Hepatic artery:**
 - Septic focus anywhere in the body
 - Endocarditis, Vascular sepsis, Ear, throat, nose, or , dental infection
- **Direct spread from a contiguous organ:**
 - Cholecystitis or empyema of the gallbladder
 - Gastroduodenal perforation
 - Colonic perforation
- **Follow blunt or penetrating injury**
- **Cryptogenic :**
 - infection is indeterminate

- Organism:
 - Gram positive aerobes :
 - *Streptococcus milleri*
 - *Staphylococcus aureus*
 - *Enterococcus* spp.
 - Gram negative aerobes:
 - *Escherichia coli*
 - *Klebsiella pneumonia*
 - *Pseudomonas aeruginosa*
 - *Proteus* spp.
 - *Enterobacter cloacae*
 - Gram positive anaerobes:
 - *Bacteroides* spp.
 - *Fusobacterium* spp.

Clinical feature:

- Symptom:

- Fever
- Right hypochondrium abdominal pain
- Swinging pyrexia
- Chills and rigors
- Marked toxicity
- General malaise and anorexia
- jaundice.

- Examination:

- Look ill
- May be jaundiced
- Vital sign: Tachycardia, high temperature, +/- hypotension
- Abdominal exam: enlarged and tender liver.

Investigation:

Labs:

CBC: ↑ WBC

LFT: elevated

Coagulation profile: normal or elevated

Blood and pus Culture

Radiology:

AXR : air in the liver (gas forming infection)

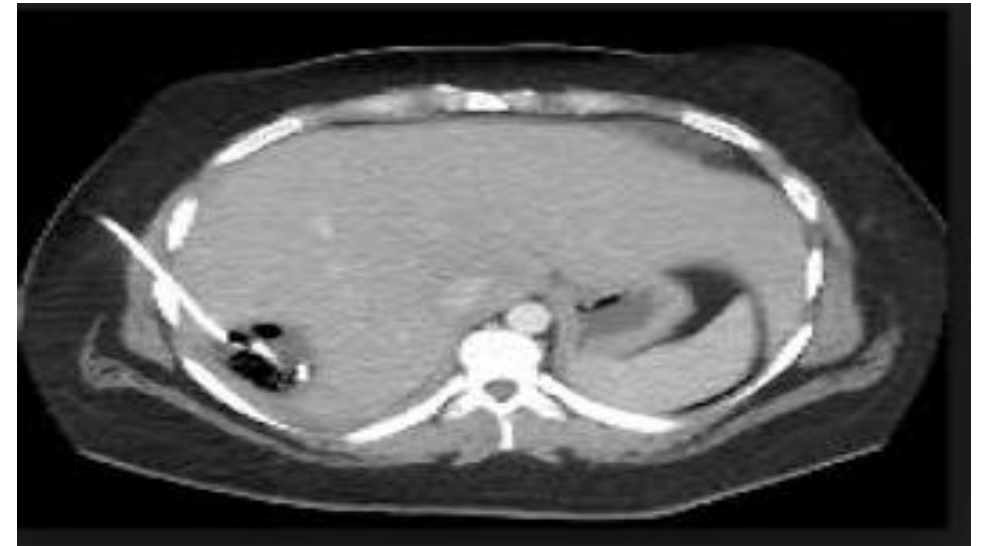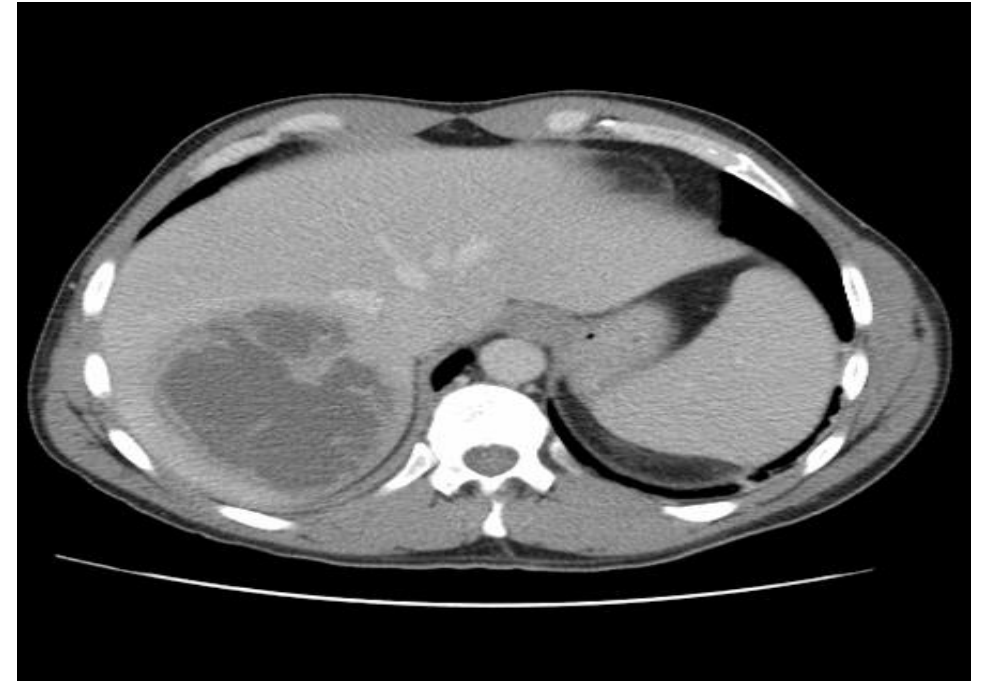
CXR: right side pleural effusion

US: hypoechoic lesion with thick wall , biliary dilatation

CT: central hypodense region and peripheral contrast enhancement during the portal phase of examination

Treatment:

- Percutaneous drainage abscesses under ultrasound or CT guidance
- Antibiotic therapy



- Amoebic liver abscess

- Pathogenesis:

- protozoal parasite infests the large intestine.
 - Ingested cyst in the large intestine → Trophozoites → penetrate the mucosa → portal venous system → liver.

- Organism:

- *Entamoeba histolytica*

- Clinical feature:

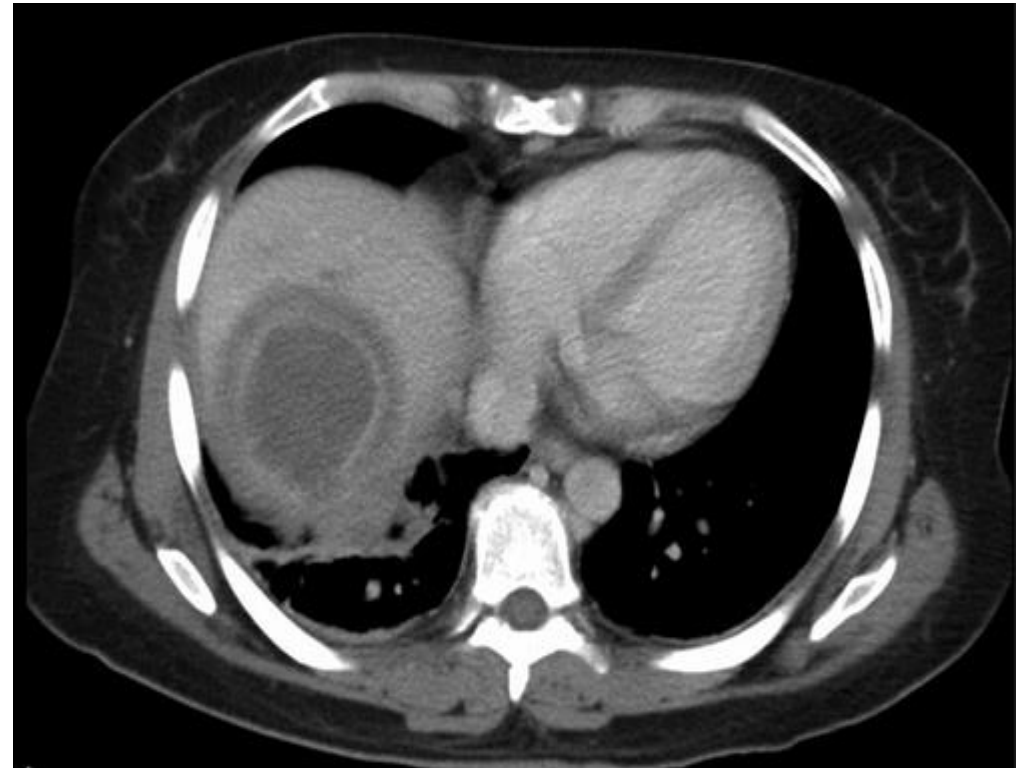
- **Symptom:** Right upper quadrant pain ,anorexia, nausea, weight loss and night sweats, diarrhea.
 - **Physical examination:** Tender enlargement of the liver +/- jaundice

Investigation:

- **Labs:**
 - CBC: ↑ WBC
 - **Direct and indirect serological tests:** (amoebic protein)
 - Indirect haem-agglutination [IHA]
 - Enzyme-linked immunosorbent assay [ELISA]
 - **Stools:** amoebae or cysts
- **Radiology:**
 - **US:** well-defined margins; they are hypoechoic lesion
 - **CT:** well-defined lesions with complex fluid, enhancing wall with a peripheral zone of edema around the abscess

Treatment:

- **Antibiotics:**
 - Metronidazol
 - Diloxanide furoate (carrier)
- **Percutaneous aspiration:**
 - No improvement after 3 days of antibiotics
 - Pyogenic abscess



Hydatid disease

Pathogenesis:

- infestation one of two forms of tapeworm in the gastrointestinal system.
- Ingested ova hatch in the duodenum → portal system → liver
- Hydatid cyst :
 - Pericyst: host tissue formed by the body as a reaction to the parasite
 - Ectocyst: external layer of the cyst
 - Endocyst: germinative layer

Organism:

- *Echinococcus granulosus* and *E. multilocularis*

Clinical feature:

- Abdominal pain or no symptom
- Rupture: anaphylaxis
- Communication with Biliary system: obstructive jaundice

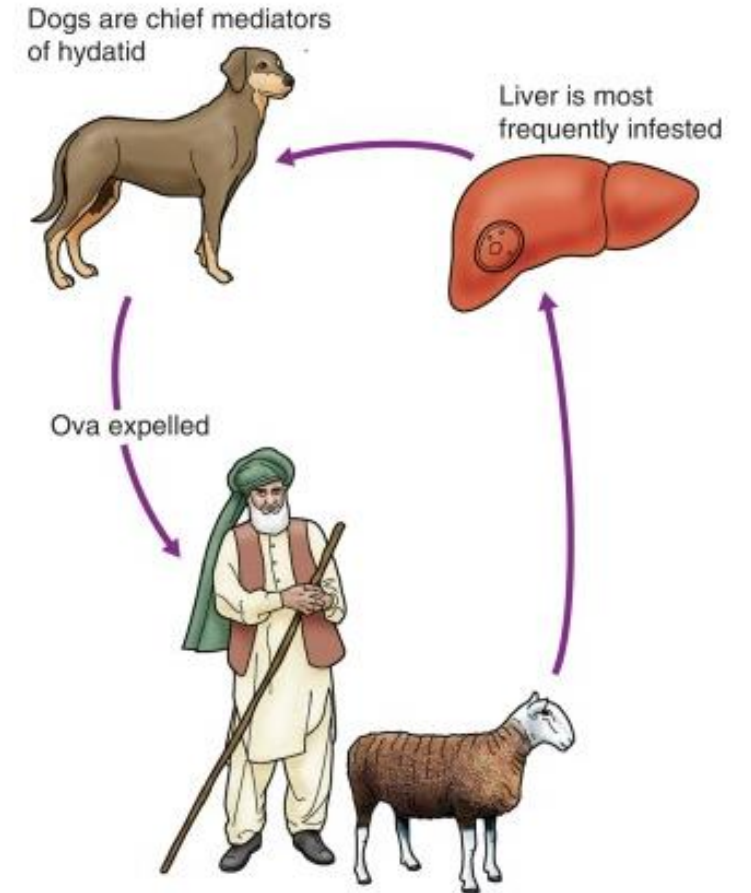


Fig. 14.10

Life cycle of *Echinococcus granulosus* .

Investigation:

Labs:

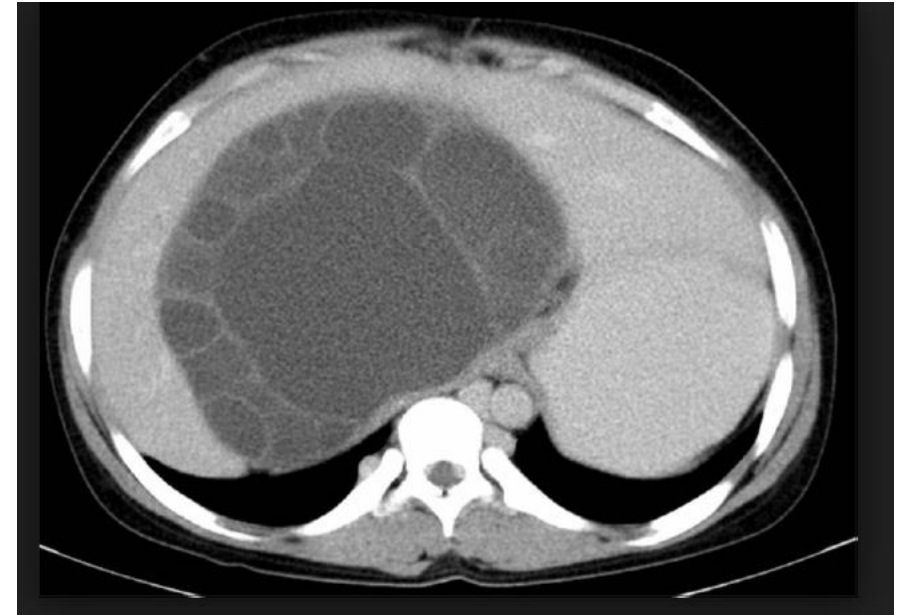
- **CBC:** eosinophilia
- **Serology test:**
 - Immunoelectrophoresis (IEP) : Not for followup
 - enzyme-linked immunosorbent assay (ELISA): IgE or IgG₄ (4 years) , IgM (6 months)
 - Immunoblotting: first-line test

Radiology:

- AXR: calcification
- US, CT MRI: well-defined, circumscribed cystic lesions with a clear membrane , daughter cysts

Treatment :

- Medical : albendazole or mebendazole
- Surgical :
 - Deroofing
 - Percystectomy
 - Liver resection
- Puncture–aspiration–injection–reaspiration (PAIR)



Tumours of the liver

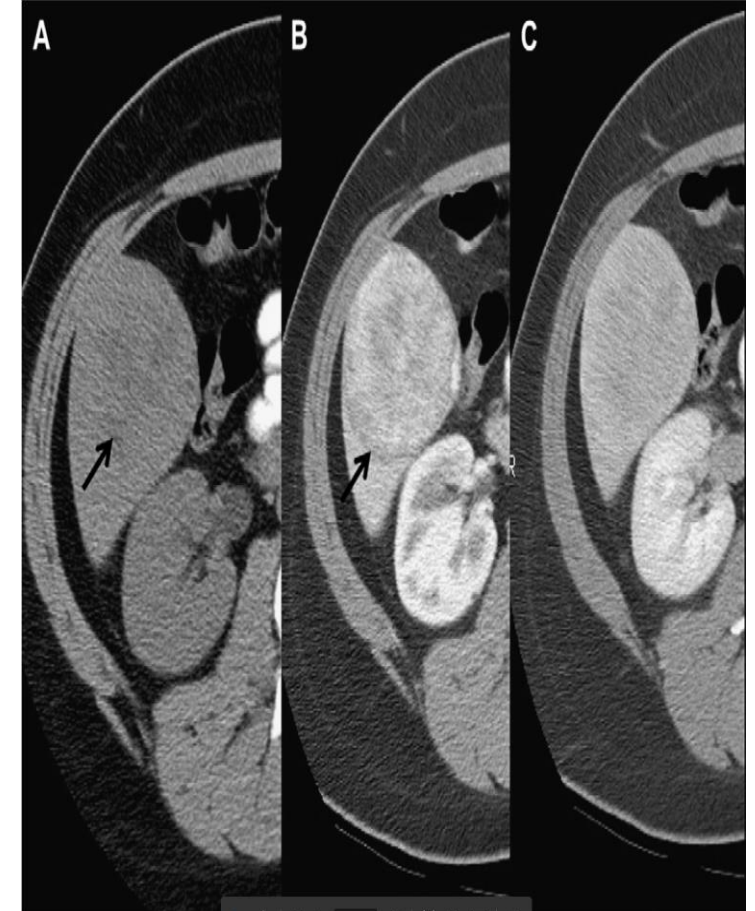
- Benign hepatic tumours :
 - Focal nodular hyperplasia (FNH)
 - Liver cell adenoma

- Malignant tumours of the liver :
 - Primary:
 - Hepatocellular carcinoma (hepatoma)
 - Cholangiocarcinoma
 - Angiosarcoma
 - Hepatic mucinous cystic neoplasm

 - Metastatic tumours

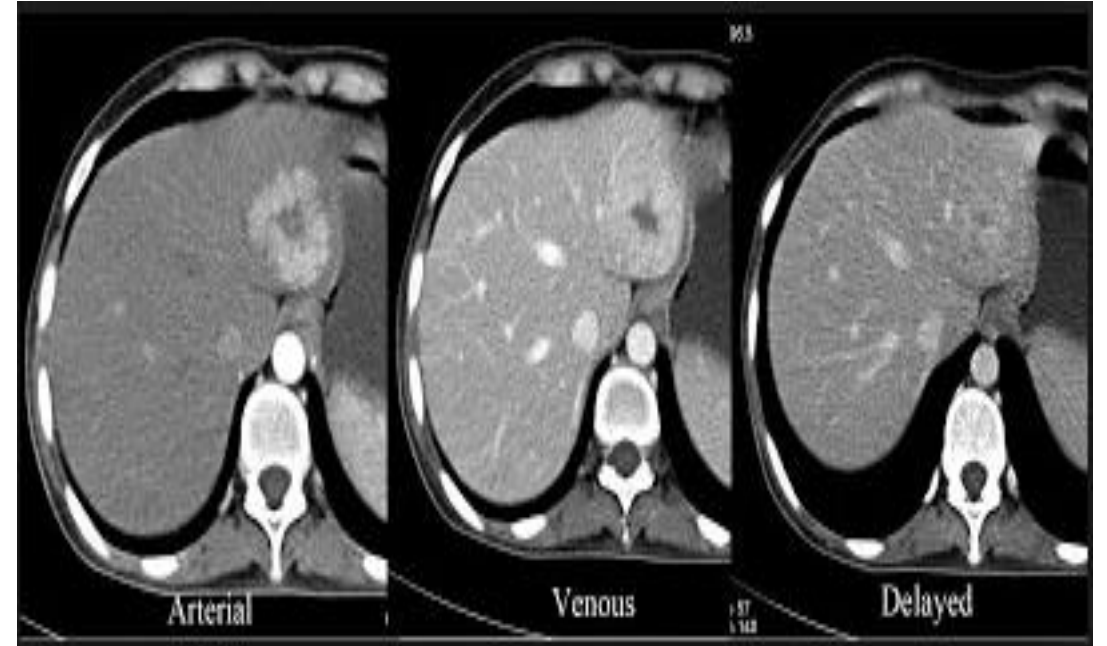
Liver cell adenoma

- W:M , 9:1
- Estrogen and anabolic steroid play a causative role.
- **Clinical feature:**
 - Right Upper Quadrant pain
- **Complication:**
 - Rupture
 - Malignant transformation
- **Investigation:**
 - US , CT, MRI
- **Treatment:**
 - Female :
 - < 5 cm : stop oral OCP
 - > 5 cm : surgery
 - Male: surgery
 - Rupture: Angioembolization



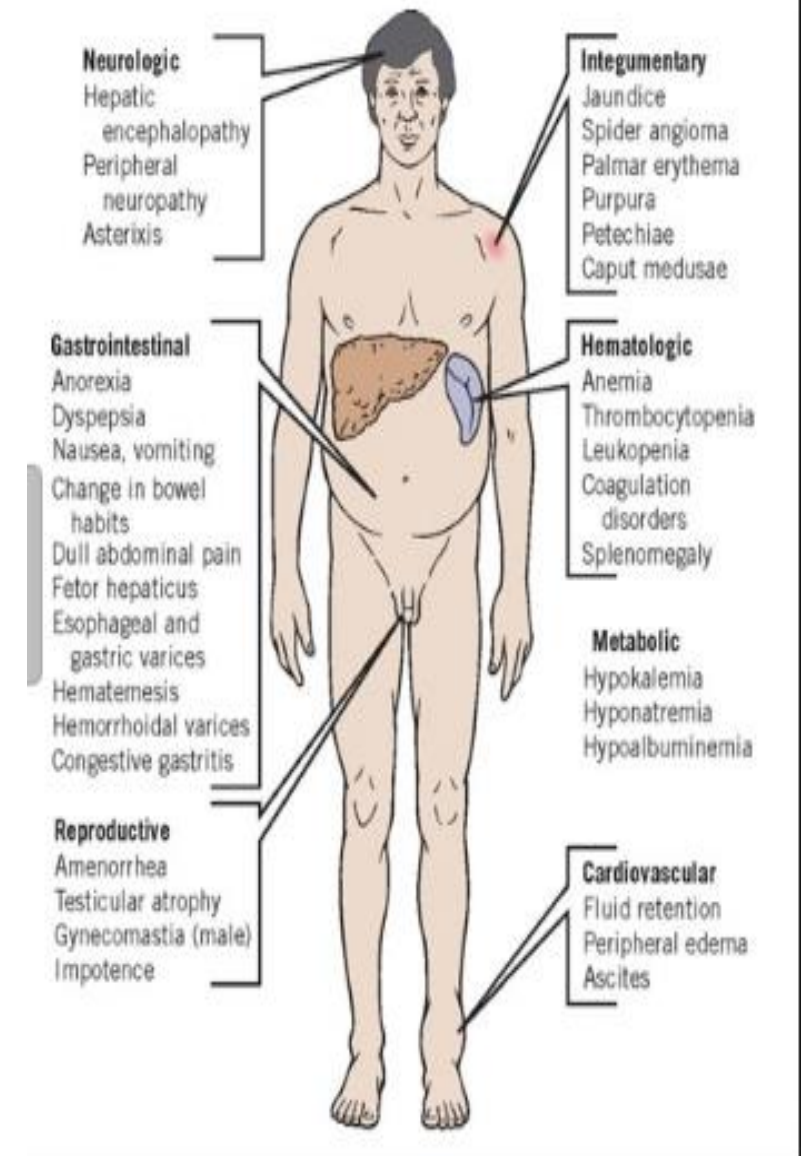
Focal nodular hyperplasia (FNH)

- Mostly Female
- Clinical feature:
 - Right Upper Quadrant pain
- Investigation:
 - US , CT, MRI
- Treatment:
 - Observation



Hepatocellular carcinoma (hepatoma)

- M > F
 - Liver cirrhosis : Hib B or C, alcoholic
 - Aflatoxin
 - Non cirrhosis : Hib B.
- **Clinical feature:**
 - **Liver cirrhosis:**
 - liver disease symptoms
 - abdominal pain, weight loss, abdominal distension, fever and spontaneous intraperitoneal haemorrhage
 - **Non cirrhosis :**
 - abdominal pain or swelling



- Investigation:

- LFT, CBC, coagulation profile

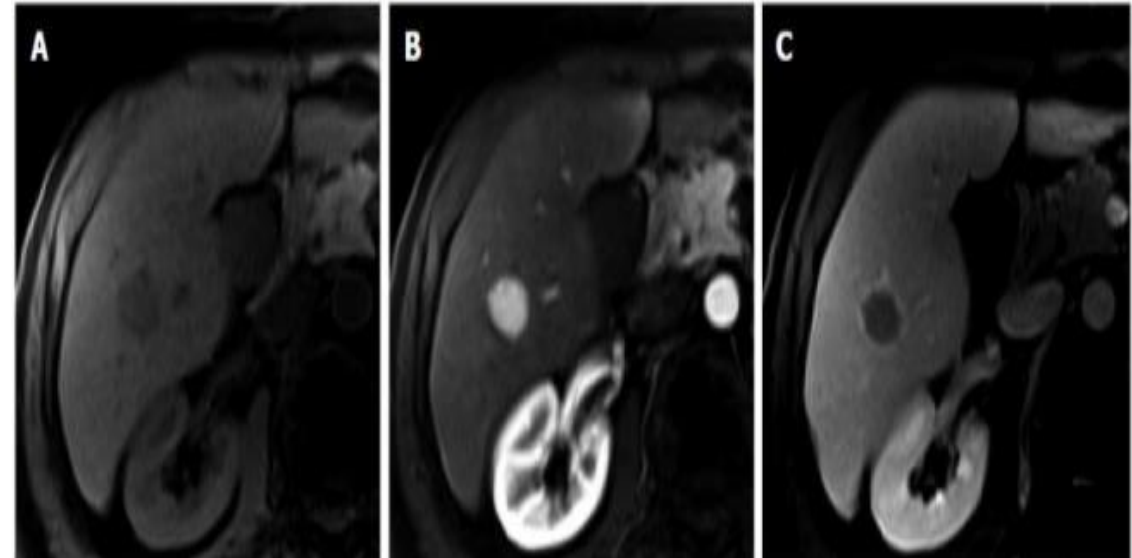
- Screening:

- US abdomen
- Alpha-fetoprotein (AFP)

- CT , MRI : liver lesion with arterial enhancement and early washout on portovenous phase

- Diagnosis:

- > 1 cm: one image with characteristic feature
- Cytology: *if the nodule is > 1 cm and feature is not typical*
- < 1 cm: *3-6 month followup*



- Treatment :
 - Transplantation:
 - Milan criteria: single tumour of 5 cm or less in diameter, or with no more than three tumour nodules each one 3 cm or less in size
 - Liver resection:
 - Non cirrhotic patient
 - Child A liver cirrhosis
 - Locoregional therapy:
 - TACE
 - Local ablation : RFA, microwave energy
 - Chemotherapy:
 - Sorafenib

Cholangiocarcinoma

- Adenocarcinoma may arise anywhere in the biliary tree
- Risk factor:
 - chronic parasitic infestation of the biliary tree
 - Choledochal cysts
- Clinical feature:
 - Jaundice
 - Abdominal pain, weight loss, anorexia
- Investigation:
 - Labs:
 - LFT : obstructive Jaundice
 - CBC , Coagulation Factor , CA 19-9
 - Radiology:
 - CT , MRI , MRCP, ERCP, PTC
- Treatment:
 - Curative:
 - Resection
 - Metastatic:
 - Palliative chemotherapy

- Metastatic malignant tumor:

- Gastrointestinal tract
- Breast
- ovaries
- Bronchus
- Kidney

- Diagnosis:

- Tumor marker: CEA, CA 19-9, CA 125
- Radiology : CT , MRI, PET CT

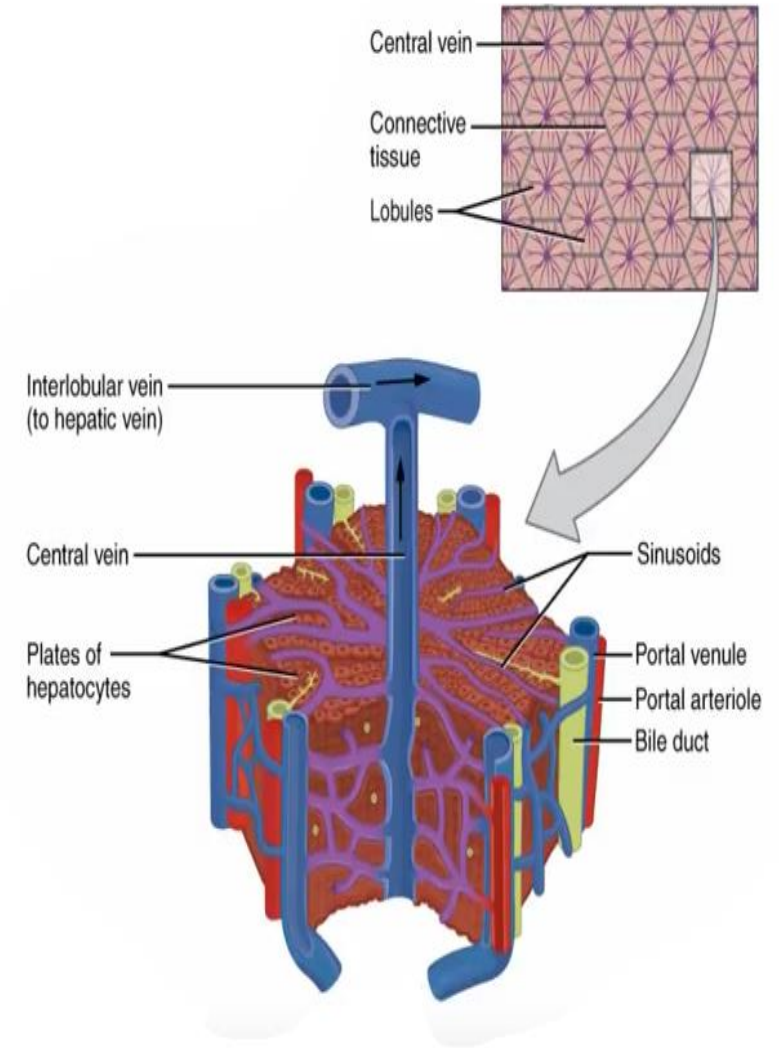
- Treatment:

- Resection
- Palliative chemotherapy

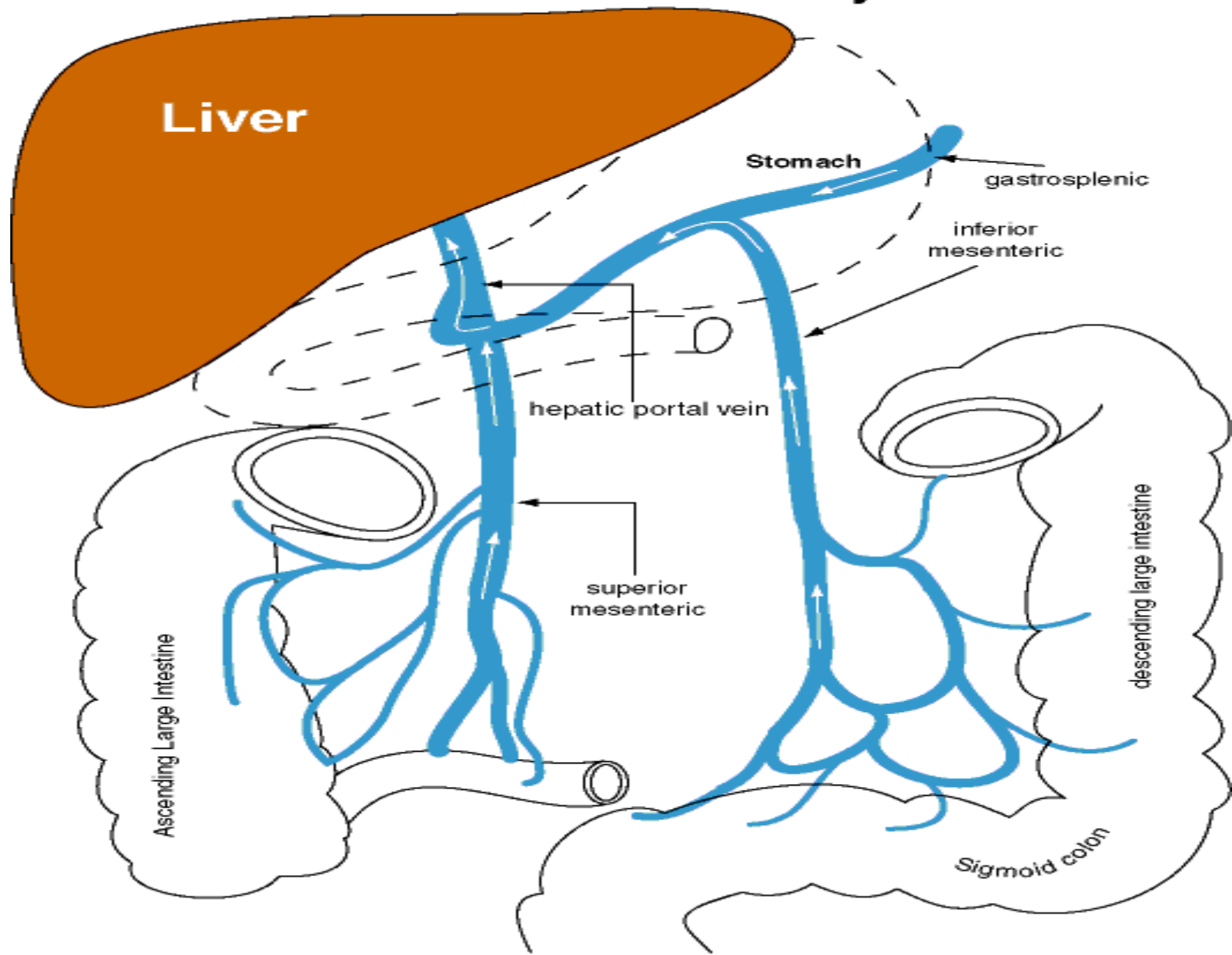
Portal hypertension

- Pressure (P) = Flow (F) X Resistance (R)
- Portal pressure : 3 – 6 mm Hg
 - PP > 10 : shunting
 - PP > 12: bleeding
- Normal elevation:
 - Eating
 - Exercise
 - Valsalva
- Changes in either F or R affect the pressure.

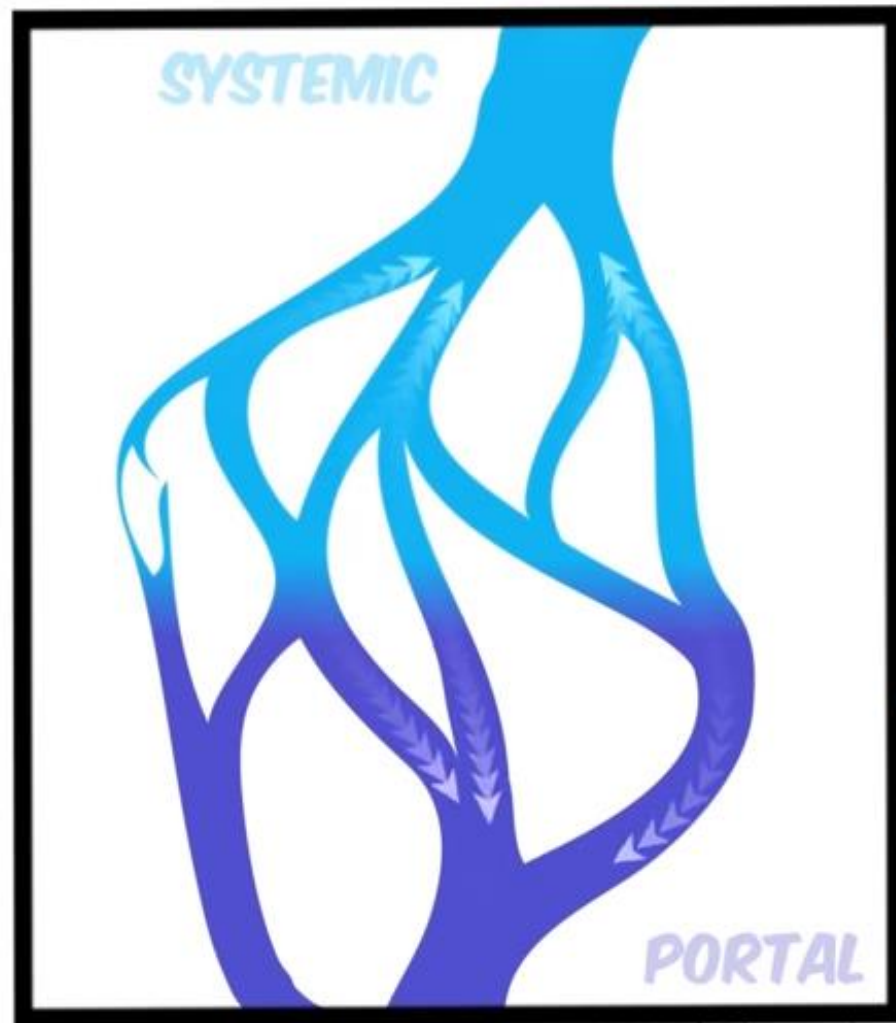
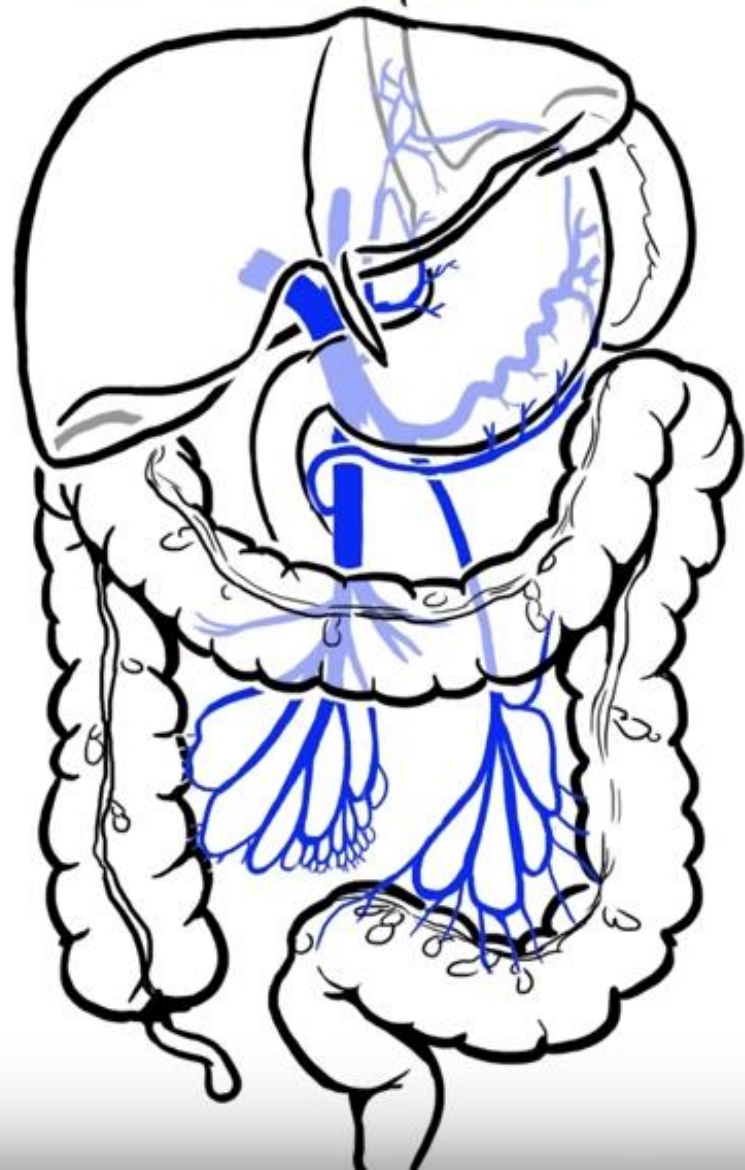- Liver disease :
 - ↓ portal vascular radius.
 - splanchnic arteriolar vasodilatation
 - Decreased sensitivity to catecholamin
 - Increased endogenous vasodilator (NO, prostacycline).



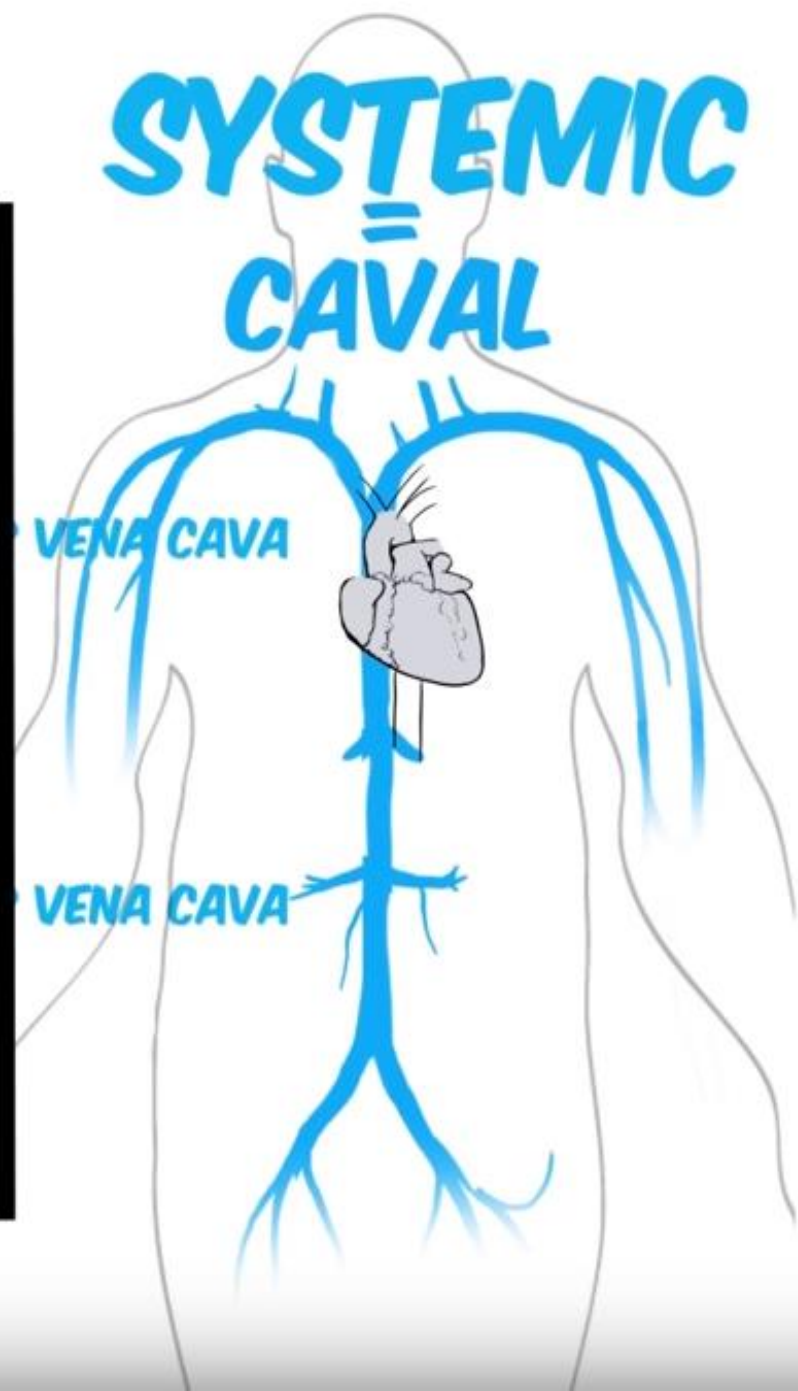
Hepatic portal System



PORTAL




SYSTEMIC CAVAL



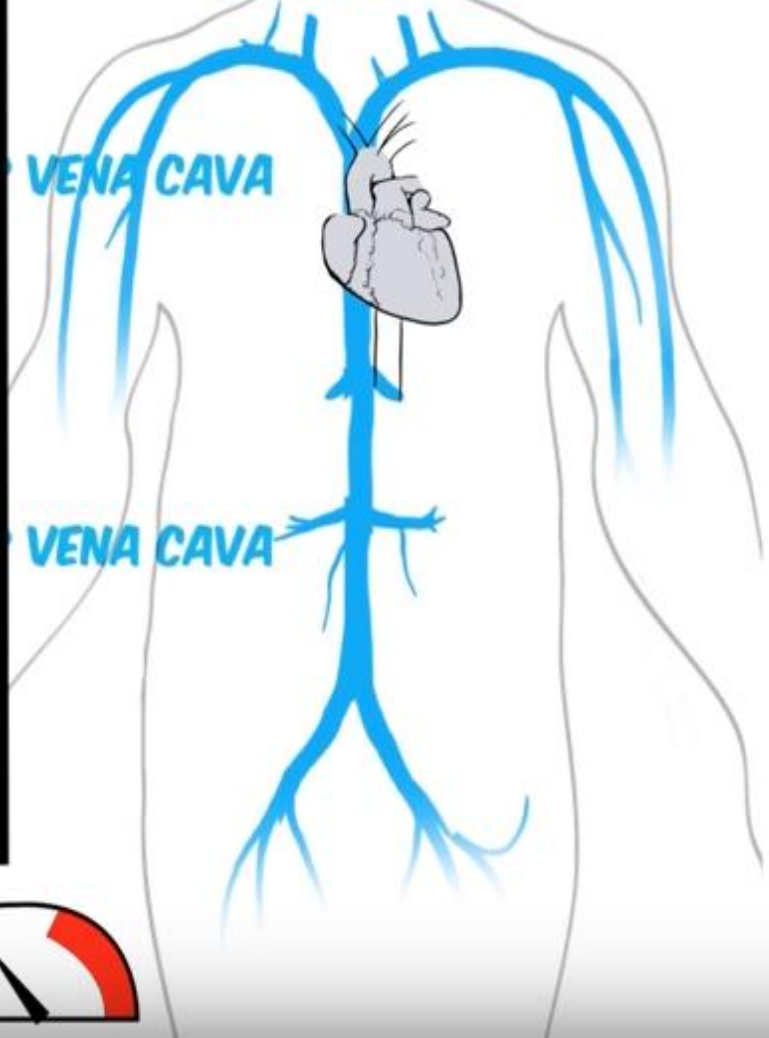
PORTAL



PORTOSYSTEMIC ANASTAMOSIS



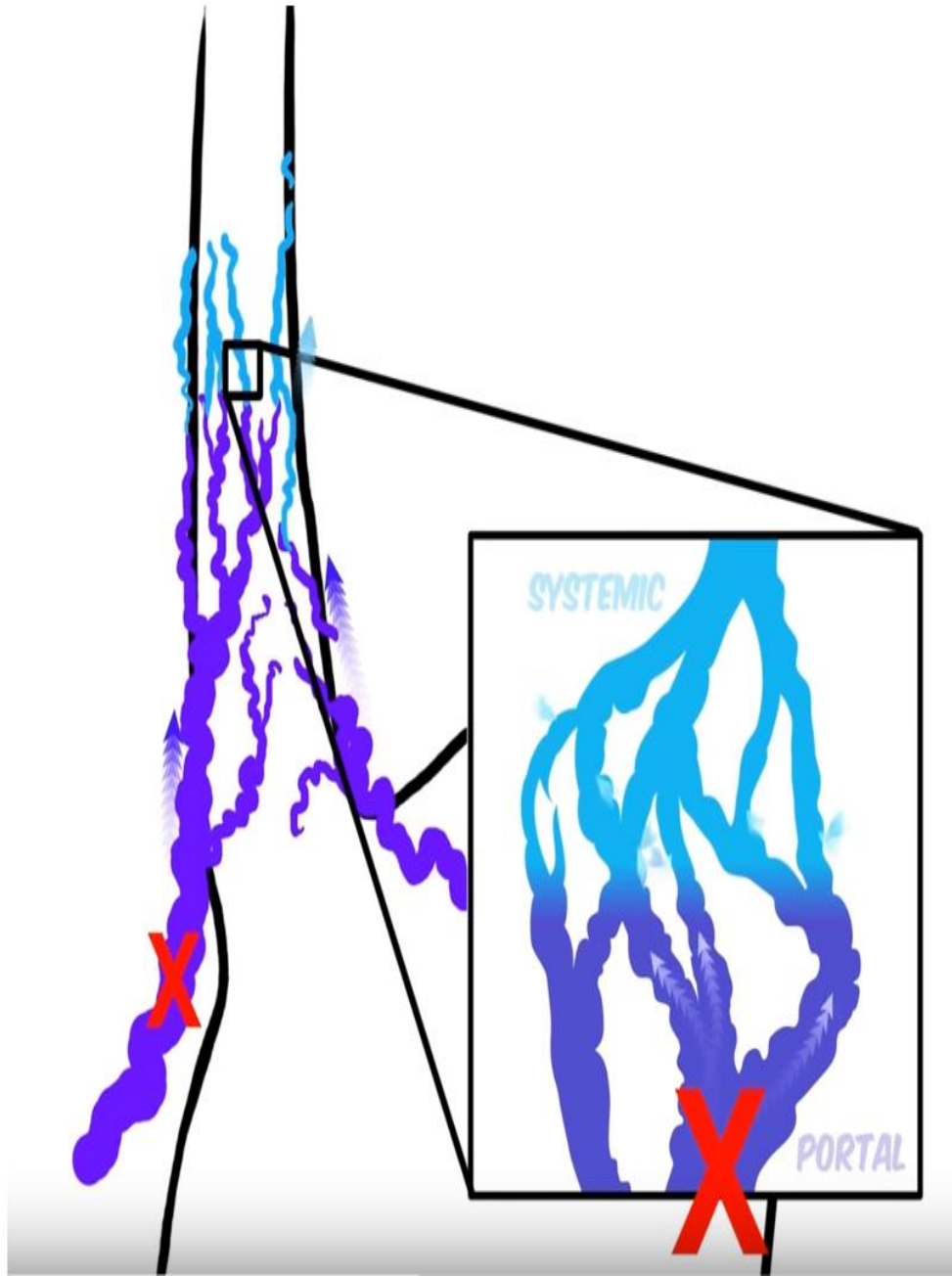

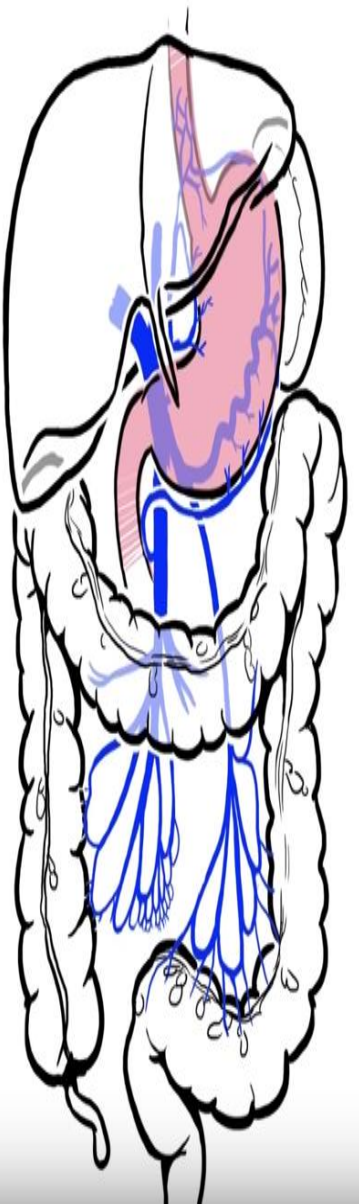
SYSTEMIC CAVAL



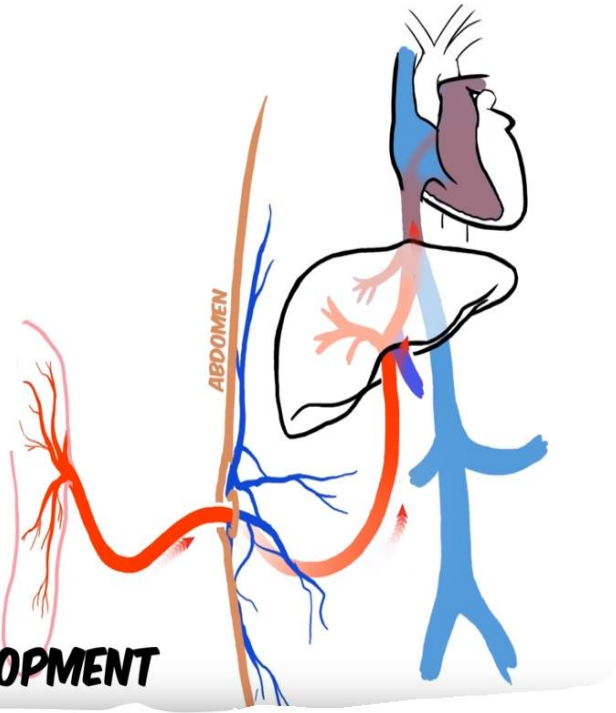
PRESSURES



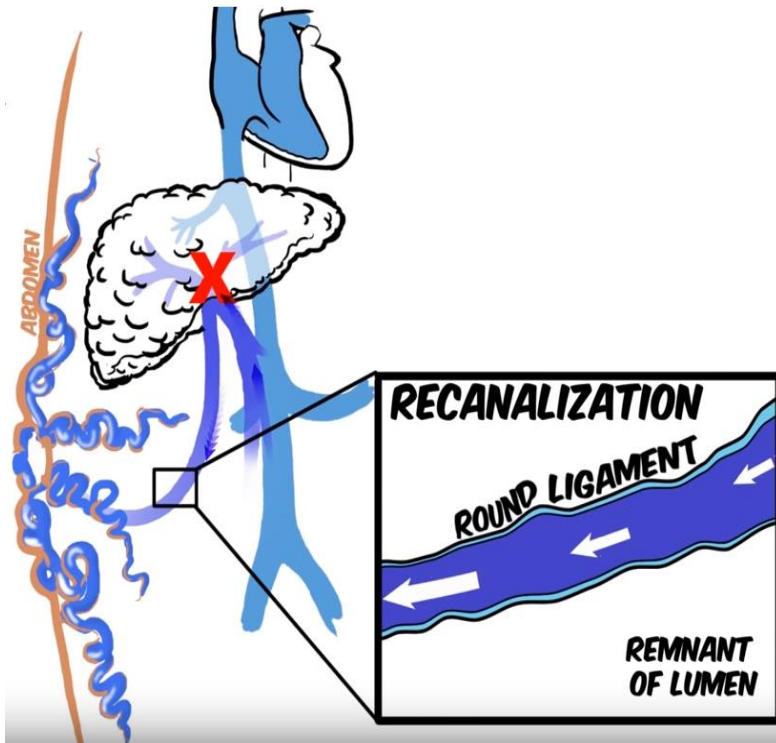
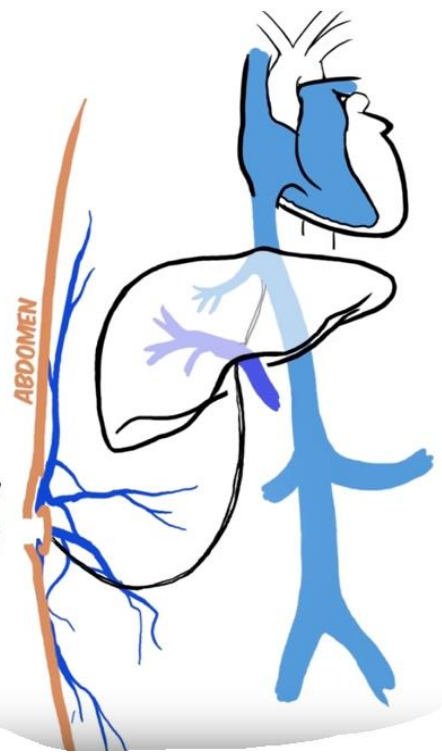
ESOPHAGEAL VARICES



**FETAL
DEVELOPMENT**

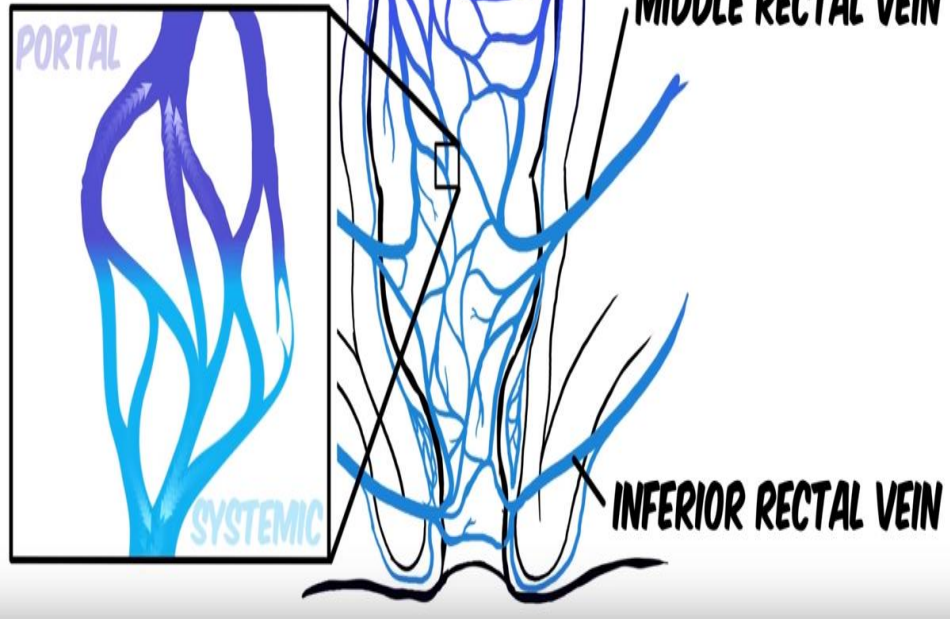


**LIGAMENTUM
TERES HEPATIS**
ROUND LIGAMENT
OF LIVER



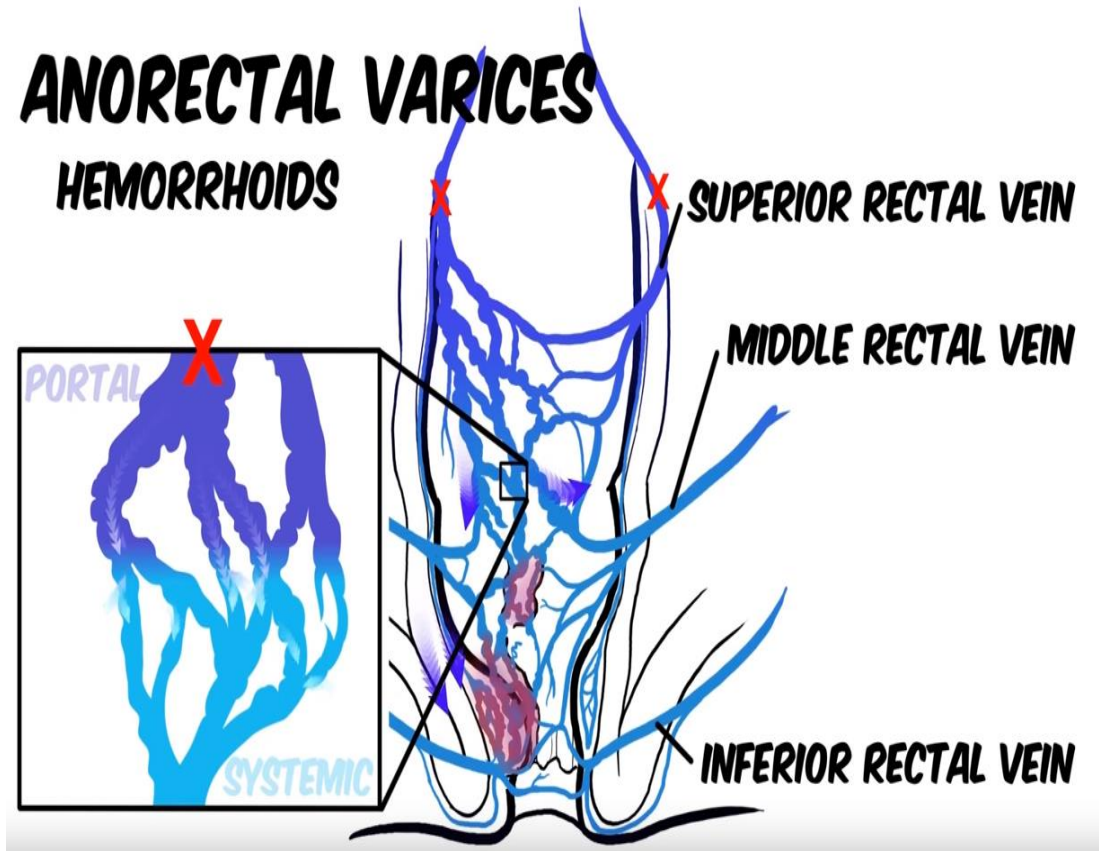
ANORECTAL VARICES

HEMORRHOIDS



ANORECTAL VARICES

HEMORRHOIDS



Causes of Portal HTN

Classification	Cause
Prehepatic	Portal or splenic vein thrombosis Increased portal flow: arteriovenous fistula, massive splenomegaly from primary hematologic disease
Hepatic	Presinusoidal: schistosomiasis, other periportal disorders (eg, primary biliary cirrhosis, sarcoidosis, congenital hepatic fibrosis), idiopathic portal hypertension Sinusoidal: cirrhosis (all etiologies) Postsinusoidal: veno-occlusive disease
Posthepatic	Hepatic vein thrombosis (Budd-Chiari syndrome) Membranous obstruction of inferior vena cava Cardiac causes (eg, constrictive pericarditis, restrictive cardiomyopathy)

Mortality/Morbidity

- Variceal hemorrhage most common complication of PH
- 90% with cirrhosis develop varices.
- 30% of these bleed.
- The first episode is estimated to carry a mortality of 30-50%.

Clinical feature

- Symptom:
 - Hematemesis +/- melena
 - Chronic liver disease symptom
- Examination:
 - Hypotension, tachycardia
 - Stigmata of liver disease

Assesment

- **Acute setting :**
 - ABC
 - History
- **Elective setting:**
 - History of chronic liver disease
 - Other differential diagnosis
 - Stigmata of liver disease

Investigation:

- **Labs:**

- **Acute setting**

- CBC , LFTs, Albumin, PT/PTT, U&E, CXR
 - Cross match

- **Chronic setting:**

- Hepatitis serology, ANA, Antimitochondrial antibodies, Alpha 1-antitrypsin deficiency

- **Radiology:**

- CXR
 - US, CT

- **Endoscopy**

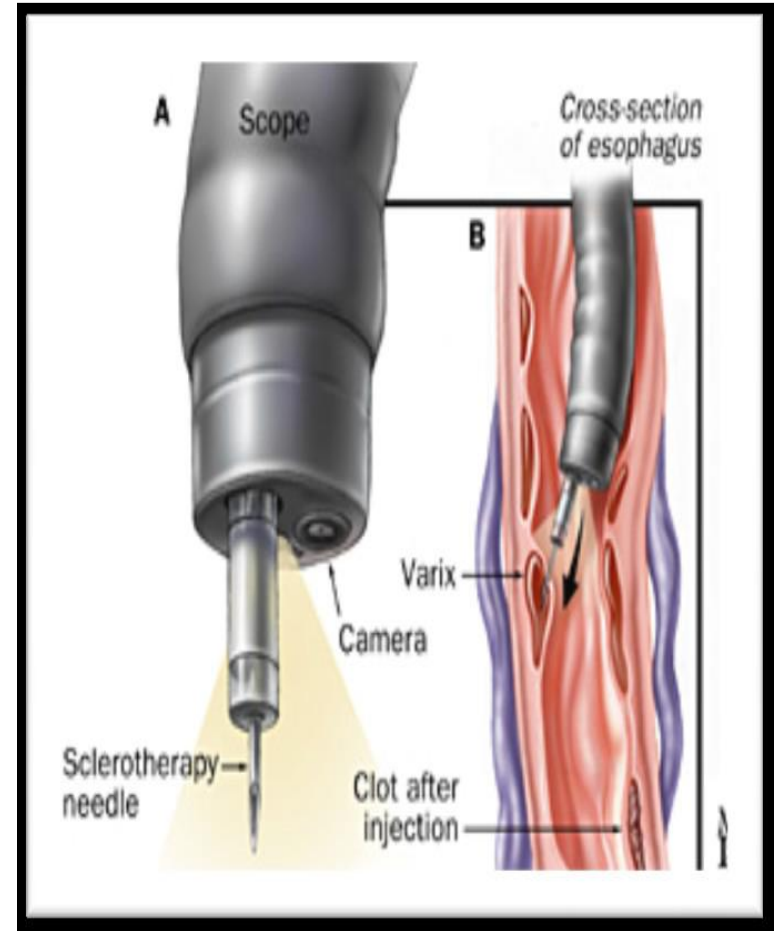
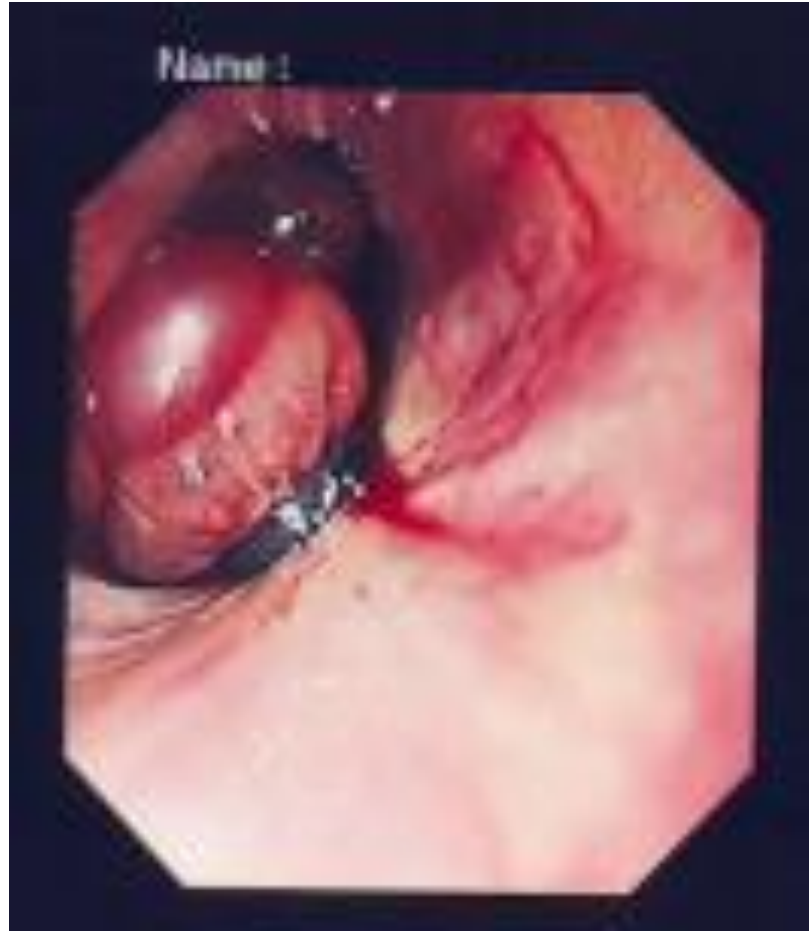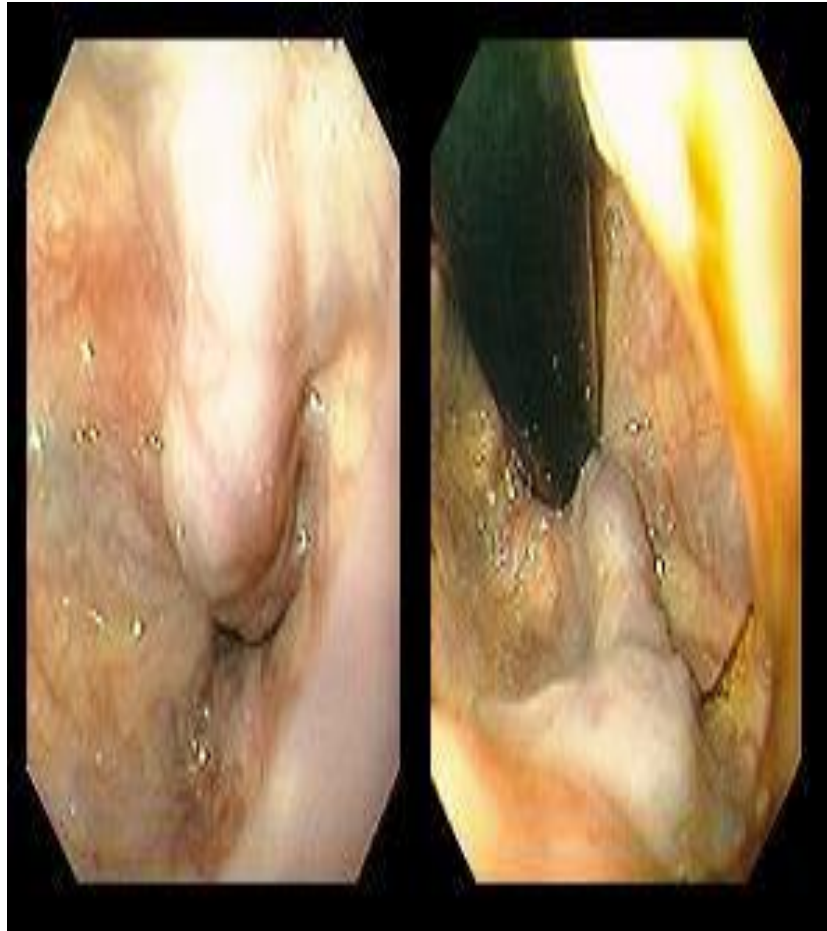- **Hepatic venous pressure gradient**

Points scored			
Criterion	1	2	3
Encephalopathy	None	Minimal	Marked
Ascites	None	Easily controlled	Intractable
Bilirubin ($\mu\text{mol/L}$)	< 35	35–50	> 50
Albumin (g/L)	> 35	28–35	< 28
Prothrombin ratio	< 1.7	1.7–2.3	> 2.3

Grade A = 5–6 points; grade B = 7–9 points; grade C = 10–15 points.

Treatment

- Endoscopy:
 - Endoscopic variceal ligation (EVL)
 - Sclerotherapy
- Pharmacology:
 - Octreotide
 - Vasopressin
- Balloon tamponade:
 - Minnesota
 - Sengstaken–Blakemore tube
- Transjugular intrahepatic portosystemic stent shunting (TIPSS)
- Surgical:
 - Shunt:
 - Selective
 - Non-selective
 - Devascularization



Balloon tamponade

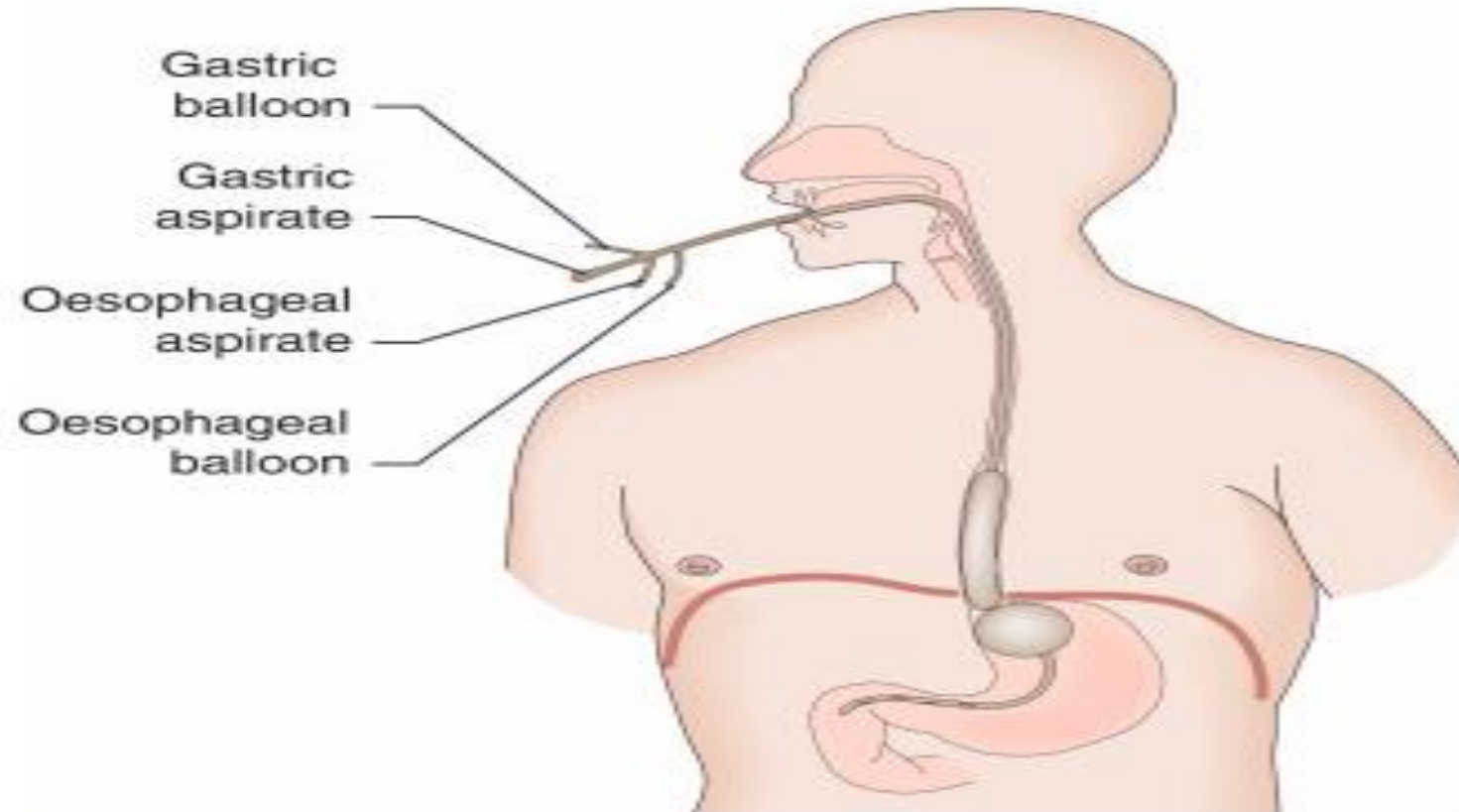
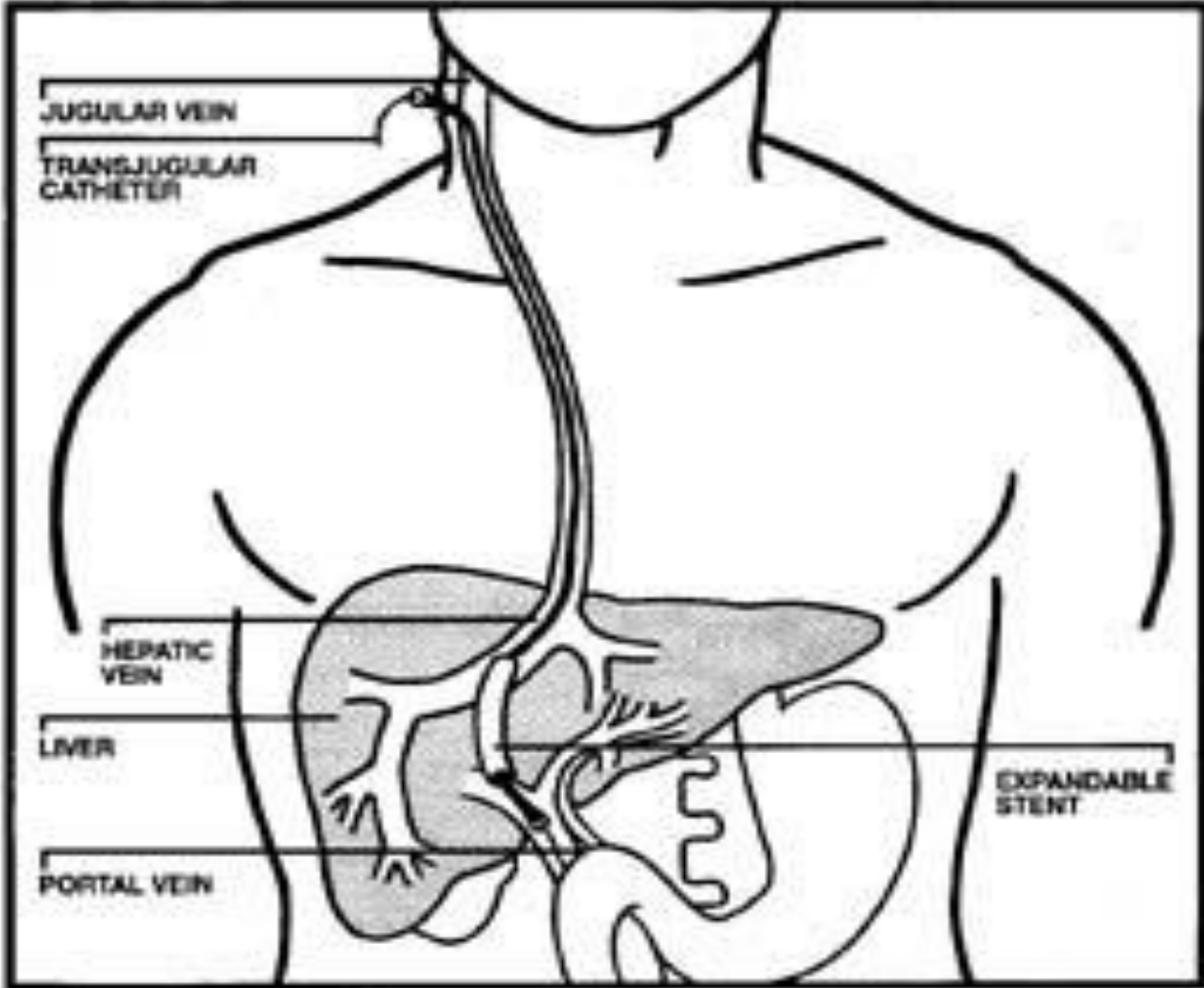


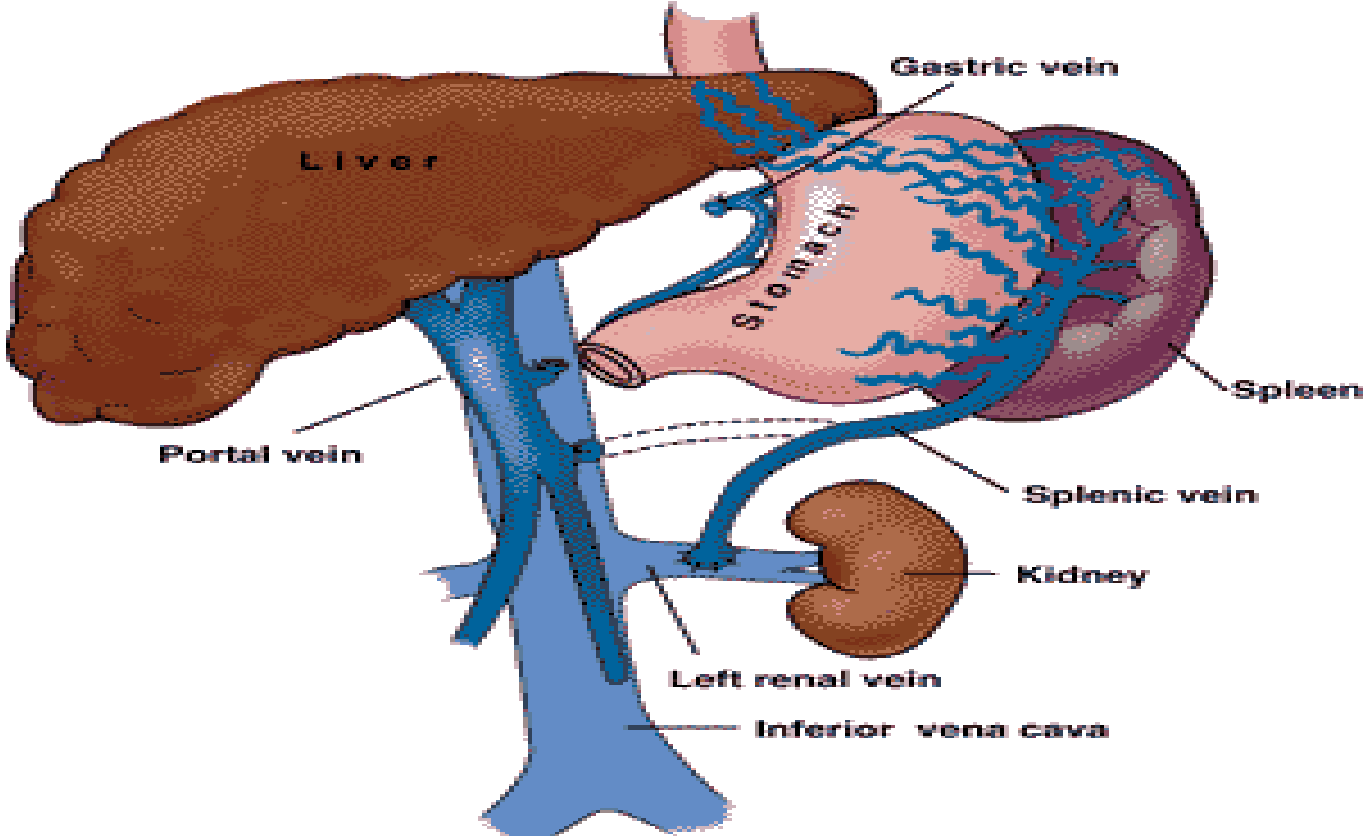
Fig. 14.12

Oesophageal tamponade using a Minnesota tube.

TIPSS



Shunts



Thanks