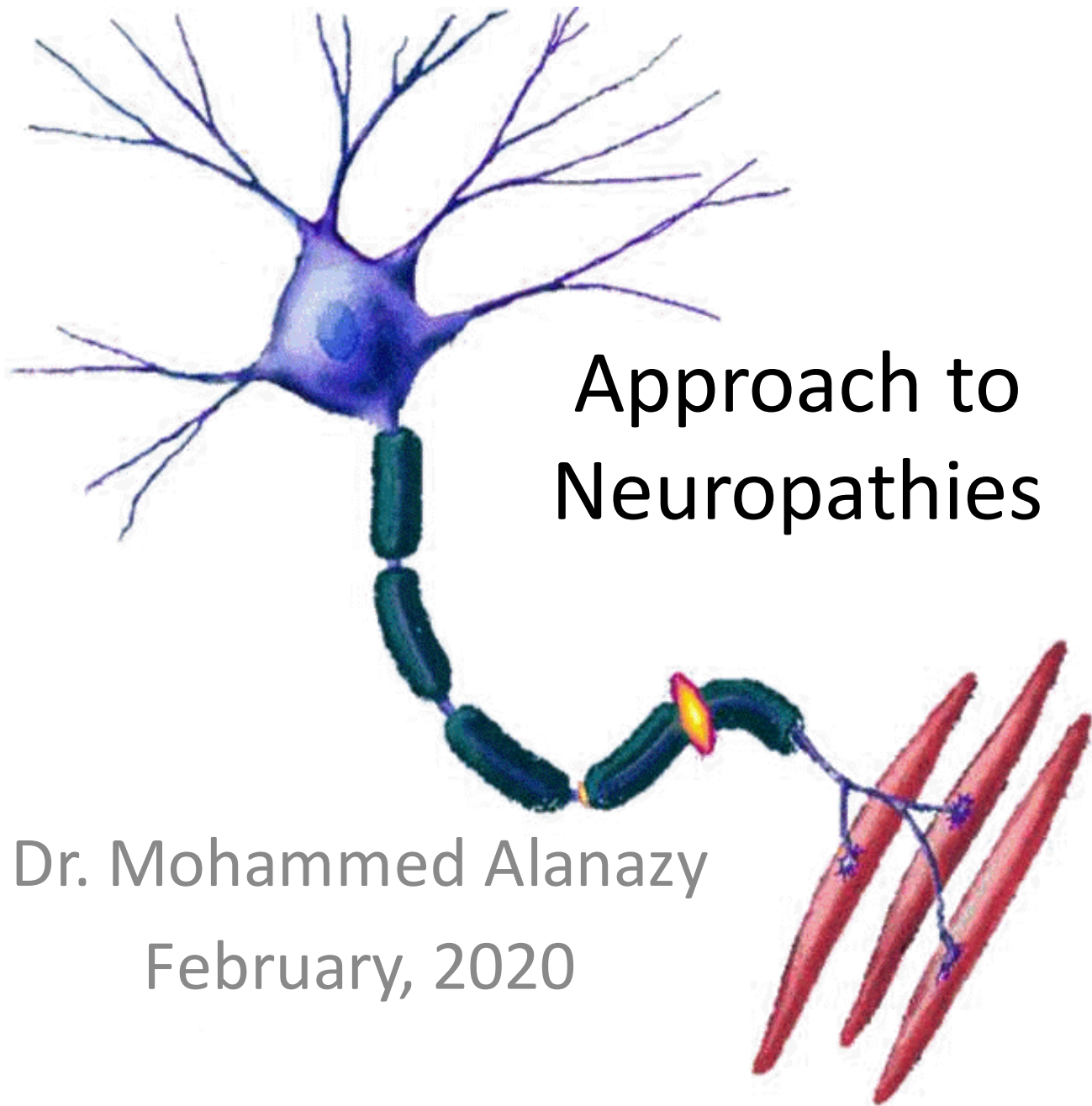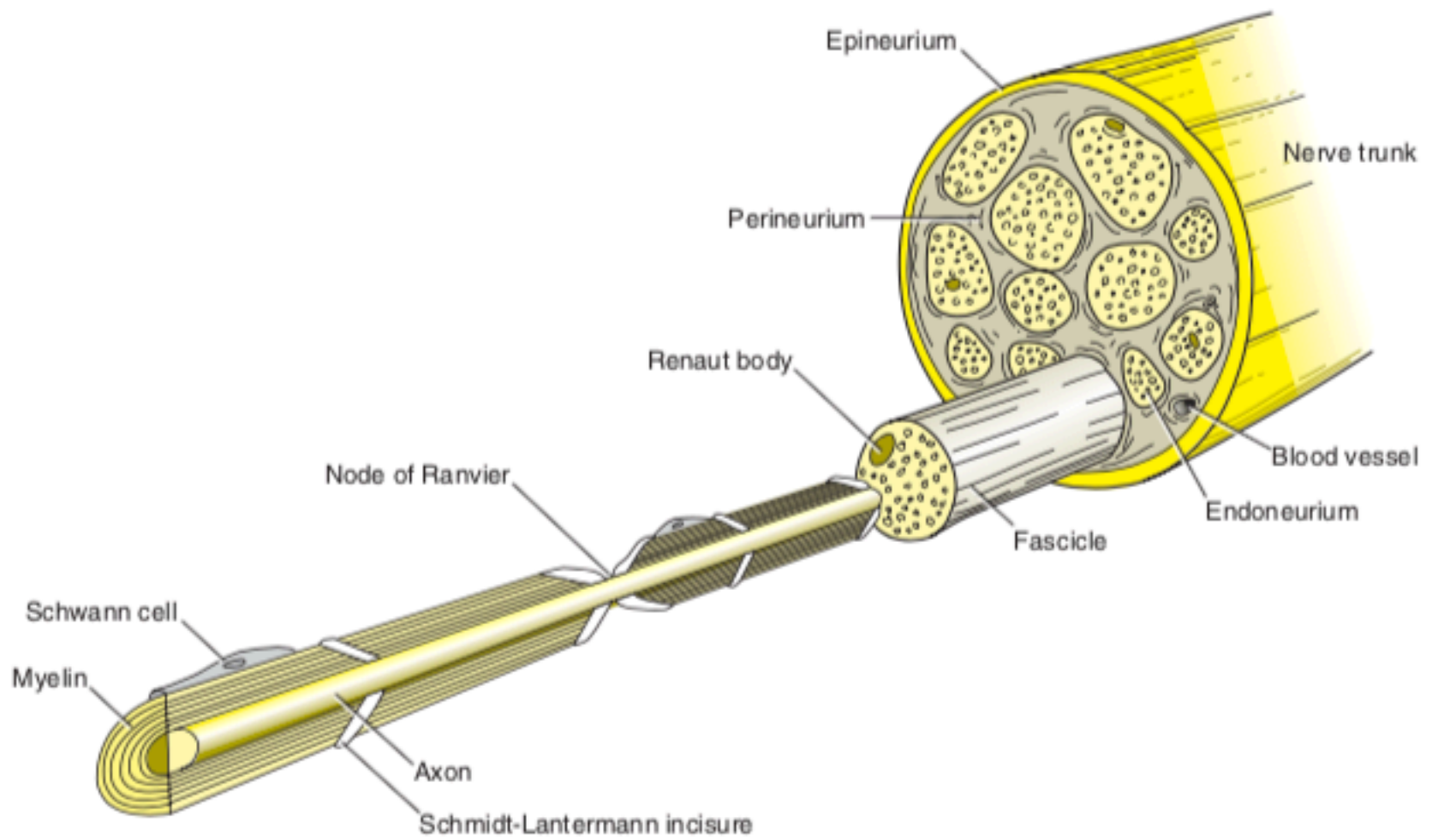


Approach to Neuropathies

Dr. Mohammed Alanazy
February, 2020

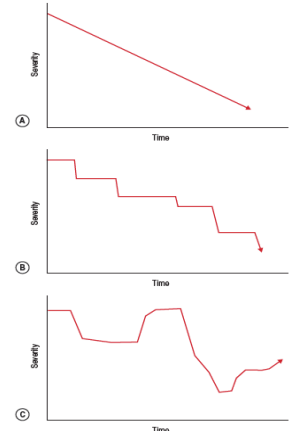
Goals and objectives

- Obtain informative history from a patient with peripheral neuropathy.
- Use clinical information to recognize different patterns of peripheral neuropathy
- Provide differential diagnosis for each pattern



History

- Symptoms
 - Tingling, burning, stabbing, throbbing, prickling, dead, icy, hot, clumsy, wooden, walking on sponges or cotton.
 - Weakness , cramps, twitches (fasciculations)
 - Distal leg
 - Tripping, stepping over curbs, uneven ground
 - Proximal
 - Standing from sitting, walking up or down stairs
 - Shaving, combing hair, brushing teeth
 - Upper extremity predominant
 - Turning keys, opening jars, doing up buttons
 - Autonomic: anhidrosis, excessive sweating, orthostatic light-headedness, impotence, dry mouth, early satiety, blurred vision in bright light
- Onset
 - <4 weeks, 4-8 weeks, >8 weeks
 - Were you a reasonable athlete as a child? Did you finish last in foot races? Were you able to skate or play soccer?
- Duration
- Progression
 - Chronic progression
 - Acute deterioration to nadir then stability or improvement



Past history and comorbidities

- Diabetes (glucose intolerance)
- Thyroid disease
- Renal failure / hepatic failure
- Malignancies
- Connective tissue disease
 - SLE
 - Rheumatoid arthritis
- Previous cervical or lumbar disc disease
- Previous entrapment neuropathies
 - Multiple entrapments (consider HNPP, amyloidosis)
- Orthopedic procedures on feet and ankles
- Bariatric surgery

Family History

- Detailed family history
 - Walking difficulty, use of cane or wheelchair
 - Postural or foot deformities
- Probe history of disabled or possibly affected individuals
- Do not necessarily accept what diagnoses other individuals have

Social History

- Exposure to alcohol
- Occupation
- Tobacco
- Recreational drugs
- Vitamin and herb use

Occupation	Neuropathy
Dentists	Nitrous oxide
Painters, glue sniffers	Hexacarbons
Farmers	Organophosphates
Welders	Lead
Jewelers	Arsenic
Plastic industry	Acrylamide

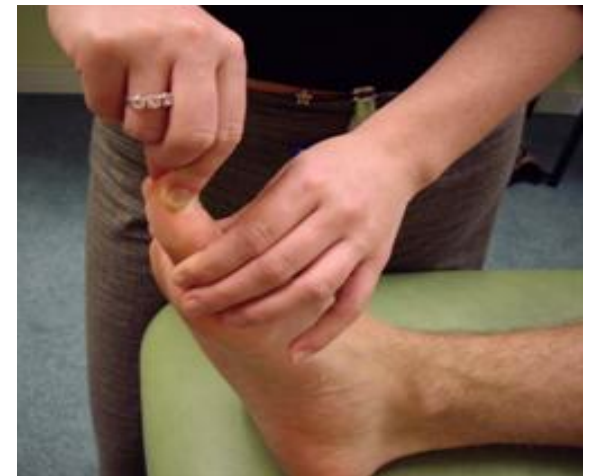
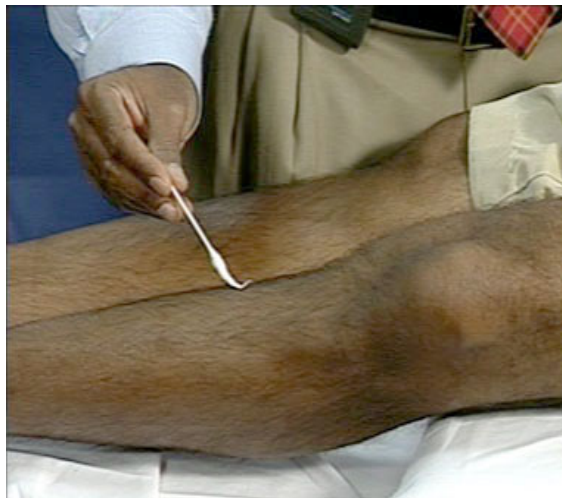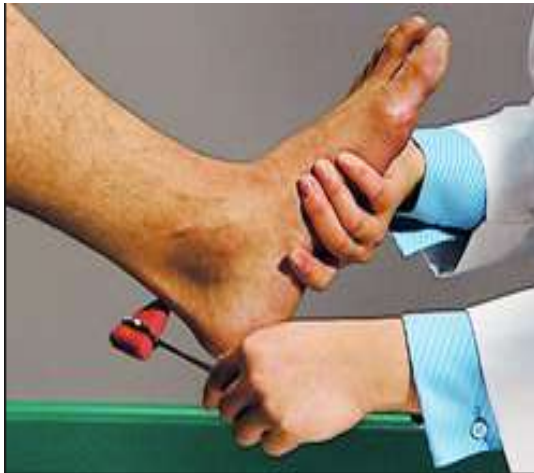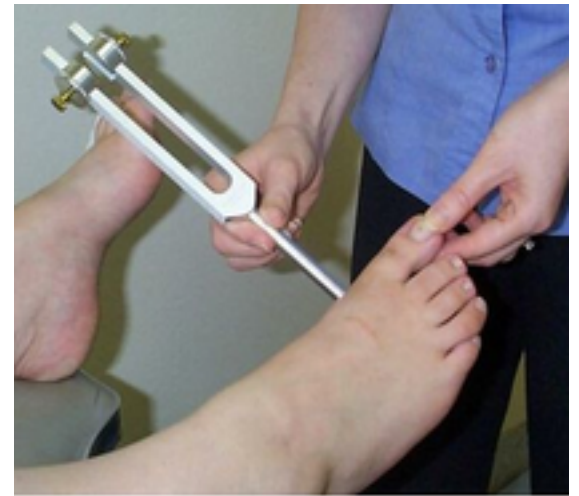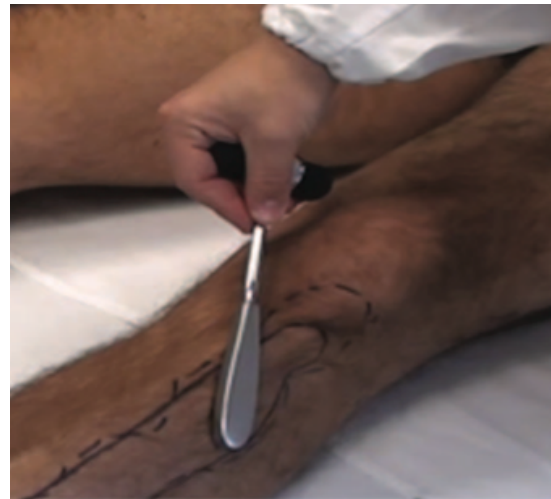Review of Systems

- Joint pain, stiffness and swelling
- Fever
- Skin rash
- Other systems

Neurological examination

- Confirm localization (LMN vs UMN, myopathy vs neuropathy)
- Recognize pattern of neuropathy
 - Motor vs sensory vs sensorymotor
 - Proximal vs distal
 - Symmetric vs asymmetric
- Recognize features of hereditary neuropathy
- Recognize features that narrows the differential diagnosis.
 - Purpura and levido reticularis
- Autonomic features
 - BP & HR supine and standing
 - Pupillary reaction to light and accommodation
- Other
 - Skin: trophic changes (such as thin, shiny, and discolored skin)
 - ulcerations or amputations.
 - peripheral pulses.

Neuro exam...



Approach

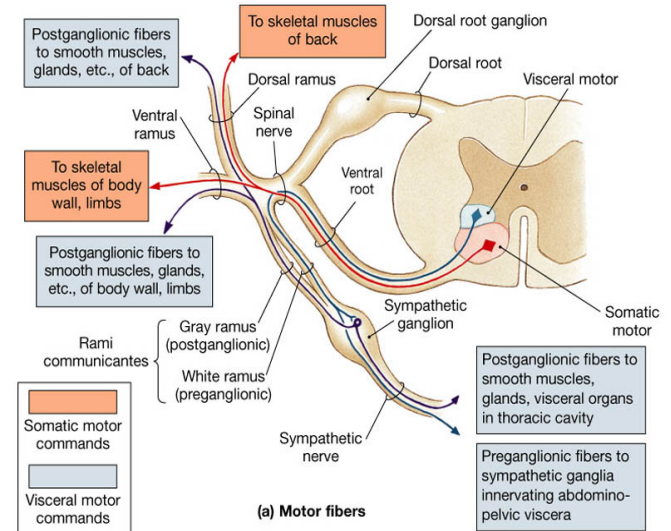
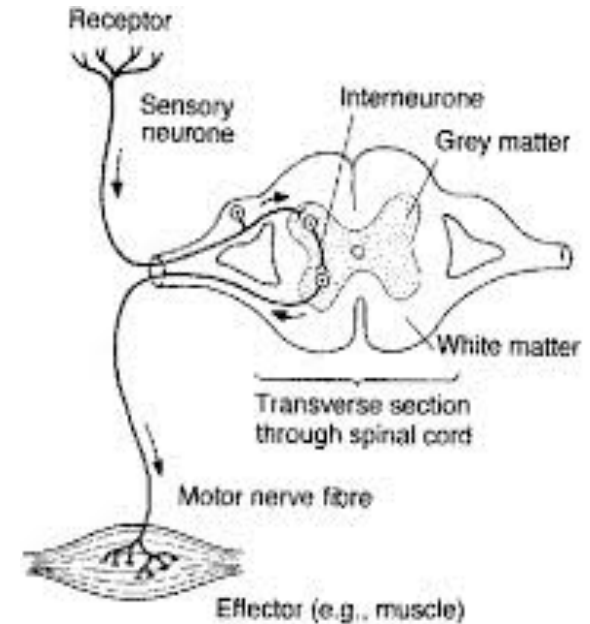
1. Recognition of a clinical pattern.
2. There are 6 key questions the clinician should consider in arriving at the pattern that fits the patient best.
3. Most neuropathy and neuronopathy patients can be placed into one of 10 patterns.

Approach – 6 questions

- 1- What systems are involved?
- 2- What is the distribution of weakness?
- 3- What is the nature of the sensory involvement?
- 4- Is there evidence of UMN involvement?
- 5- What is the temporal evolution?
- 6- Is there evidence for a hereditary neuropathy?

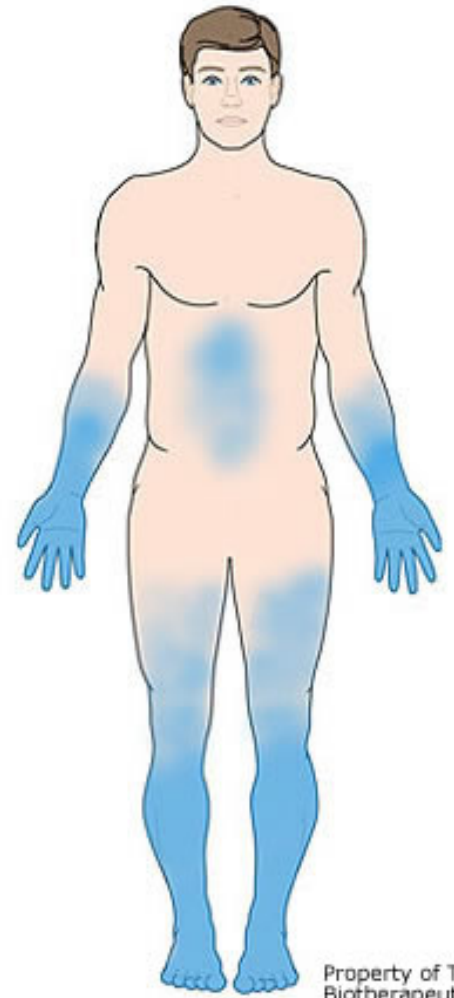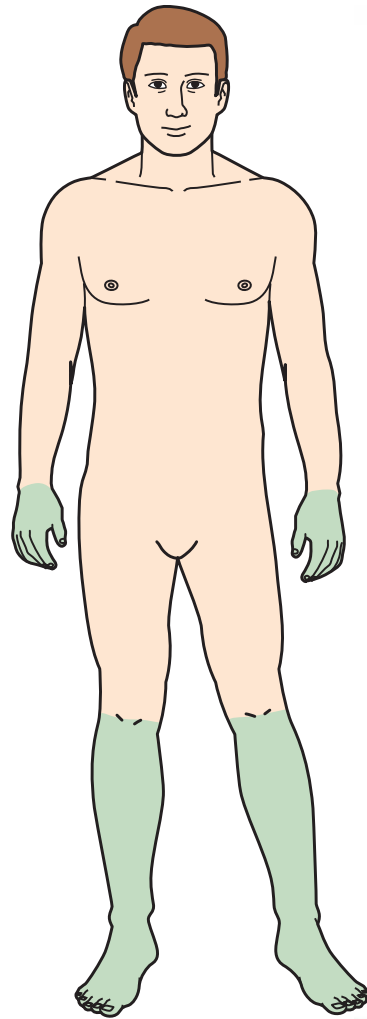
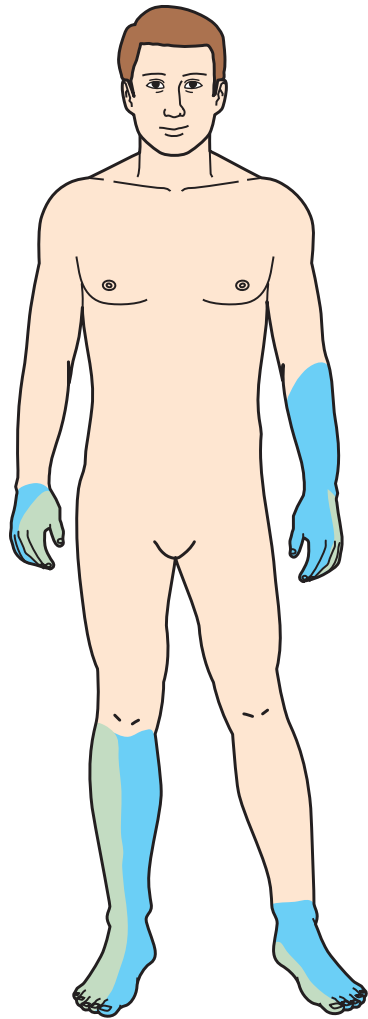
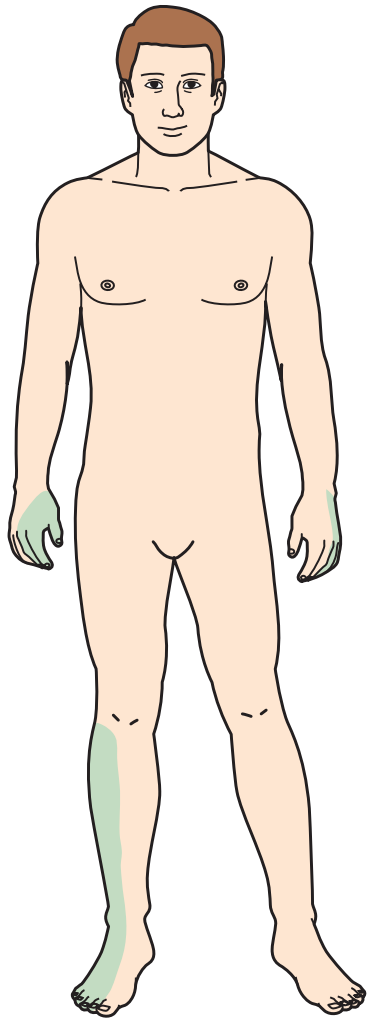
1- What Systems are Involved?

- Motor: localized to AHC, motor nerve roots, motor nerves.
- Sensory: DRG, sensory nerve roots, small nerves. Could be central
- Autonomic: autonomic nerves, gray/white communicants
- or combinations



2- What is the Distribution of Weakness?

- a. Only distal versus proximal and distal
- b. Focal/asymmetric versus symmetric



Property of Talecris Biotherapeutics

Asymmetric/focal weakness

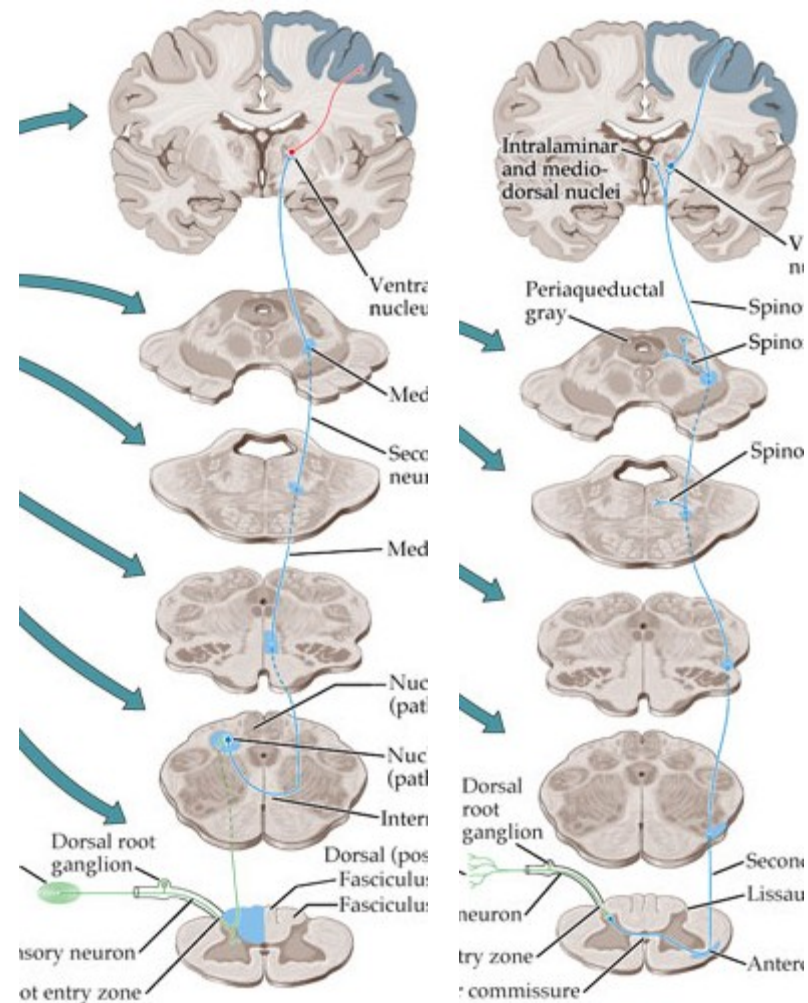
- Motor neuron disease
- Radiculopathy
- Plexopathy
- Mononeuropathy or multiple mononeuropathies
- Compressive/entrapment mononeuropathies

Symmetric weakness

- Represents a huge variety of DDx
- Symmetric **proximal** and **distal** weakness in a patient who presents with both motor and sensory symptoms → CIDP and GBS.
- Symmetric sensory and motor findings involving only the **distal** lower and upper extremities → the disorder generally reflects a primarily axonal peripheral neuropathy and is much less likely to represent a treatable entity.

3- What is the Nature of the Sensory Involvement?

- Pain (burning or stabbing) and temperature → small fiber
- Vibration and proprioception → large fiber
- Most neuropathies involve both small and large fibers.
- Severe proprioceptive loss
 - Central: dorsal column
 - Generally less profound proprioceptive loss
 - UMN signs
 - Ganglionopathy: loss of all sensory modalities and reflexes



	Negative	Positive
Motor	Weakness Fatigue Hyporeflexia or areflexia Hypotonia Orthopedic deformities (e.g., pes cavus, hammer toes)	Fasciculations Cramps Myokymia Restless legs "Tightness"
Sensory		
Large fiber	Decreased vibration sensation Decreased joint position sensation Hyporeflexia or areflexia Ataxia	"Tingling" "Pins and needles"
Small fiber	Hypotonia Decreased pain sensation Decreased temperature sensation	"Burning" "Jabbing" "Shooting"
Autonomic	Hypotension Arrhythmia Decreased sweating Impotence Urinary retention	Hypertension Arrhythmia Increased sweating

- 4- Is there evidence of upper motor neuron involvement?
 - a. Without sensory loss (ALS, PLS)
 - b. With sensory loss (B12 def, copper, vit E, etc)
- 5- What is the temporal evolution?
 - a. Acute (days to 4 weeks)
 - b. Subacute (4–8 weeks)
 - c. Chronic (>8 weeks)
 - d. Preceding events, infections, drugs, toxins
- 6- Is there evidence for a hereditary neuropathy?
 - a. Family history of neuropathy
 - b. Skeletal deformities
 - c. Lack of sensory symptoms despite sensory signs

Ten patterns of neuropathic disorders

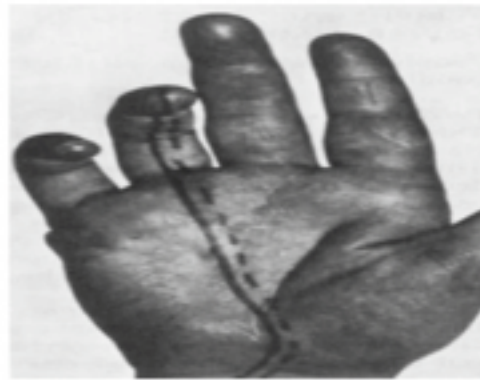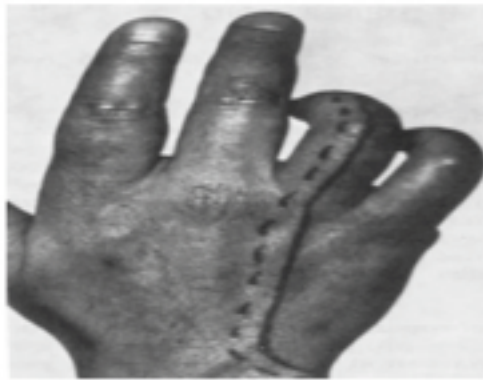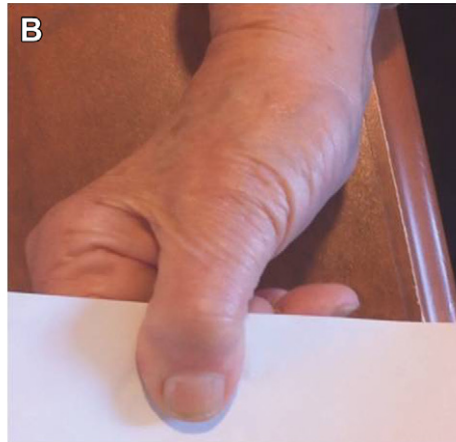
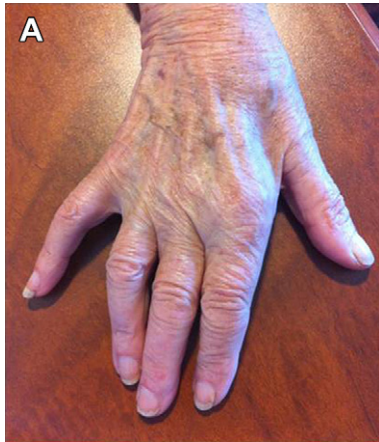
	Weakness				Sensory Symptoms	Severe Proprioceptive Loss	UMN Signs	Autonomic Symptoms/ Signs	Diagnosis
	Proximal	Distal	Asymmetric	Symmetric					
Pattern 1: symmetric proximal and distal weakness with sensory loss	+	+		+	+				GBS/CIDP
Pattern 2: distal sensory loss with/ without weakness		+		+	+				CSPN, metabolic, drugs, hereditary
Pattern 3: distal weakness with sensory loss		+	+		+				Multiple: vasculitis, HNPP, MADSAM, infection Single: mononeuropathy, radiculopathy
Pattern 4: asymmetric proximal and distal weakness with sensory loss	+	+	+		+				Polyradiculopathy, plexopathy
Pattern 5: asymmetric distal weakness without sensory loss		+	+				±		LMN and UMN – ALS Pure UMN – PLS Pure LMN – MMN, PMA, BAD, LAD, MAMA
Pattern 6: symmetric sensory loss and upper motor neuron signs		+		+	+	+	+		B ₁₂ deficiency, copper deficiency, Friedreich ataxia, adrenomyeloneuropathy
Pattern 7 ^a : symmetric weakness without sensory loss	±	+		+					Proximal and distal SMA Distal Hereditary motor neuropathy
Pattern 8 ^a : focal midline proximal symmetric weakness	+			+			+		ALS
	Nek/extensor			+			+		
	Bulbar								
Pattern 9: asymmetric proprioceptive loss without weakness			+		+	+			Sensory neuronopathy (ganglionopathy)
Pattern 10: autonomic dysfunction							+		HSAN, diabetes, GBS, amyloid, porphyria, Fabry



What is the pattern?

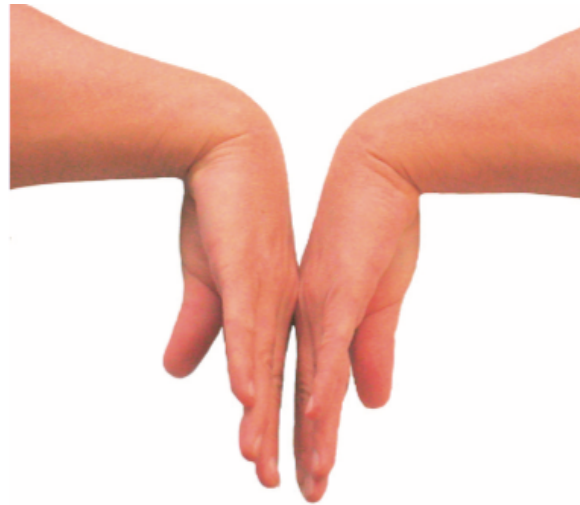
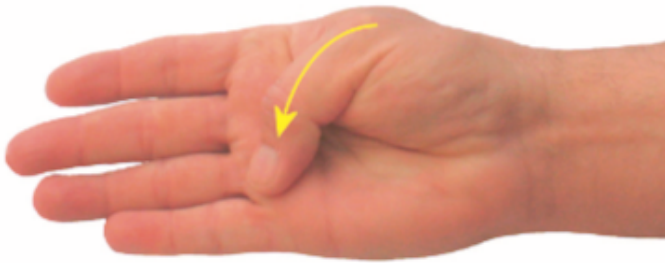
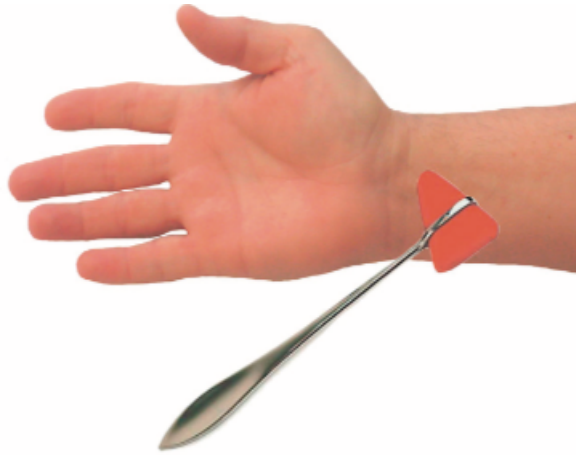- A 65-year-old woman presented with a 3-month history of right-hand numbness, grip weakness, and vague elbow pain. Examination demonstrated diminished sensation of the medial hand and fourth and fifth digits, and weakness of finger abduction and adduction, associated with intrinsic hand muscle atrophy. Froment and Wartenberg signs were evident

	Weakness				Sensory Symptoms	Severe Proprioceptive Loss	UMN Signs	Autonomic Symptoms/ Signs	Diagnosis
	Proximal	Distal	Asymmetric	Symmetric					
Pattern 3: distal weakness with sensory loss		+	+		+				Multiple: vasculitis, HNPP, MADSAM, infection Single: mononeuropathy, radiculopathy



What is the pattern?

A 67-year-old woman was referred for clumsiness, tingling, and pain in both hands of several months' duration. Symptoms were most prominent at night, often awakening her from sleep, or during hand use such as driving. Examination showed slight wasting of both thenar eminences. Reflexes were normal. Thumb abduction was weak bilaterally. Sensation was slightly reduced over the finger pads of the thumb, index, middle, and ring fingers. There was no Tinel's sign at the wrist on either side. A Phalen's maneuver elicited tingling in the middle finger bilaterally after 30 seconds.



Weakness

Proximal	Distal	Asymmetric	Symmetric	Sensory Symptoms	Severe Proprioceptive Loss	UMN Signs	Autonomic Symptoms/ Signs	Diagnosis
----------	--------	------------	-----------	------------------	----------------------------	-----------	---------------------------	-----------

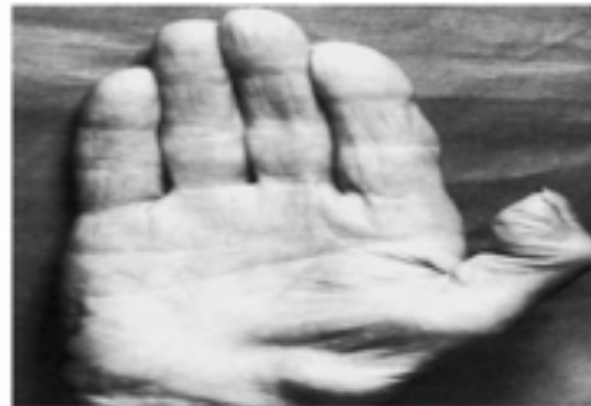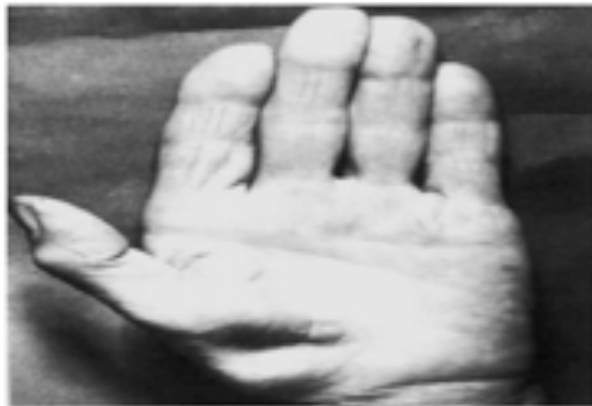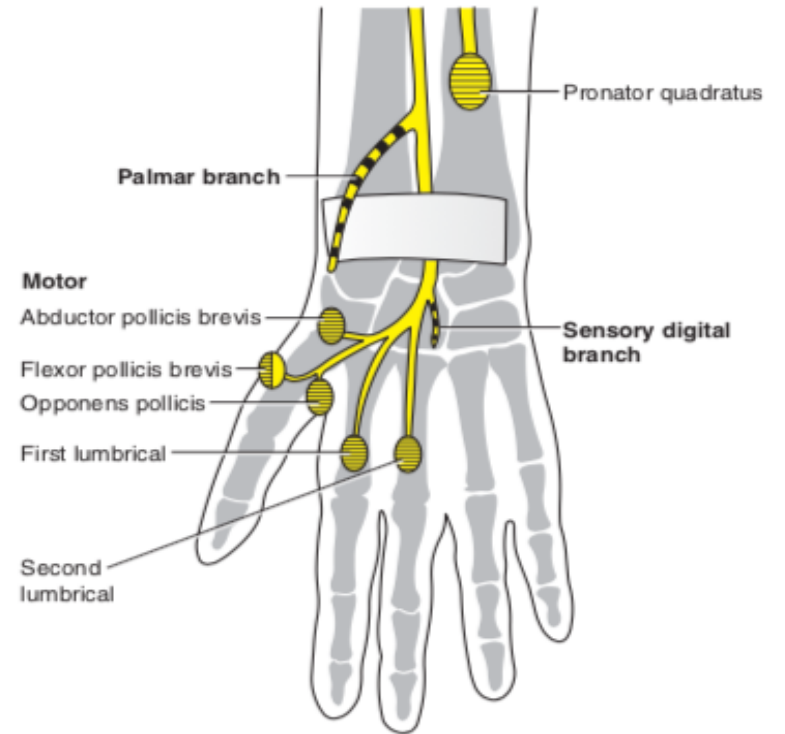
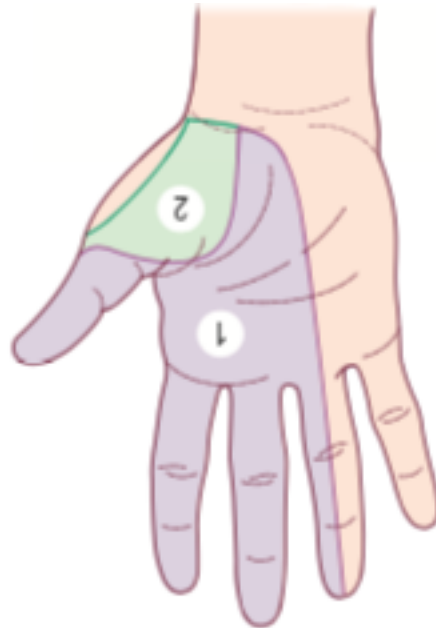
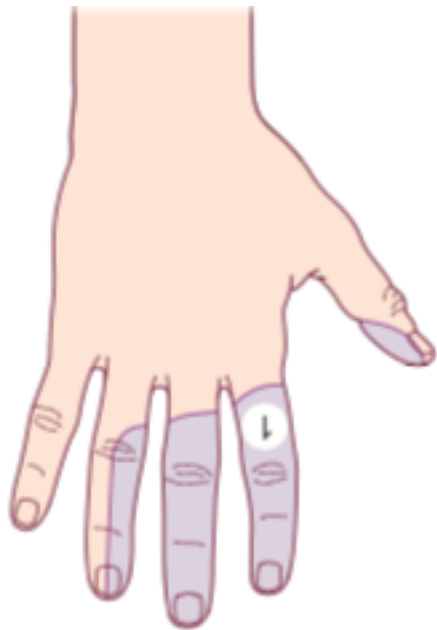
Pattern 3: distal weakness with sensory loss

+

+

+

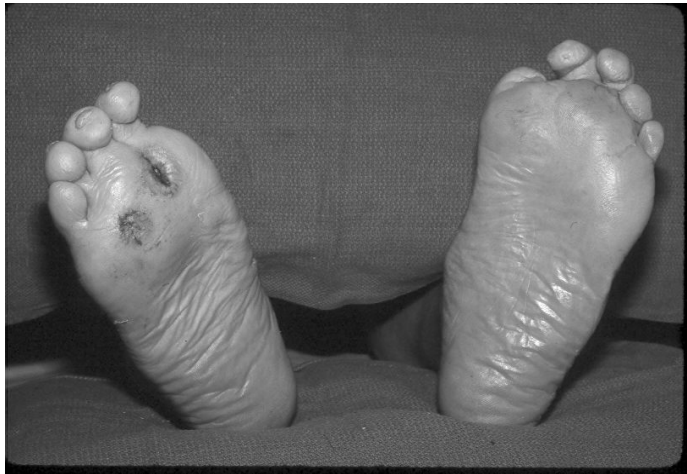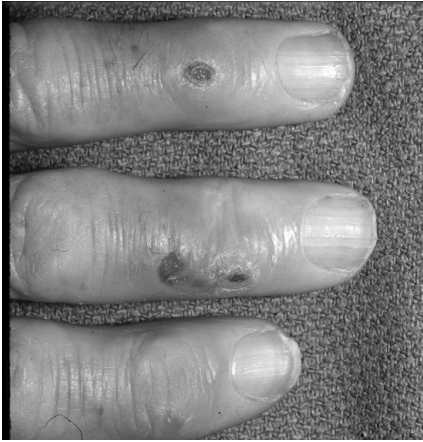
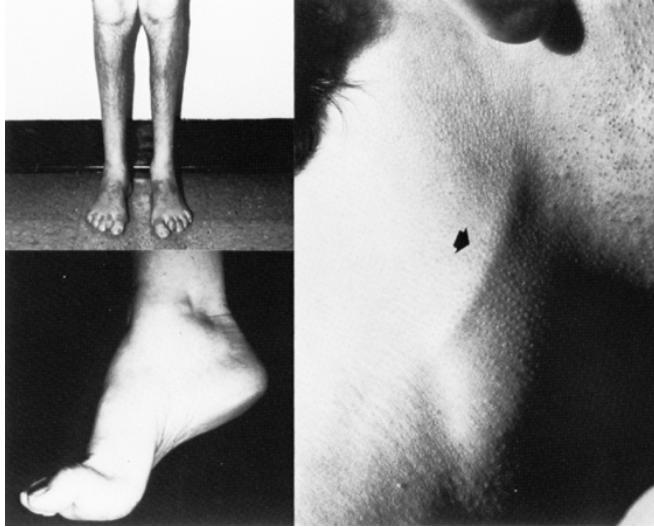
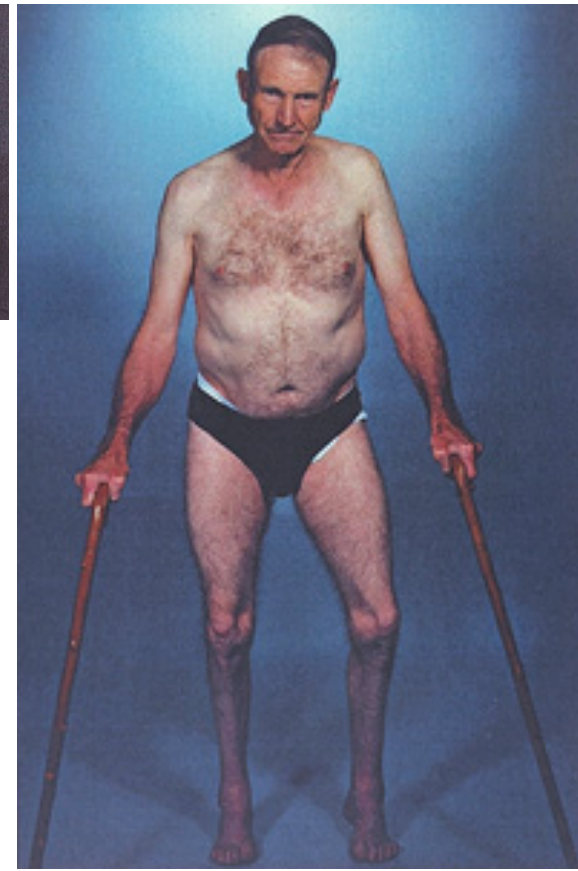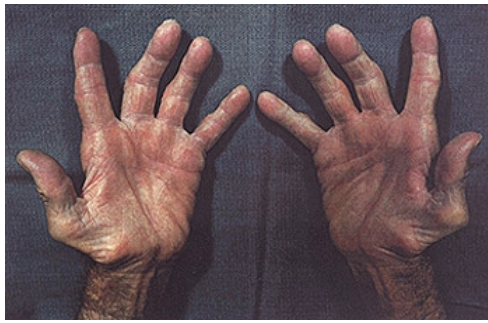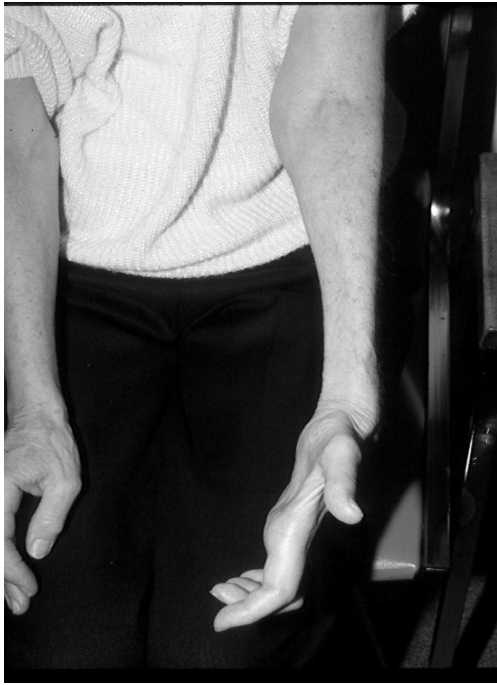Multiple: vasculitis, HNPP, MADSAM, infection
Single: mononeuropathy, radiculopathy



What is the pattern?

- A 25-year-old man with **NO** family history of neuropathy had been weak early childhood. He remembers he was unable to keep up with his peers when running. He is currently only able to walk if wearing ankle-foot orthosis. He denied sensory symptoms.
- Neurological examination showed symmetric severe weakness in distal leg muscles with power of 1-2/5 with bilateral drop feet. Proximal leg muscles were 4/5 as well as intrinsic hand muscles. Proximal upper limb muscles were normal.
- Reflexes were absent.
- Vibration and proprioception sensation were absent over the toes bilaterally and Pinprick and temperature were decreased to the knees and wrists

	Weakness				Sensory Symptoms	Severe Proprioceptive Loss	UMN Signs	Autonomic Symptoms/ Signs	Diagnosis
	Proximal	Distal	Asymmetric	Symmetric					
Pattern 2: distal sensory loss with/ without weakness		+		+	+				CSPN, metabolic, drugs, hereditary



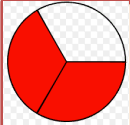
What is the pattern here?

- A 42-year-old man developed numbness and tingling in the toes, progressing up to the ankles over 2 years. He describes burning pain in his feet, mainly at night. He recently started noticing symptoms of numbness and tingling in distal fingers. He denies any weakness.
- Examination showed normal strength, with decreased pinprick and light touch sensations to the ankles and distal fingers. Vibration was absent at the toes and decreased at the ankles, and proprioception is normal at the toes. Reflexes are normal in the arms and at the knees but ankle reflexes are absent. Gait is normal

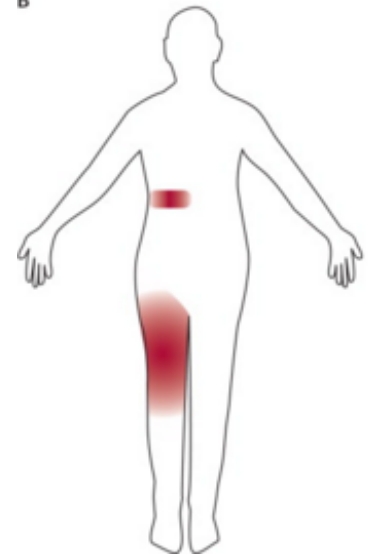
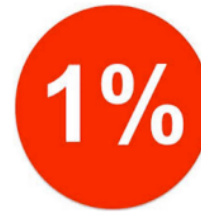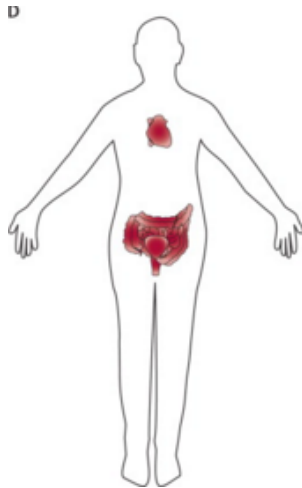
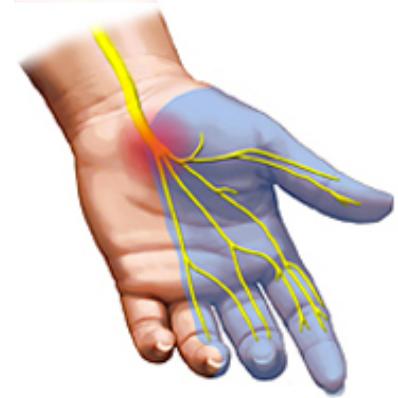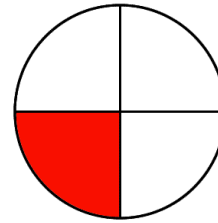
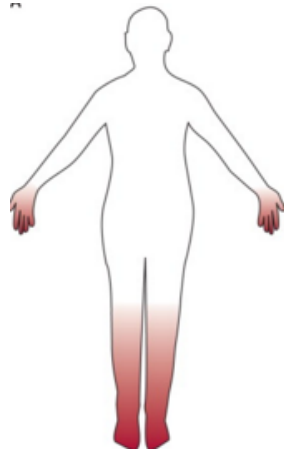
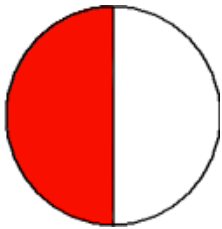
	Weakness				Sensory Symptoms	Severe Proprioceptive Loss	UMN Signs	Autonomic Symptoms/ Signs	Diagnosis
	Proximal	Distal	Asymmetric	Symmetric					
Pattern 2: distal sensory loss with/ without weakness		+		+	+				CSPN, metabolic, drugs, hereditary

Diabetic neuropathy: Classification

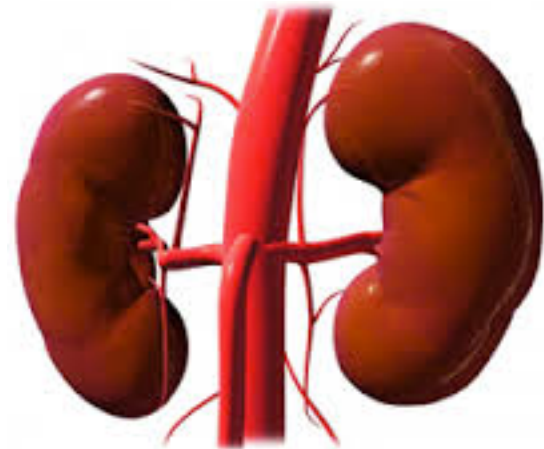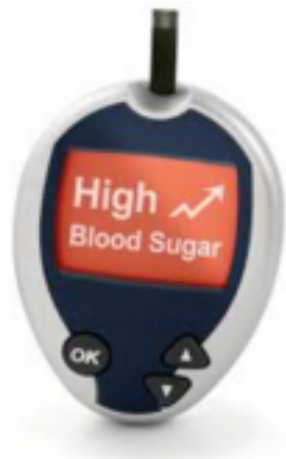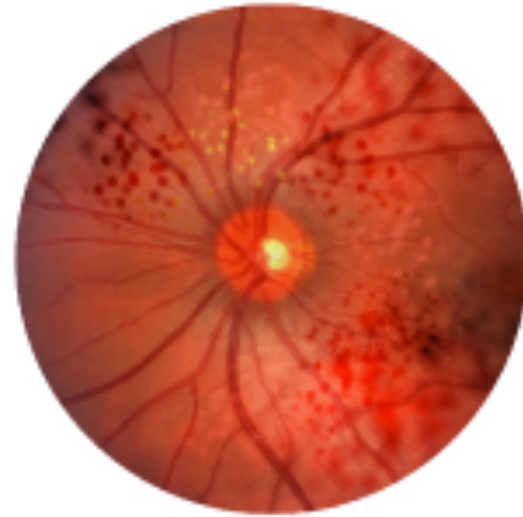- Symmetric:
 - Distal symmetric polyneuropathy (DSPN)
 - Small fiber neuropathy
 - Acute severe distal sensory polyneuropathy
 - Autonomic neuropathy
 - Diabetic neuropathic cachexia
 - Hypoglycemic neuropathy
 - Treatment-induced diabetic neuropathy
- Asymmetric/focal and multifocal:
 - Diabetic radiculoplexopathy (amyotrophy)
 - Truncal neuropathies (thoracic radiculopathy)
 - Cranial neuropathies
 - Mononeuropathies



66% of patients with DM had subclinical or clinical evidence of a peripheral neuropathy



The occurrence of neuropathy correlates with:



What is the pattern in this case?

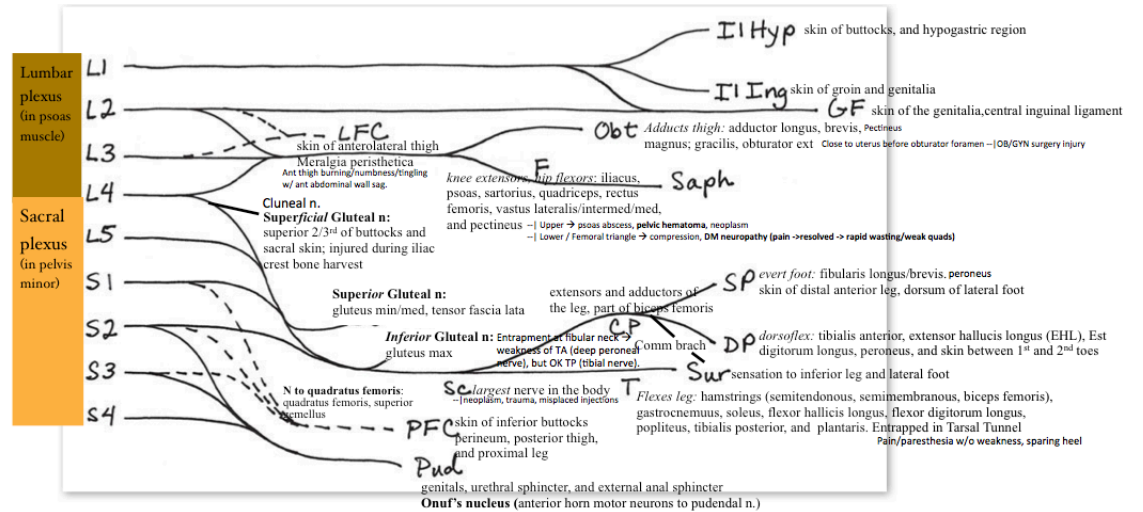
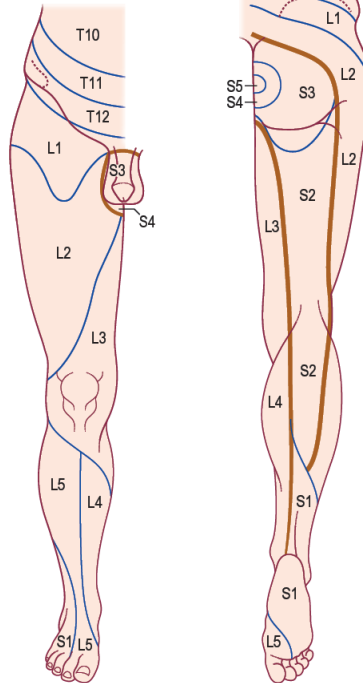
- A 36-year-old man
- Eight weeks ago, he had bent down to lift a chair and developed acute pain in the right back and buttock with radiating paresthesias into the calf and lateral foot.
- Neurologic examination:
 - normal muscle bulk and tone in the lower extremities.
 - Straight-leg raising elicited pain and paresthesias into the right leg at 45 degrees.
 - Power: weakness in right **hip extension, knee flexion, and ankle plantar flexion**
 - Sensory examination: mild sensory loss on the right sole and lateral foot.
 - DTR: right ankle reflex was absent, other DTRs were normal

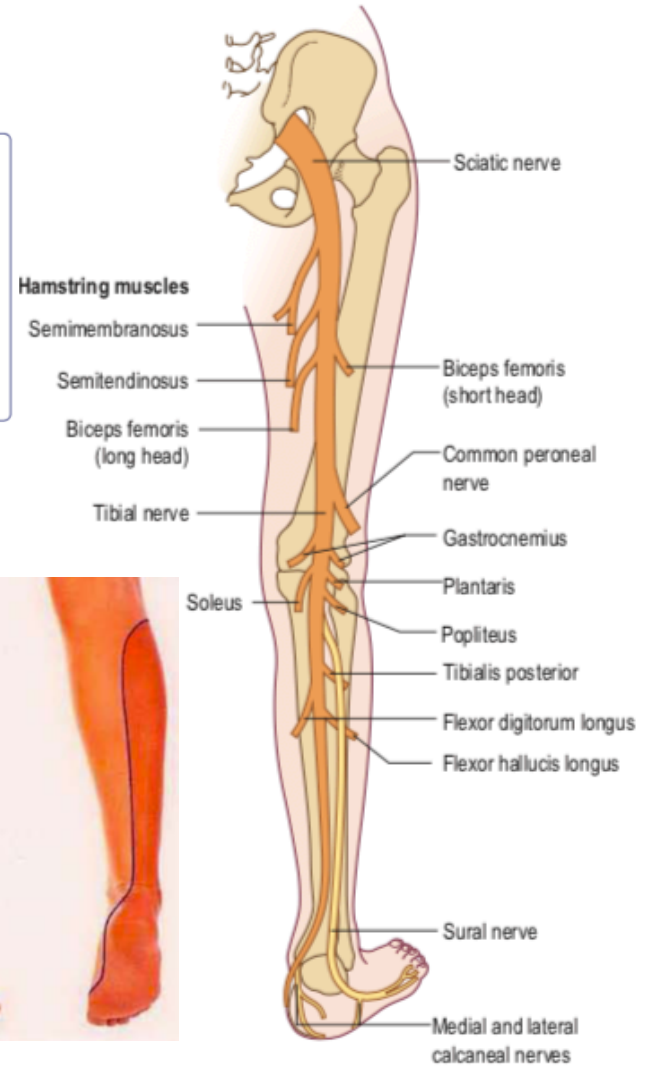
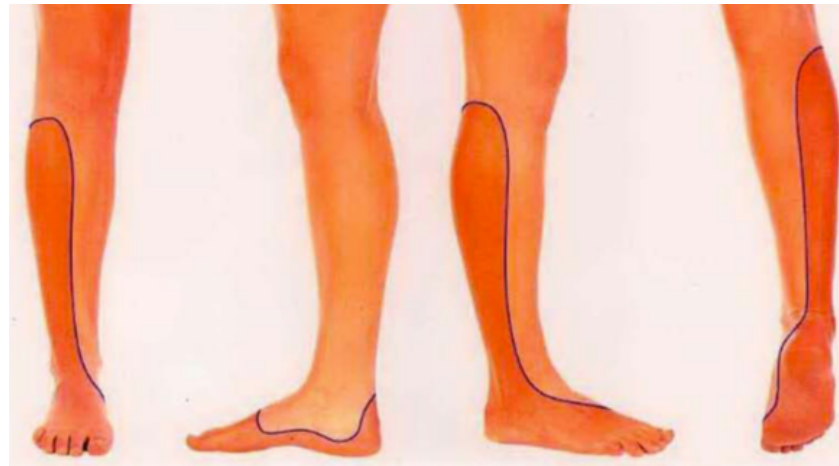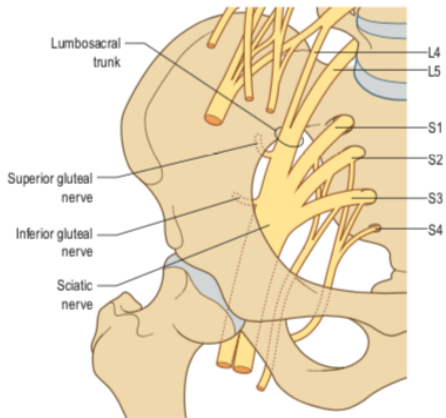
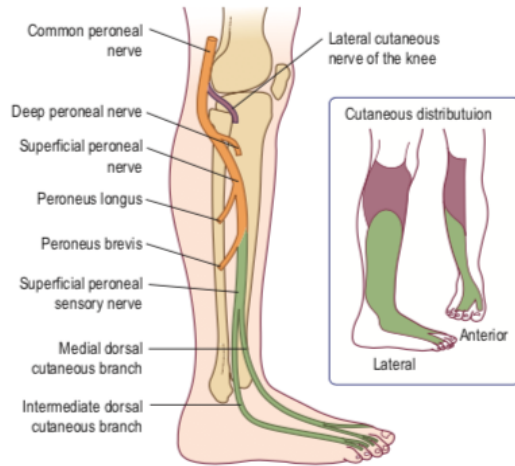
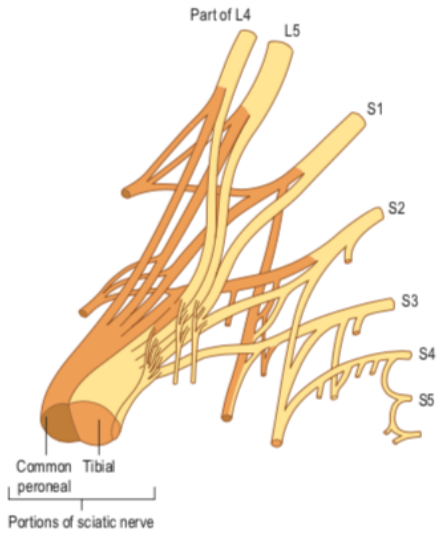
Weakness

	Proximal	Distal	Asymmetric	Symmetric	Sensory Symptoms	Severe Proprioceptive Loss	UMN Signs	Autonomic Symptoms/ Signs	Diagnosis
--	----------	--------	------------	-----------	------------------	----------------------------	-----------	---------------------------	-----------

Pattern 4: asymmetric proximal and distal weakness with sensory loss

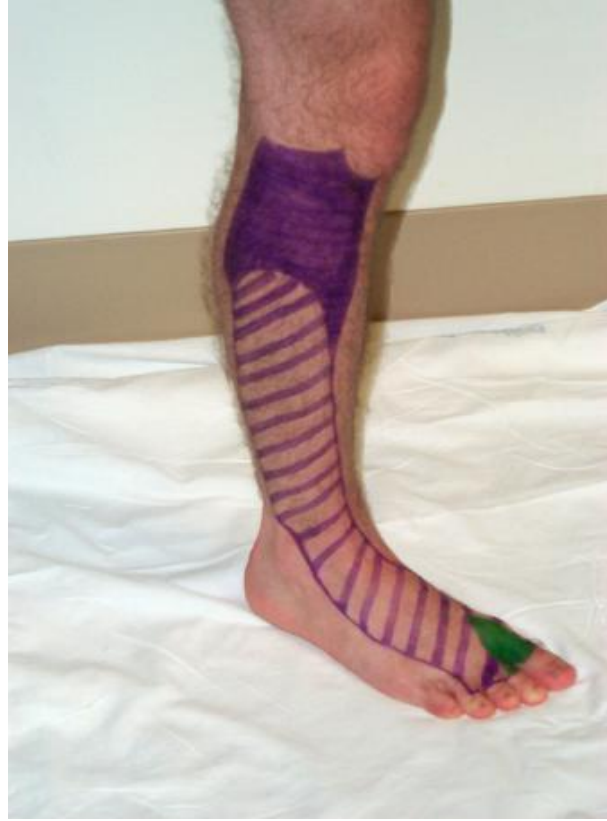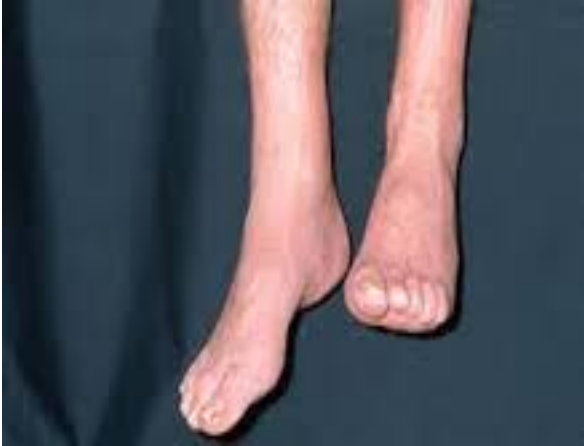Polyradiculopathy, plexopathy





What is the pattern?

- A 56-year-old man was referred for a persistent foot drop 3 weeks after coronary artery bypass surgery. Shortly after awakening from anesthesia, the patient noted difficulty dorsiflexing his right foot and toes. In addition, there was a pins-and-needles sensation over the dorsum of the right foot. He noted that when he was walking, his right foot would slap with each step. There was no pain, and the left leg was unaffected.
- On examination, muscle bulk and tone were normal and symmetric in both legs. There was marked weakness of right ankle and toe dorsiflexion (1/5) as well as ankle eversion (2/5). Foot inversion, ankle and toe plantar flexion, knee flexion, and all movements around the hip were normal. Deep tendon reflexes were intact and symmetric.
- Sensory examination showed a well-demarcated loss of sensation to pinprick and temperature over the dorsum of the right foot extending into the lateral calf. Sensation over the right lateral knee was normal, as was sensation over the lateral foot, sole of the foot, and medial calf.



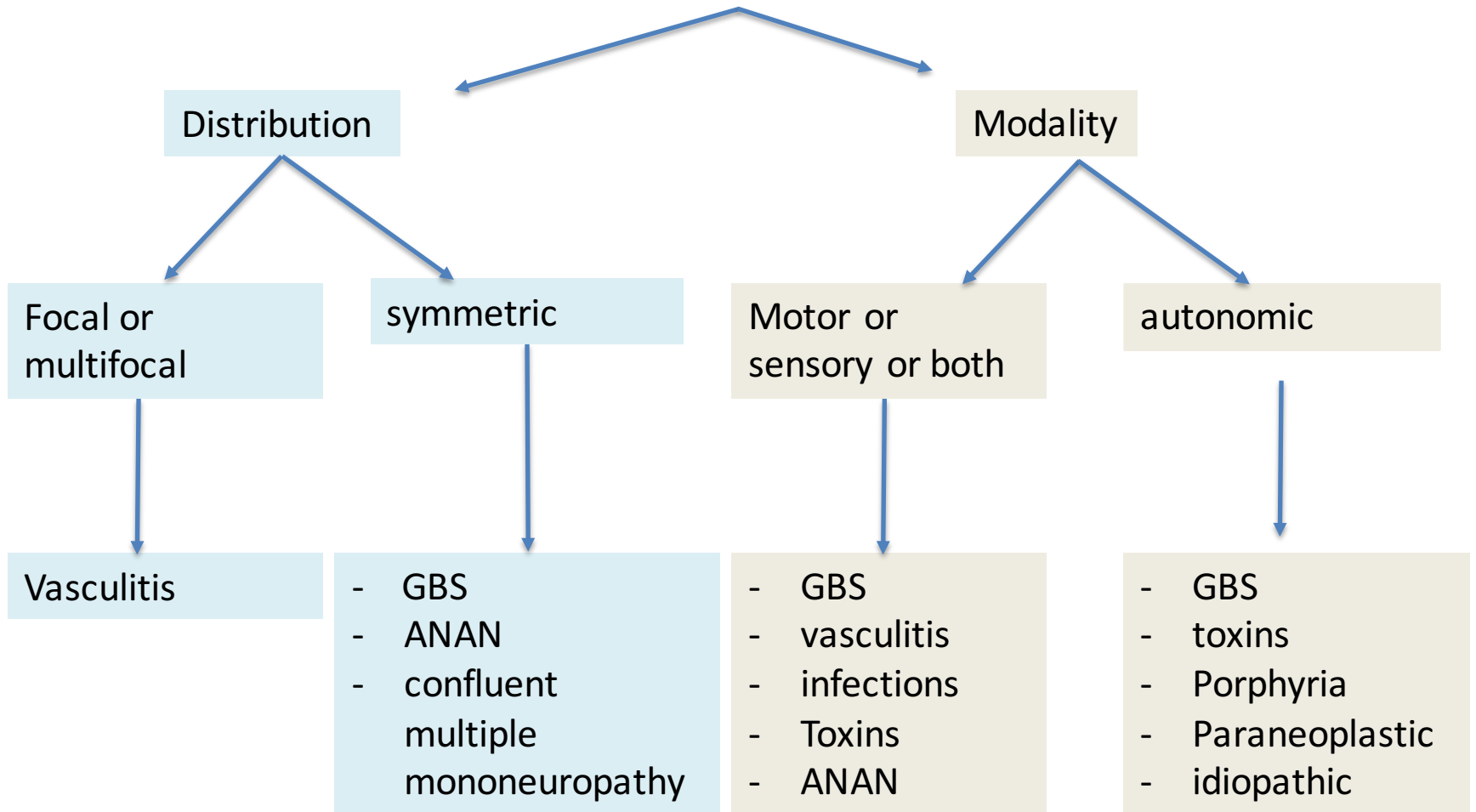
What is the pattern in this case?

- A 25 year-old woman developed numbness and tingling of the feet and hands followed by progressive leg more than arm muscle weakness over the last week. She experienced a diarrheal illness 3 weeks ago that had resolved within 10 days.
- Examination showed marked bifacial weakness and absent muscle stretch reflexes. She had normal pinprick, light touch and proprioception but vibration was reduced at the toes.
- Muscle power in the lower limbs was 2/5 and in the upper limbs 3/5, with equal proximal and distal weakness. She could not stand up or walk with assistance.

Weakness

	Proximal	Distal	Asymmetric	Symmetric	Sensory Symptoms	Severe Proprioceptive Loss	UMN Signs	Autonomic Symptoms/ Signs	Diagnosis
Pattern 1: symmetric proximal and distal weakness with sensory loss	+	+		+	+				GBS/CIDP

Acute neuropathy



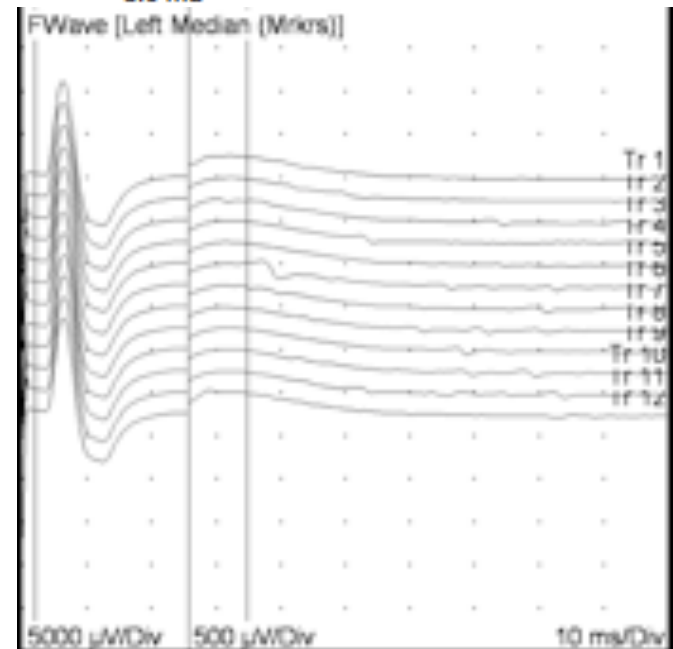
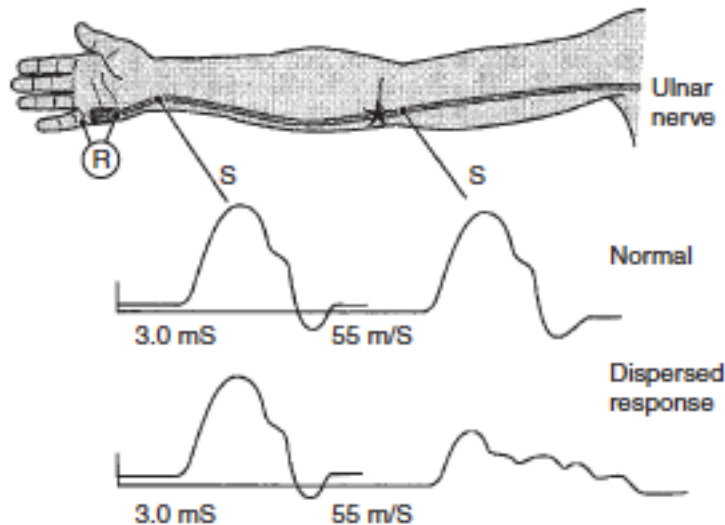
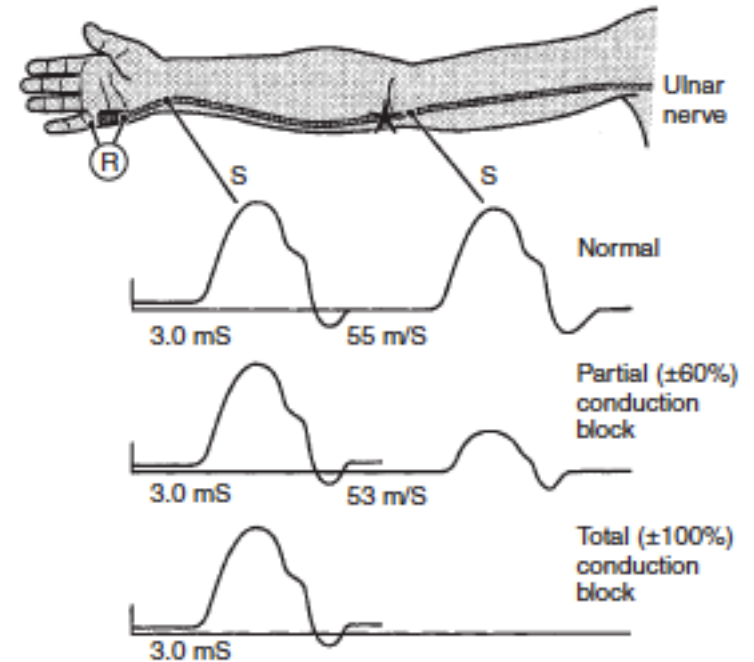
- CBC = normal,
- vitamin B12 level = normal
- Serum glucose and A1c – normal
- SPEP – normal
- CK = normal, TSH = normal, lactate = normal
- Forced vital capacity was 2.0 liters.
- Cerebrospinal fluid evaluation showed no white cells but protein was 82 mg/dl.
- Nerve conduction studies showed 50% delay in tibial and median F wave latencies. Sensory conduction showed normal sural and absent median potentials.

- Motor NCS

- Conduction block
- Temporal dispersion
- Slowed conduction velocity
- Prolonged DML
- Absent F wave.

- Sensory NCS

- normal sural SNAPs
- Absent median and ulnar SNAPs.



Treatment

- IVIG or Plasmapheresis
- Supportive therapy

- Monitor progression and prevent and manage potentially fatal complications, especially:
 - Regularly monitor pulmonary
 - Regularly check for autonomic dysfunction
 - Check for swallowing dysfunction
 - Recognize and treat pain
 - Prevent and treat infections and pulmonary embolism
 - Prevent cornea ulceration due to facial weakness
 - Prevent decubitus and contractures

