



Dr. ABDULAZIZ AL-SAIF, FRCS, FBES

Consultant Breast & Endocrine Surgeon

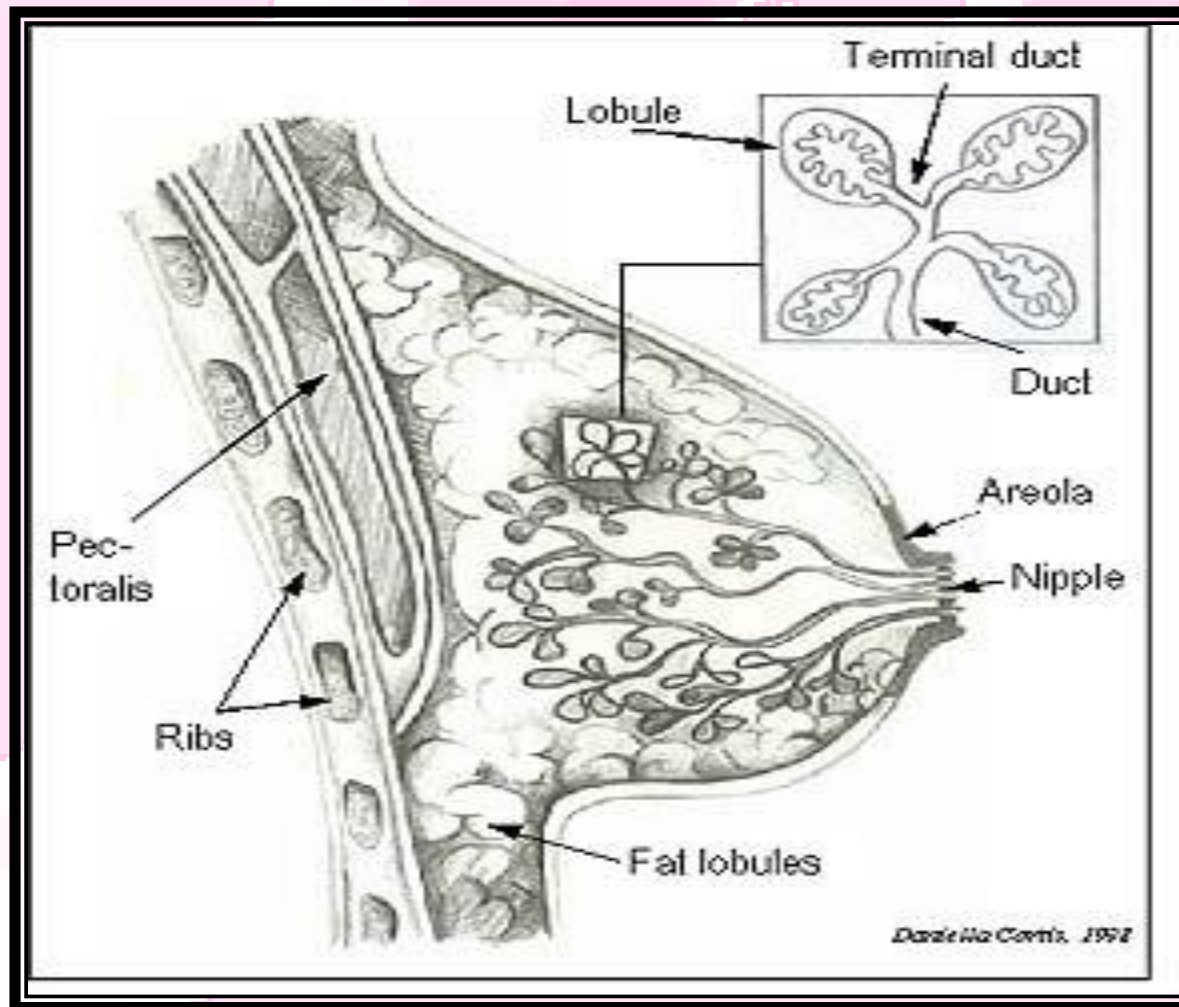
Head of Surgery Unit

Department of Surgery

College of Medicine

King Khalid University Hospital

THE BREAST

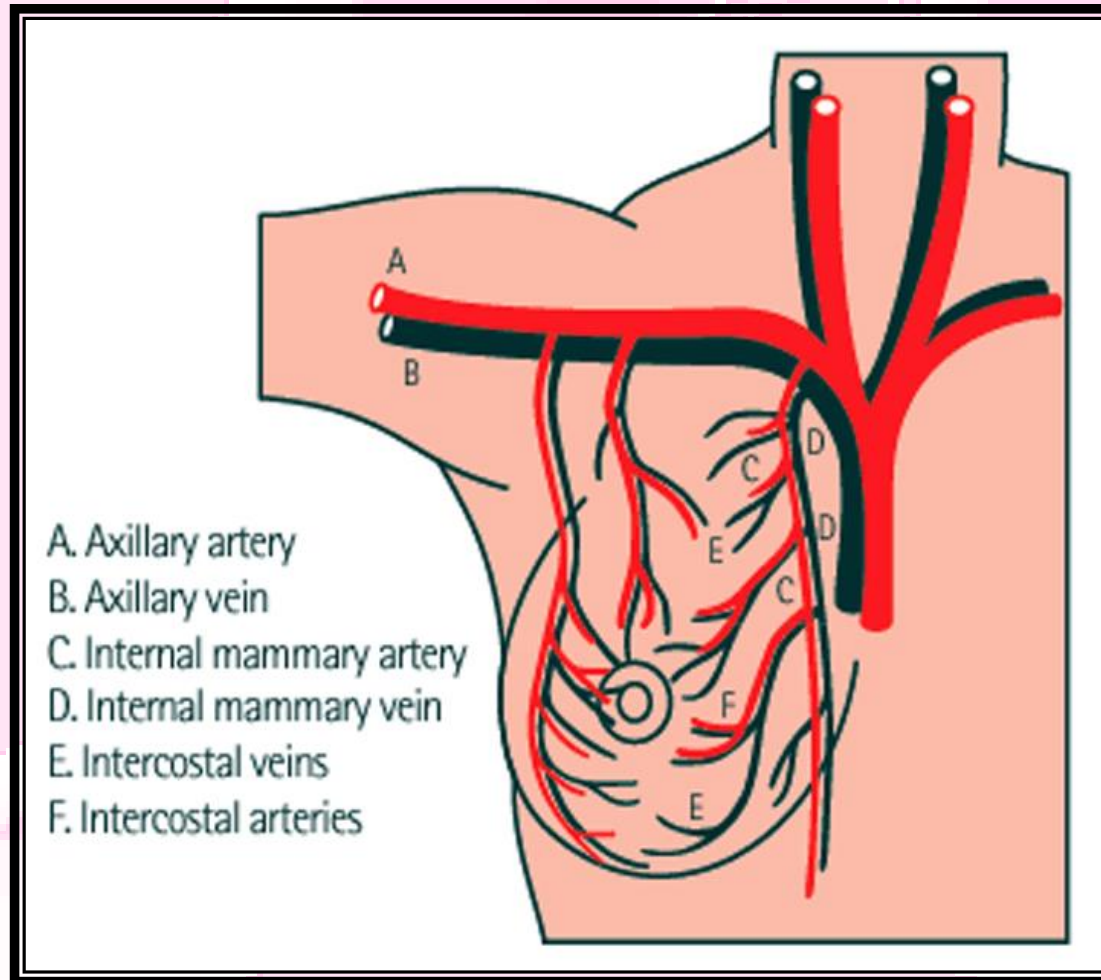


THE BREAST

Anatomy

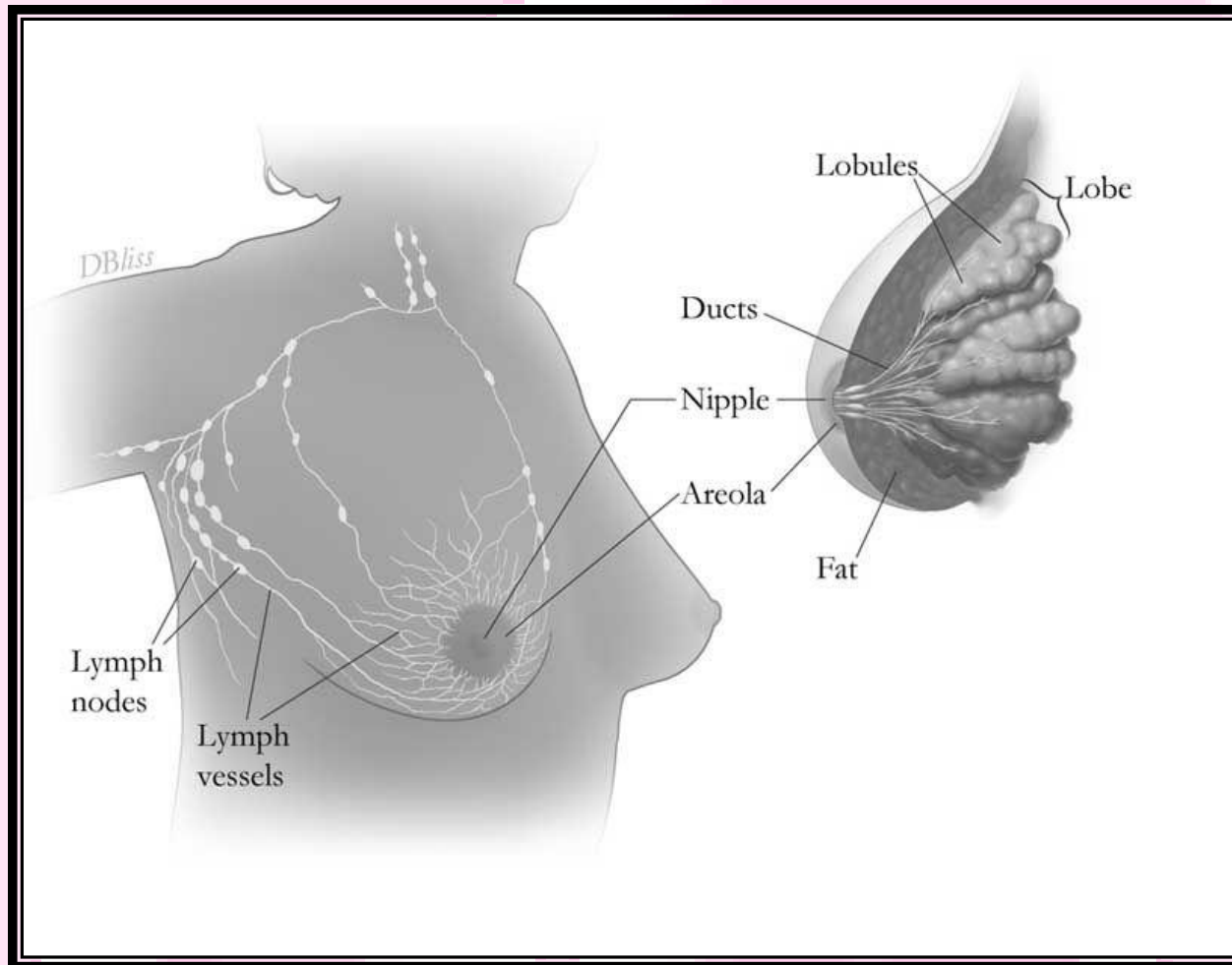
- Modified sweat gland.
- 2-6 ribs, side of sternum to mid-axillary line.
- Sets on
 - Pec. Major 60%
 - Serratus anterior 30%
 - Rectus sheath 10%
- 15-20 lobules separated by fibrous septa (Cooper's ligaments).
- Axillary tail of spence.
- **Blood supply.**
 - *Lateral thoracic and acromiothoracic branch of axillary artery.*
 - *Internal mammary artery*
 - *Intercostal aa.*

Blood Supply to the Breast



Lymphatic drainage

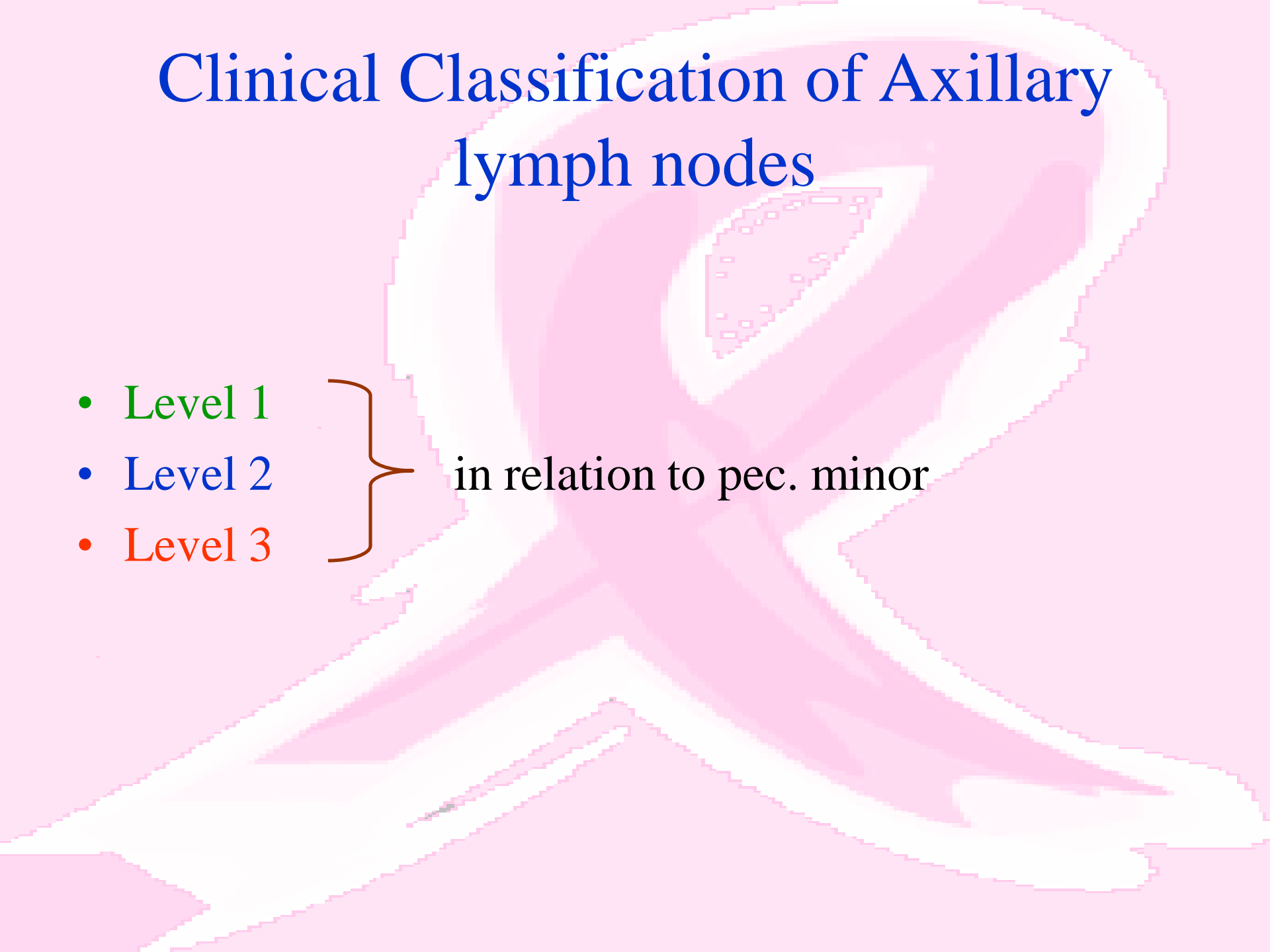
- Groups of lymph nodes:
 - Anterior: deep to pectoralis major.
 - Posterior: along subcapular vessels.
 - Lateral: along the axillary vein.
 - Central: in axillary pad of fat.
 - Apical: drains the above, behind clavicle at apex of axilla.



These pictures show the parts of the breast and the lymph nodes and lymph vessels near the breast.

Clinical Classification of Axillary lymph nodes

- Level 1
 - Level 2
 - Level 3
- } in relation to pec. minor



Women come to see a breast surgeon because of one of the followings

1. Breast lump (painful or painless) 60%
2. Breast pain without lump 10%
3. Nipple discharge 5%
4. Change in breast contour 2%
5. Nipple – areolar complex disorder 1%
6. Axillary mass 1%
7. Screen detected lesion 1%
8. Anxiety 20%

CLINICAL APPROACH



1. History.
2. Clinical examination.
3. Imaging.
4. Cytology and tissue diagnosis.

1. HISTORY

Full and complete history should be taken, particular attention should be paid to:

- *Breast development stating from childhood to present.*
- *Endocrine status of patient mainly menstruation and OCP.*
- *Size of lump in relation to menses.*

1. HISTORY....

Cont!

- Pattern of pain in relation to menses.
- How regular the cycle is and quantity of blood.
- Changes in breast during previous pregnancies e.g. abscess, nipple discharge, retraction of nipple.
- Number of pregnancies.
- Breast feeding
- Abnormalities which took place during previous lactation period e.g. abscesses, nipple retraction, milk retention.

1. HISTORY....

Cont!

- Family history of breast diseases especially cancer and particularly in near relatives.
- Nipple discharge.
- Age at menarch.
- Age at 1st birth.
- L.M.P.

- For post menopausal women.
 - *H.R.T.*
 - *Date of menopause*

2. EXAMINATION

- Disrobed from waist and above.
- Examine in sitting and supine position and 45° position.
- Inspection with arms by the side and above head:
 - *Size, symmetry, skin changes, nipple complex.*
Examine normal side first.
Examine axilla, arm, SCF
Examine abdomen
Examine the back

MANAGEMENT OF PATIENT WITH A BREAST LUMP:

- History
- Examination
- Ultrasound
- Mammogram if above 35 yrs
- FNAC or
- Core biopsy or
- Excision biopsy (rarely done)
- Definitive treatment which is either:
 - *Observation*
 - *Excision*
 - *If malignant, along the lines of cancer cases*

MANAGEMENT OF PATIENT WITH A LUMP

Cont!

- **TRIPPLE ASSESSMENT**
 - H & P
 - Mammogram (99%)
 - Core biopsy or FNA

Techniques Available for Investigations



- Clinical examination.
- Cytology of discharge.
- Mammography and ductography.
- Ultrasound.
- Imaging-guided percutaneous biopsy.
- M.R.I.
- Nuclear medicine (include PET).

Distinguish between

DIAGNOSTIC

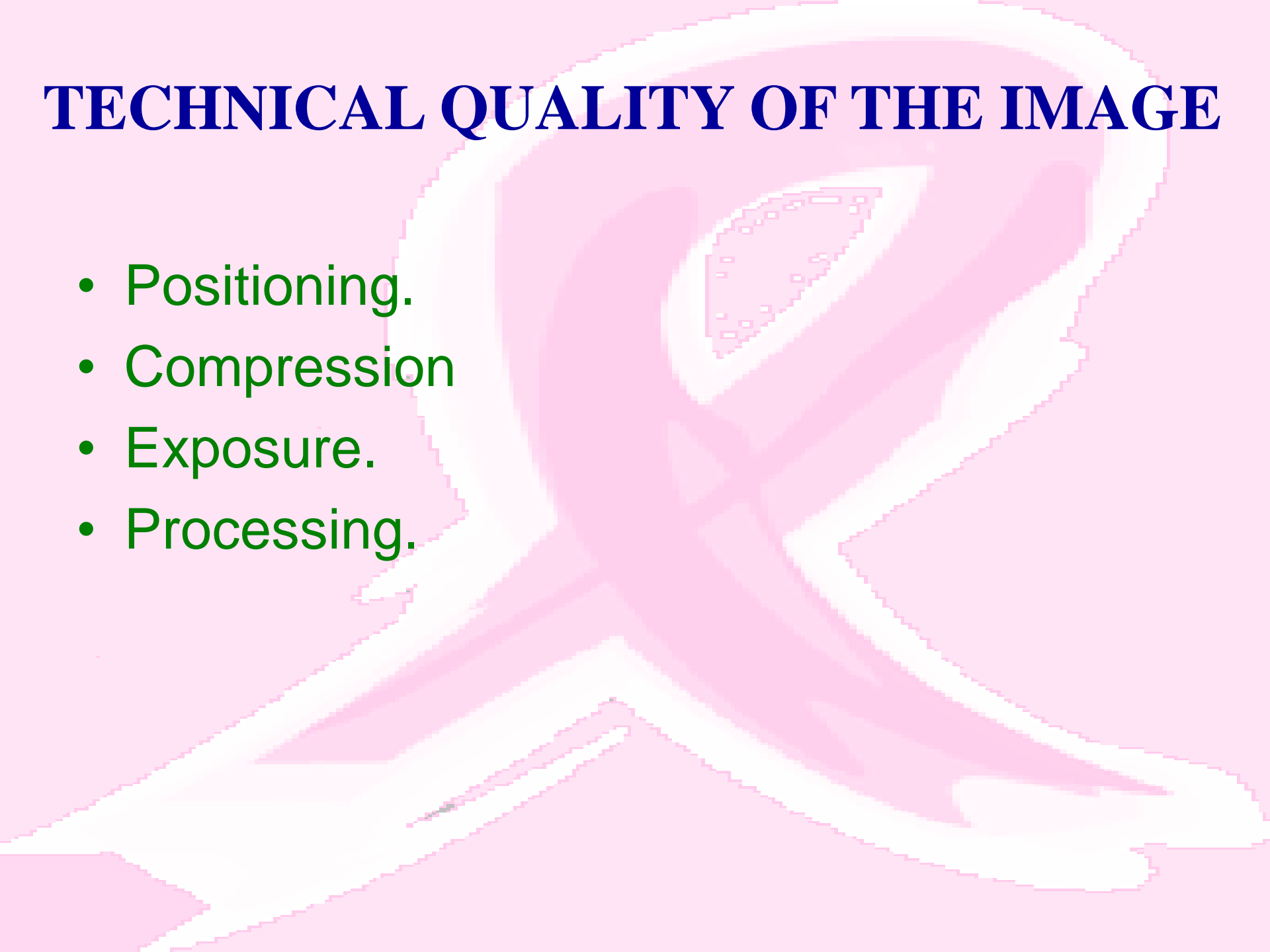
&

SCREENING

mammography

TECHNICAL QUALITY OF THE IMAGE

- Positioning.
- Compression
- Exposure.
- Processing.



CARDINAL MAMMOGRAPHIC FEATURES OF MALIGNANCY

- Spiculated mass.
- Architectural distortion without mass.
- Micro-calcifications with casting or irregularity.
- Circumscribed density with indistinct margins.
- Asymmetric density.

CALCIFICATIONS

The background of the slide features a faint, stylized illustration of a breast. A circular inset provides a magnified view of a calcification cluster, showing numerous small, dark, irregular spots. The overall color scheme is light pink and white.

- 60% of localisation biopsies are for calcs, but only 25% of these yield malignancy.
- Distribution (casting, linear, segmental, clustered).
- Morphology (pleomorphism).
- Relationship to parenchyma.

IMAGING FEATURES WHICH CAN BE ASSOCIATED WITH D.C.I.S.

- Microcalcifications (75-90%).
- Circumscribed mass.
- Ill-defined mass.
- Prominent duct or nodule.
- Architectural distortion.
- Asymmetry.
- Sub-areolar mass.

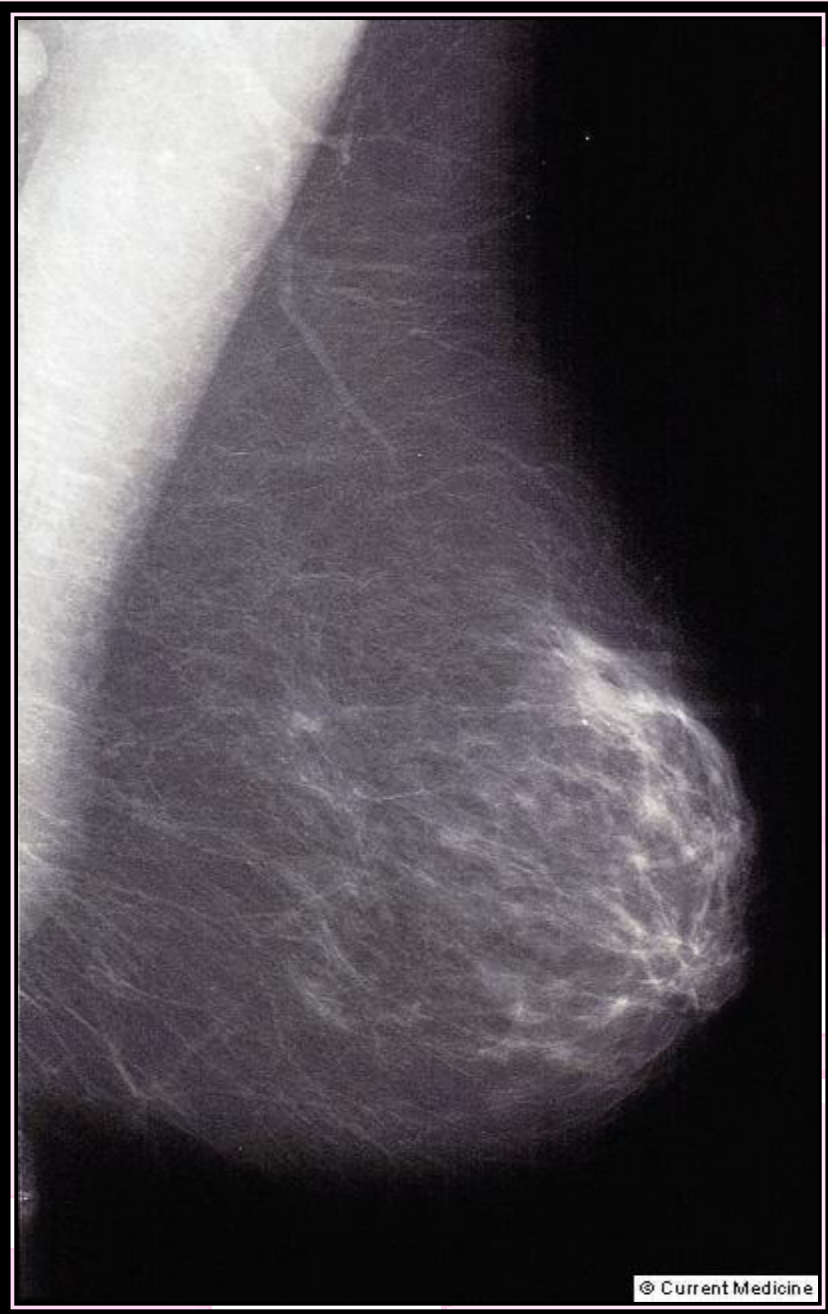
RECOGNISE THE COST OF FALSE POSITIVES

- Anxiety – “I have cancer”.
- Clinic and surgeon availability.
- Morbidity and increased cost = opportunity cost for other health initiatives.

A large, stylized white outline of a speech bubble is centered on a solid pink background. The speech bubble has a rounded top and a pointed bottom, with a smaller, similar shape inside it, creating a nested effect. The word "IMAGES" is written in a bold, dark blue, serif font across the middle of the speech bubble.

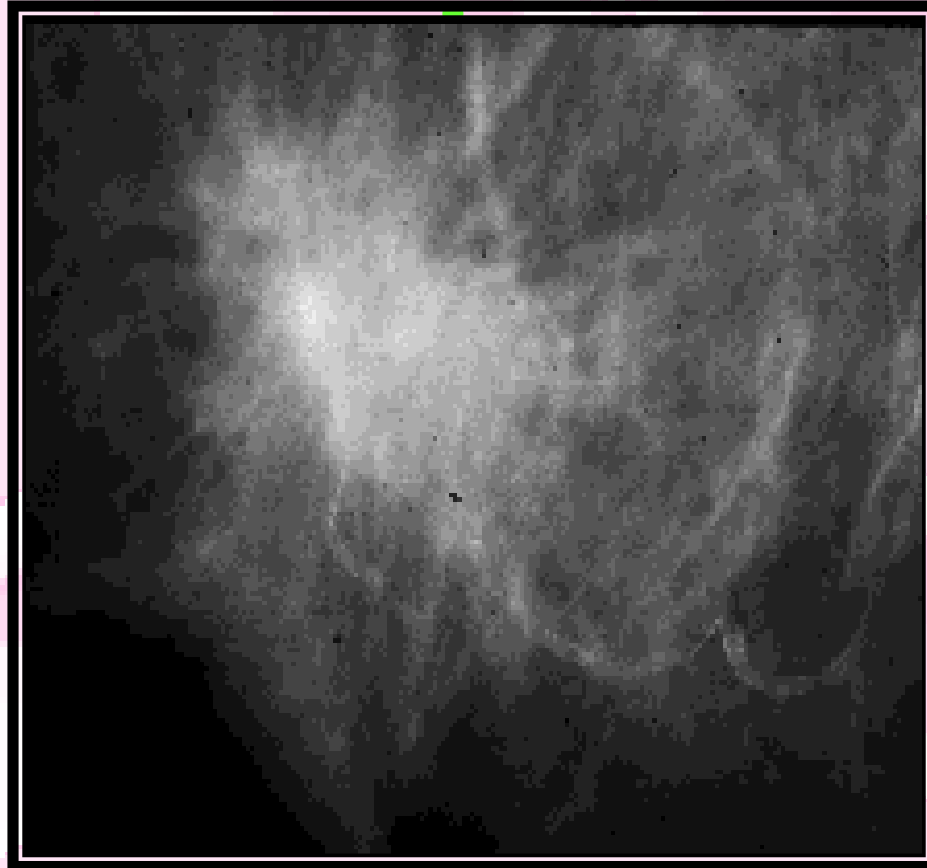
IMAGES

- Normal unilateral mammogram with two standard views. This normal mammogram is an example of a fibrofatty pattern.

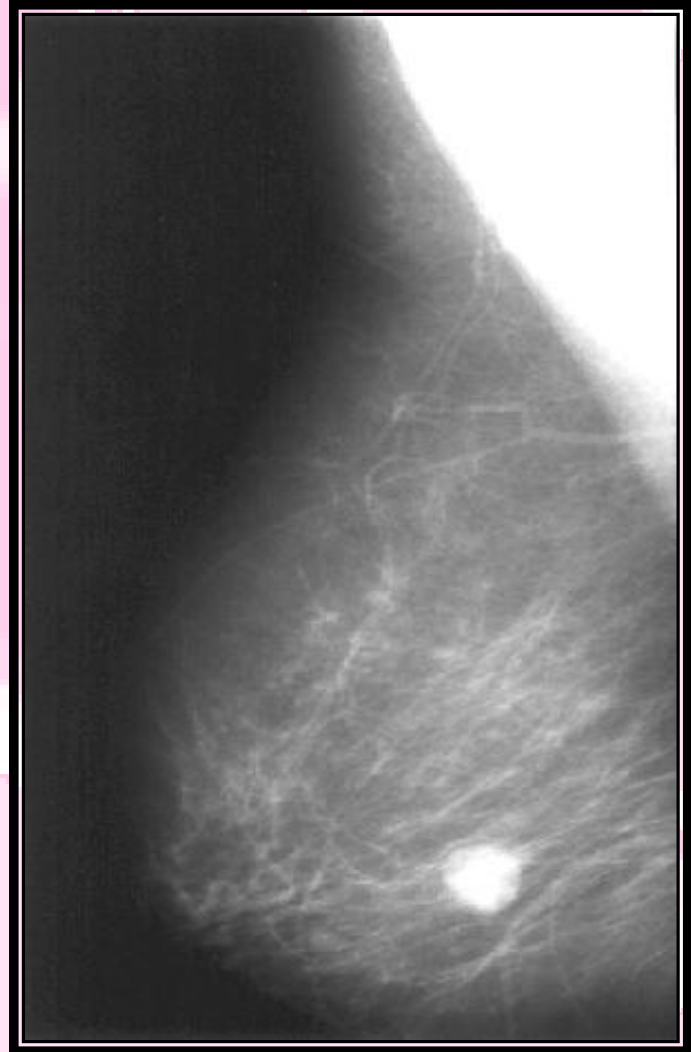
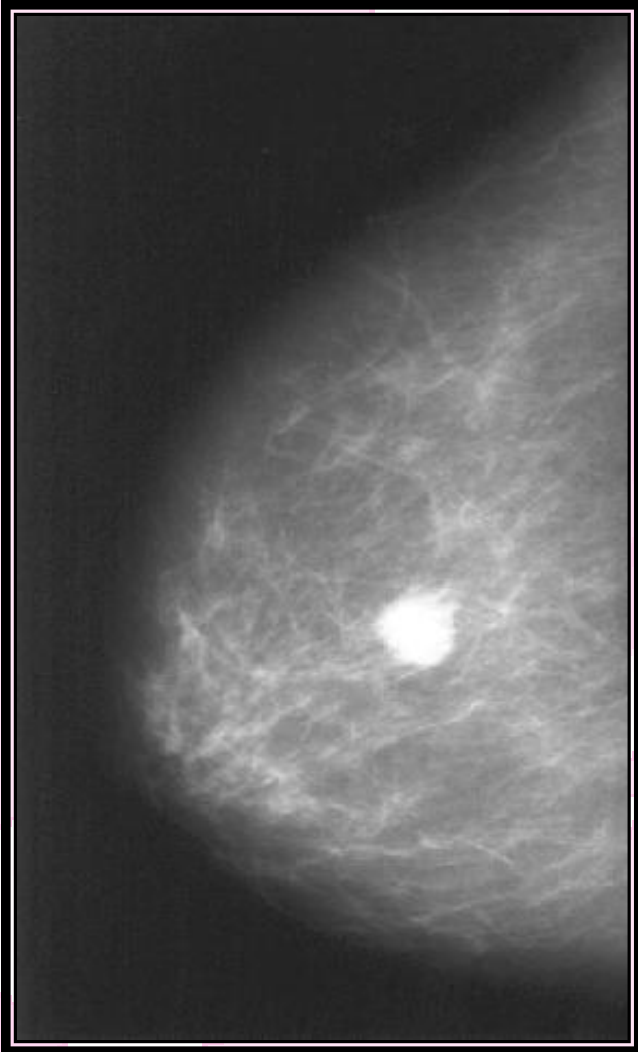
Spiculated margins

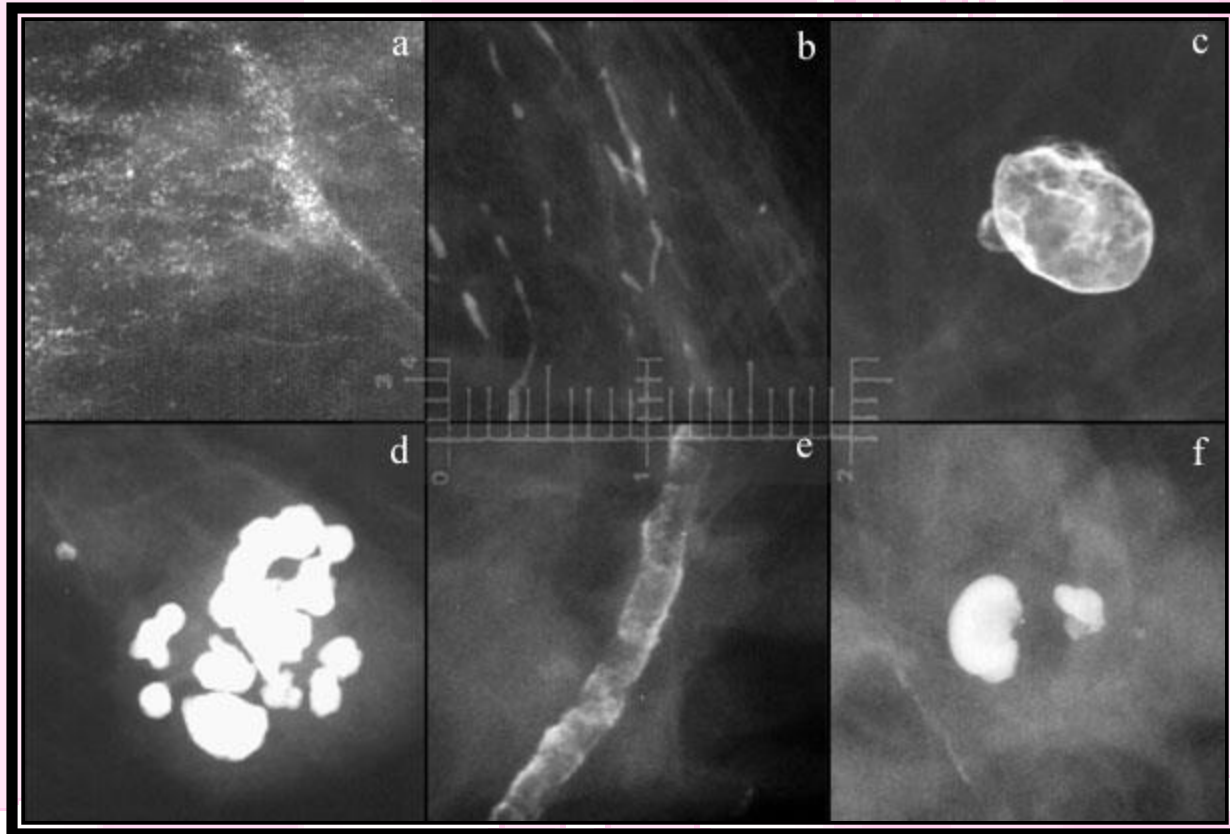
(suggestive of malignancy, biopsy should be considered):



Spiculated Mass



Benign calcifications

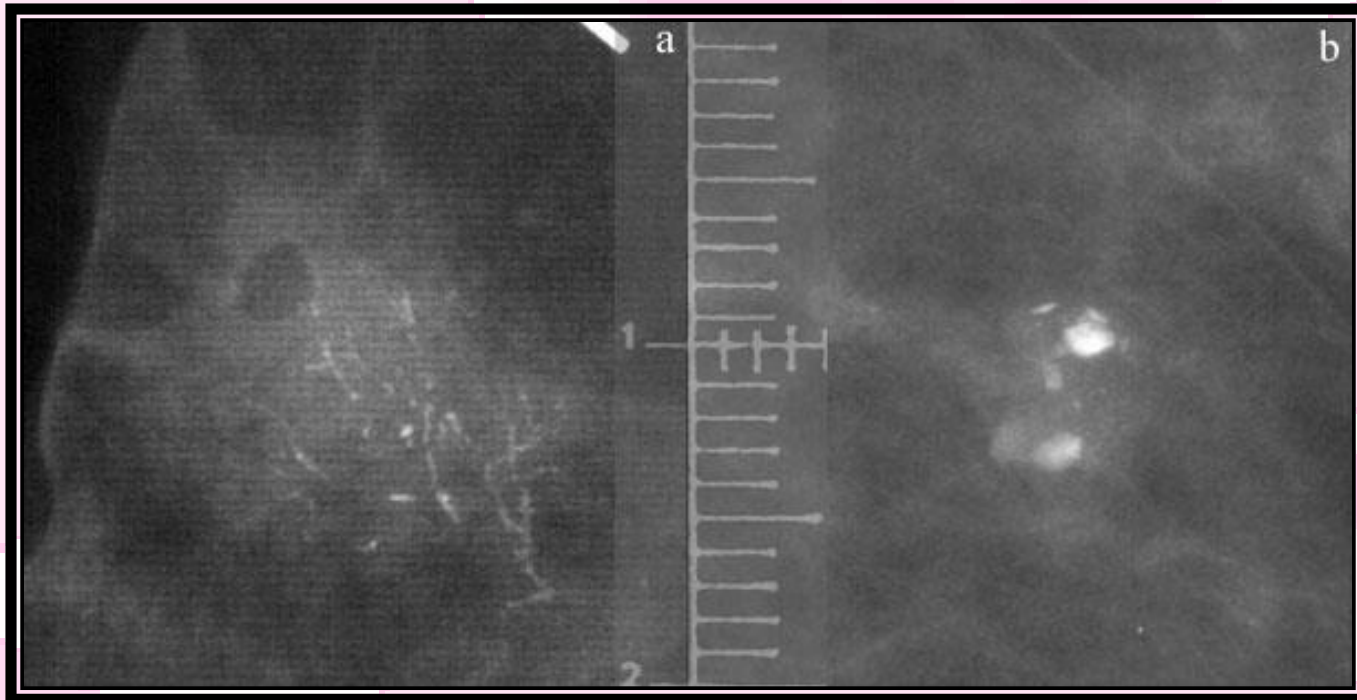


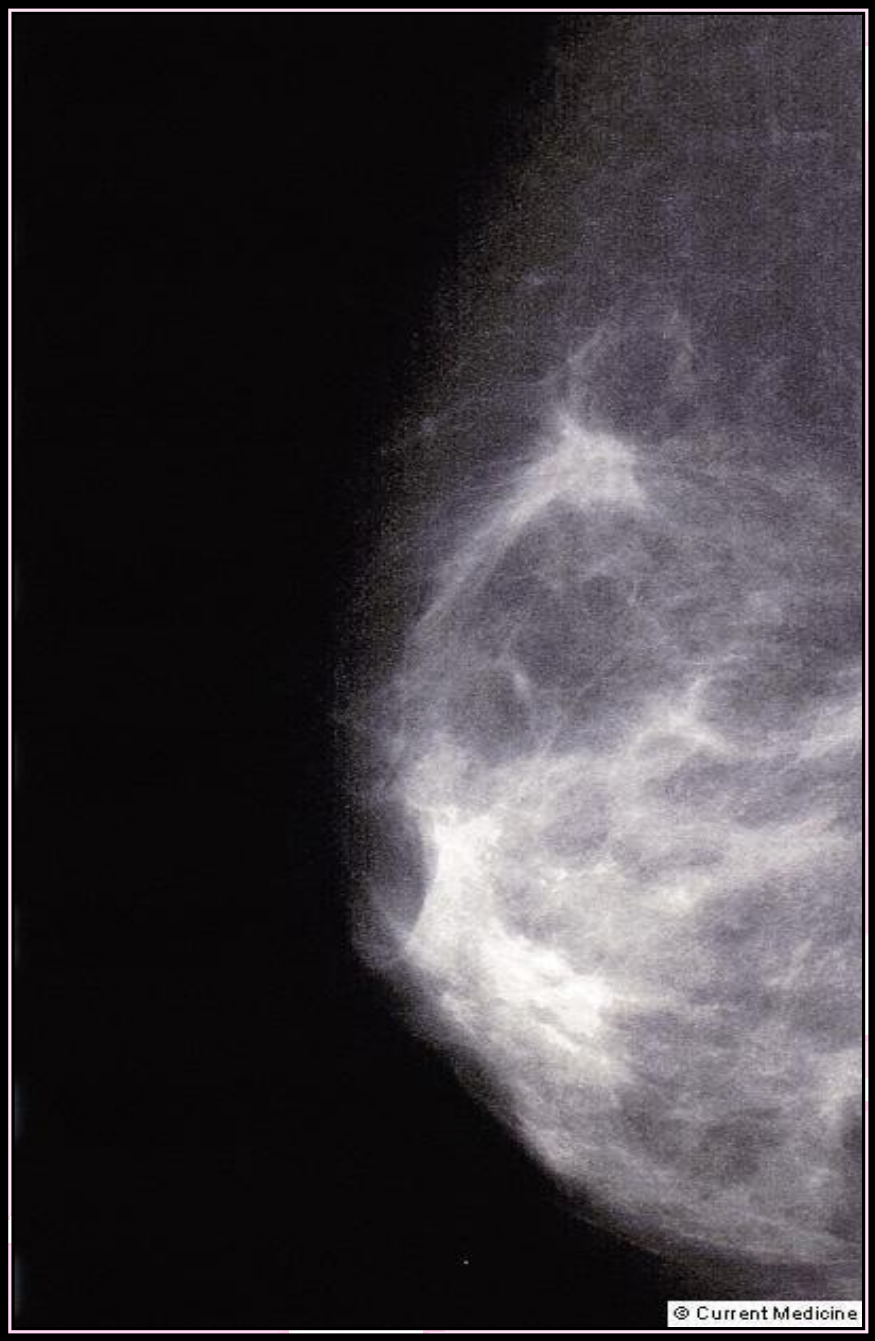
- **a-punctate b-linear c-spherical**
d-popcorn e-vascular f-smoothly dense

- b.) Linear:
Calcifications arrayed in a line that may have branch points.

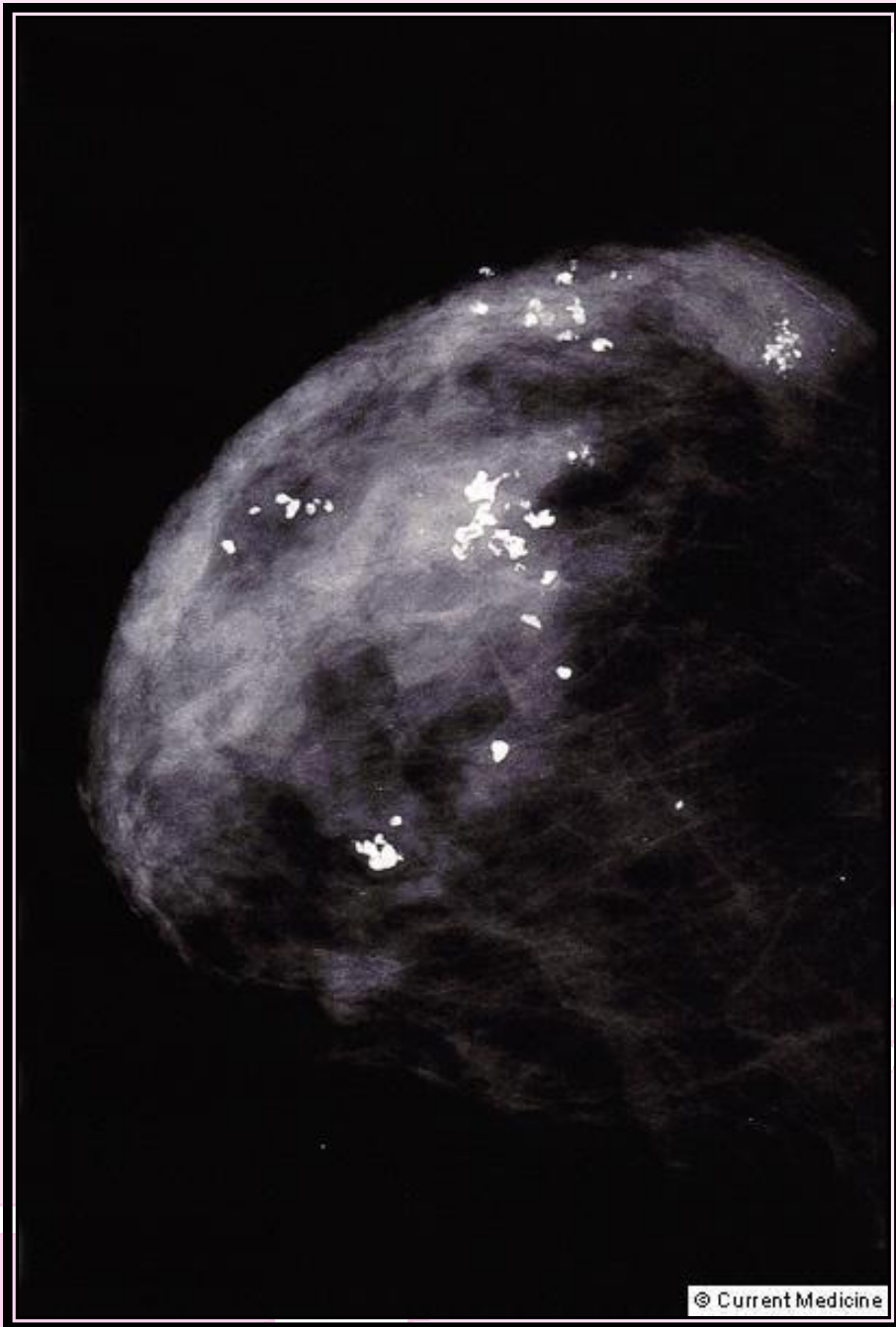
- a-DCIS

b- fibroadenoma





- Malignant mass. Intraductal and invasive ductal carcinoma not otherwise specified (NOS), nuclear grade 3. Invasive ductal carcinoma (NOS) is the most common type of breast cancer and represents 65% of the breast cancer in the United States [5]. When the histologic pattern does not fit a specific subtype, it is labeled NOS. These cancers can present as a palpable mass or a spiculated mass on mammography. Malignant-type calcifications can be seen and are usually associated with an intraductal component. Ultrasound usually demonstrates a hypoechoic spiculated mass that may be taller than wide. **A**, Mediolateral oblique view demonstrates a dense, spiculated mass with associated architectural distortion within the superior aspect of the breast. There are associated malignant-type calcifications. **B**, Directed ultrasound of the breast demonstrates a spiculated hypoechoic mass corresponding to the mammographic lesion. Ultrasound-guided core biopsy revealed invasive ductal carcinoma.



- Benign microcalcifications. **A**, Hyalinizing fibroadenoma, craniocaudal view. There are multiple scattered dense, large, coarse popcorn-like calcifications associated with a dense fibronodular pattern. When these calcifications begin to form, they may be suspicious in appearance, prompting biopsy. The calcifications may be too small to characterize, toothlike in configuration, and of varying densities. Hyalinizing fibroadenomas occur more commonly in older women. **B**, Secretory calcifications, mediolateral view. Rod-shaped, smoothly margined, dense, coarse calcifications in a pattern directed toward the nipple. These calcifications are commonly associated with ductal ectasia and periductal mastitis [2].



ULTRASOUND

ROLE OF ULTRASOUND (1)

- Characterise a mammographic abnormality.
- Characterise a mammographically occult clinical abnormality.
- Initial examination in the younger woman.

ROLE OF ULTRASOUND (2)

- Imaging guided biopsies,
- Some utility in distinguishing benign from malignant lesions.
- Still no role on screening, even in the mammographically dense breast.
- ? Developing role in monitoring neo-adjuvant therapy.

ADVANTAGES OF ULTRASOUND



- Painless.
- Does not use ionising radiation.
- Very good at detecting cysts.
- Can “see through” mammographically dense breasts.

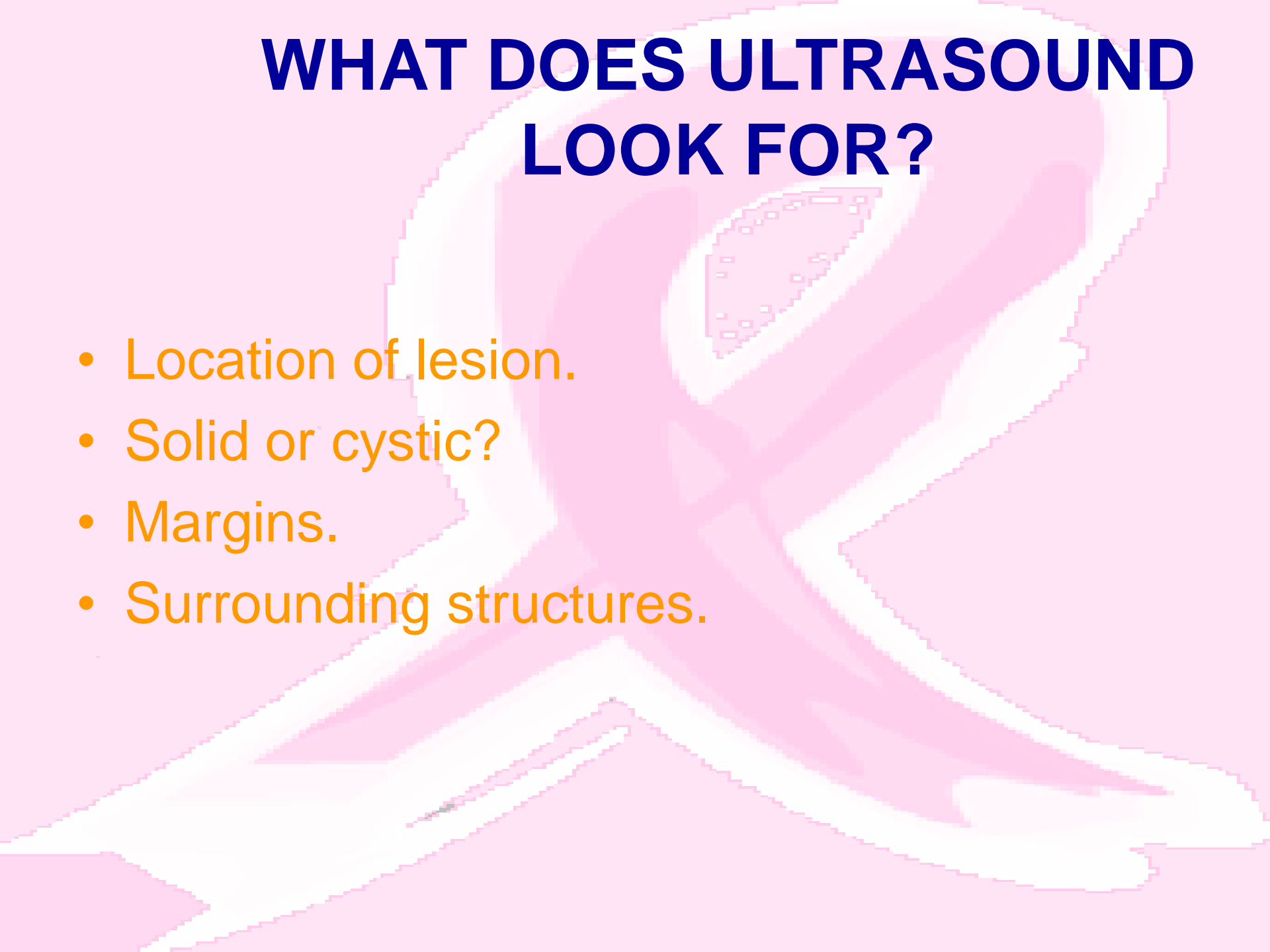
DISADVANTAGES OF ULTRASOUND



- Not good for screening the breast.
- Cannot always characterise lesions precisely.
- More operator-dependent than mammography.

WHAT DOES ULTRASOUND LOOK FOR?

- Location of lesion.
- Solid or cystic?
- Margins.
- Surrounding structures.



CYSTS

A B-mode ultrasound image showing a large, anechoic (black) cystic structure. The cyst has a smooth, well-defined border and is surrounded by a thin layer of tissue. The background shows the internal structure of the organ, with various shades of gray representing different tissue densities.

- Contain no or few echoes.
- Have smooth margins.
- Are often compressible with the ID.
- Have posterior enhancement (increased echoes = whiter).

BENIGN MASSES



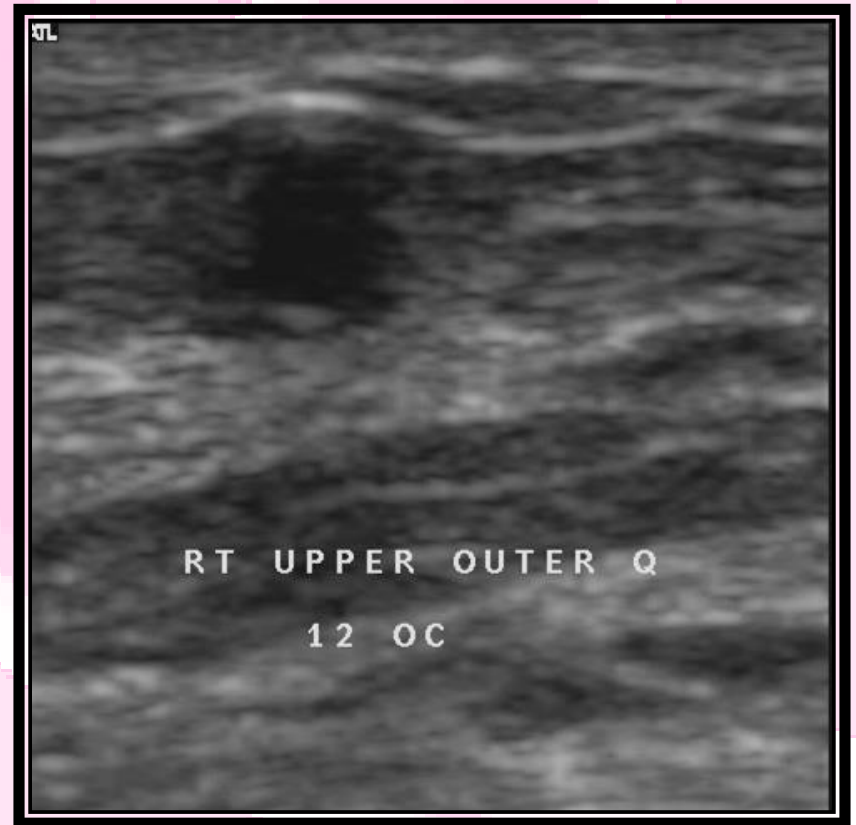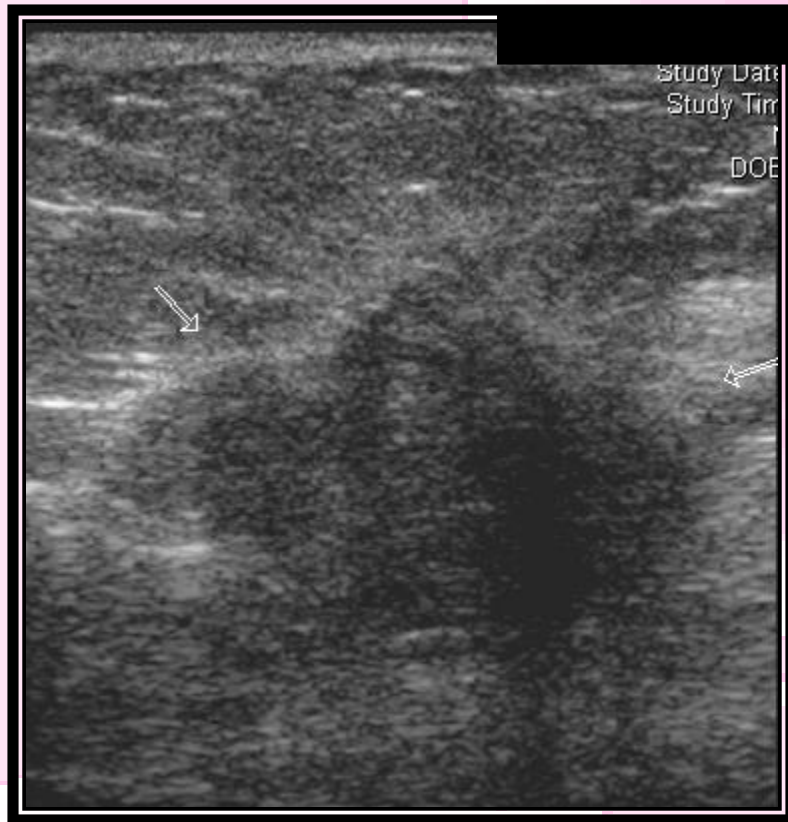- Have smooth margins.
- Have relatively uniform internal appearance.
- Don't disturb surrounding tissues.
- Are usually “wider than tall”.

MALIGNANT MASSES

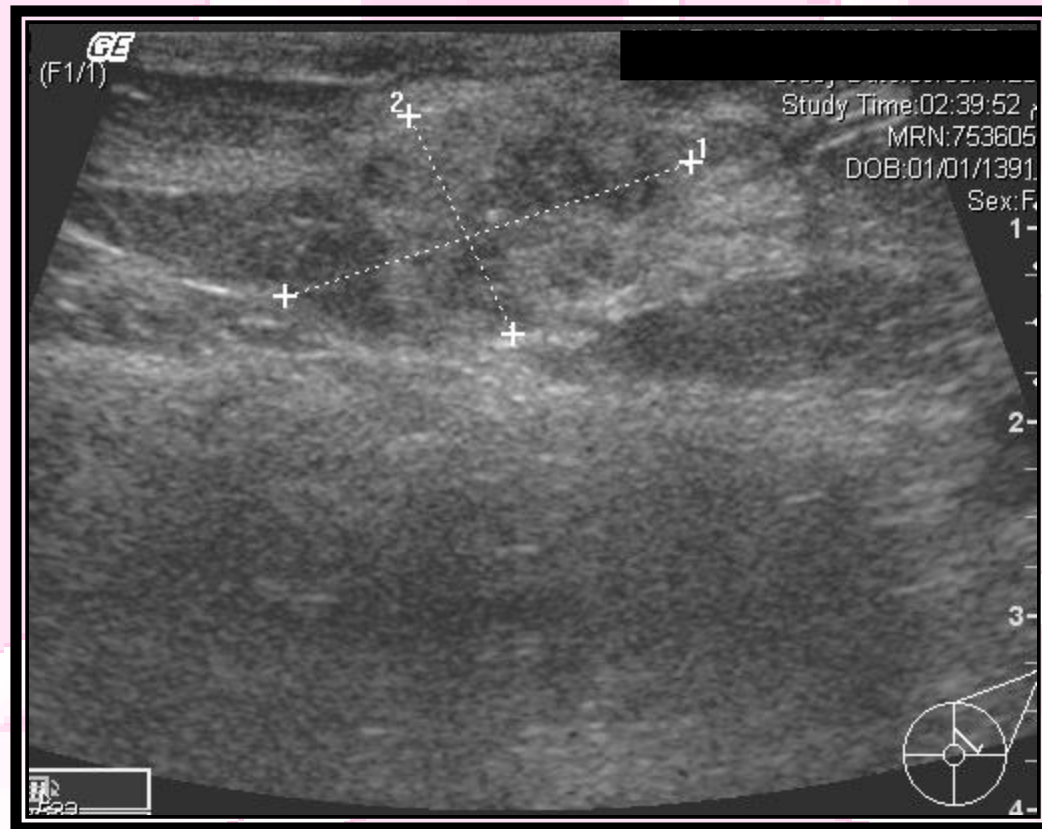


- Have irregular or indistinct margins.
- Have heterogenous internal appearance.
- Often cut across surrounding tissue planes.
- Are often “taller than wide” or rounded (special types).

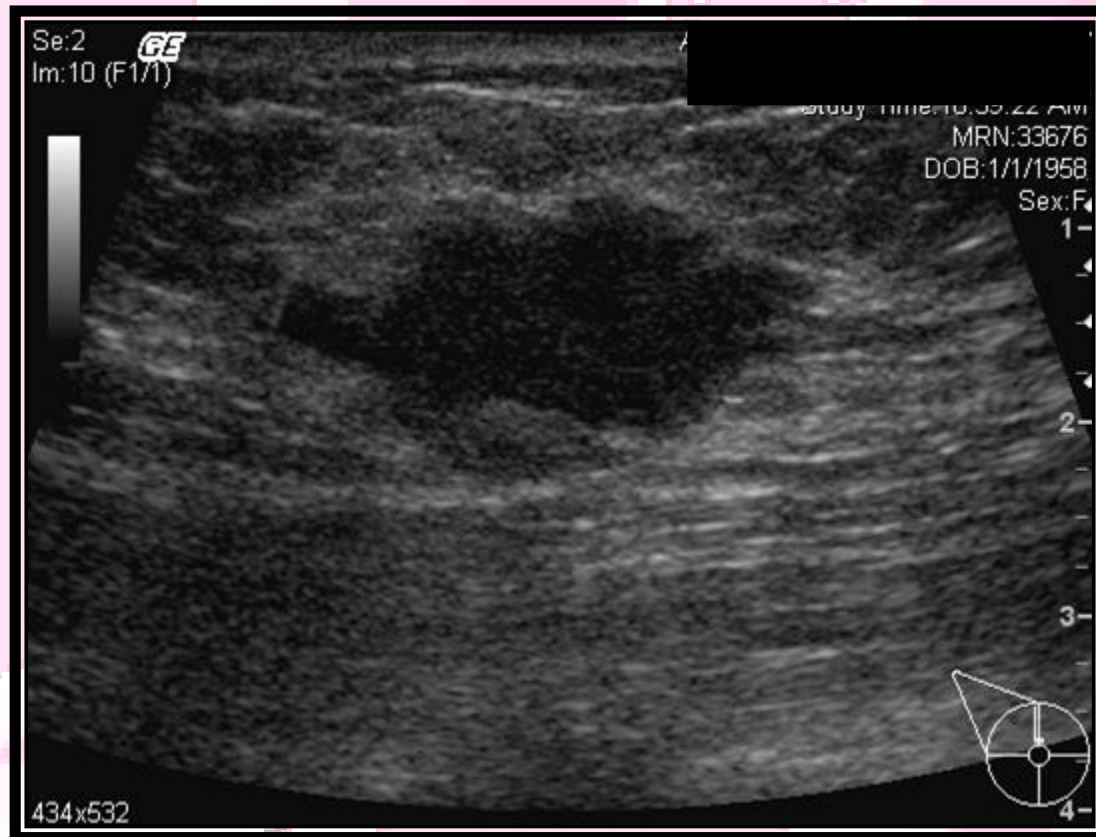
Irregular shape

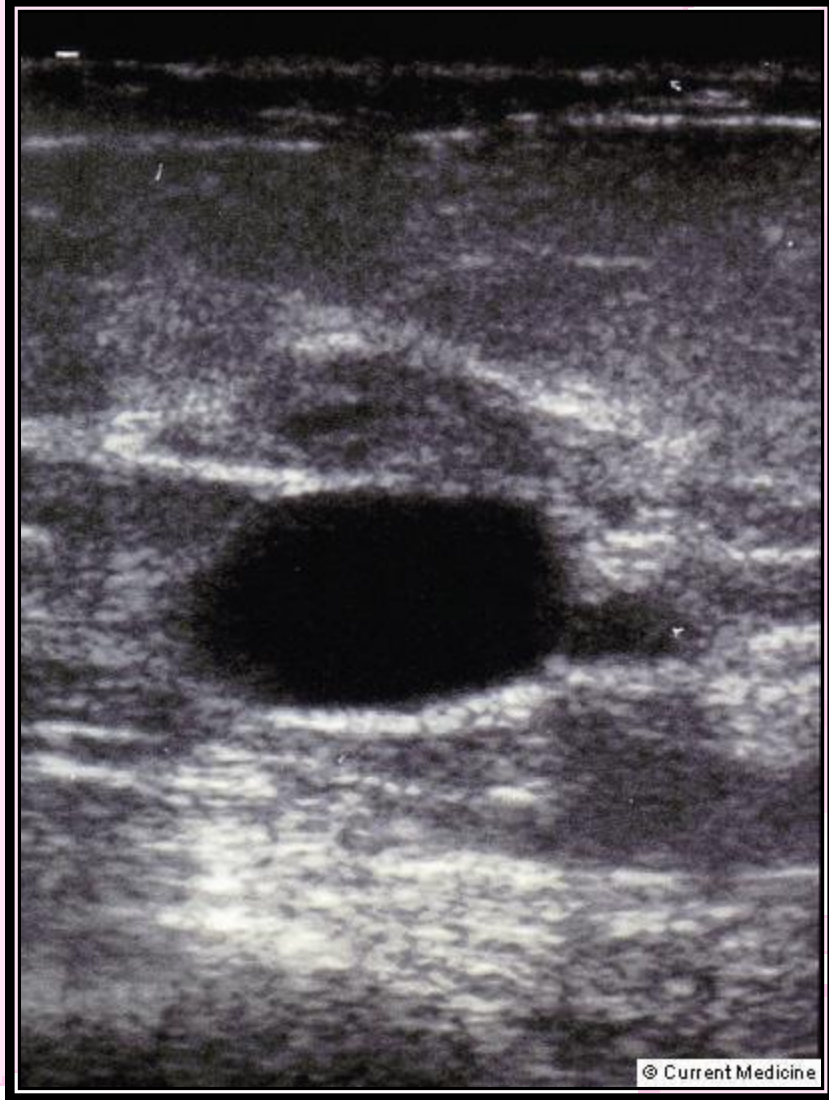

ill-Define margins



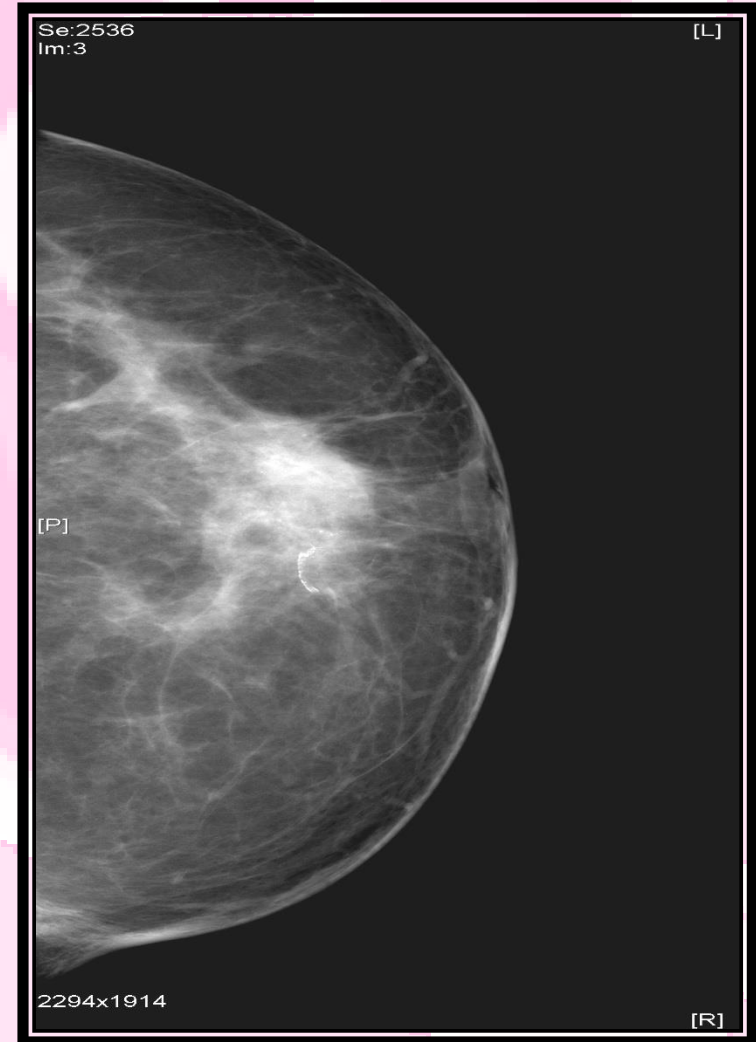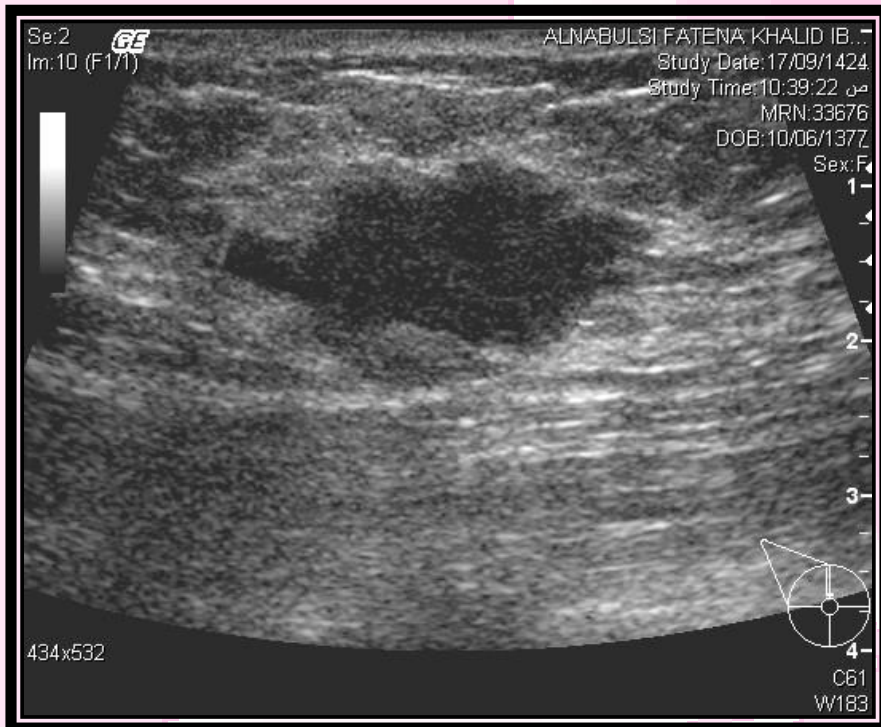
Spiculated Margins



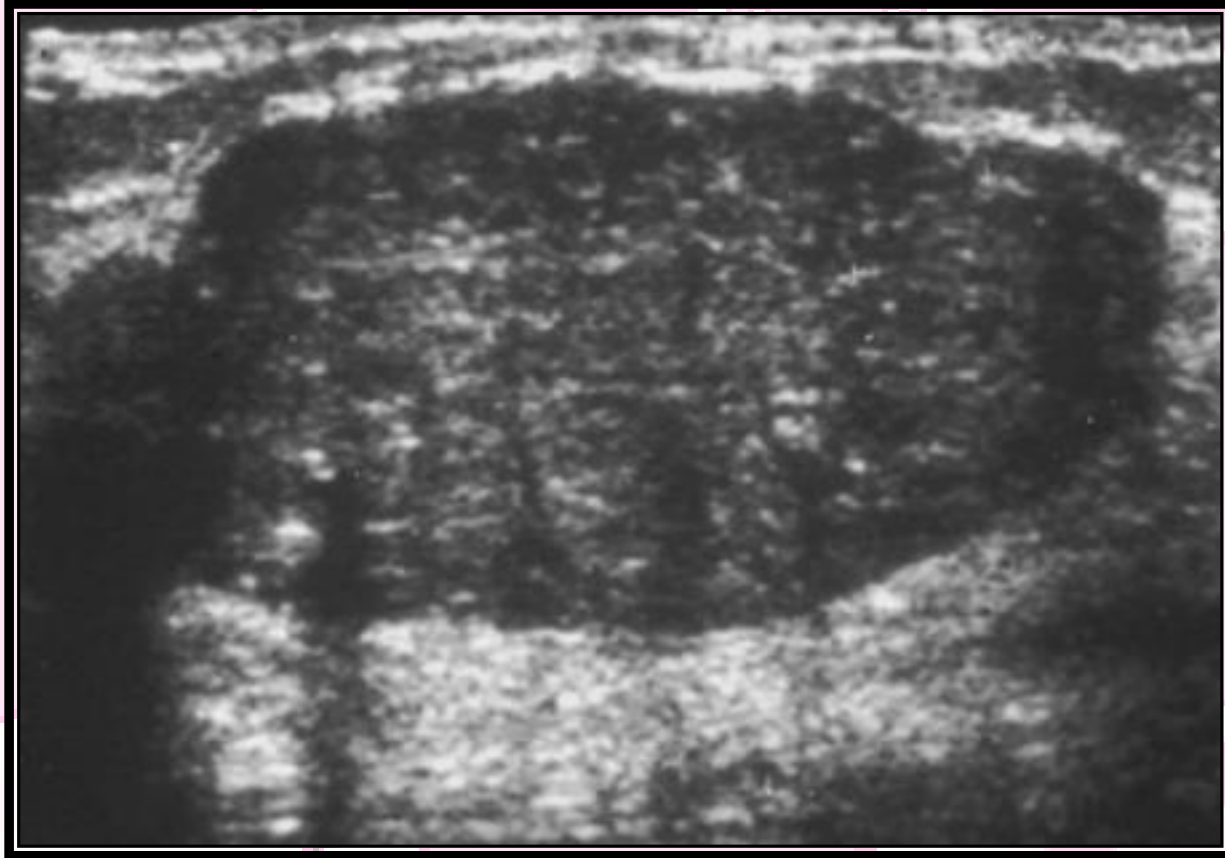


- Benign mass: simple cyst. This patient presented with a new generally well-defined mass on her screening mammogram. Ultrasound demonstrates a well-defined, smoothly marginated anechoic ovoid mass with increased through transmission consistent with a benign simple cyst. Because this finding indicates a benign lesion, the patient was told to return to annual screening follow-up. Cysts can present as a palpable mass or a focal tender area within the breast. A majority of cysts are found in asymptomatic women on their screening mammogram. On mammography, they appear as a mass and may have associated benign rim or eggshell microcalcifications. Ultrasound is the confirmatory diagnostic test demonstrating a well-defined mass devoid of internal echotexture. If any internal echoes are demonstrated, ultrasound-guided needle aspiration is recommended to fully exclude malignancy.

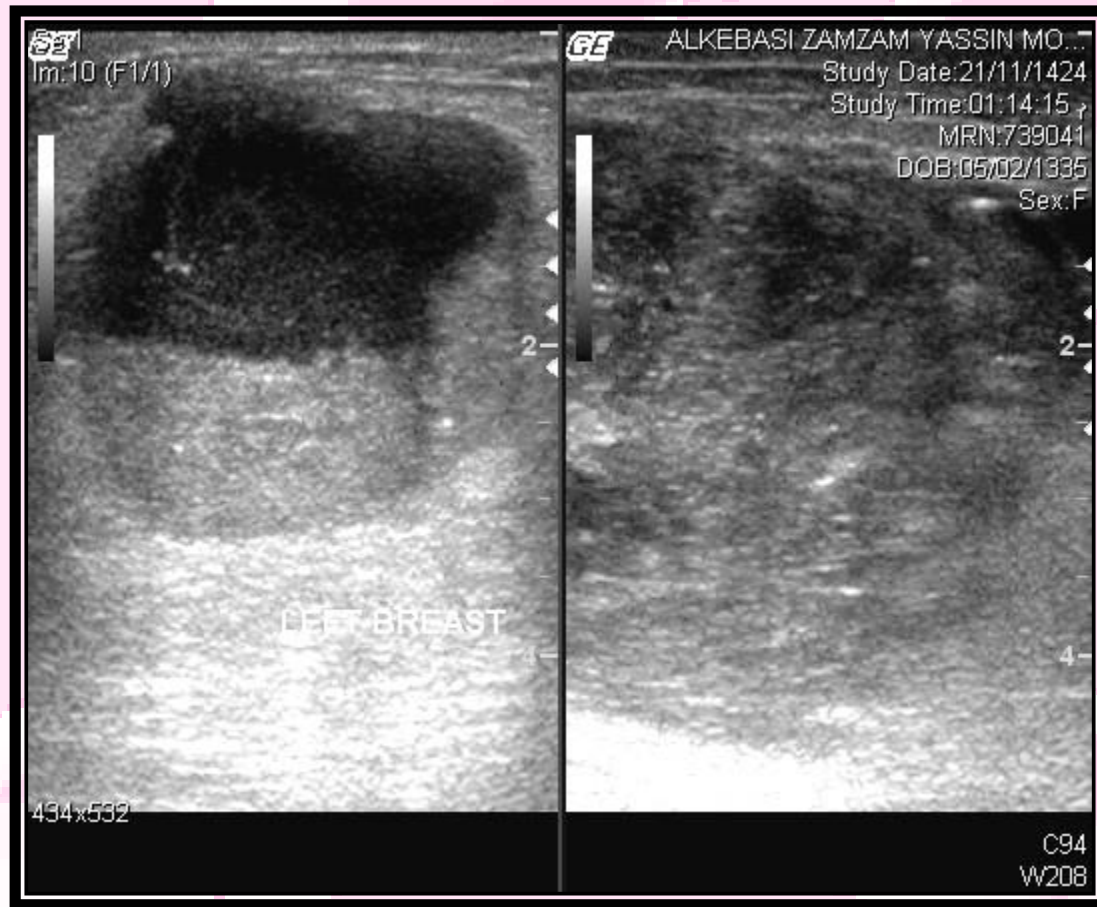
Spiculated margins



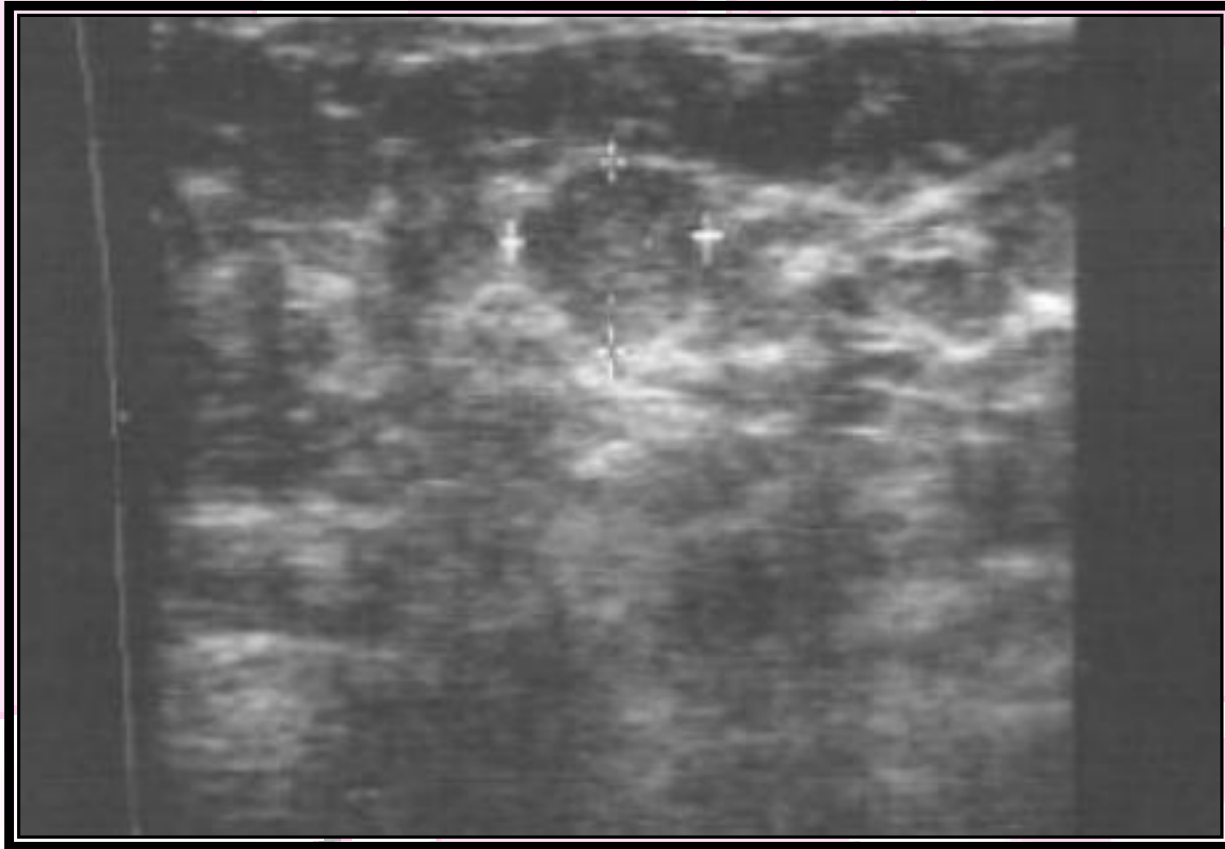
Ultrasound Fibroadenoma



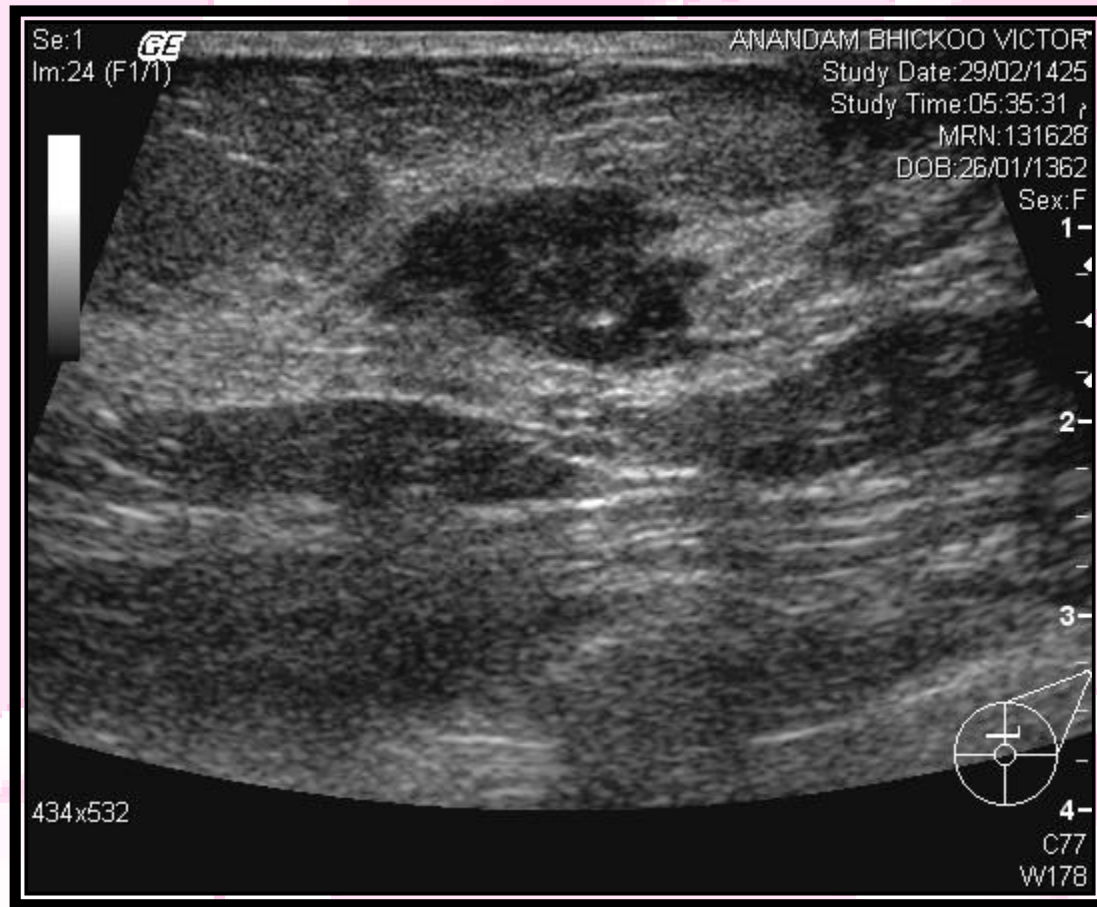
Phyllodes tumor with malignant characters



USS spiculated mass



Spiculated Margins



BASIC INVESTIGATIONS OF BREAST DISEASES... *Cont!*

F.N.A.B.

- *Description of procedure*
- *Clinical, U/S guided, mammotomes*
- *Sensitivity 80-98%*
- *False negative 2-10%*

F.N.A.B

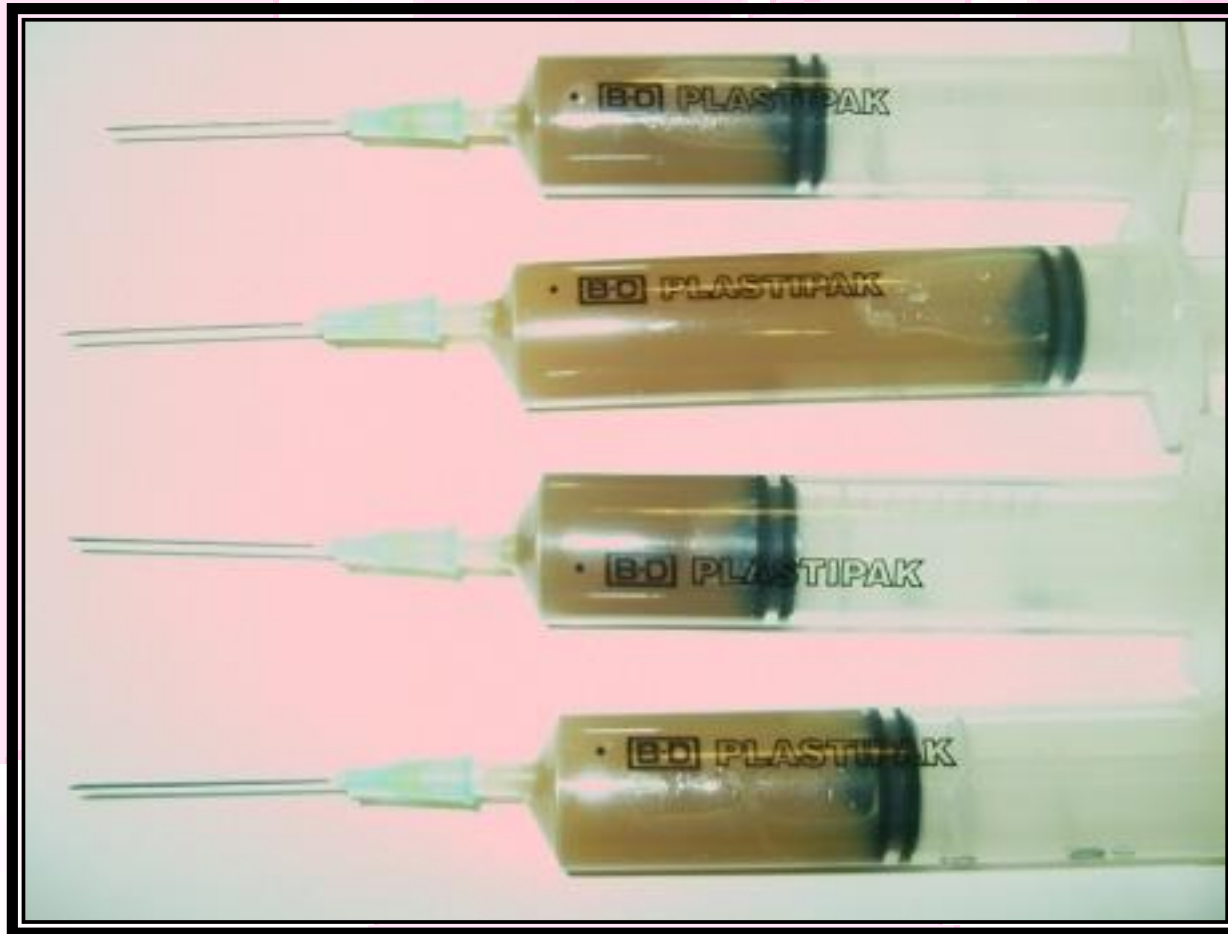Scoring of result Code 0 → Code 5

- Core biopsy
 - *Tissue diagnosis*
 - *Painful*
 - *Costly*
 - *Receptor status*

BREAST CYSTS:

- Aspirate (if more than 3 cm) if bloody go for surgical biopsy.
If non-bloody and disappear completely → observe.

If non-bloody and doesn't resolve → surgical biopsy.



Fibroadenoma

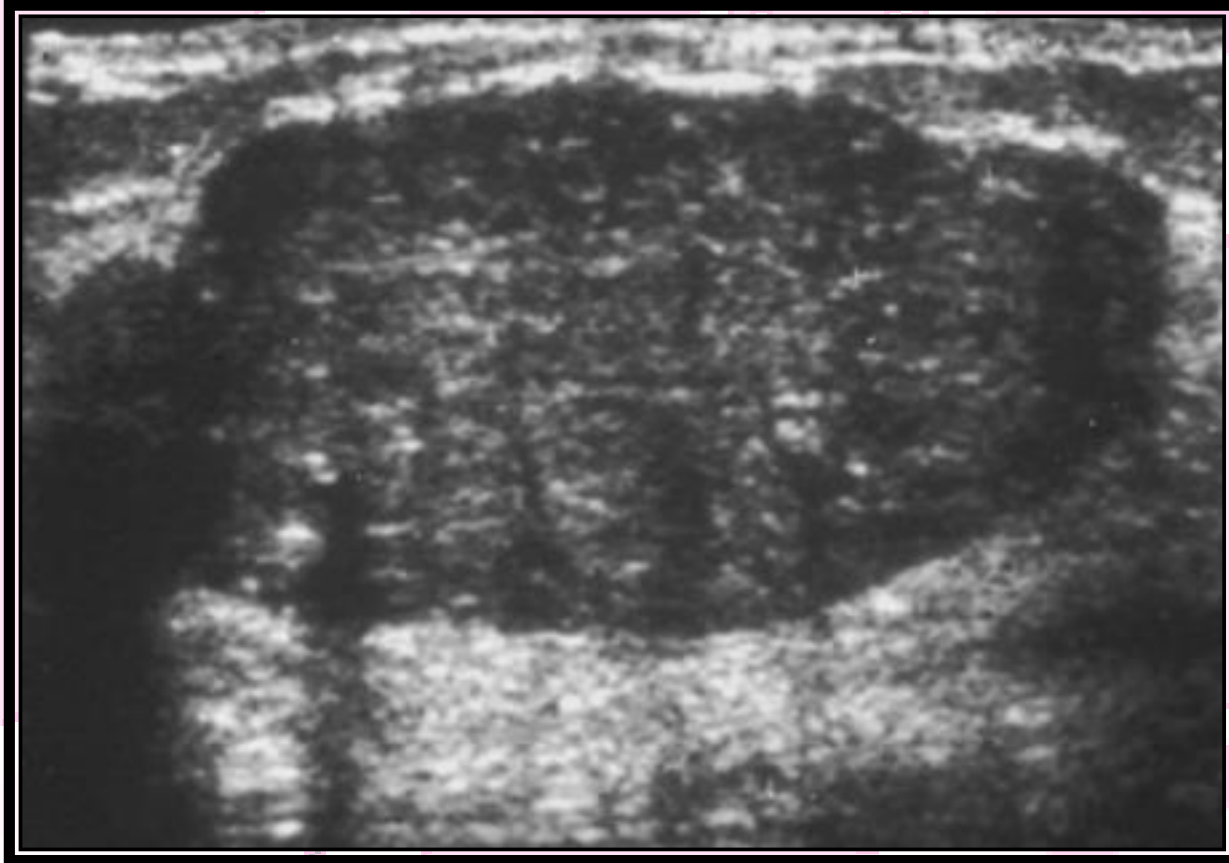
- Benign lesions, 15-30 years old of age.

Management:

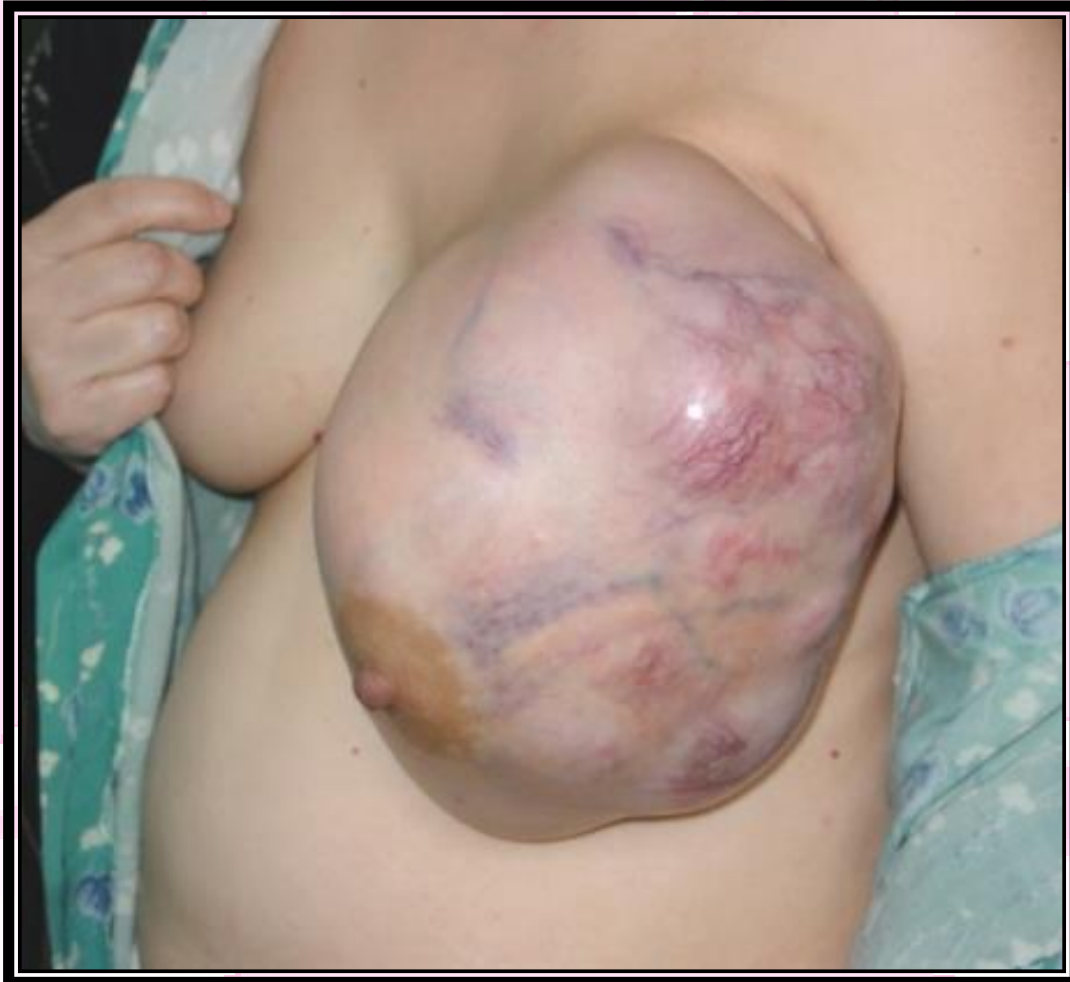to leave alone or to excise?

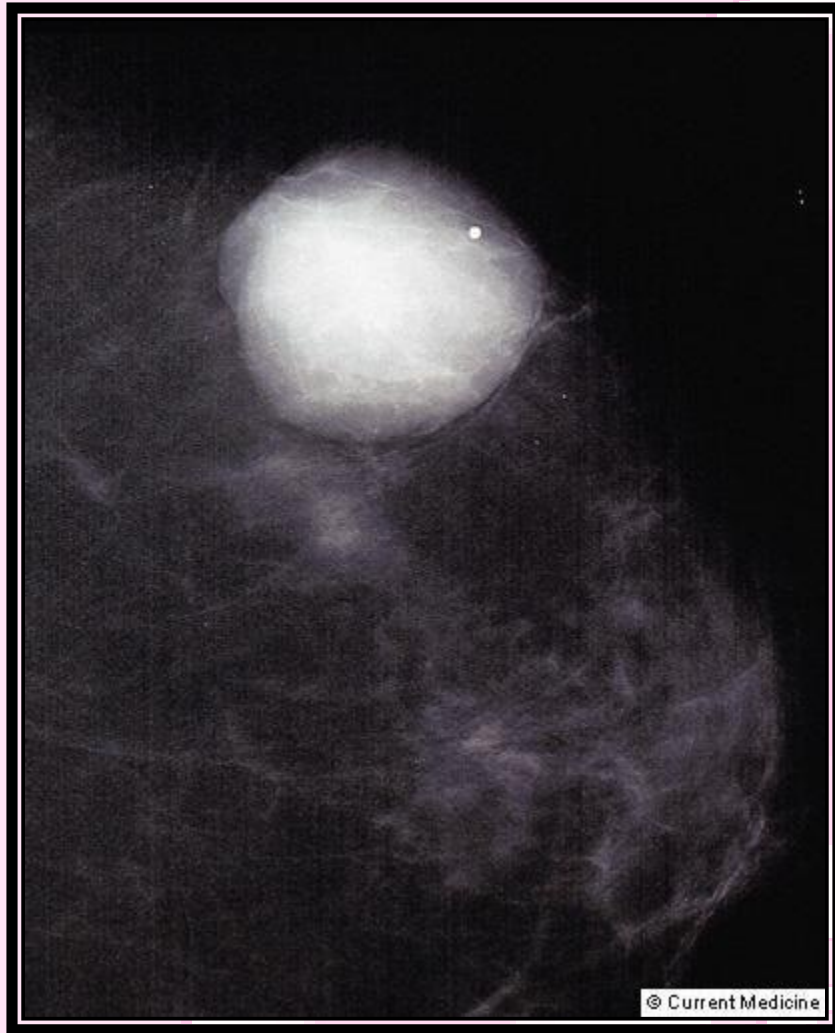e.g 1cm mass in a young female (BIRADS 2)

Ultrasound Fibroadenoma



phylloides

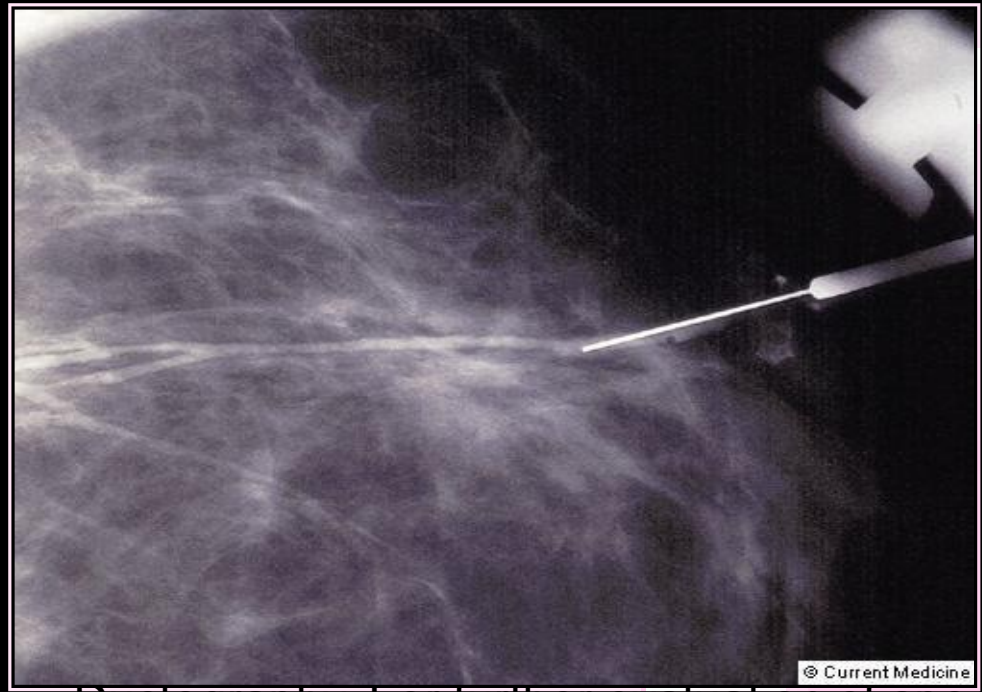




- Phyllodes tumor. The phyllodes tumor or cystosarcoma is believed to be related to the fibroadenoma. The malignant form of this lesion (about 10%) can metastasize hematogenously most commonly to the lungs and not to the axillary lymph nodes. Most of these tumors are benign, but approximately 25% recur locally if they are incompletely excised. Lesions larger than 3 cm are more likely to be malignant. By both mammography and ultrasound, these lesions present as well-defined masses that are very similar in appearance to a benign fibroadenoma. On sonographic evaluation, the malignant forms are more likely to have cystic spaces [8]. This craniocaudal view demonstrating a large, well-circumscribed, dense, palpable mass within the lateral aspect of the breast. According to the patient's history, this mass had rapidly increased in size. Ultrasound core biopsy revealed phyllodes tumor.

NIPPLE DISCHARGE

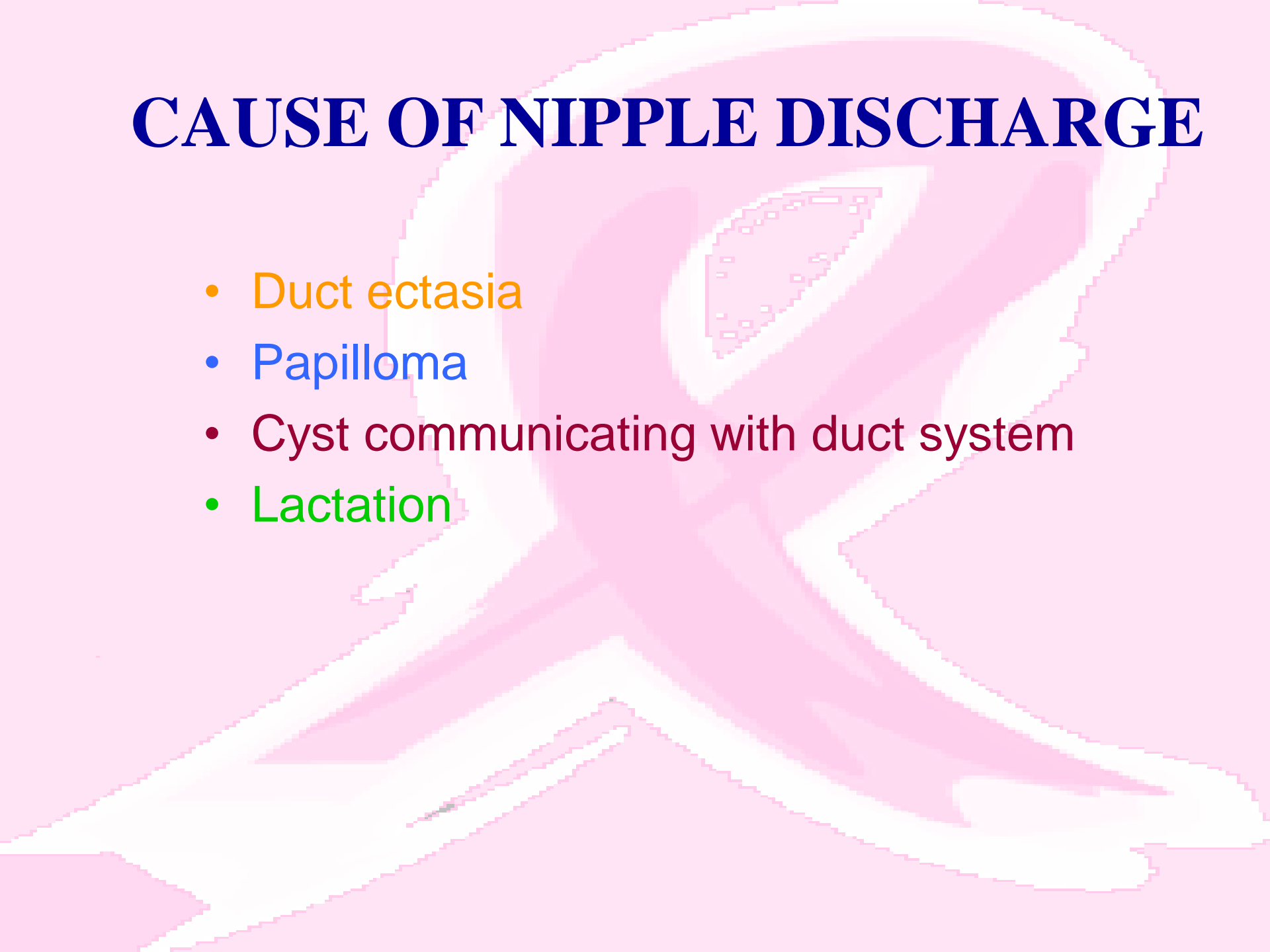
- 5% of women coming to clinic.
- 95% of them → benign
- Most important points in history are
 - *Is it spontaneous or on pressure?”*
 - *Is it coming from single or multiple?*
- Colors.
 - *Serous, serosanguinous, bloody, clear, milky, green, blue-black.*
- Investigation.
 - *H&P*
 - *R/O mass by exam and mammogram*
- Identify source of discharge.
- Consider ductography.



Ductography. For further evaluation of spontaneous nipple discharge, a painless ductogram can be performed. Using aseptic technique, a 30-gauge sialography catheter is used to cannulate the effected single ductal orifice. Approximately 0.2 to 0.4 mL of radiographic contrast is injected through the catheter. Magnification views in the true lateral and craniocaudal projections are then obtained. Ductography is useful in detecting the location of the lesion (or lesions) within the ducts and the extent of involvement. This information can be extremely helpful in presurgical planning. **A.** Normal ductogram. Magnification view demonstrates a normal contrast-opacified duct. There is no dilatation or filling defect. **B.** Abnormal ductogram. Magnification view demonstrates a single lobulated filling defect in the cannulated duct with associated ductal ectasia. Before surgery, a preoperative ductogram was performed with injection of a combination of radiographic contrast and methylene blue to localize the specific duct. The patient was found to have a solitary papilloma.

CAUSE OF NIPPLE DISCHARGE

- Duct ectasia
- Papilloma
- Cyst communicating with duct system
- Lactation



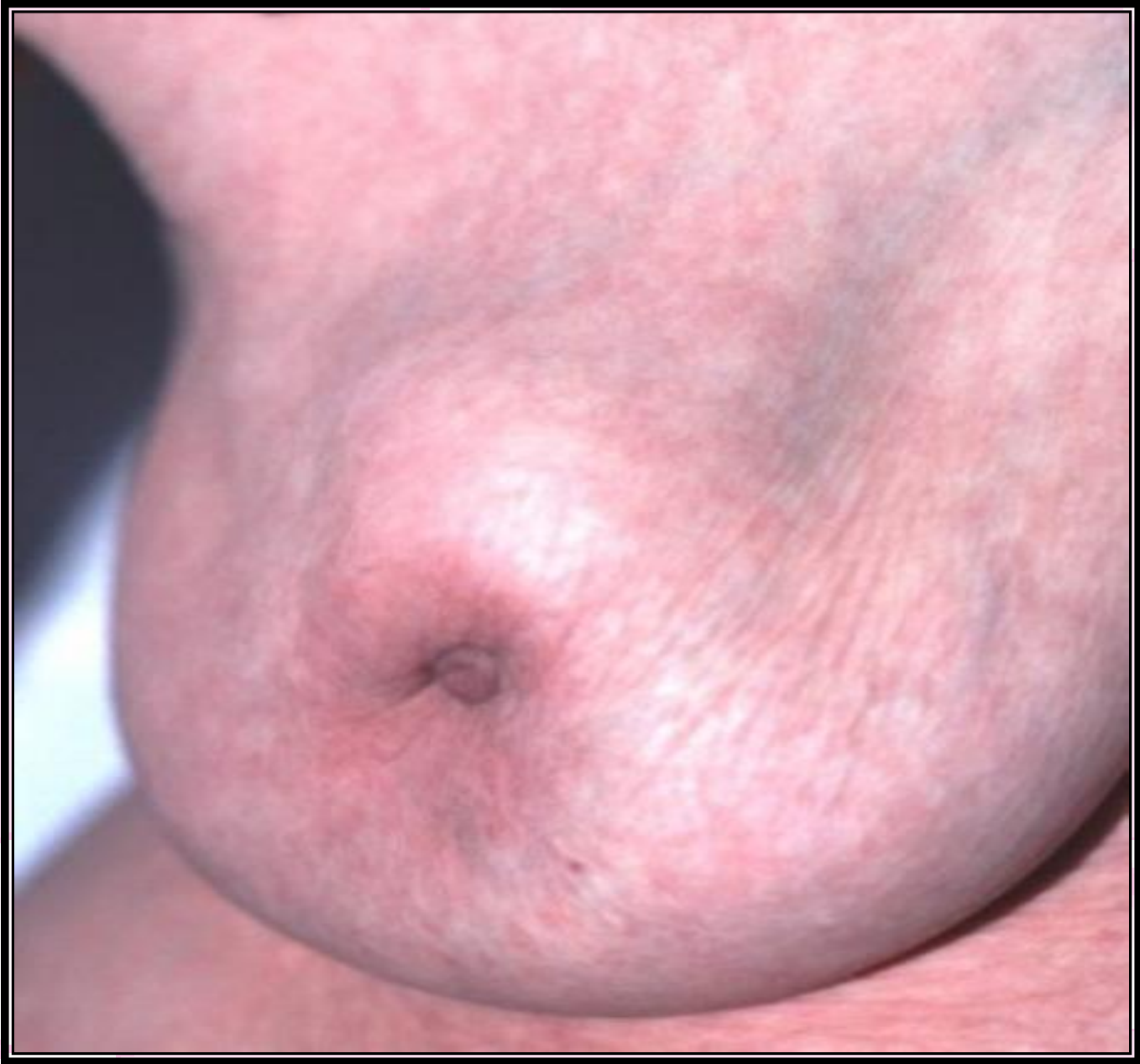MANAGEMENT

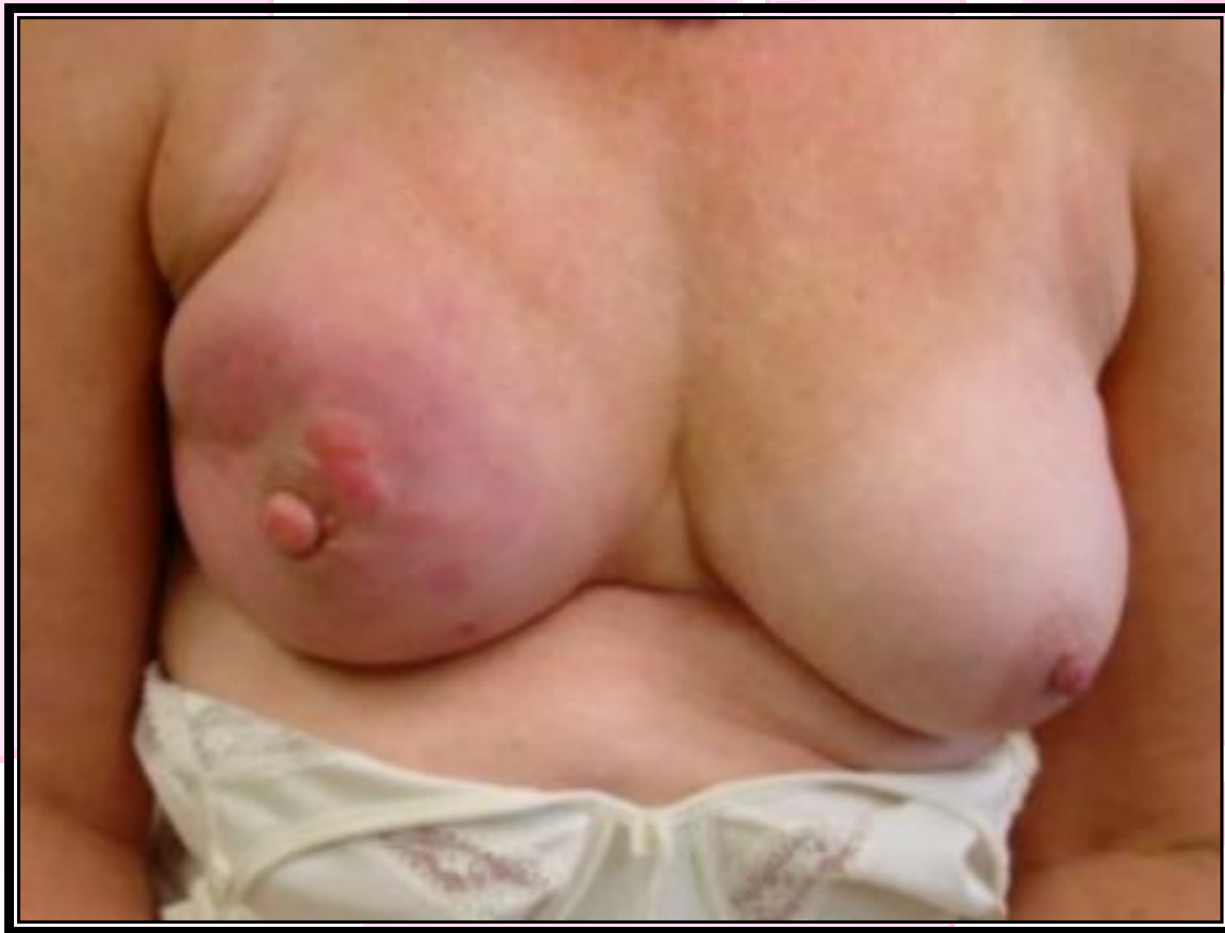

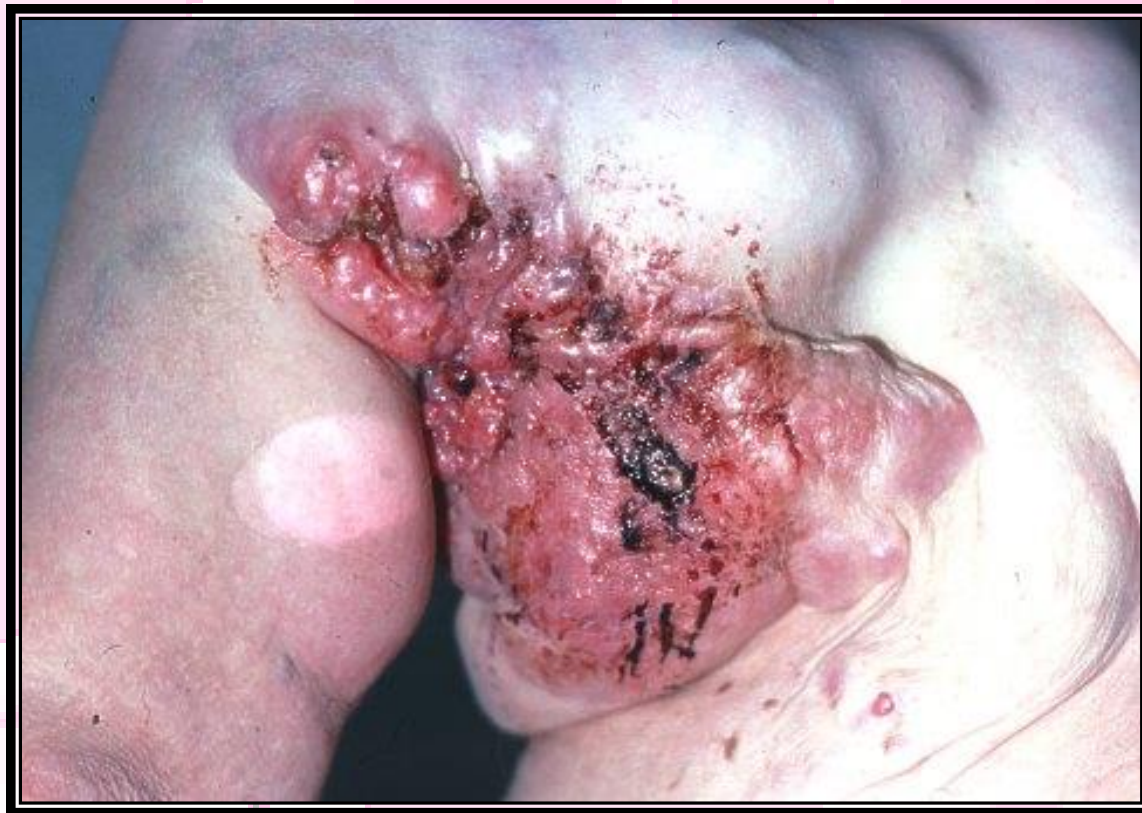- Observation
- Single duct excision
- Total duct excision



**BREAST
CANCERt**







Fast Facts

- Killer of women

USA 1:8

KSA around 3000 cases last year

250 000 cases of cancer breast last year (USA)

45000 deaths due to it in one year (USA)

Fast Facts

Cont.

- Breast cancer is the most common cause of death from cancer in western women
- The most common presentation is a painless breast mass

Fast Facts

Cont.

- 9 out of 10 women who get breast cancer do not have a family history of the disease
- Age is the biggest risk factor in developing breast cancer – over 70% of cases occur in women around 50 years
- Women aged 50–69 who have a breast screen every two years can reduce their chance of dying from breast cancer by at least 30%

Fast Facts

Cont.

- Breast cancer is the most common cancer in women aged over 35 years - 29% of all cancers diagnosed
- The average age of diagnosis of breast cancer in women is 45 - 55 years

Fast Facts

Cont.

- the five year survival rate for women diagnosed with breast cancer is around 85 %
- Although we know of many factors that contribute to the risk of women getting breast cancer, the cause remains unknown

Five-Year Survival Rates in Women with Breast Cancer*

Stage at diagnosis

Survival rates (%)

Localized

96.8

Regional

75.9

Distant

20.6

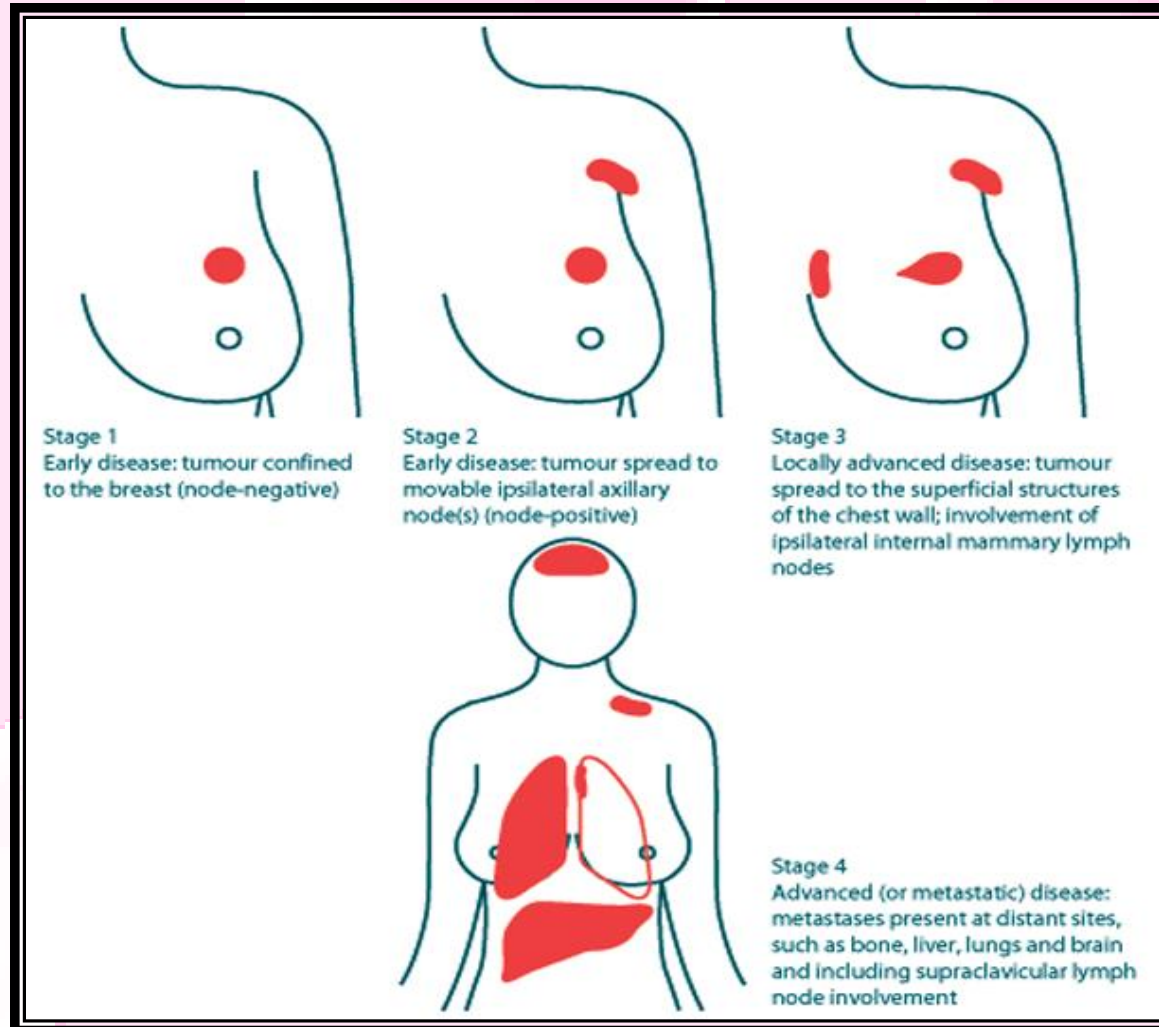
*--Based on U.S. statistics from 1986 to 1993.

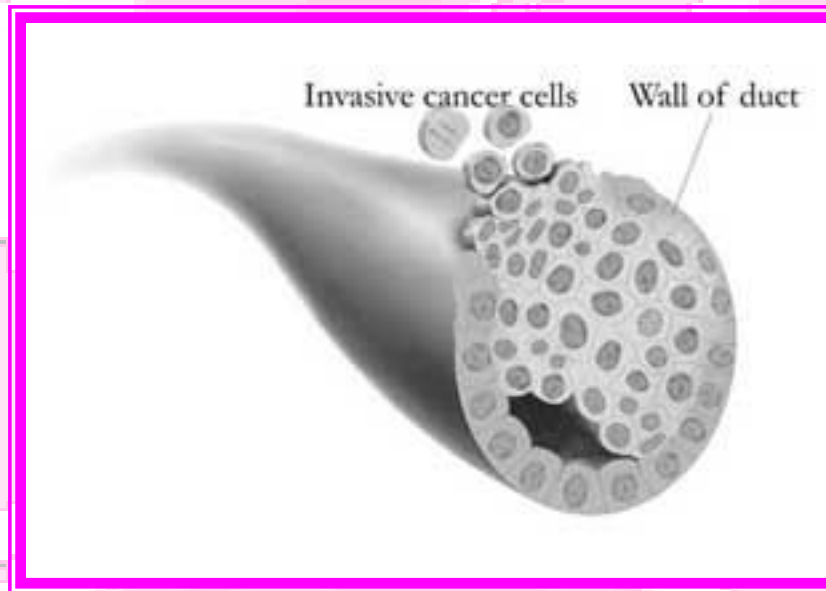
Reprinted with permission from American Cancer Society. Breast cancer facts and figures. Atlanta: American Cancer Society, 1997:14.



STAGING

Staging Classification of Breast Tumour





- This picture shows cancer that has spread outside the duct and has invaded nearby breast tissue.



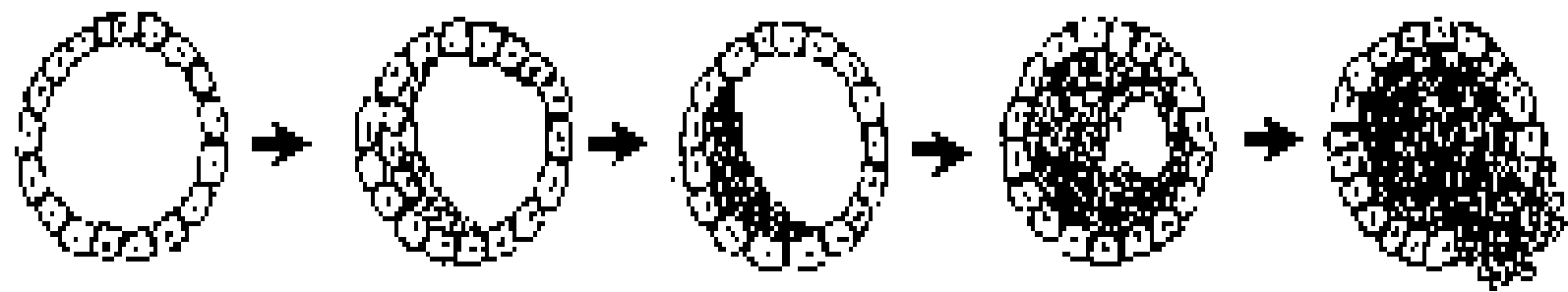
Normal
milk duct

Hyperplasia
too many cells

Atypia
cells becoming
abnormal

DCIS
cancer cells
inside the ducts

**Invasive
Cancer**
cells spread out
of the duct



How is DCIS treated ?

- Depending on the degree of DCIS the options of treatment are
 - Total mastectomy**
 - Lumpectomy**
 - Lumpectomy and radiation therapy**
- DCIS does not usually spread to the axillary lymph nodes so these are usually not removed.

PROGNOSTIC FACTORS



1. Size
2. Grade
3. Lymph nodes
4. Biological characteristic of the tumor



Histopathological Types of Breast Cancer

- **Infiltrating (or invasive) Ductal Carcinoma (IDC)**

- Starting in a milk passage, or duct, of the breast, this cancer breaks through the wall of the duct and invades the breast's fatty tissue. It can spread to other parts of the body through the lymphatic system and through the bloodstream. Infiltrating or invasive ductal carcinoma accounts for about 80 percent of all breast cancers.

- **Infiltrating (or invasive) Lobular Carcinoma (ILC)**

- This type of cancer starts in the milk-producing glands. About 10 to 15 percent of invasive breast cancers are invasive lobular carcinomas.

- **Medullary Carcinoma**

- This type of invasive breast cancer has a relatively well-defined distinct boundary between tumour tissue and normal breast tissue. It accounts for about 5 percent of all breast cancers. The prognosis for medullary carcinoma is better than that for invasive lobular or invasive ductal cancer.

- **Colloid Carcinoma**

- This rare type of invasive disease, also called mucinous carcinoma, is formed by mucus-producing cancer cells. Prognosis for colloid carcinoma is better than for invasive lobular or invasive ductal cancer.



- **Tubular Carcinoma**

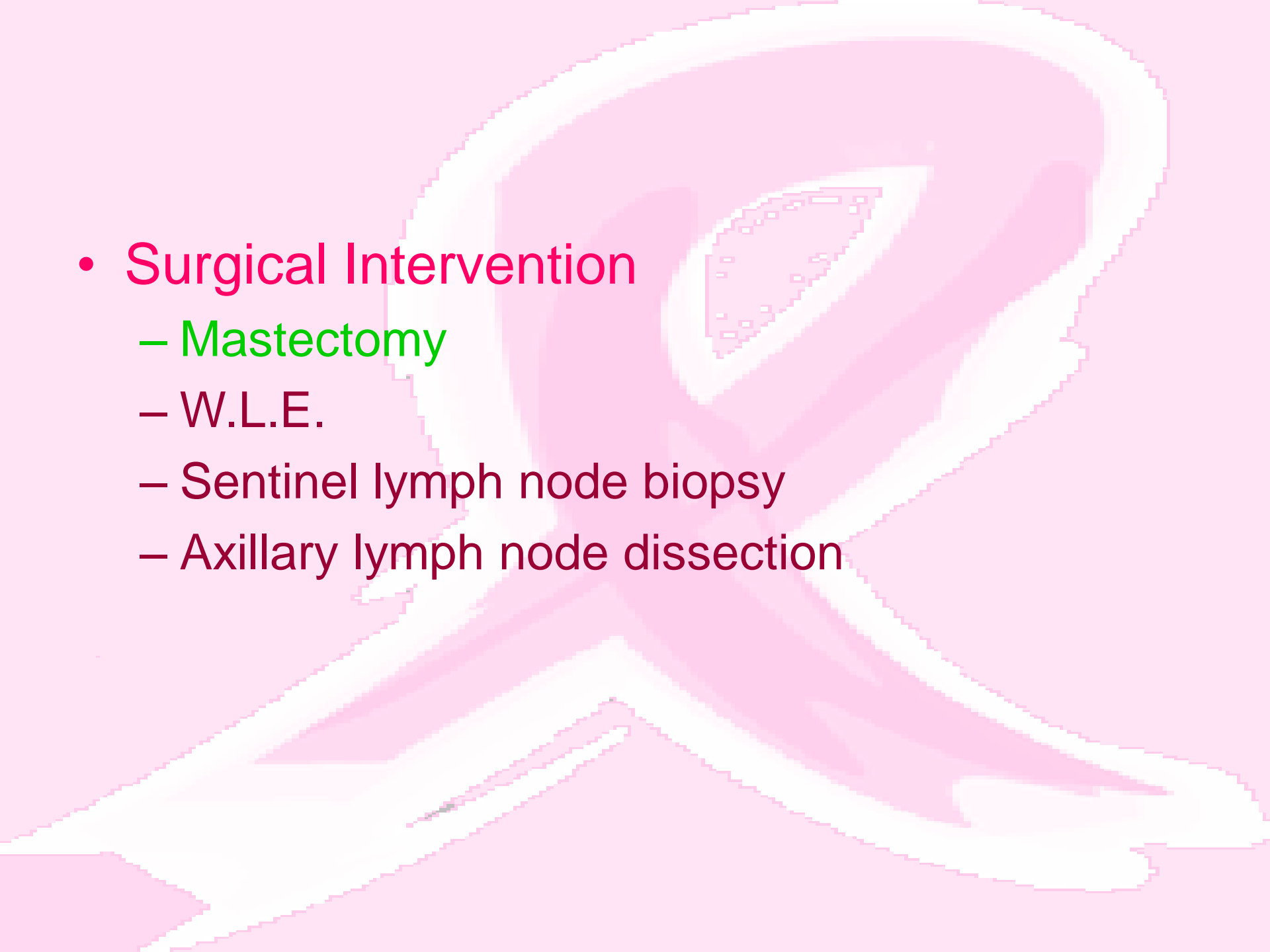
- Accounting for about two percent of all breast cancers, tubular carcinomas are a special type of invasive breast carcinoma. They have a better prognosis than invasive ductal or lobular carcinomas and are often detected through breast screening.

- **Adenoid Cystic Carcinoma**

- This type of cancer rarely develops in the breast; it is more usually found in the salivary glands. Adenoid cystic carcinomas of the breast have a better prognosis than invasive lobular or ductal carcinoma.



Lines of Treatment

- 
- Surgical Intervention
 - Mastectomy
 - W.L.E.
 - Sentinel lymph node biopsy
 - Axillary lymph node dissection

Chemotherapy

Chemotherapy for breast cancer is usually given in cycles every three or four weeks.

The common schedules include:

- CMF (Cyclophosphamide, Methotrexate and 5-Fluorouracil)
- AC (Adriamycin, Cyclophosphamide)
- Taxol or Taxotere

Chemotherapy side-effects



- Fatigue
- Anorexia
- Nausea and vomiting
- Hair loss
- Effects on the blood.
- Mouth problems
- Skin problems
- Fertility
- Bowel problems

Radiotherapy

- **What are the side-effects?**

- **Common reactions**

- **During the course of treatment**

- *skin reddening and irritation*
- *Fatigue*
- *loss of hair*
- *sore throat*

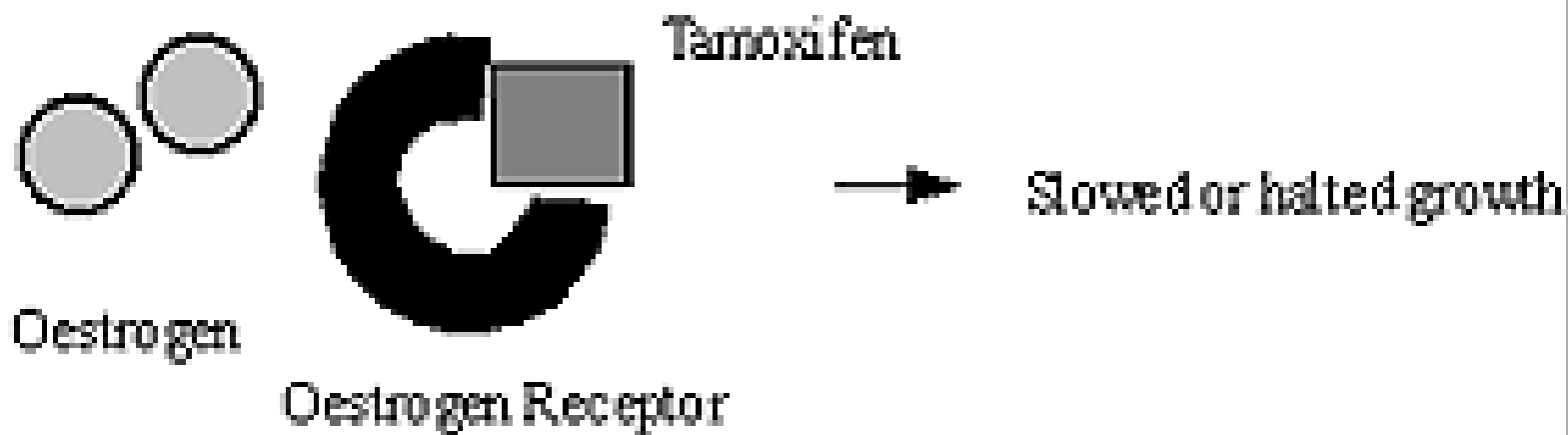
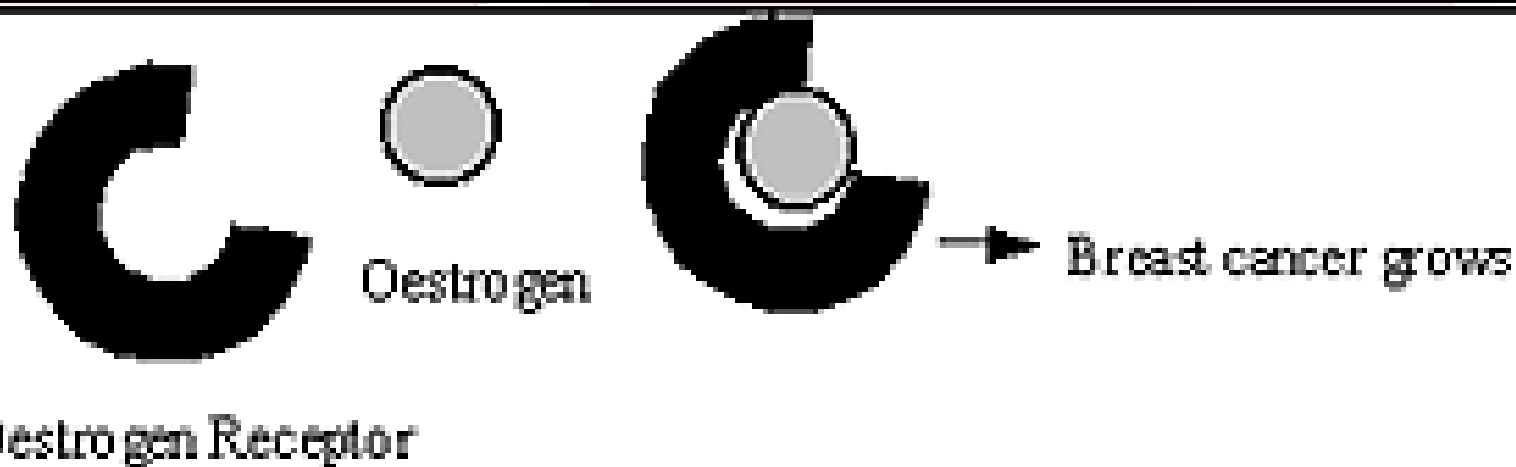
- **AFTER the course of treatment**

- *discomfort and sensitivity in the treated area.*
- *increased firmness -*
- *swelling of the treated breast -*

Tamoxifen

What is Tamoxifen ?

- Tamoxifen is a drug that has been used for the treatment of breast cancer. It can increase survival for some women with breast cancer and significantly reduce their risk of developing cancer in the opposite breast. Tamoxifen is sometimes used for patients whose breast cancer recurs.
- It is also being tested to see if it can prevent the development of breast cancer in unaffected women who are at an increased risk because of a strong family history of the disease.



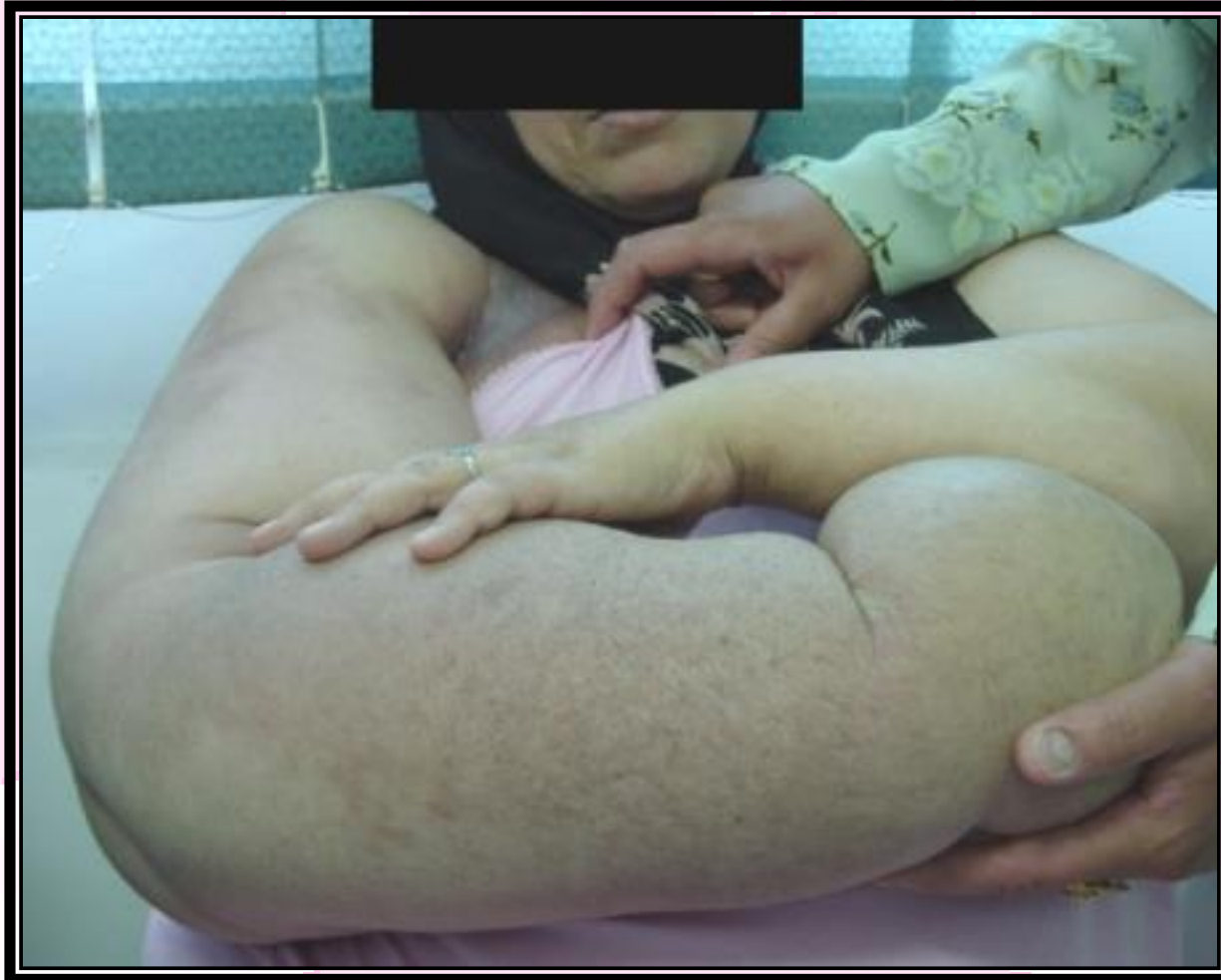How long is the treatment?

- Currently the recommended length of Tamoxifen therapy is five to 10 years.

What are the side effects?

- **Common side-effects**
 - Hot flushes or sweats
 - Irregular menstrual periods (in women who have not gone through the menopause)
 - Vaginal irritation, including vaginal dryness or discharge
 - Fluid retention and weight gain
- **Uncommon side-effects**
 - Light-headedness, dizziness, headache or tiredness
 - Rash
 - Nausea

Lymphoedema



Lymphoedema

What is Lymphoedema ?

- Lymphoedema is long-term swelling of the arm after axillary surgery or radiotherapy to the axilla.
- Symptoms include a general heaviness of the arm, a swelling of the fingers or sometimes difficulty putting on a long sleeve.
- The earlier treatment is started the easier it is to achieve good results.
- Less than 1 in 10 women who have had either lymph glands removed or radiation to the armpit will develop noticeable lymphoedema. This risk increases to 1 in 3 if the pt. had both of these treatments.

When can Lymphoedema happen??

- Lymphoedema can occur any time after the operation, even up to ten years.



Post Operative Breast Reconstructions

What is breast reconstruction?

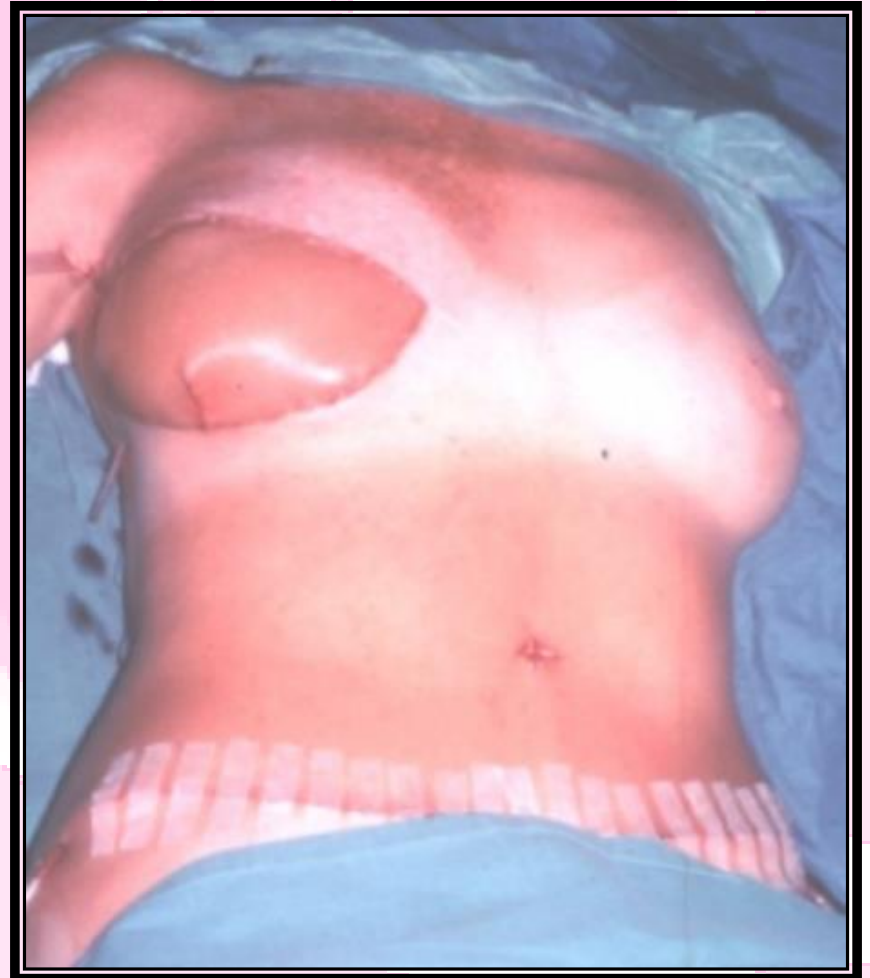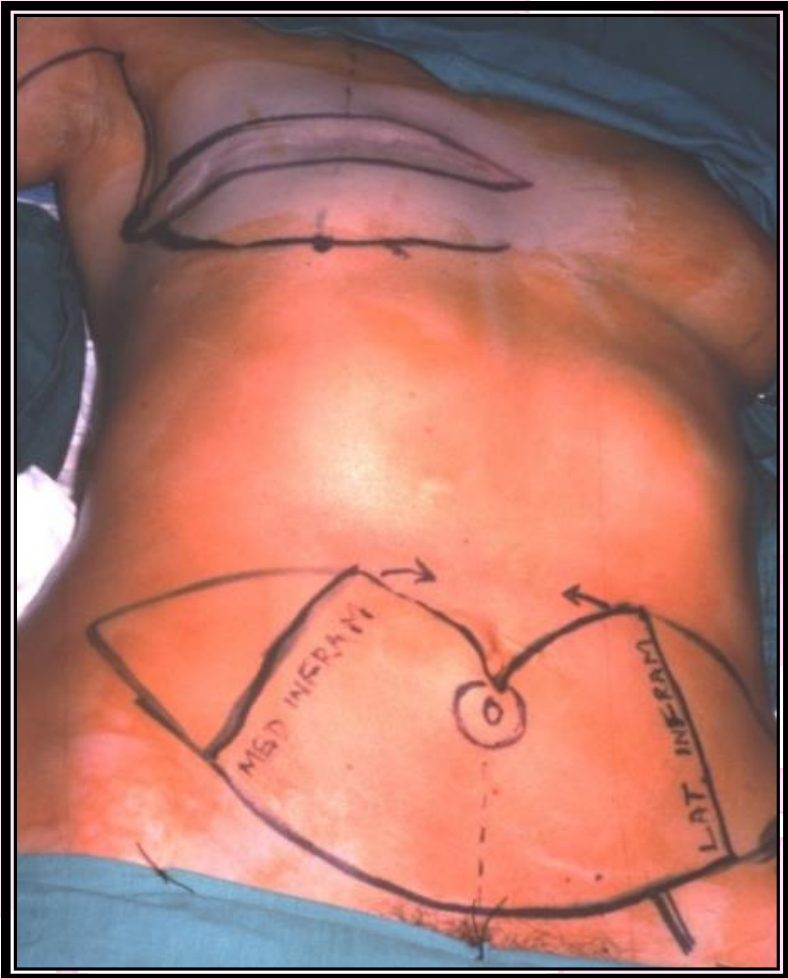
- The aim of breast reconstruction is to rebuild the breast shape and, if desired, the nipple and the surrounding darker skin (areola).

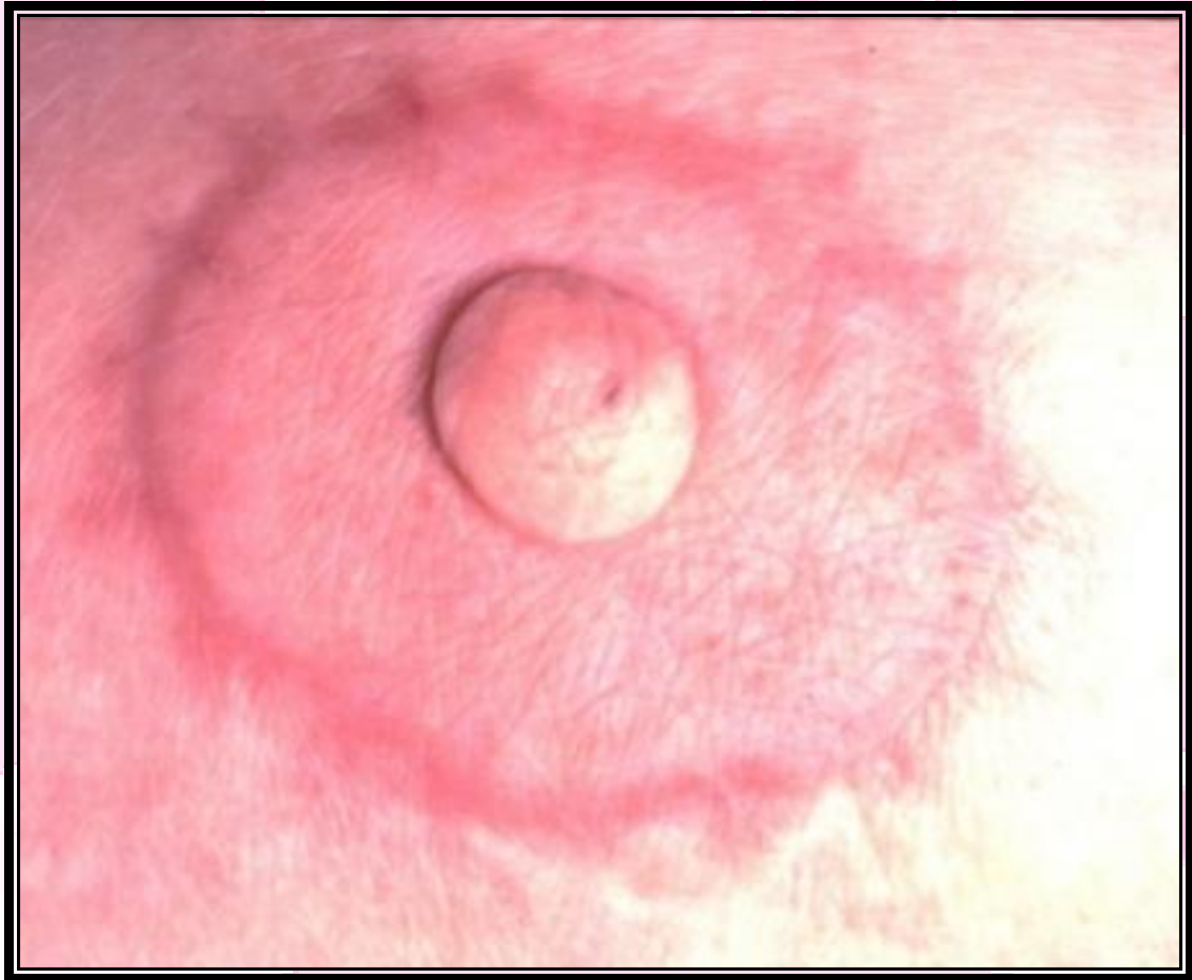What are the benefits?

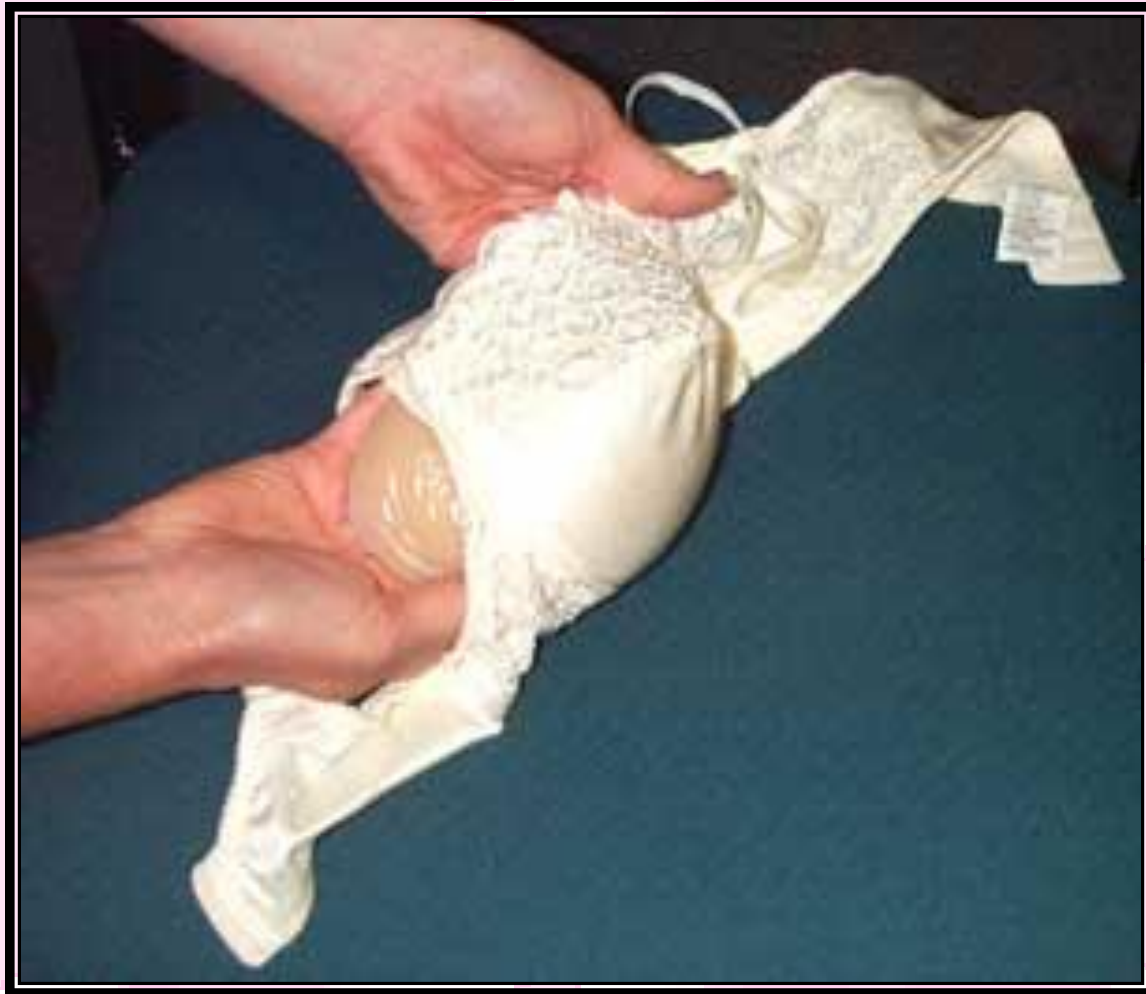- Reconstruction usually does not restrict any later treatments that may be necessary, nor does it usually interfere with radiotherapy, chemotherapy or hormone therapy.
- The patient will not need to wear an external prosthesis.
- Follow-up after the operation is no more difficult and any recurrence of cancer in the area can still be detected.
- Some women feel more self-confident and feminine when they have a permanent prosthesis or reconstruction.

What are the choices?

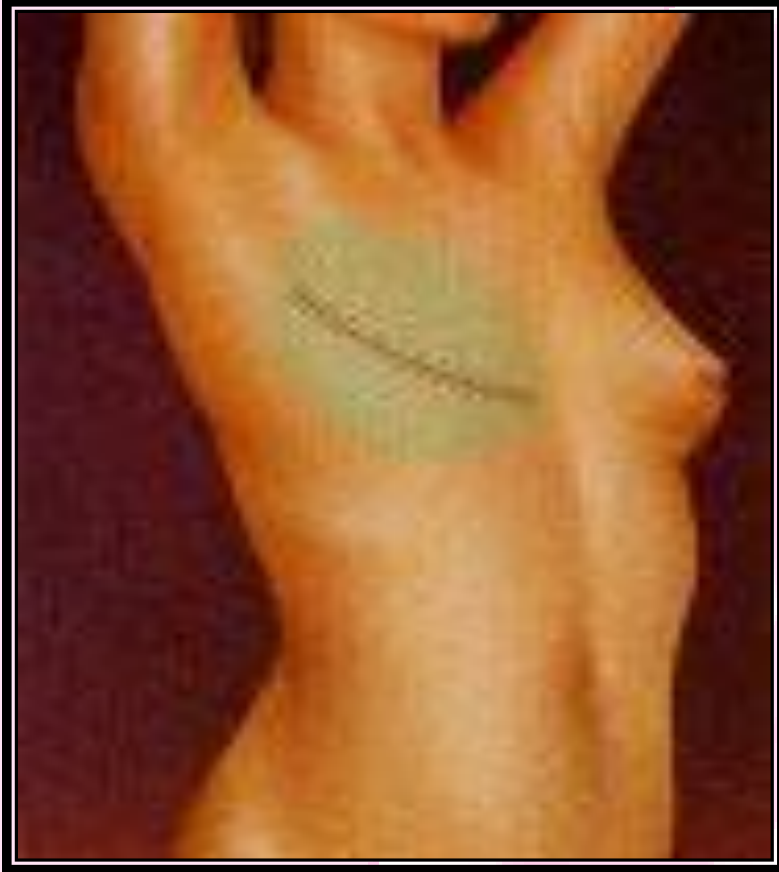- There are two main types of breast reconstruction:
 - tissue or skin expander with breast implants
 - flap reconstruction



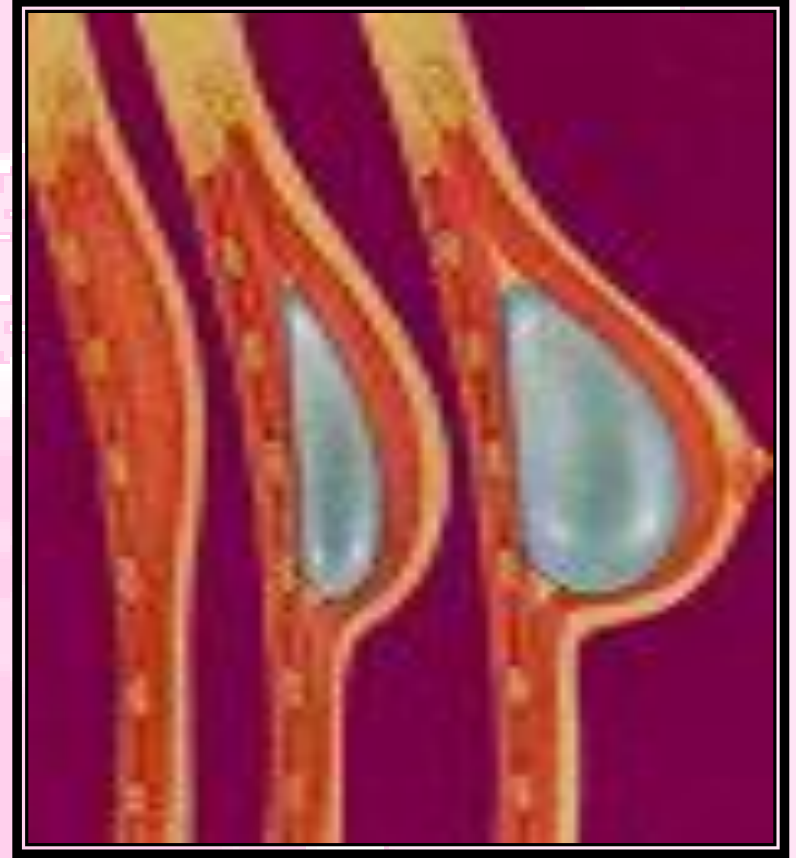



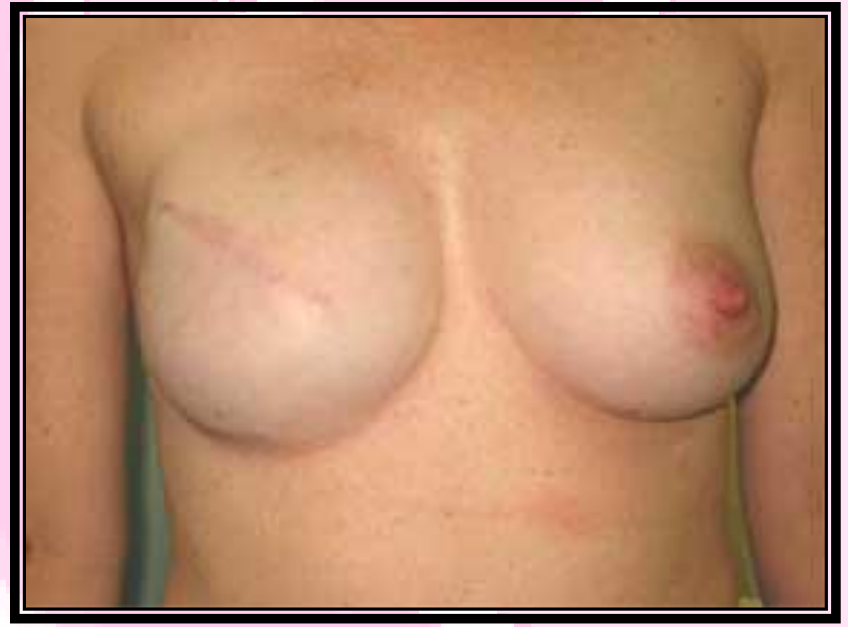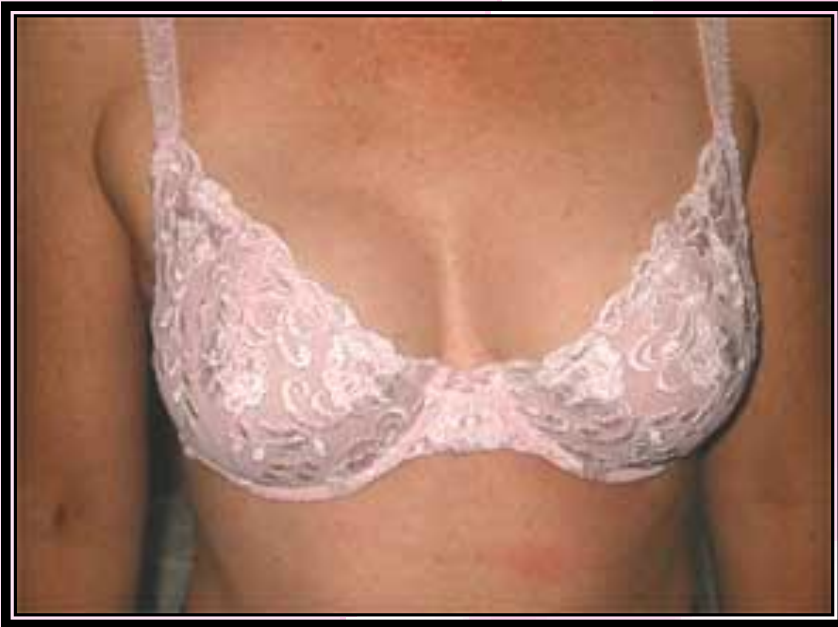External breast prosthesis - specially designed padding available in different sizes, shapes and colours



A tissue expander is inserted after the mastectomy to prepare for reconstruction



The expander is gradually filled with saline to stretch the skin enough to accept an implant beneath the chest muscle



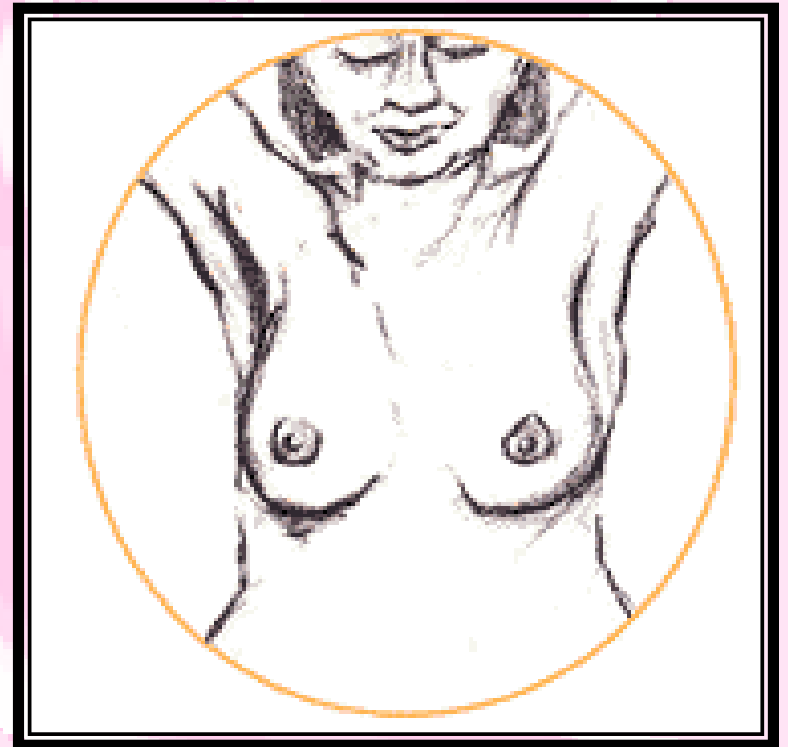
A patient with a tissue expander following a mastectomy.

When and why **BSE** should be done ???

- Once a month, preferably just after a period.
If the women has no longer have a period, she may choose a day that she will remember each month.
- To be most effective, BSE should be done regularly and carefully

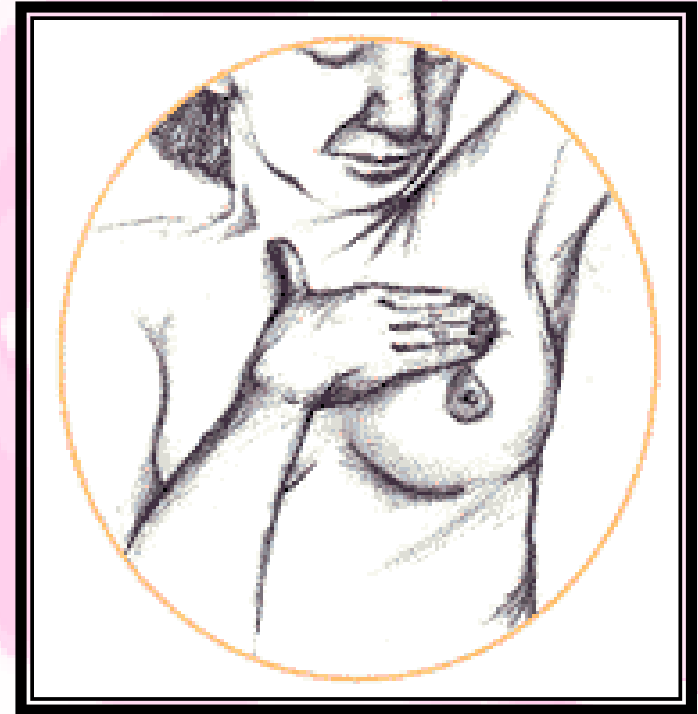
Step 1 - Look at your breasts *Cont.*

- changes in the size and shape of your breast
- any dimpling, puckering or skin changes
- anything different about your nipples



Step 2 - Feel your breasts

- You may find it easy to examine your breasts in the shower. You may also like to check your breasts lying down with a pillow under your shoulder. In either position raise your arm above your head. Use the flat part of your fingers to feel each part of your breast. Move the skin over the underlying tissue in a gentle rotating movement

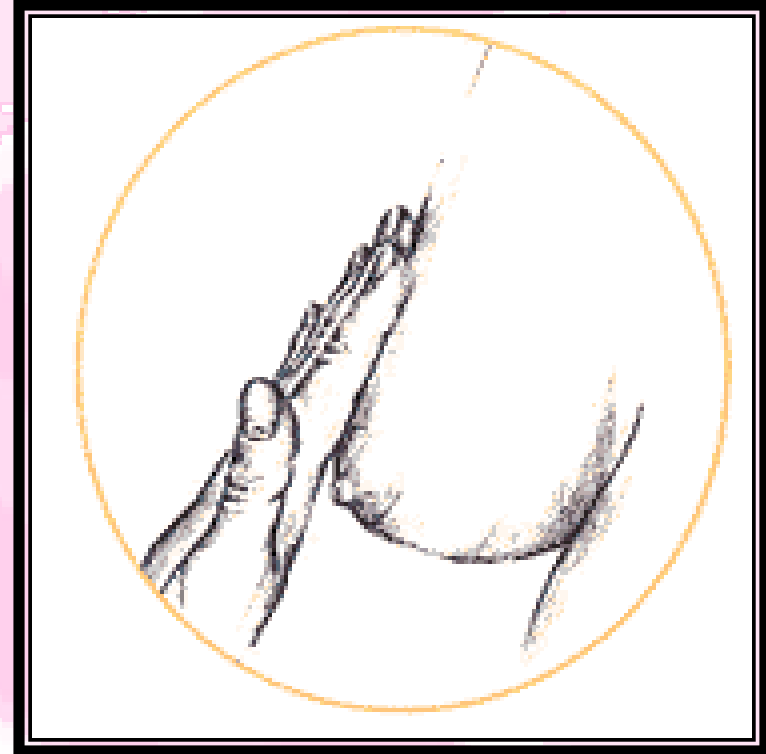


Step 2 - Feel your breasts *Cnot.*

- Cover the entire breast area in a circular movement, finishing at your nipple
- Check from the collar bone
- Check into your armpit
- Check both breasts

Look for:

- Lumps (even if painless)
- Discharge
- Thickening
- Any other changes





THANK YOU