

# Peripheral neuropathies

## Objectives :

- Obtain informative history from a patient with peripheral neuropathy.
- Use clinical information to recognize different patterns of peripheral neuropathy
- Provide differential diagnosis for each pattern

## Done by :

Team leader: Salem Al-Ammari

Team members: - Saleh Mahjoub.

- Mohammed Alasqah

- Alfahdah Alsaleem

-Haifaa Taleb

## Revised by :

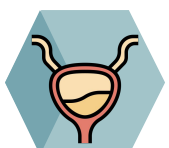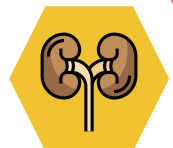
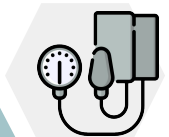
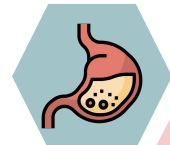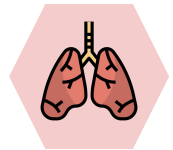
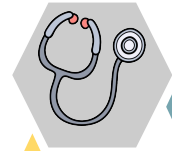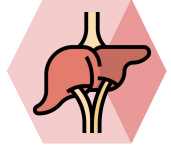
Yazeed Al-Dossare

## Resources :

Doctor's slides + Team 436

Lecturer: Dr. Mohammed Alanazy

Same as 436 slides: Yes



# Obtain informative history

## History:

### Symptoms

- Tingling, burning, stabbing, throbbing, prickling, dead, icy, hot, clumsy, wooden, walking on sponges or cotton.
- Weakness, cramps, twitches (fasciculations)
- Distal leg – Tripping, stepping over curbs, uneven ground
- Proximal
  - Standing from sitting, walking up or down stairs
  - Shaving, combing hair, brushing teeth
- Upper extremity predominant
  - Turning keys, opening jars, doing up buttons
  - Autonomic: anhidrosis, excessive sweating, orthostatic light-headedness, impotence, dry mouth, early satiety, blurred vision in bright light

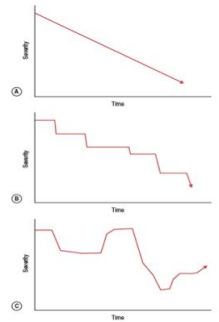
### Onset

- <4 weeks, 4-8 weeks, >8 weeks
- Were you a reasonable athlete as a child? Did you finish last in foot races? Were you able to skate or play soccer?

### Duration

### Progression

- Chronic progression
- Acute deterioration to nadir then stability or improvement



## Past history and comorbidities:

- Diabetes (glucose intolerance)
- Thyroid disease
- Renal failure / hepatic failure
- Malignancies
- Connective tissue disease
  - SLE
  - Rheumatoid arthritis
- Previous cervical or lumbar disc disease
- Previous entrapment neuropathies
  - Multiple entrapments (consider HNPP, amyloidosis)
- Orthopedic procedures on feet and ankles
- Bariatric surgery

## Family history:

- Detailed family history
  - Walking difficulty, use of cane or wheelchair
  - Postural or foot deformities
- Probe history of disabled or possibly affected individuals
- Do not necessarily accept what diagnoses other individuals have

# Obtain informative history

## Social history:

- Exposure to alcohol
- Occupation
- Tobacco
- Recreational drugs
- Vitamin and herb use

Occupation	Neuropathy
Dentists	Nitrous oxide
Painters, glue sniffers	Hexacarbons
Farmers	Organophosphates
Welders	Lead
Jewelers	Arsenic
Plastic industry	Acrylamide

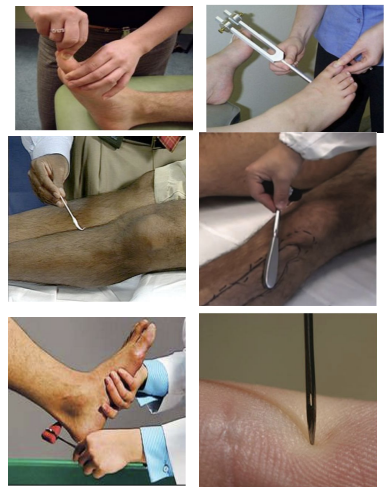## Review of systems:

- Joint pain, stiffness and swelling
- Fever
- Skin rash
- Other systems

## Neurological Examination:

- Confirm localization (LMN vs UMN, myopathy vs neuropathy)
- Recognize pattern of neuropathy
  - Motor vs sensory vs sensory motor
  - Proximal vs distal
  - Symmetric vs asymmetric
- Recognize features of hereditary neuropathy
- Recognize features that narrows the differential diagnosis.
  - Purpura and levido reticularis
- Autonomic features
  - BP & HR supine and standing
  - Pupillary reaction to light and accommodation
- Other
  - Skin: trophic changes (such as thin, shiny, and discolored skin)
  - ulcerations or amputations.
  - peripheral pulses.

Neuro exam...

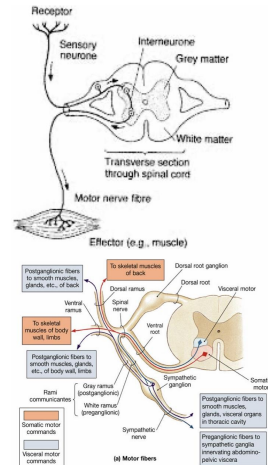


# Approach

1. Recognition of a clinical pattern.
2. There are 6 key questions the clinician should consider in arriving at the pattern that fits the patient best.
3. Most neuropathy and neuronopathy patients can be placed into one of 10 patterns.

## Approach - 6 questions:

1. What systems are involved?
2. What is the distribution of weakness?
3. What is the nature of the sensory involvement?
4. Is there evidence of UMN involvement?
5. What is the temporal evolution?
6. Is there evidence for a hereditary neuropathy?



## 1- What systems are involved ?

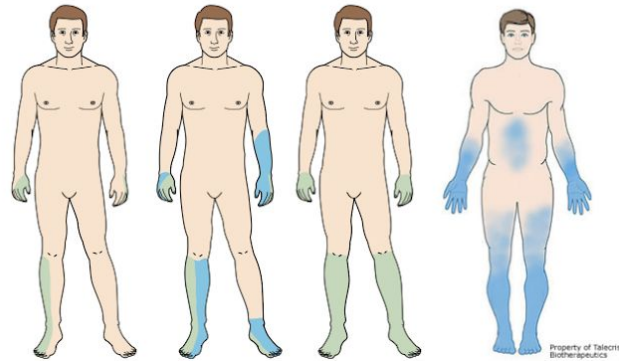
- a. Motor: localized to AHC, motor nerve roots, motor nerves.
- b. Sensory: DRG, sensory nerve roots, small nerves. Could be central
- c. Autonomic: autonomic nerves, gray/white communicants
- d. or combinations

## 2- What is the distribution of weakn

- a. Only distal versus proximal and distal
- b. Focal/asymmetric versus symmetric

### Asymmetric/focal weakness

- Motor neuron disease
- Radiculopathy
- Plexopathy
- Mononeuropathy or multiple mononeuropathies
- Compressive/entrapment mononeuropathies



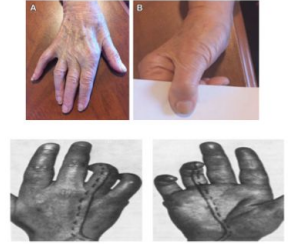### Symmetric weakness

- Represents a huge variety of DDx
- Symmetric proximal and distal weakness in a patient who presents with both motor and sensory symptoms à CIDP and GBS.
- Symmetric sensory and motor findings involving only the distal lower and upper extremities à the disorder generally reflects a primarily axonal peripheral neuropathy and is much less likely to represent a treatable entity.



# What is the pattern?

A 65-year-old woman presented with a 3- month history of right-hand numbness, grip weakness, and vague elbow pain. Examination demonstrated diminished sensation of the medial hand and fourth and fifth digits, and weakness of finger abduction and adduction, associated with intrinsic hand muscle atrophy. Froment and Wartenberg signs were evident



	Weakness				Sensory Symptoms	Severe Proprioceptive Loss	UMN Signs	Autonomic Symptoms/ Signs	Diagnosis
	Proximal	Distal	Asymmetric	Symmetric					
Pattern 3: distal weakness with sensory loss		+	+		+				Multiple: vasculitis, HNPP, MADSAM, infection Single: mononeuropathy, radiculopathy

1. **What are the systems involved?** (motor, sensory or both) Sensory and motor
2. **Where is the disruption of the weakness?** (proximal, distal or both. Symmetrical or asymmetrical) Asymmetrical distal.
3. **What is nature of sensory involvement?** Numbness, grip weakness, and vague elbow pain.
4. **Is there evidence of upper motor neuron involvement?** No, Lower motor neuron only.
5. **Onset (acute, subacute, chronic)** 3 months = chronic
6. **Is there any history of hereditary neuropathy?** No.

So we have Asymmetrical distal weakness with Sensory loss. What is the pattern? Pattern 3.

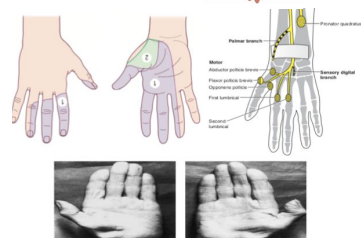
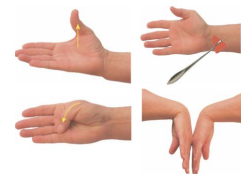
DIAGNOSIS: Mononeuropathy (ulnar involvement)

What is Ddx of pattern 3?

- Vasculitis like (Mononeuritis multiplex) which is infarction to the nerve “nerve stroke “ severe and sudden
- Mononeuropathy : focal neuropathy due to compressive lesion and the most common is carpal tunnel syndrome “compression of median nerve” + ulnar nerve compression in the elbow which causes claw hand + common peroneal neuropathy which causes foot drop .

A 67-year-old woman was referred for clumsiness, tingling, and pain in both hands of several months’ duration. Symptoms were most prominent at night, often awakening her from sleep, or during hand use such as driving. Examination showed slight wasting of both thenar eminences. Reflexes were normal. Thumb abduction was weak bilaterally. Sensation was slightly reduced over the finger pads of the thumb, index, middle, and ring fingers. There was no Tinel’s sign at the wrist on either side. A Phalen’s maneuver elicited tingling in the middle finger bilaterally after 30 seconds.

	Weakness				Sensory Symptoms	Severe Proprioceptive Loss	UMN Signs	Autonomic Symptoms/ Signs	Diagnosis
	Proximal	Distal	Asymmetric	Symmetric					
Pattern 3: distal weakness with sensory loss		+	+		+				Multiple: vasculitis, HNPP, MADSAM, infection Single: mononeuropathy, radiculopathy



Severe wasting of abductor pollicis Brevis which supplied by median nerve

Diagnosis: carpal tunnel syndrome. The most common neuropathy usually affect the dominant hand and it could be symmetrical or asymmetrical.



A 25-year-old man with NO family history of neuropathy had been weak early childhood. He remembers he was unable to keep up with his peers when running. He is currently only able to walk if wearing ankle-foot orthosis.

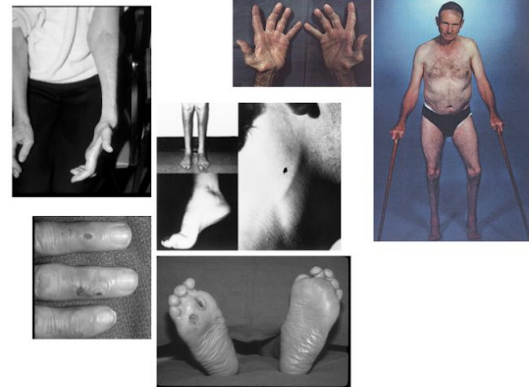He denied sensory symptoms.

- Neurological examination showed symmetric severe weakness in distal leg muscles with power of 1-2/5 with

bilateral drop feet. Proximal leg muscles were 4/5 as well as intrinsic hand muscles. Proximal upper limb muscles were normal.

- Reflexes were absent.
- Vibration and proprioception sensation were absent over the toes bilaterally and Pinprick and temperature were decreased to the knees and wrists

	Weakness				Sensory Symptoms	Severe Proprioceptive Loss	UMN Signs	Autonomic Symptoms/ Signs	Diagnosis
	Proximal	Distal	Asymmetric	Symmetric					
Pattern 2: distal sensory loss with/ without weakness		+		+	+				CSPN, metabolic, drugs, hereditary



1. **What are the systems involved?** (motor, sensory or both) Sensory and motor.
2. **Where is the disruption of the weakness?** (proximal, distal or both. Symmetrical or asymmetrical) Symmetrical distal.
3. **What is nature of sensory involvement?** Vibration and proprioception were absent + pain and temp were decreased .
4. **Is there evidence of upper motor neuron involvement?** No.
5. **Onset (acute, subacute, chronic)** Not mentioned by doctor or in the history.
6. **Is there any history of hereditary neuropathy?** Yes .

What is DDX of pattern 2?

- CSPN(cryptogenic neuropathy>no apparent reason) , which is most common
- Metabolic : diabetes , thyroid .
- The DIAGNOSIS: Hereditary .

# What is the pattern?

A 42-year-old man developed numbness and tingling in the toes, progressing up to the ankles over 2 years. He describes burning pain in his feet, mainly at night. He recently started noticing symptoms of numbness and tingling in distal fingers. He denies any weakness.

- Examination showed normal strength, with decreased pinprick and light touch sensations to the ankles and distal fingers.
- Vibration was absent at the toes and decreased at the ankles, and proprioception is normal at the toes.
- Reflexes are normal in the arms and at the knees but ankle reflexes are absent. Gait is normal

	Weakness				Sensory Symptoms	Severe Proprioceptive Loss	UMN Signs	Autonomic Symptoms/ Signs	Diagnosis
	Proximal	Distal	Asymmetric	Symmetric					
Pattern 2: distal sensory loss with/ without weakness		+		+	+				CSPN, metabolic, drugs, hereditary

1. **What are the systems involved?** (motor, sensory or both)  
Sensory, no weakness
2. **Where is the disruption of the weakness?** (proximal, distal or both. Symmetrical or asymmetrical) Symmetrical distal.
3. **What is nature of sensory involvement?** numbness and tingling in the toes and burning pain in his feet.
4. **Is there evidence of upper motor neuron involvement?** No.
5. **Onset (acute, subacute, chronic)** 2 years = chronic , progressive . they can't tell when it exactly started.
6. **Is there any history of hereditary neuropathy?** No

So we have symmetrical distal sensory loss. What is the pattern?

Pattern 2.

What are the DDx of pattern 2? predominantly sensory polyneuropathy

THE DIAGNOSIS : DM

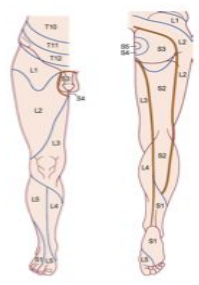
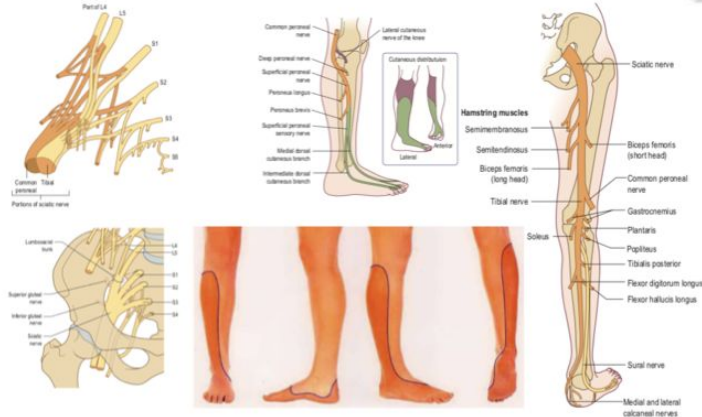



# What is the pattern?

A 36-year-old man. Eight weeks ago, he had bent down to lift a chair and developed acute pain in the right back and buttock with radiating paresthesias into the calf and lateral foot.

- Neurologic examination:
  - normal muscle bulk and tone in the lower extremities.
  - Straight-leg raising elicited pain and paresthesias in to the right leg at 45 degrees.
  - Power: weakness in right **hip extension, knee flexion, and ankle plantar flexion**
  - Sensory examination: mild sensory loss on the right sole and lateral foot.
  - DTR: right ankle reflex was absent, other DTRs were normal

	Weakness				Sensory Symptoms	Severe Proprioceptive Loss	Autonomic Symptoms/Signs	Diagnosis
	Proximal	Distal	Asymmetric	Symmetric				
Pattern 4: asymmetric proximal and distal weakness with sensory loss	+	+	+		+			Polyradiculopathy, plexopathy

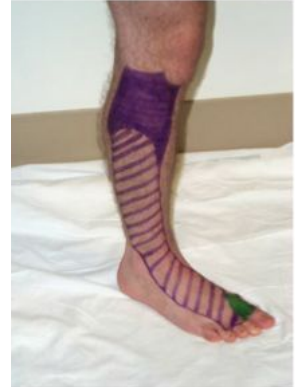

1. **What are the systems involved? (motor, sensory or both)** Sensory + motor
2. **Where is the distribution of the weakness?** (proximal, distal or both. Symmetrical or asymmetrical) Asymmetrical proximal and distal
3. **What is nature of sensory involvement?** Pain
4. **Is there evidence of upper motor neuron involvement?** No.
5. **Onset (acute, subacute, chronic)** 8 weeks = subacute
6. **Is there any history of hereditary neuropathy?** No

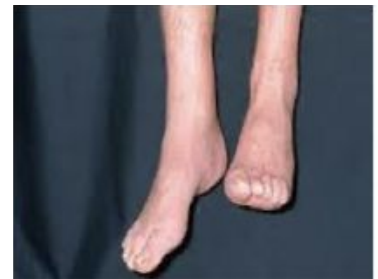So we have asymmetrical distal and proximal sensory loss. What is the pattern? Pattern 4. THE DIAGNOSIS IS : S1 RADICULOPATHY , BECAUSE THE SYMPTOMS FOLLOW THE DERMATOMES + MYOTOMES OF S1

# What is the pattern?

A 56-year-old man was referred for a persistent foot drop 3 weeks after coronary artery bypass surgery. Shortly after awakening from anesthesia, the patient noted difficulty dorsiflexing his right foot and toes. In addition, there was a pins-and-needles sensation over the dorsum of the right foot. He noted that when he was walking, his right foot would slap with each step. There was no pain, and the left leg was unaffected.



- On examination
  - muscle bulk and tone were normal and symmetric in both legs. There was marked weakness of right ankle and toe dorsiflexion (1/5) as well as ankle eversion (2/5). Foot inversion, ankle and toe plantar flexion, knee flexion, and all movements around the hip were normal.
  - Deep tendon reflexes were intact and symmetric.
- Sensory examination
  - well-demarcated loss of sensation to pinprick and temperature over the dorsum of the right foot extending into the lateral calf.
  - Sensation over the right lateral knee was normal, as was sensation over the lateral foot, sole of the foot, and medial calf.



	Weakness				Sensory Symptoms	Severe Proprioceptive Loss	LMN Signs	Autonomic Symptoms/Signs	Diagnosis
	Proximal	Distal	Asymmetric	Symmetric					
Pattern 3: distal weakness with sensory loss		+	+		+				Multiple: vasculitis, HNPP, MADSAM, infection Single: mononeuropathy, radiculopathy

1. **What are the systems involved?** (motor, sensory or both)? Both
2. **Where is the disruption of the weakness?** (proximal, distal or both. Symmetrical or asymmetrical) asymmetrical distal.

What is the nerve involve? Common peroneal nerve. Because the inversion and abduction are preserved

- How to differentiate between L5 and common peroneal nerve?

Tibialis anterior muscle weakness = foot drop. Supplied by common peroneal nerve and L5

Hip abduction and foot inversion is supplied by L5

A 25 year-old woman developed numbness and tingling of the feet and hands followed by progressive leg more than arm muscle weakness over the last week. She experienced a diarrheal illness 3 weeks ago that had resolved within 10 days.

- Examination showed marked bifacial weakness and absent muscle stretch reflexes. She had normal pinprick, light touch and proprioception but vibration was reduced at the toes.
- Muscle power in the lower limbs was 2/5 and in the upper limbs 3/5, with equal proximal and distal weakness. She could not stand up or walk with assistance.

	Weakness				Sensory Symptoms	Severe Proprioceptive Loss	UMN Signs	Autonomic Symptoms/Signs	Diagnosis
	Proximal	Distal	Asymmetric	Symmetric					
Pattern 1: symmetric proximal and distal weakness with sensory loss	+	+		+	+				GBS/CIDP

1. **What are the systems involved? (motor, sensory or both)**  
Sensory + motor.
2. **Where is the disruption of the weakness? (proximal, distal or both. Symmetrical or asymmetrical)** Symmetrical proximal and distal.
3. **What is natural of sensory involvement?** numbness and tingling of the feet and hands
4. **Is there evidence of upper motor neuron involvement?** No.
5. **Onset (acute, subacute, chronic)** 1 week = acute
6. **Is there any history of hereditary neuropathy?** No


So we have symmetrical proximal and distal sensory loss. What is the pattern? Pattern 1.

What is DDx of pattern 1?

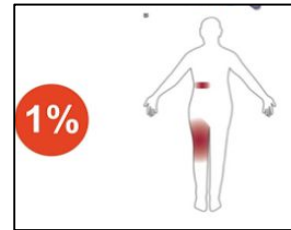
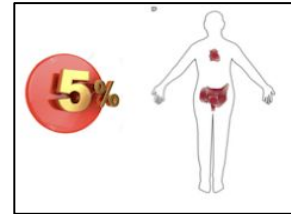
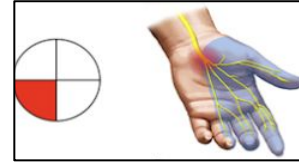
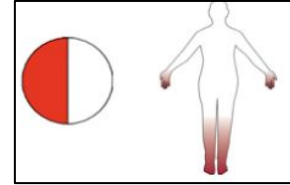
- THE DIAGNOSIS GBS , peaks at week 4 . WHENEVER ITS ACUTE CONSIDER GBS IN YOUR DDX.

# Diabetic neuropathy:

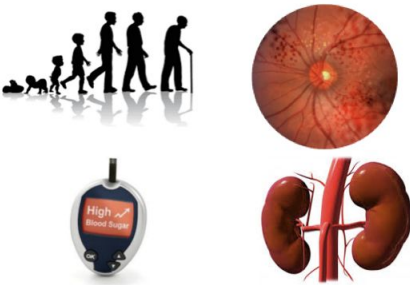
## Classification

 66% of patients with DM had subclinical or clinical evidence of a peripheral neuropathy

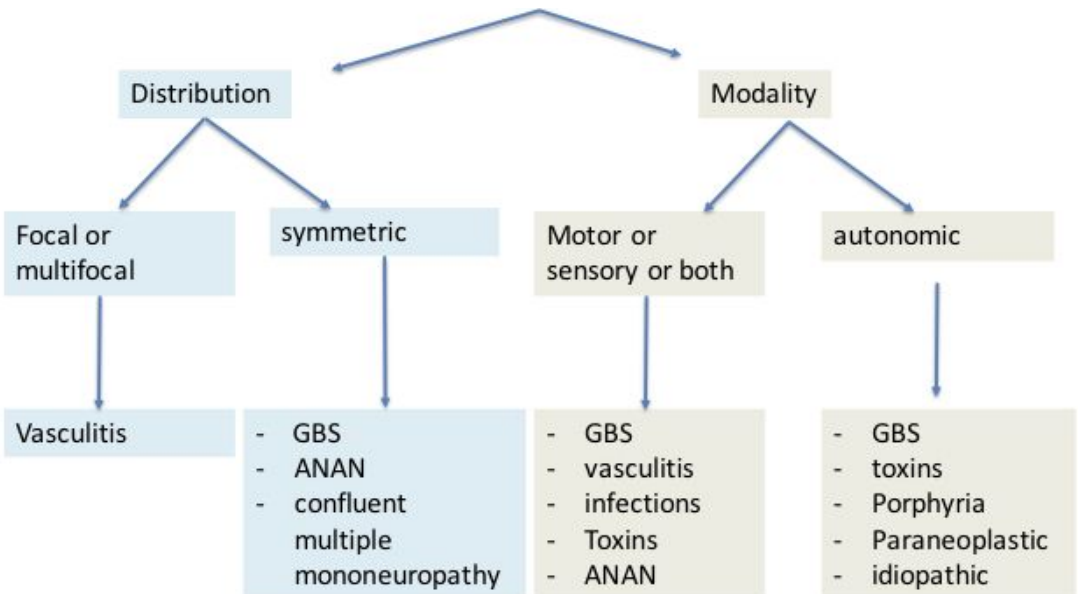
- **Symmetric:**
  - Distal symmetric polyneuropathy (DSPN)
  - Small fiber neuropathy
  - Acute severe distal sensory polyneuropathy
  - Autonomic neuropathy
  - Diabetic neuropathic cachexia
  - Hypoglycemic neuropathy
  - Treatment-induced diabetic neuropathy
- **Asymmetric/focal and multifocal:**
  - Diabetic radiculoplexopathy (amyotrophy)
  - Truncal neuropathies (thoracic radiculopathy)
  - Cranial neuropathies
  - Mononeuropathies



## The occurrence of neuropathy correlates with:



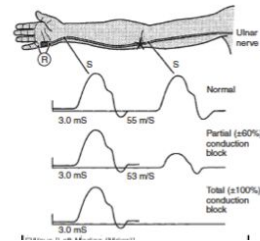
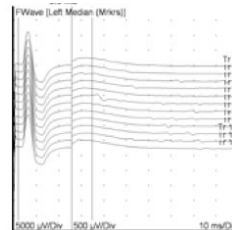
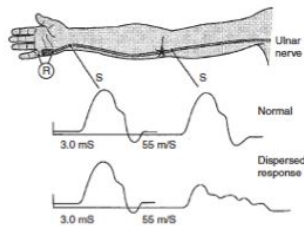
## Acute neuropathy



# Acute neuropathy Cont.

## Investigations:

- CBC = normal,
- vitamin B12 level = normal
- Serum glucose and A1c – normal
- SPEP – normal
- CK = normal, TSH = normal, lactate = normal
- Forced vital capacity was 2.0 liters.
- Cerebrospinal fluid evaluation showed no white cells but protein was 82 mg/dl.
- Nerve conduction studies showed 50% delay in tibial and median F wave latencies. Sensory conductions showed normal sural and absent median potentials.
- Motor NCS
  - Conduction block
  - Temporal dispersion
  - Slowed conduction velocity
  - Prolonged DML
  - Absent F wave.
- Sensory NCS
  - normal sural SNAPs
  - Absent median and ulnar SNAPs.



## Treatment

- IVIG or Plasmapheresis
- Supportive therapy
- Monitor progression and prevent and manage potentially fatal complications, especially:
  - Regularly monitor pulmonary
  - Regularly check for autonomic dysfunction
  - Check for swallowing dysfunction
  - Recognize and treat pain
  - Prevent and treat infections and pulmonary embolism
  - Prevent cornea ulceration due to facial weakness
  - Prevent decubitus and contractures

# Summary

	Sym	Asym	Proximal	Distal	Sens	UML	DDx	
1	Sym		Prox	Dist	Sen		GBS: Acute CIDP: Chronic	
2	Sym			Dist	Sen		CSPN: no known cause (most common) Metabolic: DM,Thyroid Drugs Hereditary: physical Exam ≠ History	
3		Asym		Dist	Sen		Vasculitis: "nerve stroke" severe, tender, and sudden HNP, MADSAM: Hereditary Mononeuropathy: Carpal tunnel syndrome Radiculopathy	
4		Asym	Prox	Dist	Sen		Polyradiculopathy, Plexopathy	
5		Asym		Dist		+/-	UML+LML - Amyotrophic lateral sclerosis Pure UML - Primary lateral sclerosis Pure LML - MMN,PMA,BAD,LAD,MAMA	
6	Sym			Dist	Sen + Proprioception loss	UML	B12 deficiency: subacute combined degenerative disease Copper deficiency Friedreich ataxia: autosomal recessive, worsen overtime adrenomyeloneuropathy	
7	Sym		+/-	Dist	Sen		proximal and distal SMAA, Distal hereditary	
8	Sym		-Neck -Exten -Bulbar			UML	Amyotrophic lateral sclerosis	
9	Asymmetric proprioception loss							Sensory Neuropathy (Ganglionopathy)
10	Autonomic Dysfunction							HSAN,DM,Amyloid,Prophyra,Fbary

# Questions

**1- A 55-year old female presented with ascending weakness and sensory loss that started 2 weeks ago after having upper respiratory tract infection. Her neurological examination showed weakness in upper and lower limbs that was symmetric and graded as 3/5. Reflexes were diminished. She had sensory loss to pinprick, vibration and joint position in both upper and lower limbs. Which ONE of the following localizations is consistent with this pattern?**

- A) Anterior horn cell
- B) Diffuse peripheral nerves and nerve roots
- C) Dorsal root ganglia
- D) Neuromuscular junction

**2- What is the most common cause for peripheral neuropathy?**

- A) DM.
- B) GBS.
- C) CMT.
- D) ALS.

**3- A 18 years old male presented with weakness and numbness for 5 years. On examination he had high arched feet. Reflexes was absent. Sensory examination showed abnormal sensation to pinprick and vibration. Muscle power was 2/5 distally, 4/5 proximally in lower limbs. And 3/5 distally, 5/5 proximally in upper limbs. Which one of the following is the most appropriate description for his neuropathy?**

- A) Diabetic Neuropathy.
- B) Inherited Neuropathy.
- C) Toxic Neuropathy.
- D) Vitamin B12 Deficiency.

**4-Patient presented with 2 months of Right leg pain. He also has back pain. On physical examination he had muscle power of 4/5 in dorsiflexion, eversion and inversion. And had 5/5 in ankle flexion, knee flexion and extension, hip flexion and extension, and hip adduction. And had 4/5 in hip abduction. He also showed sensory deficits with pinprick test but had normal vibration test. What is the most likely diagnosis?**

- A) Common peroneal injury
- B) L5 radiculopathy
- C) Femoral nerve injury
- D) Popliteal injury

Answer:

- 1- B
- 2- A
- 3- B
- 4- B