


# Emergency in Urology

 Team leaders: Alanoud Almansour, Ghaida Al Musma , Muath Alhamoud and Mohammed Alqwaifli

 Done by: Alanoud Almufarrej, Layan Alwatban, Esraa Alnazzawi, Hamdan Aldossari, and Omar Alsuhaibani

 Revised by: Aseel Badukhon

## Color Index:

● Important

● Doctor's Notes

● Extra

● Davidson's

[Editing File](#) / [Feedback](#)




# Introduction

- Compared to other surgical fields, there are **relatively few Urological Emergencies**, however, they require rapid diagnosis and immediate treatment.

<b>Non traumatic</b>	<b>Traumatic</b> (From the kidney to the external genitalia)
<b>Haematuria (very imp for OSCE)</b> The most important symptom that need immediate medical help.	<b>Renal Trauma</b>
<b>Renal Colic (very imp for OSCE)</b> Pain is the most important symptom that brings the patients to the emergency.	<b>Ureteral Injury</b>
<b>Urinary Retention</b> Inability to empty the bladder completely.	<b>Bladder Trauma</b>
<b>Acute Scrotum</b>	<b>Urethral Injury</b>
<b>Priapism</b> An involuntary, prolonged erection unrelated to sexual stimulation and unrelieved by ejaculation.	<b>External Genital Injury</b>

**This lecture is extremely important especially for OSCE, please don't skip the pictures and focus on them!**



# 1. Non traumatic Urological Emergencies

## 1. Hematuria

- What are the types of hematuria?

Gross (Macroscopic, Visible, Clinically)	Microscopic (non visible, not clinical)
1 ml of blood in 1 liter of urine <b>visible for the patients.</b>	<b>3 or more</b> RBCs/High power, in 2 out of 3 properly collected samples (AUA). Here <b>the patient is told</b> that he has Hematuria.
Emergency or urgency	Not an emergency or urgency
Susceptibility to develop a cancer is >40%	Susceptibility to develop a cancer is 1-3%

- Causes vary according to:

### 1. Patient's Age

People >40 have more susceptibility to develop painless hematuria that is caused by transitional cell carcinoma of bladder or the collecting system.

### 2. Symptomatic or Asymptomatic: Painful or painless changes your list of differentials.

<b>painful</b>	<b>Benign</b> usually. Most common differential (top of the list): Renal stones, UTI, Trauma, Renal Vein thrombosis; and the last in your list will be malignancy
<b>Painless</b>	Chronic and <b>malignant</b> usually.


### 3. The existence of **risk factors** for malignancy,

**Smoking** is the most important risk factor in the KSA especially in immunocompromised pt..

### 4. The **type**: Gross or Microscopic.

- **Causes**

<b>Prerenal</b> (Systemic)	Usually caused by hematological disorder (e.g. sickle cell anemia, hemophilia, thalassemia), developed by some medication (e.g. anticoagulants drugs) or some other diseases like liver failure, <b>SLE</b> and malaria. It can also be related to Chemotherapy
<b>Renal</b> (Kidney)	Renal calculi, renal vein thrombosis, pyelonephritis, <b>renal tumors</b> (benign or malignant), <b>renal stasis, stone, TB, glomerulonephritis</b> , renal trauma or nephritic syndrome.
<b>Postrenal</b> (Ureter, bladder, urethra and prostate)	Caused by obstruction of urinary tract downstream from the kidneys. Ex: <b>urethral stricture, BPH</b> , UTIs, <b>schistosomiasis</b> , trauma or <b>tumor</b> (bladder or ureter) e.g. transitional cell carcinoma of bladder, urethral polyp/tumor.





# A. Non traumatic Urological Emergencies

## 1. Hematuria

### ● Management

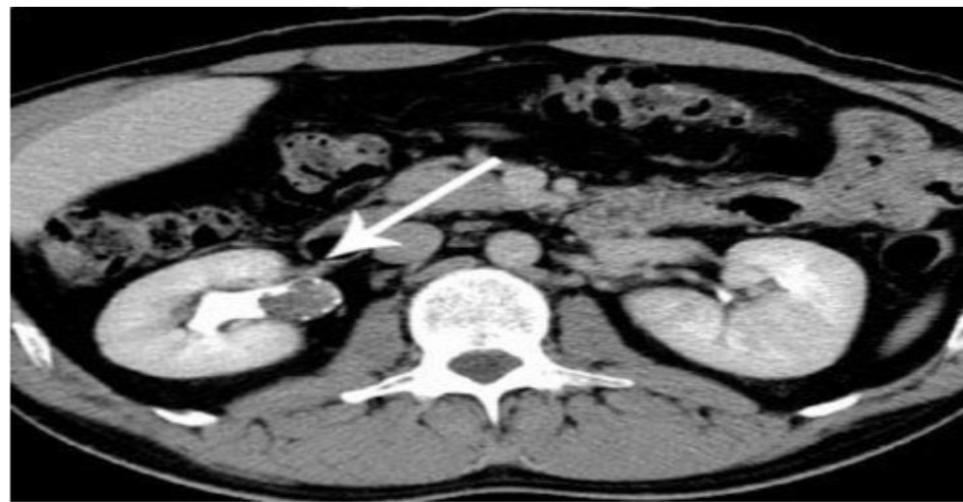★ Gross Haematuria mandates full work up:

- History. More important than P/E in this case.
- P/E (Physical Examination): usually no much signs, (Sometimes if the patient is a Sickler (sickle cell anemia) you can see signs of anemia).

### ● Investigations:

- ★ The single most important imaging method is CTU (CT Urography) & this is the gold standard method.
- ★ Insert 3 way foley urethral catheter and bladder wash out for heavy bleeding.
- ★ Treat according to the cause.

Extra



#### What is a CT Urogram used for?

Urography uses imaging and contrast material to evaluate or detect blood in urine, kidney or bladder stones, and cancer in the urinary tract. Urography with conventional x-ray is known as intravenous pyelogram (IVP). Urography is also often performed using computed tomography (CT) or magnetic resonance imaging (MRI)

### ● History of Haematuria:

<b>Age</b>	Important to consider because each age group has a specific cause of hematuria.
<b>Residency</b>	Very important question in this case. Why? Because <b>schistosomiasis</b> which is common only in some regions is one of the most common causes.
<b>Duration</b>	You should know how many days, episodes.
<b>Occupation</b>	Increased risk in those working in specific industries (e.g. people who work in paint and tire factories have a high risk of aromatic material inhalation).
<b>Pain</b> <small>painless or painful?</small>	If the patient said he has pain then you should ask which came first, the pain or the blood?. It is important to differentiate between the tumor and stone
<b>How dark is urine?</b>	Used to assess the severity.
<b>Bleeding other site Or Trauma</b>	e.g. per-rectal bleeding.
<b>Clots &amp; shape of clots</b>	- If it's <b>sausage like</b> → came from the kidney and passed through the ureter. - Assess severity and site of the pathology
<b>Timing of hematuria</b>	Help in justifying the location of the bleeding: <ul style="list-style-type: none"> <li>● <b>At the beginning of voiding</b> : (mostly due to the <b>anterior urethra</b>).</li> <li>● <b>At the end</b> : (Mostly due to the bladder neck, trigone and <b>posterior urethra</b>).</li> <li>● <b>Total and midstream</b> → at or above the level of bladder.</li> </ul>
<b>Associated Symptoms</b>	Urinary symptoms and other systemic symptoms.
<b>History of</b>	Bleeding disorders like Sickle Cell anemia , <b>infections TB</b> (usually renal TB associated with Hx of pulmonary TB), bilharziasis and stone disease.
<b>Family History</b>	Malignancies that can cause hematuria ( <b>prostatic cancer</b> ) or hematological disorders. (sometimes hematuria can be the only sign of sickle cell disease)
<b>Drugs</b>	- Anticoagulants :( <b>Warfarin</b> ). Will cause hematuria! - <b>Rifampicin</b> : can cause orange discoloration of the urine not blood - In the past we used to differentiate between discoloration and hematuria by putting the urine in a glass then put your hand behind it, if you can clearly see your hand this means its discoloration not hematuria.
<b>Colored food</b>	"الشمندر" Beetroot ● & Some candies especially cotton candies.
<b>Smoking</b>	Why is it important? It is the risk factor number one for TCC (Transitional cell carcinoma) in Saudi Arabia and renal tumors.

# A. Non Traumatic Urological Emergencies

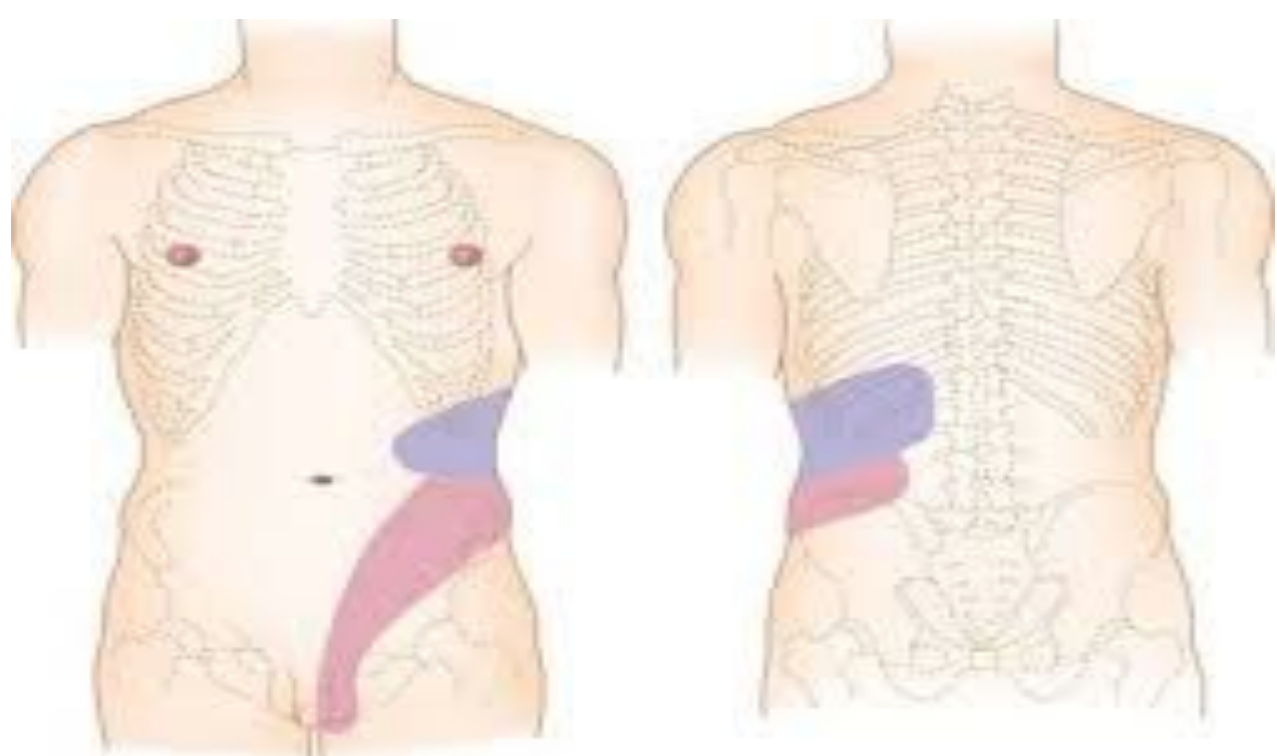
## 2. Renal Colic

- The most common urological emergency (in Saudi Arabia cases are seen daily).
- One of the most common causes of differentials associated with "Acute Abdomen"

### ● History:

- **Ureteral stones:** Acute onset of severe, intermittent flank pain often associated with nausea and vomiting.

<b>Site</b>	flank pain, or groin pain (the location of the pain is a poor indicator of stone position).
<b>Onset</b>	Sudden
<b>Character</b>	Colicky in nature
<b>Radiation</b>	Radiates <ul style="list-style-type: none"><li>- Unrelated to the site of stones</li><li>- Radiation of the pain is usually according to the dermatome of innervation:<ol style="list-style-type: none"><li>1. <b>Upper ureter:</b> innervated by T7,8,9 which also innervate the kidney and the testicles, so in a <b>male patient it will radiate to the testicle.</b> if you see a male patient with severe testicular pain with normal testicular examination and investigations, think about UPPER ureter stone.</li><li>2. <b>The Mid ureter:</b> innervated by T10 which also innervate the <b>mid bowel and the midgut</b>, so when the stone is on the right side it can radiate to the right iliac fossa and can be <b>mistakenly diagnosed as appendicitis. So how to differentiate?</b> Those affected by <b>acute appendicitis can't move due severe pain.</b> While the pain of <b>mid ureteral colic are relieved by movement</b> so, the patients are gonna move continuously.</li><li>3. <b>The Distal ureter :</b> Mainly innervated by T12 (which also innervate the bladder neck, Trigone, Labia majora, Posterior urethra, Scrotal skin) , so the patient mainly will have <b>urinary symptoms</b> (Urgency, Frequency...).</li></ol></li></ul>
<b>Associated with</b>	Nausea/Vomiting (as well as other symptoms that are related to the specific etiology behind the pain, which we are going to know later on).
<b>Timing</b>	<b>Mostly Intermittent</b> , but sometimes if there is another problem in the kidney like (Pyelonephritis) or other cause of obstructed kidney, then it will be continuous.
<b>Exacerbated by</b>	Nothing; Relieved by: analgesia and movement <ul style="list-style-type: none"><li>- The patient can't get comfortable, and might be <b>rolling around.</b></li></ul>
<b>Severity</b>	So severe (most painful)





# A. Non Traumatic Urological Emergencies

## 2. Renal Colic

### Differential Diagnosis (dr skipped it)

- Acute appendicitis
- Burst peptic ulcer.
- Radiculitis (pseudo-renal)
- Leaking (ruptured) abdominal aortic aneurysms.
- Myocardial infarction or Pneumonia or Testicular torsion.
- Ovarian pathology (e.g., twisted ovarian cyst) or Ectopic pregnancy
- Inflammatory Bowel Disease (Crohn's, ulcerative colitis) or Bowel obstruction or Diverticulitis

### Work Up

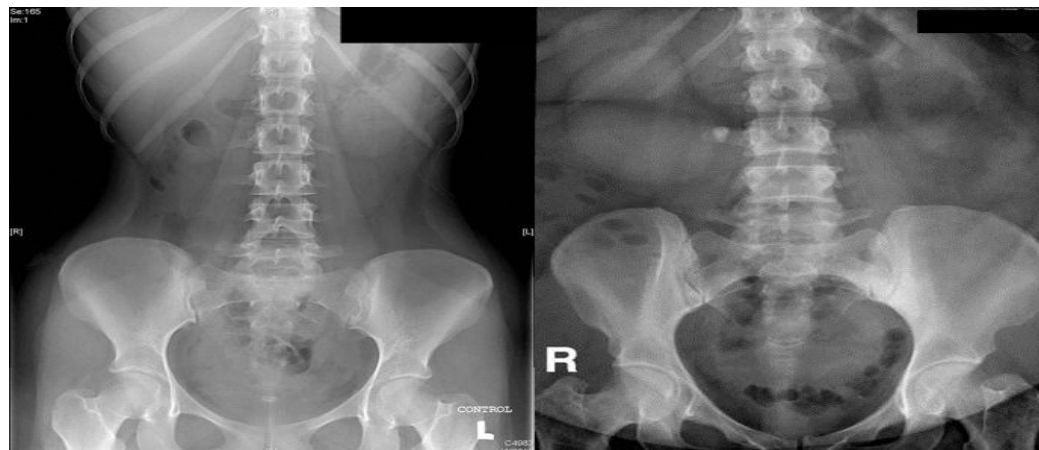
- History
- Examination: patient tends **to move around**, in an attempt to find a comfortable position.
- +/- Fever (when the renal colic is associated with pyelonephritis).

### Investigations

- Pregnancy test. (to exclude ectopic pregnancy, and also we need it for radiological consideration.
- MSU (Mid stream urine) 2 (you will find RBCs in the urine).
- U&E (Urea & Electrolyte) (if pt. has renal impairment it indicates either bilateral pathology or solitary kidney blocked by stone)

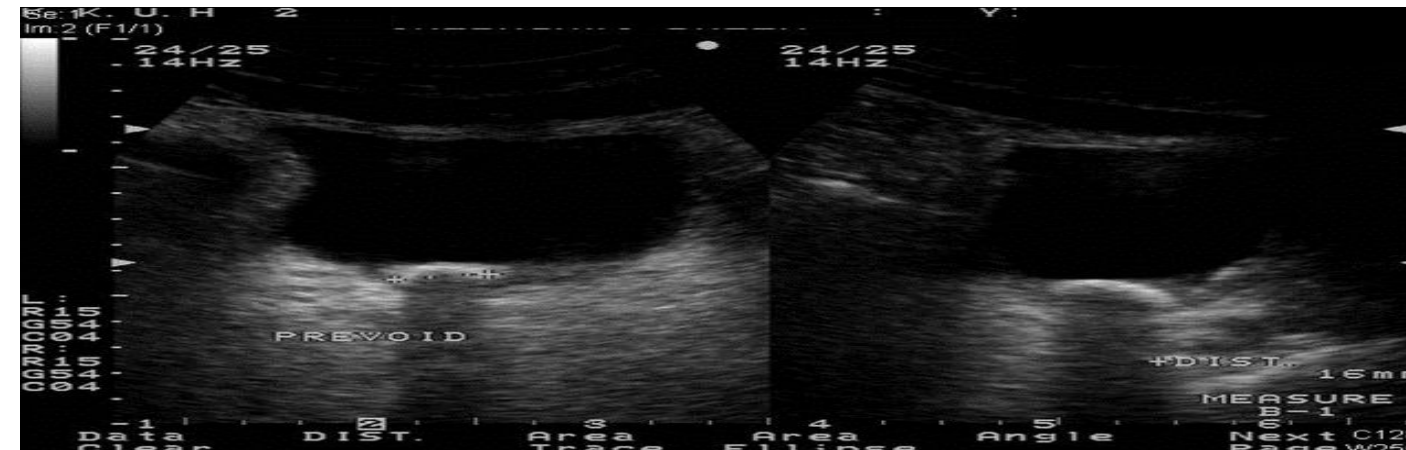### ● Radiological Investigation:

#### KUB (kidney, ureter, bladder)



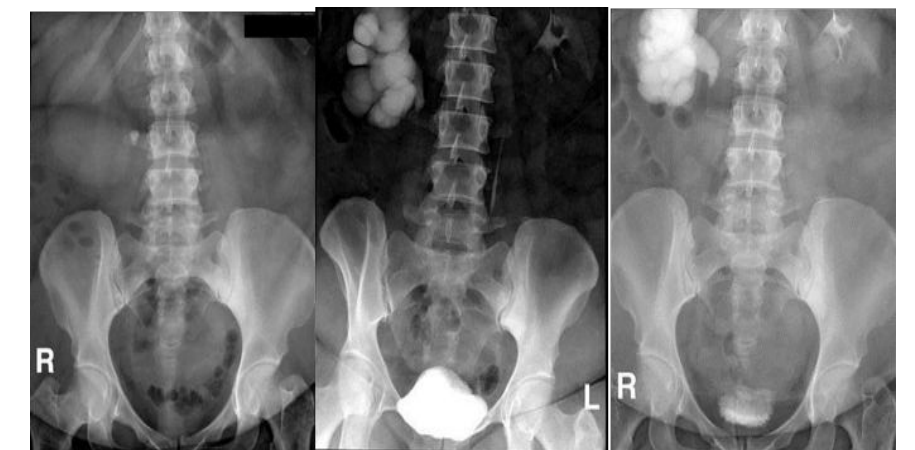
- This is an abdominal X Ray.
- Determine the location of Radiopaque stones.

#### RUS (renal ultrasound)



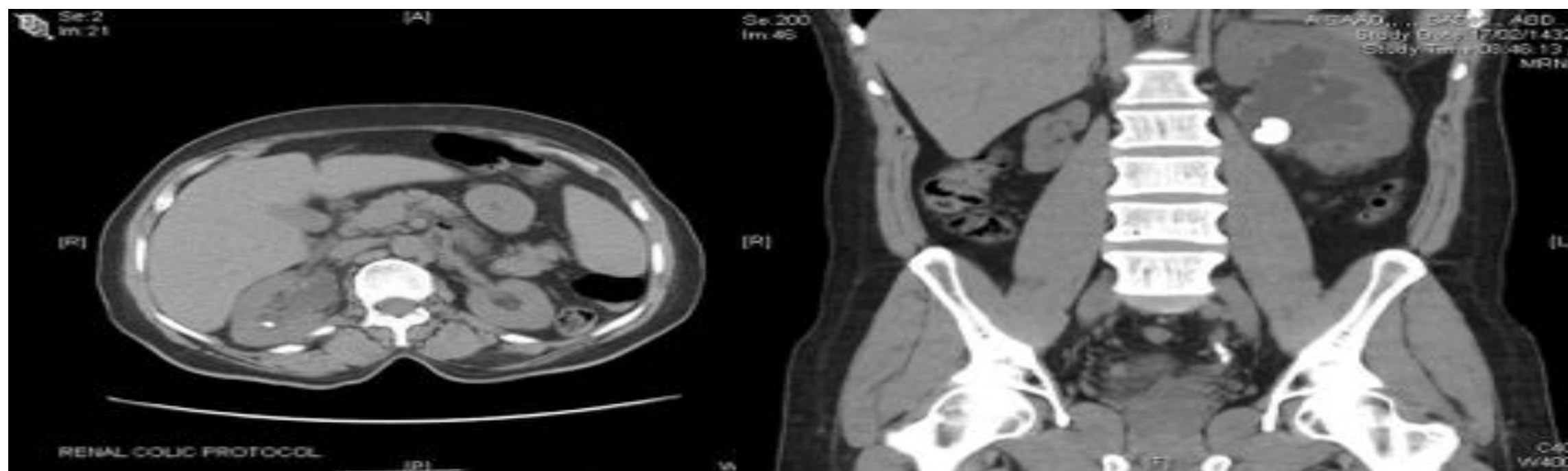
- Hyperechogenic shadow indicate stones.
- We can see the the stone but not that clear (you can't see the ureter with it).

#### IVU (intravenous urography)



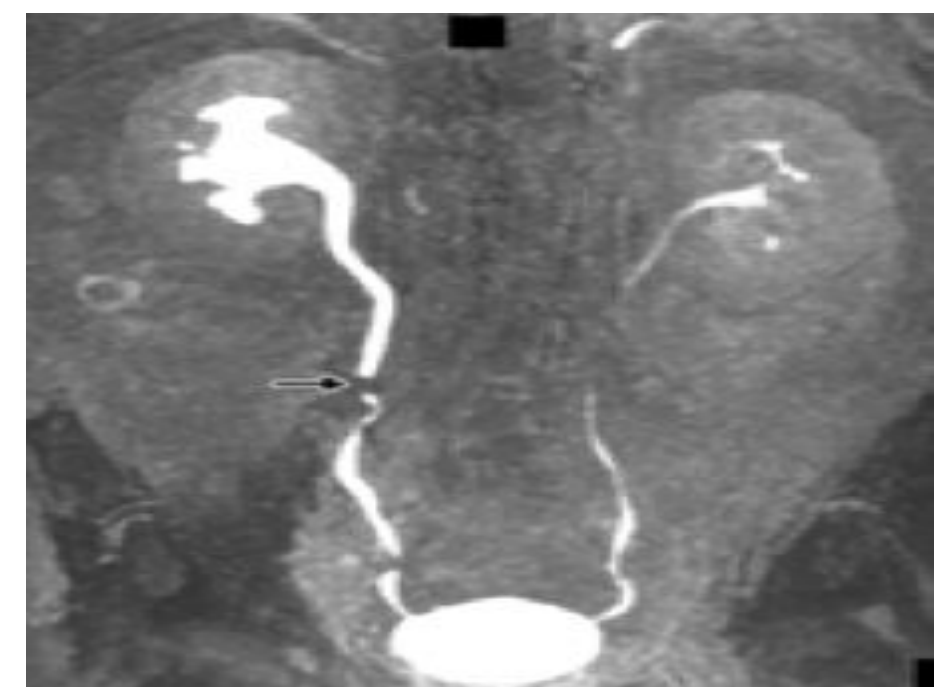
- Stone in the ureter blocking the right kidney

#### Helical CTU (Helical CT without contrast)



- The gold standard (it is a plain CT).
- Greater specificity (95%) and sensitivity (97%).
- Can identify other non-stone causes of flank pain.
- No need for contrast administration.
- Faster, taking just a few minutes
- The cost of CTU is almost equivalent to that of IVU.
- Note that there is no need to contrast bc the pt. comes to you complaining of most likely renal problem & the only thing that we can see in CT w/o contrast is a stone

#### MRI (rarely used)



- Suitable for **pregnant** ladies (No radiation).
- Very accurate way of determining whether or not a stone is present in the ureter.
- Time consuming.
- Expensive.



# A. Non Traumatic Urological Emergencies

## 2. Renal Colic

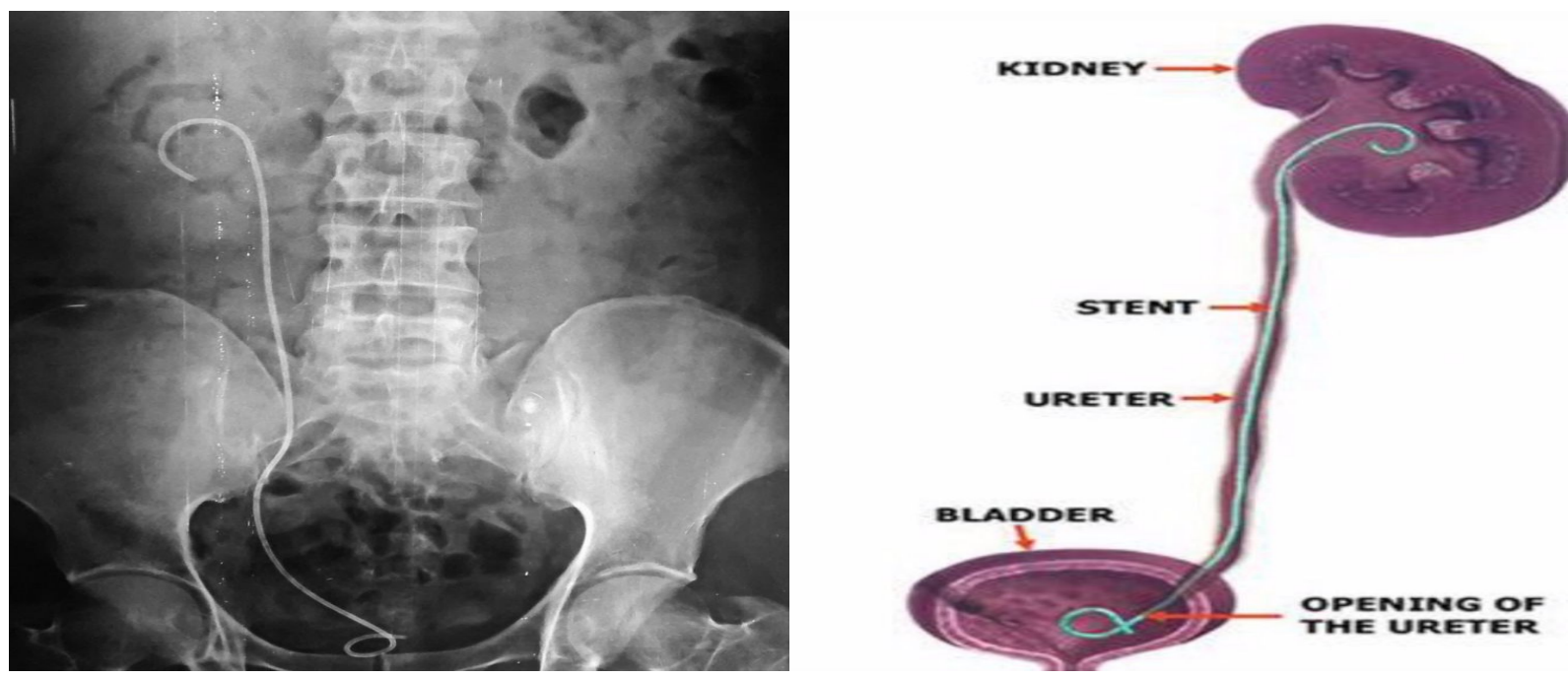
Medical Management	Surgical Management
<p><b>1. Pain relief:</b></p> <ol style="list-style-type: none"> <li>NSAIDs. E.g. Brufen, voltaren</li> <li>Intramuscular or intravenous injection, by mouth, or per rectum.</li> <li>+/- Opiate analgesics (pethidine or morphine).</li> </ol> <p>2. Hyper hydration (IV fluids &amp; drinking water)</p> <p>3. 5mm Stone or less: 'watchful waiting' with analgesic supplements; 95% of 5mm or less stones pass spontaneously</p>	<p><b>To Relieve Obstruction and/or Remove the stone.</b></p> <p><u>Indications for Intervention:</u></p> <ol style="list-style-type: none"> <li>Pain that fails to respond to analgesics.</li> <li>Association With Fever.             <ol style="list-style-type: none"> <li>(fever highly suggests pyelonephritis which requires drainage because it may cause septicemia)</li> </ol> </li> <li>Renal Function Impairment caused by stone.             <ol style="list-style-type: none"> <li>Solitary kidney obstructed by a stone, bilateral ureteric stones</li> <li>How do we assess renal functioning? <b>increase creatinine.</b></li> </ol> </li> <li><b>Obstruction Unrelieved (not to exceed 4 weeks!)</b> <ol style="list-style-type: none"> <li>(bc after 4 weeks the obstruction will cause necrosis) <b>ممكن ننتظر الحصوة تنزل بنفسها لكن لو استمر الموضوع 4 أسابيع لابد من تدخل جراحي</b> the kidney might stop working if not treated</li> </ol> </li> <li>Personal Or Occupational Reasons: <b>Doctors or pilots.</b></li> </ol>

### • Types of Surgical Intervention:

- Temporary relief of the obstruction

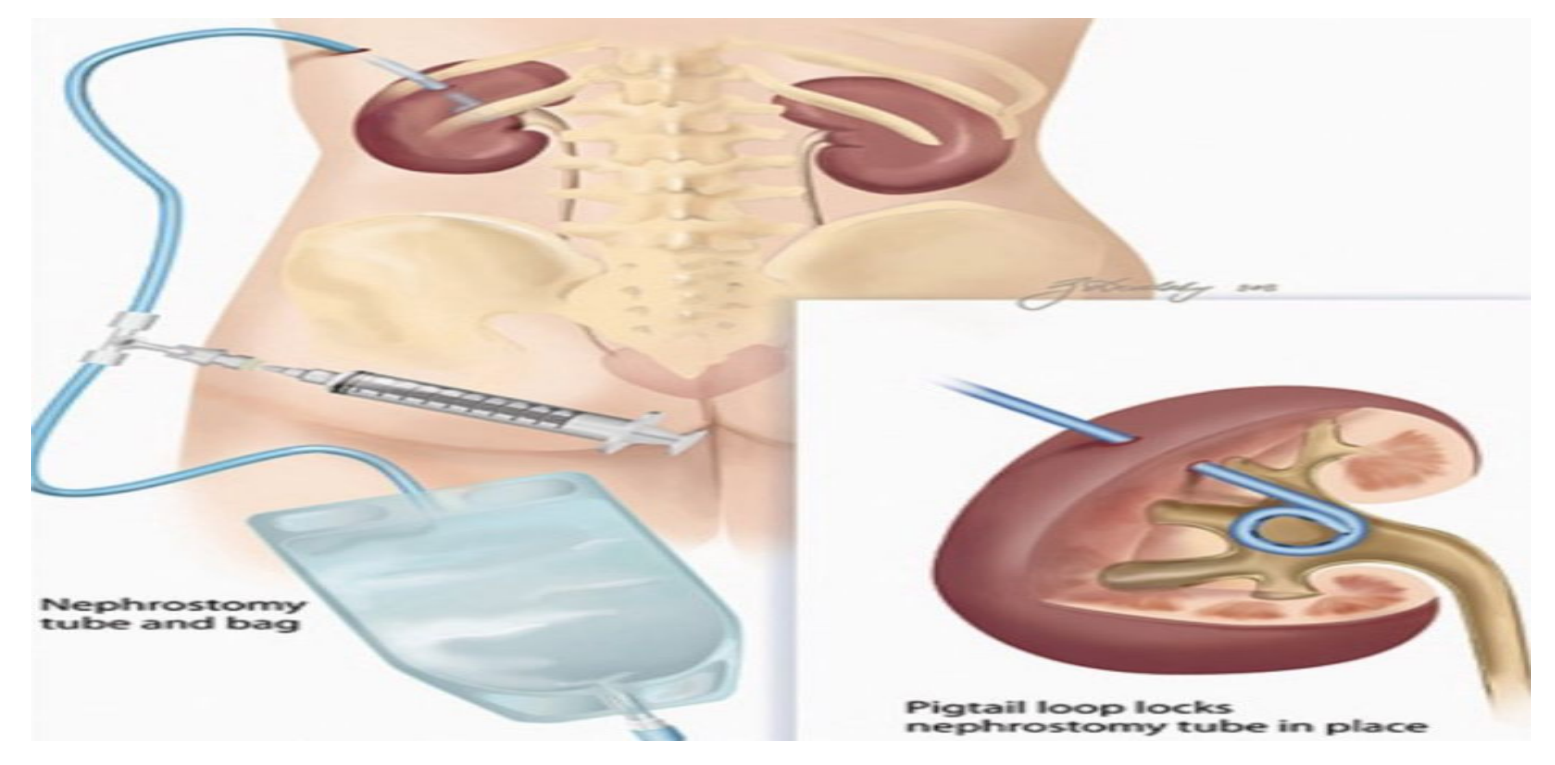
#### ★ Insertion of a double coil or JJ Stent:

- A thin tube is inserted into the ureter to prevent or treat obstruction of the urine flow from the kidney also known as urinary stent.



#### ★ Percutaneous Nephrostomy Tube:

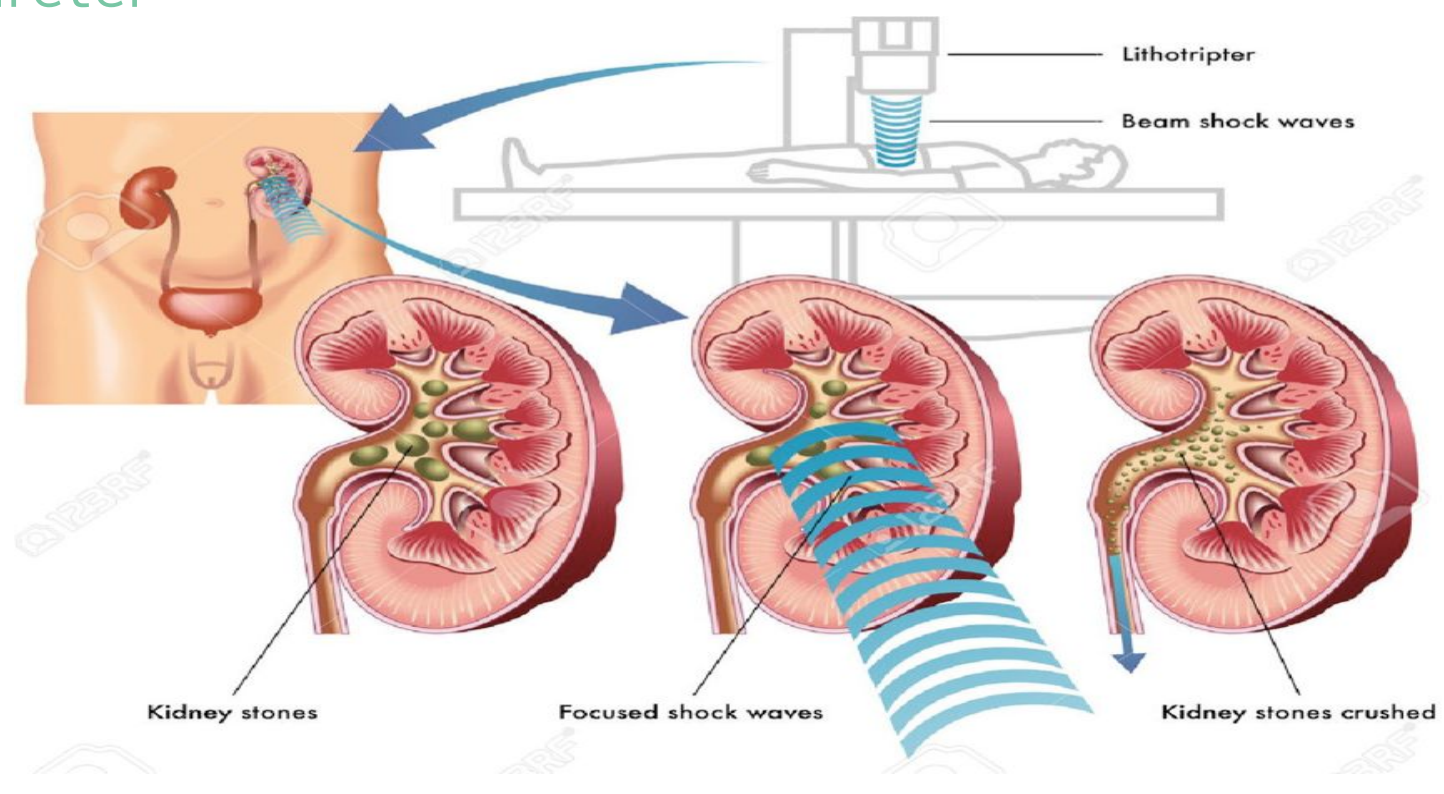
- Insert a catheter through your skin into the kidney to drain the urine.



- Definitive Treatment:

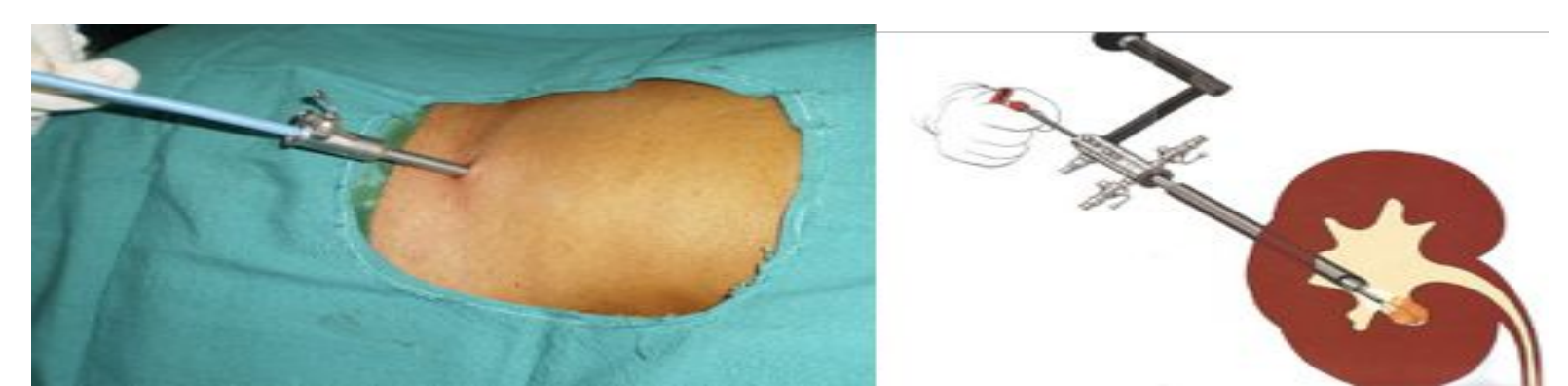#### ★ Extracorporeal Shock Waves Lithotripsy (ESWL):

- Break small radiopaque stones in kidney or upper ureter



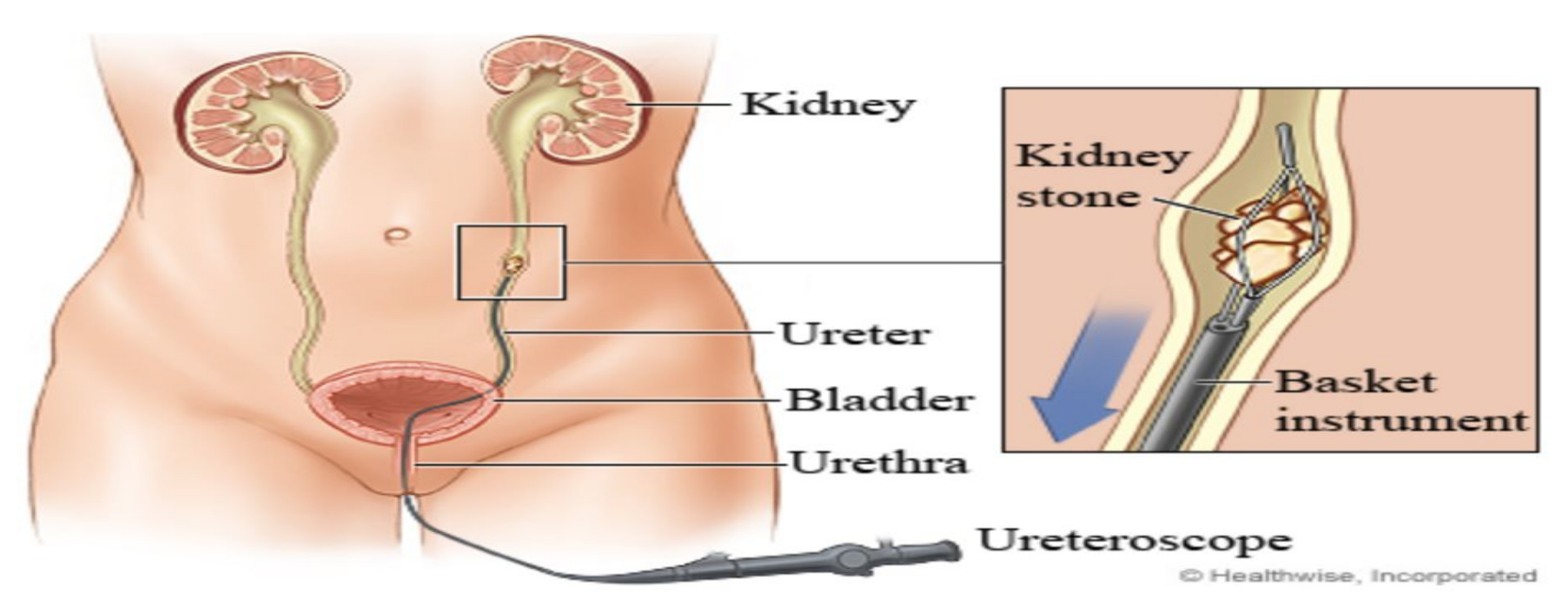
#### ★ Percutaneous Nephrolithotomy (PCNL or PNL):

- for large stones.



#### ★ Ureteroscopy (URS) (laser) (very common)

Examination of the upper urinary tract using ureteroscope that is passed through the urethra → bladder → directly into the ureter.



#### ★ Laparoscopic extraction (rare)

#### ★ Open Surgery: (very limited)

- (because of the big incision and the high chance of recurrence of the stones).



# A. Non Traumatic Urological Emergencies

## 3. Urinary Retention

### I. Acute Urinary Retention:

- Painful **inability** to void, with relief of pain following drainage of the bladder by catheterization. More common in Men than in Women.

#### ● Causes:

Men	Women (rare)
<ul style="list-style-type: none"><li>● Benign prostatic enlargement (BPE) due to BPH The most common.</li><li>● Carcinoma of the prostate</li><li>● Prostatic abscess</li><li>● Urethral stricture</li><li>● Stones</li><li>● Constipation</li></ul>	<ul style="list-style-type: none"><li>● Pelvic prolapse (cystocele, rectocele, uterine)</li><li>● Pelvic masses (e.g., ovarian masses)</li><li>● Urethral stenosis</li><li>● Urethral diverticulum</li><li>● Post surgery for 'stress' incontinence: Transvaginal tape (sling) in those with stress incontinence (لو كان مشدود أكثر من اللازم) is very common</li></ul>

#### ● Initial Management:

- ★ Urethral catheterization if you can't enter it (stricture in urethra), use the Suprapubic catheter (SPC) which passes directly to the bladder through skin.

#### ● Late Management:

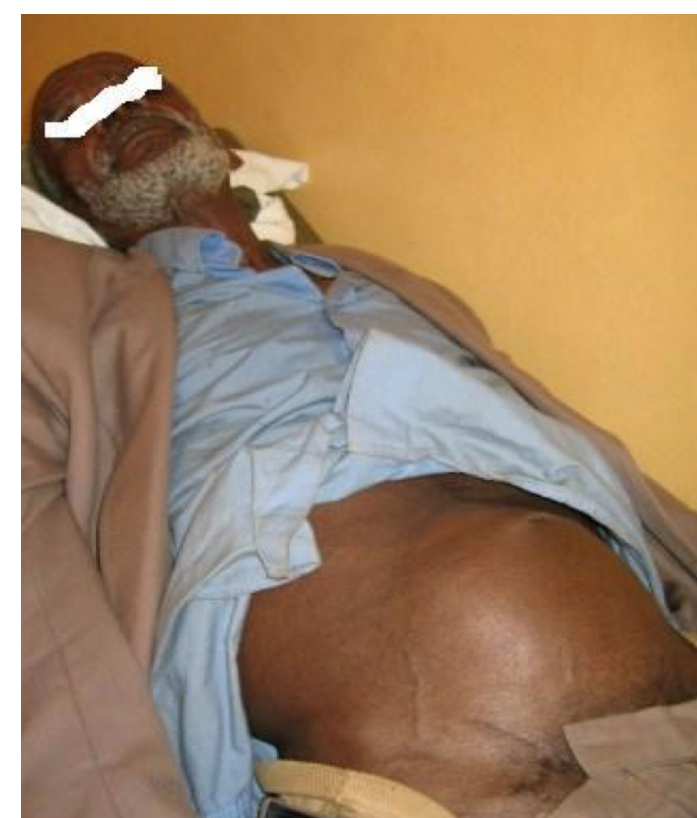- ★ Treating the underlying cause.

### II. Chronic Urinary Retention:

- Obstruction develops slowly, the bladder is distended (stretched) very gradually over weeks/months, **Pain is not a feature.** (mostly related to diabetes).
  - Why in diabetic patients? Neurogenic bladder is a form of diabetic neuropathy in which selective damage leads to autonomic neuropathy where the nerves affected result in decreased urination frequency?
- Usually associated with:
  - Reduced renal function.
  - Upper tract dilatation.


#### ● Presentation:

- ★ Urinary dribbling.
- ★ Overflow incontinence.
- ★ Palpable Bladder with no pain.
- ★ Symptoms of renal failure. (nausea and malaise)
  - Pyelonephritis



#### ● Management:

- ★ Treatment is directed to renal support. (treat the renal failure first!)
- ★ Bladder drainage.
- ★ Late Treatment of underlying cause.






# A. Non Traumatic Urological Emergencies

## 4. Acute Scrotum

- **Emergency** situation requiring prompt evaluation, differential diagnosis, and potentially immediate surgical exploration **of the testicle**

### Differential Diagnosis

- **Torsion of the spermatic cord (Most serious) Most important.**
- Torsion of the appendix testis.
- Torsion of the appendix epididymis.
- **Epididymitis (Most common).**
- **Epididymo-orchitis**
- Orchitis
- Inguinal hernia
- Trauma/ insect bite
- Dermatological lesion
- Inflammatory vasculitis (Henoch-Schonlein purpura)
- Neurological (adductor tendonitis)
- Communicating hydrocele
- **Hydrocele** (Examination will reveal positive transillumination test and big scrotum):  
This is a common condition, especially in older men, in which fluid collects in the tunica vaginalis, resulting in an enlarged but painless scrotum. The cause of most hydroceles is unknown (idiopathic).  
Hydrocoele is a common abnormality in children. It is due to failure of closure of the processus vaginalis after descent of the testis.
- Idiopathic scrotal edema
- Tumor
- Spermatocele
- Non-urogenital pathology e.g. adductor tendinitis



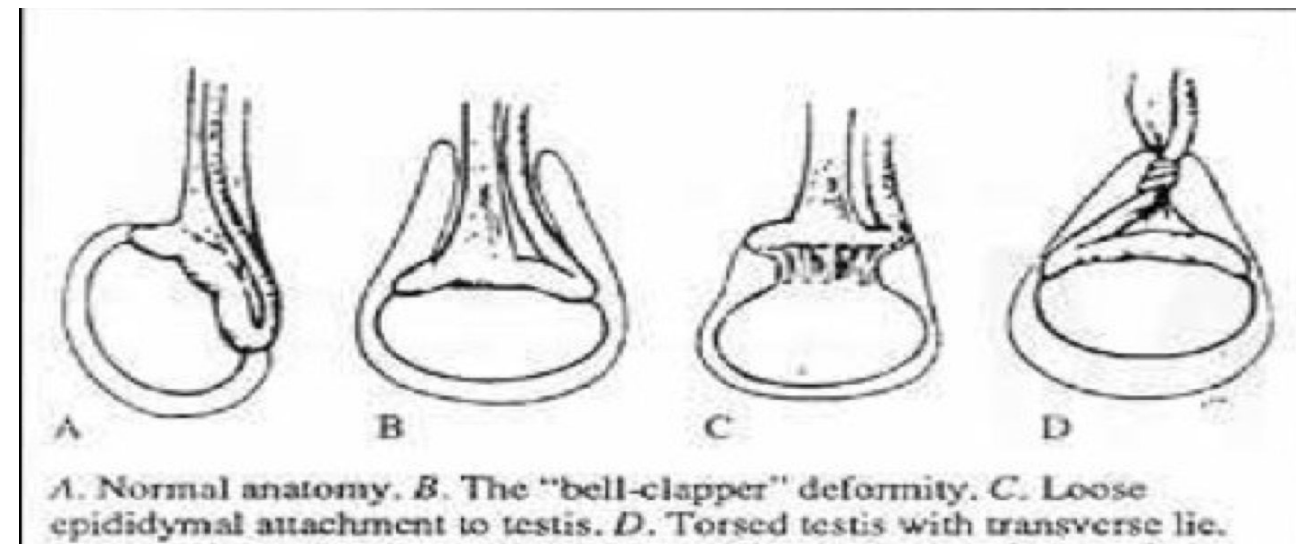
# A. Non Traumatic Urological Emergencies

[Click here to see the pictures](#)

## 4. Acute Scrotum

### I. Torsion of the Spermatic Cord

- Common among teenagers (12-18) years
- Possible in children and neonates.
- Unlikely after the age of 25 years.
- True surgical emergency of the highest order.
- Irreversible **ischemic** injury to the testicular parenchyma may begin as soon as **4 hours**.  
Might lose the testical if not treated withing 4 hours
- **As the duration of torsion increases the possibility of testicular salvage Decreases.**
- Anatomical Variations: (predisposing factors)
  - A. Normal position of the testis is longitudinal
  - B. If the tunica vaginalis is loose → allows the testis to move freely within the tunica vaginalis (bell clapper deformity)
  - C. Loose Epididymal Attachment To The Testis.
  - D. Torsion testis with horizontal line.



#### ★ Presentation:

- **Acute onset of scrotal pain.** (severe and intermittent due to attacks of torsion and detorsion).
- Majority with history of prior episodes of severe, self-limited scrotal pain & swelling
- **Nausea/Vomiting** due to pain (important sign to focus on).
- Referred to the ipsilateral lower quadrant of the abdomen.
- **Children** may present with abdominal pain **and might not complain of testicular pain.**


Any child comes to you complain of with nausea and vomiting or complains of severe abdominal pain needs to have genital examination.

Case: A mother brought her child to the clinic and said she "my child went to school and ate bad food and now he complains of abdominal pain, nausea and vomiting" after making further inspection, the child had a Torsion of the cord.

- Dysuria & other bladder (unirany) symptoms are usually **absent** (unlike epididymitis)

#### ★ Physical Examination:

- The affected testis is **high riding** transverse orientation.
- **Acute hydrocele** (swelling) or **massive scrotal edema**
- **Absent Cremasteric reflex.**
- **Testis is tender and larger than other side**
- Elevation of the scrotum causes more pain (negative Prehn's sign).





# A. Non Traumatic Urological Emergencies

[Click here to see the pictures](#)

## 4. Acute Scrotum

### I. Torsion of the Spermatic Cord

★ This is an **emergency case (requires immediate scrotal exploration)**, with a high degree of suspicion is enough to send the patient to the OR immediately

★ **Investigation:**

○ **Adjunctive tests**

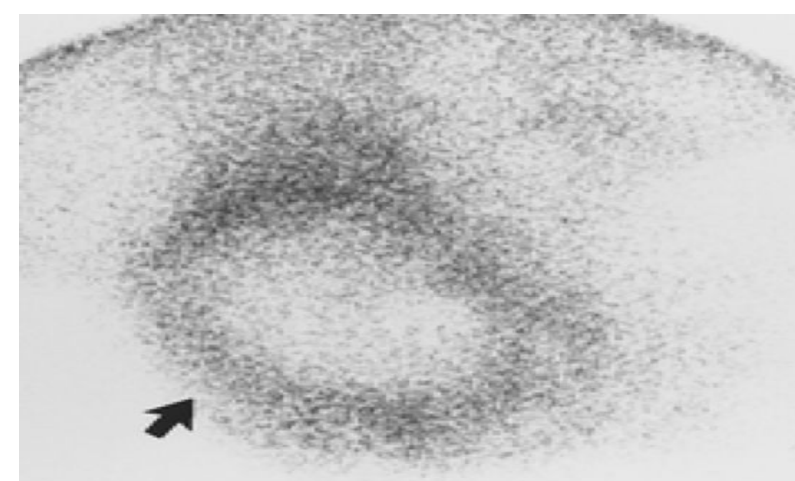
- If diagnosis is clinically suspicious don't delay the patient for any investigation
- To aid in differential diagnosis of the acute scrotum.
- To confirm the **absence** of torsion of the cord.
- **Sound Doppler** examination of the cord and testis:
  - High false-positive and false-negatives.

1. **Color Doppler Ultrasound: Investigation of choice**

- Assessment of anatomy & determining the presence or absence of blood flow.
- Sensitivity: 88.9% specificity of 98.8%
- Operator dependent.

2. **Radionuclide Imaging:**


- Assessment of testicular blood flow.
- A sensitivity of 90%, and specificity of 89%.
- False impression from hyperemia of scrotal wall.
- Not helpful to determine a Hydrocele or Hematoma (does not assess anatomy)
- Difficult to do in emergency & rarely done bc it's time consuming.



★ **Management:**

○ **Surgical Explorations:**

- A scrotal incision is done and the affected site should be examined first:
- The cord should be detorsed.
- Testes with marginal viability should be placed in warm and re-examined after several minutes.
- A necrotic testis **should be removed**.
- If the testis is to be preserved, it should be fixed.
- The **contralateral** testis must be fixed **to prevent subsequent torsion**.



# A. Non Traumatic Urological Emergencies

[Click here to see the pictures](#)

## 4. Acute Scrotum

### II. Epididymo-orchitis

#### ★ Presentation:

- Gradual pain & the patient will have urinary symptoms
- Usually present in middle age patients and older
- Indolent process (**gradual presentation**).
- Scrotal swelling, erythema, and pain
- Dysuria and fever is more common in patients with history of STD like gonorrhea

#### ★ Physical Examination:

- Localized swollen and tender epididymis, or a massively swollen hemiscrotum with absence of landmarks.
- **Cremasteric reflex should be present**
- Positive Prehn's sign indicates there is pain relief with lifting the affected testicle

#### ★ Urinalysis:

- Pyuria, bacteriuria and/or a positive urine culture and WBC.

#### ★ Management:

- Bed rest for 1 to 3 days then relative restriction.
- Scrotal elevation, the use of an athletic supporter
- Parenteral antibiotic therapy should be instituted when UTI is documented or suspected.
- Urethral instrumentation should be **avoided**

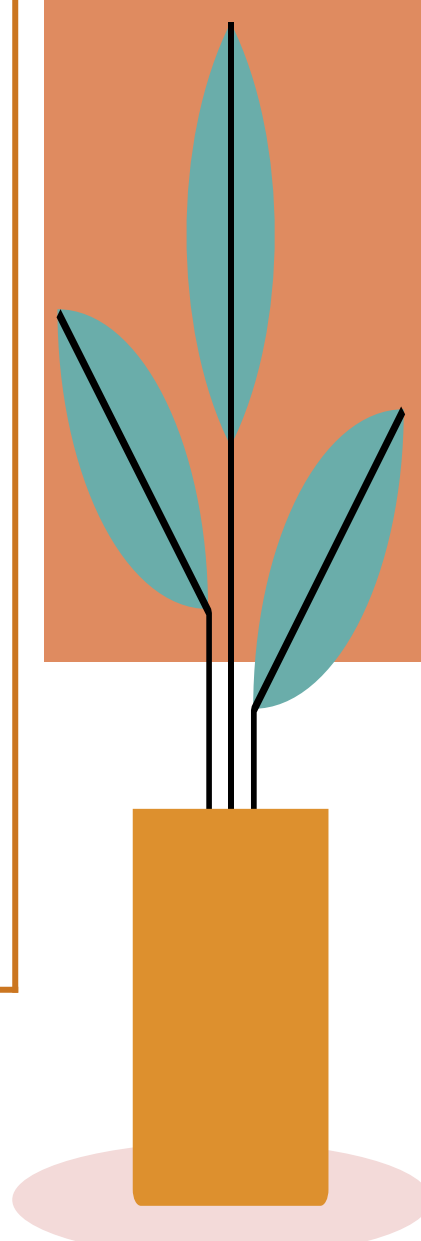
### Surgical Recall

#### - What is it Testicular torsion?

Torsion (twist) of the spermatic cord, resulting in venous outflow obstruction, and subsequent arterial occlusion → infarction of the testicle.

- **What is the classic history?** Acute onset of scrotal pain usually after vigorous activity or minor trauma
- **What is a "bell clapper" deformity?** Bilateral non attachment of the testicles by the gubernaculum to the scrotum (free like the clappers of a bell)
- **What are the symptoms?** Pain in the scrotum, suprapubic pain
- **What are the signs?** Very tender, swollen, elevated testicle; non illumination; absence of cremasteric reflex.
- **What is the differential diagnosis?** Testicular trauma, inguinal hernia, epididymitis, appendage torsion
- **How is the diagnosis made?** Surgical exploration, U/S (solid mass) and Doppler flow study, cold Tc-99m scan (nuclear study)
- **What is the treatment?**

Surgical detorsion and bilateral orchiopexy to the scrotum.





# A. Non Traumatic Urological Emergencies

## 5. Priapism

- Persistent erection of the penis for **more than 4 hours that is not related or accompanied by sexual desire.**

### ● Causes:

- Primary (Idiopathic) : 30% - 50% of the cases.
- Secondary: Drugs, Trauma, Neurological, Hematological disease (**very common**), and tumors:

### ● Types:

Ischemic (most common)	Nonischemic
(veno-occlusive, low flow) (worse) Occlusion of venous return	(arterial, high flow) (not harmful)
Due to hematological disease e.g. <b>sickle cell</b> , leukemia, malignant infiltration of the corpora cavernosa with malignant disease, or drugs e.g. prostaglandin injection; prazosin	Due to perineal <b>trauma</b> , which creates an arteriovenous fistula. ( <b>pudendal artery fistula</b> )
<b>Painful</b>	<b>Painless</b>

### ● Diagnosis: (Usually obvious from the history)

- ★ Duration of erection: **>4 hours?**
- ★ Is it painful or not? To determine the type: ischemic or not
- ★ Previous history and treatment of priapism? **Especially in sickle patients**
- ★ Identify any predisposing factors and underlying cause.

### ● Examination:

- ★ Erect, tender penis (in low-flow)
- ★ Characteristically the corpora cavernosa are rigid and the glans is flaccid.
- ★ **Abdominal** examination for evidence of **malignant** disease
- ★ Digital rectal exam (DRE): to examine the prostate and **check anal tone.**


### ● Investigation:

- ★ CBC (white cell count and differential, reticulocyte count).
- ★ Hemoglobin electrophoresis for sickle cell disease.
- ★ Urinalysis including urine toxicology.
- ★ Color flow duplex ultrasonography in cavernosal arteries:
  - Ischemic (inflow is low or nonexistent).
  - Nonischemic (inflow is normal to high).
- ★ **Penile pudendal arteriography (VERY IMPORTANT for patients with nonischemic type and sometimes you can manage them with it).**
- ★ Blood gases taken from either corpora: **this table is very important.**

	Low flow ( <b>ischemic/occlusive</b> )	High flow (nonischemic/ fistula)
<b>Blood color</b>	dark blood	bright red blood similar to arterial blood at room temperature
<b>PH</b>	<7.25 (acidosis)	= 7.4 (normal)
<b>P02</b>	p02 <30 mmHg (hypoxia)	p02 >90 mmHg (normal)
<b>PC02</b>	pCO2 >60 mmHg (hypercapnia)	pCO2 <40 mmHg (normal)

### ● Treatment:

- ★ Depends on the type of priapism.
- ★ Conservative treatment should first be tried
- ★ Medical treatment, Surgical treatment. & Treatment of underlying cause.



# B. Traumatic Urological Emergencies

[Click here to see the pictures](#)

## 1. Renal Trauma

- The kidneys relatively protected (by the thoracic cage) from traumatic injuries so a considerable degree of force is usually required to injure a kidney.

### ● Mechanisms & Causes:

#### ★ Blunt Trauma:

- Direct blow or acceleration/ deceleration injuries.
  - Road traffic accidents, falls from a height, fall on flank.
- Very Common

#### ★ Penetrating Trauma:

- Knives, gunshots, **iatrogenic** e.g. percutaneous nephrolithotomy (PCNL).


### ● Renal Imaging:

#### ★ Indications for renal imaging:

- Penetrating chest, flank, and abdominal wounds.
- A history of a rapid acceleration or deceleration.
- Macroscopic (Gross) haematuria.
- Microscopic [ $>5$  red blood cells (RBCs) per high powered field in adult but in children any amount will require imaging!] or dipstick.
- Hypotensive patient (SBP  $<90$  mmHg ).
- Any child with microscopic or dipstick haematuria who has sustained trauma

#### ★ What imaging study?

<b>IVU</b>	<ul style="list-style-type: none"><li>● Replaced by the contrast enhanced CT.</li><li>● On-table IVU (intraoperative) if patient is transferred immediately to the operating theater without having a CT scan &amp; retroperitoneal hematoma is found.</li><li>● Done to see if other (non-injured) kidney is functioning and/or exists because the injured kidney might have to be removed.</li></ul>
<b>CT Scan</b>	<ol style="list-style-type: none"><li>1. <u>Spiral non contrast</u>: does not allow accurate staging. (not helpful)</li><li>2. <u>Contrast-enhanced</u> (Imaging study of choice)<ol style="list-style-type: none"><li>a. Accurate, rapid, can assess other abdominal injuries &amp; structures.</li></ol></li></ol>
<b>Renal US</b>	<ul style="list-style-type: none"><li>● <b>Advantages:</b> (in patients who can't have x-ray)<ul style="list-style-type: none"><li>○ Can certainly establish the presence of two kidneys.</li><li>○ The presence of a retroperitoneal <b>hematoma</b>.</li><li>○ Power doppler can identify the presence of blood flow in the renal vessels.</li></ul></li><li>● <b>Disadvantages:</b><ul style="list-style-type: none"><li>○ Cannot accurately identify parenchymal tears, collecting system injuries, or extravasations of urine until a later stage when a urine collection has had time to accumulate.</li></ul></li></ul>



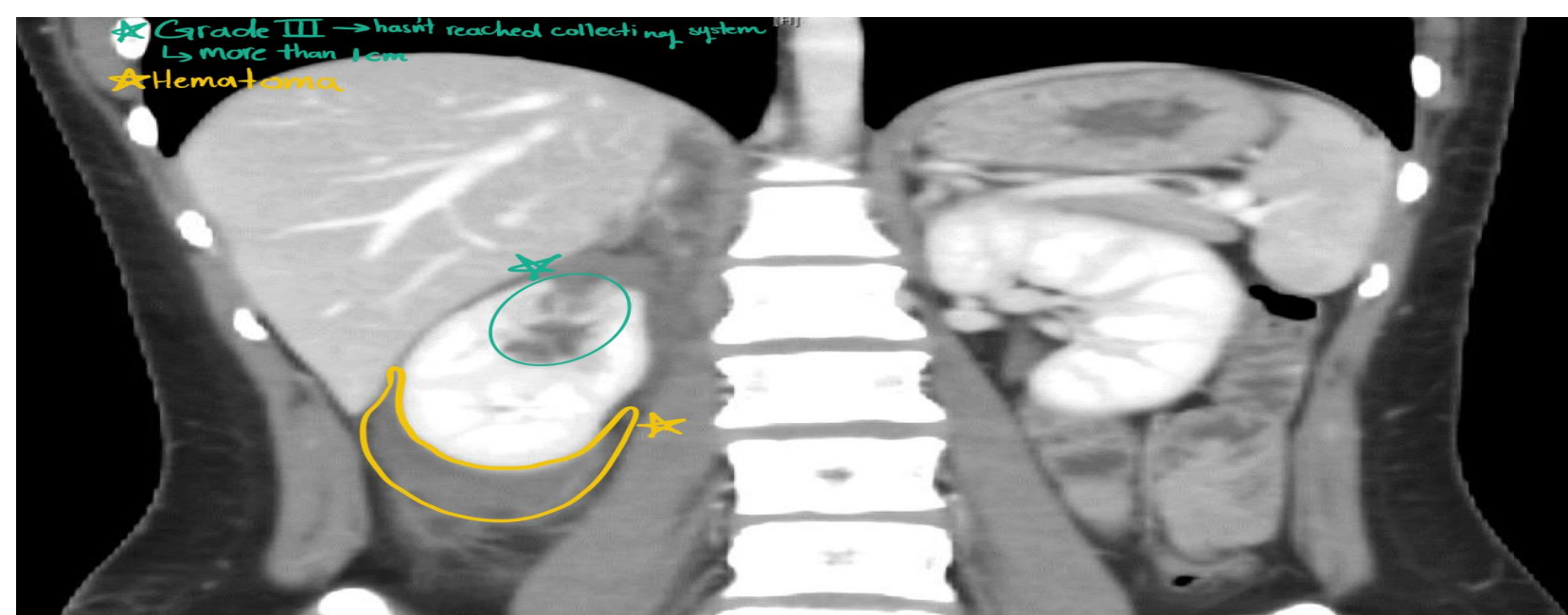
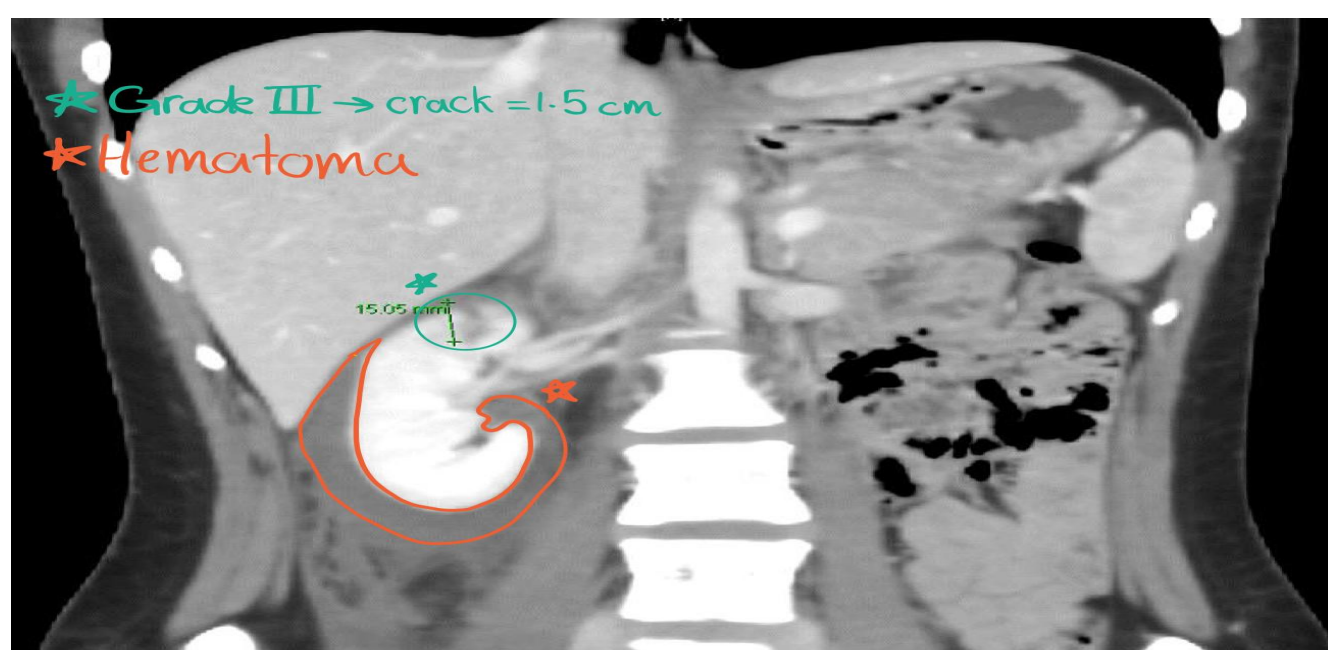
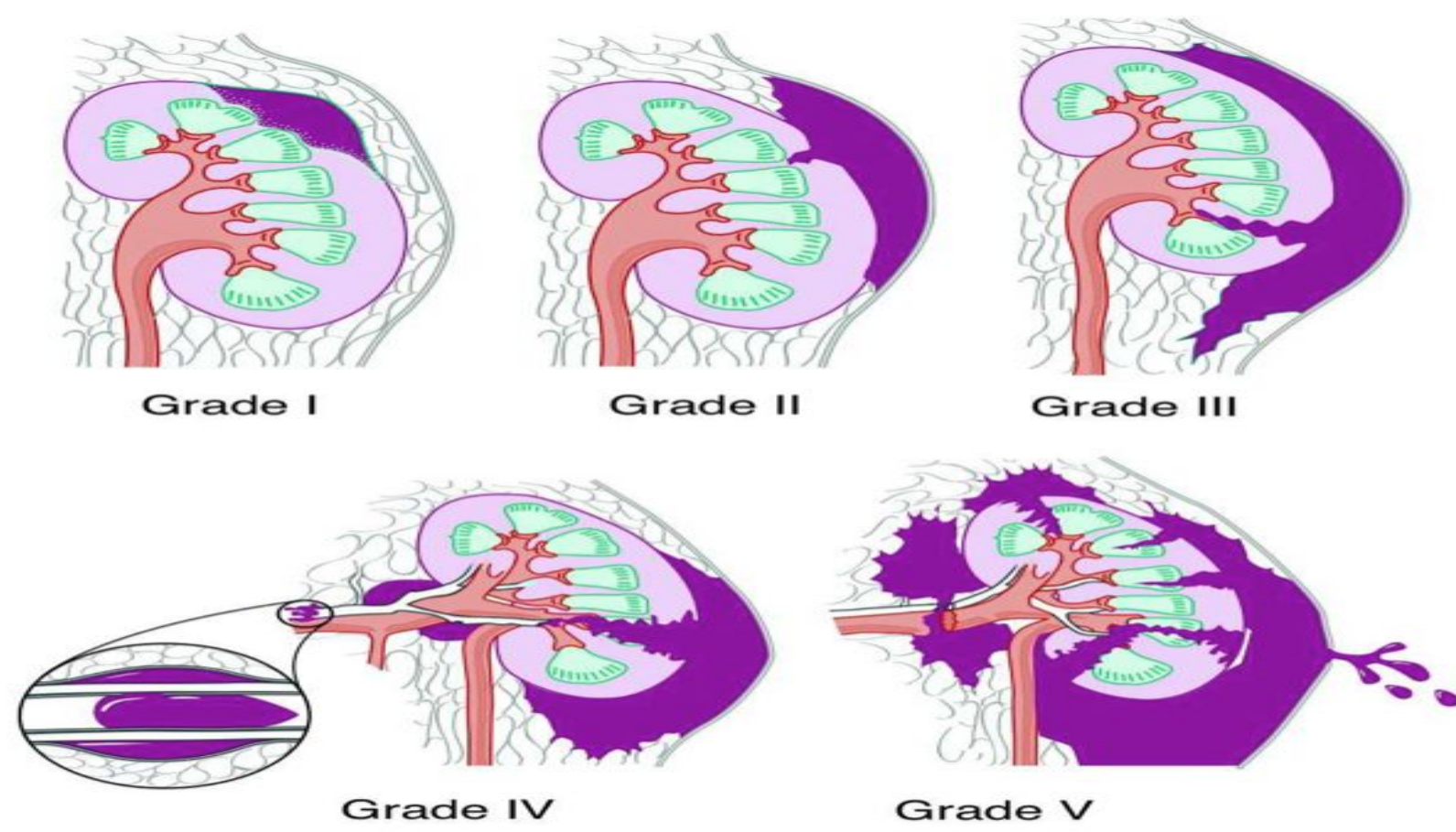
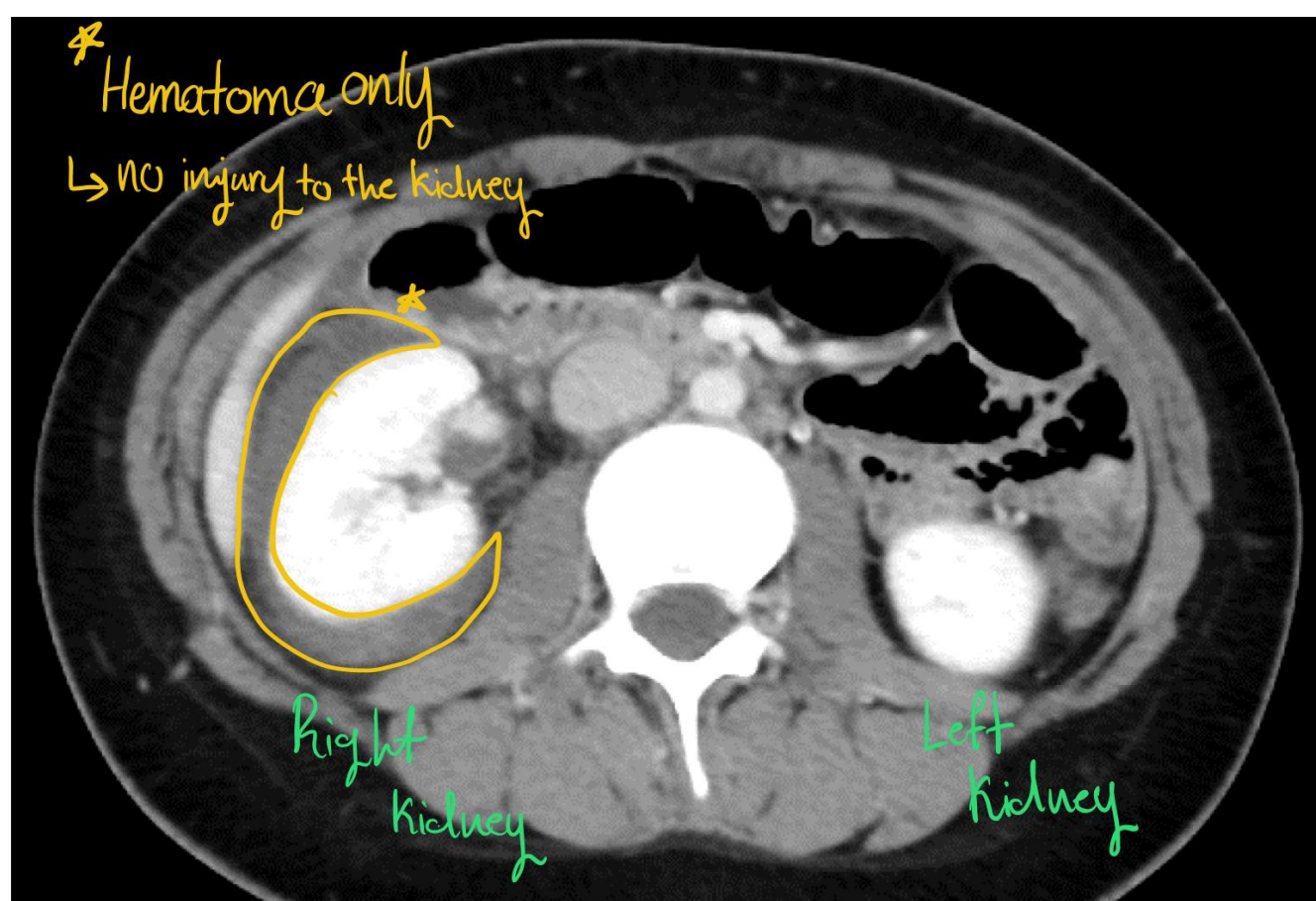


# B. Traumatic Urological Emergencies

## 1. Renal Trauma

- **Grades and Stages** : done by CT with contrast

I	Capsular hematoma without kidney tearing
II	Injury to the <u>cortex</u> (tearing) with hematoma only of <b>1 cm or less</b> .
III	Injury to the cortex and medulla <b>without reaching the collecting system</b> with hematoma <b>more than 1 cm</b> .
IV	Injury <b>reaching the collecting system</b> or injury to one of the small renal vessels
V	Completely injured or shattered kidney or avulsion (tearing)



- **Management:**

- ★ **Conservative Treatment:**

- In over 95% of blunt injuries.
- In 50% of renal stab injuries and 25% of renal gunshot wounds (Specialized centers)
- Include:
  - Wide Bore IV line to transfuse fluids.(big cannula)
  - IV antibiotics. Because hematoma is most likely to cause an infection.
  - **Bed rest.**
  - Vital signs monitoring.
  - Serial CBC and HCT
  - Follow up US &/or CT.

- ★ **Surgical Exploration:**

- **Persistent bleeding** (persistent **tachycardia** and/or **hypotension** failing to respond to appropriate fluid and blood replacement).
- **Retroperitoneal hematoma:** still held by peritoneum so, it's better not to interfere, we mark the hematoma (if it is not expanding quickly then don't open the peritoneum).
- **Expanding perirenal hematoma** (again the patient will show signs of continued bleeding) (needs Surgical intervention).
- **Pulsatile perirenal hematoma** (indicate large blood vessels injury and needs Surgical intervention) .





# B. Traumatic Urological Emergencies

## 2. Ureteral Injuries

- The ureters are protected from external trauma by surrounding bony structures, muscles and other organs therefore injury is rare

### ● Mechanisms & Causes:


External Trauma (rare)	Internal Trauma (iatrogenic)
<p>Severe force is required.</p> <p>- <b>Blunt</b> or <b>penetrating</b>:</p> <ol style="list-style-type: none"><li>1. <b>Blunt</b> external trauma severe enough to injure the ureters will usually be associated with multiple other injuries.</li><li>2. <b>Penetrating</b> knife or bullets to the abdomen or chest may damage the ureter, as well as other organs.</li></ol>	<ul style="list-style-type: none"><li>- Uncommon, but is more common than external trauma.</li><li>- Iatrogenic (during surgery):<ol style="list-style-type: none"><li>1. <b>Hysterectomy</b> (because the ureter is really close to the uterine artery), oophorectomy, and sigmoid-colectomy.</li><li>2. <b>Caesarean section</b>.</li><li>3. Ureteroscopy.</li><li>4. Aortoiliac vascular graft replacement. (rare)</li><li>5. Laparoscopies.</li><li>6. Orthopedic operations.</li></ol></li></ul>

### ● Diagnosis:

- ★ Requires a high index of suspicion, usually diagnosed Intra-operatively.
- ★ Late diagnosis: (pt ignore the pain bc they think it's a regular post-operative pain)
  - An ileus: the presence of urine within the peritoneal cavity.
  - Prolonged postoperative fever or overt urinary sepsis.
  - **Persistent drainage of fluid** (urine w/ high Creatinine) from abdominal or pelvic drains, from the abdominal wound, or from the vagina.
  - **Flank pain if the ureter has been ligated**.
  - An abdominal mass, representing a urinoma (urinoma: A urinoma is a mass formed by encapsulated extravasated urine. It may follow closed renal injury, surgical operation or arise spontaneously in the presence of obstruction).
  - Vague abdominal pain (make us suspicious).

### ● Treatment:

- ★ JJ stenting (if the injury is partial).
- ★ Primary closure of partial transection of the ureter.
- ★ Direct ureter to ureter anastomosis.
- ★ **Re-implantation** of the ureter into the bladder using a psoas hitch or a Boari flap (mostly)
- ★ Trans uretero-ureterostomy (we transfer one ureter to the other).
- ★ Auto-transplantation of the kidney into the pelvis. (rare)
- ★ Replacement of the ureter with ileum.
- ★ Permanent cutaneous ureterostomy.
- ★ Nephrectomy.





# B. Traumatic Urological Emergencies

## 3. Bladder Injuries

[Click here to see the pictures](#)

### ● Causes:

#### Iatrogenic Injury (Internal)

1. **Transurethral resection of bladder tumor (TURBT):** is a procedure in which bladder tumors can be removed from the bladder wall.
2. **Cystoscopy bladder biopsy**
3. **Transurethral resection of prostate (TURP):** is a surgery used to treat urinary problems due to an enlarged prostate.
4. **Cystolitholapaxy:** (crushing stones by scope)
5. **Caesarean section** or **Hysterectomy** especially as an emergency (most common).
6. **Total hip replacement** (very rare).

#### External Injury

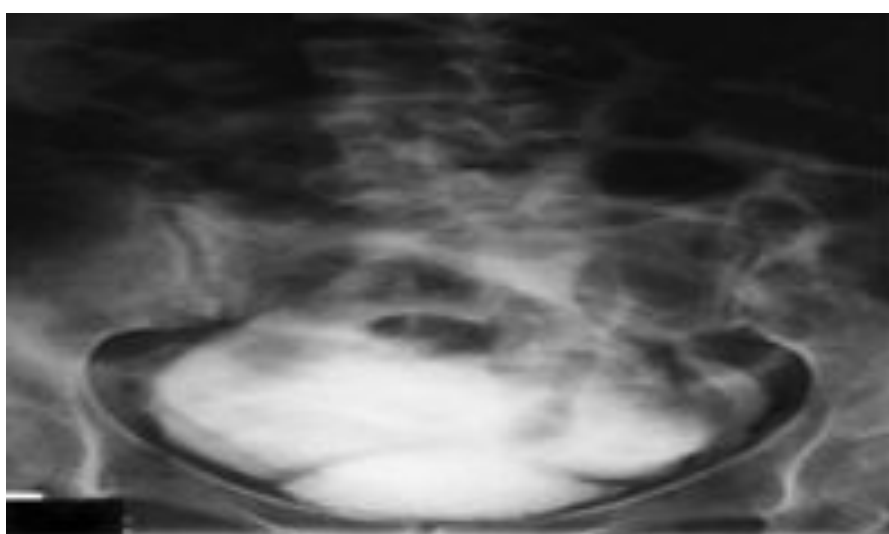
1. **Penetrating trauma** to the lower abdomen or back.
2. **Blunt pelvic trauma** in association with pelvic fracture or 'minor' trauma in a drunkard patient.
3. **Rapid deceleration injury seat belt injury** with full bladder in the absence of a pelvic fracture (which causes an injury to the breast and the bladder).
4. **Spontaneous rupture after bladder augmentation** we can augment the neurogenic bladder with the intestine patch

### ● Types of Perforation: (mostly extra-peritoneal)

#### Intraperitoneal Perforation

The peritoneum overlying the bladder, has been breached along with the wall the of the bladder, allowing urine to escape into the peritoneal cavity.

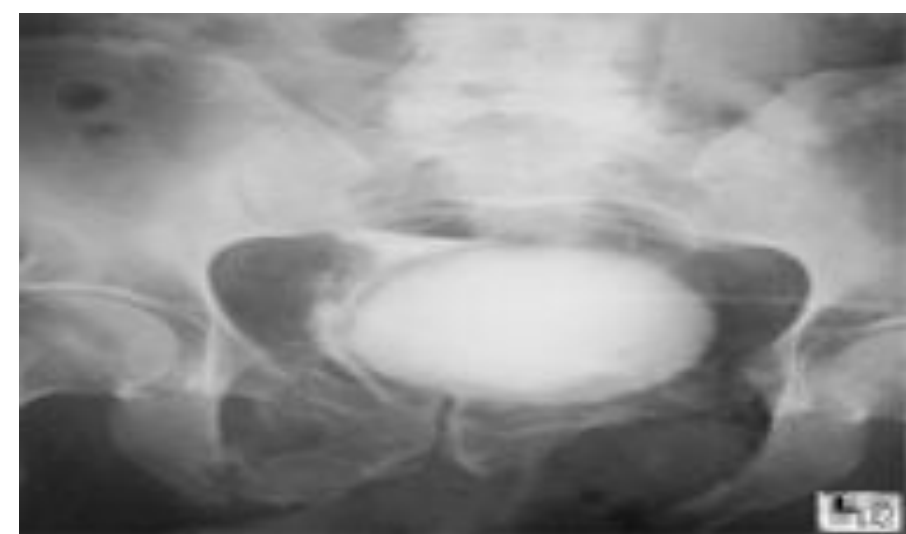
You can see the contrast outside the bladder



#### Extra-peritoneal Perforation

The peritoneum is intact and urine escapes into the space around the bladder, but not into the peritoneal cavity. (more common)

You can only see the contrast inside the bladder



#### Presentation


- Recognized intraoperatively يعني وقت الجراحة
- **The classic triad** of symptoms and signs that are suggestive of a bladder rupture:
  1. Suprapubic pain and tenderness.
  2. Difficulty or inability in passing urine.
  3. Haematuria.

#### Management or Intraperitoneal Perforation

- By **open repair** (justifications):
  - Usually large.
  - Unlikely to heal spontaneously.
  - Leakage causes peritonitis.
  - Other organs are usually injured.

#### Management of Extra-peritoneal Perforation

- **Bladder drainage.** (by foley catheter) ++++
- Open repair (surgery) is rare but only if the injury persistence +



# B. Traumatic Urological Emergencies

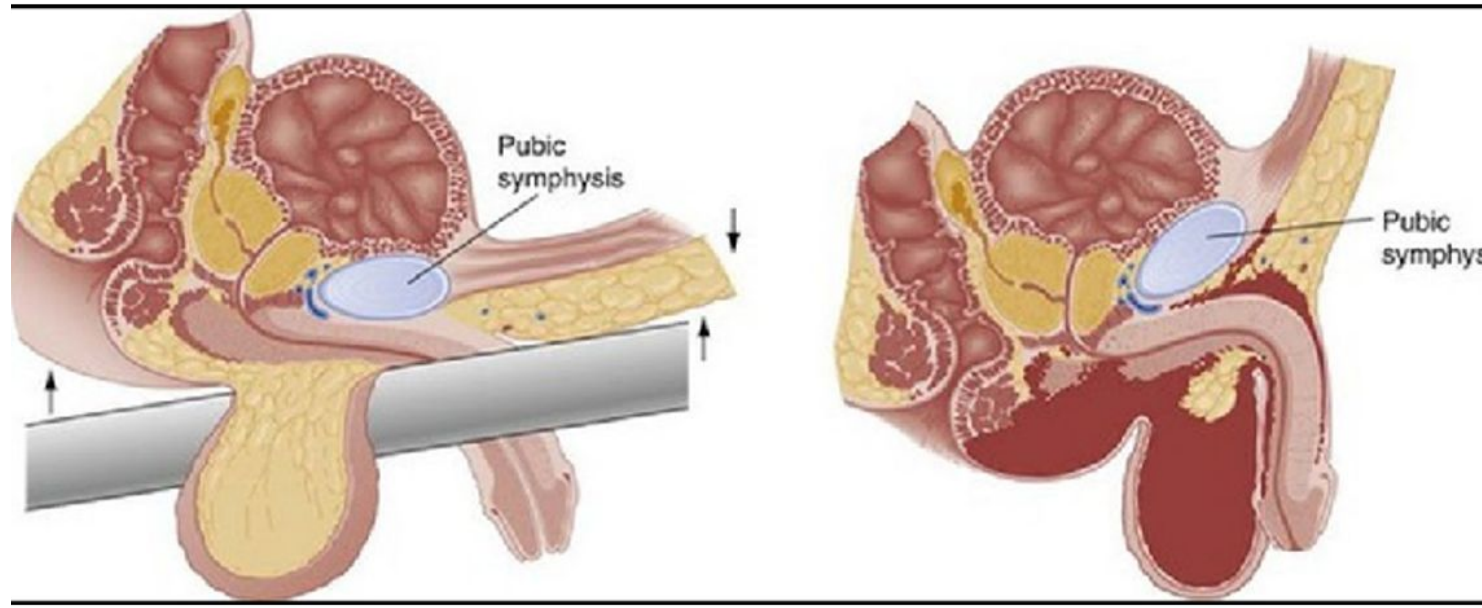
## 4. Urethral Injuries

### Anterior Injury (rare)

- The anterior urethra is outside the pelvic prim (from the external sphincter to the outside).

#### Mechanism:

- Majority are a result of **straddle injury in boys** or men. (jumping while your legs are open → hard object and pelvic bone)
- Direct injuries to the penis.
- Penile fractures.
- Inflating a catheter balloon in the anterior urethra.
- Penetrating injuries by gunshot wounds (rare)

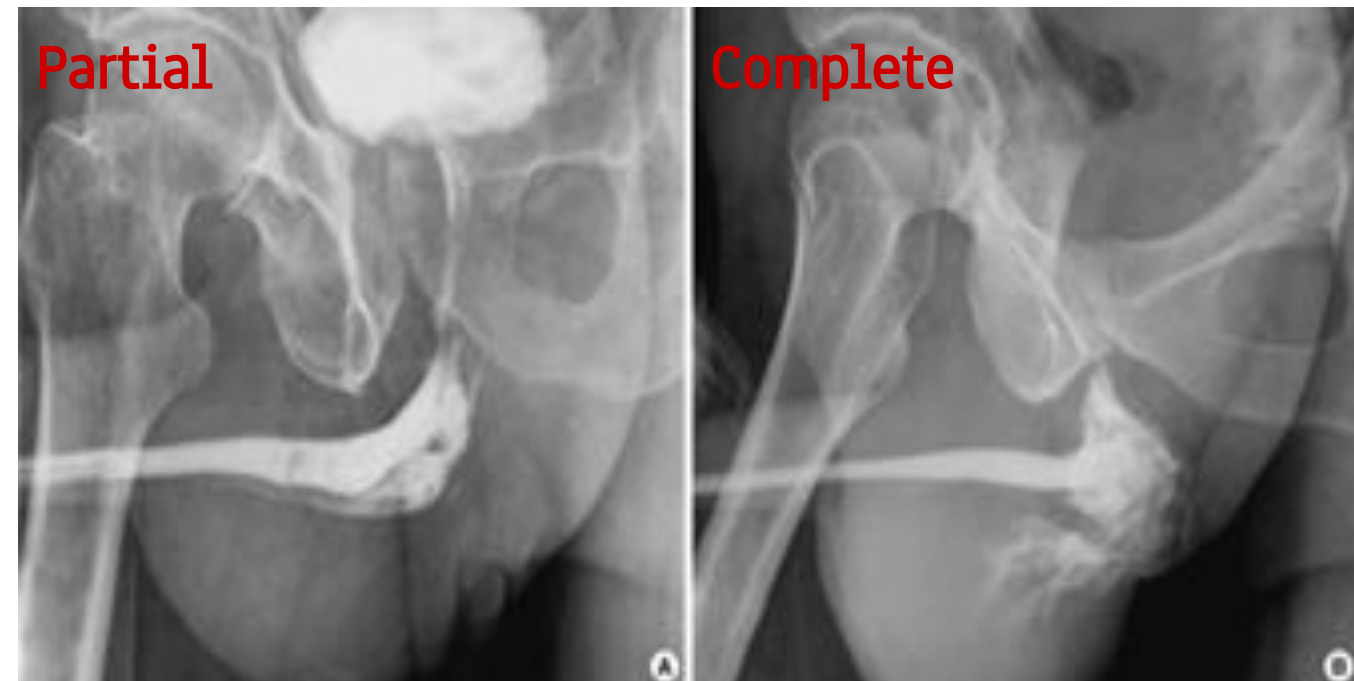

### Posterior Injury (more common)

- The posterior urethra includes the membranous and the prostatic urethra (inside).

- Mostly are associated with **pelvic fractures**. RTA (because the pelvic fractures affect the urethra membranous (حوادث السيارات))

- 10% to 20% have an association with **bladder rupture (on X-Ray it will show Christmas tree appearance)**



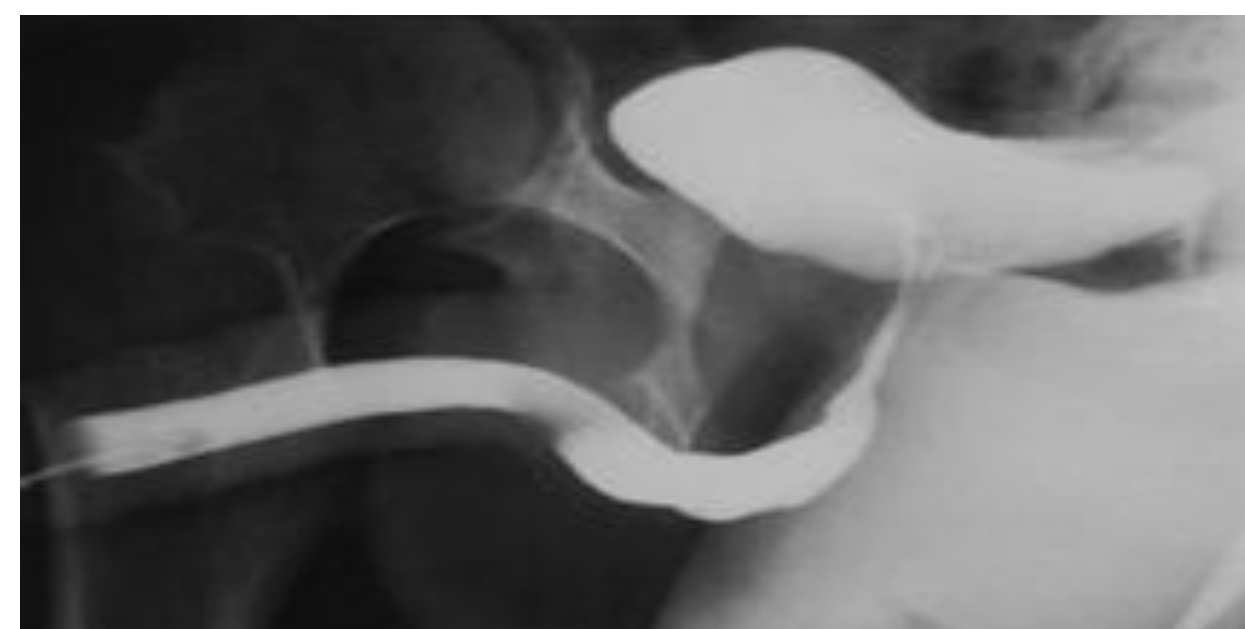
### Signs and symptoms

- **Meatal Bleeding** (Blood at the end of penis). Meatal from external meatus
- Difficulty in passing urine.
- Frank haematuria.
- Hematoma may accumulate around the site of the rupture.
- Swelling of the penis.

- Blood at the meatus, gross hematuria, and perineal or scrotal bruising.
- **High-riding prostate**, when examining by digital rectal exam you can't reach the prostate. (pushed away from your finger)

### Diagnosis of Anterior urethral injury

- ★ The diagnostic tool is Retrograde Urethrography (**ascending urethrogram**):
  - Inject contrast in the urethra
- ★ Less filling means greater damage.
- ★ Contusion: no extravasations of contrast (fluid).
- ★ Partial rupture: extravasations of contrast with contrast present in the bladder.
- ★ Complete disruption: no filling of the posterior urethra or bladder.
  - (contrast won't reach the bladder)

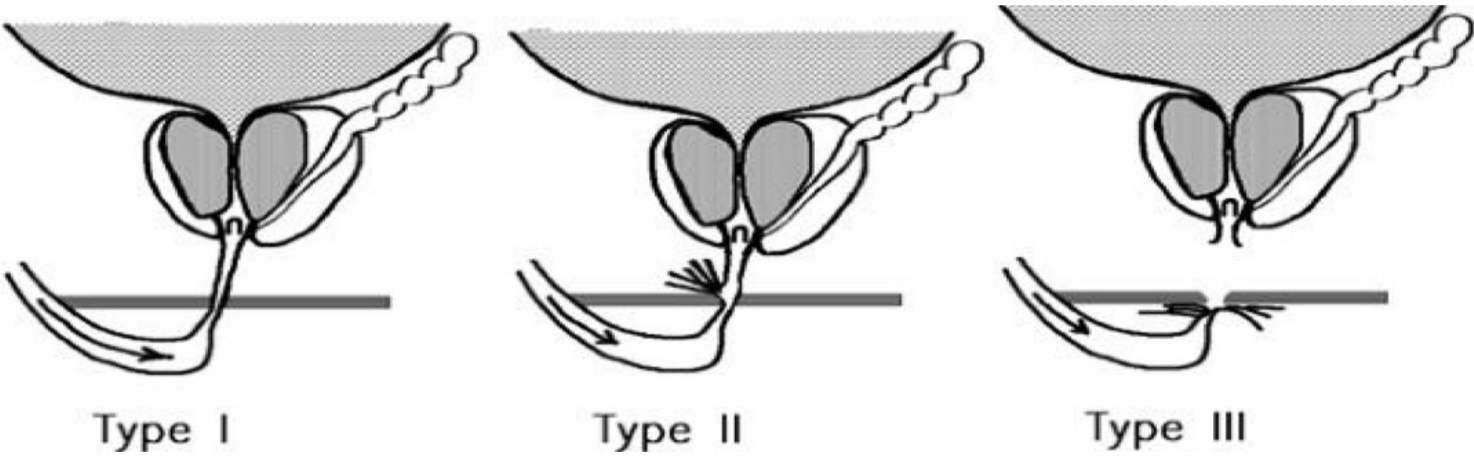




# B. Traumatic Urological Emergencies

## 4. Urethral Injuries

[Click here to see the pictures](#)

Anterior Injury (rare)	Posterior Injury
<p><b>Management:</b></p> <p><b>1. Contusion:</b></p> <ul style="list-style-type: none"><li>- Small-gauge urethral <b>catheter for one week.</b></li></ul> <p><b>2. Partial Rupture of Anterior Urethra:</b></p> <ul style="list-style-type: none"><li>- <b>No blind insertion of urethral catheterization.</b> (may be by using cystoscopy and guide wire)</li><li>- Majority can be managed by <b>suprapubic urinary diversion (catheter) for one week.</b></li><li>- Penetrating partial disruption (e.g., knife, gunshot wound), primary (immediate) repair.</li></ul> <p><b>3. Complete Rupture of Anterior Urethra:</b></p> <ul style="list-style-type: none"><li>- <b>Unstable patient:</b> use a <b>suprapubic catheter.</b></li><li>- <b>Stable patient:</b> the urethra may either be <b>immediately repaired or a suprapubic catheter is placed.</b></li></ul> <p>- <b>Penetrating Anterior Urethral Injuries</b> are generally managed by surgical debridement and repair.</p>	<p><b>Classification:</b></p> <p><b>Type I: (rare)</b></p> <ul style="list-style-type: none"><li>- <b>Stretch</b> injury with <b>intact</b> urethra.</li><li>- <b>Treatment:</b> Stenting with a urethral catheter</li></ul> <p><b>Type II: (25%)</b></p> <ul style="list-style-type: none"><li>- Partial tear but some continuity remains</li><li>- <b>Treatment:</b> Stenting with a urethral catheter.</li></ul> <p><b>Type III: (75%)</b></p> <ul style="list-style-type: none"><li>- Complete tear with no evidence of continuity</li><li>- In <b>women</b>, partial rupture at the anterior position is the most common urethral injury associated with pelvic fracture.</li><li>- <b>Treatment:</b><ul style="list-style-type: none"><li>- Patient is at varying risk of urethral stricture, <b>urinary incontinence, and erectile dysfunction (ED).</b></li><li>- Initial management with suprapubic cystostomy and attempting primary repair at 7 to 10 days after injury.</li></ul></li></ul>  <p>- Posterior urethra is short usually if u see it tall means there is hematoma but still intact which is mean type 1.</p>

## 5. External Genital Injuries

### ★ Male External Genitalia Injuries:

- Penile Fracture, eggplant deformity sign (the injury is mainly in the Corpora spongiosum).
- Glans Injury (especially with circumcision).
- Penile amputation and injuries (Call the security and the psychiatrist because patient could be the one that harmed himself and can also harm others due to some mental illness such as psychosis)
- Scrotal Injuries

### ★ Female External genitalia injuries:

- In sports, crime or during vaginal labour.
- Managed by Gynecologists unless the urethra or the bladder is involved.
- In Road traffic accidents it's extremely rare in female while its very common in males.



# Summary

## Non Traumatic Urological Emergencies

### 1. Hematuria

The most important symptom that needs immediate medical help.

- **Cause vary according to :**
  - Age
  - Painful or painless.
  - Risk factors for malignancy like smoking
  - Types gross of microscopic.
- **Work up :**
  - History more important than PE
  - Physical examination .
- **Investigation:** CT urography which is the gold standard.

### 2. Renal Colic

The most common urological emergency.

- **Investigation:**
  - Pregnancy test.
  - MSU.
  - U&E.
- **Radiological investigations:**
  - KUB
  - RUS
  - IVU
  - MRI
- Helical CT without contrast which is the gold standard.

### 3a. Acute Urinary Retention

- Painful inability to void
- **Initial management:**
  - Give the patient analgesic.
  - Urethral catheterization.
- **Late management:**
  - Treating the underlying cause.

### 3b. Chronic Urinary Retention

- Pain is not a feature and many patient come to ER with renal failure.
- **Management:**
  - Renal support
  - Bladder drainage.
  - Late treatment of the underlying cause.

### 4. Acute Scrotum

- Requires prompt evaluation, differential diagnosis and potentially immediate surgical exploration.
- **Differential diagnosis:**
  - Torsion of the spermatic cord the most serious
  - Epididymitis the most common.
  - Epididymo-orchitis.
  - Hydrocele.
- Torsion of the spermatic cord is common among teenagers 12-18 years
- **Presentation:**
  - Acute onset of scrotal pain.
  - Nausea and vomiting.
  - Children may present with abdomen pain not testicular pain .
- **Physical Examination**
  - Acute swelling and scrotal edema.
  - Absent of Cremasteric reflex.
  - Testis is the larger than other side.
  - Epididymo-orchitis
  - Cremasteric reflex should be present.

### 5. Priapism

- Persistent erection of the penis more than 4 hours not related to sexual desire.
- **Cause:**
  1. Primary: idiopathic 30-50% of the cases.
  2. Secondary: drugs, trauma, neurological and hematological.
- **Types :**
  1. Ischemic, painful is the most common.
  2. Nonischemic painless. The diagnosis usually obvious from the history, duration of erection more than 4 hours.



# Summary

## Traumatic Urological Emergencies

### 1. Renal Trauma

- **Mechanism & Causes:**
  - Blunt trauma, direct blow and road traffic accidents.
  - Penetrating trauma, knives , gunshot and iatrogenic .
- **Radiological image:**
  - IVU only indication is **intraoperative without having CT scan** in case of retroperitoneal hematoma.
  - **CT scan imaging study of choice**, accurate, and rapid.
  - Renal US
- **Management:**
  - Conservative: wide Bore IV line, IV antibiotics, Bed rest , vital signs, serial CBC and HCT and follow up US and CT .
  - Surgical Exploration

### 2. Bladder Injury

- **Causes :**
  - Iatrogenic: TURBT, cystoscopy bladder biopsy, TURP, cystolitholapaxy, caesarean section (most common), total hip replacement.
  - Penetrating trauma
  - Blunt pelvic trauma
  - Rapid deceleration injury.
- **Types of Perforation :**
  - Intraperitoneal perforation.
  - Extra-peritoneal perforation.
- **Presentation: classic triad of symptoms**
  - **Suprapubic pain and tenderness**
  - **Difficulty or inability to pass urine.**
  - **Haematuria.**
- **Extraperitoneal management :**
  - Bladder drainage by Foley catheter
  - Open repair (Surgery).

### 3. Ureteral Injuries

#### Mechanism & Causes:

- External trauma: severe force is required, blunted or penetrating.
- Internal trauma: more common than external, iatrogenic **causes**: hysterectomy, & Caesarean section.

### 4. Anterior Urethral Injury

- **Mechanism:**
  - Majority are a result of straddle injury in boys or men.
  - Penile fractures.
  - Inflating a catheter balloon on the anterior Urethral.
- **Sing and symptom:** meatal bleeding, difficulty in passing urine, frank haematuria.
- **Diagnosis:** retrograde urethrography.
- **Management:**
  - Contusion: small gauge Urethral catheter for one week
  - Partial: rupture of anterior urethra: majority managed by suprapubic urinary diversion
  - Complete: rupture of anterior urethra:
    - Unstable patient : use a suprapubic catheter.
    - Stable patient urethra may be immediate repaired or suprapubic catheter.
  - Penetrating anterior urethral injuries are managed by surgical debridement and repair

### 5. Posterior Urethral Injury

- **Mechanism:**
  - Mostly are associated with pelvic fracture, 10-20% **associated with bladder rupture.**
- **Sing:**
  - High riding prostate when Examining by digital rectal exam.
- **Management:**
  - Type 1: stretch injury with intact urethra and stenting with a Urethral catheter.
  - Type 2: treatment with stenting a Urethral catheter.
  - Type 3: initial management with suprapubic cystostomy and attempting primary repair at 7 to 10 days after injury.

# Quiz

1- A 13-year old boy presented to the Emergency Room with painful right scrotal swelling. It was gradual in onset over the last 5 days. He gave history of dysuria and suprapubic pain for the last 2 weeks. The most common cause of his symptoms is:

- a. Epididymitis
- b. Hydrocele
- c. Testicular Torsion
- d. Testicular Trauma

2- 15-year-old boy presented to emergency department with 4 hours history of sudden onset scrotal pain which excruciating. On local examination he has significant tenderness of the left hemiscrotum with high lying left testis. What will be the most appropriate next step?

- a. Scrotal US with color Doppler study
- b. Radionuclide for the scrotum
- c. Urine analysis
- d. Immediate scrotal exploration

3- 12 years old boy presented to the emergency room with severe sudden testicular pain for 3 hours, with no history of trauma, what is the most likely the diagnosis?

- a. Hydrocele
- b. Testicular Torsion
- c. Tuberculosis epididymitis
- d. Varicocele

4- which one of these is a common cause of ischemic priapism?

- a. sickle cell disease
- b. Idiopathic
- c. Trauma
- d. SLE


5- If the diagnosis is testicular torsion how would you further proceed with your work up?

- a. Take the patient to CT scan
- b. Give the patient analgesia and ask him to return to you in 3 days
- c. Take the patient to OR immediately for surgical exploration
- d. Administer antibiotics as testicular torsion is an infectious emergency

6- Which of the following is an indication for a surgical Intervention in ureteric stones?

- a. Gross hematuria
- b. If the stones is 6 millimeter in diameter
- c. Impaired renal function test due to obstruction
- d. Stone in distal ureter

1:A 2:D 3:B 4:A 5:C 6:C





# Quiz

1. If you see blood at the start of urination the problem is most likely located in?
  - a. Distal urethra
  - b. Posterior urethra
  - c. Upper urethra
  - d. Bladder
2. what is the initial management when renal colic is diagnosed?
  - a. NSAIDs
  - b. IV hydration
  - c. Opiate analgesics
  - d. All the above
3. Which of the following describe this procedure "crashing bladder stones per urethra using a stone punch"
  - a. Ureteroscopy
  - b. Cystolitholapaxy
  - c. Extracorporeal Shock Waves Lithotripsy
  - d. JJ stent

1:A 2:D 3:B

