



Pediatric Inguinal and Scrotal Conditions

Objectives:

1. Introduction.
2. Embryology
3. Inguinal hernia.
4. Hydrocele.
5. Undescended testis.
6. Acute scrotum.

 Team leaders: Alanoud Almansour, Ghaida Al Musma , Moath Alhamoud and Mohammed Alqwaifli

 Done by: Lama Alotaibi, Lojain Aziz Alrahman, Hosam Alruwaite, Hamdan Aldossere

 Revised by: Yazeed Al-Dossare

Color Index:

 Important

 Doctor's Notes

 Extra

 Davidson's

[Editing File](#) / [Feedback](#)



Extra:

❖ Inguinal canal:

-The inguinal canal is a passage through the lower abdominal wall.

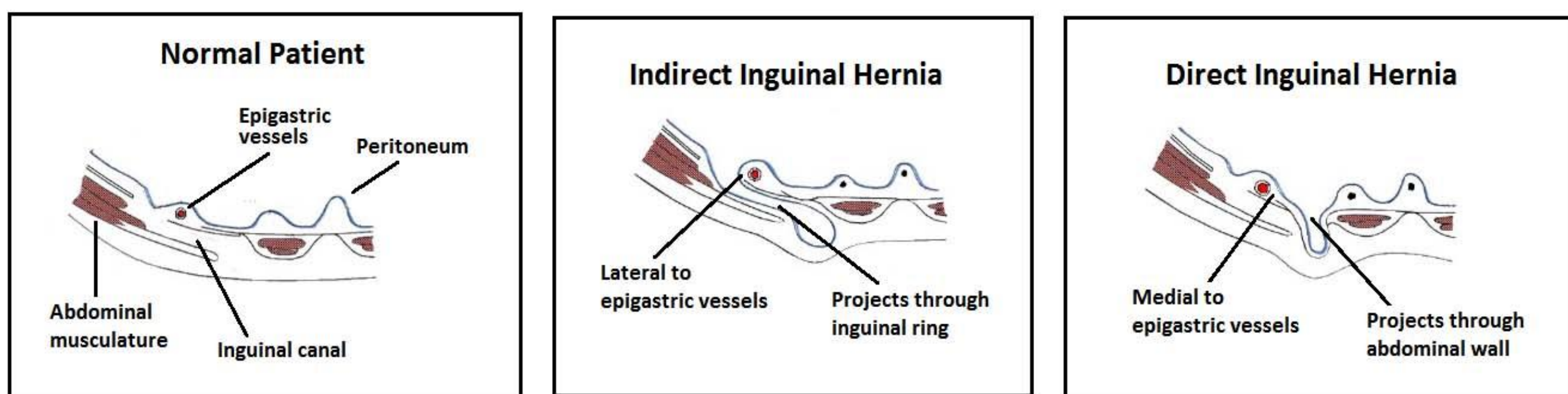
In males, the spermatic cords pass through the inguinal canals and connect to the testicles in the scrotum. The spermatic cords contain blood vessels, nerves and the spermatic duct.

In females, the round ligament pass through the inguinal canals.

-It extends from the deep inguinal ring which is the connection between peritoneal cavity and the groin to the external ring.

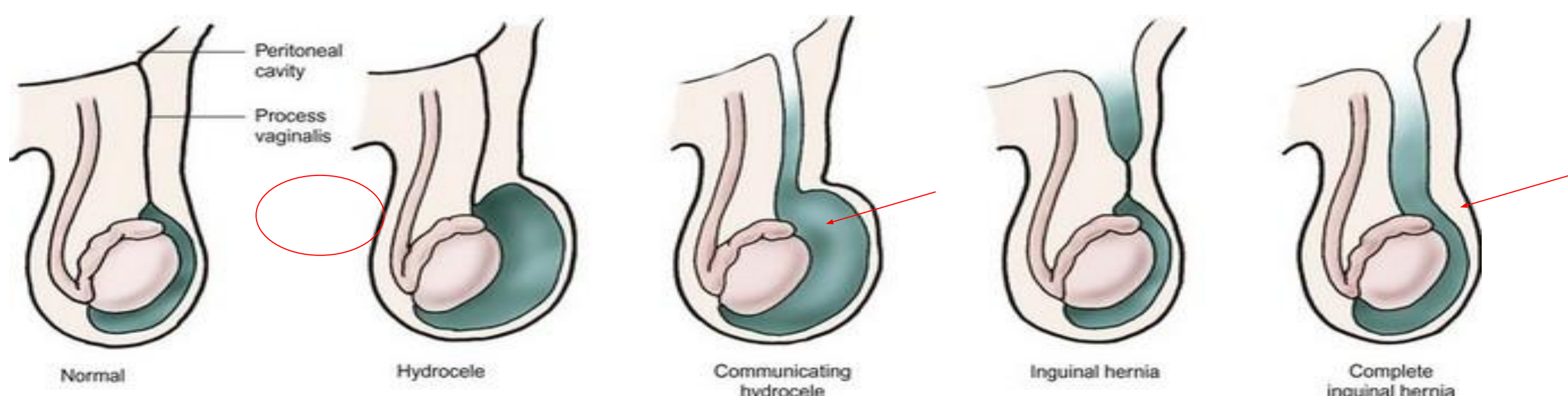-Position of the epigastric vessels is the landmark to differentiate between direct and indirect inguinal hernia.

- The deep ring is **lateral** to the inferior epigastric vessels this indicates an **indirect** inguinal hernia.
- If it's bulged to the **medial** to the inferior epigastric vessels then it's **direct**.



Adapted, with permission, from <http://www.dartmouth.edu/~humananatomy/>

- **Hernia** is the protrusion of an organ or the fascia of an organ through the wall of the cavity that normally contains it.
- **Inguinal hernia:** extension of the peritoneum (and usually its contents-small intestine) through the inguinal canal.
- **It has two subtypes:**
 1. **Indirect:** infantile form, more common, follows the tract through the inguinal canal.
 2. **Direct:** adult form, is caused by a weakness in the muscles of the abdominal wall that develops over time.



Closed processus vaginalis, which is coming out from the abdominal cavity

Patent processus vaginalis, but the calibre is **narrow**, which will allow **only fluid** to come down from the abdominal cavity to the tunica vaginalis (space around the testis) then this will lead to **hydrocele**

Patent processus vaginalis, but the calibre is **wide**, which will allow **the abdominal viscera (bowel, ovaries, fallopian tubes)** to come out from it this will lead to **hernia (indirect type)**



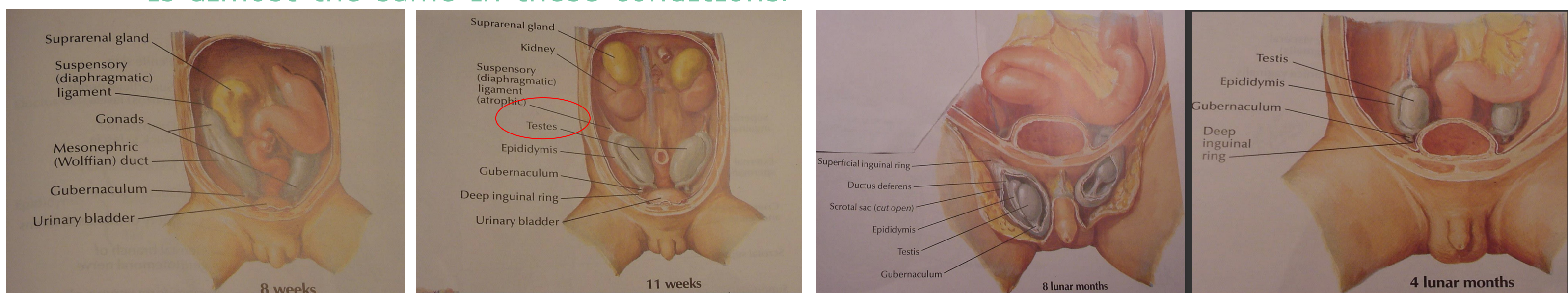
Groin Hernias - Embryology & Anatomy

- The processus vaginalis is present in the developing fetus at 12 weeks in utero.
- The processus is a peritoneal diverticulum that extends through the external inguinal ring
- As the testis descends at the 7th to 8th month, a portion of the processus attaches to the testis, as it exits the abdomen and is dragged into the scrotum with the testis

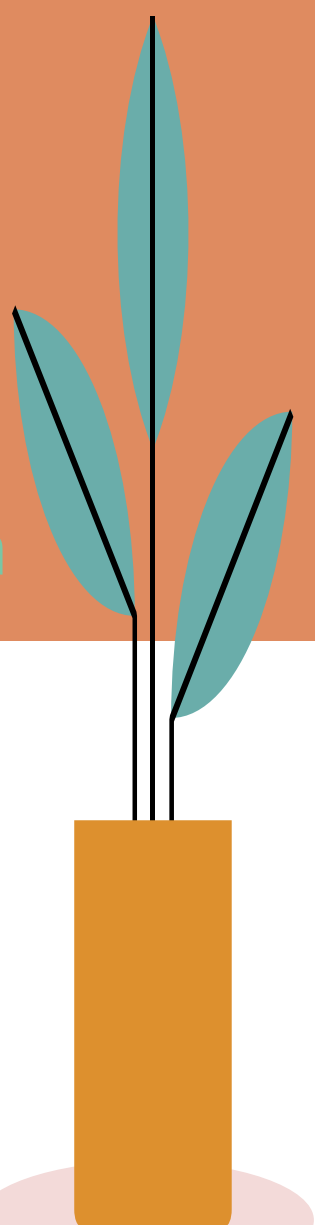
useful video

What if Processus Vaginalis persists?

- Inguinal hernia (PV is wide allowing bowel to descend)
 - 90% of undescended testes cause hernia.
 - because undescended testes prevent PV from obliteration leading to hernia.
- Hydrocele (PV is thin allowing only the fluid to descend).
- **notes:** This lecture is **very important**, the doctor mentioned every word he is saying might come in the **MCQ or OSCE**.
- This topic is important because most of what pediatric surgeons see in their practice
- is related to inguinoscrotal pathologies.
- The commonest inguinoscrotal pathologies is: **inguinal hernia and hydrocele (both are common)**
- **Undescended testis is (rare)**
- **Q: what is the commonest hernia that might affect children? Umbilical hernia, not inguinal hernia.** the cause is failure of migration and meeting up of abdominal wall folds.
- The etiology for hernia and hydrocele is the same, it is congenital in nature. Congenital means: the baby is born with it, whether it is discovered right away after birth or later in life.
- Specific etiology is processus vaginalis which is peritoneal extension from the abdominal cavity, so it is a peritoneum that migrated outside the abdominal cavity into the groin region, that is what we call processus vaginalis. **The normal fate of processus vaginalis is to close off at birth on full term babies.** We do not expect the processus vaginalis to be closed off in premature babies. Ex baby in 28 week the process vaginalis must be patent. **Preterm babies are at high risk and have higher incidence for inguinal hernia, undescended testis and hydrocele.** Because the etiology is almost the same in these conditions.



*This diagram to show that the testis is coming out from the abdomen (retroperitoneum.) The journey of the testis will go down and find it way out of the abdominal cavity through the inguinal canal out of the external ring all the way down to the base of scrotum (this is the normal pathway for testicular descent) remember it! Because any arrest in the descent process at any level here is called true undescended testis. Any arrest in the migration of testis to the scrotum outside that pathway is called ectopic testis
Ectopic = organ present at abnormal location



INGUINAL HERNIA

❖ **Definition:** it's an indirect hernia related to failure of closure of the patent processus vaginalis (PPV) at the deep inguinal ring.

- Intra-abdominal contents pass within the PPV, through:

-the deep inguinal ring, inguinal canal, superficial inguinal ring and potentially into the scrotum (male).

-the canal of Nuck to the labium (female).

-Congenital (PPV)

-Prevalence (1-5% boys). Common in the United states

-Premature (30%). Higher incidence in preterm babies

-Male/Female (4-8:1). Males are affected more because of migration of the testis from the abdominal cavity

to the scrotum later in pregnancy

-Indirect (99%).

-Right > Left. (In boys, right sided IH is found in 60% ,left sided in 30% and bilateral in 10%. May be because the PV closes earlier in the left side. In girls, 50-50% chance of developing it right or left).

*There are two types of inguinal hernia in general based on the is the anatomical landmark : **the inferior epigastric vessels.**

The types are:

1- direct type : Any defect or herniation medial to the inferior epigastric vessels toward the midline = direct type = rare in children

2- indirect type: the defect or herniation lateral to inferior epigastric vessels, through the deep inguinal ring, travel through inguinal canal, comes out the external inguinal ring all the way out to the external genitalia whether it is the scrotum or labia majora = **common in children**

❖ Associated symptoms:

Might accompany inguinal hernia, but it is rare. most of the time we see a healthy kid with inguinal or scrotal bulge

- Cystic Fibrosis
- Connective tissue disorders
- Ehlers-Danlos syndrome
- Hunter-Hurler syndrome
- Developmental dysplasia

of the hip (DDH)

❖ History :

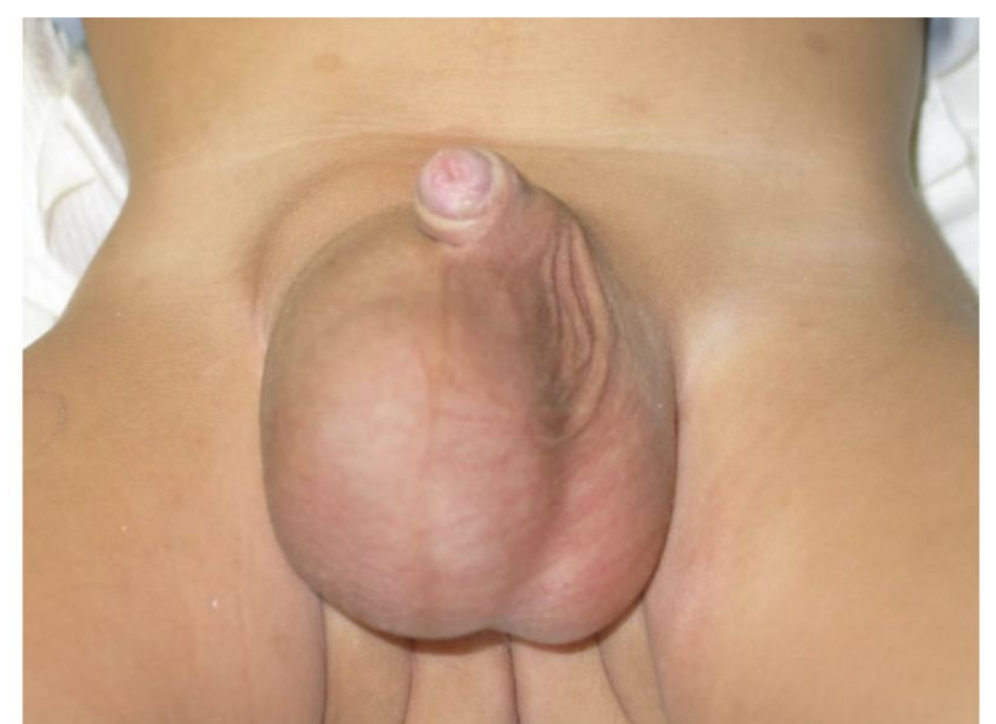
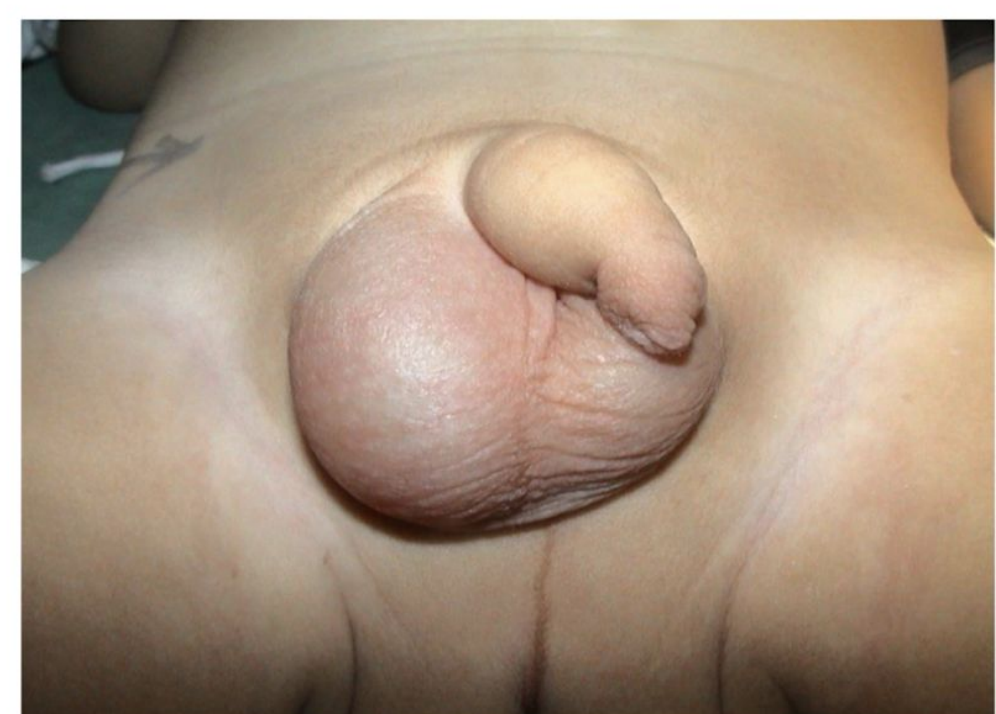How do they present? **Groin (inguinal) bulge** not scrotal bulge. If the hernia is large enough it will extend to the scrotum.

- Intermittent groin swelling.
- Asymptomatic until gets complicated.
- In girls, lump in upper part of labia majora.

❖ Examination :

- Examine the testes.
- **Reducibility.** (This is the most important examination) Any reducible lump in medicine it is hernia until proven otherwise
- **Thickened spermatic cord.** Might come in MCQ!

- Chronic peritoneal dialysis
- Preterm infants with intraventricular hemorrhage
- Myelomeningocele with VP-shunt
- Undescended testis



If you felt the groin area and rub your finger against the spermatic cord in children or babies with early subclinical inguinal hernia you will have thick spermatic cord (**silk glove sign**), the thickened hernia sac is rubbed against other the structures in the spermatic cord mainly (spermatic vessels and vas deferens),so any thickening in the groin region when you rub your finger against the cord, might indicate that the kid is having inguinal hernia or hydrocele but more specific for inguinal hernia

Might come as an **OSCE station:**

- 1-**Describe** it: " He is having a right scrotal swelling"
- 2- What is the **differential** diagnosis in children?
Right hydrocele - Right indirect inguinal hernia (don't forget to mention the laterality)

Complicated inguinal hernia (complications):

Complications from leaving the inguinal hernia unfixed. Uncomplicated hernia usually the lump is reducible.

1. Incarcerated hernia: Incarceration will result in bowel obstruction and if not treated will progress to strangulation (bowel ischemia).

- Irreducible swelling

- No evidence of bowel obstruction or strangulation Incarcerated in a space (confined), not moving anywhere

The kid is going to be healthy, not much pain or systemic symptoms or sign suggestive of other complications

2. Obstructed hernia: The kid is having bowel obstruction

-Irreducible swelling

- Symptoms and signs of bowel obstruction (bilious vomiting (green vomit), abdominal distention and pain, constipation not able to pass neither stool nor flatus) green vomit is bad in children, it means that the kid is having surgical disease until proven otherwise

3. Strangulated hernia: most serious, It means that there is ischemia (necrotic process) to the hernia content, and it's very rare in children.

-Irreducible swelling And it is very painful

-Symptoms and signs of strangulation (severe groin pain, fever, tachycardia, skin discoloration of the groin (dark pigmented overlying skin))

-It is life threatening and requires immediate surgery.

*Younger kids will express pain with excessive crying, irritability, lethargy, really sick, lump is tender.

*Tachycardia is always something serious especially in children

Management:

Herniotomy (as soon as it is feasible)

In boys leaving the hernia might lead to testicular atrophy from the external compression on the spermatic vessels from the hernia in the groin.

1. Incarcerated hernia

+/-Sedation and analgesia

Manual Reduction

Urgent couple of days herniotomy

In uncomplicated hernia elective or semi elective inguinal herniotomy within couple of weeks from diagnosis

2. Strangulated hernia

Emergent couple of hours herniotomy

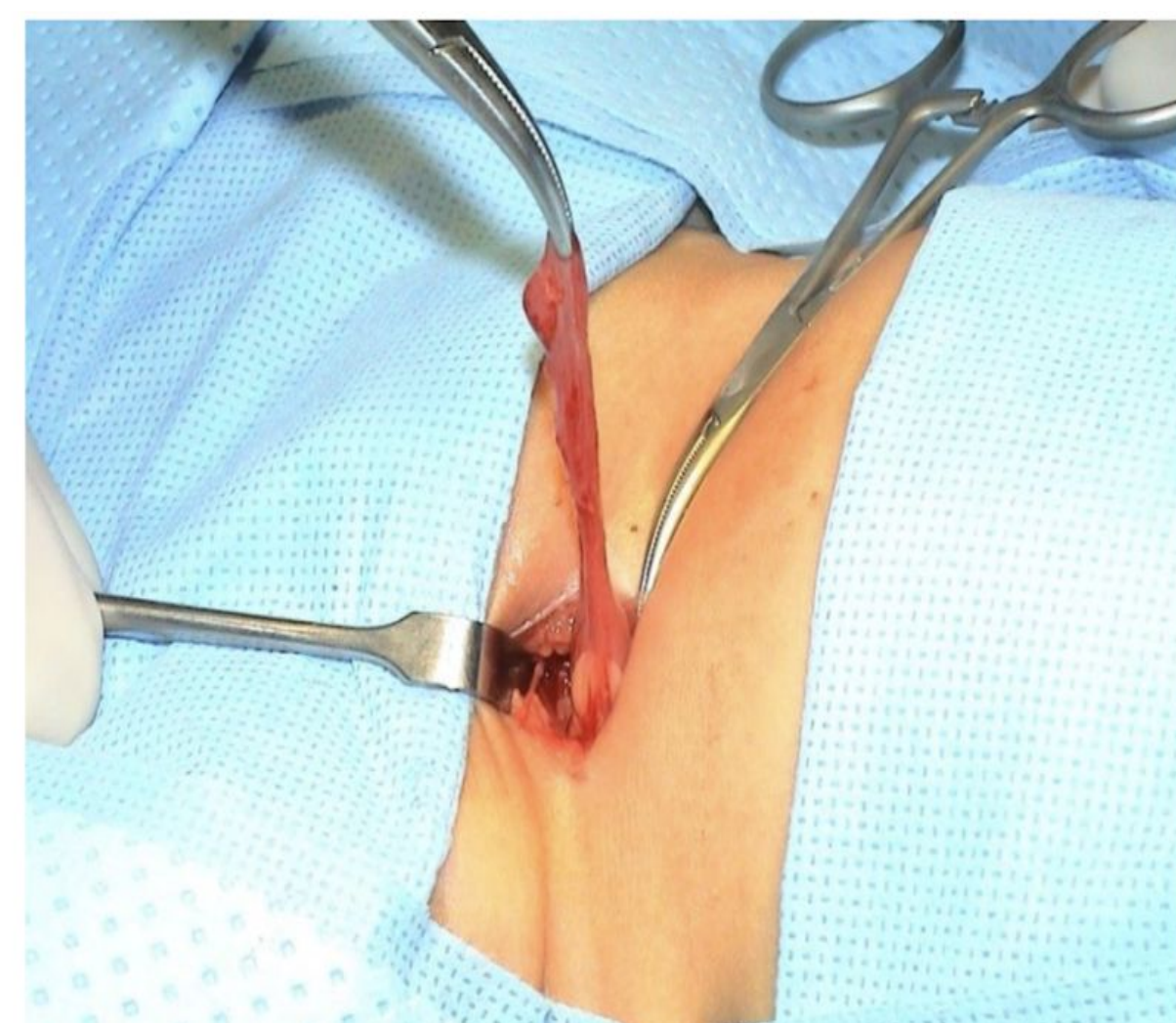
+/- bowel resection

You fix hernia by high ligation of the hernia sac or the patent processus vaginalis in hydrocele cases at the level of the deep inguinal ring (**herniotomy**) not like adult (herniorrhaphy \ hernioplasty)

Any acute surgical condition you have to go through ABC, mainly (c) which is circulation, fluid for resuscitation , NG tube to decompress stomach, give IV antibiotic, insert foley catheter.

Risk Factors:

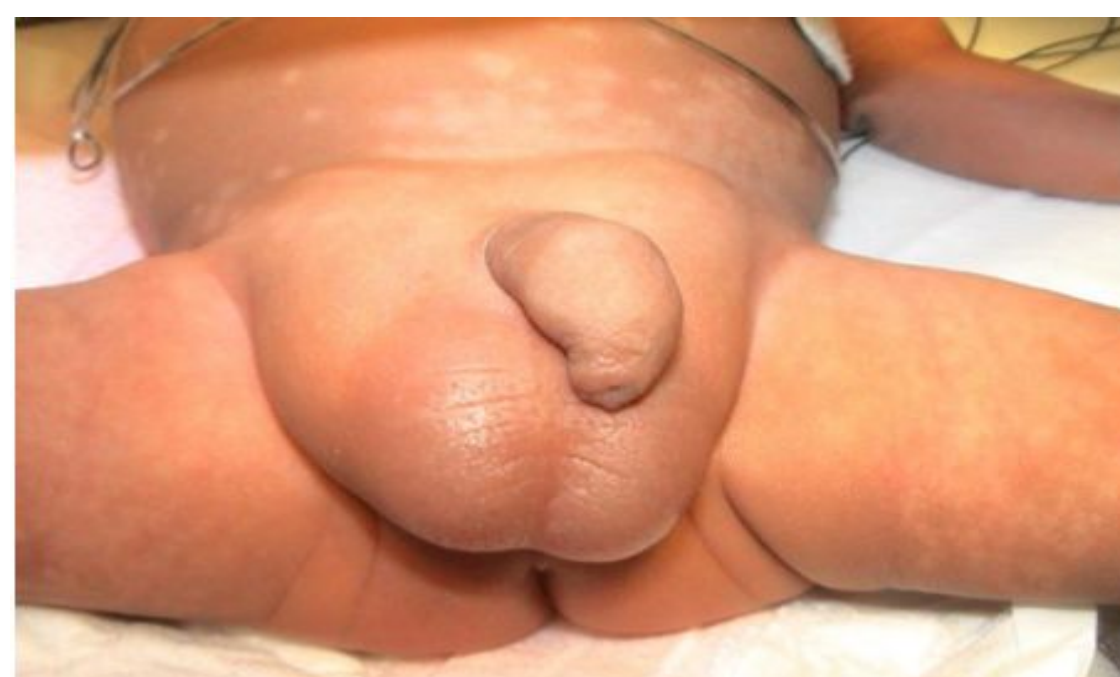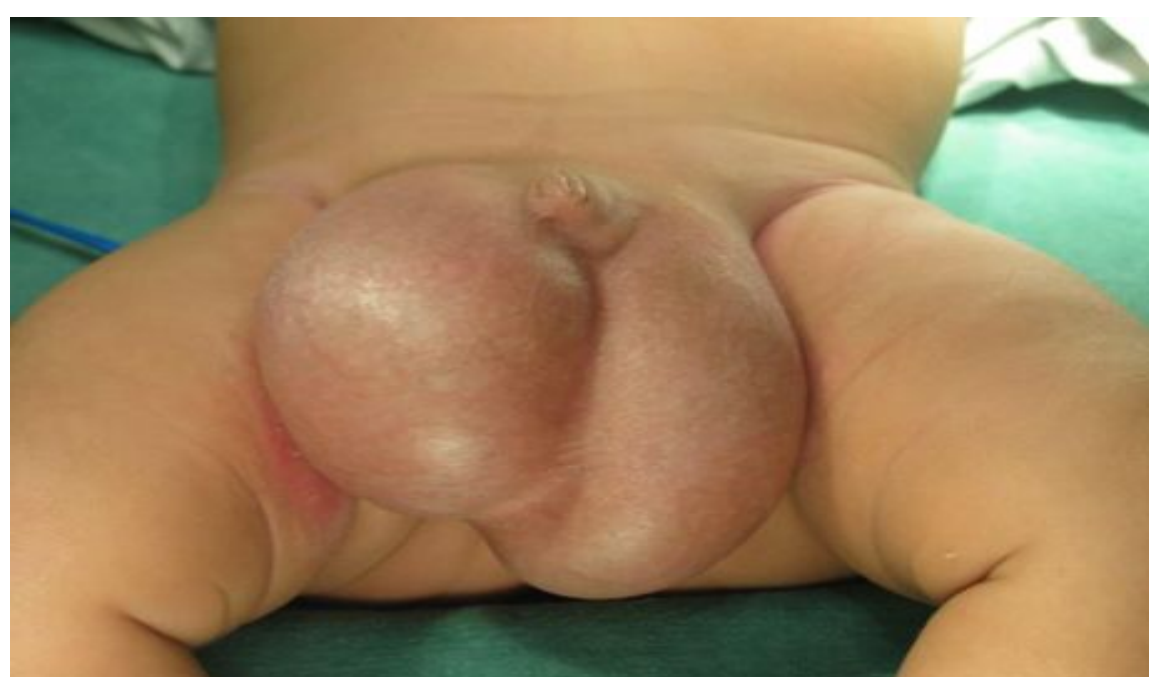- Prematurity.
- Connective tissue disorders.
- Ventriculoperitoneal shunt (VP shunt).
- Peritoneal dialysis (PD). Pediatric patients with chronic renal failure (because fluid accumulates in the abdomen).
- Ascites (any conditions cause increase intra-abdominal pressure).
- Undescended testis. Will have a high chance to get hernia (90%).
- Others.



❖ Management in detail:

Regular uncomplicated IH	Incarcerated IH
<ul style="list-style-type: none"> ● surgery is the only treatment. ● Open inguinal herniotomy (more common approach). ● Laparoscopic herniotomy (less popular) ● Preterm babies usually have their hernias repaired before discharge from nursery to avoid incarceration because they have higher chance. ● Infants & children less than 6 months should have their surgery done within weeks (OR availability). 	<ul style="list-style-type: none"> ● The presence of peritonitis or septic shock is an absolute contraindication to attempted reduction. Because septic shock means that the bowel is already dead and you don't reduce dead tissues. ● If the patient does not have septic shock, intravenous access and rehydration are initiated. Along with monitored conscious sedation (with Morphine or Pethidine). ● Firm and continuous pressure is applied around the incarceration. ● Successful reduction is usually confirmed by sudden pop of contents back to abdominal cavity. ● Over 90-95% of incarcerated IH can be successfully reduced. ● Once hernia is reduced, a delay of 24-48h is allowed before herniotomy (resolution of edema & inflammation). ● Urgent operation (Herniotomy) is necessary if reduction fails. Pt. could develop ischemia (ischemic bowel) if not treated immediately.

How to differentiate between inguinal hernia and hydrocele	
Hydrocele	Inguinal hernia
Asymptomatic	May have excessive crying, irritability, pain
swelling is primarily scrotal	Primarily inguinal swelling may extend all the way to the scrotum
You can get above the swelling (your index and thumb can meet up above the lumb you are examining)	You cannot get above it, because the swelling extending all the way up to the abdominal cavity
Cannot reduce it	Reducible (important) (except in complicated inguinal hernia cases)
Positive transillumination test	Negative transillumination test
testis is not felt	You may feel the testis easily separate from the hernia or swelling




Congenital Hydrocele

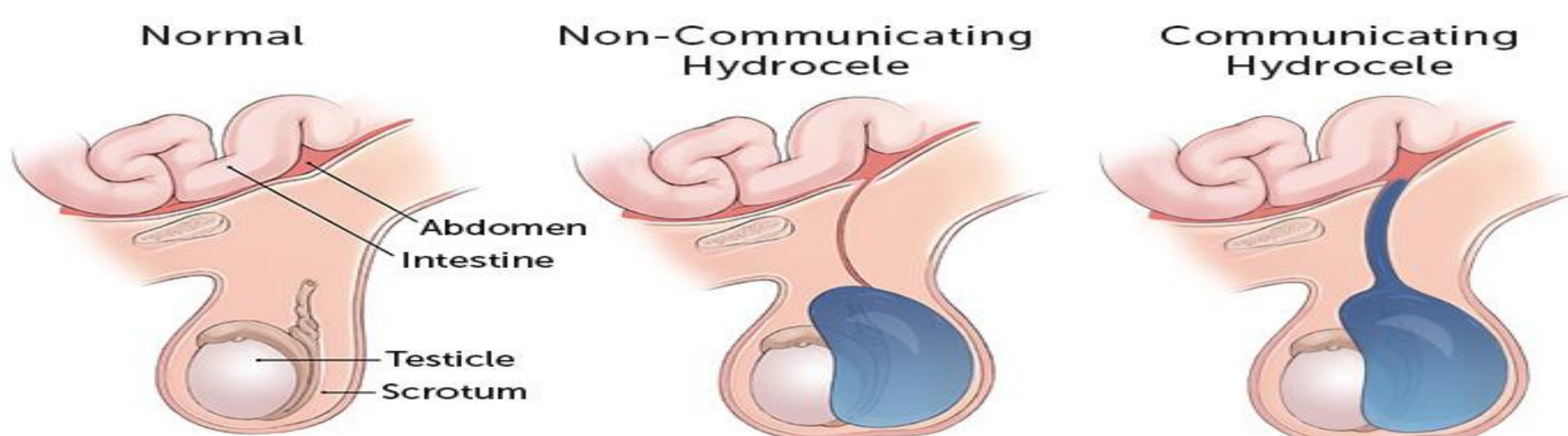
It's an abnormal collection of fluid in the processus vaginalis which fails to obliterate resulting in swelling in the scrotum and groin, mostly scrotum.

- Approximately 5% of boys have hydrocele at term.
- Differs from adult hydrocele which is more likely due to infection (epididymo-orchitis, TB), malignancy or idiopathic.

*Complications is rare in hydrocele unlike hernia, example of complications: infection or trauma (will lead to hematocele), if it is very big the mother will have difficulties in cleaning the perineum area, irritation of the adjacent skin which will lead to contact dermatitis.

<p>History</p>	<ul style="list-style-type: none"> • Scrotal swelling. • Asymptomatic. • 1% over one year of age 	
<p>Examination</p>	<ul style="list-style-type: none"> • Not reducible (most accurate) • You can get above the swelling (your fingers touch). • ++ Transillumination. • In hydrocele the child is not irritable or in pain. 	
<p>Management</p>	<ul style="list-style-type: none"> • Expectant management (observation) in the first <u>two</u> years of age. • By the age of 2 years 90% of hydrocele will have resolved. The fluid will be absorbed spontaneously • Surgery (hydrocelectomy/high ligation of PPV) (high ligation of the patent processus vaginalis at the level of the deep inguinal ring + aspiration of the fluid out of tunica vaginalis through groin incision) is indicated if the hydrocele fails to resolve by age of 2 years. 	

2. Non-communicating hydrocele or Hydrocele of tunica vaginalis: the fluid stays around the testicles.
3. Hydrocele of the spermatic cord: the fluid is located in the spermatic cord between the scrotum and the abdomen.



Descent of Testis - 2 Phases

- 10-15th week: the gubernaculum enlarges to anchor the testis near the inguinal region as the embryo enlarges
- 28-35th week: the gubernaculum migrates out of the inguinal canal across the pubic region and into the scrotum *If you do not feel the testis in a baby who is 28 week then that is normal*
- The processus vaginalis develops as a peritoneal diverticulum within the elongating gubernaculum, creating an intraperitoneal space into which the testis can descend

Embryology:

- Normal testes develop in the posterior abdominal wall from gonado-nephric ridge.
- Normal pathway for descending: abdominal wall > deep inguinal ring > inguinal canal > superficial inguinal ring > scrotum.
- Normal testes descend across the abdomen to deep inguinal ring between 8-15 weeks of gestation under control of AMH.
- Second phase of descent, the testes move through the inguinal canal into the scrotum (25-35 weeks of gestation) under control of androgens (testosterone).
- The gubernaculum guides the descent of the gonads.

UNDESCENDED TESTIS

Definitions:

★ **Undescended testis (UDT):** The testis is arrested along its normal path of descent.

★ **Retractile testes** (normal physiological phenomenon in 20% of pediatric): A testicle that may move back and forth between the scrotum and the groin. Can be manipulated into scrotum where it remains without tension. (due to strong cremasteric reflex, it persists up to age of 5-6 ys then it resolves by itself).

★ **Ectopic testis** (rare): is located outside of normal path of descent (it passes through the normal channel, but does not go to the scrotum). most common site: superficial inguinal pouch (above the superficial inguinal ring).

Incidence:

At birth: 3-4%, at one year: 1%, pre-term: 30%.

Photo in OSCE or MCQ:

What is this finding? Empty left hemiscrotum

*What is your differential diagnosis for empty hemiscrotum? **Retractile testis (very common in boys at age of 2 years mostly)**, due to hyperactive cremaster muscle in children > contract alot > pull up the testis, once the muscle relax the testis will go down*

In order to diagnose someone with retractile testis they have to fulfil three criteria:

1-The testis has to be down in the scrotum at birth (the physician who delivered the baby will tell you that the testis was down in the scrotum \ the mother have seen the testis down in the scrotum)

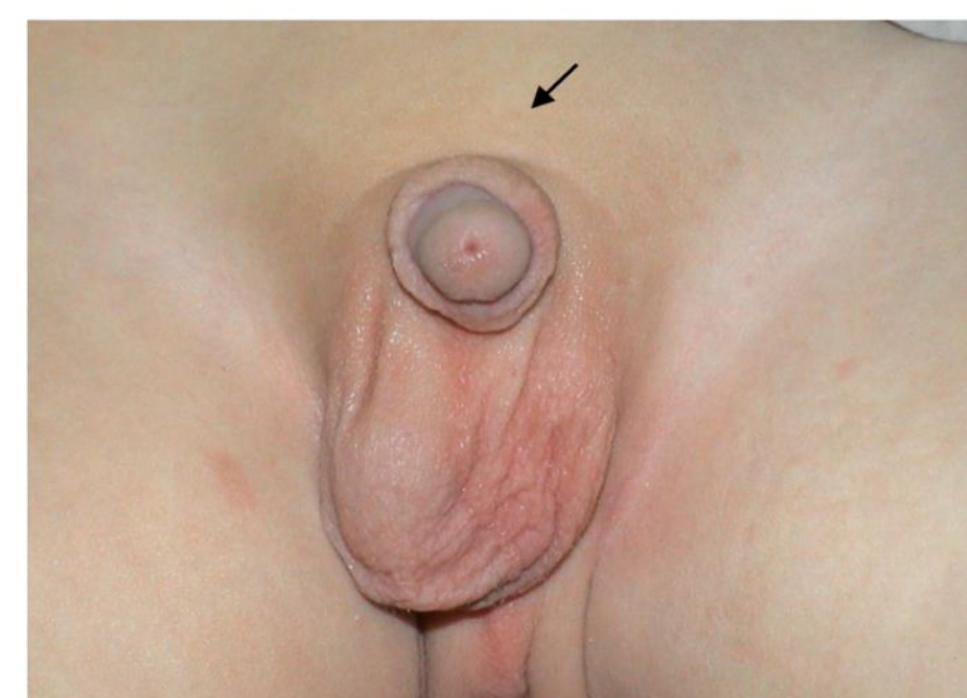2- When you try to manipulate the testis, you will be able to easily manipulate it all the way down to the scrotum

3- Once you manipulated it down to the base of the scrotum it will not rebound up immediately, it will stay in the scrotum for a while

Management? Since it is a normal physiology, reassuring the mother + periodic follow up every year or two years

*If in the question it was written that **the testis was not present at birth ? the main differential for empty scrotum is true undescended testis**, but it could be ectopic testis, testicular agenesis, vanished testis (testicular torsion in utero, lead to absorption of the testis and disappearance of testicular tissue). If it was not mentioned in the question that the testis is not present at birth then the top DDX is retractile testis*

Palpable 80%



Empty left hemiscrotum

Non palpable 20%



Empty scrotum

UNDESCENDED TESTIS

Clinical presentation:

- Empty scrotum.
- Absence of one or both testes.
- Swelling in the groin (testis or hernia).
- On examination, hemi-scrotum is underdeveloped/hypoplastic.
- Testis is palpable in the groin (inguinal canal) and fails to come down to scrotum in 80% of cases.
- Testis is impalpable/non-palpable in the remaining 20% of cases (intra-abdominal, atrophied or agenesis). If we say the testis is impalpable, we mean that we searched in all the areas that could have ectopic testis.

Diagnosis:

- Parents/Doctors
- Clinical features
 - Empty scrotum
 - Palpable or not
 - Milk it down to scrotum
- Imaging? (limited role)
- Laparoscopy
 - Diagnostic
 - Therapeutic

You don't want to do the surgery earlier in life because there is a chance of spontaneous descent of testis in scrotum, and you don't want to do it later in life because this may affect the functional outcome (**fertility and cancer risk**), our main aim from surgical intervention is to increase fertility rate and minimize cancer risk in addition to cosmetic and psychosocial aspects and higher risk of testicular torsions and testicular trauma if testis is not in normal location.

Q: which undescended testis has the worst prognosis in terms of cancer and fertility? High bilateral intra abdominal testis

Indications:

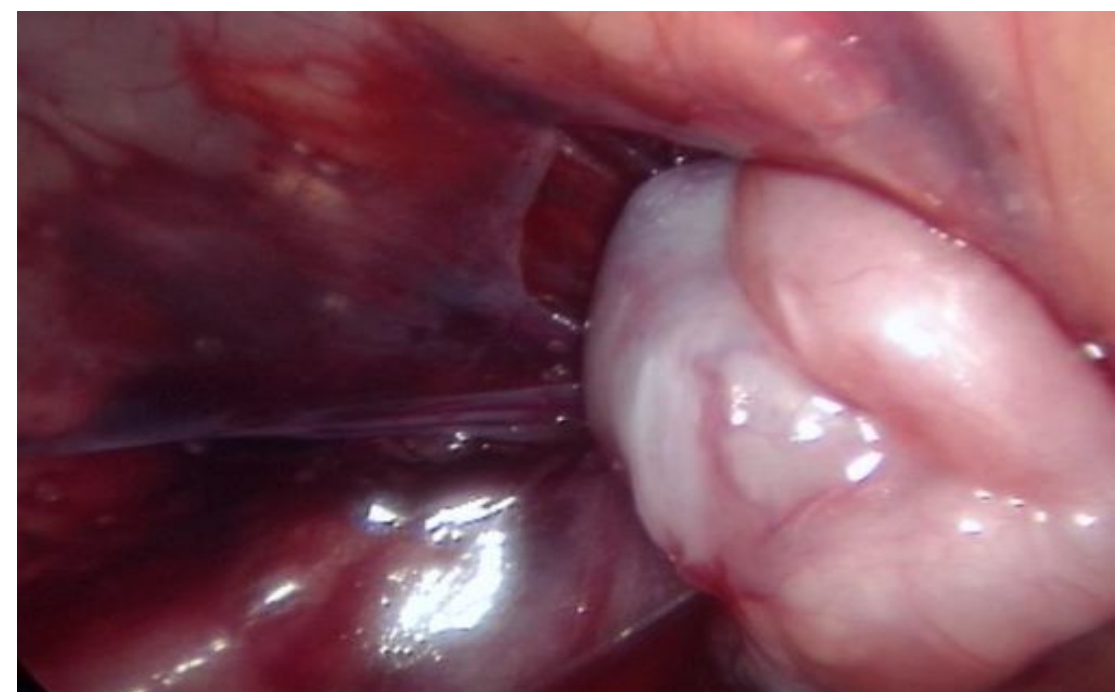
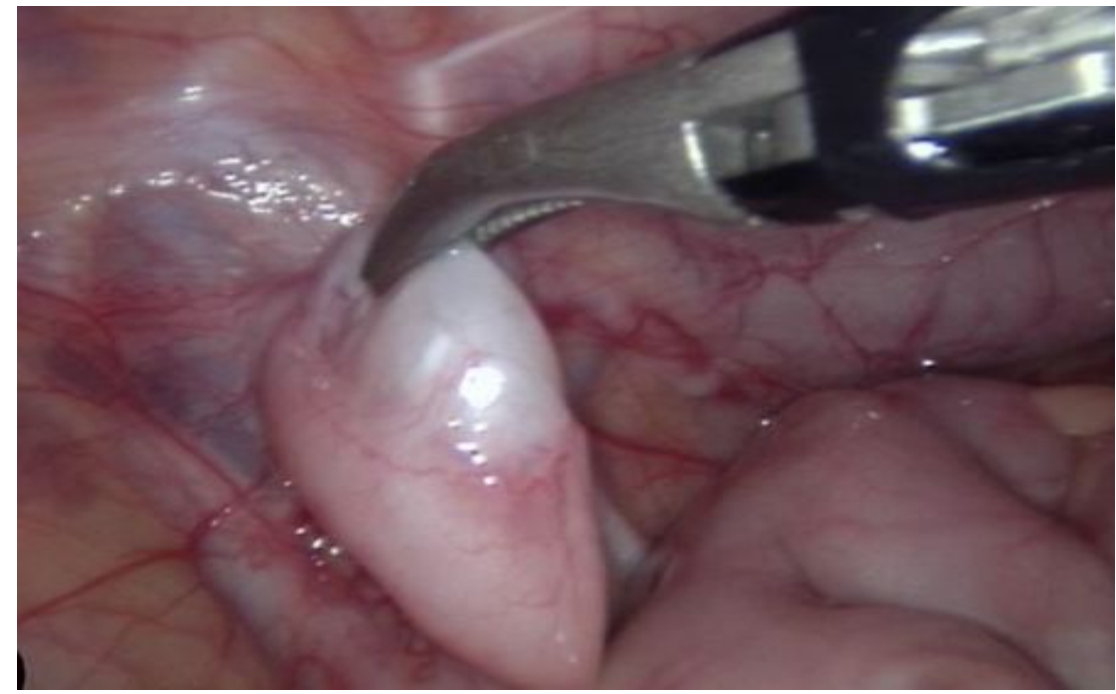
- Abnormal fertility
- Testicular tumor
- Cosmetic/Social
- Trauma/Torsion

Treatment (6 months-1 year):

Palpable - open orchiopexy

Nonpalpable - Laparoscopy assisted orchiopexy

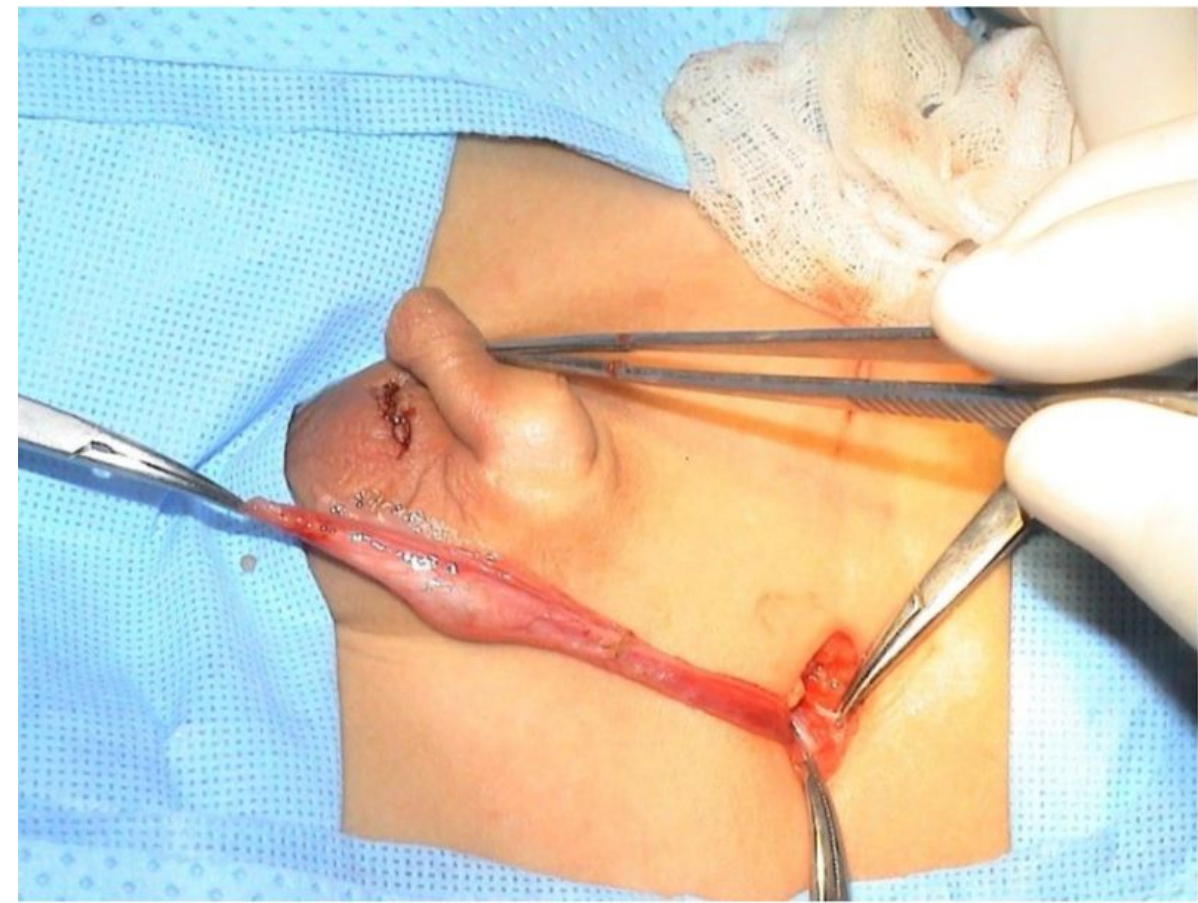
-Two stages Fowler- Stephens orchiopexy



Investigation of someone with empty scrotum?

1- US of the groin and scrotum

2- Hormonal test: beta hCG, particularly if we are dealing with bilateral undescended testis and external genital anomalies (ex. hypospadias and bilateral undescended testis), to make sure that the testis is present somewhere in the body, whether inside the abdomen or the groin.



Palpable =you can feel the testis somewhere in the groin region or scrotum

Non Palpable =you don't feel the testis in the region, so the next step in management is **laparoscopy**, you stick a scope in the abdominal cavity

If the testis is high up (high intra abdominal), you use two stage laparoscopy orchiopexy. The period between the two stages is 3 to 6 months.

1st stage: divide main blood supply to the testis (testicular vessels)

2nd stage: completion orchiopexy

Management

- Hormonal treatment: useless, and if you want to give hormones you only give it to a patient below 6 months old.
- ◆ The role of hormonal therapy is controversial.
- ◆ LHRH and HCG are used with varying degrees of success.
- Surgical treatment (orchidopexy) the treatment of choice.
- The best timing is between 6-12 months of age (because before 6ms Technical surgical problems) the tiny structures might be damaged during surgery and not after 12ms b/c the testes might be damaged under high temperature of inguinal canal > cause infertility and hormonal deficiency).
- Palpable unilateral or bilateral → orchidopexy.
- Impalpable/ nonpalpable:
 - Radiographic imaging (US,CT,MRI) not accurate. is rarely helpful in locating nonpalpable testis.
 - Diagnostic laparoscopy (the best diagnostic and therapeutic method) is the preferred approach
- If testis is intra-abdominal → Laparoscopic assisted orchidopexy.
- If atrophic (vanishing testis)→ inguinal exploration and excision.
- During laparoscopic procedure, there is one thing that indicates atrophy of testis > presence of blood vessels and vas deferens.
- if agenesis→ nothing to be done (only vas deferens is present)
- ❖ Indication for surgery: (benefit of orchidopexy)
 - ✓ To optimize fertility (the most important one). if you leave it, it will atrophy
 - ✓ To potentially reduce malignancy rate (controversial)
 - ✓ To place testis in examinable position to detect malignancy early.
 - ✓ To reduce risk of torsion.
 - ✓ To reduce risk of trauma.
 - ✓ To optimize hormonal function.
- The Testis has two functions: fertility and hormone production from leydig cell which is testosterone.
 - ✓ To repair the associated hernia (90% of UDT).
 - ✓ For cosmetic and psychological reasons.

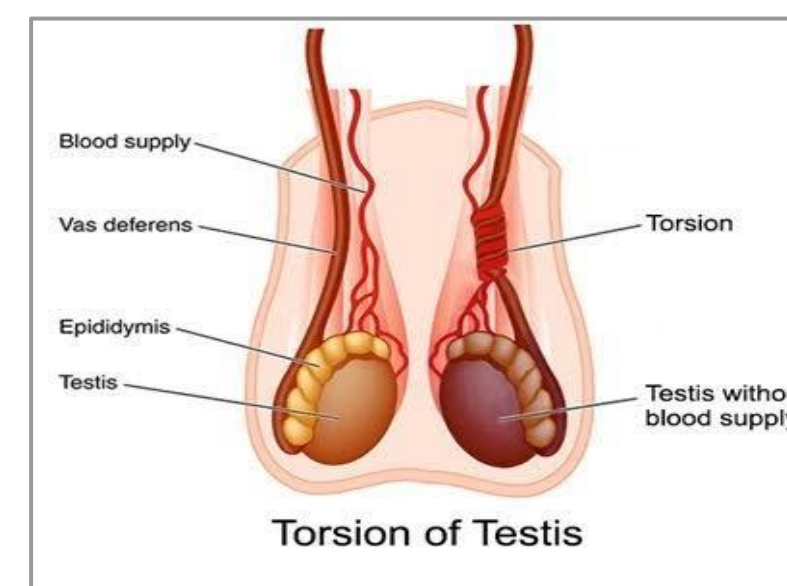
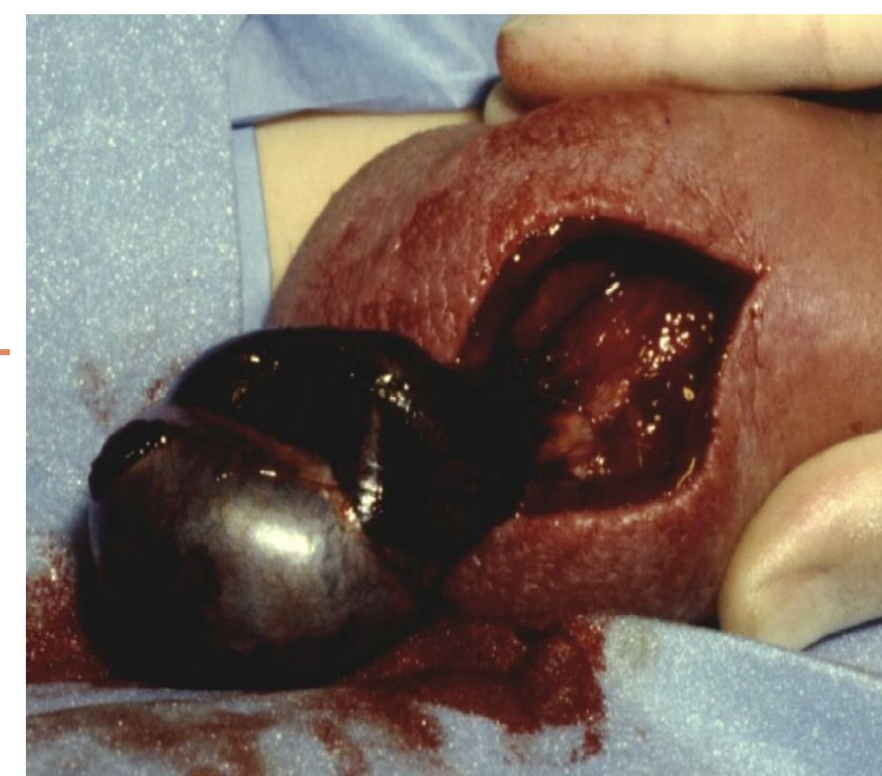ACUTE SCROTUM

Means that the kid will present with scrotal pain

Definition	Acute scrotal pain with or without swelling and erythema. Pediatric surgical emergency
DDx of an acute scrotum(causes) Q in MCQ: what is the commonest cause for acute scrotum in <u>prepubertal</u> boys? Torsion of testicular appendage Q in MCQ: what is the commonest cause for acute scrotum in <u>postpubertal</u> boys and adults? Epididymo-orchitis, be careful (not orchitis or epididymitis)	<ul style="list-style-type: none"> ● Torsion of the testis. (The most common cause and the only surgical indication): <i>number one because it is the most serious</i> ● Torsion of the appendage (<u>Prepubertal</u>). ● Epididymo-orchitis (<u>postpubertal</u>). ● Idiopathic scrotal edema (dermatitis, insect bite) ● Others: Inguinal hernia (incarcerated), Vasculitis (Henoch-schonlein purpura), acute hydrocele, trauma.

TESTICULAR TORSION

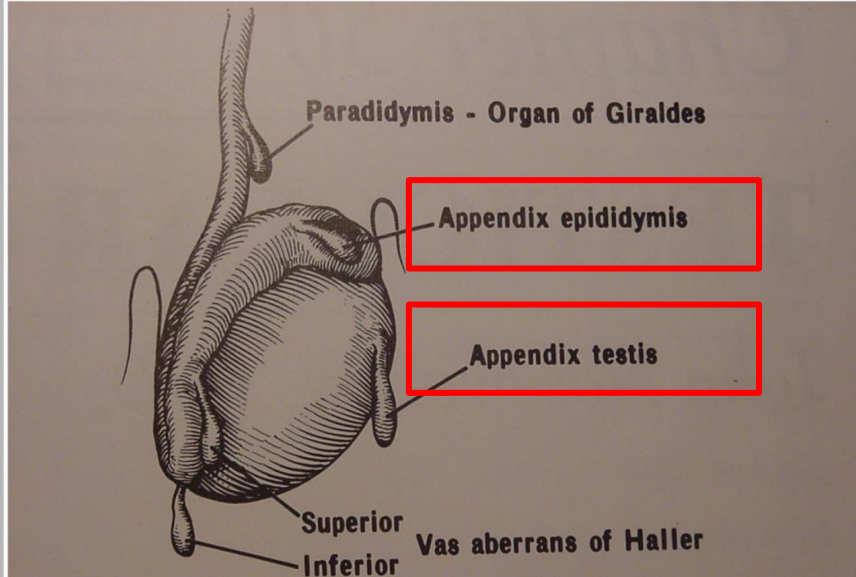
	Testicular torsion occurs when a testicle rotates, twisting the spermatic cord that brings blood to the scrotum. The reduced blood flow causes sudden and often severe pain and swelling. <i>Usually at 14 years of age and associated with systemic symptoms and signs</i>
Introduction	Incidence: 1:4000 Two peaks: peripubertal and perinatal
Symptoms	Lower abdominal pain and vomiting Hemiscrotal pain Swollen red hemiscrotum
Signs	Tender Cremasteric reflex- absent (most specific) Lies higher than contralateral testis Horizontal in position <i>When you scratch the inner aspect of the thigh, the testis will not go up</i>
Investigations	-Color Doppler US -Radionuclide Scan
Management	Timing is critical 4 - 6 hours <i>The golden time is 6 hours</i> Exploration if any doubt <i>Emergent scrotal exploration</i> Untwist (open book) and assess viability Fix the other side If more than 12 hours, it is likely to be non-viable and may need orchiectomy <i>How to untwist? Use open book direction</i> 1- the left testis is untwisted in a clockwise direction 2- the right testis is untwisted in a counter clockwise direction



DURATION OF TORSION AND TESTICULAR SALVAGE

Duration of Torsion (Hours)	Testicular Salvage (%)
<6	85-97
6-12	55-85
12-24	20-80
>24	<10

TORSION OF APPENDAGE(S)

Introduction	<p>-Embryological remnants of the mesonephric and mullerian duct system occur as tiny (2-10mm long) appendages of testis</p> <p>-Appendix testis (hydatid of Morgagni), appendix epididymis...etc</p> <p>-Peak age: 10-12 yrs (age younger than testicular torsion)</p>
Presentation	<p>pain - more gradual onset</p> <p>Blue dot sign(it represent the twisted appendix on the top of the testis,it means that the appendix is dead, you can see it through the skin sometimes)</p> <p>Swollen red hemiscrotum</p> <div data-bbox="1280 1484 1777 1959" style="border: 1px solid black; padding: 5px;"> <p style="text-align: center;">Testicular Appendages</p>  <p style="font-size: small;">FIGURE 50-1. Testicular appendages. (From Rolnick D, Kawanoue J, Szanto P, et al.: Anatomical incidence of testicular appendages. J Urol 199;75: 956-1960)</p> </div>
<p>Color Doppler scan</p> <p>duplex scrotal ultrasound, to ensure there is a blood flow to the testis and you are not dealing with testicular torsion</p>	
Management	<p>Conservative or operative if torsion cannot be excluded</p> <p>Conservative for one week= anti inflammatory medication \ scrotal support</p> <p>If the symptoms did not settle down then you may go for scrotal exploration to excise the twisted appendix</p>

epididymo-orchitis: Present with gradual onset of pain- some swelling - some redness in the scrotum- they may have urinary symptoms . Diagnosis? Duplex scrotal ultrasound , Scrotal scan (nuclear medicine) Treatment? Antibiotics, conservative-scrotal support- anti inflammatory analgesia

Torsion of appendix testis /epididymis :self limiting condition , if discovered before exploration can be treated conservatively (analgesics) ,but if found at exploration needs excision.

Testicular torsion: (the only surgical cause): o Timing is critical 4-6 H.

o Imaging studies usually are not necessary and ordering them may waste valuable time.

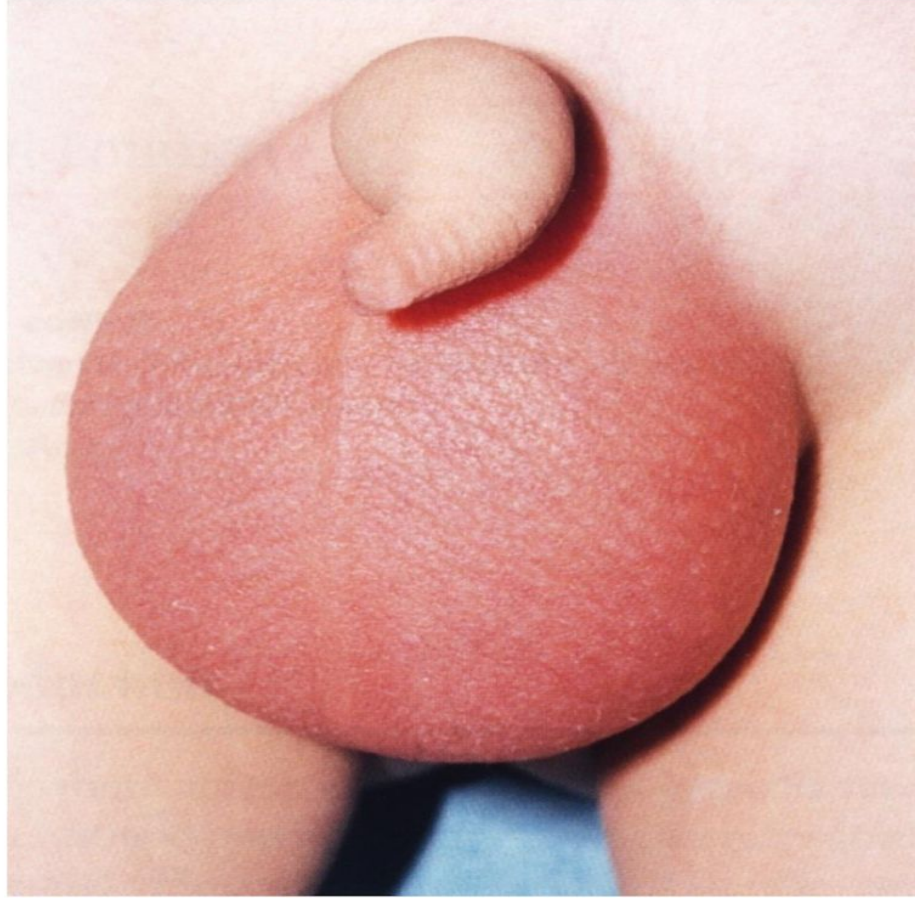
o Scrotal exploration if any doubt.

o If testis is viable untwist anticlockwise (medial to lateral) and fix both sides. 50% chance to have a torsion in the other testis.

o If a testis is not viable, excision and fixing the other side is needed.

o Fixing contralateral testis to reduce the torsion in the future

IDIOPATHIC SCROTAL EDEMA

Introduction	Cause? Peak age: 4-5 yrs Rare and happens to boys at young age	
Presentation	Swollen, red scrotum, minimal pain	
Management	Conservative, self limiting within 1-2 days Does not require surgical intervention Look of slice of salmon fish (diagnostic feature)	

Approach to acute scrotum:

Early recognition and prompt management are very important (within 6 hours). Because of the possibility of testicular torsion, as the etiology, to cause permanent damage to the testis.

→ History :

- Timing (time of onset and length)
- Pain character, onset and course (sudden vs gradual, constant vs intermittent)
- Torsion > sudden\short length , epididymo-orchitis > gradual
- Location (testes, scrotum or abdomen), NOT radiation to these sites (as in renal colic) the pain has to be originally from these sites.
- Quality (sharp, dull)
- History of trauma.

→ Examination:

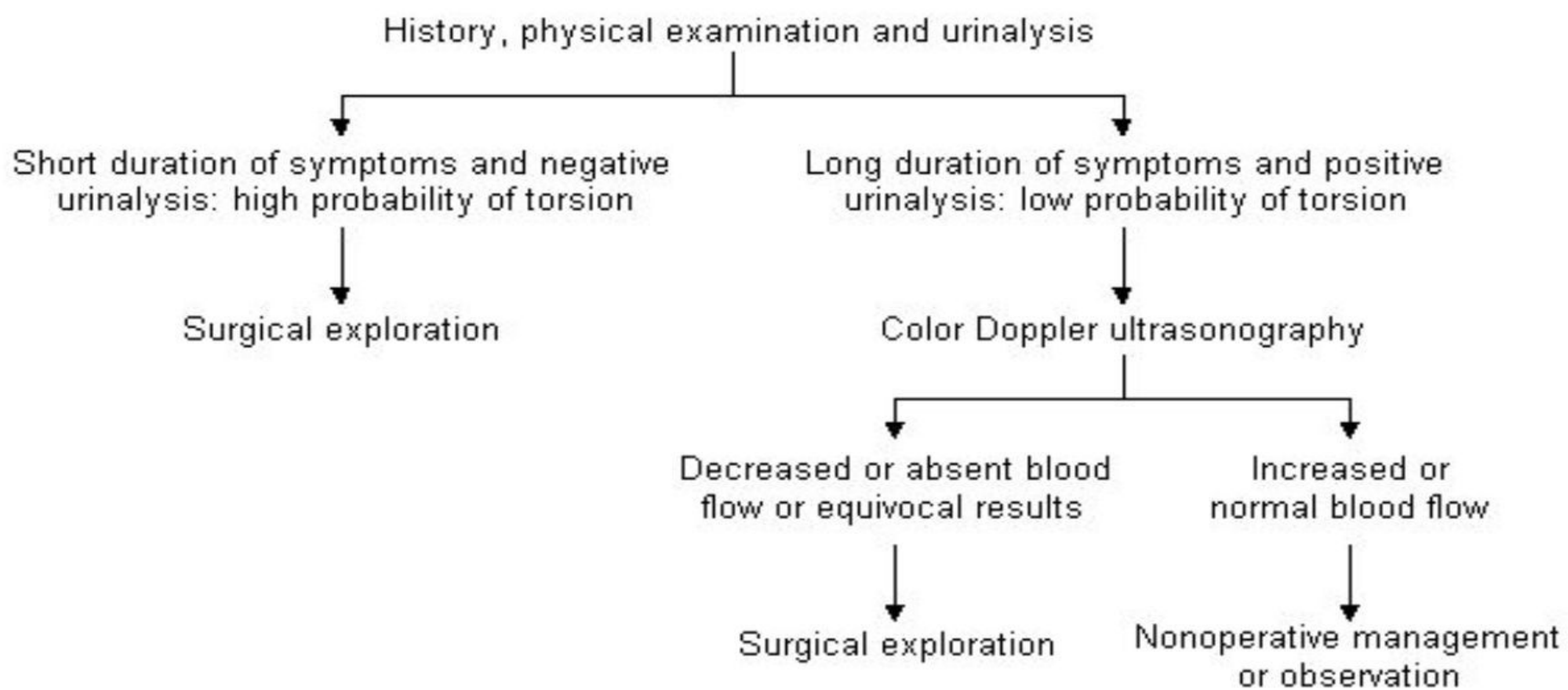
- Overall inspection of patient and comfort level. RED, SWOLLEN, SEVERELY TENDER.
- Abdominal, inguinal, and genital exam required
- Test the cremasteric reflex first: not evident clinically in testicular torsion, because it's a very painful condition.
- Absence of reflex may be most sensitive indicator of torsion of the testes
- Begin with the unaffected side
- Palpate testes, spermatic cord, epididymis and inguinal region.
- Evaluate the lie, size, masses and mobility of testis.
- In physical examination you may not feel the testis as a different organ, because everything is edematous and inflamed, if you can feel it and move it, it's not testicular torsion.
- → Investigations: make sure the investigation should be done within half an hour, any investigation take more than hour you shouldn't consider it at all.
- Done when testicular torsion is difficult to diagnosis.
- Urine analysis. (to exclude UTI (if present > epididymo-orchitis)
- US with color flow Doppler. (sensitivity 90% specificity 99%). Radio-nuclear imaging (Sensitivity 90-100%) more accurate. 12

★ Imaging studies should not delay scrotal exploration when there is high suspicion of torsion.

Summary from the doctor:

- 1- Hernia need to be fixed as soon as feasible because of complications
- 2-Hydrocele fix at the age of 2 years, and the incidence of complications is few or rare
- 2- Undescended testis : orchiopexy for undescended and ectopic testis at the age of 6 months to 1 year, how to differentiate it from retractile testis, also palpable and nonpalpable testis, and the utilization of laparoscopy in cases of non palpable undescended testis
- 4-Testicular torsion: how do they present? And next step in management? emergent scrotal exploration, do not waste your time with investigations in someone with a clinical feature strongly suggestive of testicular torsion
- 5- Torsion of testicular appendages and how to treat it
- 6-Epididymo-orchitis and idiopathic scrotal edema

Protocol for the diagnosis and treatment of the acute scrotum:



Recall:EXTRA

What is hernia?

(L. rupture) Protrusion of a peritoneal sac through a musculoaponeurotic barrier (e.g., abdominal wall); a fascial defect.

Why should hernia be repaired:

To avoid complications of incarceration/ strangulation, bowel necrosis, SBO,pain.

What is incarcerated hernia?

Swollen or fixed within the hernia sac (incarcerated = imprisoned); may cause intestinal obstruction (i.e., an irreducible hernia).

Differences between complete and uncomplete hernia?

Complete: Hernia sac and its contents protrude all the way through the defect.

Uncomplete: Defect present without sac or contents protruding completely through it.

What is hydrocele?

Clear fluid in the processus vaginalis membrane.

What is communicating hydrocele?

Hydrocele that communicates with peritoneal cavity and, thus, gets smaller and larger as uid drains and then re-accumulates.

What is noncommunicating hydrocele?

Hydrocele that does not communicate with the peritoneal cavity; hydrocele remains the same size.

Summary

	Inguinal Hernia	Hydrocele
Definition	It's an indirect hernia related to failure of closure of patent processus vaginalis	It's an abdominal collection of fluid in the processus vaginalis which fails to obliterate resulting in swelling in the scrotum and groin, mostly scrotum.
Types	Based on the anatomical landmark: 1- Direct type 2- Indirect type	1- Communicating hydrocele (most common) 2- Non-communicating hydrocele 3- Hydrocele of the spermatic cord
Complications	1- Incarcerated hernia 2- Obstructed hernia 3- Strangulated hernia	Rare but any infection or trauma can lead to hematocele
Clinical presentation	1- Painless until it gets complicated. 2- Negative transillumination test. 3- Swelling in the groin. 4- Reducibility 5- Thickened spermatic cord. 6- Bulging with (coughing, standing, laughing, jumping). 7- Disappears when lying down.	1- Painless. 2- Swelling in the scrotum. 3- Not reducible. 4- Positive transillumination test. 5- Testes are not felt. 6- You can get above the swelling.
Management	<ul style="list-style-type: none"> - Uncomplicated: hernia elective or semi-elective inguinal herniotomy within couple of weeks from diagnosis. - Complicated: if there is no peritonitis or septic shock, we try to reduce hernia by: <ul style="list-style-type: none"> - 1- rehydration - 2- sedation 	<ul style="list-style-type: none"> 1- Observation in the first two years. 2- If the hydrocele fails to resolve by age of 2 years: surgery (hydrocelectomy/high ligation)
	<ul style="list-style-type: none"> - 3- Continuous pressure is applied around the incarceration - If hernia is reduced: a delay of 24-48h is allowed before herniotomy. - If reduction fails: Urgent herniotomy 	

Summary

	Undescended testis
Definition	The testis is arrested along its normal path of descent.
Clinical presentation	<ul style="list-style-type: none"> - Empty scrotum - Absence of one or both testes - Swelling in the groin - Hemi-scrotum is underdeveloped/hypoplastic - Testis is palpable in the groin and fails to come down to scrotum in 80% of cases - Testis is impalpable in 20% of cases
Diagnosis	The best diagnostic and therapeutic method is Diagnostic laparoscopy
Management	<ul style="list-style-type: none"> - Hormonal treatment: useless and indicated only for patients below 6 months. - Surgical treatment(orchidopexy): Treatment of choice

	Acute scrotum
Definition	Acute scrotal pain with or without swelling and erythema.
Testicular torsion is the most common cause of acute scrotum and the only surgical indication.	
Clinical presentation	<ul style="list-style-type: none"> - Absent Cremasteric reflex.
Investigations	<ul style="list-style-type: none"> - Urine analysis - Color doppler US - Radionuclide scan
Management	<ul style="list-style-type: none"> - Scrotal exploration: if testis is viable, untwist anti-clockwise (medial to lateral) and fix both sides.

Quiz

1- What is the most common cause for acute scrotum in prepubertal boys:

- A) idiopathic scrotal edema
- B) Inguinal hernia
- C) Torsion of testicular appendage
- D) Vasculitis

Answer is C

2- What is the most common cause for acute scrotum in postpubertal boys:

- A) Epididymo-orchitis
- B) Inguinal hernia
- C) Trauma
- D) Vasculitis

Answer is A

3- Treatment of choice for undescended testis:

- A) Orchidopexy
- B) Hormonal
- C) A and B
- D) None

Answer is A

4- Which one of the following clinical feature helps to differentiate Between inguinal hernia and hydrocele in children?

- A) Reducibility
- B) Scrotal swelling
- C) Tenderness

Answer is A

5- 90% of hydrocele will resolve within:

- A) The first 2 years
- B) The first 6 months
- C) At age of 6
- D) At birth

Answer is A

6- What is the most serious complication from inguinal hernia:

- A) Incarcerated hernia
- B) Strangulated hernia
- C) Obstructed hernia

Answer is B