

Acute Abdomen

Objectives aren't found

Lecturer: Dr.Omar Al-Obaid

Same as 436's lecture: NO

 Team leaders: Alanoud Almansour, Ghaida Al Musma , Muath Alhamoud and Mohammed Alqwaifli

 Done by: Aljoharah Alshunifi, Lamis Alsuwailem, Mohammed Alhassan, Khalid Aloqeely , Anas Alqahtani

 Revised by: Yazeed Al-Dossare

Color Index:

 Important

 Doctor's Notes

 Extra

 Davidson's

[Editing File](#) / [Feedback](#)



Acute Abdomen

Definition: Acute abdomen denotes any **sudden, spontaneous (not influenced by something else)**, non-traumatic disorder in the abdominal area that requires urgent surgery in most cases (not all acute abdomens are managed surgically, some are medical ex: **pancreatitis**, also bowel obstruction can **be treated conservatively** 50% of the time). [Full list of possible causes of acute abdominal pain](#) (extra from the book)

- ❑ **COMMONEST CAUSE OF EMERGENCY SURGICAL ADMISSION**
- ❑ **CHALLENGING DISEASE VARIETIES**
- ❑ **RANGING FROM SIMPLE TO LIFE THREATENING DISEASES (From appendicitis to pancreatitis for instance)**
- ❑ **THE PRIMARY SYMPTOM IS ABDOMINAL PAIN**

Types of Abdominal pain (Explained below):

- 1-Visceral pain
- 2-parietal or somatic pain
- 3-Referred pain

Pathophysiology:

Visceral pain	Parietal pain
<ul style="list-style-type: none"> ● Visceral pain is insensitive to mechanical, thermal, or chemical stimulation, therefore can be handled, cut or cauterized painlessly. ● However, they are sensitive to tension (whether due to overdistension or traction), visceral muscle spasm and ischaemia. ● Visceral pain is typically described as dull and deep-seated, and is usually localised vaguely to the area occupied by the viscus during development. 	<ul style="list-style-type: none"> ● The parietal peritoneum is sensitive to mechanical, thermal or chemical stimulation, so when irritated, a reflex contraction of muscles, causing guarding(and hyperaesthesia of skin. ● Somatic pain is classically described as sharp,and is usually well localized. ● Peripheral diaphragmatic irritation leads to tenderness and rigidity, ● when irritated Centrally, pain is referred shoulder area.

-Guarding:rigidity of the abdominal wall (voluntary)

-Hyperesthesia: excessive physical sensitivity

- Visceral pain: in solid or hollow organs, they respond to ischemia or stretching
- Parietal pain: best example is acute appendicitis, first the pain is due to stretching(visceral) then after perforation there is generalized pain and peritoneal signs (rebound tenderness) due to irritation of parietal peritoneum
- Referred pain: due to a shared dermatome ,so the pain will be referred according to the dermatomes that are involved.
 - Cholecystitis → Right shoulder, neck, back (gallbladder is supplied by phrenic nerve which originates from C3-C5)
 - Appendicitis → Periumbilical area (supplied by T10)

The underlying pathological process of abdominal pain may be:

Inflammation	Infarction / Ischemia	Perforation	Obstruction
<ul style="list-style-type: none"> ● Acute inflammation of an intra-abdominal organ or the peritoneum as a result of an irritant. ● Broadly categorized into infective and non-infective ● No matter what the trigger of the inflammation, the subsequent pathological process is the same. ● Example: IBD, acute appendicitis, acute diverticulitis, acute cholecystitis, peritonitis. 	<ul style="list-style-type: none"> ● An infarct is an area of ischaemic necrosis caused either by an occlusion of the arterial supply or the venous drainage in a particular tissue, or by a generalized hypoperfusion in the context of shock. ● In acute abdominal pain, intestinal infarction is most common cause. ● Acute mesenteric (bowel) ischemia may be caused by acute mesenteric arterial embolism due to underlying cardiac cause (AF, post-MI, prosthetic valve) or abdominal / thoracic aneurysm -The patient will have high vital signs (ex:HR above 140) 	<ul style="list-style-type: none"> ● Spontaneous perforation of an intra-abdominal viscus may be the result of weakening of the wall of the viscus, due to degeneration, inflammation, infection or ischaemia, will predispose to perforation, as will peptic ulceration, acute appendicitis and acute diverticulitis. ● Perforation can also be iatrogenic. 	<ul style="list-style-type: none"> ● Obstruction refers to impedance of the normal flow of material through a hollow viscus. ● It may be caused by the presence of a lesion within the lumen of the viscus, an abnormality in its wall, or a lesion outside the viscus causing extrinsic compression. ● The smooth muscle in the viscus will contract reflexly to overcome the impedance. This reflex contraction produces 'colicky abdominal pain'

Assessment of Acute Abdominal pain

1- History taking:

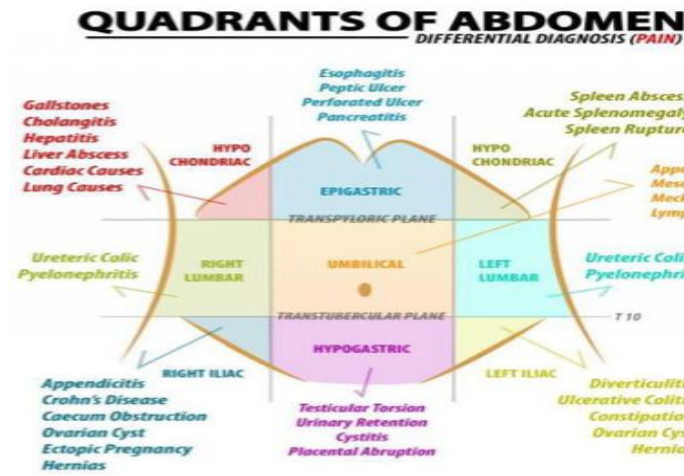
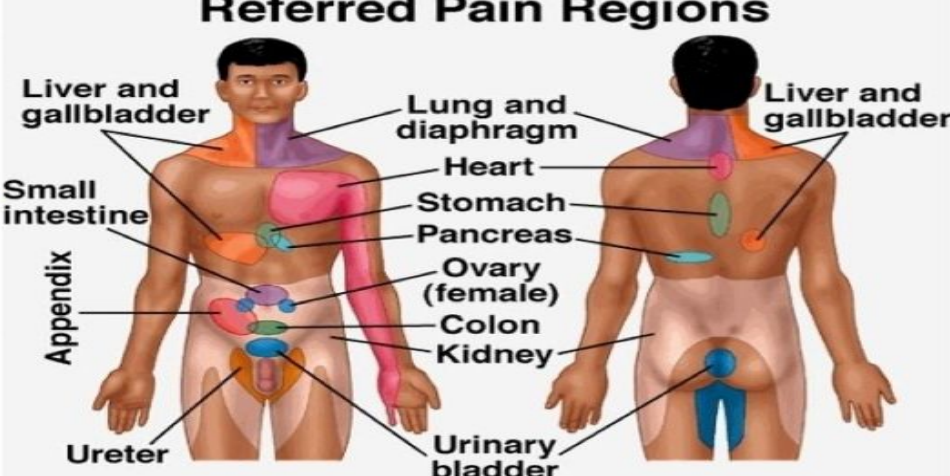
- Age , gender , occupation (it is important to know who you are dealing with)
- Chief complaint: pain*, vomiting, distention, defecation, fever.
- Past history (ex: history of peptic ulcer and now presents with acute abdomen most likely **perforation, if its repeated abdominal pain exclude acute causes)**
- Past family + Social history + Medication(**NSAIDs might cause peptic ulcer**)+**Menstrual cycle to rule out periodic pain which happens in cases of Endometriosis Or ovarian cyst .**

TWO APPROACHES:

- SYSTEMS
- ABDOMINAL TOMOGRAPHY (4 QUADRANTS)

*Most of the time patient will present with pain (SOCRATES):

Note: this slide is extra but its really helpful

<p>Site</p>	<ul style="list-style-type: none"> ○ Right iliac fossa could be Acute Appendicitis or in young female rupture of ovarian cyst or salpingitis (PID) ○ Right upper quadrant acute tenderness → cholecystitis ○ Mid portion of abdomen epigastric → pancreatitis, or peptic ulcer ○ Left upper quadrant → splenic disease (infection, abscess) ○ Left lower quadrant → sigmoid disease like diverticulitis ○ Flank region → kidneys <div style="display: flex; justify-content: space-around;">   </div>
<p>Onset</p>	<p>Usually sudden. (sudden= perforation, gradual= Inflammation)</p>
<p>Character</p>	<p>Colicky, stabbing, burning, gripping</p>
<p>Radiation</p>	<p>Radiation vs shifting:</p> <ul style="list-style-type: none"> ● Radiation means pain extends directly from one place to another, while usually remains present at the site of onset , it usually means that other structures are becoming involved. It usually follows nerve dermatomes. Ex : pain from acute pancreas radiates to the back, cholecystitis pain radiates to the right shoulder, and duodenal ulcer may radiate through to the back ● Shifting means it started in one place but “ disappeared “ and moved to include a new area. <p>Ex : acute appendicitis it was visceral then became parietal/somatic (started vaguely then shifted to the right lower quadrant. (we will explain it later in the next slides)</p>
<p>Associated Symptoms</p>	<p>Vomiting, Bloody diarrhea or constipation, fever.</p> <p>Case: Old age male came to the ER with acute abdominal pain associated with bloody Diarrhea or Back pain you have to think about bowel ischemia)</p>
<p>Time</p>	<p>--</p>
<p>Exacerbating & Relieving Factors</p>	<p>Patients who have ureteric stones will move a lot to find a comfortable position while patients who have appendicitis (or peritonitis) will lie very still because movement increases their pain.</p>
<p>Severity</p>	<p>Rated on a scale of 0 - 10 (0 no pain & 10 the worst pain you experienced) 1 - 3 (mild) / 4 - 6 (moderate) / 7 - 10 (severe)</p>

2- Physical Examination:

- General Look (they look very sick)
 - Vital Signs: usually abnormal (febrile, tachycardic, hypotensive) ○ If abnormal **stabilize and resuscitate the patient first (A, B, C's)** then continue your examination because if you don't the patient might collapse and arrest.
 - Chest → why do I check the chest in acute abdomen?
 - To rule out other causes that can be a cause of acute abdomen but originate from the chest Ex: 1. Acute epigastric pain might originate from the heart (**ischemic heart disease**), 2. **Basal pneumoniae** (can be reflected into the upper abdomen or spleen)
 - Abdomen (**Table from Davidson summarizing findings in examination**)
 - Distention: due to ileus or obstruction
 - Rectal Examination → look for blood, tumor/mass, tenderness.
 - Vaginal Examination → rule out pelvic inflammatory disease "PID" (ex: salpingitis , or oophoritis)
- Specific clinical signs in acute abdominal pain:

Sign	Explanation	Dx	Picture
Murphy's sign	taking a deep breath elicits acute pain while pressing downwards into the RUQ	acute cholecystitis	
Boas's sign	pain radiates to the tip of the scapula and there is a hyperaesthesia just below the scapula	acute cholecystitis	
Grey turner's sign	bruising and discoloration in the left flank	severe acute pancreatitis.	
Cullen's sign	bruising and discoloration around the umbilicus		

3-Laboratory tests:

- CBC (limited clinical utility) To see if there is anemia or Leukocytosis
- Urinalysis/urine culture (UTI OR Pelvic inflammatory diseases)
- Lactic acid (↑ in ischemia)
- LFT / amylase / lipase (To rule out pancreatitis)
- Cardiac enzymes/troponin and ECG (especially central chest pain or upper abdomen)
- HCG (quant/qual) (To rule out ectopic pregnancy or ruptured hemorrhagic cyst)
- Stool culture

4-Radiological tests

- Plain abdominal radiographs(X-ray) or abdominal series has several limitations and is subject to reader interpretation.
- **CT (Useful for tumors) scan in conjunction with ultrasound is superior in identifying abnormalities seen on plain film.**
- Upright CXR: Rule out pneumonia and Perforation (air under the diaphragm)
- Abdominal x-ray: to check for air fluid level(which indicates obstruction) and bowel dilatation.
- US usually for Biliary colic and hepatobiliary diseases

- Diagnosis (Extra from Team 436)

- **Acute Abdomen + Shock*(hypotension tachycardia)**
 - Think about Acute Pancreatitis/ Ruptured AAA
- **Generalized Peritonitis** (whole abdomen is tender and rigid)
 - Ruptured/perforated Viscus (Example perforated peptic ulcer disease, or perforated small bowel, or perforated colon, perforated appendicitis)
- **Bowel Obstruction** and ascites present with distention (to differentiate do percussion: in ascites dullness, in obstruction tympanic)

- Management:

Category 1 "emergent"	Need immediate operation (patient may die or arrest) Best example: ruptured AAA (abdominal aortic aneurysm)
Category 2 "urgent"	Preoperative preparation and emergency operation within 6 hours . Like category 1 but we have to resuscitate them before surgery (can't take hypotensive pt to OR) we still have some time. Why resuscitate? Because if we don't they complication rate becomes higher. Why don't we resuscitate AAA? Because we can't → whatever we give them will not reach the organs since the aorta is ruptured. Ex: peritonitis, ischemia, etc...
Category 3 "semi-urgent"	Urgent operation within 24 hours It can wait but it has to be operated on ex: acute appendicitis.

-Not all acute abdomen need surgery:

- Conservative treatment:

- Ex: acute pancreatitis

- What are the causes?

1. Biliary pancreatitis (caused by obstruction)

2. Trauma during ERCP* (gallstone removal)

3. Dyslipidemia (hypercholesterolemia)

4. Idiopathic

- Managed non-surgically 90% of times, the remaining 10% it becomes complicated → **necrotizing pancreatitis** (when it is severe and causes abscess or necrosis in pancreas) and requires surgical intervention.

*ERCP=Endoscopic retrograde cholangiopancreatography
(the most common complication of ERCP is pancreatitis)

Recall: (EXTRA)

What are peritoneal signs in acute abdomen?

Signs of peritoneal irritation: extreme tenderness, percussion tenderness, rebound tenderness, voluntary guarding, motion pain, involuntary guarding/ rigidity (late)

Define the following terms:

Rebound tenderness: Pain upon releasing the palpating hand pushing on the abdomen

Voluntary guarding: Abdominal muscle contraction with palpation of the abdomen

Involuntary guarding: Rigid abdomen as the muscles "guard" involuntarily Colic: Intermittent severe pain (usually because of intermittent contraction of a hollow viscus against an obstruction)

What conditions can mask abdominal pain?

Steroids, diabetes, paraplegia

What is the best way to have a patient localize abdominal pain?

"point with one finger where the pain is worse"

What are the differential diagnoses by quadrant?

RUQ:

Cholecystitis, hepatitis, PUD, perforated ulcer, pancreatitis, liver tumors, gastritis, hepatic abscess, choledocholithiasis, cholangitis, pyelonephritis, nephrolithiasis, appendicitis (especially during pregnancy), thoracic causes (e.g. pleurisy/pneumoniae), PE, pericarditis, MI (especially inferior MI).

LUQ:

PUD, perforated ulcer, gastritis, splenic injury, abscess, reflux, dissecting aortic aneurysm, thoracic causes, pyelonephritis, nephrolithiasis, hiatal hernia (strangulated paraesophageal hernia), Boerhaave's syndrome, Mallory-Weiss tear, splenic artery aneurysm, colon disease

LLQ:

Diverticulitis, sigmoid volvulus, perforated colon, colon cancer, urinary tract infection, small bowel obstruction, inflammatory bowel disease, nephrolithiasis, pyelonephritis, fluid accumulation from aneurysm or perforation, referred hip pain, gynecologic causes, appendicitis (rare)

RLQ:

Appendicitis! And same as LLQ; also mesenteric lymphadenitis, cecal diverticulitis, Meckel's diverticulum, intussusception

What is the differential diagnosis of epigastric pain?

PUD, gastritis, MI, pancreatitis, biliary colic, gastric volvulus, Mallory-Weiss tear

What are nonsurgical causes of abdominal pain?

Gastroenteritis, DKA, sickle cell crisis, rectus sheath hematoma, acute porphyria, PID, kidney stone, pyelonephritis, hepatitis, pancreatitis, pneumonia, MI, C. difficile colitis

What is the unique differential diagnosis for the patient with AIDS and abdominal pain?

In addition to all common abdominal conditions: CMV (most Common)---Kaposi's sarcoma---Lymphoma---TB---MAI (Mycobacterium Avium Intracellulare)

What is the classic position of a patient with peritonitis?

Motionless (often with knees flexed)

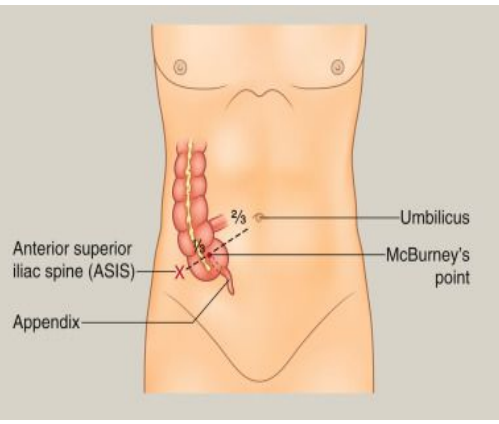
What is the classic position of a patient with kidney stones?

Cannot stay still, restless, writhing in pain Classically,

what endocrine problems can cause abdominal pain?

1. Addison crisis 2. DKA (Diabetic KetoAcidosis)

Acute Appendicitis (from the book)

<p>Anatomy</p>	<ul style="list-style-type: none"> The appendix is a worm-shaped blind-ending tube that arises from the posteromedial wall of the caecum 2 cm below the ileocaecal valve. It varies in length from 2 to 25 cm, but is most commonly 6–9 cm long. On the surface of the abdomen, this point lies one-third of the way along a line drawn between the right anterior superior iliac spine and the umbilicus (McBurney's point).
<p>Etiology:</p>	<p>the etiology of acute appendicitis remains unclear. Pathogenesis: Obstruction of the lumen of the appendix is thought to play the main role in the initiation of inflammation.</p>
<p>Clinical Features</p>	<ul style="list-style-type: none"> Only 50% of patients with acute appendicitis give a typical history. Most common in the under 40s with peak incidence between 8 and 14 years of age.
<p>History</p>	<ul style="list-style-type: none"> Classically, the onset of acute appendicitis is associated with the gradual onset of poorly localized central abdominal pain (umbilical). After a variable amount of time, the pain moves to the right iliac fossa and changes in character, to become sharper, constant and well localized (when the parietal peritoneum overlying the appendix becomes involved in the inflammatory process). It is aggravated by movement and coughing. And associated with anorexia and occasional vomiting. Low grade fever
<p>Examination</p>	<ul style="list-style-type: none"> The patient with established acute appendicitis looks unwell, the temperature is usually only mildly elevated (37.3–38.5°C) and there is often a tachycardia. Classically, the area of maximal tenderness is over McBurney's point,(see pic) with guarding and rebound tenderness 
<p>How is the diagnosis made?</p>	<p>History and physical exam mainly</p>
<p>What is the treatment?</p>	<p>Nonperforated: prompt appendectomy and cefoxitin to avoid perforation Perforated:—triple antibiotics, fluid resuscitation, and prompt appendectomy; all pus is drained and cultures obtained, with postoperative antibiotics continued for 5 to 7 days, +/- drain</p>
<p>What are the associated lab findings with appendicitis?</p>	<p>Increased WBC (>10,000 per mm³ in > 90% of cases, with a left shift in most)</p>

Peritonitis (from the book)

Note: This topic were not covered in the lecture but were mentioned in the book chapter+ITs important to know it

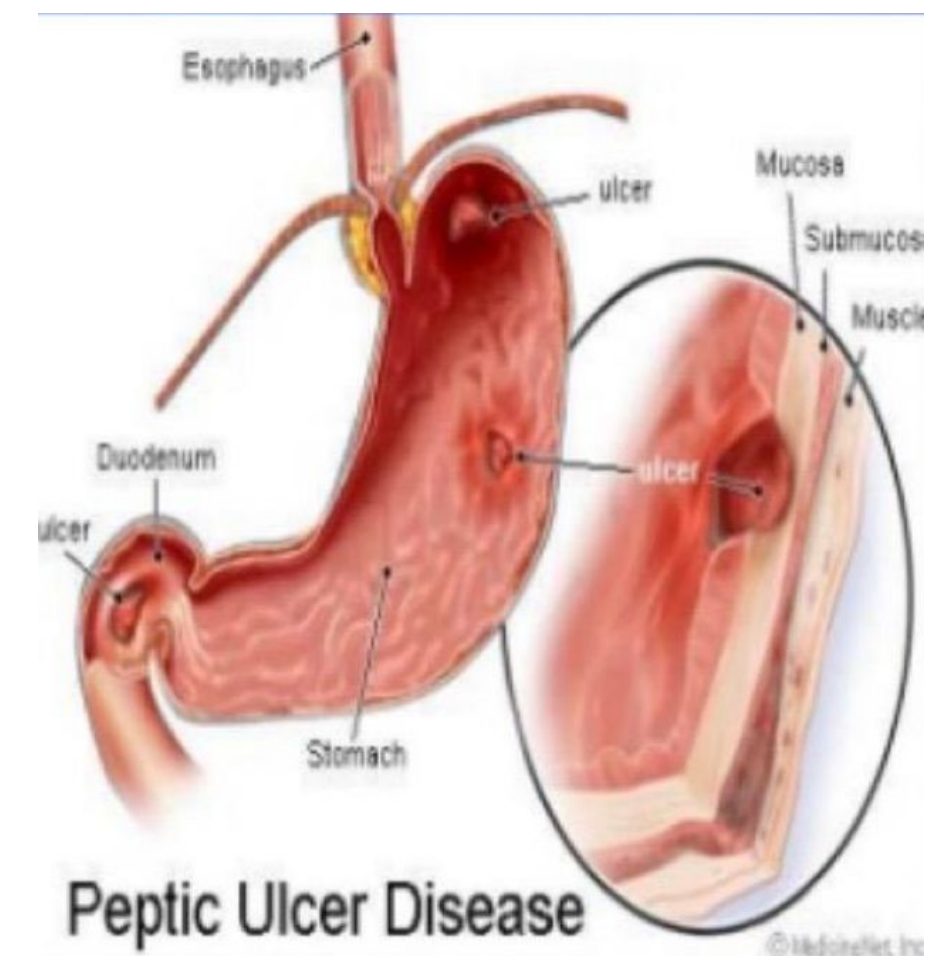
Inflammation of the peritoneum is a common feature of the acute abdomen. It can be classified as acute or chronic, septic or aseptic, and primary or secondary.

- **Primary peritonitis:** In adults, spontaneous bacterial peritonitis (SBP) may occur in patients with the **nephrotic syndrome**, but is more frequently seen in those with liver cirrhosis or **chronic renal failure** (particularly in patients on peritoneal dialysis). Classically, diffuse peritonitis with **generalized abdominal tenderness and rigidity develops within 24 hours**. **Fever and leukocytosis occur early.**

- **Secondary peritonitis:** Acute suppurative peritonitis secondary to visceral disease is the most common form of peritonitis in surgical practice.

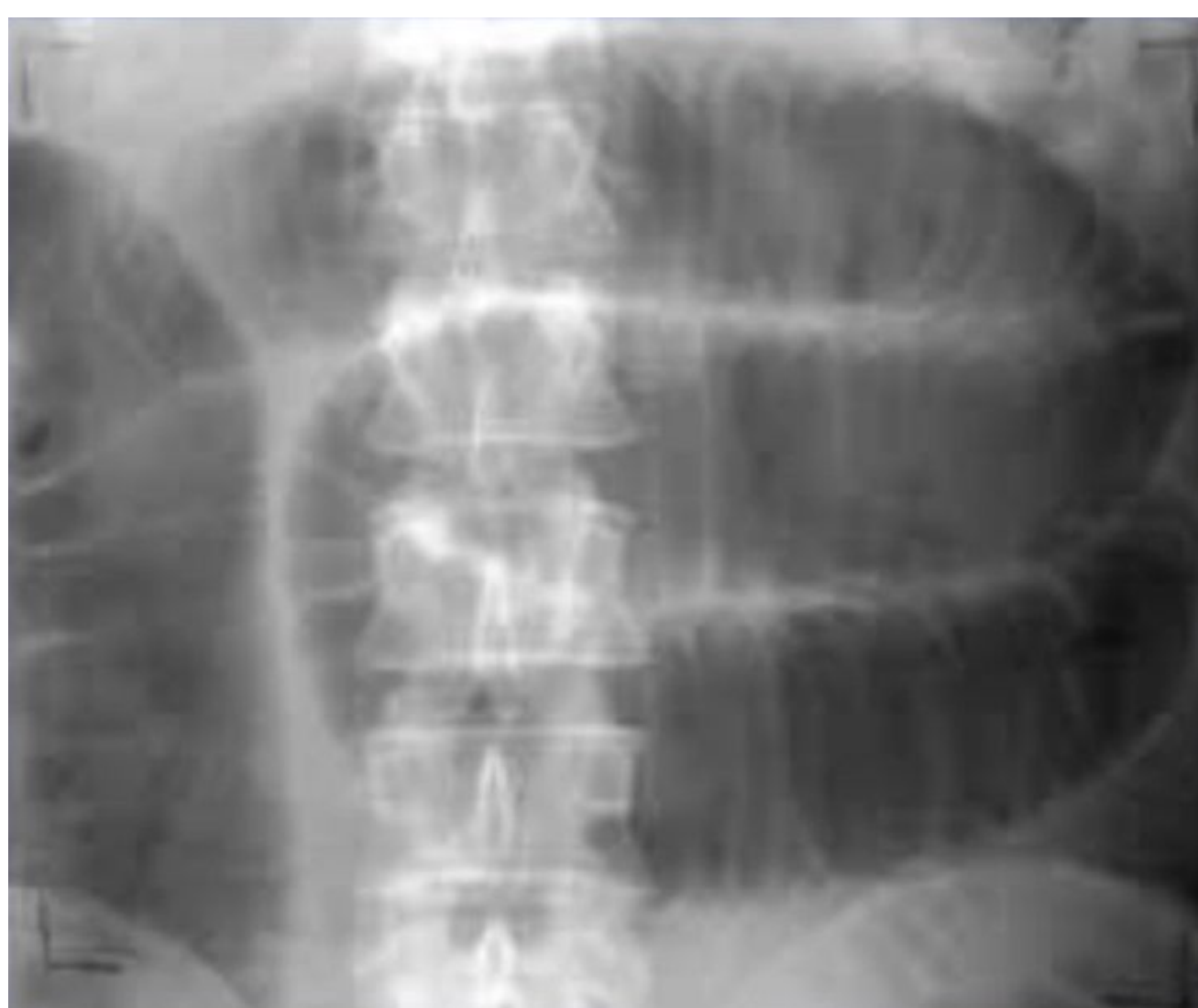Peptic ulcer disease:

- Steady, well localized **epigastric** or LUQ pain
- described as **"burning"**, "aching", "gnawing"
- Increased by coffee, stress, spicy food, smoking (Gastric ulcer).
- Decreased by food, antacids ex:H2 blockers (Duodenal ulcer)
- Only **perforated** peptic ulcer will lead to acute abdomen

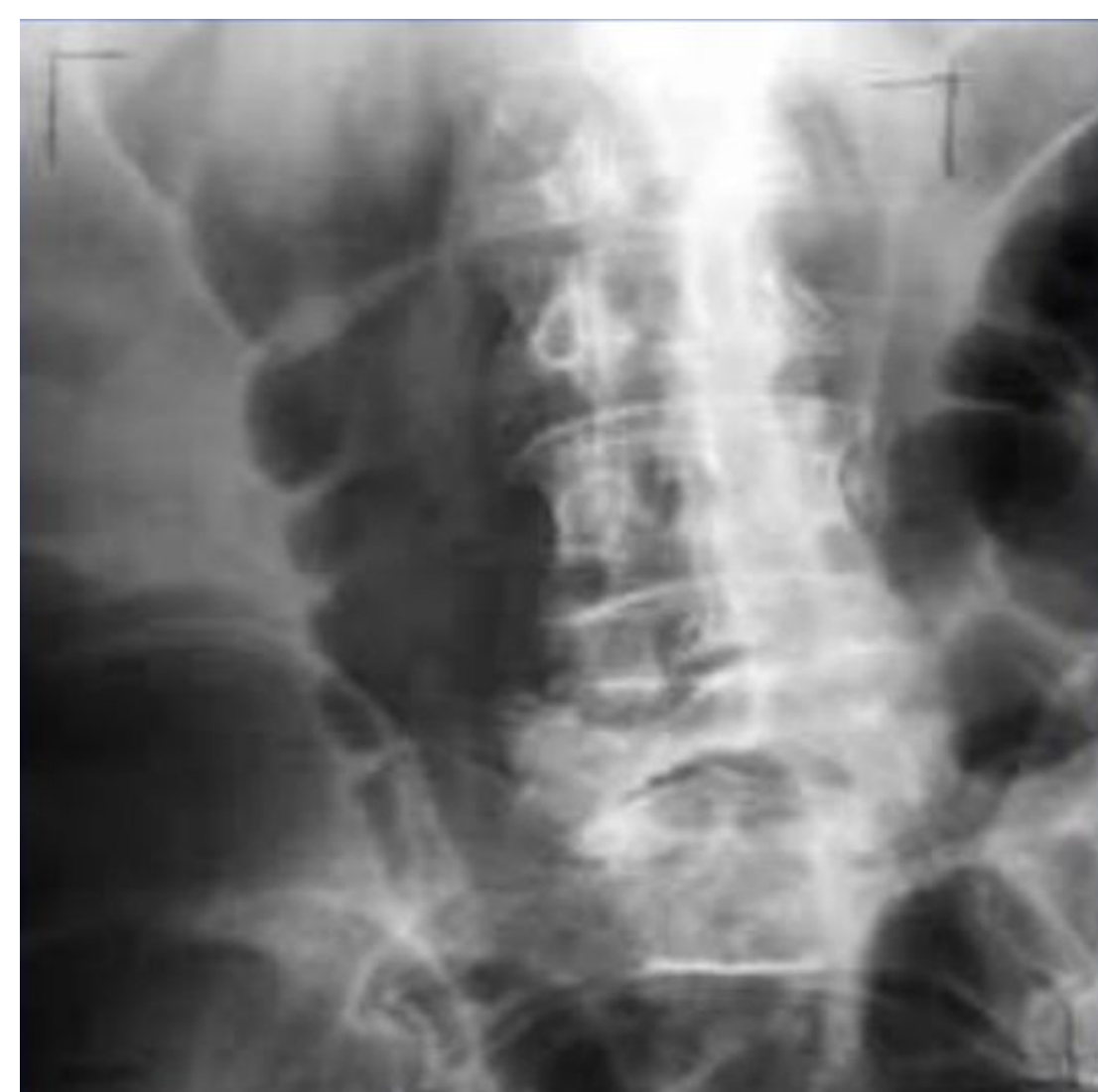

Bowel obstruction:

- Small vs large bowel obstruction
- adhesions are the commonest cause (previous surgery)
- In a virgin abdomen: don't let the sun set on a bowel obstruction! (because 100% there is a problem, So you have to do urgent surgery).
- Large Bowel obstruction is more dangerous why? can lead to ischemia and perforation
- For example, the sigmoid is obstructed but the ileocecal valve is competent:
 - secretions will accumulate → bowel obstruction → ischemia → perforation



Small bowel obstruction



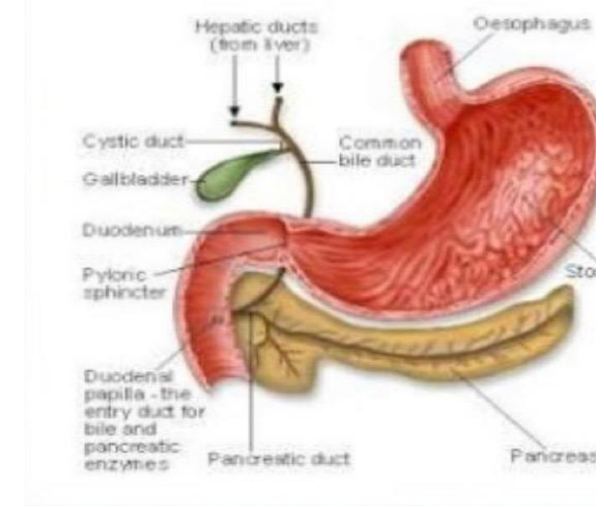
large bowel obstruction

Dilated bowel loops

How to tell if it's SB or LB? The large bowel is central and has haustration

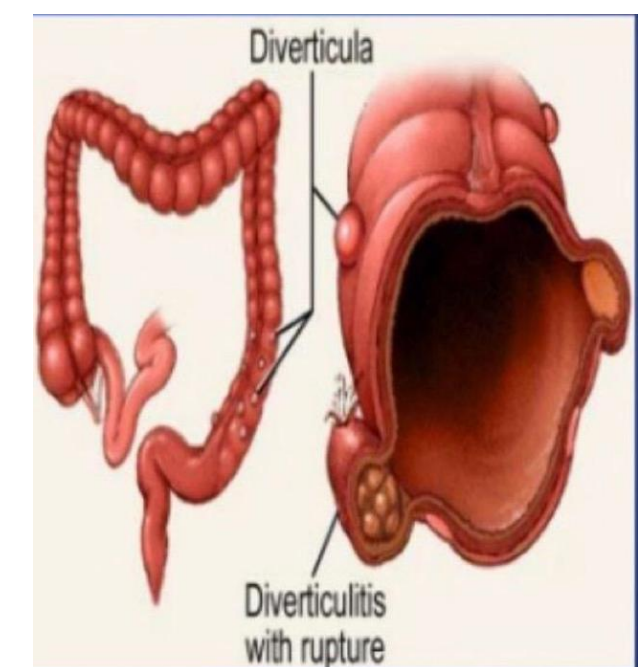
Pancreatitis

- Inflammation of the pancreas
- Triggered by ingestion of EtOH; large amounts of fatty foods
- Nausea , vomiting; abdominal tenderness; **pain radiating from upper abdomen straight Through to back**
- Signs , symptoms of **hypovolemic shock**.
- **chemical pancreatitis is much worse than bacterial peritonitis, because the enzymes will leak and will digest the structures in the abdomen → erosion of vessels and bleeding**



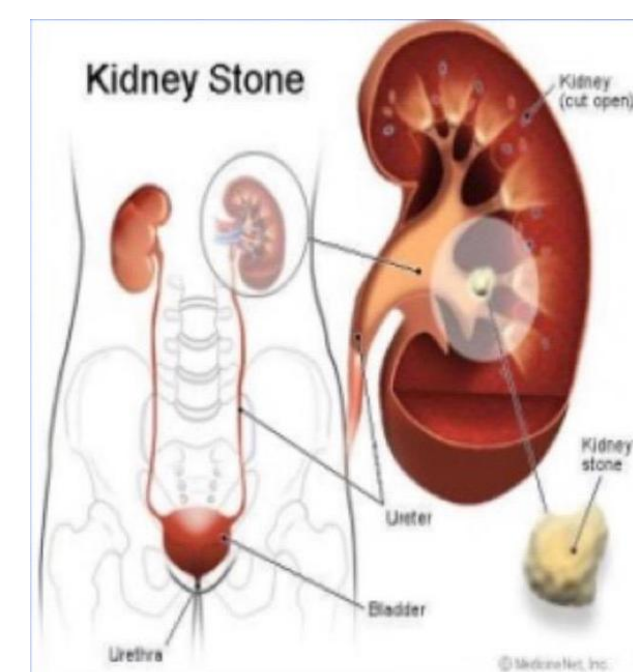
Diverticulitis

- Pouch become blocked and infected with fecal matter causing inflammation
- Pain, perforation, severe peritonitis.
- Not very common in KSA
- Related to low fiber diet and poor diet
- Causes abscess
- **Usually present with: Fever LLQ pain and Change in bowel habits**



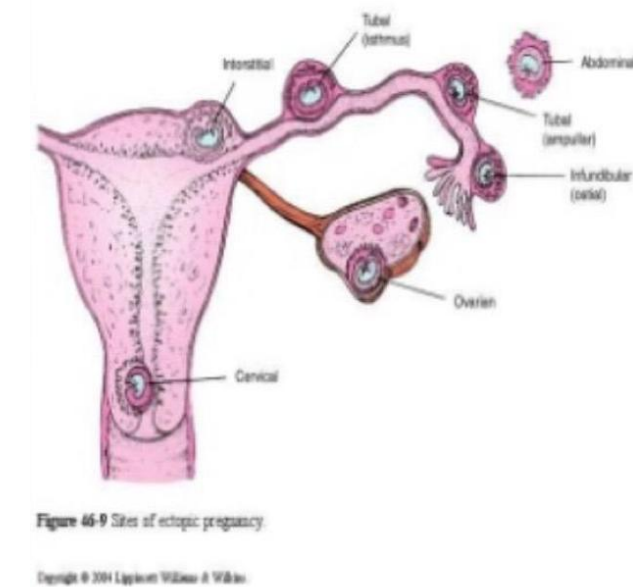
Kidney stones (you have to rule it out)

- Mineral deposits form in kidney, move to ureter.
- Often associated with history of recent UTI
- **Severe flank pain radiates to groin , scrotum**
- Nausea , vomiting , hematuria
- Extreme restlessness **and its relieved by movement**.
- **Kidney stones mimics bowel obstruction**



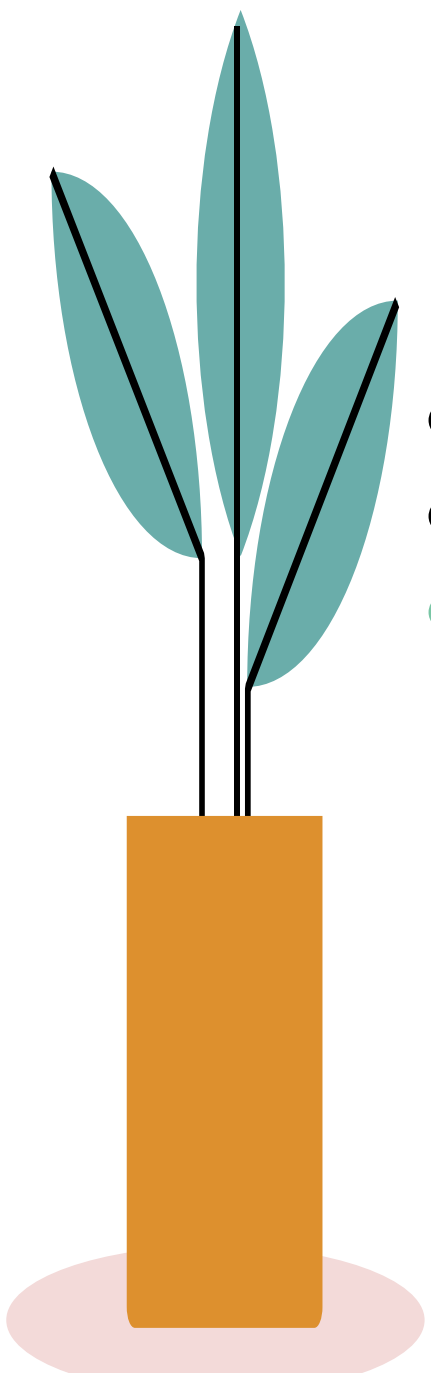
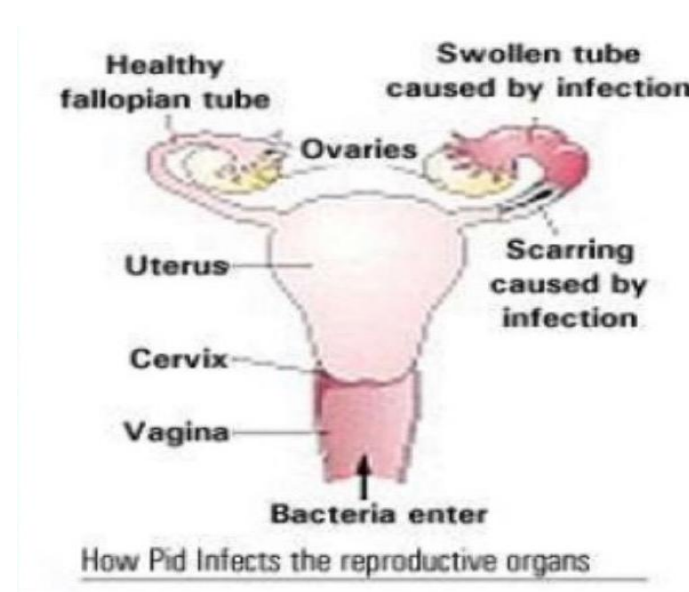
Ectopic pregnancy

- Fertilized egg is implanted outside the uterus .
- Growth causes rupture and can lead to massive bleeding.
- Patient c/o of severe RLQ or LLQ pain with radiation



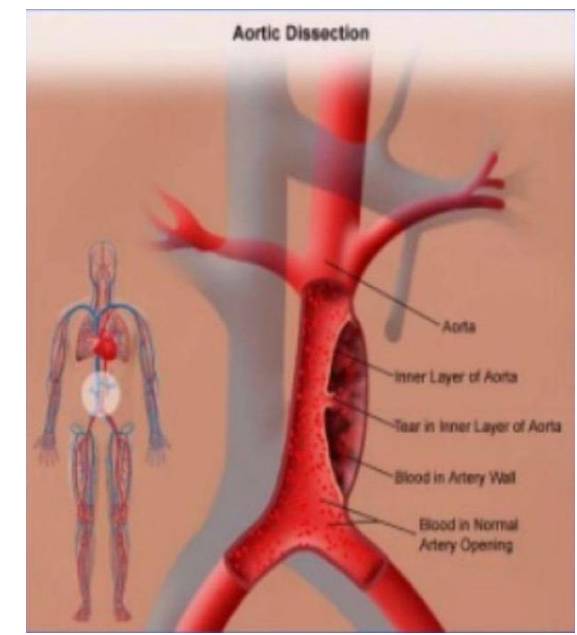
Pelvic inflammatory diseases

- Inflammation of the fallopian tubes and tissue of the pelvis
- Typically lower abdominal or pelvic pain , nausea , vomiting
- **Mimics perforated appendix, the difference is presence of vaginal discharge**



Abdominal Aortic Aneurysm

- Localised weakness of blood vessel wall with dilation
- (like bubble on tire)
- Pulsating mass in abdomen
- **Can cause lower back pain(Tearing abdominal pain that radiates to the back)**
- Rupture **shock** , exsanguination
- **You have to take him to the OR immediately!!!**



Mesenteric Ischemia (MI) difficult to diagnose because they have signs when it becomes gangrenous and perforates and they diagnosed late why because there is no test confirm it except your eyes

Diagnosis can be divided into the following :

1- Arterial insufficiency

- **occlusive - Embolic (A.Fib) / Thrombotic**
Embolic MI has most abrupt onset
- Nonocclusive - Low flow state (AMI / shock)
Usually has clinical evidence of a low flow state (acute cardiac disease)

2- Venous- Mesenteric venous thrombosis

- Occurs in hypercoagulable states (post-op)
- Usually is found in younger pts
- Has a lower mortality
- Can be treated with immediate anticoagulation
- **MI: on physical exam they have pain out of proportion to tenderness**
- **Case told by the Dr: an 80 yo known to have Afib, sudden onset of abdominal pain out of proportion to tenderness → mesenteric ischemia**

Ischemic Colitis

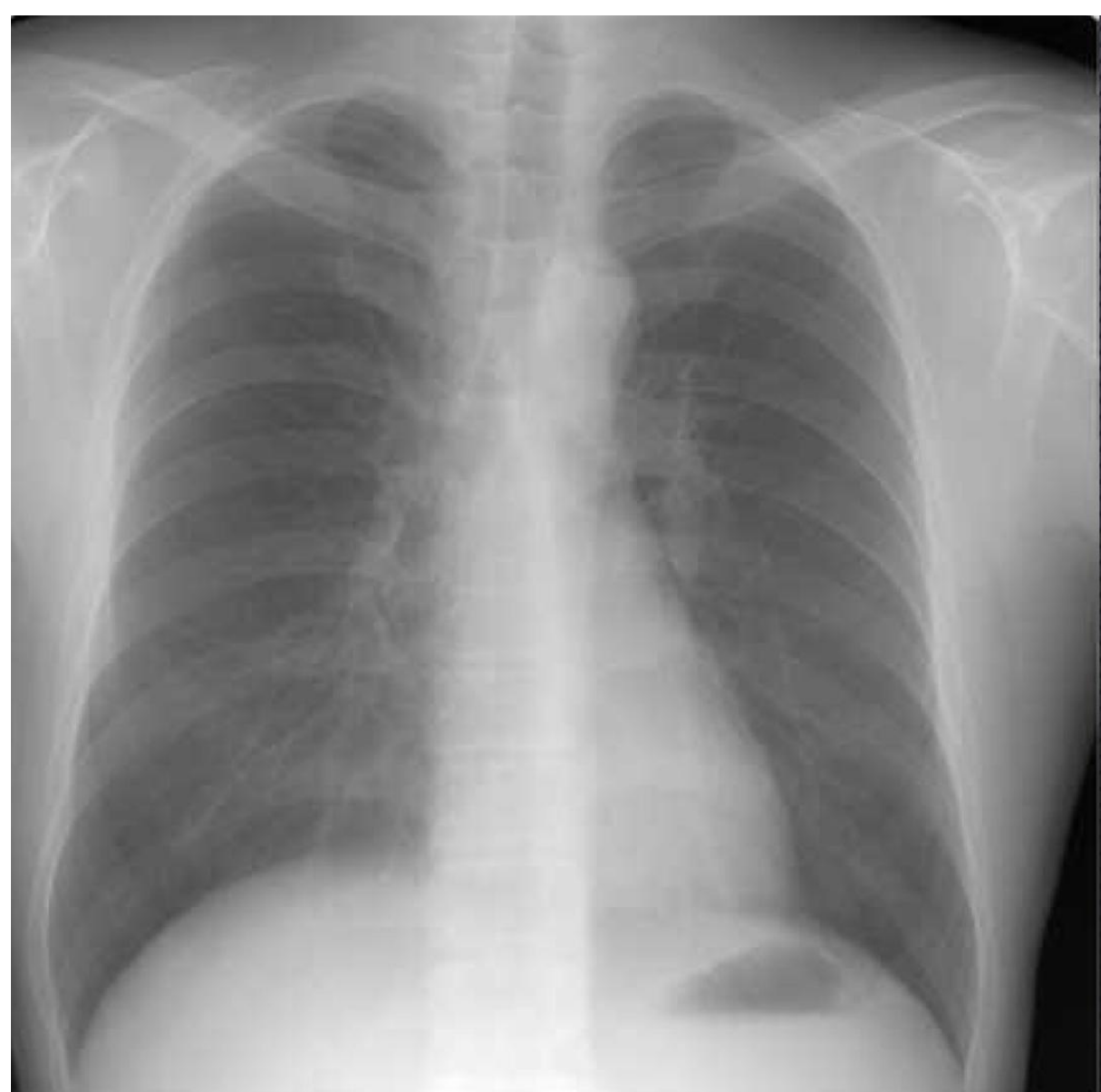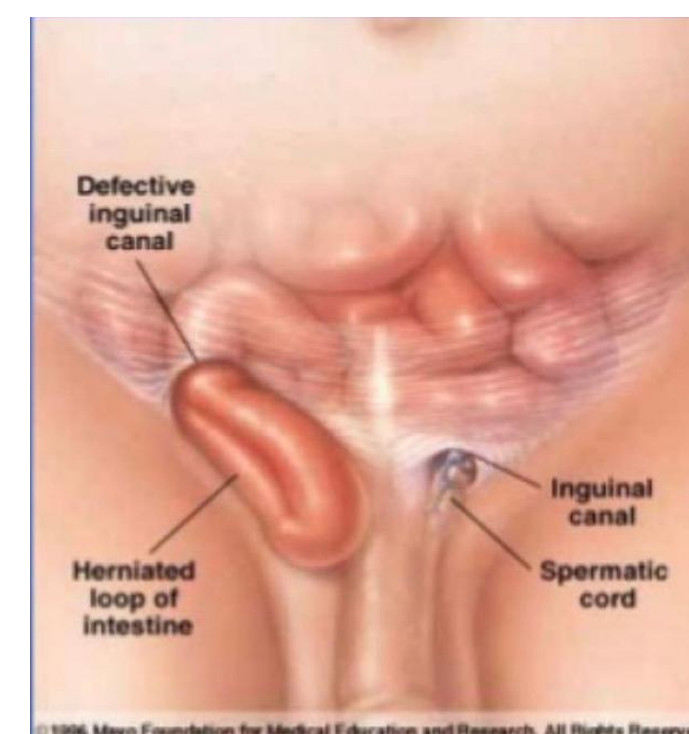
- It is a diagnosis of an older patient.
- Pain described as diffuse , lower abdominal pain in 80 % of pts .
- Can be accompanied by diarrhea often mixed with blood 60% of patient.
- Compares to mesenteric ischemia, this is not due to large vessel occlusive disease
- Angiography is not indicated. If it is performed it is often normal.
- **Usually in patients with IBD or on antibiotics due to C. Dif**
- **Can perforate and lead to peritonitis**

Extra abdominal diagnosis of acute abdominal pain : Cardiopulmonary

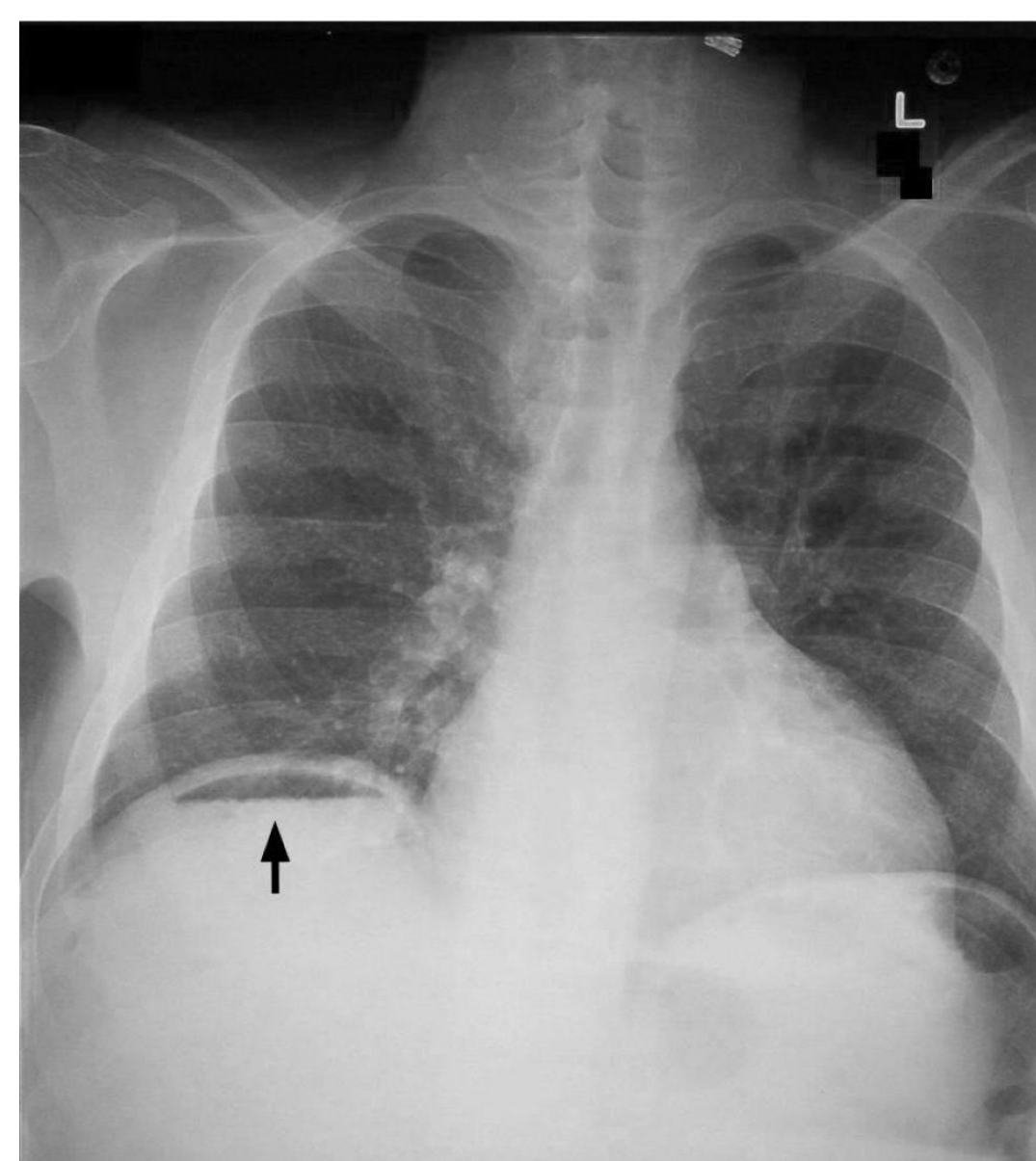
- Pain is usually in upper half of abdomen .
- A chest film should be done to look for pneumonia, pulmonary infarction, pleural effusion , and / or pneumothorax.
- A neg. Film plus pleuritic pain could mean PE.
- If epigastric pain is present one should inquire about cardiac history, get an ECG Consider further cardiac evaluation.

Inguinal hernia


- Protrusion of the intestine through a tear in the inguinal canal.
- Usually identified by abnormal mass in lower quadrant, with or without pain.
- Strangulation can lead to necrosis.



- This is a normal CXR
- Well defined gastric wall



- Air under the diaphragm
- Usually in the right side



Summary

Acute Abdomen

any sudden, spontaneous non-traumatic disorder in the abdominal area that requires urgent surgery in most cases

Types of Abdominal pain :

1. Visceral pain: **insensitive** to mechanical, thermal, or chemical stimulation, But sensitive to **tension**, visceral muscle **spasm** and **ischaemia**.
2. parietal (somatic): **sensitive** to mechanical, thermal or chemical stimulation , when irritated it causes **guarding** of abdominal wall and **hyperaesthesia** of skin
3. Referred pain : pain will be referred according to the dermatomes that are involved

pathological process of abdominal pain may be:

1. Inflammation e.g. **acute appendicitis**
2. Infarction / Ischemia e.g. **Acute mesenteric ischemia**
3. Perforation e.g. **Peptic ulcer**
4. Obstruction e.g. **Gallstones**

Assessment of Acute Abdominal pain:

SOAP

Subjective	Objective	Assessment	Plan
History Taking (SOCRATES) Site Onset Character Radiation Associated Symptoms Time Exacerbating & Relieving Factors Severity	Physical Examination +Vital Signs (inspection+palpation+percussion) (BP, HR, temp. etc)	Investigations Laboratory tests CBC, Urinalysis, LFTs, Serum amylase + Lactate and ABGs Radiological tests CXR, AXY, CT, US	Treatment Category 1 require immediate operation e.g. AAA Category 2 "urgent" Preoperative preparation and emergency operation within 6 hours . e.g. peritonitis Category 3 Urgent operation within 24 hours e.g. acute appendicitis .

Questions

1-A 32-year-old pregnant lady complains of right lower quadrant pain that comes periodically every month , What is your most likely diagnosis?

- A. acute Appendicitis
- B. chronic Appendicitis
- C. Endometriosis
- D. Cholecystitis

2.Pregnant lady in her 32 week of gestation, had right abdominal and right flank pain, Whats is the best imaging modality/investigation?

- A. US
- B. CT
- C. X-ray
- D. MRI abdomen

3.The most common complication of ERCP is ?

- A. Bleeding
- B. Injury to CBD
- C. Pancreatitis
- D. Perforation

4.A 23 years old male present with generalized abdominal pain then it shifted to the right lower abdomen Describe the mechanism?

- A. Referral pain
- B. Parietal pain becomes visceral
- C. Visceral pain become somatic
- D. Visceral Pain

5. Not all cases of acute abdomen need surgery, best example for that is:

- A. Acute pancreatitis
- B. Diverticulitis.
- C. Chronic appendicitis
- D. Ischemic colitis