



## Color Index:

- ✓ Important
- ✓ Notes
- ✓ Extra


## [Editing File](#)

# Radiology of Lung diseases

objectives:

---

→ Not provided



Done by:



Alanoud Salman



Renad Alswilmy



Dawood Ismail

Revised by:



Yazeed Al-Dossare



This table is extra from outer source.  
Extra information...

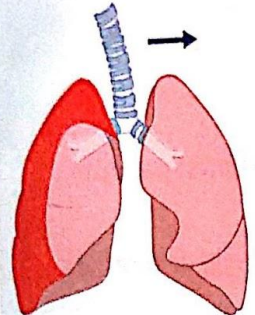
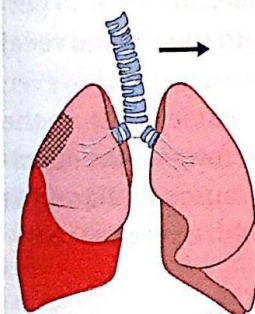
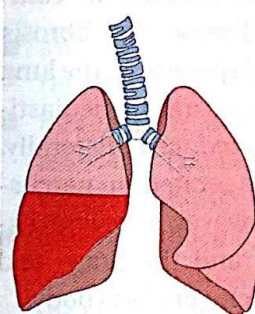
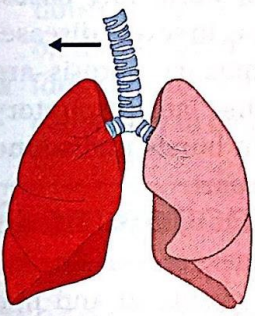
Examination findings for common respiratory presentations					
Respiratory presentation	Trachea	Expansion	Percussion	Auscultation	Vocal resonance
<b>Pneumothorax</b> 	Central or deviated away, depending on size	Reduced on affected side	Hyper-resonant	Absent breath sounds No added sounds	Reduced or absent
<b>Pleural effusion</b> 	Central or deviated away, depending on size	Reduced on affected side	Dull ('stony dull')	Absent breath sounds Pleural rub (sometimes) Bronchial breathing at the top (sometimes)	Reduced or absent
<b>Lobar consolidation</b> 	Central	Reduced on affected side	Dull (if dense; resonant if less dense)	Bronchial breathing (if dense) Coarse crepitations	Increased or bronchial
<b>Lobar collapse</b> 	Deviated towards	Reduced on affected side	Dull	Absent breath sounds No added sounds	Reduced

Table 2.19 Examination findings for common respiratory presentations. *Continued opposite.*

This table is extra from outer source.  
Extra information...

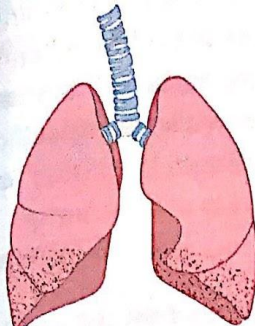
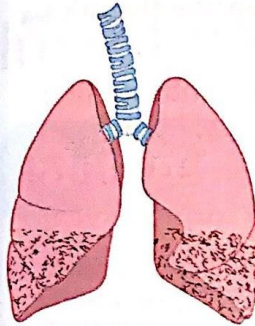
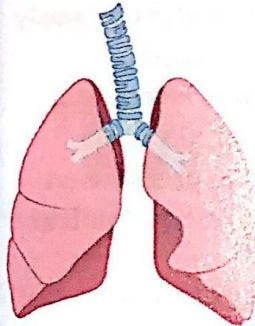
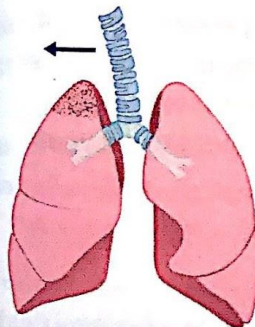
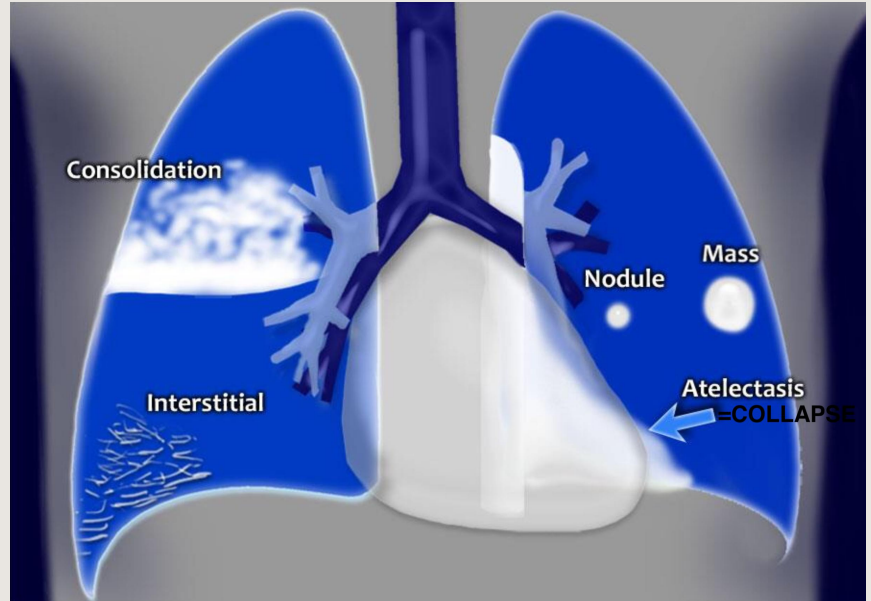
Examination findings for common respiratory presentations <i>continued</i>					
Respiratory presentation	Trachea	Expansion	Percussion	Auscultation	Vocal resonance
Pulmonary fibrosis 	Central	Reduced bilaterally	Resonant	Fine inspiratory bibasal crepitations (Velcro crepitations)	Normal
Bronchiectasis 	Central	Reduced bilaterally	Resonant	Coarse inspiratory bibasal crepitations	Normal or increased
COPD or asthma 	Central	Reduced bilaterally	Resonant	Prolonged expiration Quiet breath sounds throughout Expiratory wheeze	Normal or reduced throughout
Apical scarring (post-tuberculosis) 	Deviated towards	Reduced unilaterally	Resonant or dull	Bronchial breathing (tracheal) Focal crepitations	Normal or increased

Table 2.19 Examination findings for common respiratory presentations (*continued*).



# Lung diseases



Consolidation= pneumonia.

- Nodules= small.
- Mass= large.
- Atelectasis= lung collapse.
- Interstitial= diffuse lung disease.

- Air space disease= consolidation - fills already present air space.
- Mass or nodule= starts as single cell And grow to push not replace causing (mass effect).

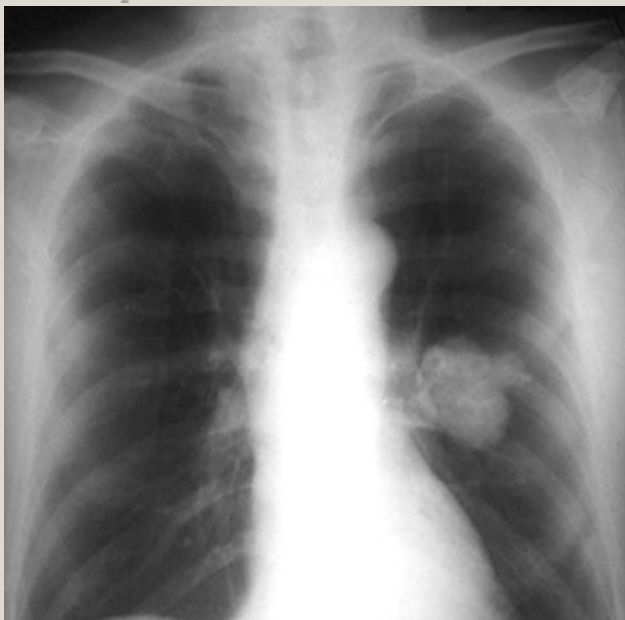## MASS

## DIFFUSE INFILTRATION

- The basic diagnostic instance is to detect an abnormality.
- In both of the cases, there is an **abnormal opacity**.

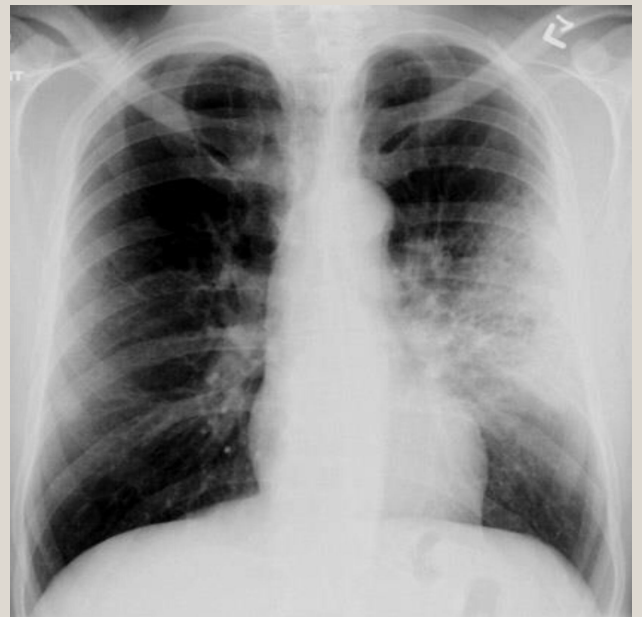• In this case, the opacity would best be described as a **mass because it has edges well-defined (clear outline) 3D structure.**

- We can see the mass in PA and lateral views which prove the 3D nature of the mass.
- In lateral view appears oval like shape "3D".



• In this case, has an opacity that is poorly defined (Not clear outline). This is airspace disease such as pneumonia (diffuse disease).

- Involve large space of the lung, flat and diffused.
- In lateral view there will be a change in its appearance.



# Solitary nodule in the lung

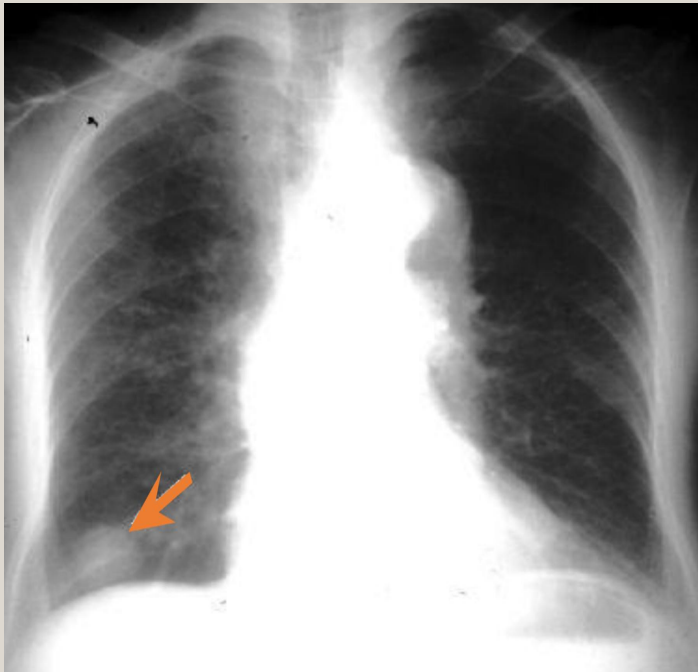
A solitary nodule in the lung can be totally innocuous or potentially a fatal lung cancer. After detection the initial step in analysis is to compare the film with prior films if available. A nodule that is unchanged for two years is almost certainly benign. Be sure to evaluate for the presence of **multiple nodules** as this finding would change the differential entirely.

- If the nodule is indeterminate after considering old films and calcification, subsequent steps in the work-up include ordering a CT and a tissue biopsy.

X-Ray can't detect nodules smaller than 1 cm so we do a CT to:

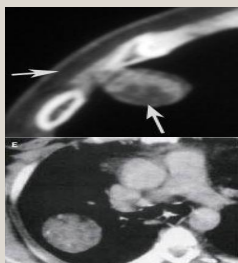
- make sure it's solitary.
- To characterise the nodule further.

## Mass



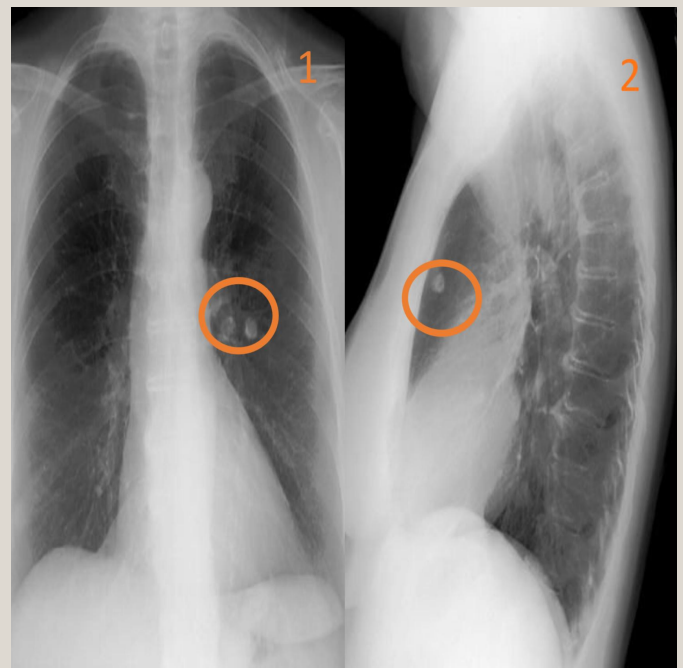
If nodule is  $> 3\text{cm}$  it's a mass  
Rounded structure (contains fat and soft tissue in other segments).

Trick: If the mass silhouette the hilum that means it's in the middle if not its in anterior or posterior. (Lateral view will further help in specifying the location).



We will discuss these pictures at the end.

## Nodules



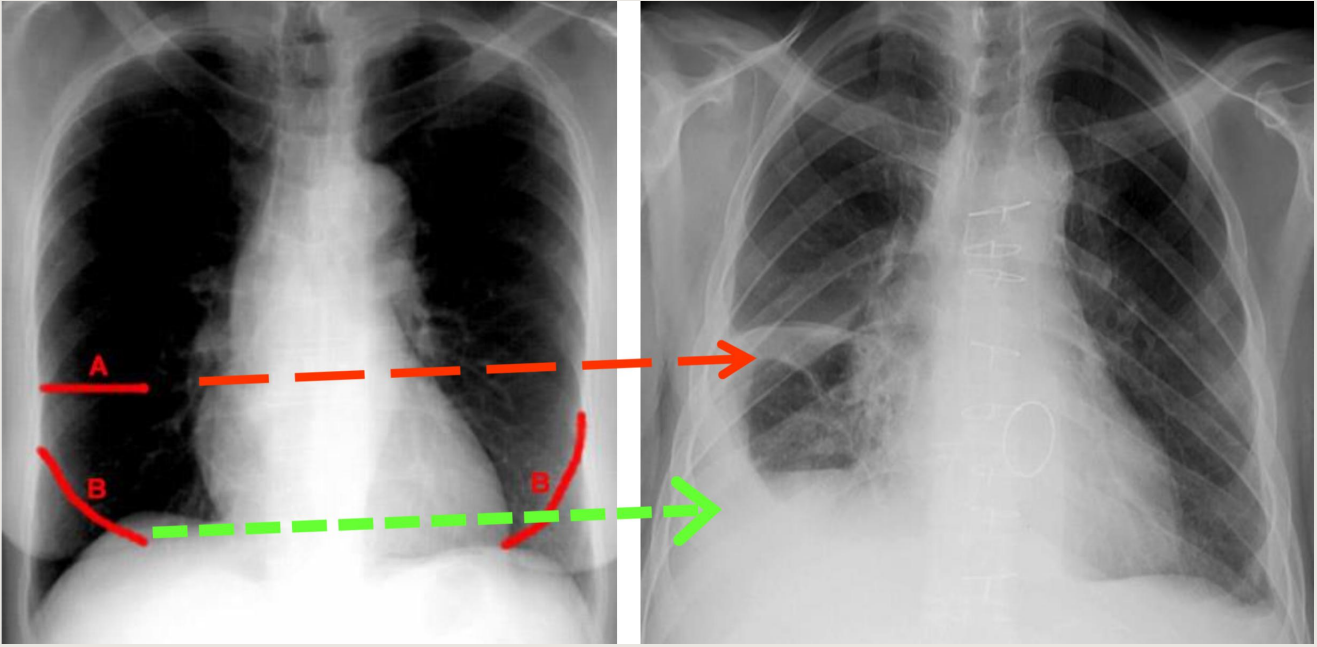
If you see Pic 1 you can tell that there is a small rounded lesion.. But is it a small infiltration or a mass lesion?

We will do lateral view Pic 2 and we will see the lesion in 3D, we can know what is the exact location of that nodule which is anterior lung solitary nodule.

So, in order to locate if it was anterior/posterior/middle we take lateral view.

# Fissures

---



Encysted pleural effusion of transverse fissure (A) and oblique fissures (B), so when we see the pathology the fissure outlines becomes more clearly.

- One of the most important things in lung X-Ray is the fissures: It has 2 benefits: It shows us the lung anatomy (upper, middle, lower lobes)
- The fissure are movable, if it moves up or down on x-ray it may indicates a pathology.

What is the most important sign for pleural effusion ?

**meniscus sign** a crescent-shaped inclusion of air surrounded by consolidated lung tissue.

## Recognizing air space disease:

---

Alveolar spaces filled with...something. Replacement of volume, there is no volume loss in consolidation.

Radiologist's report:

- "consolidation"
- "air space opacity"
- "fluffy density"
- "infiltrate"
- **Nonspecific**: Atelectasis, pneumonia, bleeding, edema, tumor.

# Atelectasis

(Which leads to collapse)

**Loss of volume** of lobe, segment or sub segment of the lung.

Example: **collapse** (lung)

# Pneumonia

(Which leads to consolidation)

**Loss of air** in lobe, segment or sub segment of the lung.

The air is replaced by something else

Example: **pneumonia** (lobe)

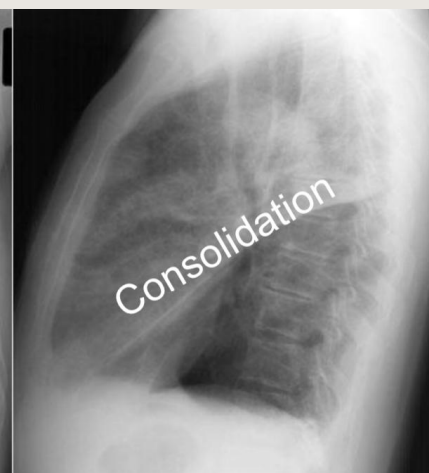
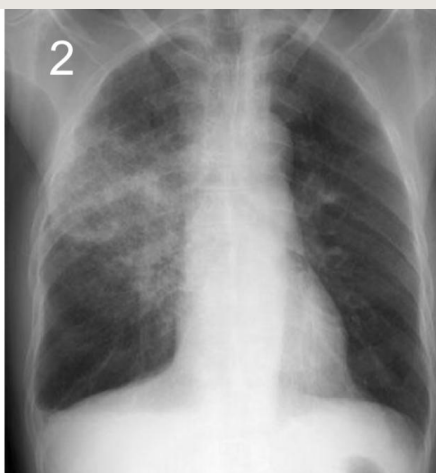
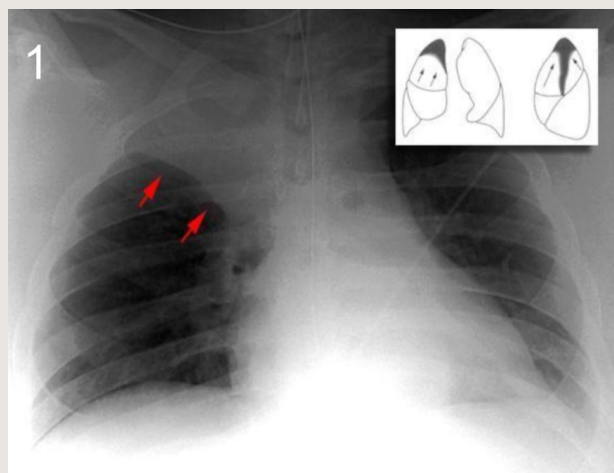
Major differentiating factors between atelectasis and pneumonia:

- **Volume loss.**
- Associated ipsilateral shift (trachea and pleura will try to fill the collapsed area).
- Linear, Wedge-shaped.
- Apex at hilum (points at hilum).

- **Normal or increase volume.**
- No shifting, or if present then contralateral.
- Consolidation, Air space process.
- Not centered at hilum.

Air bronchograms can occur in both.

Sometimes consolidation and collapse happens together but it's rare, so there will be loss of volume and some replacement of air.



**Pic 1:** chest x-ray shows consolidation in the right upper lobe and very clear line (red arrow) which represents the transverse fissure, these findings indicates upper lobe atelectasis.

**Pic 2:** diffuse area of consolidation in PA view, we don't know if there is loss of volume or not, so we will do lateral view.

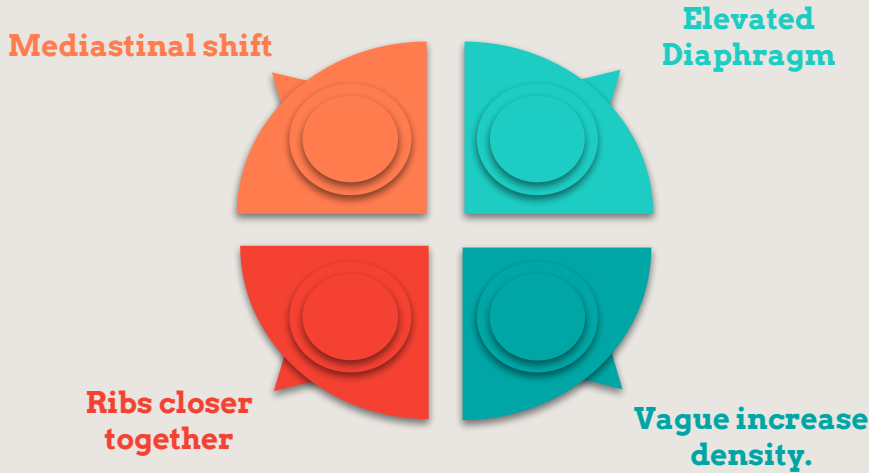
And the lateral view shows normal location of oblique fissure, so the area of consolidation that involve the upper and middle lobe is pneumonia (normally we don't see the oblique fissure this clear, but because of white contrasting pneumonia in the upper lobe, it will be obvious).



# Lobar Atelectasis

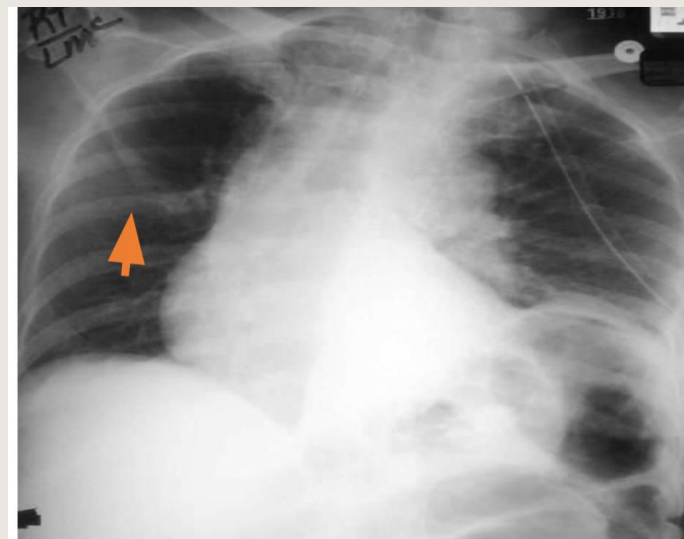
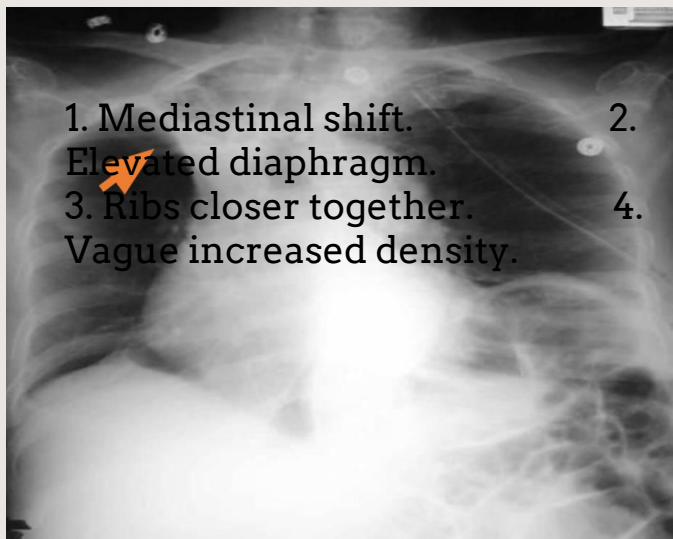
- **Best sign – shift of a fissure.**
- Rapid development and clearance.
- Air bronchograms if non-obstructive
- Secondary signs:

Air bronchograms means fluid inside the bronchioles, if there is obstruction in the level before the bronchioles, the fluid will not be able to reach it, so this sign will not be obvious.



all these 4 signs because of volume loss.

## 1- Right Upper lobe Atelectasis:



1. A patient presented with fever, they put endotracheal tube and after that, he got dyspnea back to its normal position. and chest x ray was done. They found: **right upper lobe atelectasis**. The patient took antibiotic and the proper treatment. They also removed the tube and they did follow up chest x ray.

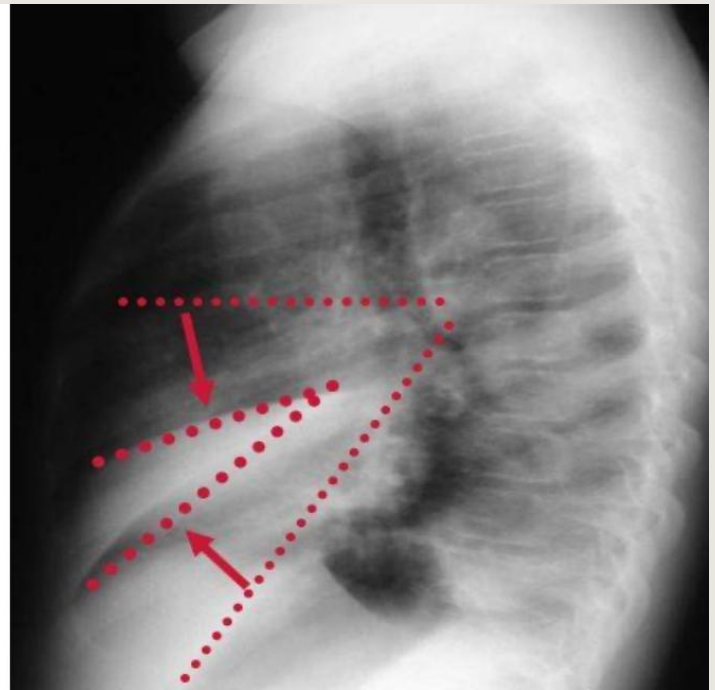
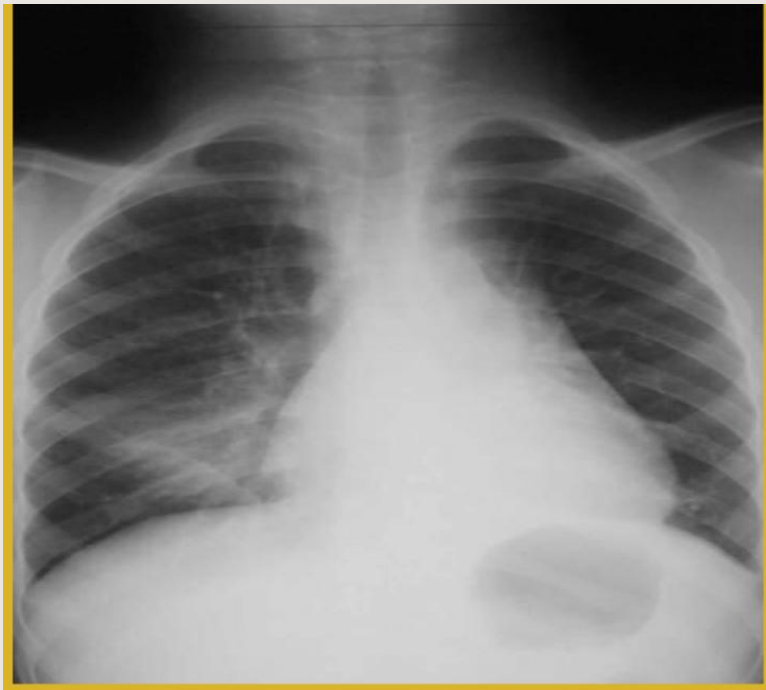2. They found the transverse line come

When we ask you to describe the image, use the word (opacity) & don't give a diagnosis straight forward.

with associated ipsilateral dislocation of the trachea



## 2- Right middle lobe atelectasis:

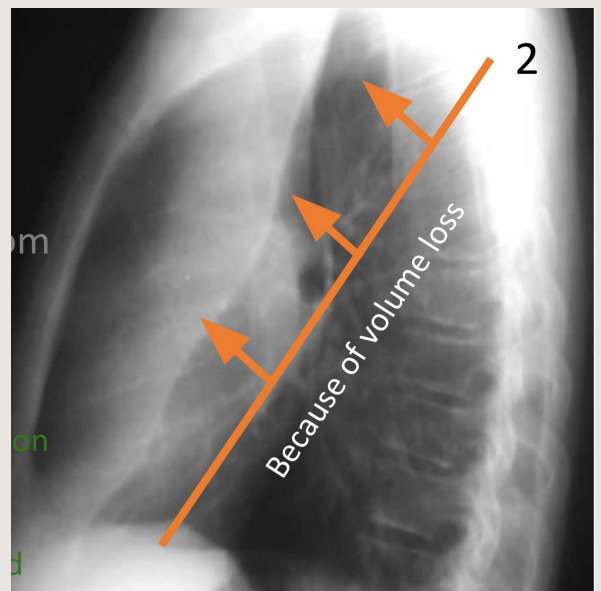
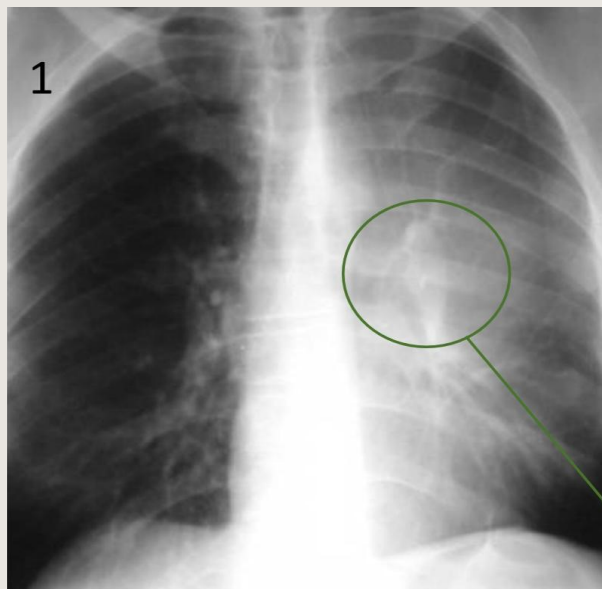


As far as I know there is 2 pathologie here: right middle lobe collapse and right lower lobe consolidation.

In the middle area of the right lung there is opacity, is it collapse?

We did lateral view and **we can see that the transverse and oblique fissure moved from their normal position which indicates right middle lobe atelectasis.**

## 3- Left Upper lobe Atelectasis:



"Hilum overlay sign" the consolidation is either anterior/posterior to the hilum and since the hilum is not silhouetted by the consolidation and the consolidation.

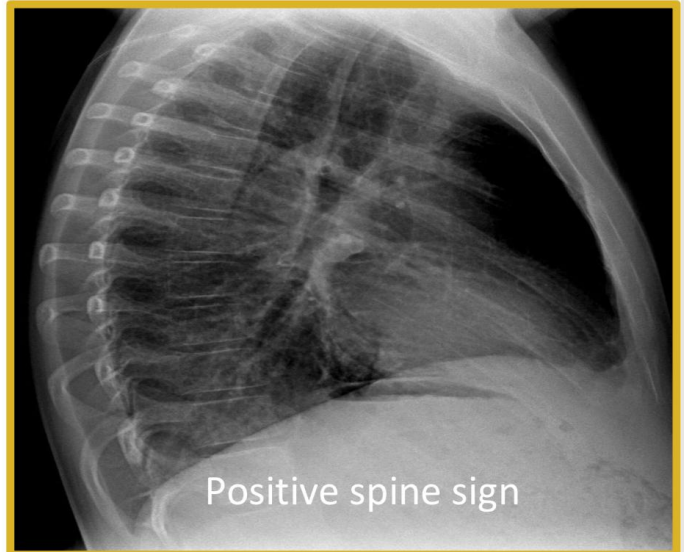
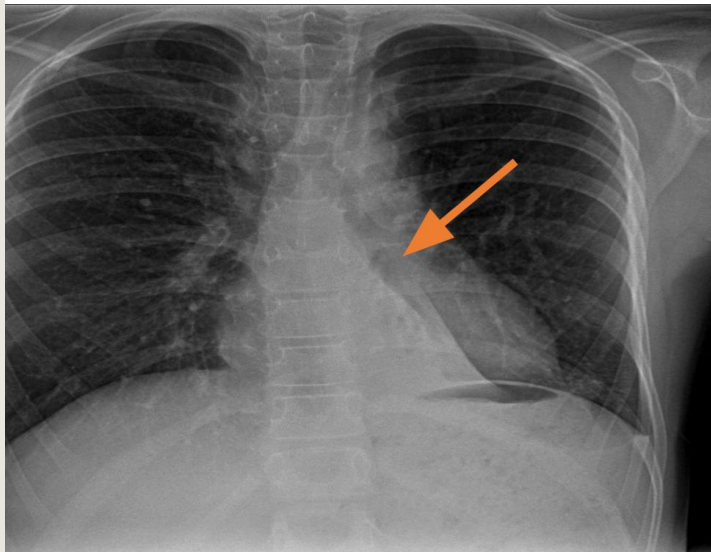
silhouettes the left cardiac border we can say it's anterior to the hilum "left upper lobe collapse".

1: there is area of consolidation on the left lung, we will do lateral view.

Pic 2: lateral view of the lung shows a clear cutline which is the oblique fissure moved from its normal position (normal oblique line crosses the lung hilum)

# Left Lower Lobe COLLAPSE:

Further Explanation later in the end.



Atelectatic left lower lobe silhouette the left hemidiaphragm:

- Well defined border, margined by fissure.
- Volume loss because the fissure shifted medially.
- Points toward the hilum.
  - The lungs are filled of air and also the bronchi, we can't see bronchial tree because it's also filled with air as the lungs, so both appear in black color while vessels appears in white because it is filled with blood.

## Pneumonia

-Signs of pneumonia. All are signs of any air space process.

Dx of pneumonia Depends on appropriate clinical scenario.

01

Air bronchogram sign

It's either collapse or consolidation

Silhouette  
Positive or negative

02

03

Dense Hilum

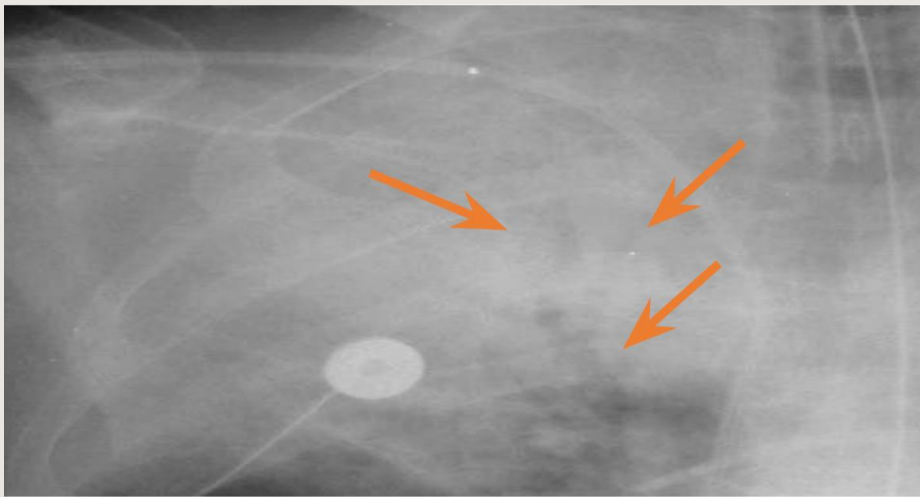
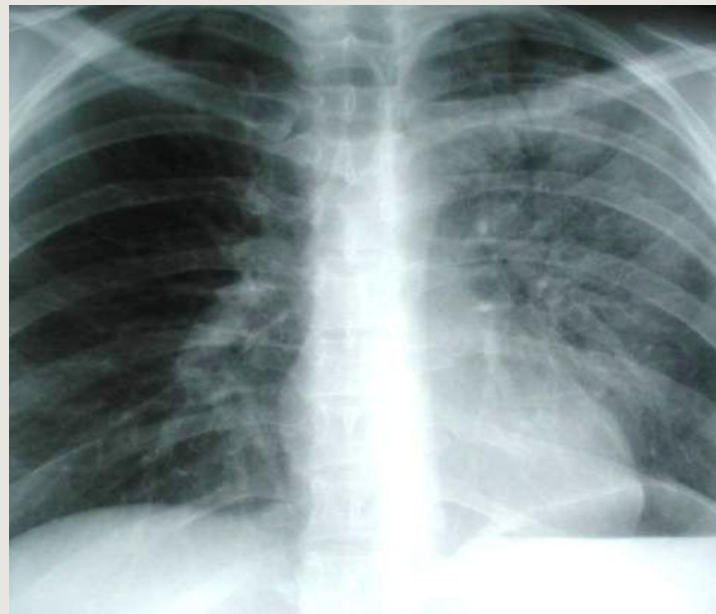
Spine sign  
Dorsal spine sign

04

# AIR-BRONCHOGRAM

it is a sign not a modality

The Right lung is normal; no obvious bronchial tree, all air spaces in normal lung will have the color black on x-ray because it contains air and also bronchial tree will appear black because it contains air.



## Pseudomonas pneumonia

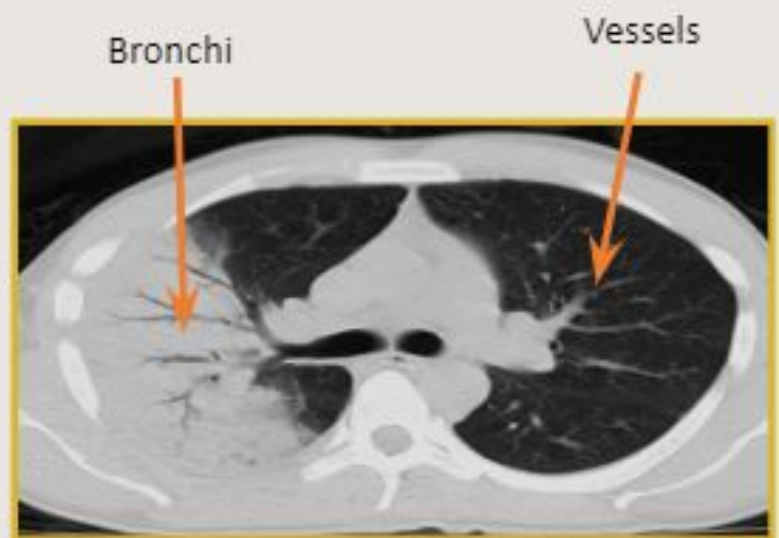
Air consolidation in the right upper lobe and we can see some dark grey lines on x-ray (arrows) which represent the the bronchial tree.

AIR-BRONCHOGRAM very clear it's a sign of pneumonia.

# Air bronchograms – CT

The Left side is completely healthy lung and we can't see the bronchial tree clearly because the whole lung contains air and the bronchial tree contains air so they will be all black.

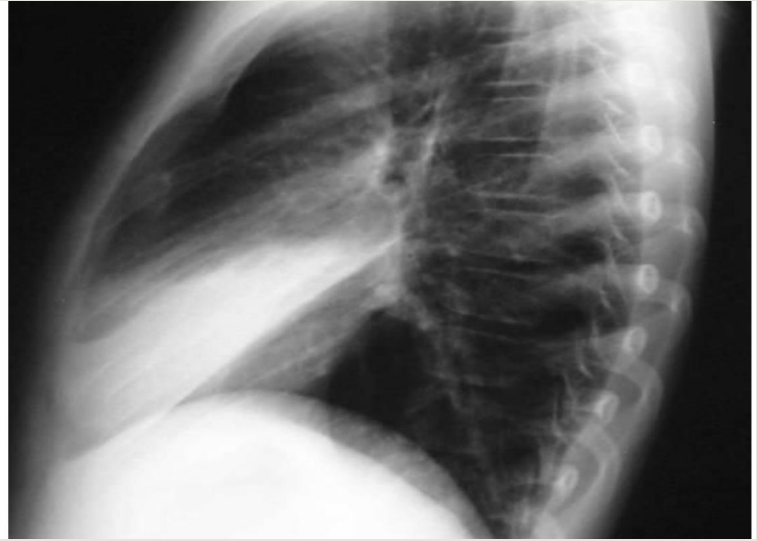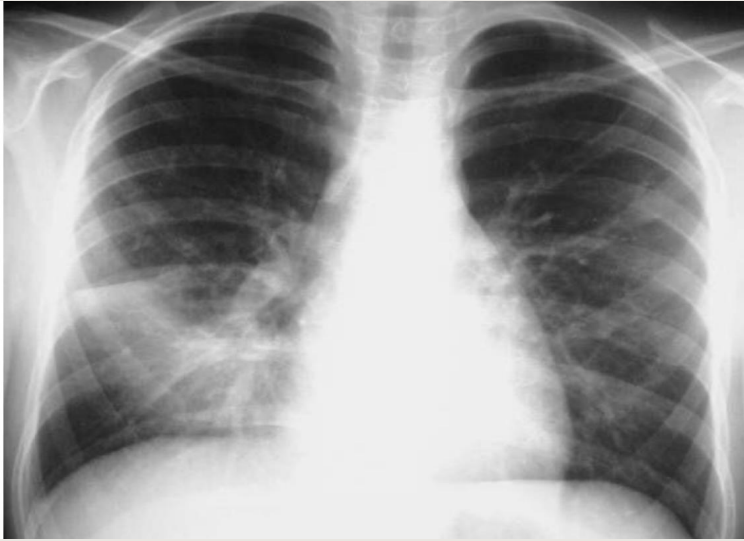
The Right diseased lung we see consolidation caused by loss of air in the lung so it will be white, but the bronchial tree is still have some air so it will be back.



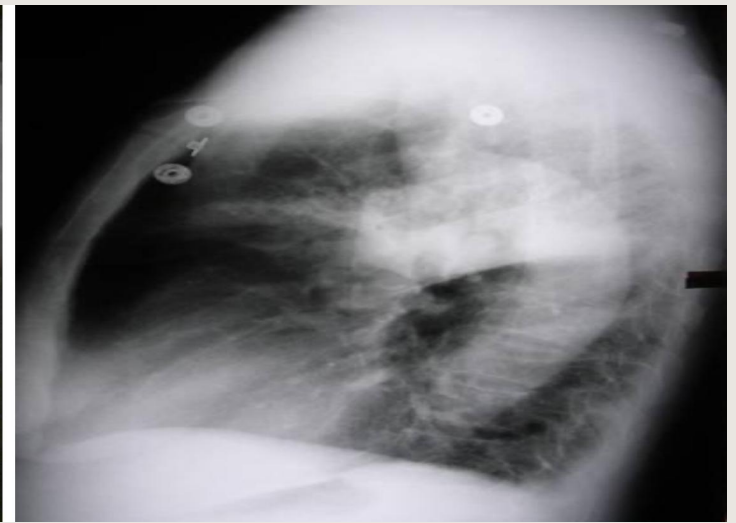
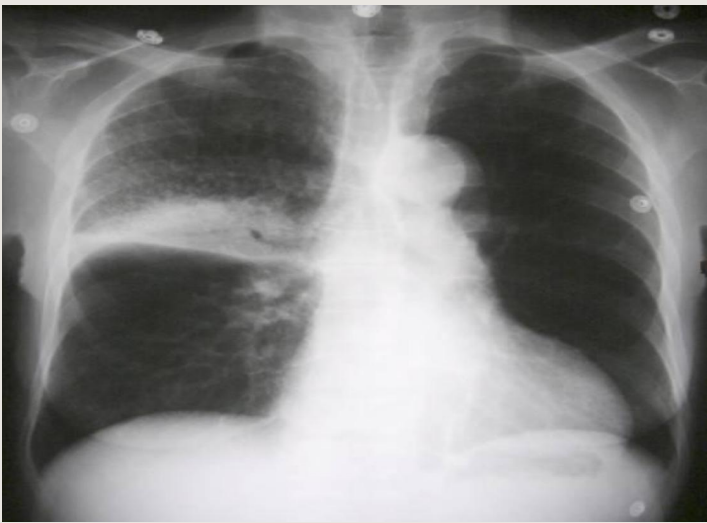Pneumonia



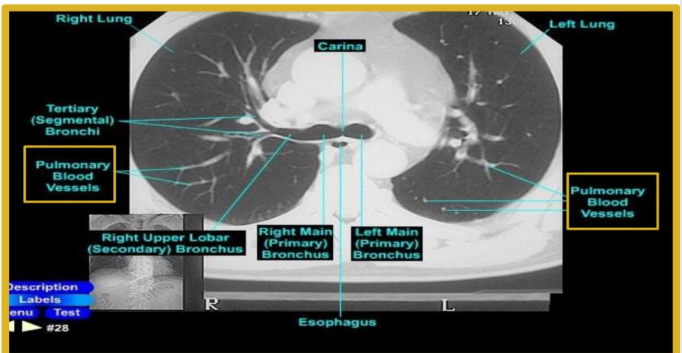
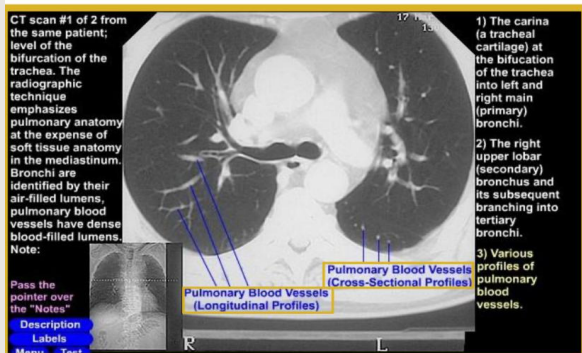
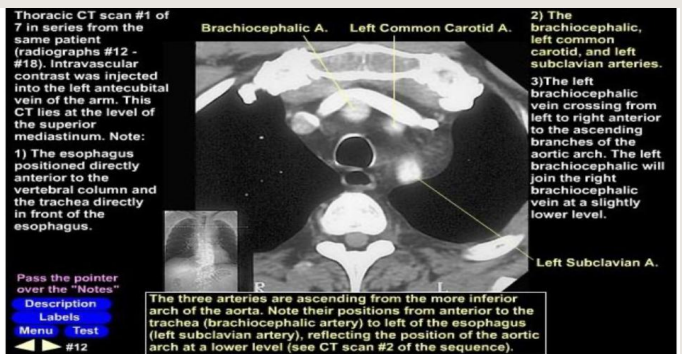
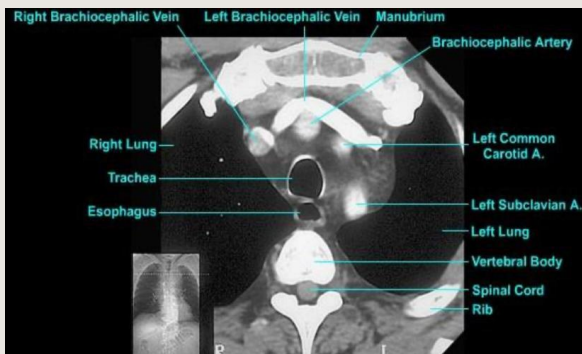
# Right middle lobe (Pneumonia)



# Right upper lobe (Pneumonia)



# CT anatomy

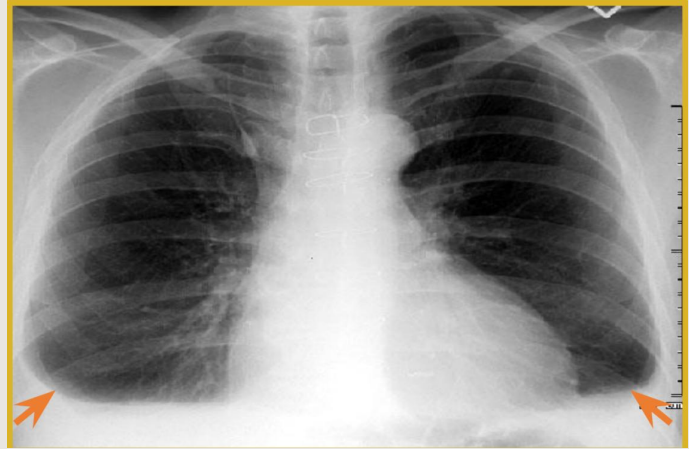


# PLEURAL EFFUSION:

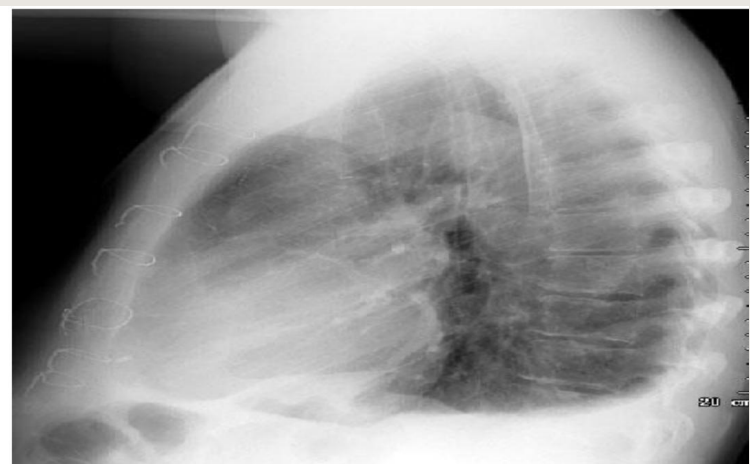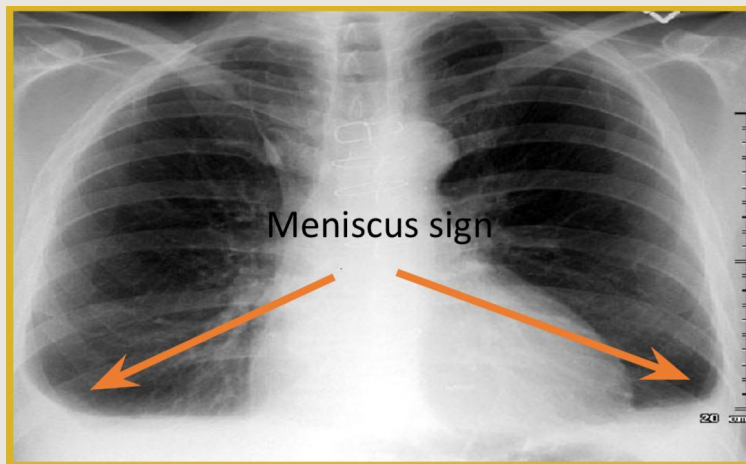
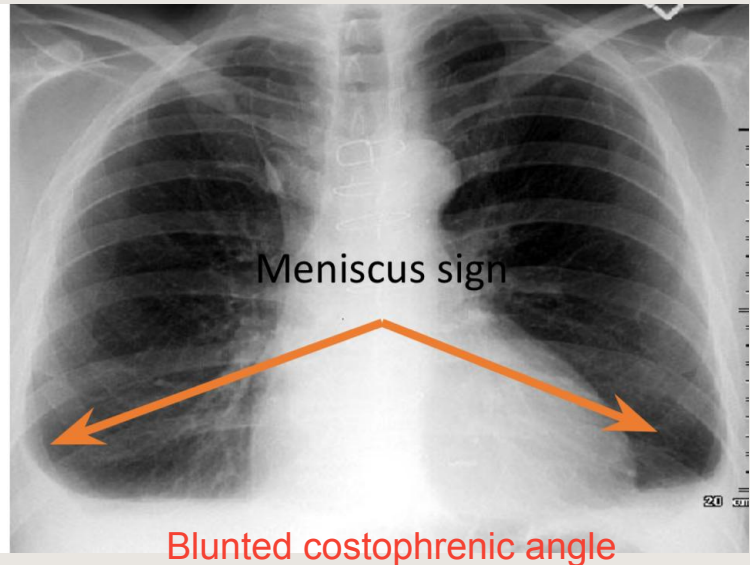
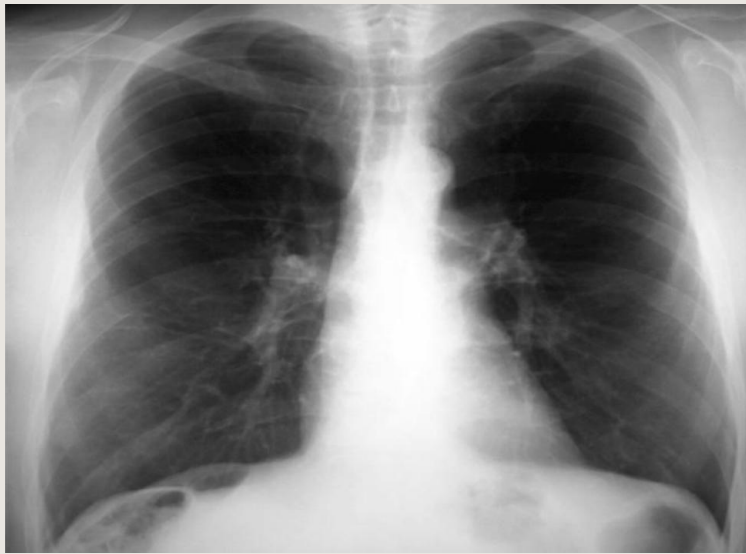what is pleural effusion?

we have little fluid in the pleural cavity. in normal image of chest we are suppose to see costophrenic angle peaks but once there is a fluid in the pleural cavity it causes blunted costophrenic angle.

So we have bilateral costophrenic angle blunting.

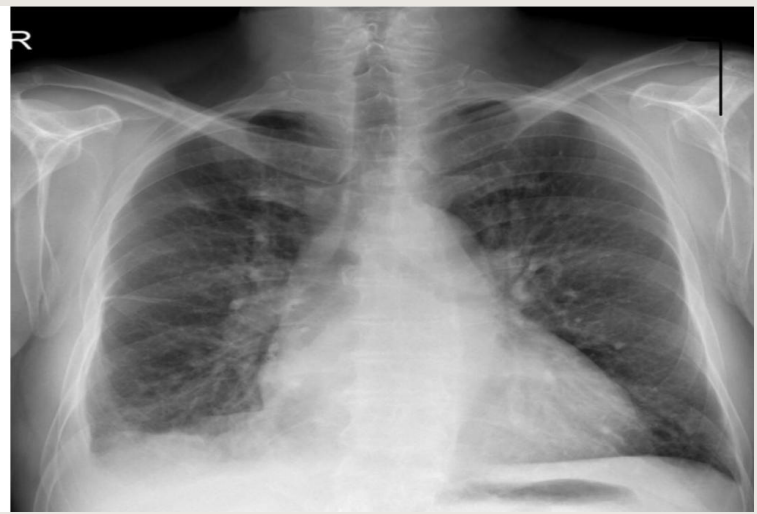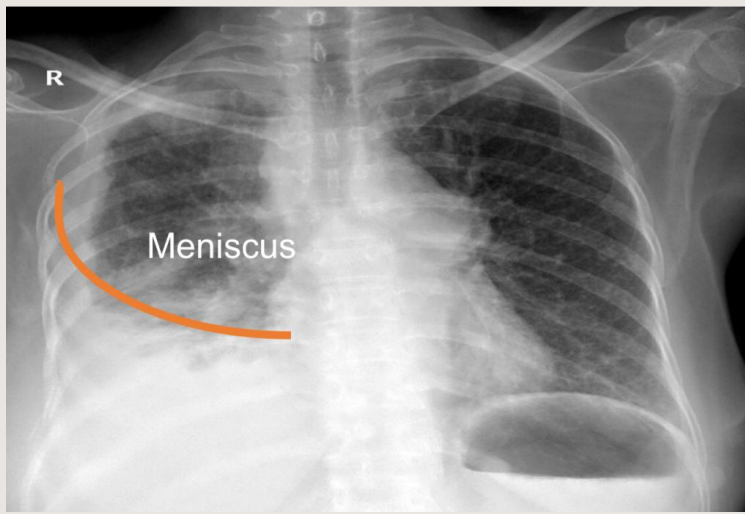


## COMPARE COSTO-PHRENIC ANGLES



On an upright film, an effusion will cause blunting on the lateral and if large enough, the posterior costophrenic sulci. Sometimes a depression of the involved diaphragm will occur. A large effusion can lead to a mediastinal shift away from the effusion and opacity the hemithorax. Approximately 200-250 ml of fluid are needed to detect an effusion in the frontal film vs. approximately 50-75ml for the lateral. Larger effusions, especially if unilateral, are more likely to be caused by malignancy than smaller ones.





once fluid increase it goes up in curve line level, it is not like a cup of water with flat line level.

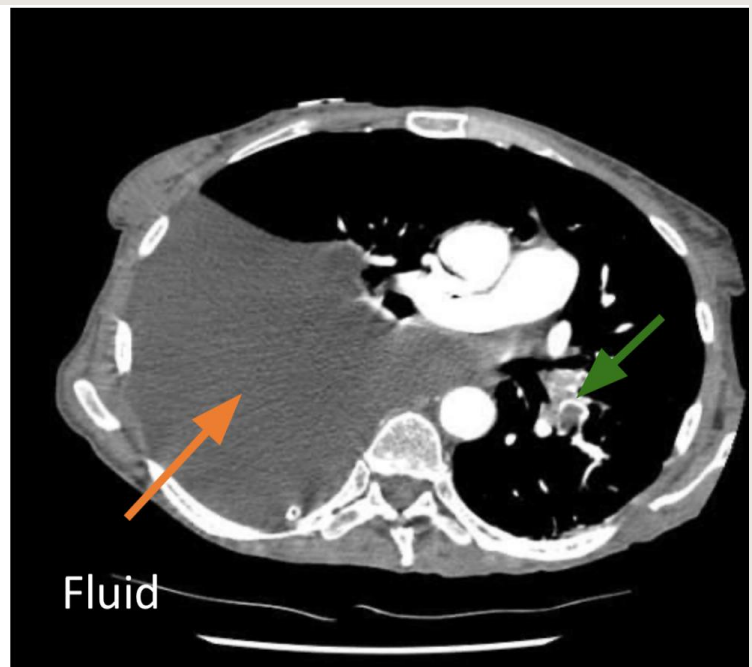
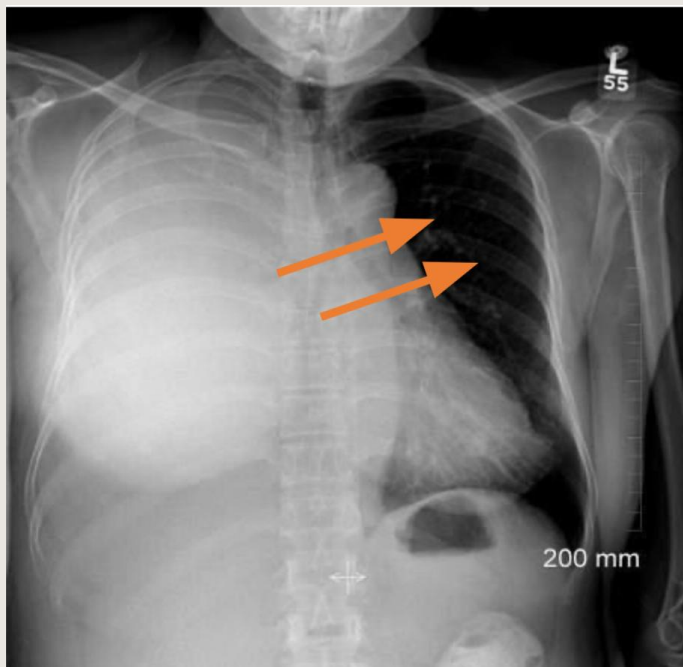
The doctor mentioned an experience in school we used to do it, we bring cup of water half empty when we see it from outside we see fluid level in flat line, but if we cover and sucked air inside it it goes up in curve line .

because there is no air & no pressure so it will be curved.

Always fluid in costophrenic angle given curve line however this is mild or moderate pleural effusion.

If we have mild pleural effusion we will get curve like in right picture, if we have moderate pleural effusion we will get picture like in the left.

## SEVER PLEURAL EFFUSION :

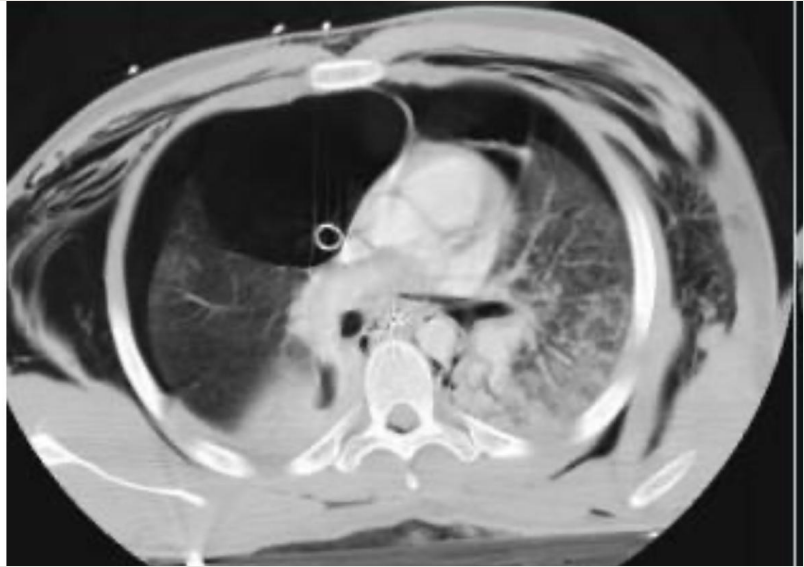
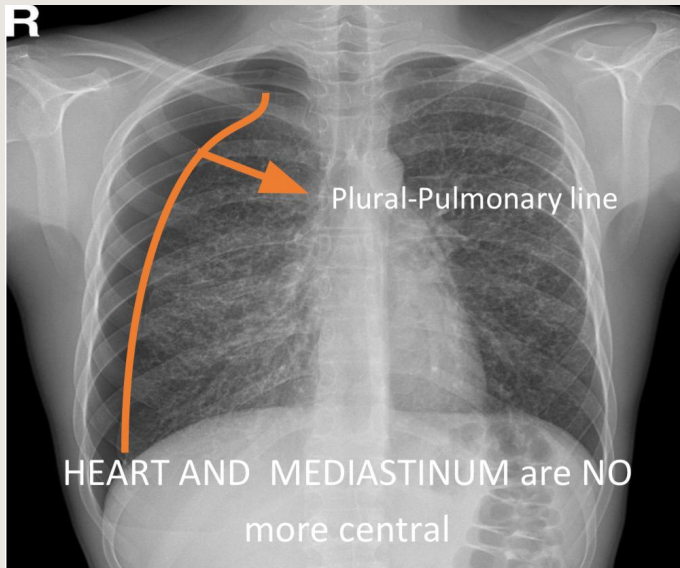


Unilateral pleural effusion .. think of malignancy. The reason for this massive mediastinal shift is the massive fluid accumulation.

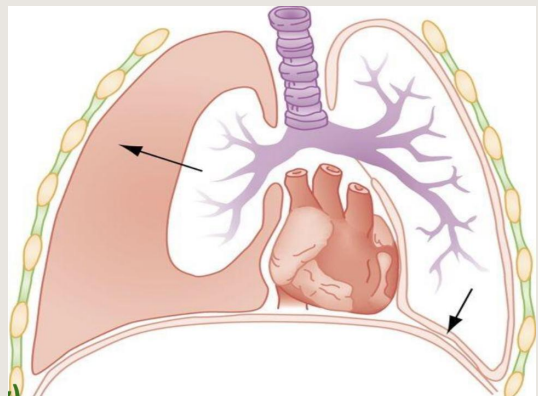
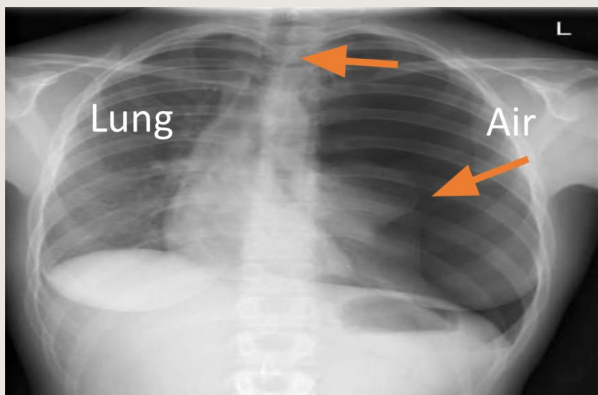
Green arrow: Notice that the artery is blocked with a thrombus.



# PNEUMOTHORAX



- A pneumothorax is defined as air inside the thoracic cavity but outside the lung.
- There will be loss of lung markings (blood vessels) and it will appear as extremely black structure.
- A spontaneous pneumothorax is one that occurs without an obvious inciting incident.



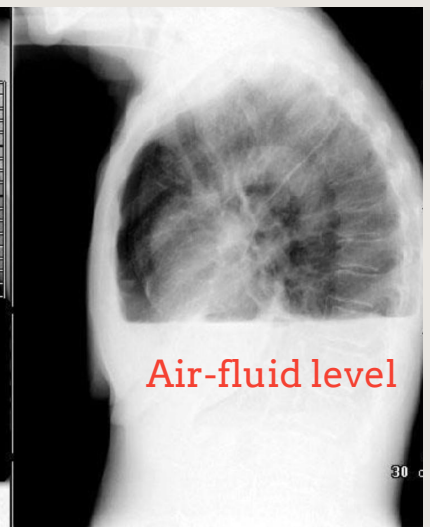
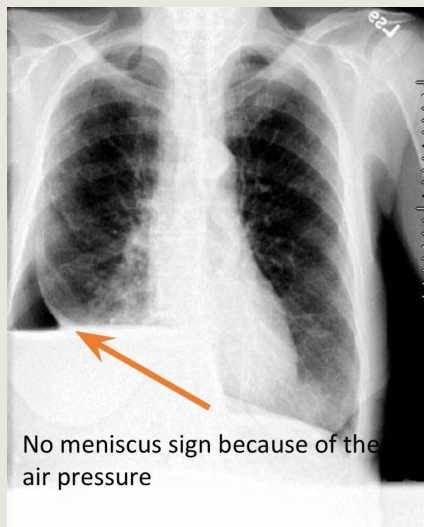
This is tension pneumothorax (clinical emergency)

- Left pneumothorax (no lung margin)
- there is a flattening of the left hemidiaphragm - the normal hump is lost -
- there is widening of intercostal spaces (when you do examination you will hear the chest hyperresonance)

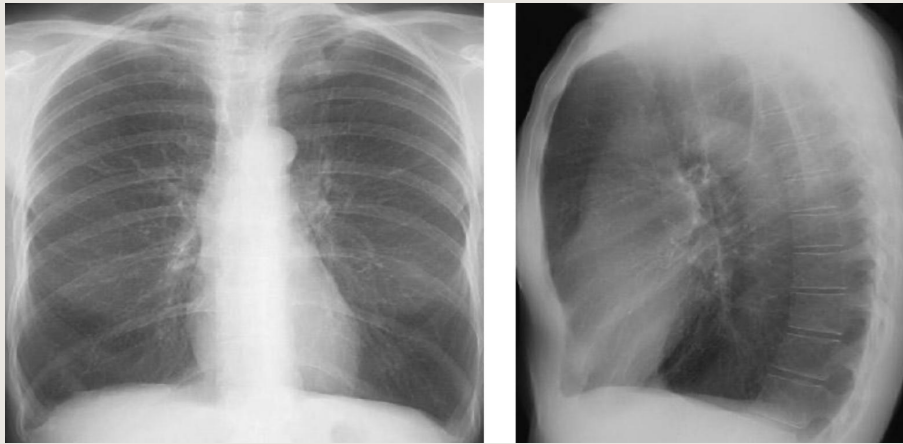## Hydro-pneumo-thorax:

- When will have air fluid level appears flat as this image?

**In Hydro-pneumo-thorax** remember the example of covered cup filled with fluid. we have three things in right side: air – fluid level, above it jet black air so we have fluid, air and the lung. Hydro-pneumothorax can be a complication of TB or AIDS



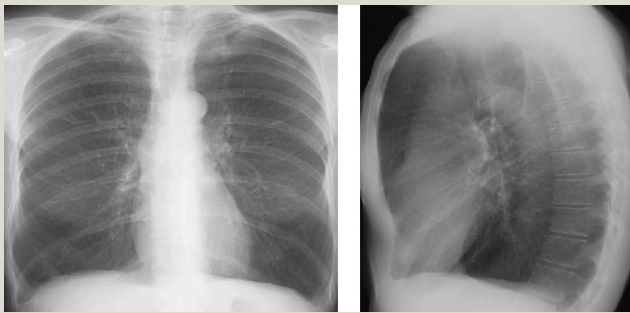
# EMPHYSEMA



We usually see 8-10 ribs but here we can see more than 10 ribs (11) due to hyperinflation.

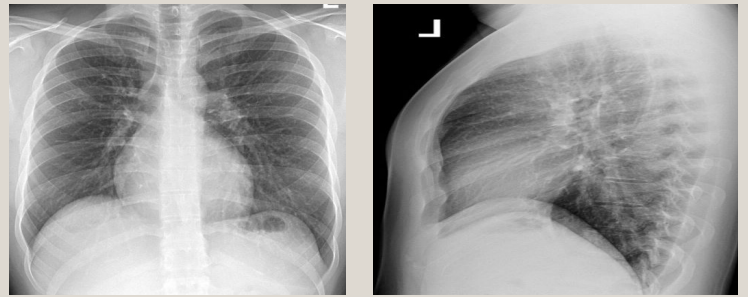- Increased Lung Volume:
  1. Flattened Diaphragm
  2. Increase in Retrosternal Airspace
  3. Barrel chest
- Small Vessels.
- Small, narrow cardiac shadow.

## Emphysema



- Diaphragmatic cupola flattened.
- Heart decreased in size.
- Retrosternal air increased.
- Barrel chest.

## Normal



- Normally curved diaphragmatic cupola
- Normal sized heart.

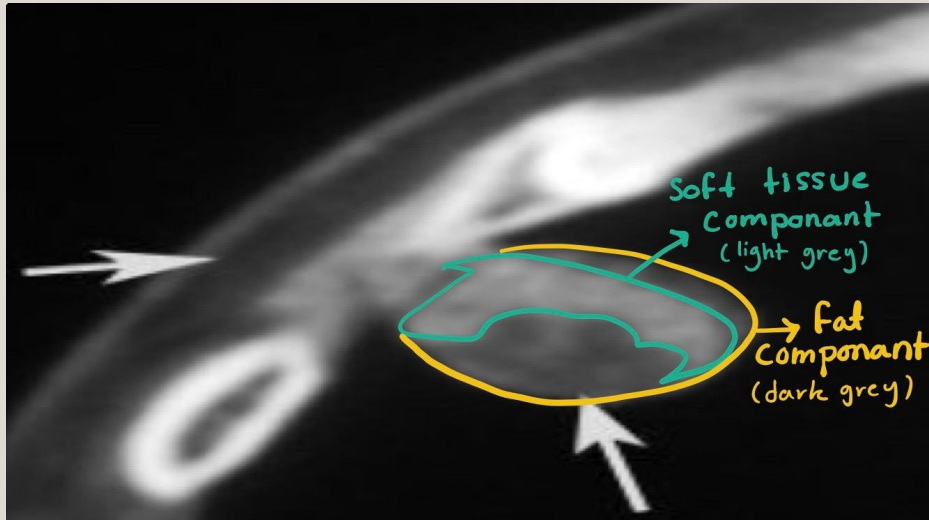
Emphysema is commonly seen on CXR as diffuse hyperinflation with flattening of diaphragms, increased retrosternal space, bullae (lucent, air-containing spaces that have no vessels that are not perfused) and enlargement of PA/RV (secondary to chronic hypoxia) an entity also known as cor pulmonale. Hyperinflation and bullae are the best radiographic predictors of emphysema.

Clinical signs of emphysema :

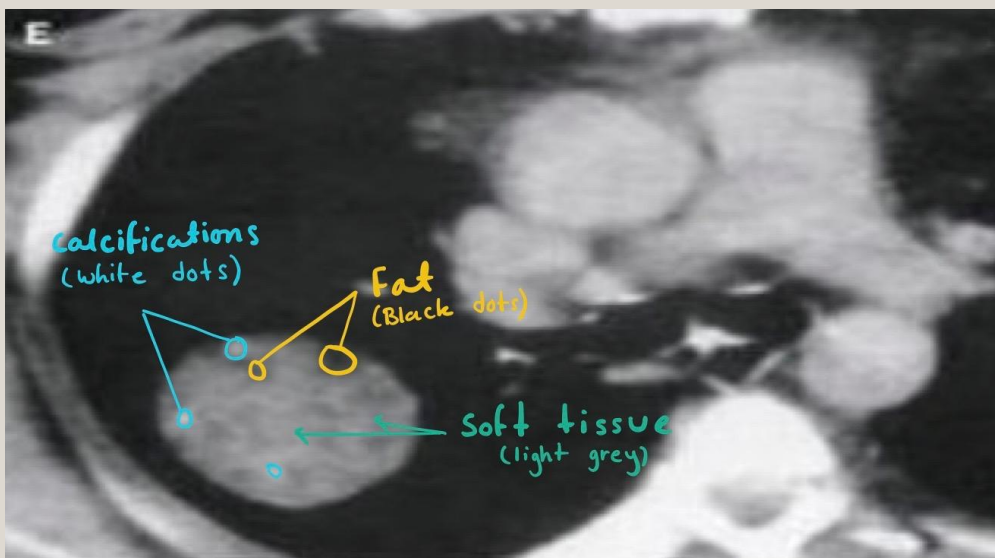
1- Shortness of breath. 2- Cyanosis.

Emphysema is loss of elastic recoil of the lung with destruction of pulmonary capillary bed and alveolar septa. it is caused most often by cigarette smoking and less commonly by alpha-1antitrypsin deficiency.

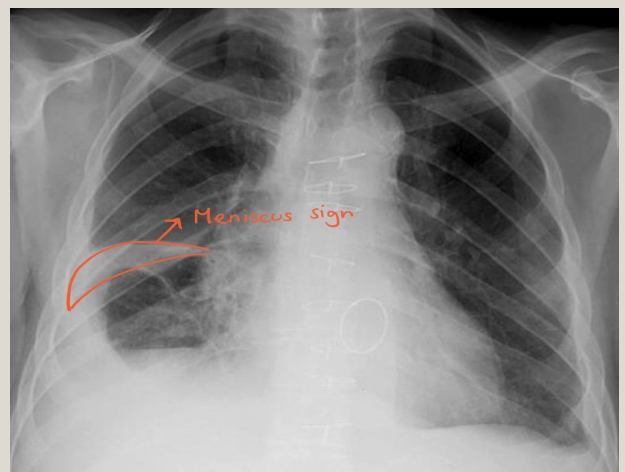
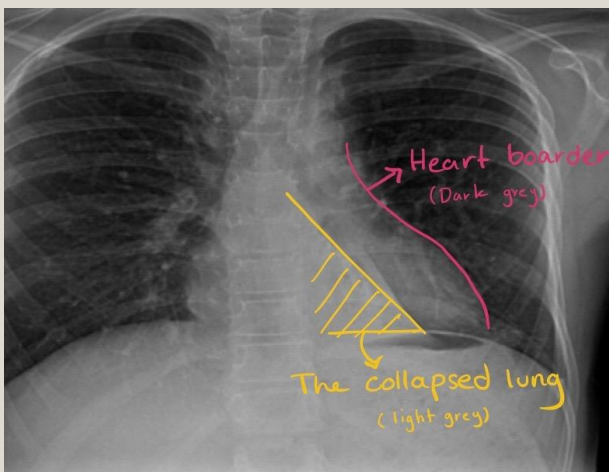
# Team 436 Explaining notes



Notice that the two arrows points to the same color gradient, which tells as that we know it is fat (Right arrow) because it has the same color of the subcutaneous fat (Left arrow) once you see fat, you don't need to do biopsy to rule out any other pathology



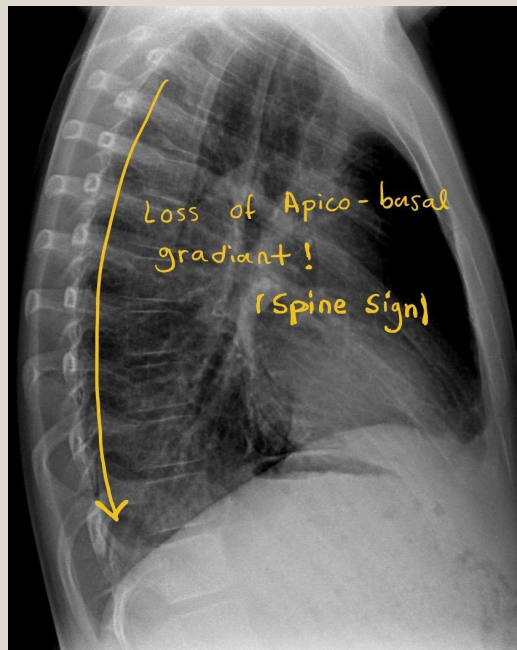
When the fat is a component of a lesion or a mass, it is a sign that it is benign





# Team 436 Explaining notes

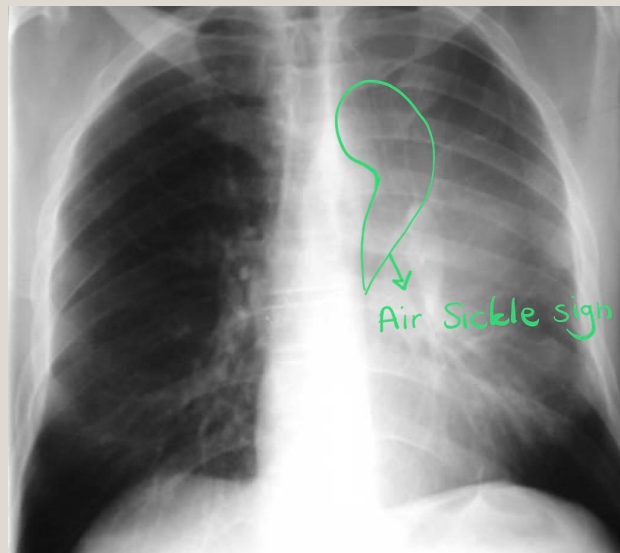
## Dorsal Spine Sign:



The whole spine appears with no change in color gradient. (It could be grey or white, but no change in gradient).

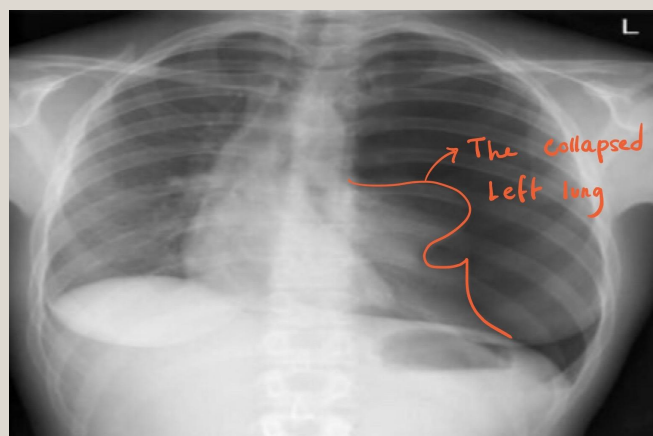
[Click here for more!](#)

## Air sickle sign:



Air crescent which may be seen between the aortic arch and medial border of the collapsed lung especially with the left lung.

## Pneumothorax slide

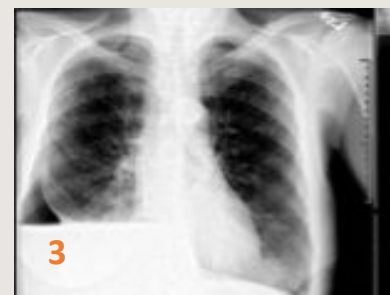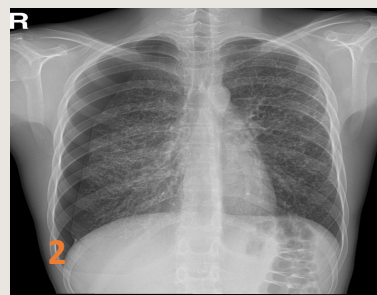
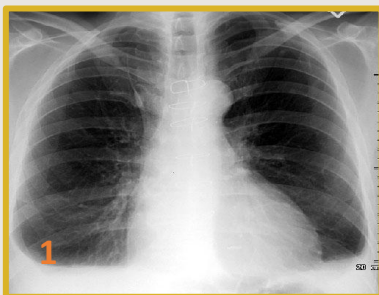


The lung condensed in a small area which increases its thickness and appear whiter than the surroundings.

# SUMMARY

- Mass/nodule have opacity that is well defined “clear outline”.
- Diffuse infiltration has an opacity that is poorly defined “not clear outline”.
- The difference between the mass and the nodule is the size “3cm”.

Atelectasis	Pneumonia
<p>Volume loss results in:</p> <ul style="list-style-type: none"><li>• Mediastinal shift.</li><li>• Elevated diaphragm.</li><li>• Ribs becomes closer.</li><li>• Vague increased density.</li><li>• Lobes expansion and fissures changing.</li></ul>	<ul style="list-style-type: none"><li>• Normal or increased volume.</li><li>• Fissures will stay the same.</li><li>• <b>Dx of pneumonia depends on appropriate clinical scenario.</b></li></ul>
Air bronchogram - Dense hilum - Silhouette - Spine sign	



1. **Pleural effusion:** fluid in the in the pleural cavity.
2. **Pneumothorax:** air inside the thoracic cavity but outside the lung.
3. **Hydropneumothorax:** the presence of both air and fluid within the pleural space.

**Emphysema:** pathologically defined as an abnormal permanent enlargement of air spaces distal to the terminal bronchioles, accompanied by the destruction of alveolar walls and without obvious fibrosis

It will cause:

Increased Lung Volume - Flattened diaphragm - increase in retrosternal air space - Barrel chest - small vessels - small & narrow cardiac shadow.

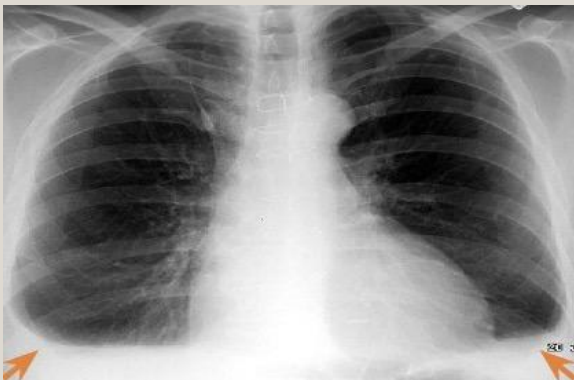
# QUESTIONS

1. The difference between mass and nodule is ?

- a) Size
- b) Density
- c) Location
- d) Quantity

2. Which of the following is true about atelectasis?

- a) Size
- b) Density
- c) Location
- d) Quantity



3. What is the name of the sign in the showing radiograph, and what does it indicate?

Answers :

- 1-A
- 2-B
- 3- Meniscus sign And it indicate pleural effusion.



help us improve with your feedback:



RadiologyRadiology437@gmail.com



@437Radiology



**please fill this very very quick form**



## References

- ✓ Slides
- ✓ 436 Teamwork



# THANK YOU FOR CHECKING OUR WORK

