




MED437
King Saud University



RADIOLOGY



TEAM

Nuclear medicine in Thyroid & parathyroid & adrenal glands

436's objectives:

- How is the thyroid scan performed?
- When is thyroid scanning helpful?
- What is significant about whether a nodule is "hot" or "cold"?
- What is the role of nuclear medicine in the treatment of thyroid disorders?
- Describe the physiologic principles of underlying Tc-99m parathyroid scintigraphy.
- Describe the various methods used for parathyroid scintigraphy with emphasis on SPECT and SPECT /CT.
- Identify the common imaging features of pathologic parathyroid glands.
 - Discuss causes of false negative and false positive scans.

Sources

Lecturer:

[Saleh Othman](#)

Same 436 lecture Slides/team:

YES + [An extra new slide.](#)

Done by:



Dawood Ismail

Saleh mahjoub

Maan Shukr

Faisal AlQarni

Revised by: Yazeed Al-Dossare



Lecture outline

1. Nuclear medicine procedure.
 - a. What are nuclear medicine methods.
 - b. Physical Properties SPECT Radionuclides
 - c. Physical Properties of Positron Emitting (PET) Radionuclides.

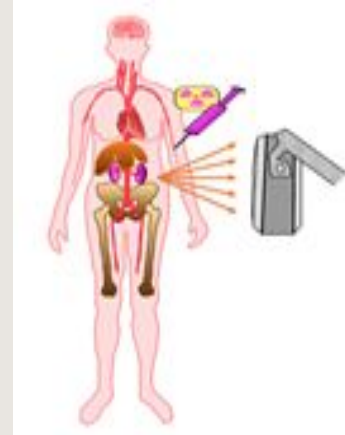2. Thyroid scan procedure.
 - a. Normal Values Of Thyroid Uptake.
 - b. Thyroid Scan Procedure (Cont.)
 - c. Normal Tc-99m Thyroid Scan and Uptake
 - d. THYROID UPTAKE MEASUREMENT (I-123 Sodium Iodide).
 - e. I-123 or I-131 Whole Body Scan (WBS) - "Planar Vs SPECT CT"

3. Parathyroid scan.
 - a. Ectopic parathyroid glands:
 - b. Parathyroid Scan Techniques (very imp)
 - c. Parathyroid imaging/scan:
 - d. Tc-99m Tetrofosmin (Dual Phase) - Dual phase MIBI Scan
 - e. Tc-99m Sestamibi
 - f. Sestamibi Dual Phase (Planar vs SPECT CT)

4. 18F-flurocholine PET/CT "NEW"

Nuclear Medicine Procedure



- Patient ingest or is injected with small amount of radioactive material, known as radiopharmaceuticals which have short half-lives to not harm the patient.
- Radiopharmaceuticals localizes in patients according to metabolic properties of that drug, so the substance taken will go to a certain organ and concentrate in it... each organ has its own radiopharmaceuticals ex: if we give the patient phosphate or calcium they will go to the bone, so they bind these with the radioactive materials (so they take the radioactive material to the bone and the bone will emit rays)
- Radioactivity decays, emitting gamma rays.
- Gamma rays that exit the patient are imaged, Detecting the radiation using a Gamma Camera (the grey box in the image) where the patient himself is the source of radiation.



remember: nuclear medicine is best for assessing function but isn't good at assessing anatomy! so recently they combined CT and nuclear in the same device (in SPECT-CT and PET-CT) to localise where the abnormal tracer is concentrated, because CT will give better details about anatomy.

Iodine is the Radiopharmaceuticals for thyroid gland.

What are the nuclear medicine imaging methods?

	Types	
Onco PET	PET : 3D PET -CT : 3D (Function and anatomy). PET: Positron emission tomography (2 photons)	
Conventional tumor imaging	Planar: 2D. SPECT: 3D. SPECT-CT : 3D (Function and anatomy). SPECT: Single photon emission computed tomography.	 <p>Dual head with added CT</p>

There are two groups of radioactive materials that are used in nuclear medicine:
SPECT radionuclides and positron emitting (PET) radionuclides

Physical Properties SPECT Radionuclides

Radionuclide	T/2 physical half life	Type of radiation	E(kev)
Technitium 99m(Tc-99m)	6 hrs	Gamma	140
Iodine I131	8 days	Gamma and Beta	364/606
Iodine I123	13.2 hrs	Gamma	159
Gallium Citrate (Ga-67)	78.3 hrs	Gamma	90,190,290
Thallium Chloride 201 (Tl201)	73.1 hrs	X-ray	68-83
Indium 111 (In 111)	2.8 days	Gamma	173,247
Xenon 133	5.2 days	Gamma	81
Krypton 81m	13 sec	Gamma	190

- We are required to know the half life of the **first three** (in red) because they are the most commonly used. One day when you order a nuclear study the patient will ask you **how much will the material stay in my body?**
- 80% of procedures in KCUH uses (Tc-99m).
- (I-131) is used as therapy for hyperthyroidism and thyroid cancer (Beta rays) while (I-123) is used for diagnosis of thyroid problems and cancer.

Physical Properties of Positron Emitting (PET) Radionuclides:

Radionuclide	T/2 physical	positron energy	Productivity
Carbon 11	20mins	0.96	accelerator
Nitrogen-13	10mins	1.19	accelerator
Oxygen-15	2mins	1.73	accelerator
Fluorine 18	110 mins	0.635	accelerator
Gallium 68	68 mins	1.9	generator (germanium 68)
Rubidium 82	1.3mins	3.15	generator (strontium-82)

- Fluorine-18 is labeled with glucose. so wherever there is increased glucose consumption in the body it will be taken up (as in tumors where there is increased glycolysis)
- Doctor said: "You are required to know the **two** in red".

Thyroid Scan Procedure

	Tc-99m Pertechnetate	I-123
Dose	0.5-4.0 mCi given IV that means of the injected amount only 0.5-4.0% of the tracer will appear	0.5 mCi orally
Half life	6 Hours	13 Hours
Cost	Not Expensive (Generator) Available all the time "Quick scan".	Expensive (it needs Cyclotrone) Which is Only available once a week
Time of imaging	20 min post injection <u>only one visit</u> It only take half an hour, the patient comes to department then we inject the material after 20 min an image will be taken; THAT'S IT.	6 and 24 hours post ingestion <u>3 visits</u> : 1- take iodine, 2- 6hrs 3- 24hrs. While here the patient come to the department take the capsule/injection then has to come after 6 hours then again after 24 hours.
Remarks	Trapped only not organified It only gives information about the trapping (step before organification)	Trapped AND organified Gives information about trapping and about organification which is the synthesis of thyroxine (T4, T3) Its benefits comes when you're looking for enzymes, hormones deficiencies remember the physiology of thyroxine production (iodine is first trapped in thyroid gland then organified to make thyroxine) if you take a sample after iodine 123, you'll notice that thyroxine is radioactive.

When Iodine is trapped by the thyroid gland thyroid hormones are synthesized, then it would be organified to form Thyroxine. In Tc- 99m it is not organified so when there is problem in organification, we can't use it.

To assess the organification we use I- 123 not technetium.

Normal Values Of Thyroid Uptake.

- **I131 OR I-123 RAIU (4 & 24 hours):**
Normal 4 hour RAIU : 5 - 15%
Normal 24 hour RAIU : 8 - 35%
- **Tc- 99m Uptake (20 min Uptake):**
Normal : 0.5 - 4 .0%

Thyroid Scan Procedure (Cont.)

Radiopharmaceutical and doses:

1- Tc-99m as sodium pertechnetate 0.5 -4.0 mCi given Intravenously.

or,

2- I-123 Sodium Iodide 0.5 mCi orally.

Gamma camera:

Small or large field of view.

Patient position:

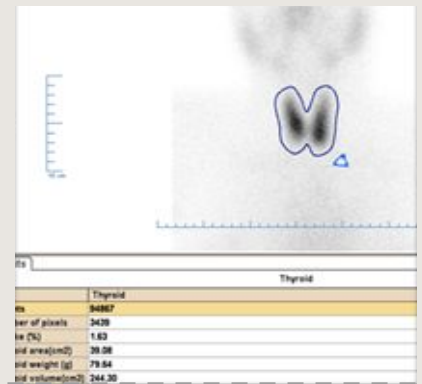
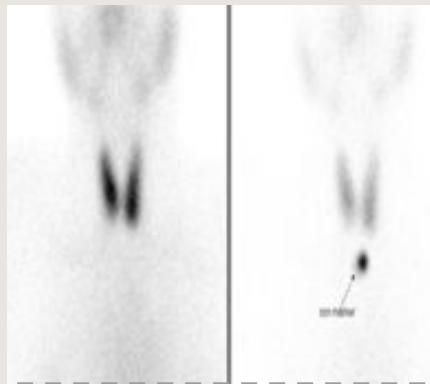
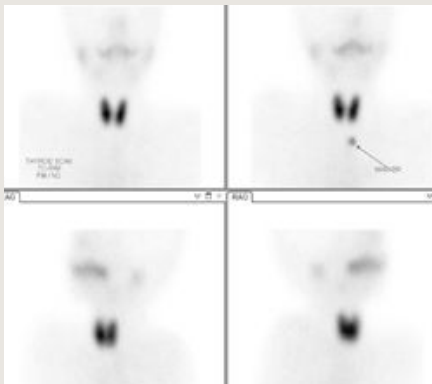
Supine with chin tilted up facing the camera.

Imaging:

1- 20 min. post injection of Tc99m: ANT(Anterior), LAO (Left anterior oblique) and RAO (Right anterior oblique) images obtained.

2- 6 and 24 hours post oral dose for I-123: ANT, LAO and RAO images.

Normal Tc-99m Thyroid Scan and Uptake



Marker: Suprasternal notch. A marker should be putted on the suprasternal notch it's very important in the case of retrosternal- goiter; different views will be obtained in order to appreciate any defects
RAO: right anterior oblique.
LAO: left anterior oblique.

SNN: Sun Suprasternal Notch. **Why?** To check how far it is from the sternum.

Normal Thyroid uptake in Tc-99m: 0.5-4% in this image it's 1.63 (normal)

THYROID UPTAKE MEASUREMENT (I-123 Sodium Iodide):

The Thyroid Uptake Measurement measures the metabolic activity of the thyroid gland as reflected by its extraction of iodine from the blood.

Indications:

1. Diagnosis of Grave's disease.
2. Evaluation of subacute and chronic thyroiditis.
3. Thyroid Cancer.

Patient preparation:

• **Must be off thyroid hormones:**

1. Thyroxine (T-4) for at least 4 weeks.
2. Triiodothyronine (T-3) for at least 10 days.

هناك كبسولتين "تحتويان على نفس النسبة" واحدة موجودة في المختبر والأخرى تعطى للمريضة، بعد يوم من بلع المريضة للكبسولة المعطاة يتم حساب نسبة الأيودين في كبسولتها ومقارنته بكبسولة المختبر.

• **Must not be taking antithyroid medications:**

1. Propylthiouracil (PTU) and tapazole for at least 3-5 days.

• **Must not have had intravenous or intrathecal iodinated contrast material**

(IVP, CT with contrast, myelogram, angiogram) for at least 3 weeks.

- **Other agents may interfere, but usually only to a small extent.**
- **NPO 2-4 hours before and for at least 1 hour after ingesting the radiopharmaceutical.**

	Uptake only	Imaging plus uptake studies
Equipment:	Uptake probe (single crystal probe with flat field collimator).	Gamma camera
Radiopharmaceutical:	I-123: 100 µ Ci.	I-123: 500 µCi.
Dose given orally One cap	What is the difference between Uptake only & imaging Plus uptake?	
	<i>Uptake only:</i> Gives information about the activity.	<i>Imaging + Uptake:</i> Give information about the shape and activity.

Notes:

Thyroid uptake measurements may be determined using Tc-99m-pertechnetate.

Patient position:

Sitting.

Detector Field of view:

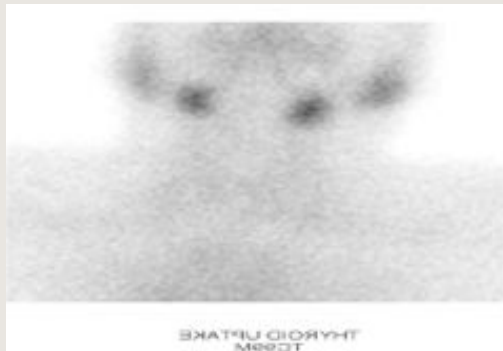Neck.

Causes of:

This can be a question in the exam:
Which of the following can cause high thyroid uptake?


Low Thyroid Uptake

- **Parenchymal Destruction:**
 - Acute, Subacute and Chronic Lymphocytic Thyroiditis
- **Hypothyroidism:**
 - Primary or Secondary (insufficient pituitary TSH secretion)
 - Surgical/Radioiodine Ablation of Thyroid
- **Blocked Trapping:**
 - Iodine load (most common): Iodinated contrast material, Food rich in iodide: fish, cabbage, ...etc
 - Exogenous thyroid hormone replacement depressing TSH levels (thyrotoxicosis factitia)
 - Ectopic thyroid: Struma Ovarii
- **Blocked Organification:**
 - Antithyroid medication (PTU): Note- Tc-99m uptake should not be affected



High Thyroid Uptake

- **Hyperthyroidism:**
 - Grave's Disease or TSH-secreting pituitary adenoma
- **Autonomous toxic nodule**
- **Multinodular toxic goiter** (Plummer's Disease)
- **Enzyme defects:**
 - Dyshormonogenesis.
- **Iodine starvation** (Iodine deficiency)
- **Lithium Therapy**
- **Recovery phase of thyroiditis.**
- **Rebound** following abrupt withdrawal of antithyroid meds

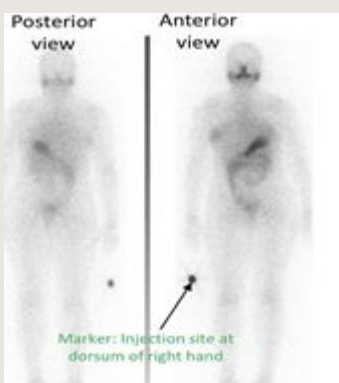


Tc-99m Thyroid scan and uptake
Thyroid uptake here in 2.96% which is normal.

Thyroid metastasis study (I-123 or I-131 as Sodium Iodide):

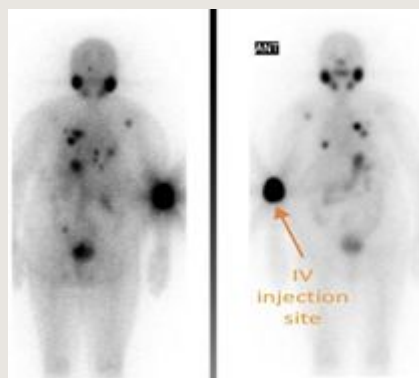
Indications:	Detection and localization of persistent or recurrent functioning thyroid cancer.
Patient Preparation:	<p>Stimulation of potentially functioning thyroid tissue:</p> <ol style="list-style-type: none"> <u>Inject recombinant human thyrotropin on 2 consecutive days</u> and administer the radiopharmaceutical on the third day. <u>Withdraw thyroid replacement hormones:</u> <ul style="list-style-type: none"> - Thyroxine (T-4) for at least 4 weeks. - Triiodothyronine (T-3) for at least 10 days. <p>The patient must not have had i.v iodinated contrast material (IVP, CT with contrast, myelogram, angiogram) for at least 3 weeks .</p> <p>The patient should be NPO for at least 4 hours prior to radiopharmaceutical administration and for at least 1 hour afterwards.</p> <p>Also the patient must avoid iodine-containing food such as fish.</p>
Radiopharmaceutical, Dose, & Technique of Administration:	<p>Radiopharmaceutical: Oral administration:</p> <ol style="list-style-type: none"> I-123 as sodium iodide : 2 mCi. I-131 as sodium iodide : 2-10 mCi. <p>Thyroid tissue uptake is TSH dependent, so prior to whole body scan 2 exogenous TSH injections must be given to the patient to find out any metastases after thyroid cancer treatment.</p>
Imaging used Gamma camera	Whole body scan.

Negative WBS



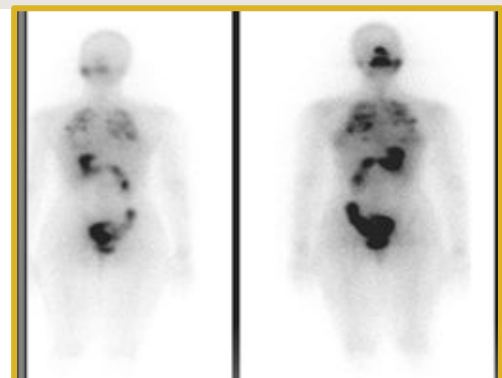
(post thyroidectomy - clear lungs and no local disease neither metastases) normal physiologic uptake of iodine in the stomach and urinary bladder.

Bone Metastases



(Normally Iodine uptake in salivary glands, and metastatic several ribs and left humerus.) no thyroid uptake because its removed.

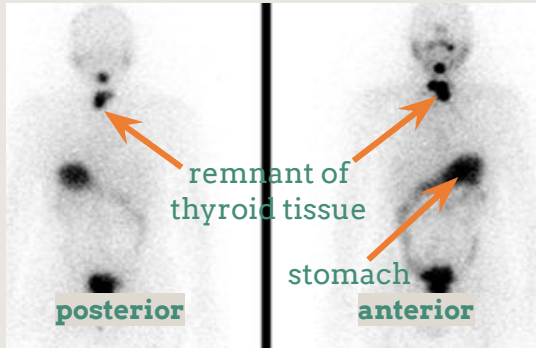
Lung Metastases



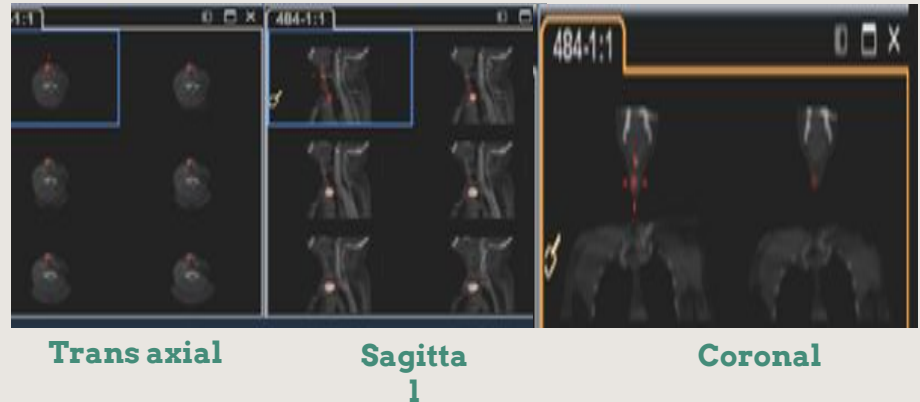Specially follicular type because it has hematogenous spread.

I-123 or I-131 Whole Body Scan (WBS) - "Planar Vs SPECT CT"

PLANAR



SPECT-CT



unsuccessful thyroidectomy.. there are multiple thyroid remnant in the neck in planar image, to know where exactly you have to do spect CT. **SPECT CT** is very important to determine the exact **location** of the abnormality. Sagittal view shows remnants in front of trachea and trans axial view shows that is antero-lateral to the trachea. This patient is post-operative which supposed there is no uptake of iodine in the neck (the thyroid is removed!). Which means these is **Local Recurrence** "The red thing is remnant in thyroglossal cyst"... knowing the exact site helps the surgeon decide which surgical approach to use.

When is thyroid scanning helpful? Indications for Thyroid Scan:

1. **Evaluation of thyroid nodules:** No. & type (hot vs cold nodule).

2. **Evaluation of congenital hypothyroidism:** Agenesis Vs. Dyshormonogenesis.

Note: TSH tests are routinely ordered for newborns as part of the screening program to evaluate how well the thyroid gland is working. If TSH is high we want to know if there is thyroid or not so we do thyroid scan (we don't use US because we can't see the base of the tongue in case of ectopic thyroid in the base as well it can not evaluate the function).

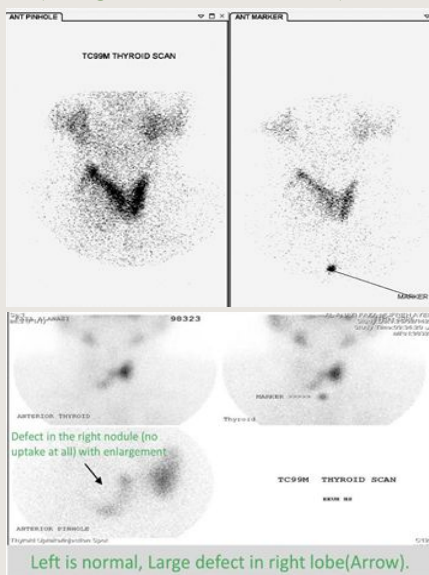
3. **Evaluation of neck masses:** ectopic thyroid, thyroglossal cyst.

4. **Evaluation of thyrotoxicosis.**

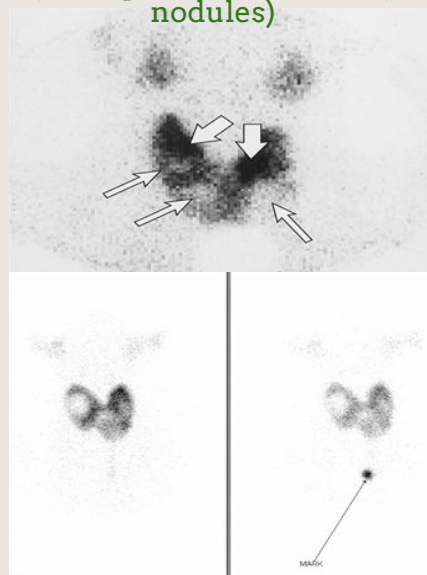
Evaluation of thyroid nodules (Single vs MNG):

- **The chance of malignancy is more in Solitary cold nodule than in MNG.**
- As the number of nodules increase, the chance of malignancy decrease.


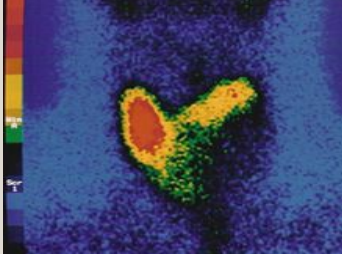
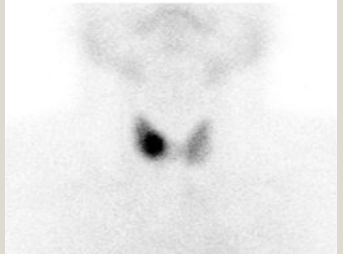
Solitary cold nodule (Single raised nodule)



Multinodular goiter (Multiple cold (nox-toxic) nodules)

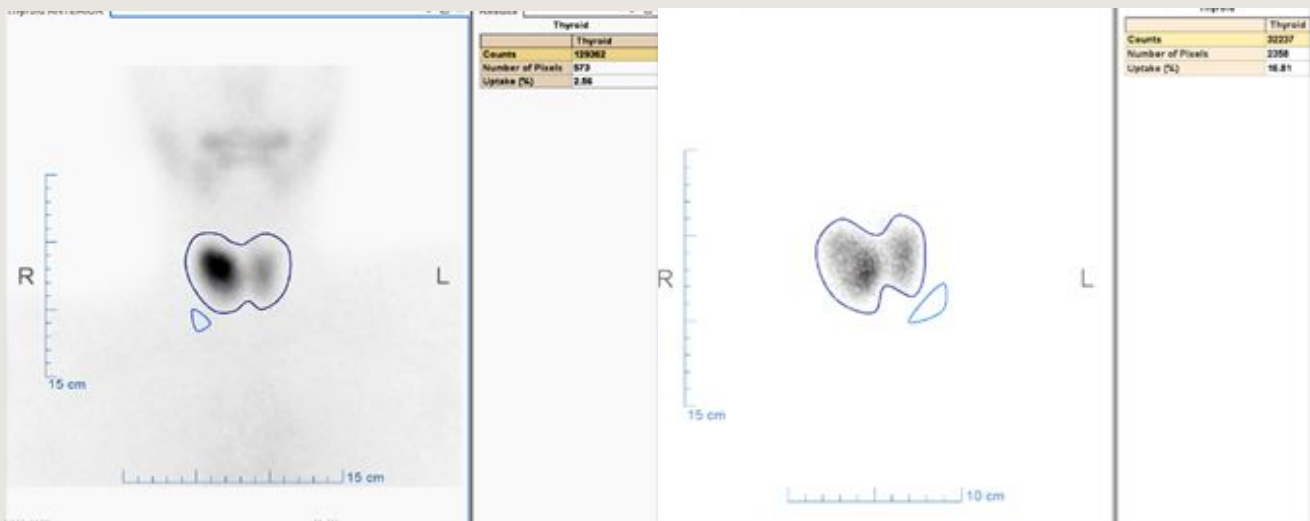


Evaluation of thyroid nodules (Hot vs Cold vs Warm):IMP!

<p>HOT</p> <p>you can't see extra-nodular thyroid tissue (normal thyroid around the nodule)</p>	<p>COLD IMP</p>	<p>WARM</p> <p>you can see the the extra-nodular thyroid tissue</p>
		
<p><5% Malignant</p> <p>(Autonomous toxic nodule) is a hot nodule that takes up all the tracer, suppressing the rest of the gland and independent on pituitary thyroid axis.</p>	<p>15% (Female) - 20% (Male) Malignant</p> <p>No uptake at all in the affected gland.</p>	<p>Suspicious</p> <p>There is uptake more than the rest of the gland without suppressing the gland... this image is taken by technetium. (Further investigations are needed by iodine 123 to see if it is really hot or cold)</p>

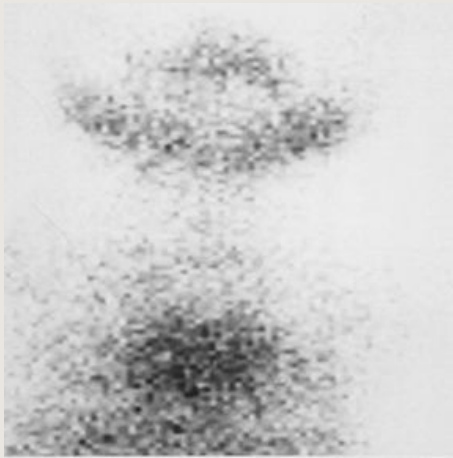
Discordance Tc -I-123 Scan:

- The chance of malignancy of a discordant nodule about **20%**
- A warm nodule in Tc is worrying it can be cold when done by I123. **Why?** because Tcm99 is only a trap whereas I123 is both trap and organification test.



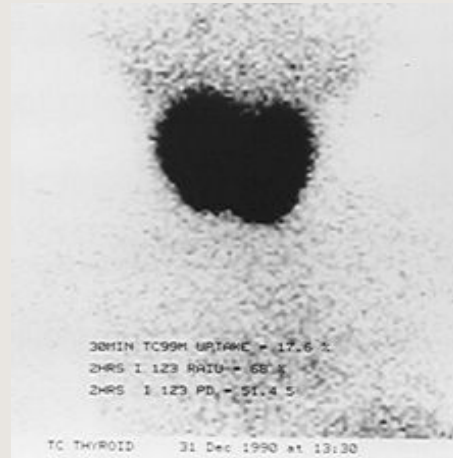
The picture on the left is because of technetium in the blood vessels itself not in the tissue where it is warm or hot ($\frac{1}{2}$ life is short), the 2nd picture is because of iodine, the uptake is in the same tissue so it shows the tissue where it is cold ($\frac{1}{2}$ life is long).

Evaluation of congenital hypothyroidism:



Agenesis

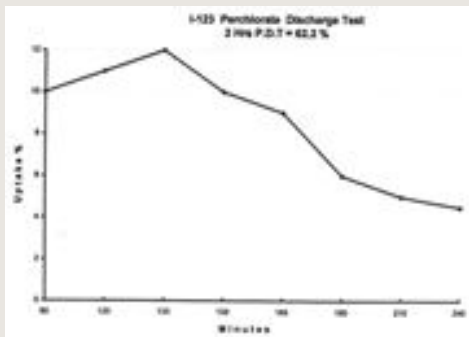
Treatment is lifelong thyroxine. in pediatric, TSH work is done, if it's high we do thyroid evaluation, we will find agenesis



Dyshormonogenesis

Abnormal gland (problem in organification because of enzyme defect) so it uptakes more iodine because tries to produce thyroxine

Perchlorate Discharge Test

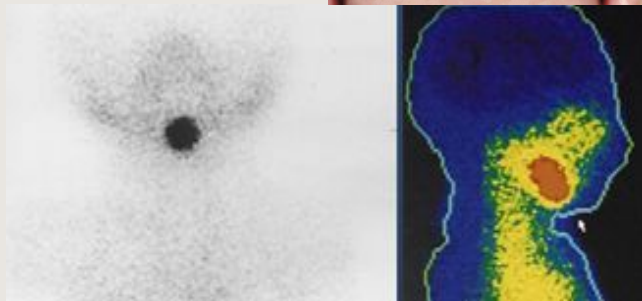
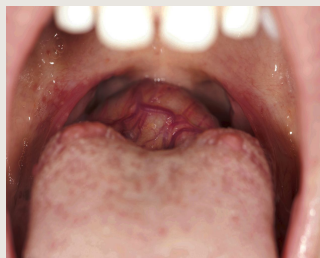

- 50 - 80 uCi I¹²³ orally.
- 2 hrs RAIU
- 400 mg KClO₄
- RAIU/ 15 min for 2 hrs.

Positive test : ≥ 15 fall of RAIU below 2 hrs. uptake.

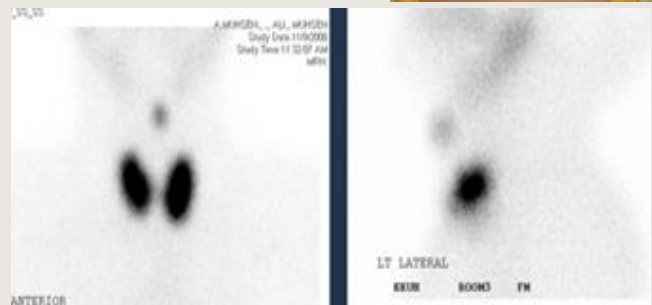
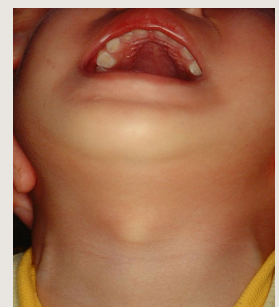
Evaluation of Neck masses: **IMP!**

ectopic "lingual" thyroid.



Lateral view is taken to confirm the diagnosis. "don't surgically remove any lump under the tongue", sometimes it causes compression symptoms so it is removed and is implanted elsewhere in the body in an area of high blood perfusion as in arm or abdomen.

thyroglossal cyst



As the thyroid descend through the thyroglossal duct sometimes this duct remains producing a cyst (remnant of thyroid tissue). can be surgically removed.

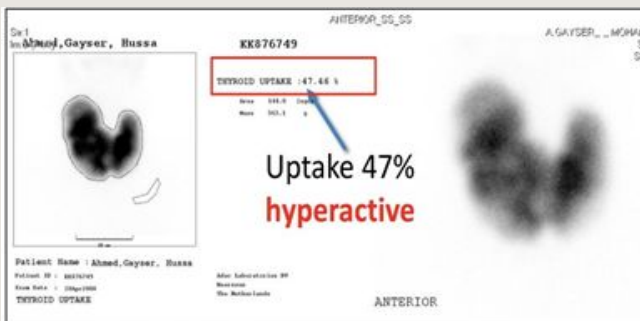
Evaluation of thyrotoxicosis

- Thyrotoxicosis is **NOT** synonymous to Hyperthyroidism.
- **Thyrotoxicosis:** Is a complex of signs and symptoms due to elevated thyroid hormones in the blood, **Whatever the origin.**
- **Hyperthyroidism:** Overproduction of thyroid hormones by the thyroid gland (hyperactive gland).

*nuclear tests can help in differentiating between thyrotoxicosis with hyperthyroidism from thyrotoxicosis without hyperthyroidism.

Evaluation of Thyrotoxicosis WITH hyperthyroidism:

- Graves' Disease.
- Neonatal hyperthyroidism.
- Toxic nodular goiter: (MNTG or Plummer's disease, ATN or toxic adenoma).
- Iodine induced: (Jod-Basedow disease) Rare causes: (Excessive HCG by trophoblastic tumor, Hypothalamic pituitary neoplasms (TSH induced).




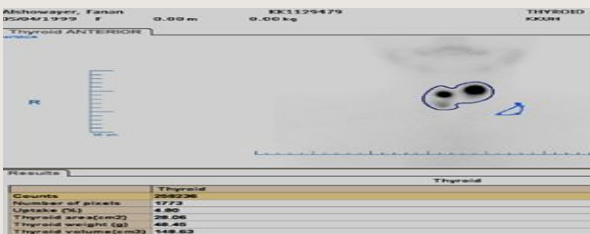
Graves' Disease on top of MNG the normal tissue between the nodules has graves. **Nodular Graves Disease (Marine-Lenhart syndrome)**

Diffuse enlargement in Graves disease with very high uptake 49% (This pictures is from 435 slides)

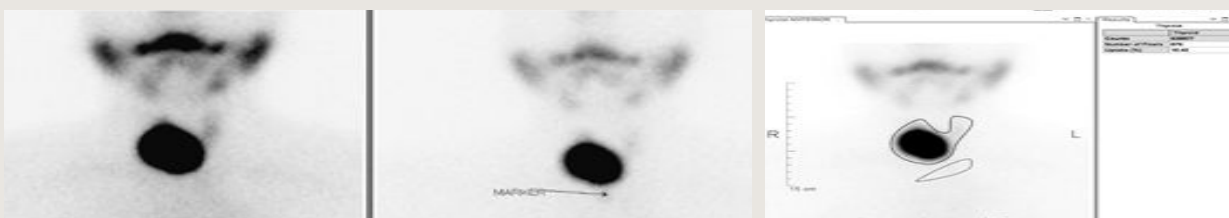
Management: Definitive treatment.

1. Antithyroid drugs, complication? agranulocytosis tell your patient "if feeling of sore throat come to the ER".
2. Surgery.
3. Radioactive Iodine.

MNTG (Plummer's Disease) (Multinodular Toxic Goiter)



Autonomous thyroid nodule "ATN"



Very hot nodule, the rest of the gland is not seen.
 - Autonomous: not dependence on TSH. It releases its hormone without the need of TSH. The best case for Iodine therapy.

Evaluation of Thyrotoxicosis WITHOUT hyperthyroidism:

- **Subacute thyroiditis.**

Usually the history tells you that the patient had recent infection, 95% normally recover 5% will have complete hypothyroidism..

- **Chronic thyroiditis with transient thyrotoxicosis.**
- **Thyrotoxicosis factitia** (exogenous hormone).

taking thyroxine to lose weight.

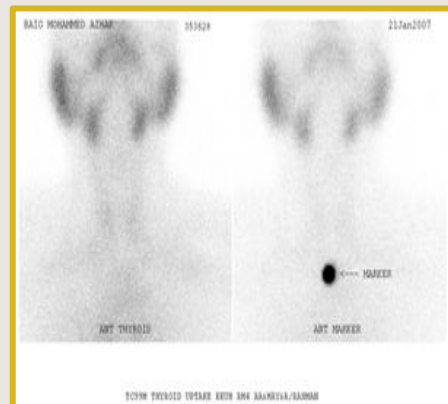
- **Thyroid extract** (e.g.Hamburger thyrotoxicosis)

"Ground beef contaminated with thyroid tissue"

لأن الجزار يسوي البرقر من لحم الرقبة زمان والناس يأكلونه ويصير تايروتوكيكوسيس

- **Ectopic thyroid:**
(Metastatic thyroid carcinoma, Struma ovarii)

The treatment here is mainly symptomatic relief.
Treat the underlying cause and it will become normal.



Subacute thyroiditis "SAT"
You don't see the thyroid gland!

Radioactive Iodine Therapy:

Hyperthyroidism

- **Isotope used: I-131**
- **Physical Properties: Solution** (be careful with elderly or kids risk of spilling) **or capsule.**
- **Main Side effect: Hypothyroidism.** when it reaches to this extent we give them thyroxine for life.
- **Dose:**
Calculated: considering weight and uptake of the gland. (To delay the onset of hypothyroidism)
Empirical: Graves (5-15mCi) ATN (15-20 mCi) higher.

doses will destroy the remnant of thyroid.
iodine is very dangerous, volatile منطائر and goes anywhere as long as there is space thru sweat or urine.

Thyroid Cancer

- **Isotope used: I-131**
- **Physical Properties: Solution or capsule.**
 - Thyroid remnant: 80-100 mCi
 - Lymph nodes mets: 100 mCi
 - Local Recurrence: 100 mCi
 - Lung mets: 150 mCi
 - Bone mets: 200 mCi

You don't need to memorize these numbers EXCEPT the graves!!!
higher doses here to destroy the tissue!

Parathyroid Scan

Normal and Ectopic Parathyroid Glands:

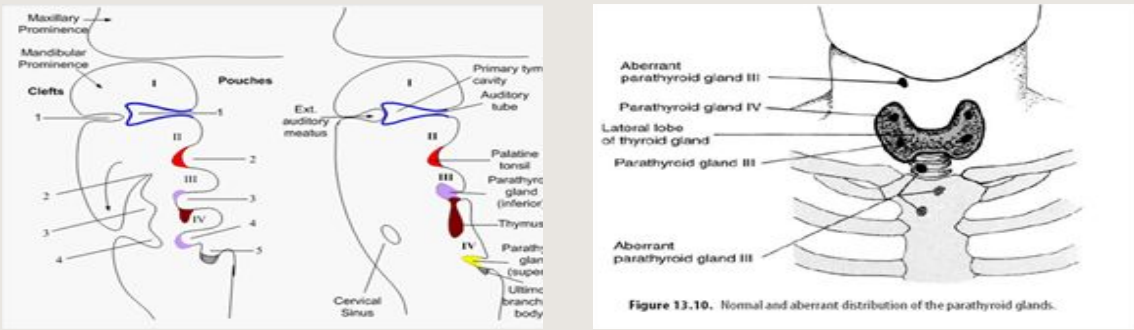


Figure 13.10. Normal and aberrant distribution of the parathyroid glands.

- **The third pair of pouches:** proliferates into the inferior parathyroid glands and the thymus.
- **The fourth pair of pouches:** proliferates into the superior parathyroid glands and the lateral angle of the thyroid gland.

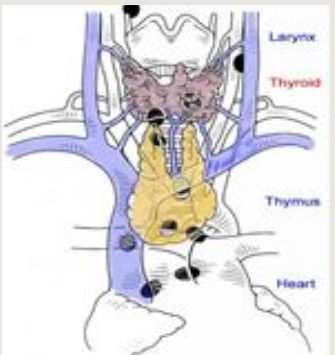
Because the inferior parathyroid glands undergo more extensive migration during embryogenesis, they are more likely to be found in ectopic locations.

Remember: best way for beginning the assessment of parathyroid gland is lab tests for parathyroid hormone and calcium level.

Ectopic parathyroid glands:

Location of an ectopic parathyroid glands:

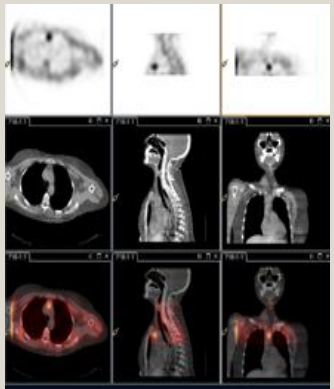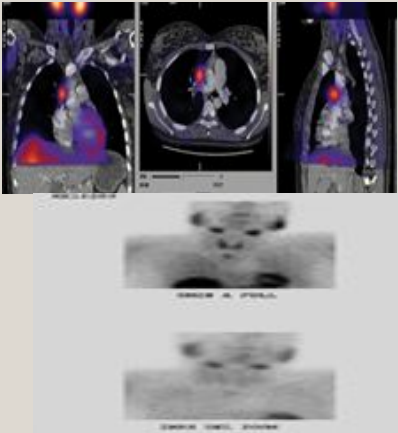
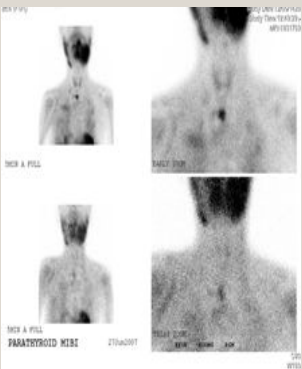
- Submandibular.
- Retropharyngeal.
- Retroesophageal.
- Posterosuperior mediastinal.
- Intrathyroidal.
- Within the tracheoesophageal groove Carotid sheath.
- Thyrothymic ligament.
- Intrathymic.
- Antero-superior mediastinal.



don't use nuclear medicine scans for counting "normal" parathyroid glands... normal glands are too small.

Ectopic parathyroid adenoma



<p>Ectopic parathyroid: 16% of total adenomas in upper mediastinum</p>	<p>PLANAR vs SPECT/CT SPECT-CT images accurately localize the adenoma and guide the surgeon to the best surgical approach, for ex. here we might need a thoracic surgeon.</p>	<p>Antero-superior mediastinum "here we can localize the adenoma retrosternal close to the aortic arch"</p>
---	--	--



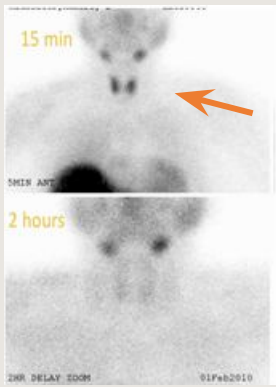Parathyroid Scan Techniques (very imp)

- **TL-201_ Tc-99m subtraction:** Several protocols have been developed for routine subtraction of thyroid tissue from parathyroid tissue, **they don't use it anymore because the mechanism includes administering two isotopes and to keep patient still with fixed head.**
- **Tc-99m Sestamibi (Dual Phase)** Used currently for parathyroid imaging (**Gold standard**): The Parathyroid Study depicts hypertrophied parathyroid tissue, probably because of uptake of Tc-99m-sestamibi in the mitochondria of hyperactive cells.
- **Tc-99m Tetrofosmin (Dual Phase). take time, and not sensitive.**

Parathyroid imaging/scan:

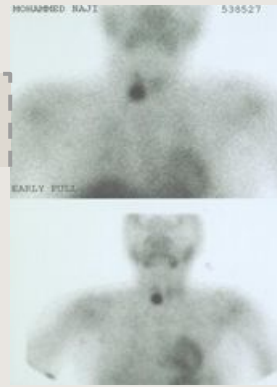
Radiopharmaceutical	99mTc / 201Tl Subtraction	99mTc sestamibi
Activity administered	- 80 MBq (2 mCi) 201Tl 370 MBq (10 mCi) 99mTc.	925 MBq (25 mCi).
Images acquired	- Inject Tl .rst and acquire 15-min 100 000 count view of neck and mediastinum. - Then acquire similar Tc images without moving patient. Subtract Tc data from Tl after normalization to equal count densities.	- Anterior (and oblique) views at 15 min and at 2–3h; SPECT as needed.
	 <p>1. We give thallium--it goes thyroid and parathyroid. 2. Then give only technetium-- it goes only to thyroid. 3. Subtract the images to visualize the parathyroid gland.</p>	 <p>1. inject the sestamibi -- it will go to the thyroid and abnormal parathyroid. (Early phase) 2. After 2 hours we take another image. The remnants will represent the abnormal parathyroid. (Late phase)</p>

Tc-99m Tetrofosmin (Dual Phase) - Dual phase MIBI Scan



it's normal for submandibular glands and parotid to uptake

Normal parathyroid glands are small and not visualized.



"Right lower parathyroid adenoma"

Abnormal parathyroid glands could be visualized.

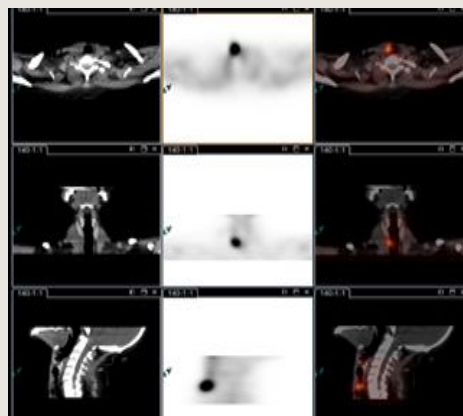
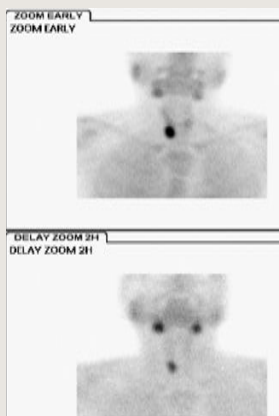
Tc-99m Sestamibi

The Parathyroid Study depicts hypertrophied parathyroid tissue, probably because of uptake of Tc-99m-sestamibi in the mitochondria of hyperactive cells.

Indications	Detect and localize parathyroid adenomas.
Patient Preparation:	None.
Radiopharmaceutical, Dose, & Technique of Administration:	<ul style="list-style-type: none"> • Radiopharmaceutical: 25 mCi Tc-99m-sestamibi i.v. • Patient position: Supine with head and neck extended and immobilized. • Gamma camera Imaging field: <ol style="list-style-type: none"> 1. Neck. 2. Upper two thirds of the mediastinum.
<p>Acquire images at 15 minutes and 2-3 hours post injection. SPECT/SPECT CT images improves localization.</p> <ul style="list-style-type: none"> • TI - Tc99m subtraction: Several protocols have been developed for routine subtraction of thyroid tissue from parathyroid tissue. 	

Sestamibi Dual Phase (Planar vs SPECT CT)

PLANAR




SPECT-CT

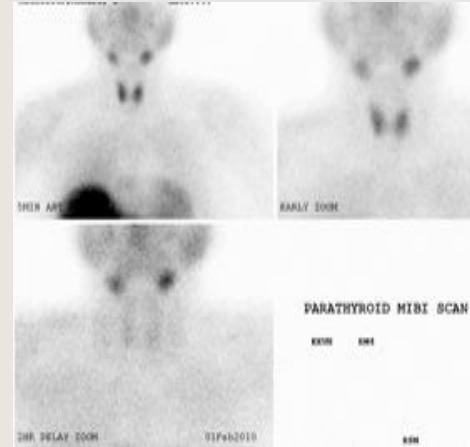
"here we can localize the adenoma lateral to the trachea"

Sestamibi Parathyroid Scan Results :

High PTH /High Ca "TP:True Positive"



High PTH / High Ca "FN:False negative"



Mechanism of sestamibi uptake: > is the cause of the FN result

SESTAMIBI : METHOXYISOBUTYLISONITRILE.

- Its parathyroid uptake was first reported by Coakley et al. in 1989
- Mechanism of MIBI uptake and retention is still unclear. Multifactors have been proposed:

1. Biochemical properties of the tracer:

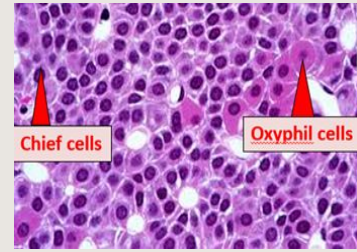
Lipophilicity: The lipophilic sestamibi molecule is concentrated by mitochondria. This explains why adenomas with an abundance of mitochondrial-rich oxyphil cells retain the sestamibi Cationic charge.

2. Cell Type : A predominance of oxyphil cells within an adenoma is more likely to lead to a positive scan.

3. Local factors: Blood flow, trans-capillary exchange, interstitial transport and negative intracellular charge of both mitochondria and membranes.

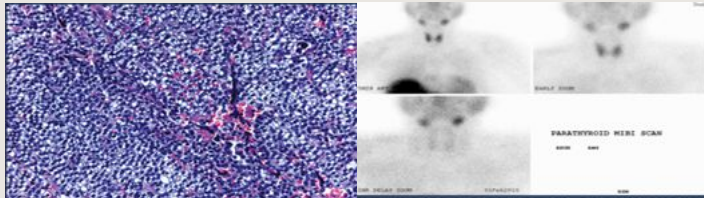
Normal parathyroid glands comprise 2 cell types[1]:

1. **Chief cells:** responsible for PTH production.
2. **Oxyphil cells:** eosinophilic cells whose cytoplasm is composed almost entirely of mitochondria.

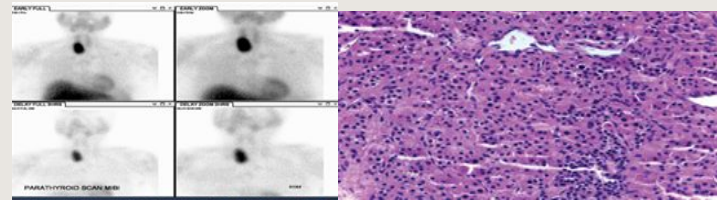


While the normal oxyphil cell does not synthesize and secrete PTH, the oxyphil cells of pathologic parathyroid glands do secrete the hormone.

[1] Note: sestamibi concentrates in the mitochondria. if the adenoma derived from oxyphilic cell it will show on sestamibi (the scan will be **positive**) and if the tumor derived from Chief cell it will not show on sestamibi (it will not uptake the sestamibi and the scan will be **negative**) we do MRI -and ultrasound- to confirm adenoma from chief cells



Parathyroid adenoma composed entirely of glycogen-rich chief cells.



Parathyroid adenoma composed mainly of mitochondrial-rich oxyphil cells.

What is the cause of the FN Sestamibi scan results?

1. **Histologic type:** False-negative scans can occur with parathyroid glands containing predominantly clear cells.
2. **Size and Location:** Smaller-volume parathyroid adenomas and those in the upper position are less likely to be localized with sestamibi scans.
3. **Number of adenomas:** FN rate is increased with MGD compared with patients with a single adenoma.
4. **Decreased tracer concentration:** Possible association:
 - A. P-glycoprotein expression.
 - B. Multidrug resistance-related protein expression.
5. **Variability of radiotracer uptake in parathyroid adenomas:** Related to differences in perfusion and metabolic activity.

Even with refinements in sestamibi scanning, the fact that all parathyroid adenomas are not created equal on a cellular level may inevitably lead to FN scans in a certain number of cases.

False-Positive Scintigraphic Findings:

(EXTRA)

In the clinical setting of hyperparathyroidism, false-positive findings are uncommon.

- Solitary thyroid adenoma or a multinodular goiter.
- Benign or malignant tumors: breast, lung, and head and neck carcinomas and their lymph node and osseous metastases, as well as bronchial carcinoids.
- Primary thyroid lymphomas.
- Cervical L.N. metastasis from PTC carcinoma.
- Reactive lymph nodes.
- Remnant thymus.
- PTH-secreting paraganglioma.
- Enlarged submandibular salivary gland.

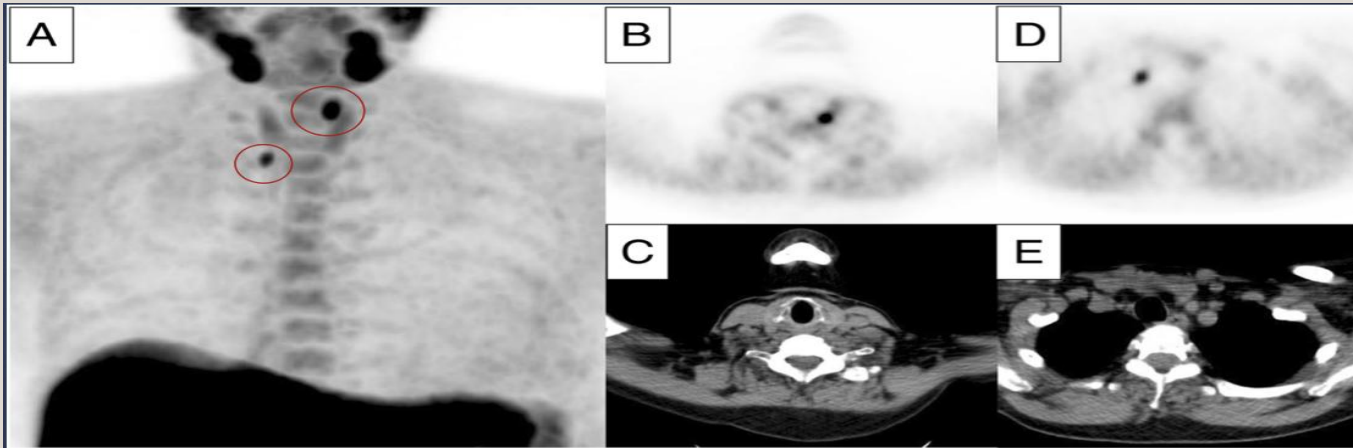
(EXTRA)

Points To Remember Before Proceeding For Parathyroid Imaging:

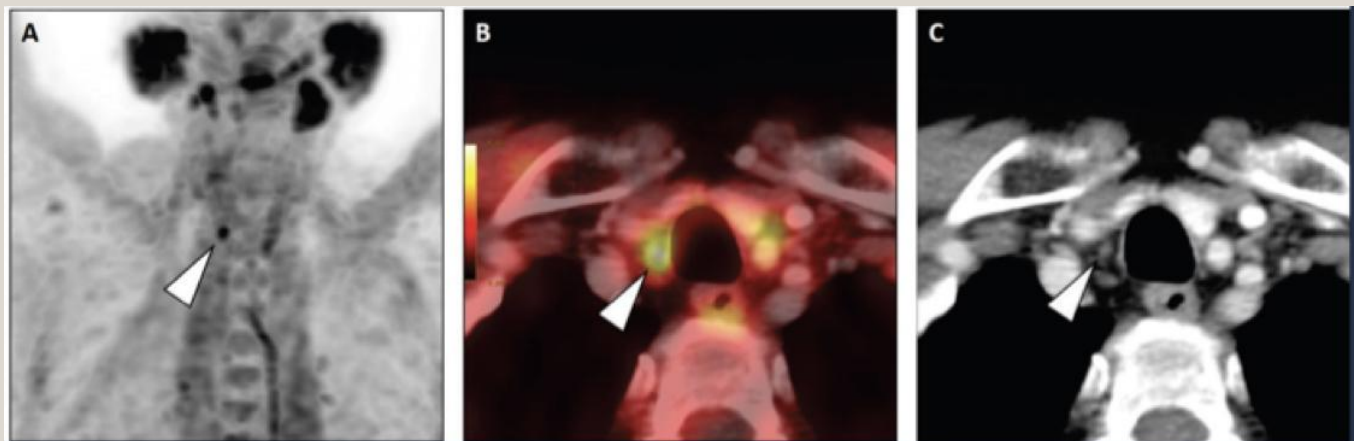
- **Imaging is not for diagnosis:** High Ca and PTH establish the diagnosis.
- **Imaging does not identify normal parathyroids:** These are too small to be seen (20-30mg).
- **Imaging should detect abnormal parathyroid(s) and indicate the approximate size and the precise relationship to the thyroid gland:** lateral, SPECT and SPECT /CT.
- **Imaging should identify ectopic glands:** SPECT and SPECT/CT. "Full neck and upper mediastinum"
- Optimal imaging should be able to **differentiate** patients with single adenoma from those with MGD.
- Imaging should identify **thyroid nodules** which may require concurrent surgical resection.

- new radiopharmaceuticals for parathyroid imaging
- very sensitive for chief cells and oxyphilis.
- very expensive "one dose could cost 16000 SR!".

18f-fluorocholine parathyroid scan:



Double parathyroid adenoma (SESTAMIBI scan was negative)



Focal hyperactivity posterior to the right caudal pole of right thyroid lobe and, histologically confirmed as parathyroid adenoma. Previous imaging by neck US and MIBI was inconclusive

Don't forget (By 432 team)

- Technetium half-life is **6 hours**.
- **To assess the organification we use I123** not Tc-99.
- **The gold standard tracer in RAIU is 123.**
- **If patient is on thyroxine s/he should stop it 3-4 weeks before thyroid scan.**
- If patient is on antithyroid s/he should stop it 3-5 days before thyroid scan.
- The patient **should not** have any I.V contrast for at least 3- weeks before scan.
- RAIU is to determine how much of the dose we give to the patient is taken by the thyroid gland.
- I 123 is used for **diagnosis** while I 131 for **therapy** (cancer or hyperthyroidism).
- Causes of abnormal thyroid uptake. (either high or low)
- A common cause of thyroid cancer is **irradiation**.
- In thyroid cancer the uptake is most likely **normal**.
- **Hot nodules have no chance (<5%) of being malignant.**
- Cold nodules have 15% chance of malignancy in females and **higher in males 20%.**
- **The most common cause of hot nodule is ATN.**
- **Indication of thyroid nuclear imaging include:**
 1. *Evaluation of thyroid nodules.*
 2. *Evaluation of congenital hypothyroidism: Agenesis Vs. Dyshormonogenesis.*
 3. *Evaluation of neck masses: ectopic thyroid, thyroglossal cyst.*
 4. *Evaluation of thyrotoxicosis.*
- Perchlorate discharge test is used **to confirm dyshormonogenesis.**
- **RAIU is used also to evaluate:**
 1. *Thyroiditis : subacute and chronic thyroiditis.*
 2. *Thyroid Cancer : Remnants uptake in preparation for therapy. (after surgery how much remnants is left, to prepare for I 131 therapy).*
- **Lactating mothers should stop breastfeeding according to the following:**
 1. **Completely after I 131 therapy**
 2. **3 weeks after diagnostic I 131**
 3. **12 h after 99mTc.**
- **The main side effect of radioactive iodine therapy for hyperthyroidism is hypothyroidism.**
- Parathyroid imaging needs combination of several modalities. Sestamibi and MRI are the best combination.
- Parathyroid scan results depends on the **histological type of adenoma.**
- Normal parathyroid scan doesn't exclude parathyroid adenoma.

Indications for Thyroid Scan:

- Evaluation of thyroid nodules : No. & type
- Evaluation of congenital hypothyroidism : Agenesis Vs. Dyshormonogenesis.
- Evaluation of neck masses : ectopic thyroid, thyroglossal cyst.
- Evaluation of thyrotoxicosis

Thyroid :

Thyroid scan:

- Tc-99m: not expensive, one-time imaging after 20min of injection, **trapped NOT organified**
- I-123: expensive, three-time imaging one after intake, then 6hrs then 24hrs, **trapped AND organified**

Evaluation of thyroid nodules:

- **Hot:** due to high activity, suppresses the other parts of the gland , <5% of malignancy, ATN as an example
- **Cold:** no uptake of the affected part, higher chance of malignancy
- **Warm:** the uptake is slightly higher than the others, suspicious....

Evaluation of Neck masses:

- **Ectopic thyroid:** Ex. lingual thyroid(base of the tongue), functional
- **Thyroglossal cyst:** forms from remnants of thyroglossal duct

Radioactive iodine therapy:

- **Hyperthyroidism:** I131(isotope) At small doses
- **Thyroid cancer:** I131 at higher doses

Parathyroid :

99m sestamibi (dual phase) is the **GOLD STANDARD**.

adenoma rising from chief cells will have **negative** parathyroid scan (false -ve)

adenoma rising from oxyphil cells will have **positive** parathyroid scan (true +ve)

QUESTIONS

1- TC-99m uptake after 20 minutes in a patient was 37%, which of the following would be the underlying thyroid problem :

- a) post thyroid radio-radio ablation
- b) struma ovarii
- c) insufficient pituitary TSH secretion
- d) recovery phase of thyroiditis

2- what is the gold standard modality for parathyroid scan imaging :

- a) Tc-99m tetrofosmin
- b) Tl-201/Tc-99m subtraction
- c) Tc-99 Sestamibi (Dual phase)
- d) Xenon 133

3- Which of the following is best used for assessing the organification function of thyroid gland?

- a) CT scan
- b) Ultrasound
- c) Technetium nuclear study
- d) iodine-123 nuclear study

4- A 67 y.o. gentleman undergone sestamibi dual phase scan to investigate his elevated blood calcium levels. 2 hours later, there was no uptake seen. what would you conclude?

- a) absent parathyroid glands
- b) it's better to do MRI afterwards because maybe it's parathyroid adenoma composed mainly of chief cells
- c) it's better to do MRI afterwards because maybe it's parathyroid adenoma composed mainly of oxyphil cells
- d) better to do chest x-ray

1- d 2- c 3- d 4- b

help us improve with your feedback:



RadiologyRadiology437@gmail.com

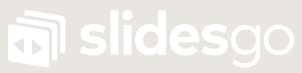

We would be happy, if you leave your feedback

[click Here !](#)

References

- ✓ Slides
- ✓ 436 Teamwork



You did it !

