



Color Index:

- ✓ Important
- ✓ Notes
- ✓ Extra

Radiology of thyroid & parathyroid & adrenal gland

[Editing File](#)

Objectives

- Identify the anatomy, location of the thyroid gland & parathyroid gland.
- Understand the radiological sign and radiological investigations of thyroid Ophthalmopathy.
- Recognize renal osteodystrophy involving different skeletal images as well as radioiodine study.
- To know the thyroid nodules and how we can differentiate benign from malignant nodule.
- To explain the usage of scintigraphy for thyrotoxicosis.

Sources

Lecturer:
Dr.Fahad Al-Bader
Same 436 lecture Slides:
YES

Done by:

 **Reem alqarni**

 **Anas Alsuwaida**

 **Adnan almogbel**

 **Rasheed alballa**

Revised by:

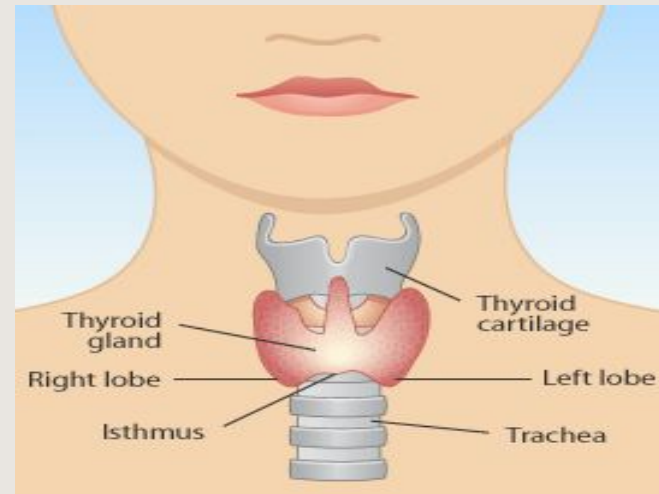
 **Yazeed Al-Dossare**



Anatomy of the Thyroid Gland:

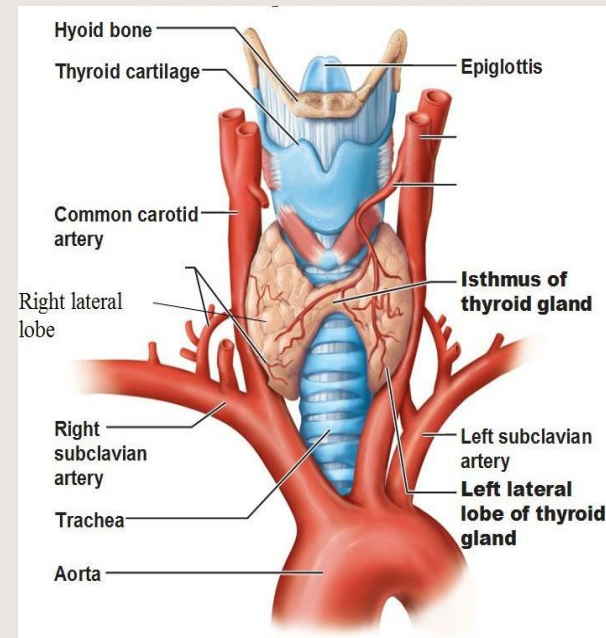
- Anterior neck, the lower part of the front and side of the neck.
- Extending from the level of C5 - T1.
- Overlays 2nd – 4th tracheal rings.
- Average width: 12-15 mm (each lobe).
- Average height: 40-60 mm long.
- Average weight: 25 g.

(Understand the numbers, **don't** memorize)



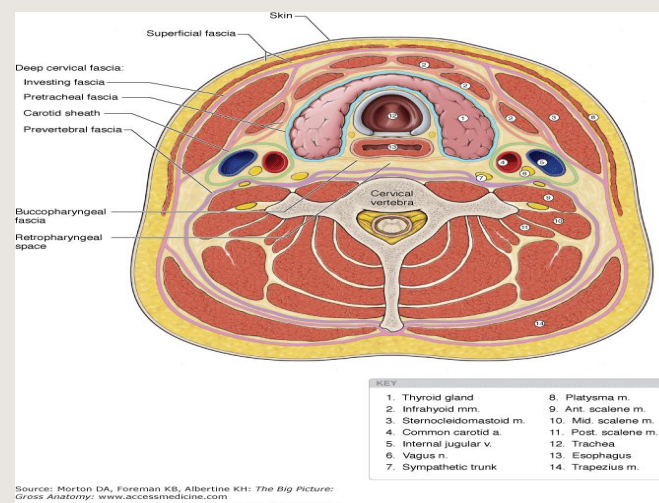
Gross Anatomy

- The thyroid extends from **C5 to T1** and lies anterior to the thyroid and cricoid cartilages of the larynx and the first three tracheal rings.
- Each lateral lobe extends upwards to the oblique line of thyroid cartilage and below up to the 5th or 6th tracheal ring.
- The isthmus extends across the midline in front of the 2nd, 3rd and 4th tracheal ring.
- The thyroid is butterfly or "H"-shaped and is composed of two lobes, each with a superior and inferior pole, connected by an isthmus. Each lobe measures approximately 4-6 cm in length.



Relations:

- Anteriorly: strap muscles.
- Posteriorly: thyroid cartilage, cricoid cartilage, trachea.
- Posteromedially: tracheoesophageal groove (containing lymph nodes, **recurrent laryngeal nerve**, parathyroid glands).
- **Posterolaterally: carotid space** (carotid artery, internal jugular vein, vagus nerve).



Source: Morton DA, Foreman KB, Albertine KH: *The Big Picture: Gross Anatomy*; www.accessmedicine.com
Copyright © The McGraw-Hill Companies, Inc. All rights reserved.

Thyrotoxicosis Vs Hyperthyroidism

A group of symptoms and signs due to increase production of thyroid hormones. (typical sign and symptoms of Hyperthyroidism: Weight loss, diaphoresis, tremors, palpitation, exophthalmos (exophthalmos is mainly associated with graves disease). while hypothyroidism usually comes to females (وما يدون يكون عندهم خمول وزيادة في الوزن)

- Hyperthyroidism : A hyperfunctioning thyroid gland.
- Thyrotoxicosis: **Any cause**. (endogenous or exogenous)

Thyrotoxicosis:

- **Hyperthyroidism**
 - 1- Diffuse toxic goiter (Graves' disease¹).
 - 2- Single toxic nodule.
 - 3- Multi-nodular toxic goiter.

- **Early phase sub-acute thyroiditis.**
- **Exogenous thyroid hormone intake.**

TFT & Thyroid Scan: (what is the first modality that you will do when a patient has Thyrotoxicosis e.g. patient complains of tremors, exophthalmos, and Weight loss, and the thyroid panel showed high T3/T4 but low TSH ? □ultrasound)

- Thyrotoxicosis → suppressed TSH and elevated T3/T4.
- Based on TFT (thyroid function test), the exact cause of thyrotoxicosis can not be determined.
- **Thyroid scan** is a very helpful tool in differentiating between various causes of thyrotoxicosis.

Thyroid scan and uptake:

Radioactive Iodine (RAI) is used for thyroid **scan** and **uptake**
→ it's given **orally**.

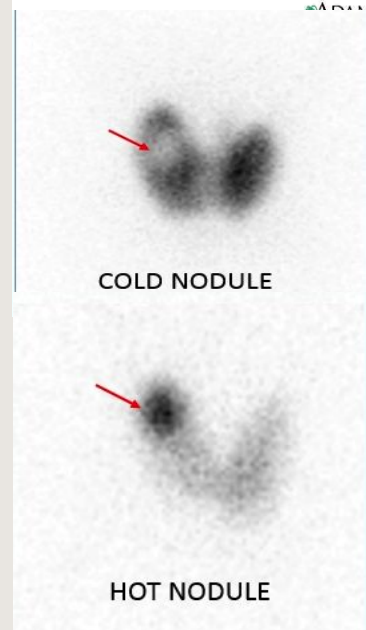
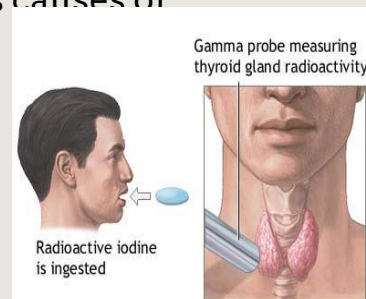
- Image and uptake are obtained **after 24 hours**
→ This test determines how much of orally ingested iodine accumulated in the thyroid at 24 hours.

Imaging Findings:

- Symmetric or asymmetric uptake.
- Homogeneous or inhomogeneous uptake.
- Nodules: Cold or Hot.

If the active material was **trapped** in the nodules then its called **hot** nodules. If the material **isn't trapped** then it's called **cold** nodules.

If there is diffuse enlargement it will be treated medically, If it is single it will be treated surgically, you will give the patient radioactive iodine orally then scan after 24 hours.



¹ the main finding is multiple diffuse nodules

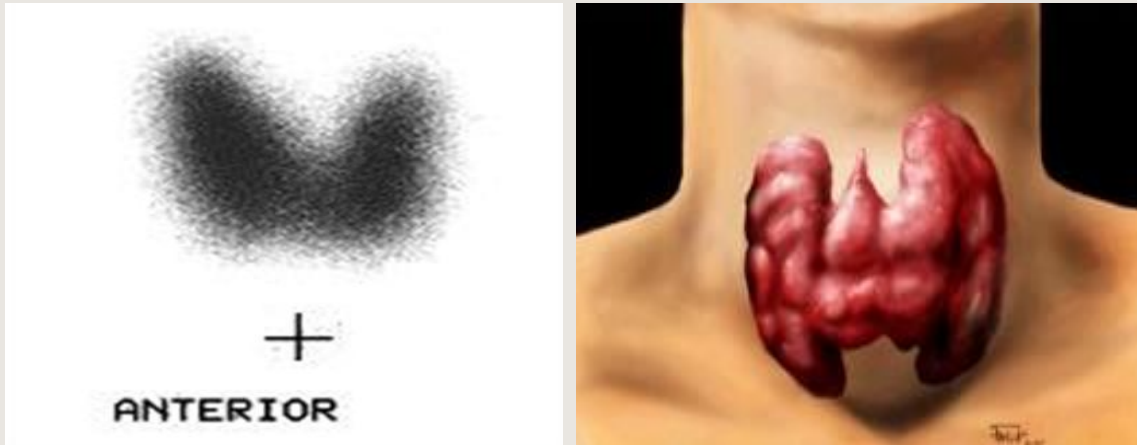² it will appear as multiple focal activity on the nuclear scan

Thyrotoxicosis :

A) Hyperthyroidism:

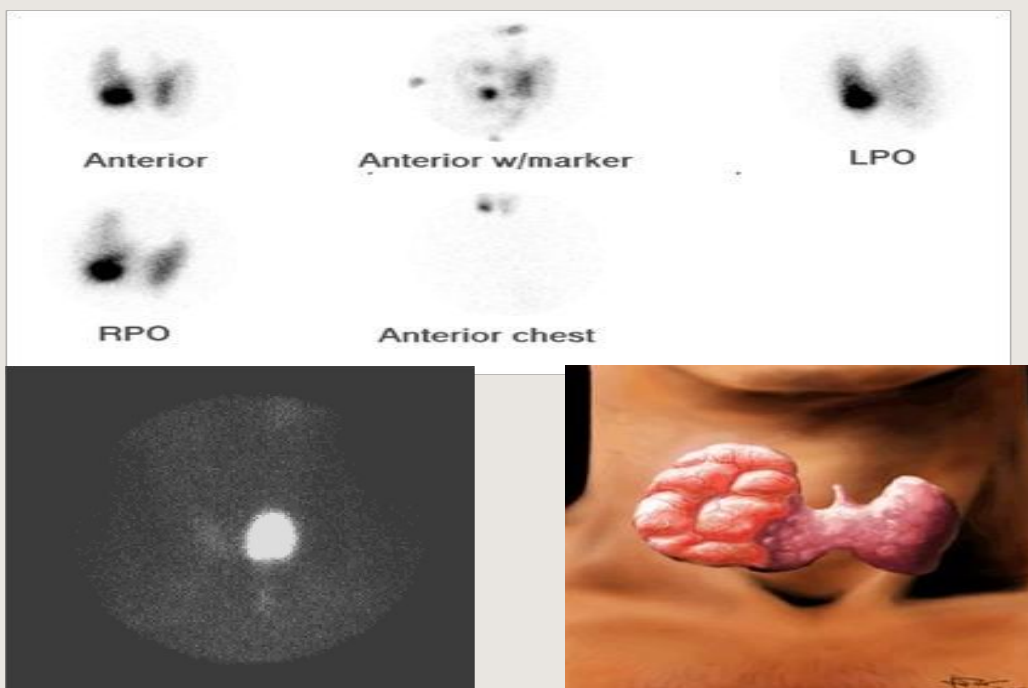
I. Diffuse Toxic Goiter (Graves' Disease): (associated with bilateral exophthalmia)

- Diffuse enlargement of thyroid gland.(usually symmetrical)
 - Homogeneous increased uptake due to an increase in activity.
 - No significant focal abnormalities (nodules).
 - 24-hour RAI uptake is elevated, usually >35%.
- (Dr said not important to remember the number)



II. Single Toxic Nodule: (In graves disease the treatment will be medical while in toxic nodule the treatment might be medical or surgical)

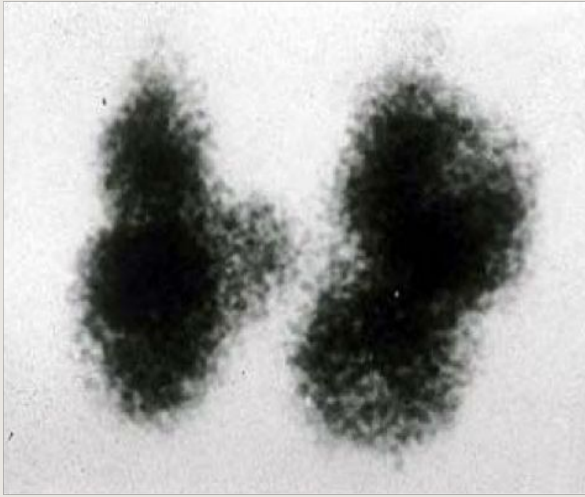
- Single hot nodule (independent of TSH or autonomous).
- Rest of thyroid gland is poorly visualized due to low TSH level (TSH dependent).
- 24-hour RAI uptake is slightly elevated, usually around 20%.



Toxic (hot) nodule

III. Toxic Multinodular Goiter

- **Mild inhomogeneous** uptake in thyroid gland.
- Multiple **cold (Malignant)** and **hot (Benign) nodules** in both thyroid lobes.
- 24-hour uptake is **mildly elevated**, usually between 20%-30%.

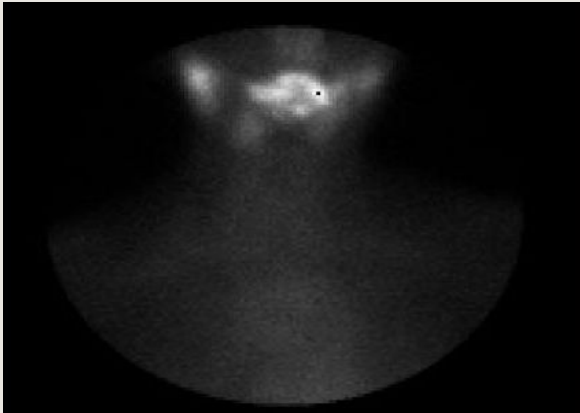


Multinodular goiter
with diffuse asymmetrical appearance of the gland with multiple areas of hyperfunction activity.

Early Phase Subacute Thyroiditis :

(Dr said not important in radiology)

- **Inhomogeneous uptake** could be mild or severe. In some cases thyroid gland is not visualized.
- No significant focal abnormalities (nodules).
- 24-hour RAI uptake is **low**, usually < 5%.



In Summary

Malignancy (Cold nodule)	Bilateral symmetrical uptake (No nodule) ³	Cold & Hot nodules together
 COLD NODULE	 pyramidal lobe GRAVE DISEASE	 TOXIC MULTINODULAR
 HOT NODULE	 suppression of remainder of gland AUTONOMOUS NODULE	 RAIU < 5% THYROIDITIS

The outline of the thyroid gland is clear with hot nodule

We can't see the outline of the thyroid gland

Minimal uptake

³Diffused increase of the radioactive uptake + diffuse enlargement.

Hypothyroidism

- The main cause is **chronic thyroiditis** (Hashimoto's thyroiditis).
- TFT → **TSH is elevated** & Low T3/T4.
- Thyroid scan **does not** have significant diagnostic value in this entity. Unless, there is a nodule, thyroid scan may be helpful.

Thyroid Nodules

Common, almost existing in half of the population.

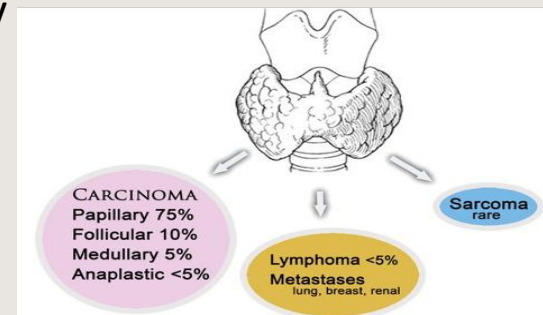
- Usually found by **physical examination** or by **ultrasound**.
- **US is the first** modality used to investigate a palpable thyroid nodule⁴.
- **Scintigraphy** (thyroid scan) is reserved for characterizing **functioning nodules** and for **staging follicular** and **papillary** (not aggressive, very common, good prognosis) **carcinomas**.
- The patient is usually **euthyroid**⁵.
- If the patient is **hyperthyroid** do nuclear scan otherwise do FNA.
- FNA is the most **accurate** and **cost-effective** method for diagnostic evaluation of thyroid nodules.
- FNA have a sensitivity of 76%–98%, specificity of 71%–100%.

Frequency of Occurrence of Thyroid Malignancy

- Lymphoma is very rare and sarcoma is extremely rare.
- Papillary and follicular are very common.

Risk Factors for thyroid Cancer:

1. Family history of thyroid cancer.
2. History of head and neck irradiation.
3. **Male** Gender. (It is more common in female. If we find it in male then it is highly suspicious).
4. Age of less than 30 years or more than 60 years.
5. Previous diagnosis of type 2 Multiple Endocrine Neoplasia (**MEN-2**).



From 433:

-If you have a patient with multi-nodular goiter and lab shows euthyroid, what is the next step?

US then FNA.

-If you have a patient with multi-nodular goiter and lab shows hyperthyroidism, what is the next step?

US then thyroid scan then +/- FNA if needed.

So, always after TFT do US.

⁴ it is not definitive, if you see features of malignancy you have to do FNA to confirm diagnosis.

⁵ the patient comes with neck swelling, no other symptoms, the lab is normal, so there is no signs suggesting hyper or hypothyroidism. You have to do US to roll out cancer.

US Features of Thyroid Nodules⁶

-Certain US features are helpful in differentiating between the two.

-**Malignant features are:**

1. Micro-calcifications.
2. Local invasion.
3. A nodule that is taller than it is wider.
4. Markedly reduced echogenicity (**hypoechoogenicity**).
5. Lymph node metastases

-**Other** less specific features of malignant nodules which may be useful, such as:

1. Absence of a halo.
2. ill-defined irregular margins.
3. Solid composition.
4. Vascularity

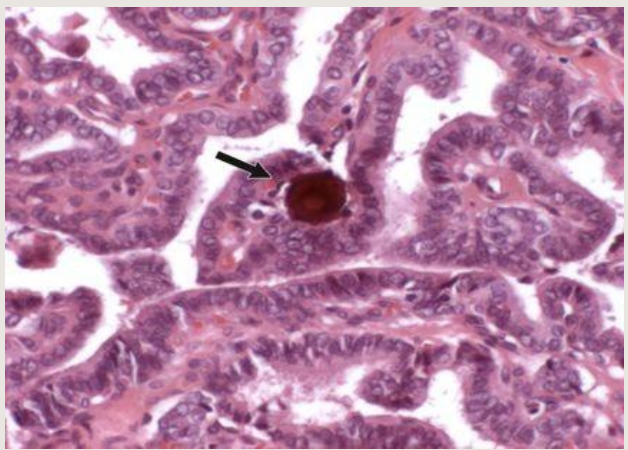
US Feature*	Sensitivity (%)	Specificity (%)	Positive Predictive Value (%)	Negative Predictive Value (%)
Microcalcifications (1–5)	26.1–59.1	85.8–95.0	24.3–70.7	41.8–94.2
Hypoechoogenicity (2–5)	26.5–87.1	43.4–94.3	11.4–68.4	73.5–93.8
Irregular margins or no halo (2–5)	17.4–77.5	38.9–85.0	9.3–60.0	38.9–97.8
Solid (4–6)	69.0–75.0	52.5–55.9	15.6–27.0	88.0–92.1
Intranodule vascularity (3, 6)	54.3–74.2	78.6–80.8	24.0–41.9	85.7–97.4
More tall than wide (2)	32.7	92.5	66.7	74.8

From the schedule above: (Don't memorize the numbers)

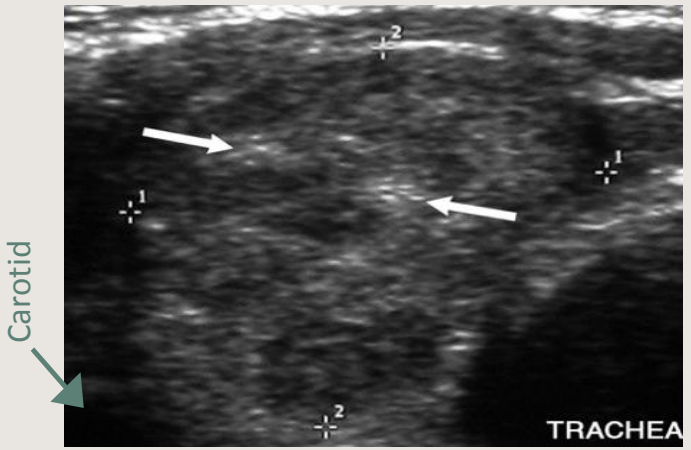
The most important malignant feature is microcalcification, increased internal vascularity, taller than wider and hypoechoogenicity.

Thyroid microcalcifications

Papillary thyroid carcinoma in a 42 y/o man: IMP!



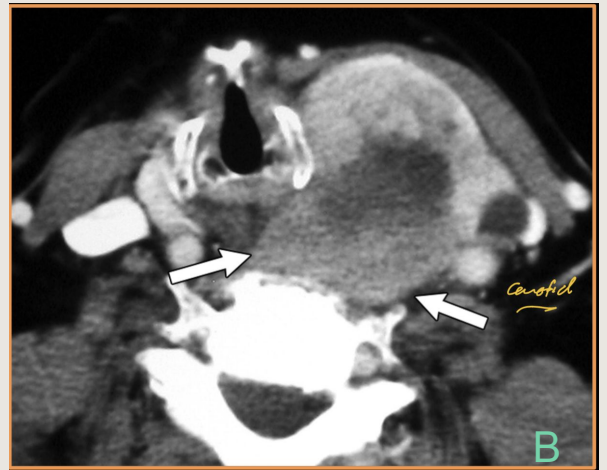
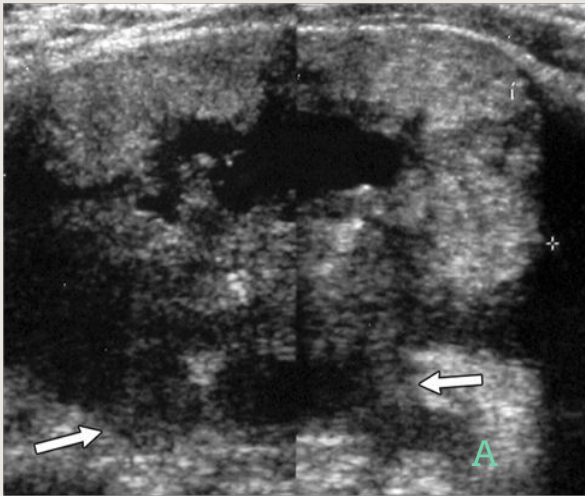
Psammoma bodies (arrow), which are 10–100 μm in diameter.



Transverse sonogram of the right lobe of the **thyroid** demonstrates punctate echogenic foci **without** posterior acoustic shadowing, findings indicative of **microcalcifications** (arrows) which suggest **malignancy**. If you find this you have to take biopsy FNA (**Fine needle aspiration**).

⁶ if you see it, you are handicap to send it to surgery, so you have to do FNA before sending the patient to surgery.

Anaplastic thyroid carcinoma in an 84-year-old woman.



Nodules invading the capsule suggesting a very malignant tumor (e.g. medullary carcinoma)

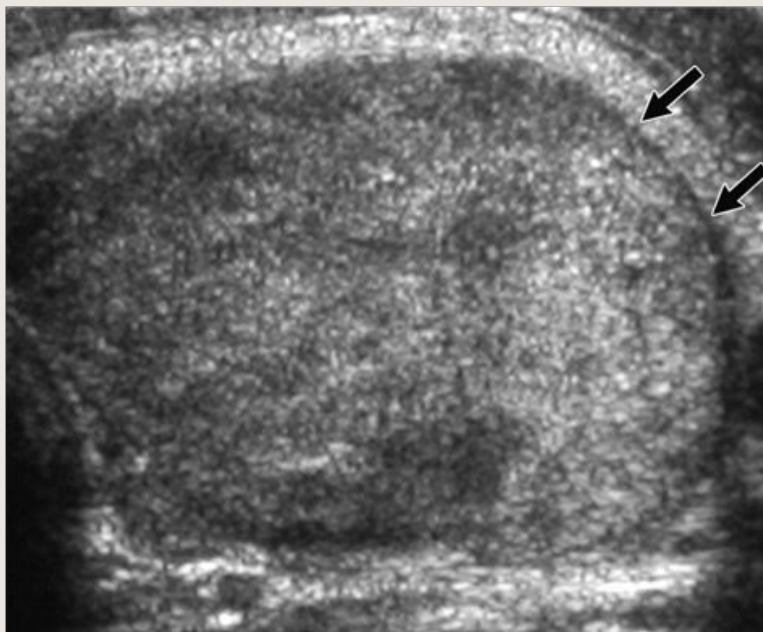
(A) Transverse sonogram of the left lobe for the thyroid shows an advanced tumor with infiltrative posterior margins (arrows) and invasion of prevertebral muscle. Anaplastic type invading the capsule and prevertebral muscles. (B) Axial contrast-enhanced CT image shows a large tumor that has invaded the prevertebral muscle (white arrows). (Dr talked about the carotid artery)

Margin, Contour, and Shape:

-A completely uniform halo around a nodule is highly suggestive of benignity, with a specificity of 95%.

Presence of halo = most likely benign.

Follicular adenoma in a 30-year-old woman:

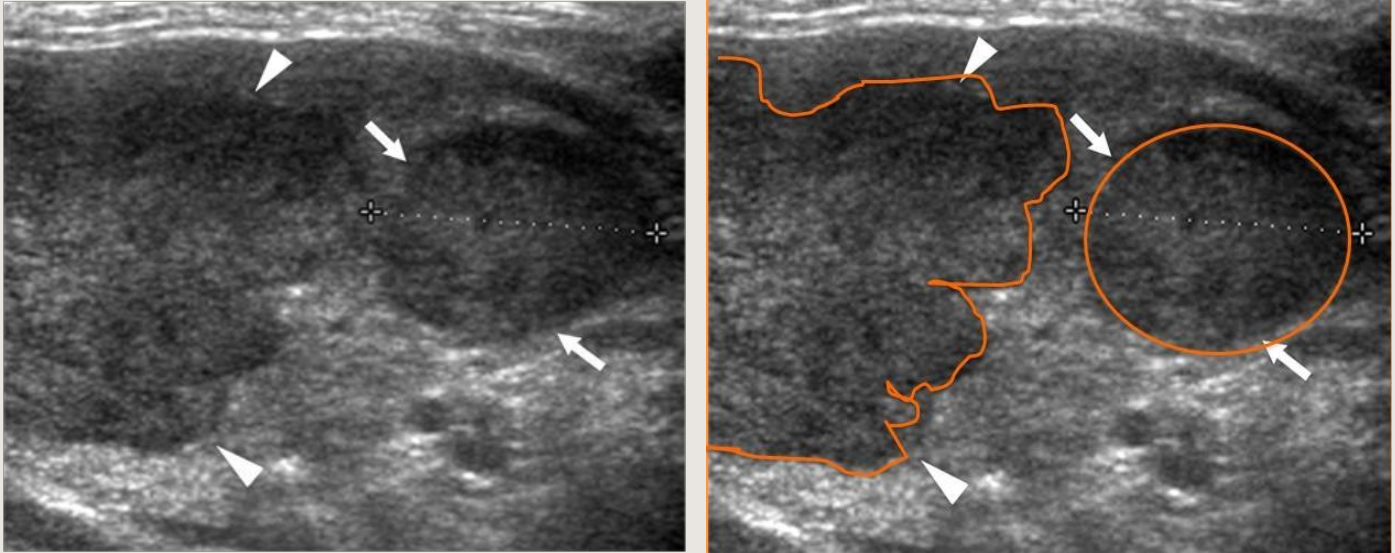


Halo (arrows) suggesting benign lesion (well capsulated)

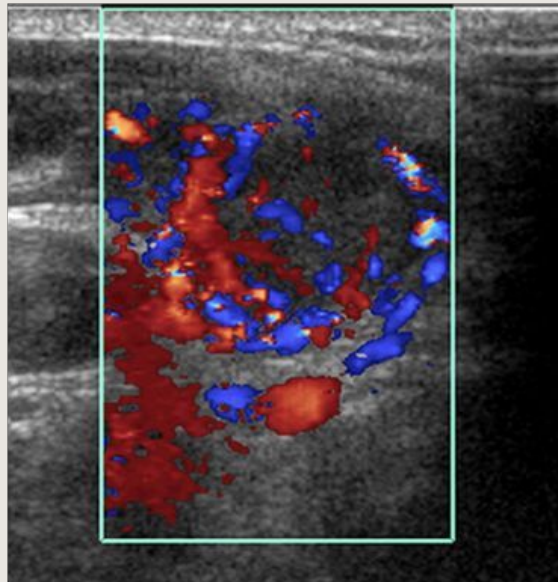
Vascularity

- Papillary thyroid carcinomas had some intrinsic blood flow
- Avascular nodule is very unlikely to be malignant.
- When vascularity of the nodule is within the center it is usually considered malignant while if it is in the periphery it is considered as a benign.

Renal cell carcinoma metastases to the thyroid in a



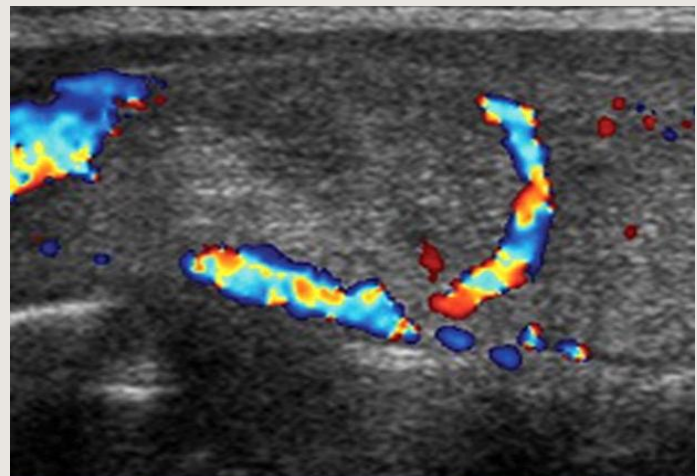
Longitudinal sonogram of the right lobe of the thyroid shows a round **hypoechoic** nodule (arrows) and an **irregular-shaped hypoechoic** nodule (arrowheads).



Color Doppler sonogram of the round nodule shows increased internal vascularity.

Follicular adenoma in a 36-year-old woman:

Longitudinal color Doppler sonogram of the right lobe of the thyroid shows perinodular flow around a follicular adenoma. (Flow around the follicle, not intrinsic)



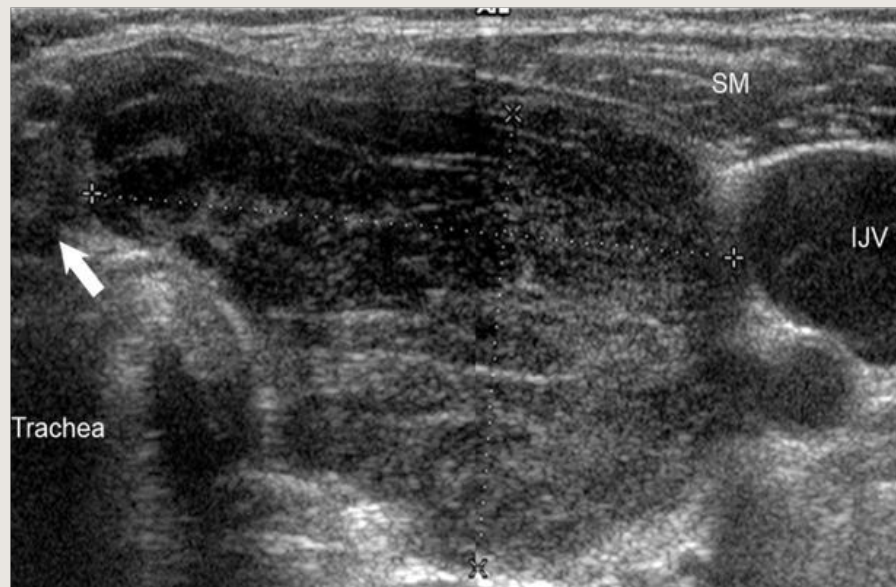
Hypoechoic Solid Nodule:

Marked **hypoechoogenicity** is very suggestive of **malignancy**.

- Benign → **Hyper**-echoic: Presence of halo → **A**vascularity.

- Malignant → **Hypo**-echoogenicity: Absence of halo → **I**ncrease vascularity.

B cell lymphoma of the thyroid in a 73-year-old woman with Hashimoto thyroiditis:



Diffused hypoechoogenicity suggests neoplastic changes

Transverse sonogram of the left lobe of the thyroid shows a large heterogeneous mass (between calipers) with marked hypoechoogenicity when compared with the strap muscles (SM). A normal isthmus (arrow) also is visible. IJV = internal jugular vein. large heterogeneous mass (between calipers) with marked hypoechoogenicity.

Non Specific US Features:

- The size of a nodule **is not helpful** for predicting or excluding malignancy.
- There is a common but mistaken practice of selecting the largest nodule in a multinodular thyroid for FNA.

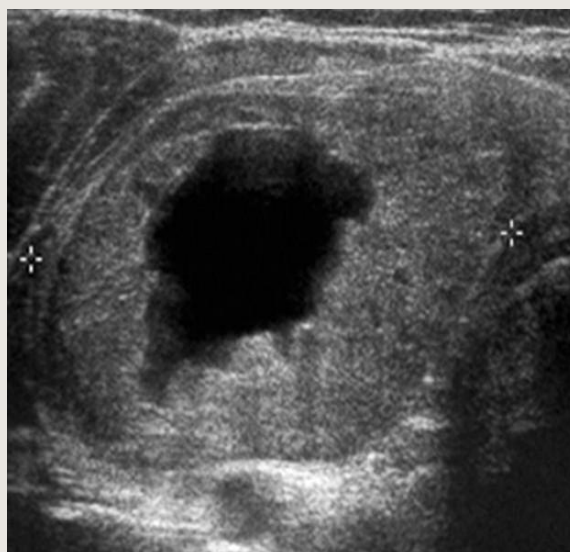
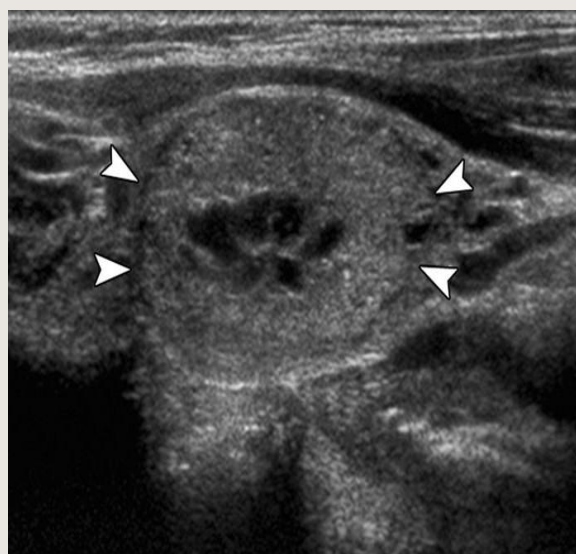
Interval Growth of a Nodule

- In general, interval growth of a thyroid nodule is a **poor indicator of malignancy**. Benign thyroid nodules may change in size and appearance over time.
- The exception is clinically detectable **rapid interval growth**, which most commonly occurs in **anaplastic thyroid carcinoma** but also may occur in lymphoma, sarcoma, and, occasionally, high-grade carcinoma.
- Number of Nodules: Although most patients with nodular hyperplasia have multiple thyroid nodules and some patients with thyroid carcinoma have solitary nodules, the presence of multiple nodules should never be dismissed as a sign of benignity.

Recommendations for Thyroid Nodules 1 cm or Larger in Maximum Diameter

US Feature	Recommendation
Solitary nodule	
Microcalcifications	Strongly consider US-guided FNA if ≥ 1 cm
Solid (or almost entirely solid) or coarse calcifications	Strongly consider US-guided FNA if ≥ 1.5 cm
Mixed solid and cystic or almost entirely cystic with solid mural component	Consider US-guided FNA if ≥ 2 cm
None of the above but substantial growth since prior US examination	Consider US-guided FNA
Almost entirely cystic and none of the above and no substantial growth (or no prior US)	US-guided FNA probably unnecessary
Multiple nodules	Consider US-guided FNA of one or more nodules, with selection prioritized on basis of criteria (in order listed) for solitary nodule*
(This table is for your information)	

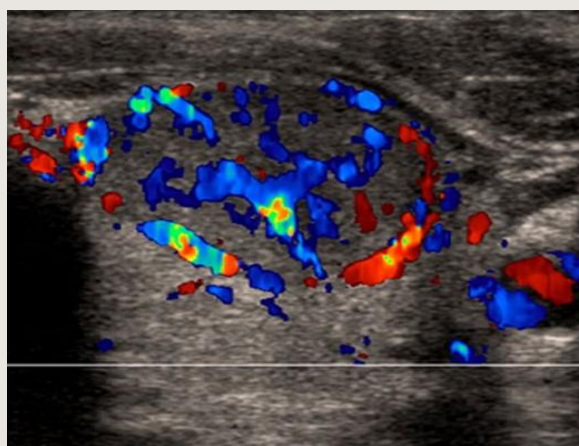
Thyroid nodules of varying parenchymal composition (solid to cystic)



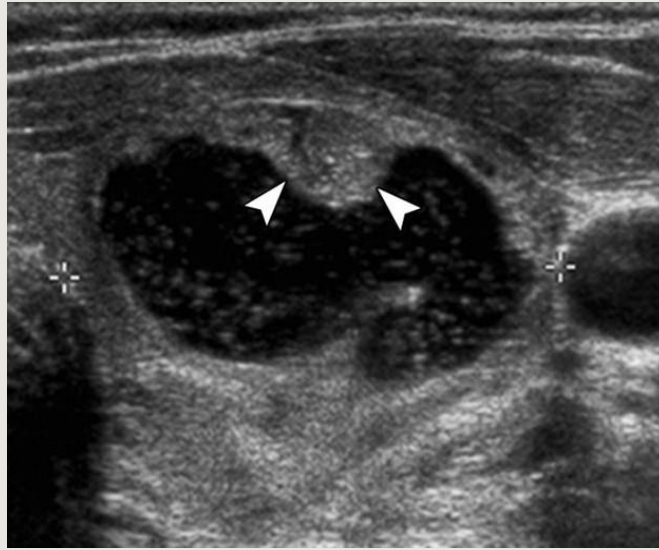
- **Left image:** Sagittal image of predominantly solid nodule (arrowheads), which proved to be benign at cytologic examination.
- **Right image:** Transverse image of mixed solid and cystic nodule (calipers), which proved to be benign at cytologic examination.
- **both images have halo = benign tumor.**

Vascularity suggests malignancy:

- Predominantly solid thyroid nodule: Addition of color Doppler mode shows marked internal vascularity, indicating increased likelihood that nodule is malignant. This was a **papillary carcinoma**.



Predominantly cystic nodule with small solid-appearing mural component:



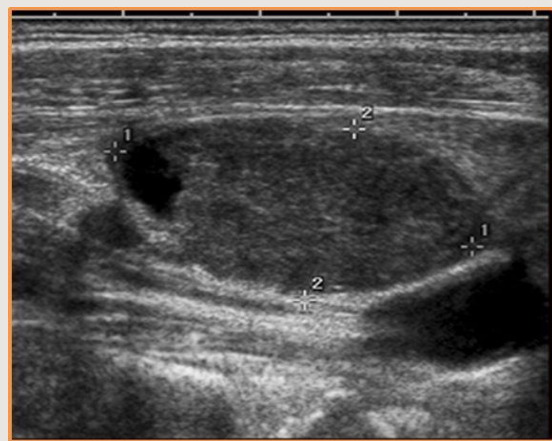
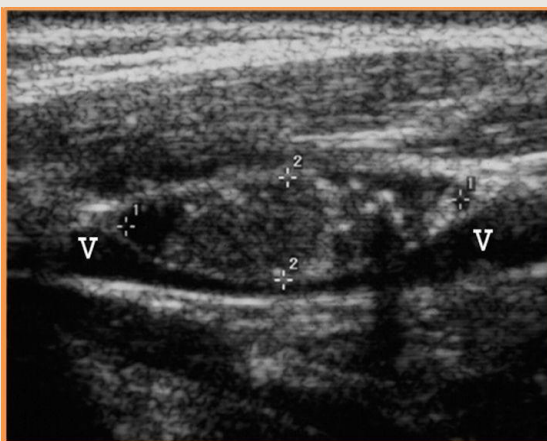
Gray-scale image shows predominantly cystic nodule (calipers) with small solid-appearing mural component (arrowheads). + Halo in addition of color, Doppler mode demonstrates flow within mural component (arrowheads), confirming that it is tissue and not debris. US-guided FNA can be directed into this area. The lesion was benign at solid-appearing cytologic examination.

US Features of Malignant Lymph Nodes

1. Rounded bulging shape.
2. Increased size.
3. Replaced fatty hilum.
4. Irregular margins.
5. Heterogeneous echotexture.
6. Calcifications.
7. Cystic areas.
8. Vascularity throughout the lymph node instead of normal central hilar vessels at Doppler imaging.

Keep in mind US is suggestive NOT diagnostic.

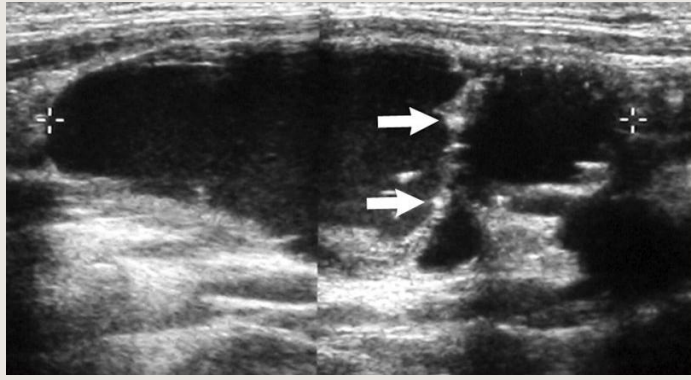
Abnormal cervical lymph nodes:



(a) Sagittal US image of enlarged node (calipers) with central punctate echogenicities, consistent with microcalcifications, shows mass effect on internal jugular vein (V) (compression). it was proved to be metastatic papillary carcinoma.

(b) Sagittal US image of enlarged node (calipers) with cystic component. It was proved to be metastatic papillary carcinoma.

Papillary carcinoma and cystic lymph node metastasis in a 28-year-old woman:



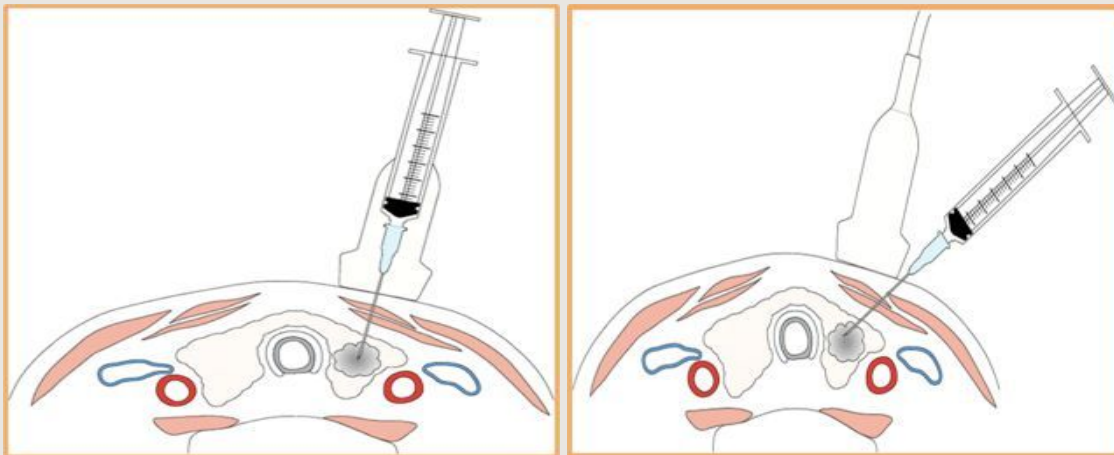
-US shows irregular hypoechoic tumor and microcalcification, the arrows refer to foci microcalcification.

-If there is cysts → another indication for malignant.

US-guided FNA Technique:

The needle may be introduced parallel or perpendicular to the transducer, and the needle tip should be carefully monitored during the procedure.

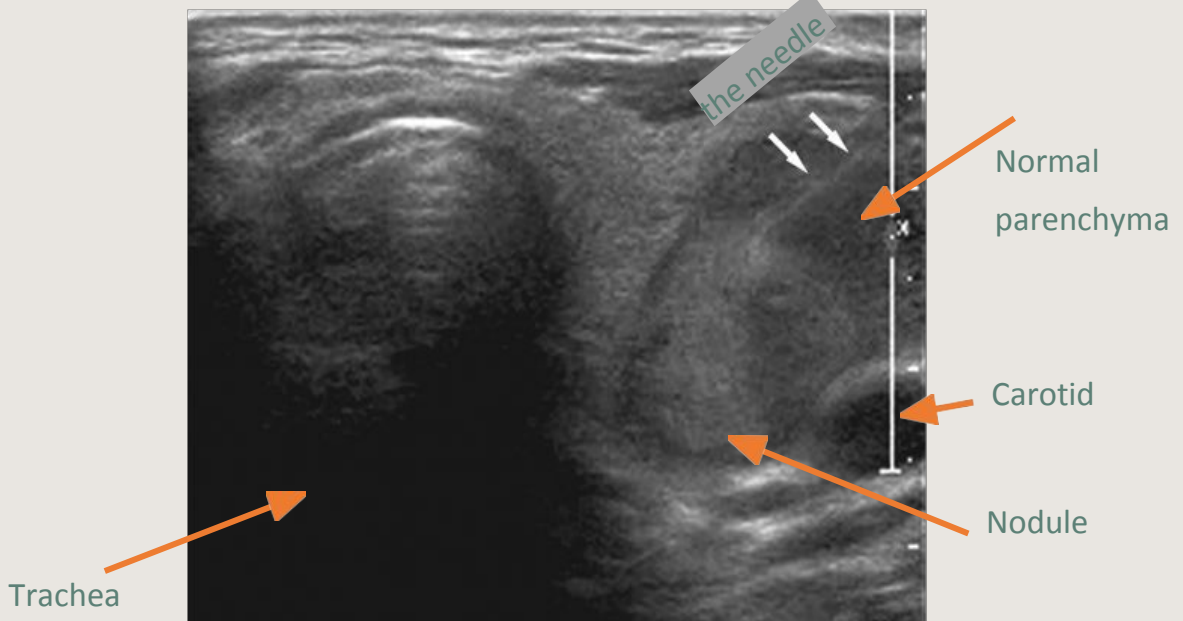
Diagram shows insertion of the needle in a plane parallel to that of scanning.



You have to use US guidance:

- 1-To target the needle to go inside the nodule.
- 2-To not injure the carotid.
- 3-To not injure the trachea.

Parallel positioning of the fine-gauge needle for thyroid nodule biopsy:



To summarize:

First you have to identify whether it is euthyroid or hyperthyroid → If it is hyper you have to assess if it's solitary nodule or multiple or Grave's → You have to assess by US if it is neoplastic or not → If you suspect malignancy do FNA to confirm.

* If it is papillary carcinoma, It is hard to diagnose even by FNA.

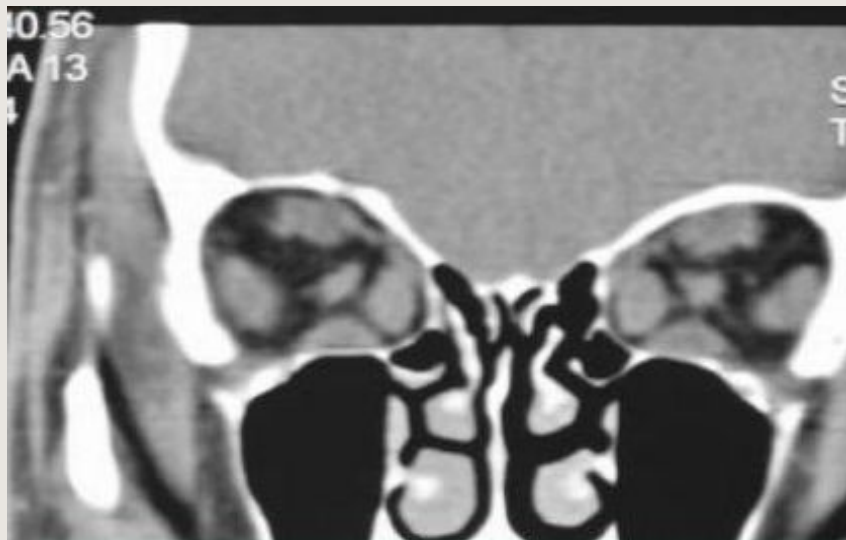Thyroid Ophthalmopathy (Graves' Disease):

Clinical history:

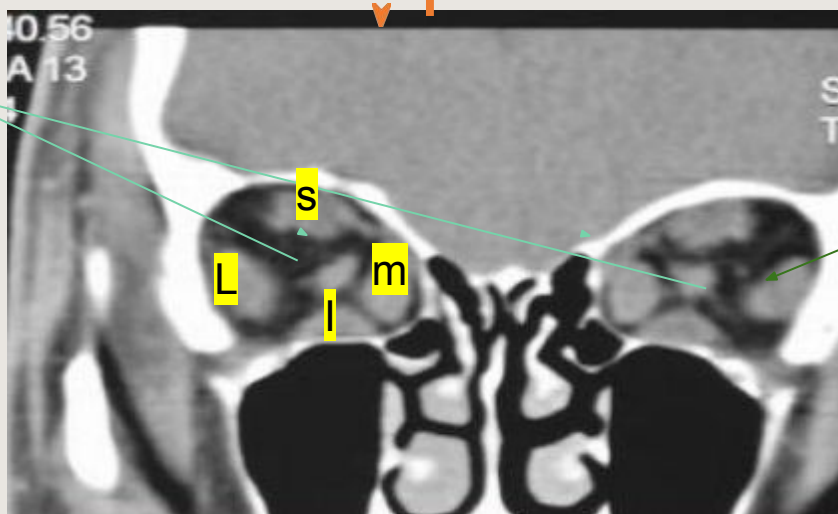
- **Slow onset** (months), **painless** exophthalmos. (Usually presented by **bilateral** proptosis)

Patterns of muscle involvement in thyroid ophthalmopathy:

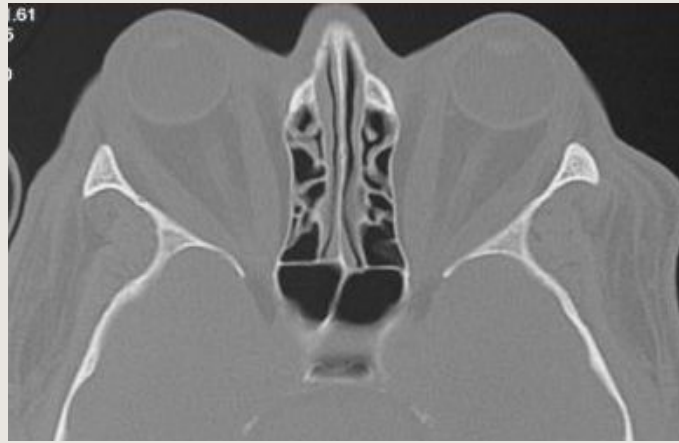
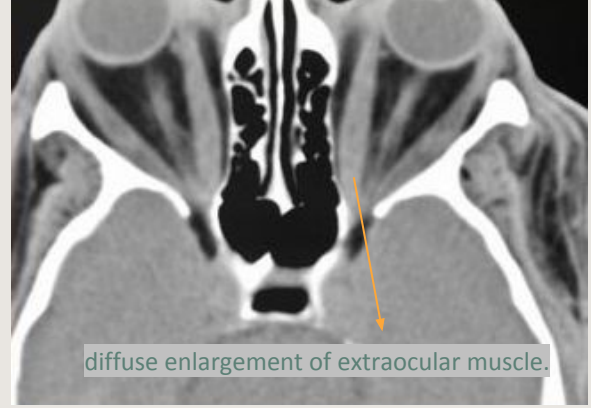
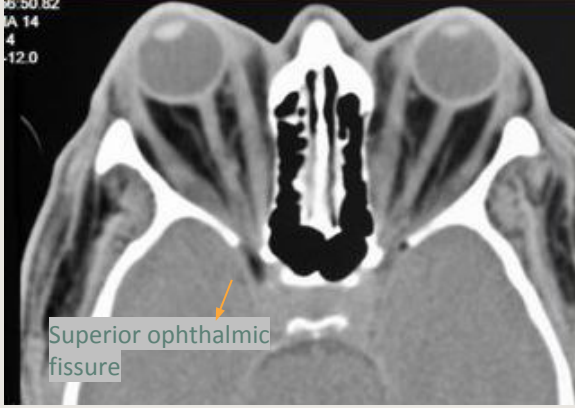
1. **Bilateral (85%)**
2. Unilateral (5%)
3. Normal muscles (10%)
 - Involvement of **All** muscles is **the most common scenario** of extraocular muscle enlargement.
 - If only individual muscles involved, commonly its **Inferior** then **Medial recti muscles**
 - **Lateral rectus muscle: last to become involved**; rarely/never the only muscle involved
 - The first muscles get affected respectively are: **I'M SLOW** (**I**nferior, **M**edial, **S**uperior, **L**ateral) **IMP**
 - Muscle enlargement characteristically involves the body of the muscle, sparing the tendinous attachment to the globe. (does not affect the tendon)
 - Patients should not be having hyperthyroid (some have euthyroid).
 - **CT Coronal imaging** is **the method of choice** for assessing muscle thickness.



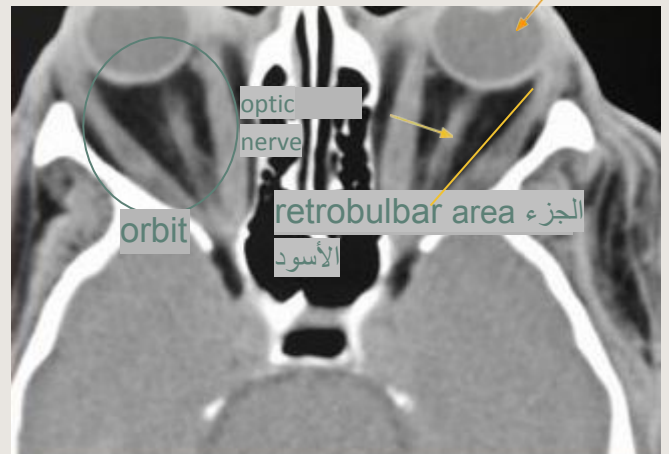
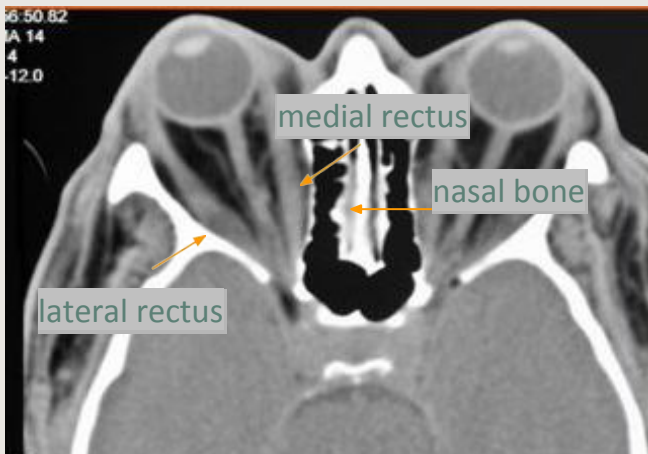
optic nerve the circle in the middle between 4 rectus muscles



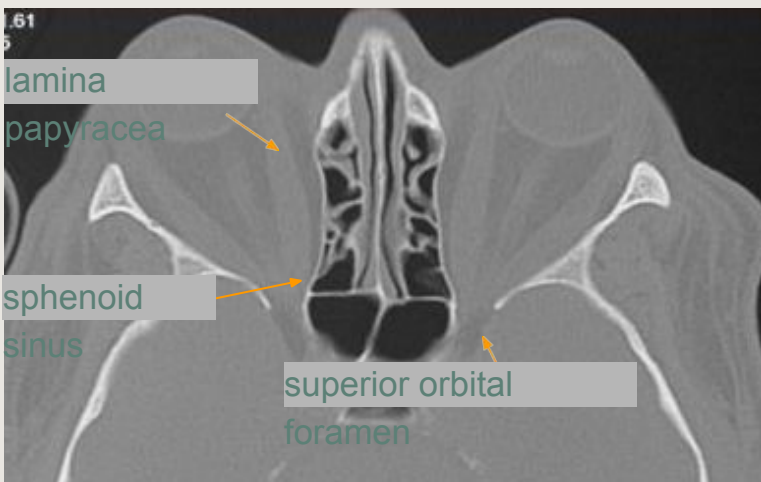
Lateral rectus muscle



CT axial image level of orbit:



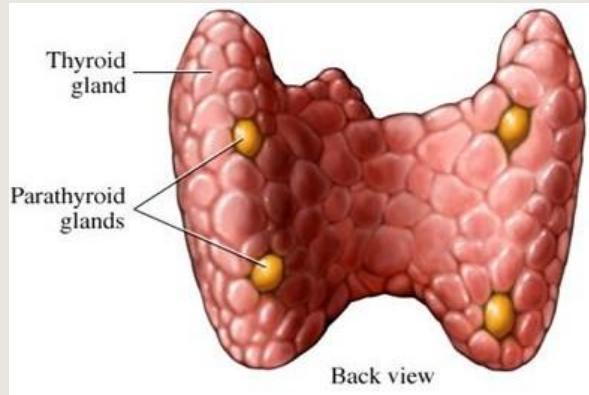
Soft tissue window



Bone window

- Radiological features:** The disease is bilateral
1. Exophthalmos protrusion (because the globe is outside the orbit).
 2. Enlargement of extraocular muscles.
 3. increased retrobulbar fat pad.
 4. herniation in the fat through superior ophthalmic fissure.
 5. medial impression of lamina papyracea.
 6. Stretching of optic nerve.

Anatomy of the Parathyroid gland



- Two pairs of glands usually positioned behind the left and right lobes of the thyroid.
- Typically 4 parathyroid glands (Superior and Inferior) parathyroid glands.

Renal Osteodystrophy

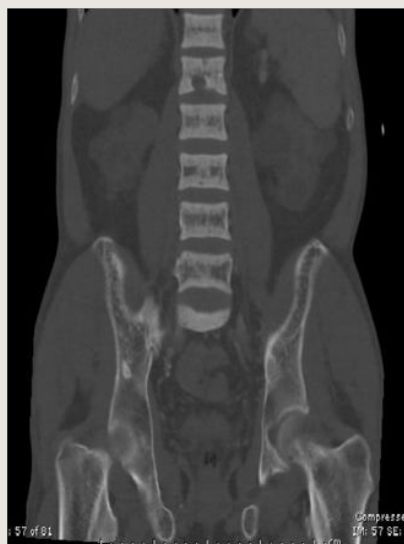- Seen in setting of: chronic, **end-stage renal disease**.

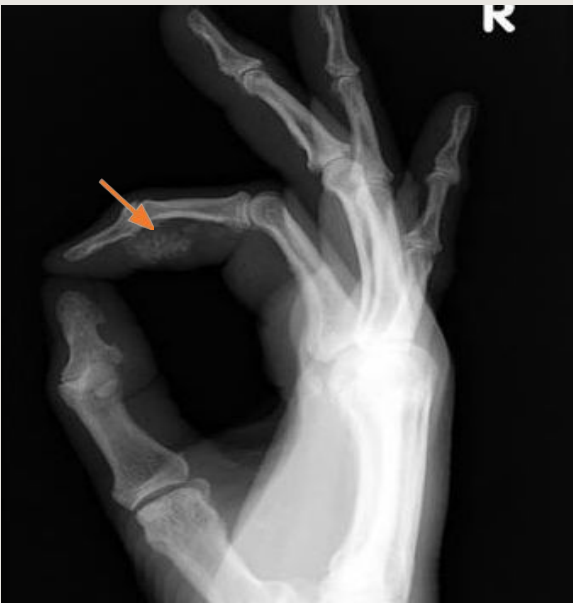- Related to combination of:

1. **Osteomalacia.**
2. **Secondary hyperparathyroidism** (in primary the patient will present with renal stones)

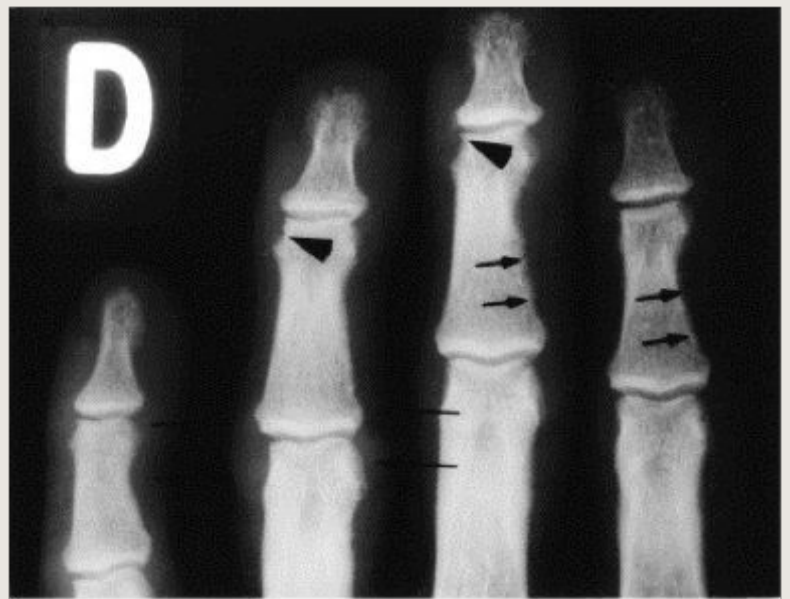
- **Radiological manifestation**

1. **Bone resorption** mainly (Sub-periosteal)
 2. Cortical thinning.
 3. **Soft tissue and vascular calcifications**
 4. **Osteosclerosis**
 5. **Brown tumors** (seen in primary rather in secondary).
- **Osteopenia** is the most common finding; however, **10-20%** of patients also exhibit osteosclerosis.
 - **Characteristic finding of osteosclerosis is "Rugger jersey spine"**, Bands of hazy sclerosis that parallels the vertebral body endplates.
 - Both axial and appendicular skeleton involved.
 - Increased risk for **pathologic fracture**.

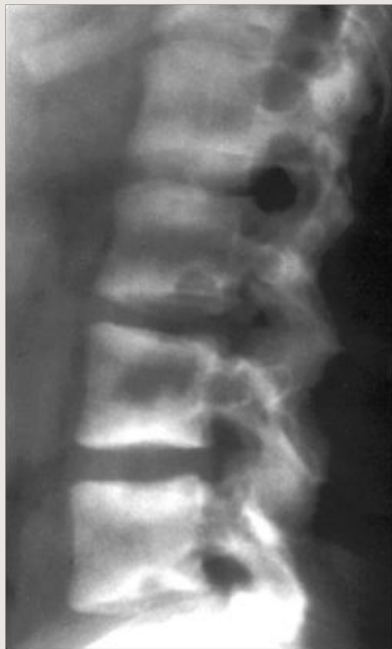



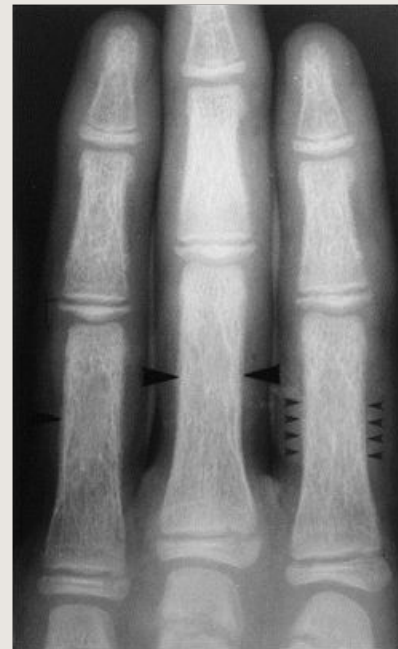Soft tissue calcification



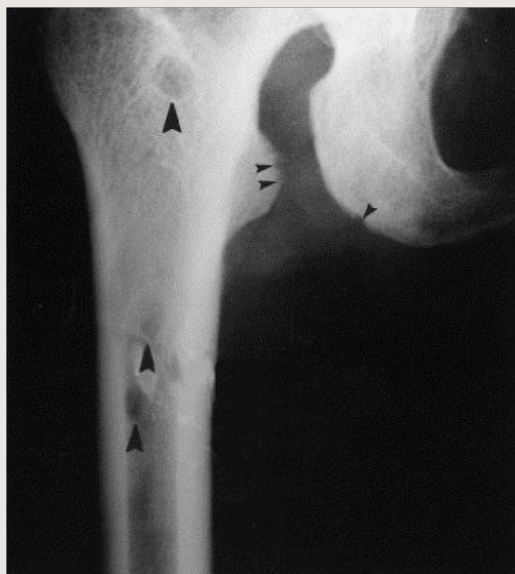- Typical subperiosteal bone resorption at the "radial aspects of the middle phalanges" (small arrows) with bone resorption at the margins of the distal interphalangeal joints (short arrows).



Rugger jersey spine



Cortical thinning



Subligamentum resorption + Brown tumors

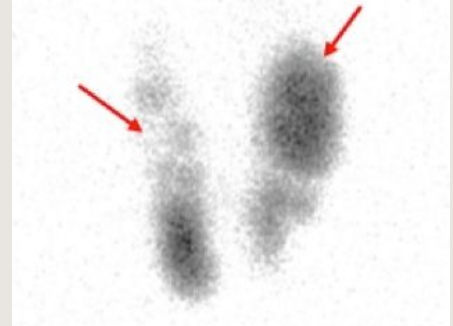
SUMMARY

- The first modality of choice in palpable thyroid nodule is **ULTRASOUND**
- A completely uniform halo around a nodule is highly suggestive of benignity, with a specificity of 95%.
- **Signs of malignant nodules:**
 - 1. **Micro-calcifications** 2. Local invasion 3. A nodule that is taller than it is wider 4. Markedly reduced echogenicity (hypoechoogenicity) 5. **Lymph node metastases** 6. **Absence of a halo** 7. Defined **irregular margins** 8. Solid composition.
- **US Features of Malignant Lymph Nodes:**
 - 1. Rounded bulging shape 2. Increased size 3. Replaced fatty hilum 4. Irregular margins 5. Heterogeneous echotexture 6. Calcifications 7. Cystic areas 8. Vascularity throughout the lymph node instead of normal central hilar vessels at Doppler imaging
- **FNA:**
 - **In case of malignant nodules features DO FNA ULTRASOUND GUIDING..** You have to use US guidance, why: 1- to target the needle to go inside the nodule. 2- To not injure the carotid. 3- To not injure the trachea.
- **Radiological features of Grave's ophthalmology:**
 - The disease is bilateral, 1. Exophthalmos protrusion (because the globe is outside the orbit) 2. Enlargement of extraocular muscles 3. increased retrobulbar fat pad 4. herniation in the fat through superior orbital fissure 5. Stretching of optic nerve.
- **Renal Osteodystrophy (parathyroid disease):**
 - **Seen in setting of chronic and end-stage renal disease.** Related to combination of Osteomalacia and Secondary hyperparathyroidism.
 - Radiological manifestations: 1. **Bone resorption mainly (Sub-periosteal)** 2. Cortical thinning 3. Soft tissue and vascular calcifications. 4. **Osteosclerosis (Rugger jersey spine)** 5. **Brown tumors**

QUESTIONS

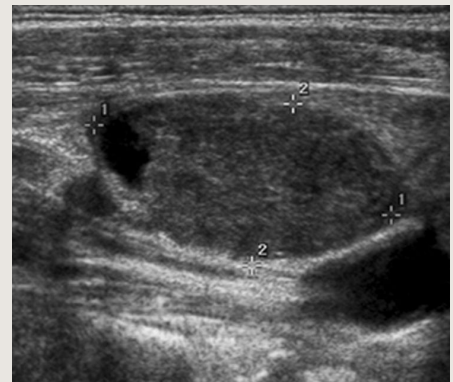
1. Describe the nodule in the picture?

- a) hot nodule
- b) Graves disease
- c) Toxic multinodular
- d) Thyroiditis



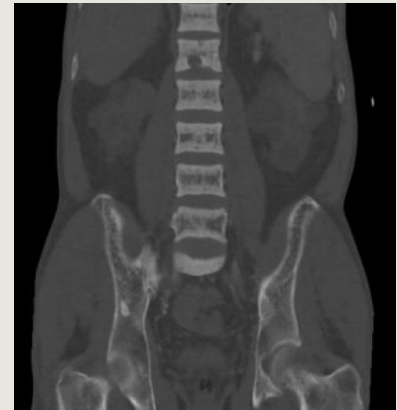2. The picture shows :

- a) cystic nodule
- b) metastatic papillary carcinoma
- c) follicular adenoma
- d) multinodular goiter



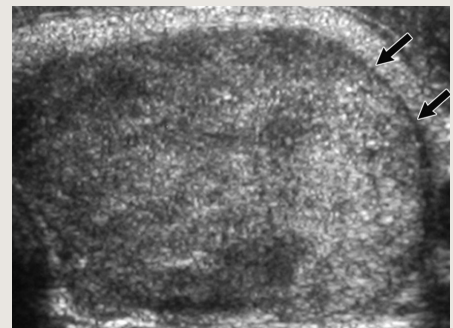
3. Name the sign ?

- a) Rugger Jersey
- b) Spina bifida
- c) Aaron sign
- d) Chvostek sign



4. The picture shows:

- a) cystic nodule
- b) metastatic papillary carcinoma
- c) follicular adenoma
- d) multinodular goiter



- 1. C
- 2. B
- 3. A
- 4. C

help us improve with your feedback:



RadiologyRadiology437@gmail.com

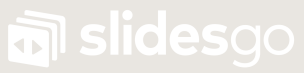

We would be happy, if you leave your feedback

[click Here !](#)

References

- ✓ Slides
- ✓ 436 Teamwork



You did it !

