

Chronic Diarrhea

Objectives:

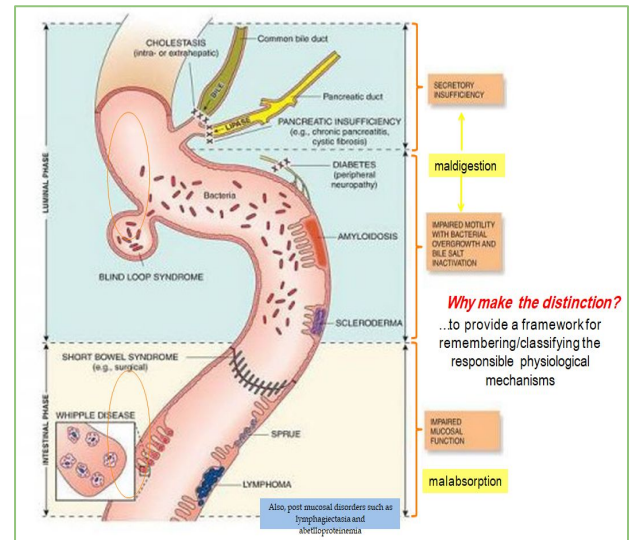
- ★ To have an overview regarding chronic diarrhea:
 - Definition.
 - Pathophysiology.
 - Classification.
 - Approach.
- ★ To discuss common causes of chronic diarrhea:
 - Celiac Disease.
 - Whipple Disease.
 - Tropical Sprue.
 - Small Bowel Bacterial Overgrowth.
 - Exocrine Pancreatic Insufficiency.
 - Bile Salt-Induced Diarrhea.

Color index:

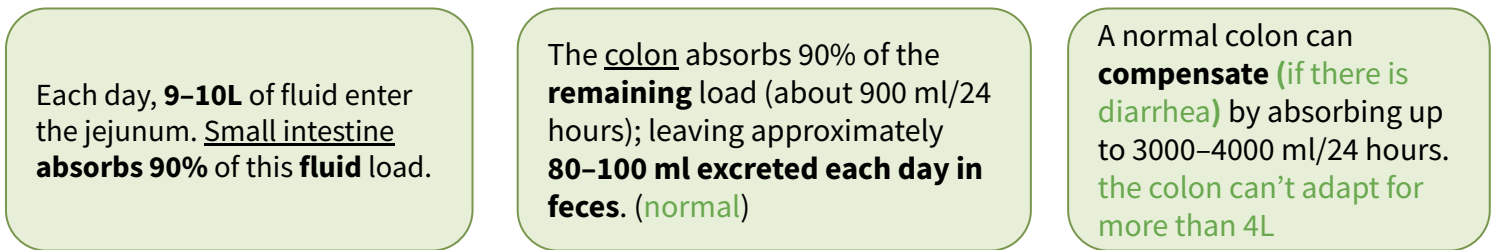
Original text Females slides Males slides
Doctor's notes Text book Important Golden notes Extra

Definitions

- **Diarrhea:** A change in consistency (subjectively become loose) or volume of liquid in the stool or increased frequency
- **Acute Diarrhea:** <2 wks (Usually due to infectious causes)
- **Subacute Diarrhea:** 2-4wks
- **Chronic Diarrhea:** >4-6 wks
- **Maldigestion:** Inadequate breakdown of large molecules.
- **Malabsorption:** Inadequate mucosal transport of digested products to the blood stream

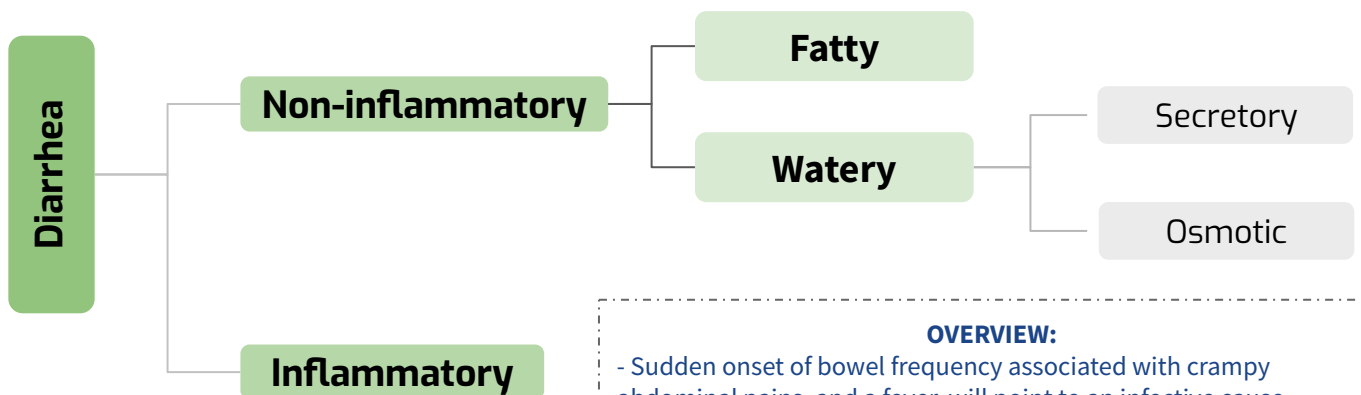


Pathophysiology



So, Which one will cause LARGE VOLUME diarrhea; Small or large bowel disease?
 ➤ Small bowel, because normally it absorb most of the fluid (9L)

Classification of Diarrhea



OVERVIEW:

- Sudden onset of bowel frequency associated with crampy abdominal pains, and a fever, will point to an infective cause
- bowel frequency with loose, blood-stained stools to an inflammatory basis
- The passage of pale, offensive stools that float, often accompanied by loss of appetite and weight loss, to steatorrhea.

Common medications and toxins associated with diarrhea

- ◆ **Acid-reducing agents (H2 blockers, PPIs).**
- ◆ Magnesium-containing antacids.
- ◆ **Antiarrhythmics** (eg, digitalis, quinidine).
- ◆ **Antibiotics.**
- ◆ Antineoplastic agents.
- ◆ Antiretrovirals.
- ◆ **Beta blockers.**
- ◆ Colchicine.
- ◆ **Levothyroxine.**
- ◆ **SSRIs.**
- ◆ **Furosemide.**
- ◆ Metformin.
- ◆ **NSAIDs, ASA.**
- ◆ Prostaglandin analogs (ie, misoprostil).
- ◆ Theophylline.
- ◆ Amphetamines.
- ◆ **Caffeine.**
- ◆ Alcohol.
- ◆ **Narcotic/opioid withdrawal.**
 - Narcotic it self can cause constipation, after withdrawal Diarrhea ensue

1) Watery Diarrhea

Osmotic Diarrhea

- ◆ Poorly absorbed substances that **remain** in the lumen of the intestine and obligate **retention of water** within the lumen by virtue of their **osmotic effects**
- ◆ Osmotic diarrhea is **RELIEVED** by fasting
- ◆ Fecal osmotic Gap = $290 - 2(\text{stool Na} + \text{stool k})$
 - **>50 mOsm/Kg** is Suggestive of an osmotic diarrhea
 - **>100 mOsm/Kg** is more specific (Definitive!)



Ingestion of poorly absorbed agent

- ➔ **Carbohydrate malabsorption:** diet high in Fructose or sugar alcohols
- ➔ **Diuretics:** Mannitol
- ➔ **Osmotic laxatives:** Magnesium, phosphate, sulfate, sorbitol, lactulose



Loss of nutrient transporter

- ➔ **Lactose intolerance** (due to **lactase deficiency**)
- ➔ **Disaccharidase deficiency**
- ➔ **Glucose-galactose malabsorption**

1) Watery Diarrhea

Secretory Diarrhea

- ◆ There is both active intestinal secretion of fluid and electrolytes, and decreased absorption.

How to differentiate between **Osmotic** and **Secretory** ?

- 1) **Diagnostic fast test:** Osmotic diarrhea is **RELIEVED** by fasting, while secretory diarrhea **does NOT** respond to fasting !
- 2) **Fecal osmotic gap:**
 - a) >100 mOsm/kg → Osmotic diarrhea
 - b) <50 mOsm/kg → Secretory diarrhea


Causes include:

- 1 **Infections:** The most common cause is a bacterial toxin.
- 2 **Pancreatic insufficiency**
- 3 **Inflammation & Dysregulation:** Diverticulitis, Vasculitis, **microscopic colitis**, Gastroenteritis
- 4 Absence of an ion-transport mechanism.
- 5 Reduction of mucosal surface area by surgery or disease.
- 6 Congenital chloridorrhea
- 7 **Bile Acid induced diarrhea:** Ileal bile acid malabsorption.
- 8 **Idiopathic:** Epidemic (Brainerd), Sporadic.
- 9 Medications (NSAIDs, Colchicine), stimulant laxative abuse, toxins.
- 10 **Malignancy:** Colon CA, lymphoma, rectal villous adenoma
- 11 **Abnormal motility:** DM-related dysfunction, IBS, Post-vagotomy diarrhea.
- 12 **Circulating secretagogues (endocrinopathies):** as in Addison's disease, Hyperthyroidism, **Carcinoid syndrome**, Pheochromocytoma, **Gastrinoma** (a.k.a ZE syndrome) VIPoma, Somatostatinoma.

An area for your notes

2) Fatty Diarrhea (Steatorrhea)

- Present with **Bloating**, flatulence, **greasy** malodorous stools that is **foul smelling** and **difficult to flush**
- **Weight loss**, s/s of **vitamin deficiencies**¹ (peripheral neuropathy, easy bruising)
- **Iron deficiency anemia**, **coagulopathy**, hypoalbuminemia, osteopenia.



Malabsorption

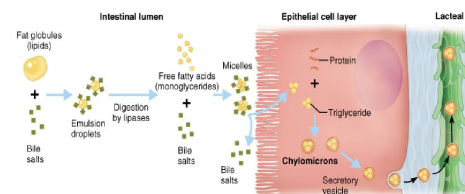
inadequate mucosal transport of digestion products

- **Mucosal diseases** (eg, **Celiac sprue**, Whipple's disease).
- **Mesenteric ischemia**.
- **Structural disease**: Short bowel syndrome, Post-resection diarrhea.
- **Small bowel bacterial overgrowth** (bile salt deconjugation).
- **Lymphatic obstruction** (Due to radiation, infection, **Lymphoma**)

Maldigestion

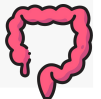inadequate breakdown of triglycerides

- **Pancreatic exocrine insufficiency** (eg, chronic pancreatitis, **CF**).
- **Inadequate luminal bile acid concentration** (eg, advanced primary biliary cirrhosis).



3) Inflammatory Diarrhea

- Presents as **small volume** diarrhea with **Blood, mucus**, and pus, with **abdominal pain** and **fever**.
- Positive fecal **leukocytes**, gross or occult **blood**, **ESR/CRP**, **leukocytosis**, **Persists on fasting**.



Causes/DDx

Inflammatory bowel disease:

Ulcerative colitis, Crohn's disease, Diverticulitis, Ulcerative jejunoileitis.

Infectious diseases:³

- Pseudomembranous colitis (Clostridium difficile infection)²
- Invasive bacterial infections (e.g., some types of E. Coli, Shigella, **TB**, MAC, yersiniosis)
- Ulcerating viral infections (e.g., **cytomegalovirus**, Herpes simplex)
- Invasive parasitic infections (e.g., amebiasis, strongyloides).

- **Ischemic colitis.**
- **Radiation colitis.**
- **Neoplasia:**
 - Colon cancer
 - Lymphoma

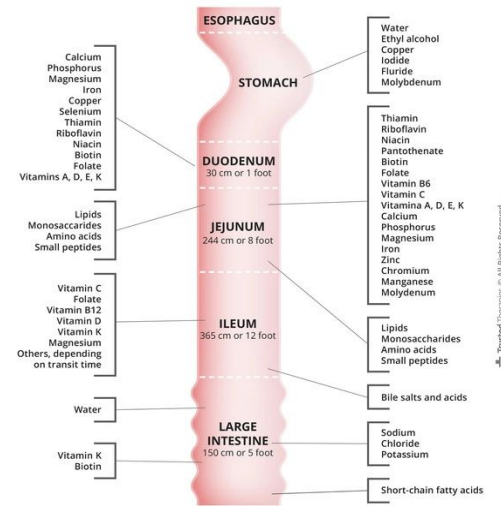
1. Fat soluble vitamins (AKED)

2. Diarrhoea occurs in the first few days after taking the antibiotic or even up to 6 weeks after stopping the drug. The causative agent is C. difficile. First-line antimicrobial therapy involves metronidazole (500 mg orally 3 times daily for 10 days) or vancomycin (125 mg orally 4 times daily for 7–10 days). Although vancomycin is more effective than metronidazole against hypervirulent C. difficile strains (e.g. ribotype 027), it is more expensive and may drive the emergence of vancomycin resistance in other organisms (e.g. enterococci, Staph. aureus). For these reasons, some authorities reserve its use for relapse (15–30% of patients), failure of initial response or severe infection.

3. **SEECYS**: Salmonella, E.coli, Entamoeba, Campylobacter, Shigella, Yersinia enterocolitica

◀ Nutrient / vitamin absorption¹

Duodenum/Jejunum	Ileum
<ul style="list-style-type: none"> Carbohydrates / simple sugars. Fats. Amino Acids. Iron. Fat Soluble Vitamins (A, D, E, K). Calcium. Magnesium. Minerals. 	<ul style="list-style-type: none"> Vitamin B12. Bile salts. Magnesium.
	Colon
	<ul style="list-style-type: none"> Short-chain fatty acids. Vitamin K * Vitamin B7 (Biotin) * <p>* Produced by bacterial gut flora.</p>



Note: The duodenum, jejunum and ileum make up the small intestine.

Signs / Symptoms of Malabsorption

Malabsorption of	Clinical features	Lab findings
Calories	Weight loss w/ normal appetite	-
Fat	Pale voluminous stool, steatorrhea	Stool fat >6 g daily
Protein	Edema, muscle atrophy, amenorrhea	Low albumin, low protein
Carbohydrates	Watery diarrhea , flatulence, milk intolerance	Stool pH < 6 ² ; stool osmotic gap >100; increased breath hydrogen
Vitamin B12	Anemia , subacute combined degeneration of spinal cord (paresthesias, ataxia, loss of position/ vibratory sense), hypersegmented neutrophils , neuropathy	Macrocytic anemia ; low B12 level; increased MMA and homocysteine levels; abnormal Schilling test
Folic acid	Anemia	Macrocytic anemia ; decreased serum/RBC folate; increased homocysteine level
Iron	Anemia, glossitis, pagophagia	Microcytic anemia ; decreased serum iron and ferritin levels; increased TIBC
Calcium and Vitamin D	Paresthesia, tetany, pathologic fractures, positive Chvostek and Trusseau signs, osteoporosis	Low serum calcium; abnormal DEXA; elevated Alk Phos
Vitamin A	Follicular hyperkeratosis, night blindness	Decreased serum carotene
Vitamin K	Easy bruising, bleeding disorders	Elevated INR; decreased Vitamin K-dependent coagulation factors (2, 7, 9, 10)
Vitamin B (general)	Cheilosis, painless glossitis, angular stomatitis, acrodermatitis	-

1. Why this is important? You expect abnormalities when resecting a certain part of the GI. For eg, disease of the terminal ileum → Vit. B12 deficiency. Disease of the colon → Vit. K deficiency (coagulopathy and megaloblastic anemia).
 2. due to colonic bacterial fermentation to CO₂, H₂, and short chain FA

How to approach a patient with diarrhea?

History

Onset Congenital, abrupt or gradual	Stool characteristics Watery, bloody, fatty	Abdominal pain IBD, IBS or ischemia	Aggravating factors Diet, stress	Iatrogenic diarrhea Drugs, radiation, surgery	Systemic diseases Hyperthyroidism, DM, Collagen vascular disease, tumor syndromes, AIDS, Ig deficiencies
Pattern Continuous, intermittent	Fecal incontinence	Weight loss Malabsorption, Neoplasm	Mitigating factors Diet, OTC or Rx drugs	Factitious diarrhea Laxatives	
Duration Acute, Subacute, Chronic			Previous evaluation		
Epidemiology Travel, Food, water					

Physical examination

General Fluid balance, nutrition	Skin Flushing, rashes, dermatographism	Thyroid Masses	Chest Wheezing	Heart Murmur	Abdomen Hepatomegaly, mass, ascites, tenderness	Anorectal Sphincter competence, Fecal occult, blood test	Extremities Edema
--	--	--------------------------	--------------------------	------------------------	---	--	-----------------------------

Routine laboratory tests

CBC Anemia*, leukocytosis** *As a consequence of nutrients deficiency or GI bleeding **Seen in inflammatory etiologies	Chemistry screen Fluid electrolyte, nutritional status and serum protein/ globulin
--	--

Stool analysis

Weight	Electrolytes Osmotic gap	pH¹ carbohydrates malabsorption	Fecal occult blood testing Bleeding	Stool WBCs inflammation	Fat output Sudan stain Quantitative	Laxative screen
---------------	------------------------------------	--	---	-----------------------------------	--	------------------------

1. Because if the CHO didn't get absorbed, the normal flora will ferment them generating acidic radicals

Special laboratory tests

- **Stool culture** (more useful only for acute), An ova and parasite (O&P) exam, Giardia Ag, **C diff**, Coccidia, Microsporidia, Cryptosporidiosis.
- **Fecal leukocytes** (or marker for neutrophils: lactoferrin or calprotectin).
- **Fecal occult blood.**
- Stool electrolytes for **osmolar gap = $290 - 2[\text{Na} + \text{K}]$** .
- **Fat content** (48h or 72h quantitative or Sudan stain).
- **Laxative screen** (if positive, repeat before approaching pt).
- **Imaging:**
 - Small bowel series.
 - CT/MRI or CT/MR enterography.
- **Endoscopy** with small bowel biopsy and aspirate for quantitative culture. (Esp. for celiac disease)
- **Colonoscopy**, including random biopsies. (Esp. for IBD)

An area for your notes

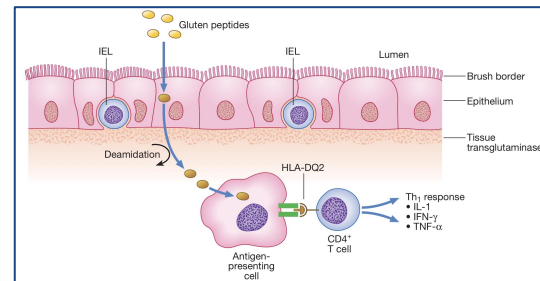
Introduction



- **Small intestinal²** malabsorption of nutrients following the ingestion of **wheat** gluten or related proteins from **rye, barley and oats**.
- A characteristic, though not specific, **villous atrophy** of the small intestinal mucosa.
- **Prompt** clinical and histologic **improvement following** strict adherence to a **gluten free diet**.
- Clinical and histologic relapse when gluten is reintroduced.

Pathophysiology

- 1 The disease affect the mucosa with marked variation ⇒ Loss of normal villous structure (**flattening**) ⇒ Intestinal crypts are elongated and open onto a flat absorptive surface.
- 2 Leaky mucosa with **increased permeability** due to structural changes of the tight junctions between damaged absorptive cells.
- 3 Marked **increase in cellularity** of the lamina propria – plasma cells and **lymphocytes**.

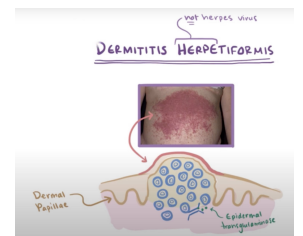


Presentations

Non-specific GI symptoms	Nutritional deficiency	Fat soluble vit. deficiencies	Malignancy	Other
<p>Most common:</p> <ul style="list-style-type: none"> Diarrhea. Bloating. Dyspepsia. 	<p>Anemia⁶ (Iron & folate). Osteoporosis.</p>	<p>Vit A: poor night vision, follicular hyperkeratosis. Vit D: hypocalcemia, osteoporosis. Vit K: easy bruising & bleeding, elevated INR.</p>	<p>T-cell lymphoma.</p> <p>Small bowel adenoCa.</p>	<p>Dermatitis herpetiformis.⁵</p> <p>Elevated ALT & AST.</p> <p>Asymptomatic⁴</p>

At Risk³

- IgA deficiency (2-3%).
- Type 1 DM (3-6%).
- Autoimmune thyroid disease (6-8%).
- Connective tissue disease.
- Down's syndrome.



1. Autoimmune disease that is positive in serology, complicated when uncontrolled, differ from gluten intolerance that has no microscopic abnormalities or antibodies.
 2. **Endoscopic biopsy (GOLD standard)** taken from the duodenum because it is the first contact with gluten,
 3. If these patients present with non-specific GI symptoms, you should think of celiac
 4. If you diagnosed someone with CD, you have to screen 1st degree relatives. You may find structural abnormalities with no symptoms. There is a strong genetic component, with around 10% of first-degree relatives of an index case affected, and there is strong (approximately 75%) concordance in monozygotic twins.
 5. If they start **gluten-free strict diet**, it will disappear but some patients require additional treatment with dapsone
 6. CBC may show microcytic or macrocytic anaemia from iron or folate deficiency and features of hyposplenism (target cells, spherocytes and Howell-Jolly bodies).

Celiac Disease Cont'

Serology

Anti-tissue transglutaminase antibody (IgA):¹

- Sensitivity 95%; specificity 97.5%.
- **BEST INITIAL**

IgA anti-gliadin antibodies:

- Sensitivity 75-90% (~80)
- Specificity 82-95% (~85).

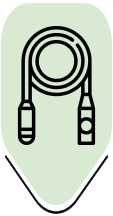Endomysial antibody (IgA):

- Sensitivity 85-98% (~93)
- Specificity 97-100% (~99).

IgG anti-gliadin antibodies:

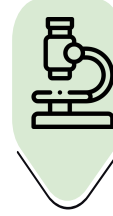- Sensitivity 69-85% (~75) Spec 73-90% (~80).
- **Can be used in IgA deficient patients.**

Diagnosis

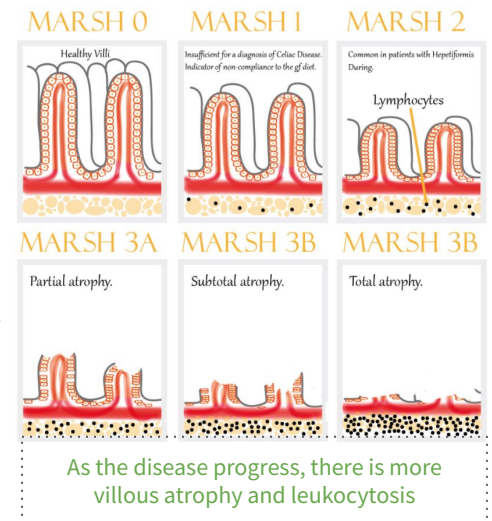


Endoscopy: might be Normal.²

- Loss of mucosal folds, **Crypt hyperplasia**
- Flattening of mucosa. (**Villous atrophy**)
- **Scalloping of mucosa**. Ulcerations.
- **HLA-DQ2** is present in 90-95% of coeliac disease patients and **HLA-DQ8** in about 8%



Biopsy histology: MARSH classification



Management

Education: most common reason for failure to improve with dietary treatment is accidental or unrecognised gluten ingestion

Gluten-free diet: avoid wheat, barley, rye & oat.

Correct nutritional deficiencies (Iron, Ca, Vit D, folate).

Anticipate complications.

Whipple Disease



Chronic systemic infection by **Tropheryma whipplei**. (an intracellular gram-positive bacteria)



Has **GI, CNS, CVS, MSK & skin manifestations.**

Pathophysiology

- Malabsorption – **weight loss, diarrhea** (watery or fatty³) and abdominal pain:
 - Caused by bacterial and **macrophage-predominant** inflammatory cell infiltration of the small intestinal mucosa and **obstruction of mesenteric lymph nodes.**

1) If the antibody screen is positive, **adult** patients should remain on a gluten-containing diet until **duodenal biopsies are taken**. High-titre serology in **children** can be diagnostic **without the need for endoscopy and biopsy**. Antibody titres usually become negative with successful treatment.

2) **Endoscopic appearances should not preclude biopsy**, as the mucosa usually looks normal. As the histological changes can be patchy, an adequate number of biopsies – currently, more than four biopsies from the second part of the duodenum plus one from the duodenal bulb – should be retrieved.

3) Fatty diarrhea because of lymphatic obstruction

PAS the foamy Whipped cream in a CAN

Effect of The Disease on Other Organs or Systems¹



Neurologic:



- Progressive dementia.
- Supranuclear ophthalmoplegia.
- Altered LOC.
- Oculo-masticatory & oculo-facial skeletal dysfunction.

CVS:



- Endocarditis – MV most common.
- Myocarditis.
- Pericarditis.

MSK:



- Seronegative oligo or polyArthralgias.

Skin (common):

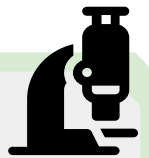

- Hyperpigmentation.

Histopathology

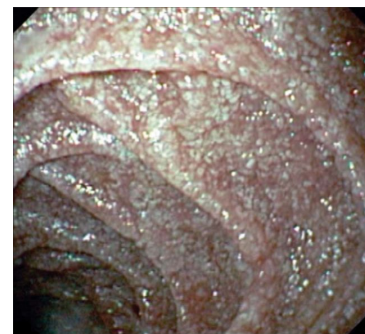


- Foamy macrophages on routine H&E.
- Numerous PAS-positive granular particles² (pink/purple appearing):
 - Lysosomes filled with T. whipplei.



Diagnosis

- Diagnosis is made by the characteristic features on small bowel biopsy, with characterisation of the bacillus by polymerase chain reaction (PCR).
- Whitish to yellow plaque-like patches in 75% of patients (representing lipid droplets and/or lymphangiectasia).



Management



- 2 weeks with Abx to cross BBB:
 - Ceftriaxone 2g IV daily monotherapy THEN Septra (TMP/SMX) DS tab BID x 1 year.³
 - OR Penicillin G (2 MU IV q4h) PLUS streptomycin THEN Septra (TMP/SMX) DS tab BID x 1 year

1. Low-grade fever is common and most patients have joint symptoms to some degree, often as the first manifestation. Occasionally, neurological manifestations may predominate and CNS involvement is the most serious consequence.

2. periodic acid-Schiff (PAS) very specific for whipple disease

3. Long-term follow-up is essential, as clinical relapse occurs in up to one-third of patients, often within the CNS; in this case, the same therapy is repeated or else treatment with doxycycline and hydroxychloroquine is necessary.



Normal Microbiome

- 1** | Stomach $0-10^3$ CFU/ml.
- 2** | Jejunum $0-10^4$:
 - Gram +ve aerobes (oral streptococci, lactobacillus); no gram -ve aerobes.
- 3** | Ileum 10^5-10^9 .
- 4** | Colon $10^{10}-10^{12}$:
 - **Anaerobes:** bacteroides, peptostreptococcus, lactobacillus, bifidobacterium, clostridium.
 - **Facultative aerobes:** e. coli, enterococcus, staphylococcus.

Notice the increasing concentration throughout the tract

Normal barriers that prevent SBBO (a.k.a blind loop syndrome)

- ◆ **Gastric acid & pancreatic enzymes**
 - **What disrupts this barrier?** chronic pancreatitis, low HCl from surgery, pernicious anemia, partial gastrectomy or Long Term PPI.
- ◆ **Intact bowel structure**
 - **What disrupts this barrier?** Surgery, diverticulum. because of bowel stasis
- ◆ **Cleansing effect of bowel motility – interdigestive migrating motor complex**
 - **What disrupts this barrier?** dysmotility (Systemic sclerosis, Diabetic autonomic neuropathy, Chronic intestinal pseudo-obstruction)
- ◆ **Gut immunity – intraluminal secretory IgA**
 - **What disrupts this barrier?** immunodeficiency (Eg, hypogammaglobulinemia)
- ◆ **Competent ileocecal valve**
 - **What disrupts this barrier?** scarring from inflammation, surgery
- ◆ **Competition by other bacteria**
 - **What disrupts this barrier?** antibiotics.

Small Bowel Bacterial Overgrowth (SBBO)

Effect of SBBO



Investigations¹

Jejunal culture – Gold standard.
(If >10⁴ it's abnormal)

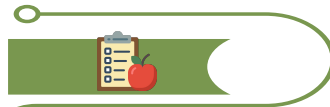Schilling's test:
determine whether you're absorbing vitamin B-12 properly
(Explained Next slide)

C14-labeled bile acid breath test.
C14-xylose breath test.
H breath test.

Presentation



- Bloating, **watery diarrhea**, **abdominal pain**, weight loss, **neuropathy**.
- **Vitamin A,D,E,K deficiency:** therefore bruising, night blindness, bone diseases.



- Iron deficiency.
- Hypoproteinemia, hypoalbuminemia.
- Fat and CHO malabsorption.



- **B12 deficiency¹** – utilized by the bacteria for nutrition.
- **Elevated folate²** level - produced by bacteria.

Management

Nutrition – replace fat soluble vitamins, B12:

- Low CHO diet to limit bacteria substrate.

Treat underlying cause: Most important thing.
e.g. discontinue acid suppressive meds, treat inflammatory Crohn's disease, remove strictures, etc.

7 – 10 days of antibiotics:

- **Metronidazole**, Amox/Clav, **Tetracycline**, Doxycycline, Amoxicillin.
- May need to cycle Abx to avoid resistance.
- If breath testing reveals high methane production, addition of neomycin may be beneficial.

- Bowel cleanse with PEG, Prokinetic.
- Octreotide – at low dose, has a promotility effect: Causes hypomotility at higher doses.
- Probiotics – minimal evidence.

1. leading to anemia
2. There is **NORMAL to ELEVATED** folate; in contrast to extensive celiac disease or bowel resection

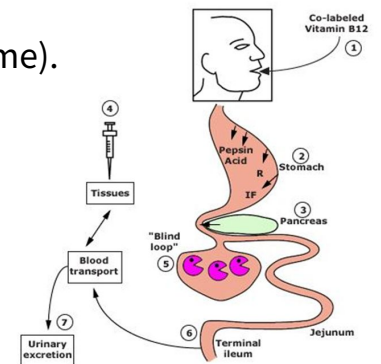
◀ Schilling's Test

Differential Results of The Schilling Tests in Several Diseases Associated With Cobalamin Malabsorption

Cause of Fat Malabsorption	⁵⁸ Co-Labeld Cobalamin	With Intrinsic Factor	With Pancreatic Enzymes	After 5 Days of Antibiotics
Pernicious Anemia	Reduced	Normal	Reduced	Reduced
Chronic Pancreatitis	Reduced	Reduced	Normal	Reduced
Bacterial Overgrowth	Reduced	Reduced	Reduced	Normal
Ileal Disease	Reduced	Reduced	Reduced	Reduced

- Malabsorption of vitamin B12 may occur as a consequence of:

- Deficiency of intrinsic factor (eg, pernicious anemia (improved with intrinsic factor), gastric resection).
- Pancreatic insufficiency (improved with pancreatic enzyme).
- Bacterial overgrowth (improved with antibiotic).
- Ileal resection or disease.



★ To distinguish between these causes of fat malabsorption, the **Schilling test** is performed on 4 stages. **Radiolabeled B₁₂ is given orally (given in every stage)**, in each stage you'll **add one** of the following and then measure B₁₂ from urine sample:

- **Stage I: + IM unlabeled vitamin B₁₂**. if B₁₂ levels are normal then the cause of its deficiency was **decreased intake**. If not do Stage II
 - **Stage II: + intrinsic factor (IF)** if B₁₂ is normal after supplement of IF then the cause was **lack of intrinsic factor (Eg, pernicious anemia)**. If not do Stage III
 - **Stage III: + oral antibiotics**. if B₁₂ is normal after antibiotics then the cause was **bacterial overgrowth**. If not do Stage IV
 - **Stage IV: + supplement of pancreatic enzymes**. if B₁₂ is normal after supplement of **pancreatic enzyme** (trypsin) then the cause was pancreatic insufficiency.
- If B₁₂ is not normal after all of these stages the cause of deficiency might be **ileal disease**.

Tropical Sprue

Introduction

- Is characterized by villous atrophy and crypt hyperplasia.
- Most **tropical regions** of Asia, Africa, the Middle East, the Caribbean and Central and South America:
 - It is an acquired defect – not present in newborns. Travelers from the industrialized world may develop it.

The cause is unknown, but seems to be due to continuous bacterial contamination of the upper small bowel and nutritional deficiency.

Present with:

- **Chronic diarrhea** often with **steatorrhea**, anorexia, abdominal cramps, bloating
- **B12 and folate deficiency. (Unlike SBBO)**
 - features of megaloblastic anaemia



Investigation:

- If suspicion is high ⇒ **jejunal aspirate and biopsy. GOLD STANDARD**



Management:

- **Tetracycline** for 3-6 months is the treatment of choice
- **Folate & B12 Supplement.**
- Severely ill patients require resuscitation with fluids and electrolytes for dehydration, and nutritional deficiencies should be corrected. Vitamin B12 (1000 µg) is also given to all acute cases.

Bile Acid-Induced Diarrhea

Obj.

Definition:

- Bile acids get synthesized in the liver and secreted into the bowel (95% get absorbed in the terminal ileum and only 5% go to the colon). If the small intestine is resected and bile is not absorbed, free bile acid is very irritant to the colon. Bile salts which overflow into the colon causes secretion of water and electrolytes → Diarrhea
- increased oxalate absorption → renal oxalate stones.

Etiology:

- Bile acid diarrhoea can occur idiopathically (type 1) or as a complication of small bowel resection, post cholecystectomy (type 2)

SxS:

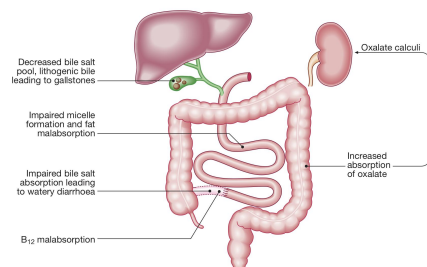
- Urgent **watery diarrhea** or mild steatorrhea

Diagnosis:

- Contrast studies and tests of B12 and bile acid absorption, such as the ⁷⁵Se-homocholelic acid taurine (SeHCAT) test
- An elevated serum 7α-hydroxycholestenone is a useful non-invasive marker of bile acid diarrhoea.

Treatment:

- **Bile acid sequestrants e.g. cholestyramine** (it binds to bile acids thus reducing its irritant effects).



Most common scenario is in patients with Crohn's disease who have undergone ileal resection.

Introduction

- Mainly in patients with chronic pancreatitis (most common cause is alcohol), Steatorrhea
- Improves with pancreatic enzymes replacement therapy (Protease and lipase supplements)
- Hx of abdominal pain, high alcohol intake for long time, diarrhea = pancreatic insufficiency.

Enzyme Secretion of Pancreas and Role in Digestion

Secretion	Site of Action	Active Enzyme	Substrate and Products
Pancreatic Juice	Duodenum	Pancreatic Amylase	Starch → Maltose
		Trypsin	Protein → Peptide
		Chymotrypsin	Protein → Peptide
		Pancreatic Lipase	Fats → Fatty Acids + Glycerol

Diseases & Mechanisms Associated With Exocrine Pancreatic Insufficiency

Disease or Condition	Pathological Mechanism
Chronic Pancreatitis , CF, Diabetes, Sequelae of Acute Necrotizing Pancreatitis, Hereditary Pancreatitis.	Loss of Pancreatic Parenchyma (Responsible for Most Cases of EPI).
Periampullary Tumors, IPMN, Pancreatic Head Carcinoma, Benign Pancreatic Tumors.	Obstruction of Main Pancreatic Duct.
Celiac Disease, Crohn's Disease, Schwachman-Diamond Syndrome.	Decreased Pancreatic Stimulation.
Zollinger-Ellison Syndrome.	Acid-mediated Inactivation of Pancreatic Enzymes.
Gastrectomy, Gastric Bypass, Extensive Small Bowel Surgery.	Gastrointestinal/Pancreatic Surgery.

	<ul style="list-style-type: none"> ● Chronic diarrhea (>4 weeks) can be osmotic, secretory, inflammatory or fatty diarrhea. ● Fecal osmotic gap is helpful to point toward osmotic diarrhea ● Iron, Ca & folate are absorbed in proximal bowel; <ul style="list-style-type: none"> ○ while B12 is absorbed in ileum.
<p>Celiac disease</p>	<ul style="list-style-type: none"> ● Should always be suspected in patients with iron-def anemia, diarrhea or dyspepsia. ● Anti-TTG is most helpful. ● Biopsy shows villus atrophy. ● Gluten-free diet. ● Watch for complications: nutritional & malignancy
<p>Whipple Disease</p>	<ul style="list-style-type: none"> ● Chronic systemic infection by Tropheryma whipplei. ● Has GI, CNS, CVS, MSK & skin manifestations ● Biopsy: Foamy macrophages & PAS-positive granular particles ● Tx Ceftriaxone 2g IV daily monotherapy THEN Septra (TMP/SMX) DS tab BID x 1 year. OR Pen G (2 MU IV q4h) PLUS streptomycin THEN Septra (TMP/SMX) DS tab BID x 1 year
<p>SBBO</p>	<ul style="list-style-type: none"> ● Look for & treat underlying causes ● B12 def ● Schilling's test
<p>Tropical Sprue</p>	<ul style="list-style-type: none"> ● Hx of travel to tropical area for long period
<p>Bile acid-induced diarrhea</p>	<ul style="list-style-type: none"> ● Watery diarrhea ● Improves with cholestyramine
<p>Exocrine pancreatic insufficiency</p>	<ul style="list-style-type: none"> ● Mainly in patients with chronic pancreatitis ● Steatorrhea ● Improves with pancreatic enzymes replacement therapy

Lecture Quiz

Q1: You see a 25-year-old woman who presents with a 24-hour history of watery diarrhoea. She states that she has opened her bowels 11 times since her onset of symptoms. Associated symptoms include nausea and vomiting with abdominal cramps and pain which started in the evening following a barbeque meal in the afternoon that day. The patient is alert and orientated and her observations include a pulse rate of 69, blood pressure of 124/75 and temperature of 37.1°C. On examination, her abdomen is soft, there is marked tenderness in the epigastric region and bowel sounds are hyperactive. The patient is normally fit and well with no past medical history. The most likely diagnosis is

- A. Irritable bowel syndrome
- B. Gastroenteritis
- C. Ulcerative colitis
- D. Laxative abuse

Q2: A 35-year-old woman presents with a 24-hour history of watery diarrhoea. She has opened her bowels nine times since the onset of her symptoms. You diagnose gastroenteritis after learning that the patient and her family all ate at a new restaurant and the rest of her family have had similar problems. The most appropriate management is:

- A. Oral rehydration advice, anti-emetics and discharge home
- B. Oral antibiotic therapy and discharge home
- C. Admission for intravenous fluid rehydration
- D. Admission for intravenous antibiotic therapy
- E. No treatment required

Q3: A 56-year-old man presents with a 2-week history of diarrhoea which has not settled following an episode of 'food poisoning'. Which of the following would be the most appropriate investigation?

- A. Full blood count
- B. Urea and electrolytes
- C. Stool sample for microscopy, culture and sensitivities
- D. Abdominal x-ray
- E. Liver function tests

Q4: A 2-year-old boy presents with a history of smelly, bulky diarrhea and poor weight gain. A small bowel biopsy shows villous atrophy. What is the most likely etiology?

- A. Bacillus cereus
- B. Campylobacter jejuni
- C. Carcinoid
- D. Celiac disease
- E. Clostridium difficile
- F. Crohn's disease

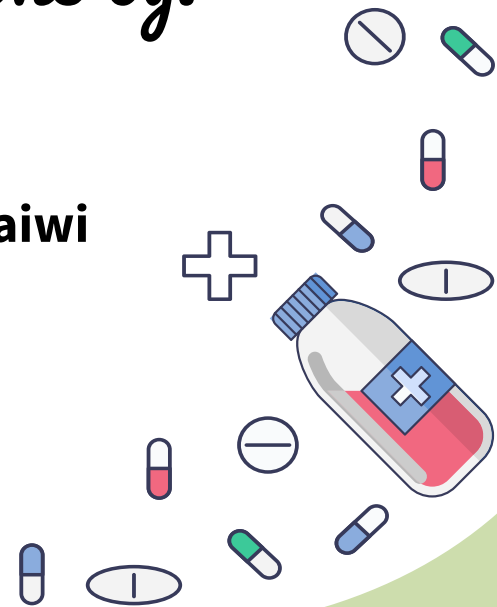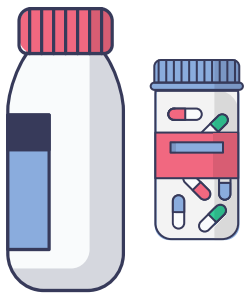Q5: A 62-year-old farmer presents for a second opinion after unrevealing extensive workup of migrating joint pain for the past 2 years and chronic diarrhea, postprandial abdominal cramping, and weight loss for the past 6 months. Your suspicion for Whipple disease is high. Which of the following statements regarding this disease is true?

- A. Chronic diarrhea is common, but extraintestinal symptoms are rare.
- B. Prolonged antibiotic treatment is required to eradicate the causative organism.
- C. The causative organism, Tropheryma whipplei, is easily cultured.
- D. The disease is more common in women than in men.
- E. Colonoscopy with biopsy is the diagnostic test of choice.

THANKS!!

This lecture was done by:

- **Jehad Alorainy**
- **Noura Alturki**
- **Abdulrahman Bedaiwi**



Females co-leaders:

Raghad ALKhashan
Amirah Aldakhilallah

Males co-leaders:

Mashal AbaAlkhail
Nawaf Albhijan

*Send us your feedback:
We are all ears!*

