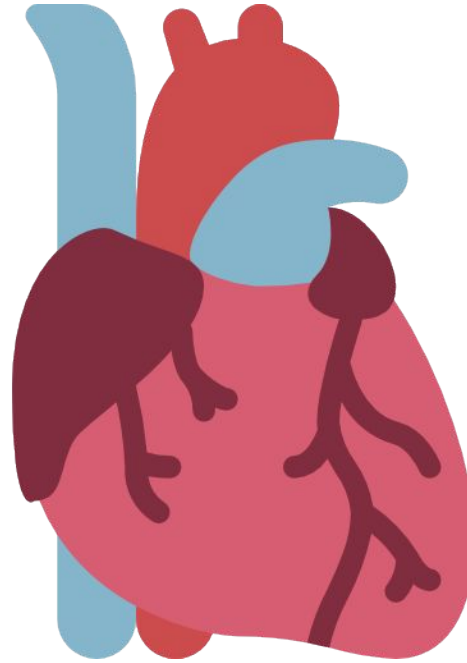


Lecture 3,4

Editing file



Rheumatic Heart Disease & Valvular Heart Diseases

Objectives:

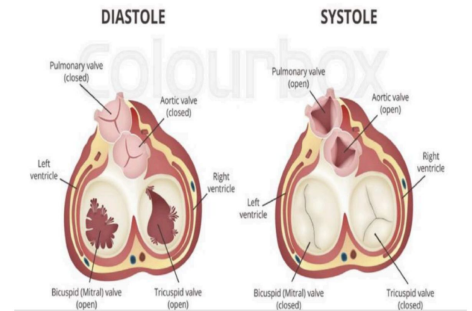
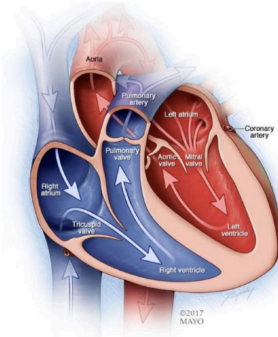
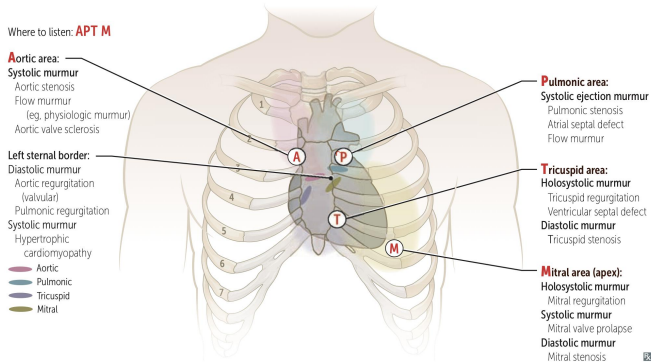
- ★ What is ARF And RHD? Diagnosis, Jones Criteria & 2015 revision, Differential Diagnosis, Investigations, Management, Prevention, Rheumatic Valvular Heart Disease
- ★ Describe the etiology, pathology, and natural history of valvular heart disease.
- ★ Describe the clinical symptoms and signs of valvular heart disease.
- ★ Explain the clinical examination findings of particular valvular problems.
- ★ Determine the role of echocardiograms in valvular heart disease, both in diagnosis and prognosis.
- ★ Discuss the long-term systemic consequences of valvular heart disease.
- ★ Describe the management and identify the indications of surgical intervention for particular valvular heart diseases.

Color index:

Original text Females slides Males slides
Doctor's notes Text book Important Golden notes Extra

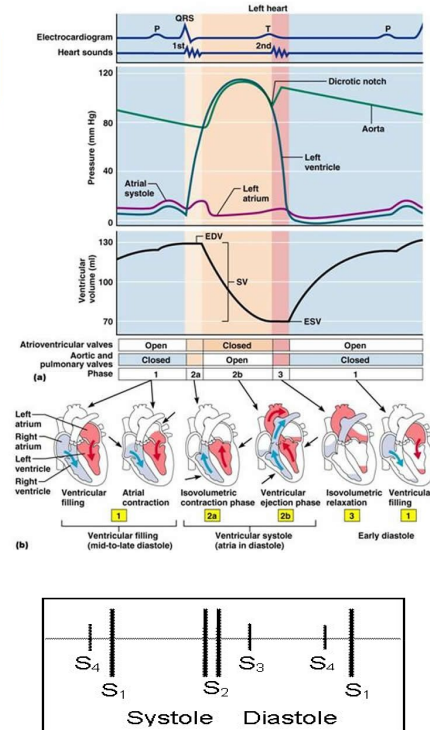
Characteristics of heart valves

Valve	Structure	Site of auscultation	Open in	Sound
Mitral valve	Bicuspid	Left 5th intercostal space at the midclavicular line (Apex)	Diastole	S1 (LUB)
Tricuspid valve	Tricuspid	Left 5th intercostal space at the sternal border		
Aortic valve	Semilunar	Right 2nd intercostal space at the sternal border	Systole	S2 (DUB)
Pulmonary valve	Semilunar	Left 2nd intercostal space at the sternal border		



Heart sounds

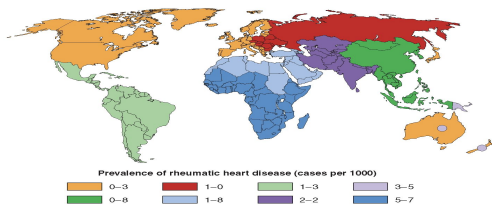
16.8 Normal and abnormal heart sounds				
Sound	Timing	Characteristics	Mechanisms	Variable features
First heart sound (S1)	Onset of systole	Usually single or narrowly split	Closure of mitral and tricuspid valves	Loud: hyperdynamic circulation (anaemia, pregnancy, thyrotoxicosis); mitral stenosis Soft: heart failure; mitral regurgitation
Second heart sound (S2)	End of systole	Split on inspiration Single on expiration (p. 447)	Closure of aortic and pulmonary valve A ₂ first P ₂ second	Fixed wide splitting with atrial septal defect Wide but variable splitting with delayed right heart emptying (right bundle branch block) Reversed splitting due to delayed left heart emptying (left bundle branch block)
Third heart sound (S3)	Early in diastole, just after S2	Low pitch, often heard as 'gallop'	From ventricular wall due to abrupt cessation of rapid filling	Physiological: young people, pregnancy Pathological: heart failure, mitral regurgitation
Fourth heart sound (S4)	End of diastole, just before S1	Low pitch	Ventricular origin (stiff ventricle and augmented atrial contraction) related to atrial filling	Absent in atrial fibrillation A feature of severe left ventricular hypertrophy
Systolic clicks	Early or mid-systole	Brief, high-intensity sound	Valvular aortic stenosis Valvular pulmonary stenosis Floppy mitral valve Prosthetic heart sounds from opening and closing of normally functioning mechanical valves	Click may be lost when stenotic valve becomes thickened or calcified Prosthetic clicks lost when valve obstructed by thrombus or vegetations
Opening snap (OS)	Early in diastole	High pitch, brief duration	Opening of stenosed leaflets of mitral valve Prosthetic heart sounds	Moves closer to S2 as mitral stenosis becomes more severe. May be absent in calcific mitral stenosis



Introduction to RHD

Overview on RHD epidemiology

- The incidence of RF and the prevalence of RHD has declined substantially in Europe, North America and other developed nations. This decline has been attributed to improved hygiene, reduced household crowding, and improved medical care. Also due to an improve in socioeconomic status and the usage of antibiotics.
- The major burden is currently found in low and middle income countries (India,middle east), and in selected indigenous populations of certain developed countries (Australia and New Zealand).
- In underdeveloped countries RHD is the leading cause of CV death during the first five decades of life.
- **It is a disease of poverty and low socioeconomic status.**
- ARF incidence in Eastern province of SA was 22/100,000, age 5-14 years.
- A study from Western province showed a prevalence of RHD 2.4/1000, age 6-15 years.
- A large study showed an overall prevalence of ARF and RHD in SA 3.1/1000 , age 6-15



Global burden

Total RHD cases	Cases with CHF	Cases require valve surgery	Annual incidence of RF, nearly half develop carditis	Deaths from RHD
15.6 million	3 million	1 million	0.5 million	230,000/YR

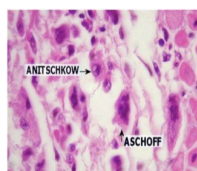
1- Acute Rheumatic Fever (ARF)

General characteristics

- Acute rheumatic fever (ARF) is a **sequela of streptococcal infection**—typically **following 2 to 4 weeks after group A streptococcal (strep. pyogenes) pharyngitis** and has rheumatologic, cardiac, and neurologic manifestations.
- Acute rheumatic fever **usually affects children (most commonly 5-15 years)** or young adults.
- The most common cause of acquired heart disease in childhood and adolescence.
- **Rheumatic Heart disease (RHD) is a possible long-term consequence of ARF.**

Pathophysiology

1. The condition is triggered by an **immune-mediated delayed response** to infection with specific strains of **group A (beta hemolytic) streptococci** → Development of antibodies against streptococcal **M protein** → Cross reaction of antibodies with cardiac myosin and sarcolemmal membrane protein due to **molecular mimicry**.
2. Antibodies produced against the streptococcal antigens cause inflammation in the endocardium¹, myocardium² and pericardium³, as well as the joints and skin, **but the major effect on health is due to damage to heart valves.**
3. **Histological findings: Aschoff bodies in myocardium composed of:**
 - a. Central area of fibrinoid necrosis surrounded by characteristic multinucleated giant cells, mononuclear cells (Anitschkow cells) and other inflammatory cells (plasma cells, and T lymphocytes) due to a type IV hypersensitivity reaction



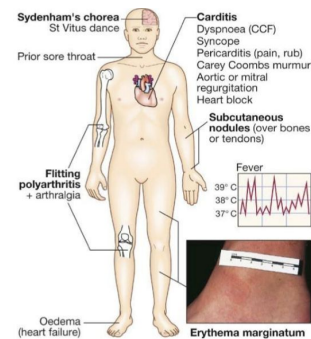
1- Endocarditis: Mitral valve is involved more commonly than the aortic valve. It's characterized by small vegetations along lines of closure that lead to regurgitation (While chronic RF will lead to stenosis because of fibrosis)

2- Myocarditis is the most common cause of death during the acute phase.

3- Pericarditis will lead to friction rub and chest pain.

◀ Clinical features

- Acute rheumatic fever is a **multisystem disease** that usually presents with fever, anorexia, lethargy and joint pain, **2-4 weeks after an episode of streptococcal pharyngitis**. There may be **no history** of sore throat.
- **Arthritis** occurs in approximately **75%** of patients. Other features include subcutaneous nodules, erythema marginatum, carditis and neurological changes.



◀ Diagnosis

- **Diagnosis is primarily clinical** and is based on a constellation of signs and symptoms, which were initially established as the **Jones criteria**. There's no single test to diagnose ARF.
- **Only about 25%** of patients will **have a positive culture** for group A streptococcus at the time of diagnosis because there is a latent period between infection and presentation.
- **Serological evidence of prior infection with GAS e.g.** Elevated ASO titer or Anti-DNAse B titer
- A presumptive diagnosis of acute rheumatic fever can be made without evidence of preceding streptococcal infection in cases of isolated chorea or pancarditis, if other causes for these have been excluded.
- The symptoms and signs are shared by many inflammatory and infectious diseases.
- **Accurate diagnosis is important, because:**
 - Overdiagnosis will result in individuals receiving treatment unnecessarily
 - Underdiagnosis may lead to further episodes of ARF causing damage, and the need for valve surgery, and or premature death

◀ Diagnostic criteria

- **A firm diagnosis requires: 2 Major manifestations OR 1 Major and 2 Minor manifestations along with Evidence of a recent streptococcal infection** (Elevated ASO titer or Anti-Dnase B titer and a positive throat culture)

◆ 1992 Modified Jones criteria



Major criteria ¹	Minor criteria
<ol style="list-style-type: none"> 1) Migratory polyarthritis (Joints) 2) ♥ Carditis 3) Subcutaneous Nodules. 4) Erythema Marginatum 5) Sydenham chorea 	<ol style="list-style-type: none"> 1) Arthralgia 2) First degree heart block (Prolonged PR interval) 3) Fever 4) Elevated inflammatory markers (ESR, CRP)

1- Discussed in details in page 6

◀ Diagnostic criteria cont.

◆ 2015 Revision of Jones criteria

1	<p>In accordance with the degree of prevalence of ARF/RHD in the population:</p> <p>A. Low risk populations have been defined as those with:</p> <ol style="list-style-type: none"> ARF incidence < 2:100000 school-age children or All age prevalence of RHD of < 1:1000 population per year <p>B. Children not from low risk population have been considered to be at moderate or high risk.</p>
2	<p>Advocated the use of Echocardiography in all cases of confirmed or suspected ARF or RHD, to diagnose valvulitis (subclinical carditis) and has been included as a major criterion to diagnose carditis.</p>
3	<p>Aseptic monoarthritis and Polyarthralgia has been included as a major criteria in moderate or high risk population.</p>
4	<p>Fever, ESR & CRP:</p> <p>A. low risk population: >38.5°C, ESR >60 and or CRP > 3mg/dl</p> <p>B. Moderate or high risk population: >38°C and ESR >30 and or CRP > 3mg/dl.</p>

◆ So, let's mix the modified and revised versions of Jones criteria

For all patient populations with evidence of preceding GAS infection:

- Diagnosis of **Initial** ARF: **2 Major OR 1 Major and 2 Minor**. (If it's the first time, 3 minor aren't enough)
- Diagnosis of **recurrent** ARF: **2 Major OR 1 Major and 2 Minor OR 3 Minor**.

Major criteria	
Low-risk populations	Moderate- and high-risk populations
<ol style="list-style-type: none"> 1) Carditis: <ol style="list-style-type: none"> a) Clinical and/or subclinical (by echo). 2) Arthritis: <ol style="list-style-type: none"> a) Polyarthritis only 3) Sydenham chorea 4) Erythema marginatum 5) Subcutaneous nodules 	<ol style="list-style-type: none"> 1) Carditis: <ol style="list-style-type: none"> a) Clinical and/or subclinical (by echo). 2) Arthritis: <ol style="list-style-type: none"> a) Polyarthritis or monoarthritis b) Polyarthralgia 3) Chorea 4) Erythema marginatum 5) Subcutaneous nodules
Minor Criteria	
Low-risk populations	Moderate- and high-risk populations
<ol style="list-style-type: none"> 1) Polyarthralgia 2) Fever (≥ 38.5°C) 3) ESR ≥ 60 mm in the first hour or CRP ≥ 3mg/dl 4) Prolonged PR interval, after accounting for age variability (Unless carditis is a major criterion)¹ 	<ol style="list-style-type: none"> 1) Monarthralgia 2) Fever (≥ 38°C) 3) ESR ≥ 30 mm in the first hour or CRP ≥ 3mg/dl 4) Prolonged PR interval, after accounting for age variability (Unless carditis is a major criterion)¹

¹ If carditis is present as a major manifestation, a prolonged P-R interval cannot be considered an additional minor manifestation.

◀ Diagnostic criteria cont.

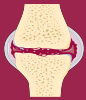◆ Jones major criteria explanation:

Carditis



- A '**pancarditis**', occurs in 50-70% of cases. Its incidence declines with increasing age.
- It may manifest as **breathlessness**, **palpitations** or **chest pain**
- Tachycardia is common; its absence makes the diagnosis of myocarditis unlikely.
- **The only manifestation of ARF that leaves serious permanent damage.**
- **Valvular lesions:**
 - **Mitral valve: (Most common to be involved)**
 - Early mitral regurgitation or prolapse while mitral stenosis in late stage
 - **Aortic valve:**
 - Early Aortic regurgitation while aortic stenosis in late stage
- A **soft Pansystolic murmur due to mitral regurgitation** is very common and/ or a **soft mid-diastolic murmur (the Carey Coombs murmur)** is typically due to valvulitis.
- May be **subclinical** (without murmurs or other S&S) so we should **use Echo**.
- Cardiomegaly and CHF may occur.

Arthritis



- This is the **most common major manifestation and occurs early** when streptococcal antibody titres are high, occurs in 35-66% of cases. Duration is short < 1 week.
- An acute **painful asymmetric and fleeting migratory inflammation of the large joints** typically affects the **knees, ankles, shoulders, elbows**. The joints are involved in quick succession and are usually **red and swollen**.
- **Rapid improvement with salicylates (aspirin)**. The pain characteristically responds to aspirin; if not, the diagnosis is in doubt.
- Does not progress to chronic disease.

Sydenham chorea

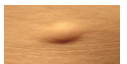


- Also known as **Saint Vitus's Dance**, occur in 10-30%, female predominance.
- This is a **late extrapyramidal neurological manifestation** that appears at least 3 months after the episode of acute rheumatic fever, when all the other signs may have disappeared.
- **Emotional lability may be the first feature** and is typically **followed by Abrupt purposeless, involuntary, Irregular, nonrepetitive choreiform movements 'Fidgety'** of the **hands, face, neck, trunk and limbs**.
- Clinically manifest as clumsiness, deterioration of handwriting, emotional lability or grimacing of face.
- Spontaneous recovery usually occurs within a few months. Approximately one-quarter of affected patients will go on to develop chronic rheumatic valve disease.

Subcutaneous nodules

(Associated with severe carditis)

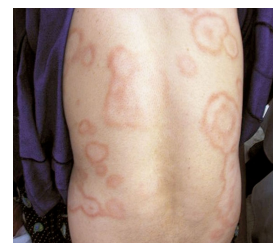- They are **small** (0.5–2.0 cm), **firm** and **painless** and are **best felt over extensor surfaces** of joints, bone prominences, tendons and spine. occurs in 10% of cases.
- Short lived (lasts for few days). They typically appear more than 3 weeks after the onset of other manifestations and therefore **help to confirm** rather than make the diagnosis.



Erythema marginatum

(Associated with carditis)

- Erythema marginatum occurs in less than **5-6%** of patients
- The lesions start as round or irregular red macules that fade in the centre (**pale center**) but remain **red at the edges** (wavy/serpiginous margin). The resulting red rings or 'margins' may coalesce or overlap.
- Location: Mainly on the trunk, abdomen and proximal extremities but the face spared.
- Less common, but **highly specific** manifestation of ARF.



◀ Differential diagnosis of ARF

Presentation		
Polyarthritis and fever	Carditis	Chorea
<ul style="list-style-type: none"> 1) Septic arthritis (Including disseminated gonococcal infection) 2) Connective tissue and other autoimmune disease 3) Viral arthropathy 4) Reactive arthropathy 5) Lyme disease 6) Sickle cell anemia 7) Infective endocarditis 8) Leukemia or lymphoma 9) Gout or pseudogout 	<ul style="list-style-type: none"> 1) Innocent murmur 2) Mitral valve prolapse 3) Congenital heart disease 4) Infective endocarditis 5) Hypertrophic cardiomyopathy 6) Myocarditis: Viral or idiopathic 7) Pericarditis: Viral or idiopathic 	<ul style="list-style-type: none"> 1) SLE 2) Drug intoxication 3) Wilson's disease 4) Tic disorder 5) Choreoathetoid cerebral palsy 6) Encephalitis 7) Familial chorea (Including Huntington's) 8) Intracranial tumor 9) Lyme disease 10) Hormonal

◀ Investigations

1. **Evidence of a systemic illness:**
 - a. **CBC: Leukocytosis**
 - b. **Raised erythrocyte sedimentation rate (ESR) and C-reactive protein (CRP).**
2. **Evidence of preceding streptococcal infection:**
 - a. **Throat swab culture (preferably before giving antibiotics)¹:** group A beta-hemolytic streptococci (also from family members and contacts)
 - b. **Anti-streptococcal serology:** (Repeat 10-14 days later if first test not confirmatory)
 - i. **Elevated Antistreptolysin O antibodies (ASO titres):** >200 U (adults) or >300 U (children)
 - ii. **Elevated Ant-DNAse B titer**
3. **Evidence of carditis:**
 - a. **Chest X-ray:** cardiomegaly; pulmonary congestion
 - b. **ECG:**
 - i. **First-degree AV block (Prolonged PR interval);** features of pericarditis; T-wave inversion; reduction in QRS voltages.
 - ii. Arrhythmias
 - iii. Repeat in 2 weeks and again in 2 months, if still abnormal.
 - c. **Echocardiography:** (If negative, consider repeating after 1 month)
 - i. Cardiac dilatation
 - ii. Mitral regurgitation with dilatation of the mitral annulus and prolapse of the anterior mitral leaflet; it may also demonstrate aortic regurgitation and pericardial effusion.

1- Throat cultures should be taken but positive results are obtained in only 10–25% of cases since the infection has often resolved by the time of presentation.

1- Acute Rheumatic Fever (ARF) cont.

Treatment

1

Bed Rest:

The duration should be guided by symptoms, along with temperature, leucocyte count and ESR, and should be continued until these have settled.

2

Salicylates:

Aspirin¹

60/75-100mg/kg/day as 4 divided doses for 6-8 weeks, until a blood level of 20-30mg/dl is attained. This usually **relieves** the symptoms of **arthritis** rapidly and a response within 24 hours helps confirm the diagnosis.

3

Antibiotics:

Like Procaine benzylpenicillin G² 4 million units/day x10 days. Should be given on diagnosis to **eradicate GAS from throat** infection.

4

Steroids

(Prednisolone):

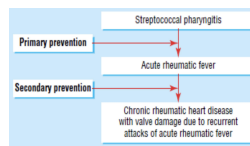
1-2 mg/kg/day taper over 6 weeks. **Produces more rapid symptomatic relief than aspirin and is indicated in cases with carditis or severe arthritis.**

Prednisolone should be continued until the ESR is normal and then tailed off.

5

Heart Failure Treatment :

Like diuretics and ACEI.



Prevention

1) Primary prevention:

- a) Prompt antibiotic treatment of GAS pharyngitis with **BPG 1.2M units IM**.

2) Secondary prevention:

- a) Antibiotics prophylaxis with **IM penicillin G benzathine 1.2MU** every 4 weeks or 3 weeks in high risk situations (alternatively 250mg **oral penicillin V**)
- b) **If the patient is penicillin allergic:** Oral **Sulfadiazine** (0.5g once daily for patients 27kg (60lb) OR 1g once daily for patients >27kg (60lb)
- c) **If the patient is penicillin and sulfadiazine allergic:** use oral **erythromycin** 250mg twice daily

■ Duration depend on the risk and severity of the original episode:

- Rheumatic fever without carditis:** 5 years **or** until patient reaches 21 years of age. (whichever is longer)
- Rheumatic fever with carditis:** 10 years **or** until patient reaches 21 years of age. (whichever is longer)
- Rheumatic fever with carditis and permanent valvular heart defects:** 10 years **or** until patient reaches 40³ years of age.(whichever is longer, sometime life long prophylaxis)



2- Chronic Rheumatic Heart disease

General characteristics

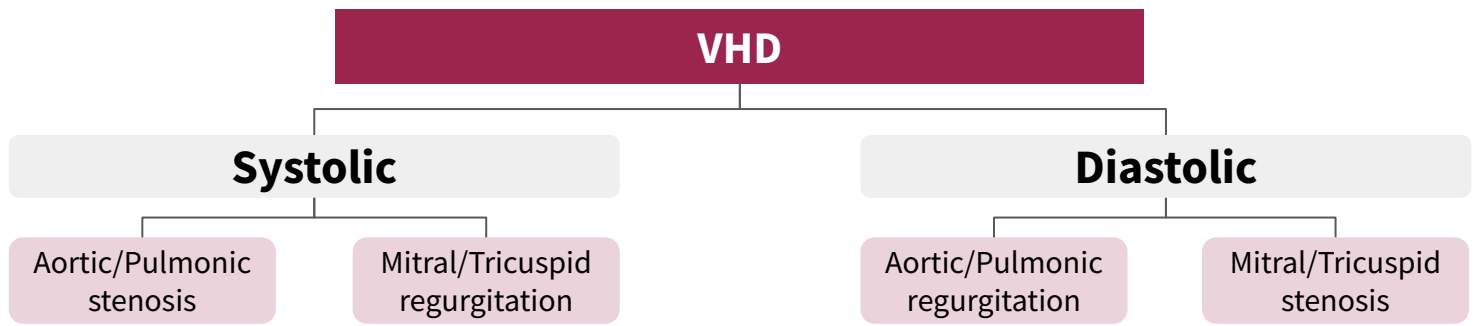
- **A sequela of ARF**, chronic valvular heart disease develops in at least half of those affected by rheumatic fever with carditis.
- A leading cause of CV morbidity & mortality in young people.
- **The mitral valve is affected in more than 70% of cases; the aortic valve is the next most frequently involved (40%) , followed by the tricuspid (10%) and then the pulmonary valve (2%).**
- Mitral Stenosis is more common in females (3:1), while males have higher incidence of Aortic Regurgitation.
- The main pathological process in chronic rheumatic heart disease is progressive fibrosis.
- Fusion of the mitral valve commissures and shortening of the chordae tendineae may lead to mitral stenosis with or without regurgitation. Similar changes in the aortic and tricuspid valves produce distortion and rigidity of the cusps, leading to stenosis and regurgitation.

1- Aspirin should be continued until the ESR has fallen and then gradually tailed off, If aspirin fails then use Glucocorticoids.

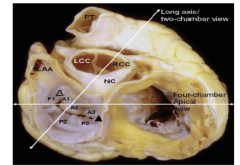
2- If the patient is penicillin-allergic, erythromycin or a cephalosporin can be used.

3- Why 40? Because throat infections after the age of 40 are rare, unless the person is working closely with kids then therapy should be continued

Valvular heart diseases (VHDs) Classification

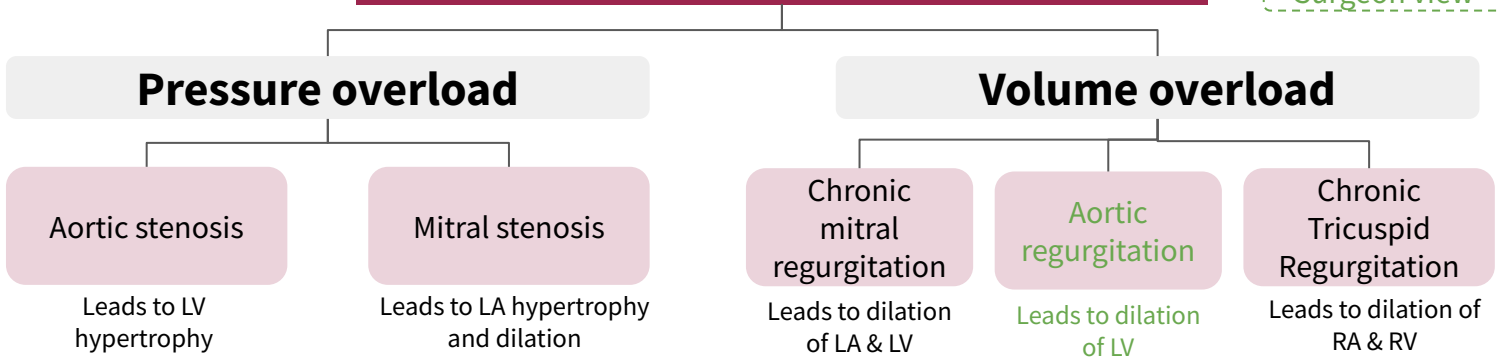


Hemodynamic consequences



Surgeon view¹

Hemodynamic consequences of VHD²



Investigations

- ECG³
- CXR
- ★ Echocardiogram: **(Best initial test for all VHDs)**
 - M mode, 2D, 3D, 4D, TEE, Doppler.
- 24hrs monitor for heart rhythm
- MRI
- Cardiac catheterization **(Most accurate)**
- Exercise test.

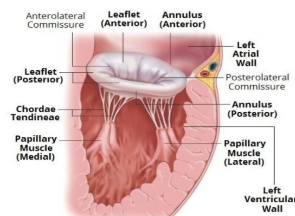
Stages of VHD

Stage	Definition	Description
A	At risk	<ul style="list-style-type: none"> Patients with risk factors for development of VHD.
B	Progressive	<ul style="list-style-type: none"> Patients with progressive VHD (Mild-Moderate) (Asymptomatic)
C	Asymptomatic severe	<ul style="list-style-type: none"> Asymptomatic but reached the criteria of severe VHD: <ul style="list-style-type: none"> C1: Asymptomatic with compensated cardiac function. C2: Asymptomatic but decompensated cardiac function.
D	Symptomatic severe	<ul style="list-style-type: none"> Developed symptoms secondary to VHD

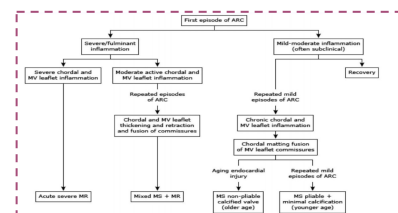
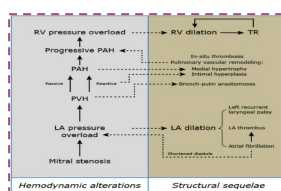
1- It is crucial that you know the anatomical relations of each valve
 2- Volume overload → LV dilation, Pressure overload → LV hypertrophy
 3- ECG define which chamber is enlarged. Eg: Lt. Axis deviation means LV is enlarged or hypertrophied or that there's a Left Bundle Branch Block (LBBB). Rt. Axis deviation means RV enlarged or hypertrophied or that there's a Right Bundle Branch Block (RBBB)

Definition

- It is the **restriction and narrowing** of the Mitral valve with impairment of left ventricular filling.
- Etiology:**
 - Almost always due to rheumatic heart disease.**
 - 25% alone, 40% with MR, 35% with AV, 6% with TV
 - Other causes include:** Bacterial Endocarditis, Congenital mitral stenosis (Shone syndrome), Systemic Lupus Erythematosus (with libman sacks endocarditis), Rheumatoid Arthritis, Atrial Myxoma³, Malignant carcinoid with lung metastasis or patent foramen ovale, Drug induced (Methysergide), Radiation induced, Calcific (Especially in old people), Fabry's disease, Whipple's disease, Mucopolysaccharidosis.



Pathophysiology



- In rheumatic mitral stenosis, the mitral valve orifice is slowly diminished by progressive **fibrosis**, **calcification** of the valve leaflets, and **fusion** of the cusps and subvalvular apparatus.
- The mitral valve orifice is normally about 5 cm² in diastole but can be reduced to <1 cm² in severe mitral stenosis. **The patient is usually asymptomatic until the orifice is < 2 cm².**

01

Increase in left atrial pressure (Hallmark of MS):

- A.** As stenosis progresses, left ventricular filling becomes more dependent on left atrial contraction. Mitral valve stenosis → increase in left atrial pressure¹ → backup of blood into lungs → increased pulmonary capillary pressure → cardiogenic **pulmonary edema** → pulmonary hypertension → backward heart failure, right ventricular hypertrophy and secondary tricuspid regurgitation (LV is protected)
- ★ **B.** **Atrial fibrillation²** is very common due to progressive **dilatation of the LA.**

02

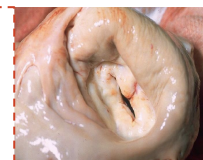Limited LV filling & Cardiac output

- A.** Mitral valve stenosis → obstruction of blood flow into the left ventricle (LV) → limited diastolic filling of the LV (↓ end-diastolic LV volume) → decreased stroke volume → decreased cardiac output

Integrity of the valve in mitral stenosis

- Cusps thicken**
- Calcium deposits form**
- Commissures fused together**
- Chordae tendineae becomes thickened and shortened**

Fish mouth appearance



1- Situations that demand an increase in cardiac output, such as pregnancy and exercise, also increase left atrial pressure and are poorly tolerated.

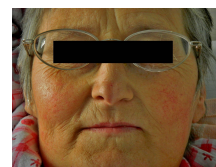2- Its onset often precipitates pulmonary oedema because the accompanying tachycardia and loss of atrial contraction (↓ Atrial kick) lead to marked haemodynamic deterioration (↓LV filling) and a rapid rise in left atrial pressure.

3- It's a benign tumor that arises from the atrial septum blocking the mitral valve

1- Mitral stenosis (cont.)

Signs & Symptoms

- It's a progressive lifelong disease.
- Slow and stable initially then progressive acceleration years later
- Long latent period post RF (Symptoms onset ~ 10 years after RHD)
- All signs and symptoms will increase with exercise and during pregnancy.



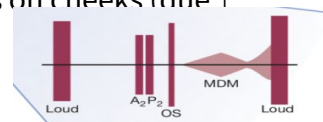
STENOSIS

Symptoms

- **Hallmark: Increased LA pressure** (Afib, Pulmonary hypertension)
- **Dyspnea on exertion³** and Poor exercise tolerance
- **Fatigue, syncope** (Due to ↓ cardiac output).
- **Oedema & Ascites:** Inability to tolerate the increased volume
- **Pulmonary edema:** develops when there's a sudden ↑ in flow rate across a markedly narrowed mitral orifice.
- **Orthopnea, PND and Palpitation** (Due to AF which is caused by LA Enlargement)
- **PHT symptoms:** Right HF, hemoptysis(10%) (Due to rupture of thin dilated bronchial veins)
- **Stroke or peripheral Embolism secondary to Atrial fibrillation (AF)**
- **Ortner's syndrome:** which is hoarseness due to left recurrent laryngeal nerve compression by the dilated LA.

Signs

- **Face (Cyanosis): Mitral facies** (Malar flush) pink purple plaques on cheeks (due ↑ Systemic vasoconstriction)
- **Pulse:** Regular (sinus), Irregularly irregular with AF, Low volume.
- ★ **JVP:** Prominent a wave in sinus rhythm (**Absent in AF**)
- **Heart sounds:**
 - **Loud S1¹** when leaflets are still pliable, can be palpable (**Tapping apex beat**).
 - **Loud P2** (due to pulmonary hypertension) which is followed by an opening snap
 - **Opening snap¹** of the mitral valve after a **Normal S2:** A high frequency, early diastolic sound that can mimic a split second heart sound. Caused by thickened valve leaflets as they open (Earlier OS indicates severe MS)²
- ★ **Murmur:** Low pitched **mid-diastolic rumble** at the apex with presystolic accentuation⁴. **The murmur is localised and does not radiate!**
- **S3 CANNOT BE HEARD IN MITRAL STENOSIS**
- **Right ventricular heave (lift)** "Parasternal heave" due to pulmonary hypertension
- **Signs of pulmonary hypertension.**



Complications

ABCD

Atrial fibrillation & **C**lots with systemic embolization

P(B)ulmonary hypertension & Lung congestion


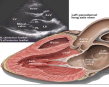
Congestive heart failure (CHF)

Dysphagia
(Due to compression of the esophagus by LA)

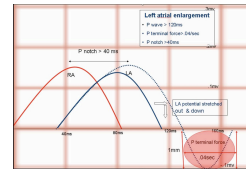
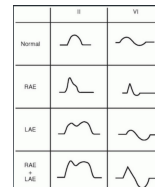
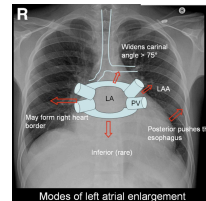
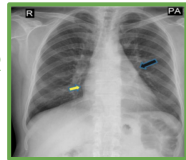
- 1- However, the first heart sound and opening snap may be inaudible if the valve is heavily calcified.
 - 2- What indicates severe MS? Presence of pulmonary HTN, Shorter interval between S2 and opening snap, Prolonged mid diastolic murmur.
 - 3- First bouts of dyspnea in patients with MS are usually precipitated by exercise, emotional stress, infection, or Atrial fibrillation all of which increase the rate of blood flow across the mitral orifice and result in further elevation of left atrial pressure → pulmonary venous congestion.
 - 4- Typically heard best at the 5th left intercostal space at the midclavicular line (the apex). Heard loudest with the bell of stethoscope when the patient is lying on his/her side (left lateral decubitus position). The murmur is accentuated by exercise and during atrial systole (pre-systolic accentuation). Since it's low pitched it increases with squatting/leg raising and decreases with standing/valsalva maneuver. If there was coexisting MR there will be a pansystolic murmur that radiates to axilla.
- **Orthopnea, SOB, PND:** backward pressure symptoms due to elevated pressure of the LA, PCWP, Pulmonary HTN

1- Mitral stenosis (cont.)

◀ Diagnosis

Investigation	Findings / notes
Clinical	<ul style="list-style-type: none"> Clinical evaluation of Mitral Stenosis begins with an in-depth history and physical exam. Bloods, FBCs, U&Es, Cholesterol, clotting, ECG exercise testing and echodoppler
ECG	<ul style="list-style-type: none"> Atrial fibrillation (AF), right atrial enlargement¹ (P pulmonale), signs of right ventricular hypertrophy (Sokolow-Lyon index). left atrial enlargement (P mitrale): Broad notched (bifid) p waves. 
Echo (Gold standard)	<ul style="list-style-type: none"> Thickened immobile cusps, decreased mitral valve area, enlarged left atrium, Reduced rate of diastolic filling of left ventricle. Hockey stick appearance: classic for MS 
Cardiac cath	<ul style="list-style-type: none"> Required if surgery or valvuloplasty is being considered, to screen for coexisting conditions such as CAD.
CXR	<ul style="list-style-type: none"> Left atrial enlargement (LAE): straightening of the left heart border & a double shadow Late in the course: Pulmonary congestion (Kerley B lines) and prominent PA, Calcified MV. Dorsal displacement of the esophagus (visible in barium swallow test)

We see **mitralization (ruler sign)**: Straightening of the left heart border as well as pushed "right atrial deviation" to the side on a CXR due to prominence of the left atrial appendage or the pulmonary outflow tract. A double shadow reflecting how big the atrium is.



◀ Management

- Patients with **mild symptoms can be treated medically** but intervention by balloon valvuloplasty, mitral valvotomy or mitral valve replacement should be considered if the patient remains symptomatic **despite medical treatment or if pulmonary hypertension develops.**

Treatment of symptomatic mitral stenosis

1- Medical therapy (Treat the symptoms)

- Treatment of HF: ONLY** Diuretics² and Na restriction
- AF control:** (More details in arrhythmias lecture)
 - ★ Digoxin (Digitalis), Beta & Ca channel blockers, Antiarrhythmic, Anticoagulation (Warfarin).
- Endocarditis prophylaxis:** to prevent endocarditis (No longer routinely recommended)

2- Surgical therapy (Treat the cause)

You choose according to the severity of the condition:³

- First line: Percutaneous mitral Balloon commissurotomy (PMBC) AKA. mitral valvuloplasty** if the following criteria are fulfilled:
 - Mobile, non calcified valve on echo
 - No LA thrombus
 - No or mild mitral regurgitation
- Alternatives: Open Commissurotomy³, Mitral Valve Replacement³**

1- Eventually because of Tricuspid regurgitation. Continuous wave (CW) Doppler can be used to estimate of pulmonary artery pressure through measurement of the degree of tricuspid regurgitation.

2- ACE inhibitors and other afterload-reducing drugs are contraindicated because they cause dilation of peripheral blood vessels, which may lead to cardiovascular decompensation! Also In pregnant women it is better to do PMBC because diuretics can cause intrauterine growth retardation.

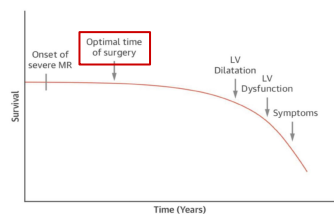
3- Asses severity by Doppler echocardiography: (Always check for LA thrombus with TEE prior to surgery)

- Good leaflet morphology, no calcification → **Valvuloplasty** (the Wilkins score can also be used to determine if the valve is suitable for PMBC.)
- Leaflet/chordal thickening, Mild valve calcification → **Open commissurotomy**
- Severely scarred leaflets, moderate - severe calcification (cannot be re-opened without producing significant regurgitation), presence of mitral regurgitation or LA thrombus despite anticoagulation → **Mitral valve replacement**

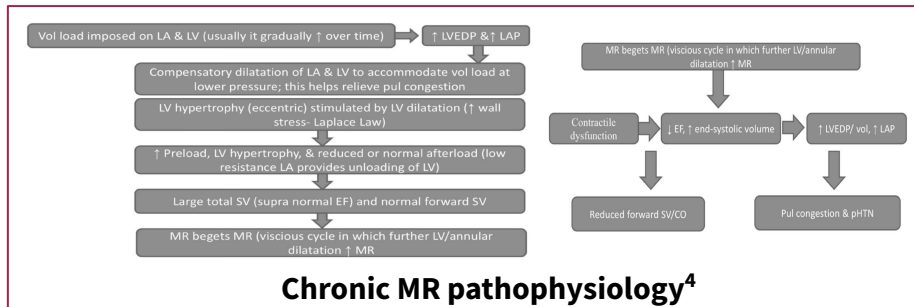
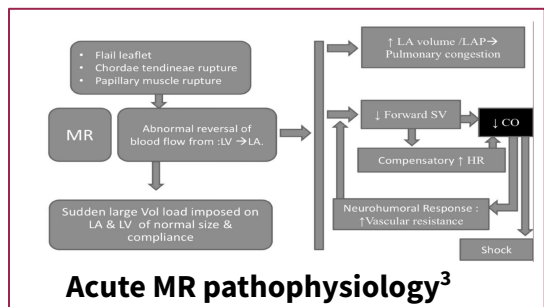
2- Mitral Regurgitation (MR)

Definition & Types

- ◆ Backflow of blood from the left ventricle into the left atrium, due to inadequate functioning (**insufficiency**) of the mitral valve.



	Acute MR	Chronic MR
Etiology	<ul style="list-style-type: none"> ● Infective Endocarditis ● Papillary muscle rupture (post MI, Myocarditis) ● Trauma ● Chordal rupture/leaflet flail (MVP, IE) 	<p>Primary (Organic)</p> <ul style="list-style-type: none"> ● Myxomatous (Mitral Valve Prolapse)¹ ★ Rheumatic heart disease ● Endocarditis (healed) ● Mitral annular calcifications ● Congenital (cleft, AV canal/HOCM with SAM) ● Radiation. SLE and Marfan's syndrome <p>Secondary (Functional)</p> <ul style="list-style-type: none"> ● Ischemic (LV remodeling) & Hypertensive heart disease ● Dilated cardiomyopathy <p>Note: The abnormal & dilated LV causes Papillary muscle displacement which in turn results in leaflet tethering with associated annular dilation that prevents coaptation.</p>
Symptoms	<ul style="list-style-type: none"> ● Decompensated HF symptoms: Dyspnea, orthopnea, PND ● Low cardiac output state ● Cardiogenic shock: due to the heart's inability to accommodate the fast changes 	<ul style="list-style-type: none"> ● Initially asymptomatic ● HF symptoms (Dyspnea, orthopnea, PND, LL edema) ● Decreased exercise tolerance ● Palpitation with AF if present ● PHTN symptoms if present
Signs	<ul style="list-style-type: none"> ● Large volume collapsing pulse and prominent V wave on JVP ● Tachycardia, Tachypnea, Hypotension. ● Soft & Short early systolic decrescendo murmur ● S4 heart sound 	<ul style="list-style-type: none"> ● Large volume collapsing pulse and prominent V wave on JVP ● Normal HR (Sinus AF may be present) ● Normal/High BP ● Laterally displaced (forceful) diffuse tapping apical impulse (PMI) +/- palpable systolic thrill ★ Normal/Soft (muffled) S1 heart sound "while in MS it is loud" ● S2 physiologic or wide split due to premature AV closure ● S3 in advanced stages of disease (Bc of the vibration of chordae tendineae) ● S4 may be heard in functional MR ★ High pitched holosystolic (pansystolic) murmur (Louder at the apex and radiates to left axilla)²



1- often associated with Marfan's syndrome which is an autosomal dominant connective tissue disorder that affects the microfibrils and elastin in connective tissue throughout the body. MFS is associated with disorders of the cardiovascular system (e.g., mitral valve prolapse, aortic aneurysm, and dissection), the musculoskeletal system (e.g., tall stature with disproportionately long extremities, joint hypermobility), and the eyes (e.g., subluxation of the lens of the eye).

★ 2- Louder with squatting or expiration (& that is a way to differentiate between MR and MVP since they have similar murmurs, but MVP gets better (fainter) with squatting and expiration) Heard loudest with the bell of stethoscope when the patient is lying on his/her side (left lateral decubitus position).

3- Acute mitral regurgitation causes a rapid rise in left atrial pressure (because left atrial compliance is normal) and marked symptomatic deterioration.

4- Chronic mitral regurgitation causes gradual dilatation of the LA with little increase in pressure and therefore relatively few symptoms. Nevertheless, the LV dilates slowly and the left ventricular diastolic and left atrial pressures gradually increase as a result of chronic volume overload of the LV

2- Mitral Regurgitation (cont.)

◀ Diagnosis

Investigation	Findings/notes
Clinical evaluation	Acute: ¹ sitting upright, you can hear rales (wet lungs) and the murmur can be subtle. Chronic: diffuse, tapping apical impulse. May have pulmonary findings. S3 +/- palpable.
ECG	<ul style="list-style-type: none"> • LA enlargement (bifid P wave), AF and PHT findings • LV hypertrophy
Echo (Gold standard)	<ul style="list-style-type: none"> • Dilated left atrium and left ventricle • Dynamic left ventricle (unless myocardial dysfunction predominates) • Structural abnormalities of mitral valve Note: Consider Cardiac MRI if the findings of both TTE and TEE are inconclusive.
Cardiac cath	<ul style="list-style-type: none"> • Helpful for confirmation and prior to surgical intervention. • Needed if the patient is old/ suspected ischemic MR.

Other tests: Bloods, FBCs, U&Es, Cholesterol, clotting and ECG exercise testing

◀ Management

- **Surgical/percutaneous intervention is the gold standard for management**

Type	Treatment
Acute MR	<p>Surgical (Repair, replace)²: All patients with acute MR should undergo surgery.</p> <p>Medical: Only temporarily while surgery is planned. The aim is to reduce symptoms:</p> <ul style="list-style-type: none"> • HF if present: Diuretics, Vasodilators e.g. Nitrates, ACEI. • Hypotension if present: Inotropes e.g. Dobutamine • AF if present: Digoxin and anticoagulants (Details in arrhythmias lecture)
Chronic MR	<p>Medical: Initiated in all patients to optimize cardiac function but surgery is the definitive Tx:</p> <ul style="list-style-type: none"> • Identify and treat the underlying cause • HF if present: Diuretics, BB, Vasodilators e.g. Nitrates, ACEI. • AF if present: Digoxin and anticoagulants (Details in arrhythmias lecture) <p>Surgical (Repair “MitralClip” or replace)²: When is it indicated?³</p>

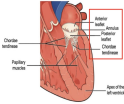
1- Check ECG and troponin in Acute MR to rule out MI.

2- Mitral valve **repair** is now the treatment of choice for severe mitral regurgitation, even in asymptomatic patients, because results are excellent and early repair prevents irreversible left ventricular damage, Do not wait for left ventricular end systolic diameter (LVESD) to become too large because the damage will be irreversible.

3- Surgery is **indicated** in patients with **symptomatic severe mitral regurgitation, left ventricular ejection fraction >30% and end-diastolic dimension of <55 mm**, and in **asymptomatic patients with left ventricular dysfunction (end-systolic dimension >45mm and/or ejection fraction of <60%)**. Surgery should also be considered in patients with **asymptomatic severe mitral regurgitation with preserved left ventricular function and atrial fibrillation and/or pulmonary hypertension**.

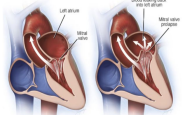
General characteristics

- Prolapsing (billowing) mitral valve. This is also known as Barlow syndrome or floppy mitral valve.
- It is due to excessively large mitral valve leaflets, an enlarged mitral annulus, abnormally long chordae or disordered papillary muscle contraction.
- **It's the most common cause of Mitral Regurgitation in developed countries¹.**
- **Etiology:**
 - Mostly idiopathic but it is associated with Connective tissue disorders (e.g. **Marfan's syndrome**, Ehlers-Danlos syndrome, Osteogenesis imperfecta), thyrotoxicosis, rheumatic or ischaemic heart disease and autosomal dominant PKD



Pathophysiology

- The most common underlying pathology in the case of mitral valve prolapse is **myxomatous degeneration** (deposition of glycosaminoglycan such as dermatan sulfate) of the mitral valve due to a primary disease or connective tissue disorder:
 - Long, floppy mitral valve leaflets with excessive valvular tissue → the mitral annulus becomes dilated and the chordae tendineae become elongated (and may rupture) → prolapse of one or both mitral valve leaflets into the left atrium during systole → Papillary muscle traction & Activation of stretch receptors → Papillary muscle and subendocardial ischemia → MR, Pain & Ventricular arrhythmias



Signs & Symptoms

- **Mitral valve prolapse associated with severe mitral regurgitation has a risk of sudden cardiac death.**

Symptoms

- ★ **Most patient are asymptomatic for their entire live.**
 - **Atypical chest pain** is the most common symptom if any were present.
 - **Palpitations** may be experienced because of the abnormal ventricular contraction or because of the **atrial and ventricular arrhythmias**
 - Sudden cardiac death due to fatal ventricular arrhythmias is a very rare but recognized complication.

Signs

- **Mitral valve prolapse click:** High frequency, **Mid-systolic click (most common sign)** Produced by the sudden prolapse of the valve and the tensing of the chordae tendineae that occurs during systole. best heard at the mitral region, *Increases with standing and valsalva maneuver but decreases with squatting*
- Followed by a Late systolic murmur that is best heard at mitral region and may radiate to axilla. (if associated with MR).
- **If present with severe MR:** S3 may be heard (especially in left decubitus position)

For the diagnosis: Echocardiography is the test of choice²

Treatment

No treatment is required in most cases. Just Beta blockers for the chest pain and palpitations

- **Surgery is rarely required, this condition is benign. When is surgery required?**
For patients with severe MR, mitral valve surgery (repair favoured over replacement) is indicated.
- **Treatment of complications if present:**
 - **Ventricular ectopics:** Avoid caffeine and give B-Blockers for symptoms relief
 - **IE:** MVP patient with past history of IE require IE prophylaxis
 - **Atrial fibrillation (AF):** Anticoagulation is advised to prevent thromboembolism.
 - **Transient ischemic attacks (TIA) and/or stroke:** Prophylactic aspirin

1- While 70% of patients with MVP have some form of mitral regurgitation, only 4% of patients with MVP have severe mitral regurgitation.

2- Echocardiographic definition of MVP: displacement of the mitral valve during systole by more than 2 mm above the mitral valve annulus in the parasternal long-axis view

Case study 1

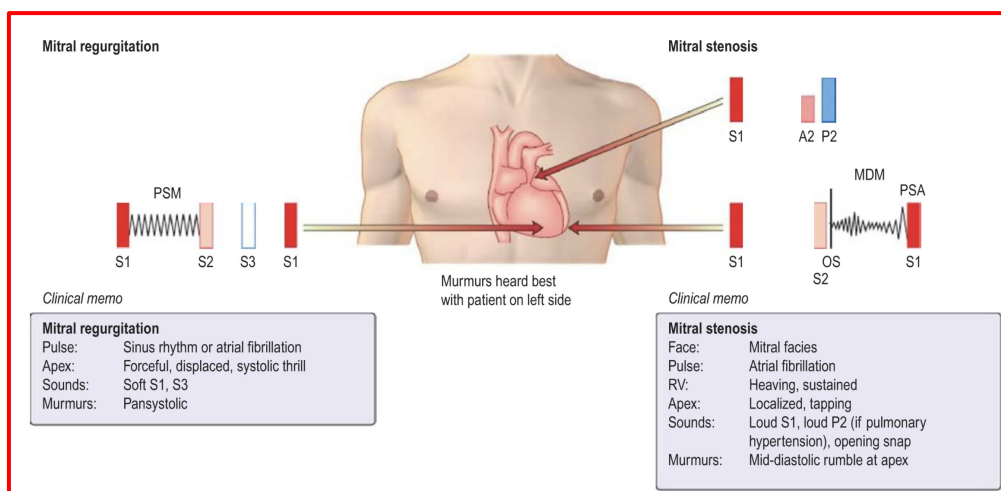
A 36-year-old woman who is 22 weeks pregnant presents with dyspnea and palpitations. Her dyspnea began at 16 weeks of pregnancy but has progressed to the point where she is dyspneic at rest. She sleeps upright in a chair. On examination, her heart rate is 108 beats per minute with an irregularly irregular rhythm. Her blood pressure is 90/64 mm Hg. The first heart sound is louder than the second heart sound at the base. There is a high-pitched, snapping, discrete, early diastolic sound that follows the second heart sound. There is a diastolic rumbling murmur heard over the apex with the patient positioned in the left lateral decubitus position. Pulmonary auscultation reveals bibasilar wet rales. The patient's jugular venous pressure is 16 cm H₂O.

- **What is the diagnosis?** Mitral stenosis
- **What's the best initial test for this case?** Echocardiography to confirm the diagnosis as well as to appropriately stage the disease (measuring ventricular diameter, flow velocities, extent of regurgitation, etc.).
- **Echocardiography was performed and it showed a mobile, non calcified valve with no LA thrombus. The patient was given medical treatment initially but symptoms didn't go, what's the best next step in managing this patient?** Percutaneous mitral Balloon commissurotomy (PMBC)
- **What findings will most likely present on ECG?** Biphasic p wave in V1 (sign of LA enlargement) and others mentioned previously

Case study 2

A 69-year-old woman with a history of hypertension and rheumatic heart disease in childhood presents to the clinic complaining of worsening shortness of breath with exertion, fatigue, and occasional palpitations. On physical examination, she appears in no acute distress, and her vital signs include a temperature of 37.0°C (98.6°F), blood pressure of 140/80 mm Hg, pulse rate of 80/min, respiratory rate of 12/min, and oxygen saturation of 99% on room air. Her physical examination is remarkable for mild crackles in both lung fields bilaterally, a laterally displaced point of maximum impulse, a diminished S₁, and a 3/6 holosystolic murmur heard best at the apex and radiating to the axilla. The murmur is reduced with Valsalva maneuver.

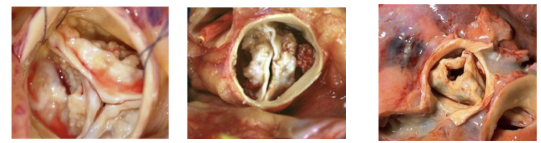
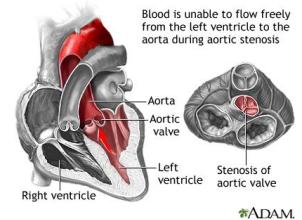
- **What is the diagnosis?** Mitral regurgitation
- **What medical management options exist?** Patients with symptoms of mitral regurgitation benefit from acute vasodilator therapy (which reduces preload on the left ventricle, thereby reducing the "stretching" pressure on the mitral valve orifice) or β -blockers, calcium channel blockers, hydralazine, or diuretics to reduce afterload and encourage forward flow. Additionally, patients with **rheumatic** MR and atrial fibrillation, or history of systemic embolization should receive anticoagulation. Patients with **nonrheumatic** MR should also receive anticoagulation, if they have atrial fibrillation or a history of embolization.
- **What surgical management options exist?** The surgical options in mitral regurgitation include mitral valve repair (also known as mitral valve annuloplasty) and mitral valve replacement. Repair has been shown to have better outcomes than replacement



4- Aortic stenosis (AS)

Definition

- It is a chronic progressive disease that produces obstruction to the left ventricular stroke volume leading to symptoms of chest pain, breathlessness, syncope and presyncope and fatigue.
- In contrast to patients with mitral stenosis, which tends to progress very slowly, patients with aortic stenosis typically remain asymptomatic for many years but deteriorate rapidly when symptoms develop; if otherwise untreated, they usually die within 3–5 years of presentation.
- **Differential diagnosis:** AS should be distinguished from these
 - Supravalvular obstruction (Murmur R carotid, $\uparrow A_2$)¹
 - Subvalvular stenosis (Often leads to AR)²
 - Hypertrophic cardiomyopathy (HCM)³

Degenerative⁴Bicuspid⁵RHD⁶

Etiology

Age Sx appear	Etiology
★ >65 years old	Calcification and degeneration of a normal valve (Most common cause 80%). Risk factors: old age, male gender, elevated lipoprotein(a) and LDL, hypertension, diabetes and smoking.
< 65 years old	Congenital Bicuspid Aortic valve * (Most common in young)
30-60 years old	Rheumatic heart disease Note: Key feature here is that the mitral valve will be affected not only aortic

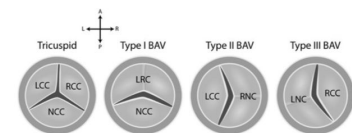
Other causes: CTD e.g. Rheumatoid

*Bicuspid Aortic Valve (BAV):

- Most common congenital abnormality of the heart with **males** being affected more than females.
- 70-80% of cases are due to fusion of the right & left coronary and non-coronary leaflets while 20-30% of cases are due to fusion of the right & non-coronary leaflets

Note: Fusion of the non coronary & left coronary leaflets is rare.

- Associated aortopathy (Medial degeneration) : aneurysm, dissection, **coarctation and root dilation**. So, they should have regular follow-up echo.
- Requires annual imaging if aorta > 4.5cm
- Beta blockers in absence of significant AI
- **Ask a replacement if:**
 - Aorta >5.5cm
 - Aorta >5cm with risk factors for dissection (e.g. FHx or progression of 0.5cm/y)
 - Aorta >4.5cm If AVR is indicated



1- A congenital fibrous diaphragm above the aortic valve, often associated with mental retardation and hypercalcaemia (Williams syndrome)

2- A congenital condition in which a fibrous ridge or diaphragm is situated immediately below the aortic valve.

3- how to differentiate? Murmur in HCM gets better (fainter) with squatting/expiration, but worse with AS.

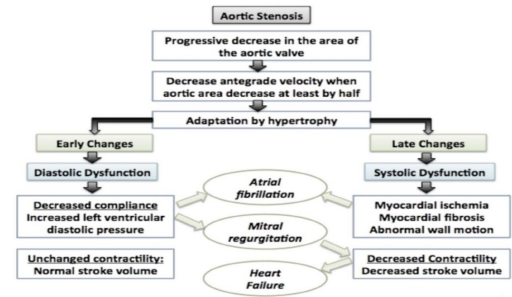
4- the leaflets themselves are thickened, with inflammatory degenerative changes and heavy calcification.

5- fusion between two cusps making only two cusps seen, calcification and degenerative changes.

6- Classical appearance in rheumatic: commissures got fused, one whole valve with no clear leaflet demarcations

Pathophysiology

- ◆ Obstructed left ventricular emptying → ↑ left ventricular pressure (pressure overload) → compensatory left ventricular **concentric** hypertrophy (reduce wall stress, reduce ventricular Compliance, ↑ LVEDp & ↑ LAp, **Cardiac output is reduced¹**)
- ◆ Forceful atrial contraction augments filling at the thick, non compliant ventricle and generates a prominent S4 gallop that elevates the left ventricular end-diastolic pressure.

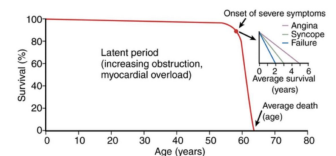


Signs & Symptoms

- Aortic stenosis is commonly picked up in asymptomatic patients at routine clinical examination.
- Symptoms typically present on exertion, unless AS is severe (when valve area is < 1cm²)
- When symptoms develop the prognosis is poor

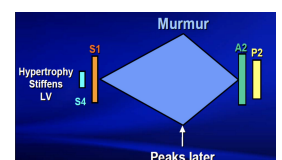
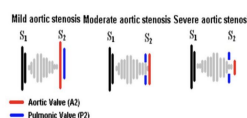
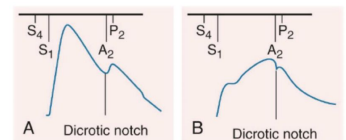
Symptoms

- **Classical triad (SAD): Syncope (exertional), Angina, Dyspnea**
- **Angina** (most common) → imbalance between supply & demand → 5 yrs survival.
 - ↑ LVEDp → leads to ↓ coronary perfusion.
 - Myocardial hypertrophy → ↑ O₂ demand.
- **Syncope** with exertion → 3 yr survival
- **Dyspnea**
- ★ **Congestive heart failure (CHF)** → 2 yrs survival (the **worst**).



Signs

- **Pulses:**
 - ★ **Pulsus Parvus et Tardus:** Low volume, slow rising, delayed upstroke carotid pulse
 - Narrow pulse pressure
 - Brachioradial delay.
- **Apex:** Sustained Bifid LV impulse (from LVH). (Not displaced PMI)
- ★ **Presence of a palpable systolic thrill at the base of the heart**
- **Auscultation:**
 - ★ **Harsh Crescendo-decrescendo (Diamond shape)^{2,3}, mid-to-late systolic ejection** murmur that **radiates bilaterally to the carotids**. (best heard in the aortic area)
 - **Gallavardin phenomenon:** High-pitched musical components of the murmur of aortic stenosis heard at the apex
 - ★ **Soft S2 (When AV is immobile), reversed splitting (Splitting of S2 on expiration), single S2 (soft or absent A2)**
 - **Prominent S4 gallop** (Caused by atrial contraction) → it is heard unless co-existing mitral stenosis prevent this. (Best heard at the apex)
 - Early systolic ejection click (due to abrupt stop of the leaflets upon opening) → It is heard unless the valve has become immobile and calcified



1-Initially CO is maintained but later the decreased distensibility of the LV reduces CO → Backflow into pulmonary veins → pulmonary venous congestion → Higher afterload (pulmonic pressure) on the right heart → Right HF → CHF

2- The murmur is often likened to a saw cutting wood and may (especially in older patients) have a musical quality like the 'mew' of a seagull.

★ 3- If the murmur's peak (The top of the diamond) is late → means severe disease. When early it is mild disease

Investigations¹

Test	Findings/notes
ECG	<ul style="list-style-type: none"> • Signs of LVH: Deep S-waves in V1 and V2, Tall R-waves in V5 and V6 and Down-sloping ST segments and T inversion (“strain pattern”) • Normal axis or LAD • Signs of left atrial enlargement: Bifid & wide p wave • ECG exercise stress testing: May be used in asymptomatic patients. A positive test may be indicated by the onset of symptoms, ECG changes, or an abnormal BP response. <p>Note: Nonspecific for AS (helpful but not diagnostic, so absent LVH doesn’t rule out AS!)</p>
CXR	<ul style="list-style-type: none"> • Typically demonstrates a small heart; cardiomegaly occurs if heart failure develops. • Dilated ascending aorta. • LV enlargement, rounded heart apex and calcification of Aortic valves
Echo (Gold standard)	<ul style="list-style-type: none"> • Allow assessment the valve area, ejection fraction and ventricular hypertrophy. • Calcification and narrowing of the aortic valve • Concentric hypertrophy and increased mean pressure gradient across the aortic valve.
Cardiac cath	<ul style="list-style-type: none"> • Most accurate test, used when echo is inconclusive • Mainly to identify associated CAD

Other tests: CBC, U&Es, lipids, coagulation profile and cardiac MRI

Management

Symptoms are a good index of severity

Symptomatic

Asymptomatic

1. **Surgical therapy** (Treat the cause):
 - a. **Aortic valve replacement (AVR)²** is the **only truly effective therapy for AS**, either with Bioprosthetic or Mechanical³ AVR. **2 possible approaches:**
 - i. **Surgical AVR:** Pts with low surgical risk
 - ii. **Transcatheter AVR (Transfemoral, Transapical):** Pts with high surgical risk or contraindication
2. **Medical therapy** (Treat symptoms)
 - a. Anticoagulants are required only in patients who have AF or those who have had a valve replacement with a mechanical prosthesis.
 - b. **Hypertension is common:** Cautious use of vasodilators due to afterload reduction

1. Under **regular review for assessment** of symptoms and echocardiography
2. Surgical intervention for asymptomatic people with severe aortic stenosis is recommended in those with:
 - a. symptoms during an exercise test or with a drop in blood pressure or an LVEF of <50%
 - b. Those undergoing cardiac surgery

1- cardiac MRI, cardiac catheterization and ECG exercise stress test are “special tests” only done when you are not sure about the symptoms of the patient (e.g.: the patient has other underlying conditions) or patients with severe AS, and only done under supervision.

2- Delay exposes the patient to the risk of sudden death or irreversible deterioration in ventricular function. Old age is not a contraindication to valve replacement and results are very good in experienced centres, even for those in their eighties. Without definite treatment (surgery), more than 50% of the symptomatic patients with severe aortic stenosis will die within the first 2 years of diagnosis!

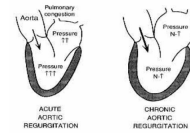
2- Which type of valve to use, mechanical or bioprosthetic? **Mechanical valves**, in general, result in better outcomes; they are preferred in patients with expected long life spans, those with a preexisting mechanical valve in a different location, those already requiring warfarin therapy due to thromboembolism risk factors, and those < 65 years old. A **bioprosthetic valve**, however, is preferred in patients who cannot or will not take warfarin and those > 65 years old who have no thromboembolic risk factors

Definition

- Aortic Regurgitation (AR) is the **leaking of the aortic valve** of the heart that causes blood to flow from Aorta to the LV during diastole.
- This condition can result from either disease of the aortic valve cusps, infection, trauma or dilatation of the aortic root².
- Usually presents 4th-6th decades of life with males affected 3 time more than females.

Etiology

Valvular (aortic valve cusps)	Non-valvular (aortic root)
Infectious: IE, RF	Marfan
Congenital: BAV, Marfan	syphilis
Inflammatory: SLE, RA, Behcet	Ankylosing spondylitis
Degenerative: Myxomatous AV, calcific AV	Idiopathic aortitis
Trauma	Ehler danlos syndrome
Postaortic valvuloplasty	Aortic dissection
Drug induced: Fenfluramine	Trauma
	VSD



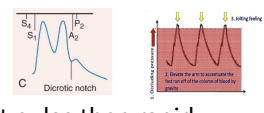
Acute vs Chronic AR/AI

	Acute AR	Chronic AR
General info	<ul style="list-style-type: none"> • A medical emergency • The compensatory changes seen in chronic disease do not have time to develop 	<ul style="list-style-type: none"> • Patients may remain asymptomatic for many decades • Develops slowly with compensatory changes
Consequences	<ul style="list-style-type: none"> • Reduced coronary flow - the coronaries fill predominantly during diastole, regurgitant flow at this time reduces filling. Results in angina or in severe cases myocardial ischaemia. • Increased EDP- causes increased pulmonary pressures with resulting pulmonary oedema and dyspnoea. In severe cases, cardiogenic shock may occur. 	<ul style="list-style-type: none"> • Increase in the left ventricular end-diastolic volume (essentially the preload). • Increased stroke volume compensating for regurgitant flow supported by the ventricular hypertrophy to maintain ejection fraction, with a greater preload leading to greater contractility (Frank-Starling law) • Eventually further increases in preload cannot be met by greater contractility and heart failure develops.
Causes	<p>Aortic root:</p> <ul style="list-style-type: none"> • Aortic dissection (ascending aorta) <p>Valvular (Aortic valve cusps):</p> <ul style="list-style-type: none"> • Infective endocarditis • Chest trauma → Rupture of leaflet • Failure of prosthetic heart valve • Acute RF <p>Others: Ruptured sinus valsalva aneurysm</p>	<p>Aortic root:</p> <ul style="list-style-type: none"> • Hypertension (severe) • Connective tissue disorders e.g. Marfan syndrome, Ehlers-Danlos syndrome, osteogenesis imperfecta • Idiopathic Aortitis <p>Valvular (Aortic valve cusps):</p> <ul style="list-style-type: none"> • Bicuspid aortic valve: Most common cause of AR in young adults and developed countries • Rheumatic heart disease: Most common cause of AR in developing countries • Calcific degeneration <p>Others: Tertiary syphilis, Arthritides (Reiter's syndrome, Ankylosing spondylitis and Rheumatoid arthritis)</p>
Symptoms	<ul style="list-style-type: none"> • Sudden, severe dyspnea • Chest pain • Symptoms of low CO & HF 	<ul style="list-style-type: none"> • Exertional dyspnea • Chest pain

1- Best heard to the left of the sternum during held expiration

2- usually in pt who had syphilis, aneurysm, atherosclerosis, aortic dissection, Marfan syndrome

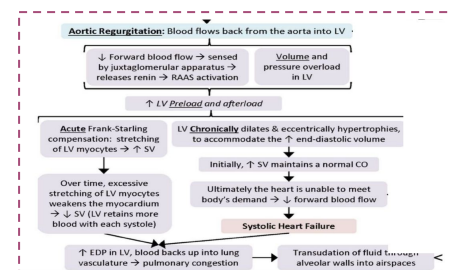
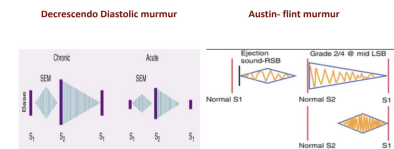	Acute AR	Chronic AR
Signs	<ul style="list-style-type: none"> ● Cardiogenic shock & Heart failure: Hypotension, tachycardia, elevated JVP...etc ● Peripheral signs of chronic AI are usually absent because the body did not have time to develop the compensatory changes seen in chronic AI ● S3+ Murmur is early, short, faint and may be absent <p>Note: The classical signs of aortic regurgitation in such patients may be masked by tachycardia and an abrupt rise in left ventricular end-diastolic pressure. The pulse pressure may also be normal or near-normal and the diastolic murmur may be short or even absent.</p>	<p>Murmurs:</p> <ul style="list-style-type: none"> ○ Diastolic decrescendo blowing murmur (most typical)¹ ○ Austin Flint Murmur²: soft Mid-diastolic murmur ● Point of maximal impulse (PMI): displaced inferolaterally ● Diffuse, and hyperdynamic LV ● BP: High (150/50) with widened pulse pressure ● Pulse: Pulsus bisferiens/collapsing/waterhammer pulse ● HS: Soft S1,2 (with S4, S3 Gallop in advanced AI) <p>Peripheral signs of AR³:</p> <ol style="list-style-type: none"> 1. De Musset's - systolic nodding of the head. 2. Quincke's - capillary pulsation of nail beds. 3. Corrigan's sign - abrupt distension with prominent pulse then rapid collapse. 4. Traube's (pistol shot femoral) - systolic & diastolic bruit in the femoral artery 5. Duroziez's - systolic bruit in the femoral artery with proximal compression and diastolic sound with distal compression using the stethoscope. 6. Müller's - systolic pulsation of uvula. 7. Hill's sign - SBP in legs > 20 mmHg higher than SBA in arms.



Pathophysiology

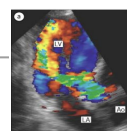
- ◆ **Widened pulse pressure** → ↑ systolic BP and ↓ Diastolic BP (collapsing pulse) Seen in hyperdynamic circulation (pregnancy, anemia, infection, thyrotoxicosis)
 - Stroke volume increased → (high Systolic BP)
 - Regurgitant volume increased → (Low Diastolic BP)
- ◆ **Imbalance between myocardial supply and demand:**
 - ↓ Diastolic BP → ↓ perfusion pressure → ↓ supply.
 - ↑ LV size (thus ↑ wall stress) → ↑ demand

Note: If mitral regurgitation ensues, left ventricular failure develops, leading to a rise in left ventricular end-diastolic pressure and pulmonary oedema.



Investigations

Test	Findings/notes
ECG	<ul style="list-style-type: none"> ● Left ventricular hypertrophy (deep S-waves in V1 and V2, tall R-waves in V5 and V6). ● Left ventricular strain may be seen in severe disease.
CXR	<ul style="list-style-type: none"> ● Cardiomegaly, calcifications, prominent aortic root/arch (Due to dilated aorta)
Echo (Gold standard)	<ul style="list-style-type: none"> ● Allows visualisation of the origin of regurgitant jet & its width. Assess LV size and function. ● Look for dilated aortic root and reversal of blood flow in aorta
Cardiac cath	<ul style="list-style-type: none"> ● Dilated LV and aortic root



Other tests: CBC, U&Es, lipids, coagulation profile, cardiac MRI and ECG stress test

1- AR due to valvular disease is best heard in the left third and fourth intercostal spaces and along the left sternal border (Erb point). Whereas AR due to aortic root disease (e.g., aortic dissection) is best heard along the right sternal border. In more severe stages, there might be a harsh, crescendo-decrescendo mid-systolic murmur that resembles the ejection murmur heard in aortic stenosis
 2- it resembles stenosis but it is NOT! (Because the 1st heart sound is normal), it is functional stenosis
 3- The relevance of these signs in clinical practice today is questionable. They are used less and less nowadays because patients are not left long enough before treatment to develop these signs

5- Aortic Regurgitation (cont.)

Management

Acute AR (Usually symptomatic)	<p>Surgical therapy:</p> <ul style="list-style-type: none"> Aortic valve replacement (AVR)¹ is indicated when symptoms develop <p>Medical therapy: Vasodilators and inotropes</p>
Chronic AR (Usually asymptomatic)	<p>Surgical therapy:</p> <ul style="list-style-type: none"> Aortic valve replacement (AVR) is indicated in <ul style="list-style-type: none"> Symptomatic patients with chronic severe AR In asymptomatic with LVEF ≤ 50% Asymptomatic with LVEF >50% but with a dilated LV (end-diastolic dimension >70mm or systolic dimension >50mm) In those undergoing CABG or surgery of the ascending aorta. If aortic root dilatation is the cause of aortic regurgitation, as can occur in Marfan’s syndrome, aortic root replacement is usually necessary. <p>Medical therapy:</p> <ul style="list-style-type: none"> Treat HTN: Vasodilators (Nifedipine, ACE-I) ACE inhibitors/ARBs are reasonable in patients with severe symptomatic AR and/or LV dysfunction when surgery is not performed because of comorbidities. SBE (Subacute bacterial endocarditis) Prophylaxis

6- Right sided VHDs²

Tricuspid valve (Same as mitral)	Pulmonary valve (Same as aortic)
Stenosis	Stenosis
<ul style="list-style-type: none"> Characterized by obstruction of blood flow from the right atrium into the right ventricle during diastole due to impaired opening of the valve. Extremely rare and is most commonly caused by infective endocarditis (especially in IV drug users), carcinoid tumors, or rheumatic fever. Murmur: Mid-Delayed diastolic rumbling murmur localised in the tricuspid area with a decrescendo. First heart sound is also loud Symptoms? like RHF: Increase JVP, Congested and pulsating liver & lower limb edema 	<ul style="list-style-type: none"> Characterized by obstruction of blood outflow from the right ventricle into the pulmonary arteries during systole. Usually congenital or RHD (rare), echo is used to confirm and assess the severity of the stenosis. Murmur: Crescendo-decrescendo ejection systolic murmur maximum at the pulmonary area that radiates to the back (to the lung not to the carotid as AS). Treatment: Transcatheter dilatation of the pulmonary valve by balloon pulmonary valvuloplasty or replacement by surgery Symptoms: Low CO
Regurgitation	Regurgitation
<ul style="list-style-type: none"> Characterized by retrograde blood flow from the right ventricle into the right atrium during systole due to insufficient closure of the valve. Extremely rare and can be caused by infective endocarditis (especially IV drug users), rheumatic fever, or right ventricular heart failure. Murmur: Soft Holosystolic murmur in the tricuspid area radiates to the apex (not axilla) 	<ul style="list-style-type: none"> Characterized by retrograde blood flow from the pulmonary artery into the right ventricle during diastole due to insufficient closure of the valve. Could be due to RHD Murmur³: Graham Steel murmur: high-frequency decrescendo diastolic murmur Symptoms: High CO Treatment: if severe → valve replacement

1- Both mechanical prostheses and tissue valves are used. Tissue valves are preferred in the elderly and when anticoagulants must be avoided, but are contraindicated in children and young adults because of the rapid calcification and degeneration of the valves.

2- All right-sided heart murmur increase in intensity and duration with inspiration (While all left-sided heart murmur increase with expiration). This is helpful to differentiate between Mitral vs Tricuspid OR Aortic vs Pulmonary

3- Early-diastolic murmur over the pulmonary area & the second heart sound will be less

Case study 1

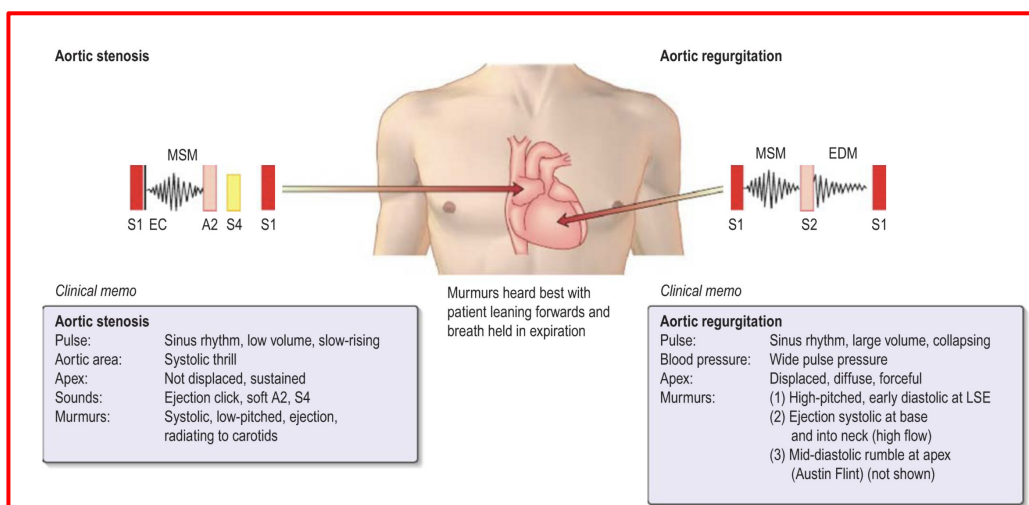
A 75-year-old man with a history of Marfan's syndrome presents to his physician complaining of a 6-month history of shortness of breath. He says his exercise tolerance has gradually decreased from 10 blocks on level ground to about 1 block and is limited by shortness of breath. He also reports shortness of breath at night, as well as generalized fatigue, occasional palpitations, and feeling like his heart is "pounding," especially when he lies on his left side. On physical examination, he appears in no acute distress and is a tall, thin man with a marfanoid body habitus. Vital signs include a temperature of 37.0° C (98.6°F), blood pressure of 160/50 mm Hg, pulse rate of 80/min, respiratory rate of 12/min, and oxygen saturation of 99% on room air. He has a laterally displaced point of maximum impulse; distant heart sounds; a high-pitched, blowing early diastolic murmur heard best at the left sternal border that is decreased by the Valsalva maneuver; clear lungs; and peripheral pulses with sharp upstrokes and downstrokes.

- **What is the diagnosis?** Aortic regurgitation
- **What's the best initial test for this case?** An echocardiogram is essential and will confirm the diagnosis by evaluating the degree of valvular dysfunction and myocardial compensation.
- **What are the next steps in management?** Initial management includes vasodilation, diuresis, and possibly digoxin, depending on systolic function. Once medical therapy is begun, workup for causes and assessment of need for valve surgery should be undertaken. In asymptomatic patients with severe AR who have left ventricular enlargement and normal LV systolic function, surgery may be forgone for vasodilator therapy, which reduces afterload and effectively shunts a greater proportion of the ejection fraction into the systemic circulation. In this patient with Marfan's syndrome, the most important determinant of the need for surgery is the diameter of the aortic root, as aortitis of any cause (syphilis, rheumatologic diseases) can dilate the aorta and cause aortic insufficiency.

Case study 2

A 72-year-old man with a history of peripheral vascular disease presents to the clinic complaining of having shortness of breath for the past month. He had previously been able to climb two flights of steps with little difficulty, but now cannot climb one flight without severe shortness of breath. On further questioning, he reports occasional chest pain on heavy exertion, and says 1 week earlier he fainted after climbing the stairs from his basement. He denies a history of heart or lung problems, high cholesterol, diabetes, smoking, or family history of heart or lung disease. On physical examination, he appears in no acute distress, and his vital signs include a temperature of 37.0° C (98.6° F), blood pressure of 140/80 mm Hg, pulse rate of 80/min, respiratory rate of 12/min, and oxygen saturation of 99% on room air. There is a slow rise of the carotid upstroke, a sustained apical impulse, and a quiet S2, as well as a 3/6 harsh systolic ejection murmur heard best at the second intercostal space at the right sternal border

- **What is the diagnosis?** Aortic stenosis
- **What's the best initial test for this case?** An echocardiogram is an essential diagnostic tool that can assess the degree of valvular stenosis and the peak and mean gradients across the valve, which can help calculate the valve area.
- **What are the next steps in management?** Aortic valve replacement



RHD

RF	Etiology	Occurs two to three weeks after an untreated infection with group A streptococcus (GAS).
	Pathology	Molecular mimicry between streptococcal M protein and human cardiac myosin proteins.
	S&S	Nonspecific symptoms (e.g., fever, malaise, and fatigue) and JONES
	Diagnosis	Primarily clinical, and is based on the Jones criteria. Diagnostic evaluation in acute rheumatic fever typically shows elevated inflammatory markers, positive antistreptococcal antibodies, and valvular damage on echocardiogram.
	Treatment	The first-line treatment is penicillin combined with symptomatic anti-inflammatory treatment, typically with salicylates or glucocorticoids (if salicylates are not effective).

VHDs

(Remember Echo is the gold standard test for all VHDs)

(Remember all murmurs get louder with squatting/leg raising and fainter with standing/valsalva except MVP and HOCM which get louder with standing/valsalva and fainter with squatting/leg raising)

MS	Etiology	Rheumatic fever
	S&S	STENOSIS
	Murmur	Opening snap and mid-diastolic murmur at the apex with loud S1
	Treatment	Antiarrhythmics (β -blockers, digoxin, or CCBs) and warfarin for AF. Mitral balloon valvotomy and valve replacement are effective for severe cases
MR	Etiology	Primarily 2° to rheumatic fever or chordae tendineae rupture after MI, Myxomatous degeneration due to mitral valve prolapse, Infective endocarditis]
	S&S	Patients present with dyspnea, orthopnea, PND, and fatigue
	Murmur	Acute MR: Soft & Short early systolic decrescendo murmur Chronic MR: High pitched holosystolic (pansystolic) murmur (radiates to left axilla)
	Treatment	Mitral valve repair or replacement is the definitive treatment
AS	Etiology	Most often seen in the elderly (senile calcific aortic stenosis).
	S&S	May be asymptomatic for years despite significant stenosis. Classical triad (SAD): Syncope (exertional), Angina, Dyspnea
	Murmur	Harsh crescendo-decrescendo systolic ejection murmur that radiates to carotid.
	Treatment	Aortic valve replacement (surgical or transcatheter methods)
AR	Etiology	Acute: Infective endocarditis, aortic dissection, chest trauma, MI Chronic: Valve malformations, rheumatic fever, connective tissue disorders (ie, Marfan syndrome), syphilis, inflammatory disorders
	S&S	Acute: Rapid onset of pulmonary congestion, cardiogenic shock, and severe dyspnea Chronic: Slowly progressive onset of dyspnea on exertion, orthopnea, and PND. Uncomfortable heart pounding when lying on left side
	Murmur	Early blowing decrescendo diastolic murmur at the left sternal border, mid-diastolic rumble (Austin Flint murmur)
	Treatment	Acute MR: AVR Chronic: Vasodilator therapy (e.g. ACEIs) until symptoms become severe enough to warrant valve replacement.

Lecture Quiz

Q1: A 32-year-old recent immigrant from Haiti presents for her first clinic evaluation. When she was 12 years old, she had rheumatic fever that was treated with antibiotics. She is asymptomatic. Her physical examination shows a heart rate of 70 beats per minute with a blood pressure of 122/77 mm Hg. She has no jugular venous distention. Her lungs are clear. She has a regular rate and rhythm with a loud S1 and physiologically split S2. A soft early diastolic rumble is heard at the apex with an opening snap after S2. There is wide separation between A2 and the opening snap. No peripheral edema is present. Which of the following is the most appropriate next recommendation for this patient?

- A- Start Anticoagulation
- B- Start oral penicillin V 250 mg twice daily
- C- Start diuretics
- D- Take abx for dental procedure

Q2: A 70-year-old male is seen in the office for chest pain. He reports that he is getting substernal chest pain, without radiation, when he mows his lawn. The pain resolves with 10–15 minutes of rest. He has never had pain at rest. He has no other cardiac complaints and his review of systems is otherwise negative. He has an unremarkable medical history and takes only a baby aspirin a day. On examination, his blood pressure is 160/70, pulse 85, and respiratory rate 16. His cardiac examination is notable for a harsh, 3/6 systolic ejection murmur along the sternal border that radiates to the carotid arteries. His carotid pulsation is noted to rise slowly and is small and sustained. His lungs are clear. The remainder of his examination is normal. Subsequent workup confirms the diagnosis of critical aortic stenosis. Which of the following treatments would be most appropriate at this time?

- A- Beta-blocker
- B- ACEI
- C- Aortic valve replacement
- D- Mitral valve replacement

Q3: A 48-year-old man presents to the ED with a 4-hour history of new-onset shortness of breath, difficulty breathing while supine, and nonproductive cough. Medical history reveals he had rheumatic fever as a child. Vital signs are within normal limits, and oxygen saturation is 97% on room air. On examination there is a low-pitched diastolic rumble as well as an opening snap, both best auscultated at the apex. Rales and musical rhonchi are auscultated on inspiration in both lung fields. ECG shows an irregularly irregular rhythm. Creatine kinase-myocardial band fraction, troponin T, and troponin I are negative 6 hours after the onset of symptoms. Testing reveals the thyroid-stimulating hormone level is normal. Which of the following is the most likely cause of the patient's pulmonary edema?

- A- Acute aortic stenosis
- B- Acute mitral regurgitation
- C- Mitral stenosis
- D- MI

Q4: A 32-year-old woman attends her GP for a routine medical examination and is noted to have a mid-diastolic murmur with an opening snap. Her blood pressure is 118/71 mmHg and the pulse is regular at 66 beats per minute. She is entirely asymptomatic and chest x-ray and ECG are normal. What would be the most appropriate investigation at this point?

- A- Anti-streptolysin O titre
- B- Blood culture
- C- Echocardiography
- D- Cardiac catheterization

Q5: A 76-year-old male is brought to accident and emergency after collapsing at home. He has recovered within minutes and is fully alert and orientated. He says this is the first such episode that he has experienced, but describes some increasing shortness of breath in the previous six months and brief periods of central chest pain, often at the same time. On examination, blood pressure is 115/88 mmHg and there are a few rales at both bases. On ECG there are borderline criteria for left ventricular hypertrophy. Which of the following might you expect to find on auscultation??

- A- Mid-diastolic murmur best heard at the apex
- B- Crescendo systolic murmur best heard at the right sternal edge
- C- Diastolic murmur best heard at the left sternal edge
- D- Pan-systolic murmur best heard at the apex

Q6: A 59-year-old man presents for a well person check. A cardiovascular, respiratory, gastrointestinal and neurological examination is performed. No significant findings are found, except during auscultation a mid systolic click followed by a late systolic murmur is heard at the apex. The patient denies any symptoms. The most likely diagnosis is:

- A- Austin flint murmur
- B- Graham steell murmur
- C- Barlow syndrome
- D- Carey coombs murmur

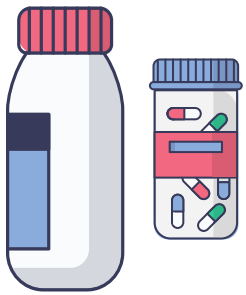THANKS!!

This lecture was done by:

Mashal AbaAlkhail

Note takers:

- Jehad AlOrainy
- Raghad ALKhashan



Females co-leaders:

Raghad ALKhashan
Amirah Aldakhilallah

Males co-leaders:

Mashal AbaAlkhail
Ibrahim ALAsous

*Send us your feedback:
We are all ears!*

