

Radiology of hepatobiliary diseases

Dr. Reshaid Aljurayyan

Assit. Professor Department of Radiology

Collage of Medicine

King Saud University

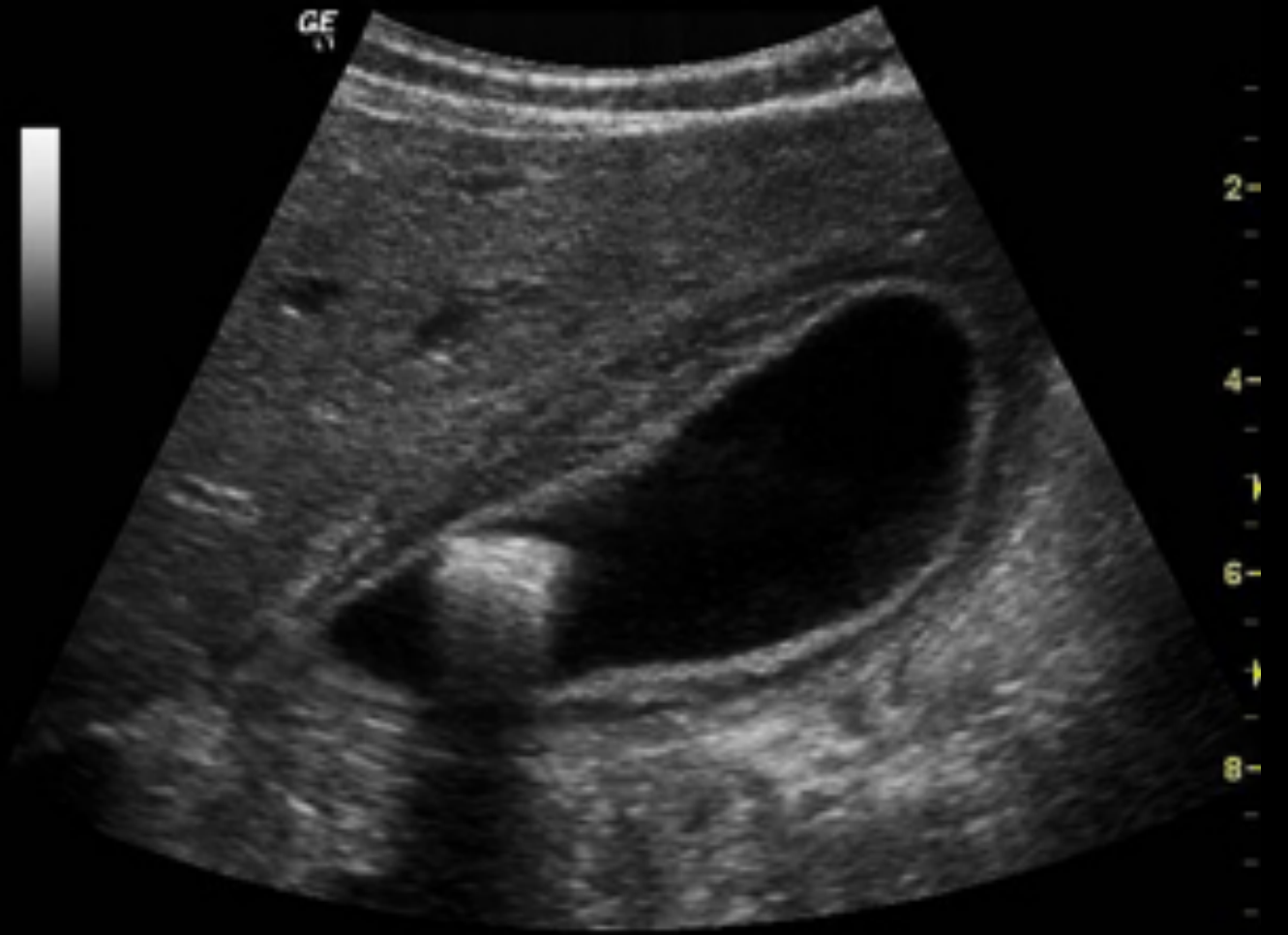Cases.....

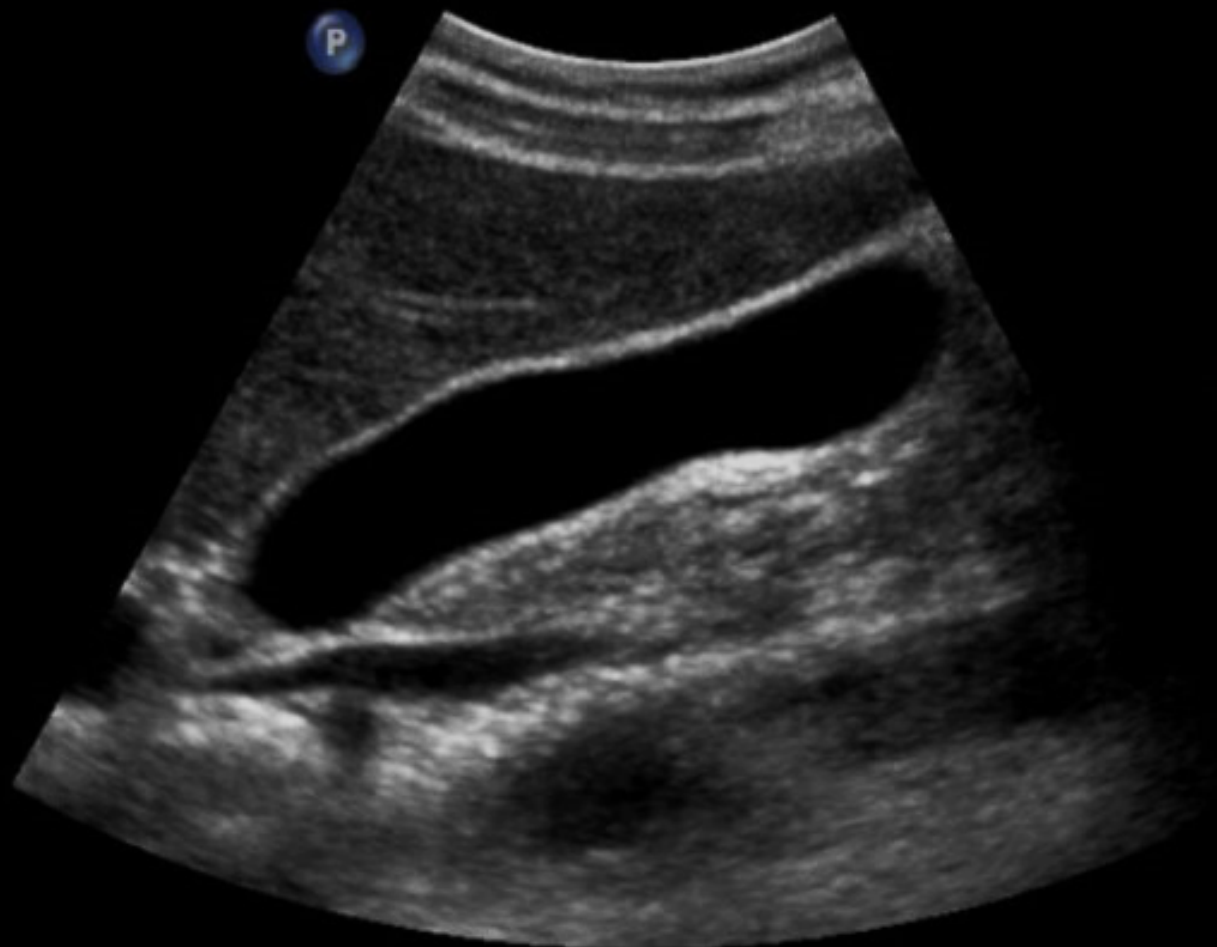Case 1

45 year-old female with RUQ pain radiating to right shoulder and aggravated by fatty meals associated with vomiting.

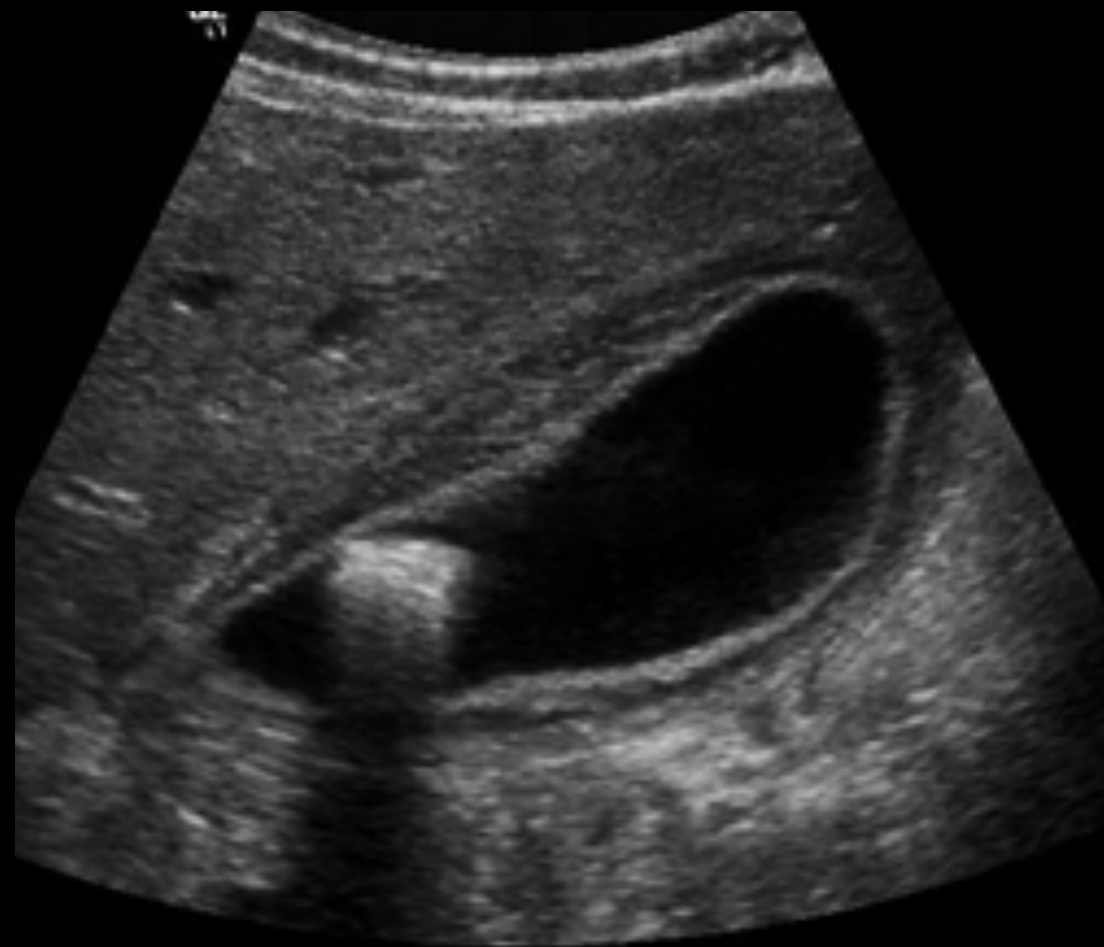- What is most likely diagnosis?
- What is the best radiology modality to start with?

**What is
abnormal?**

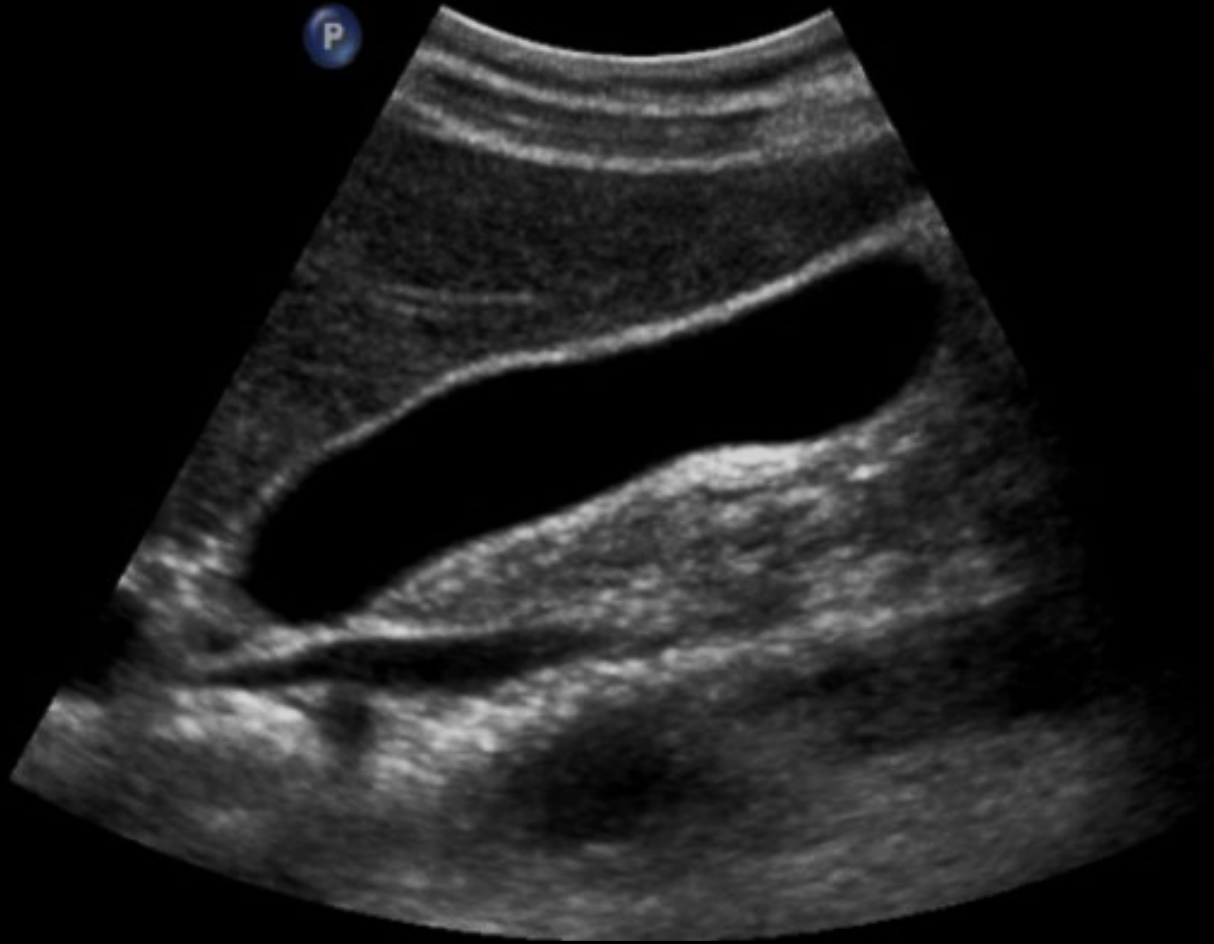



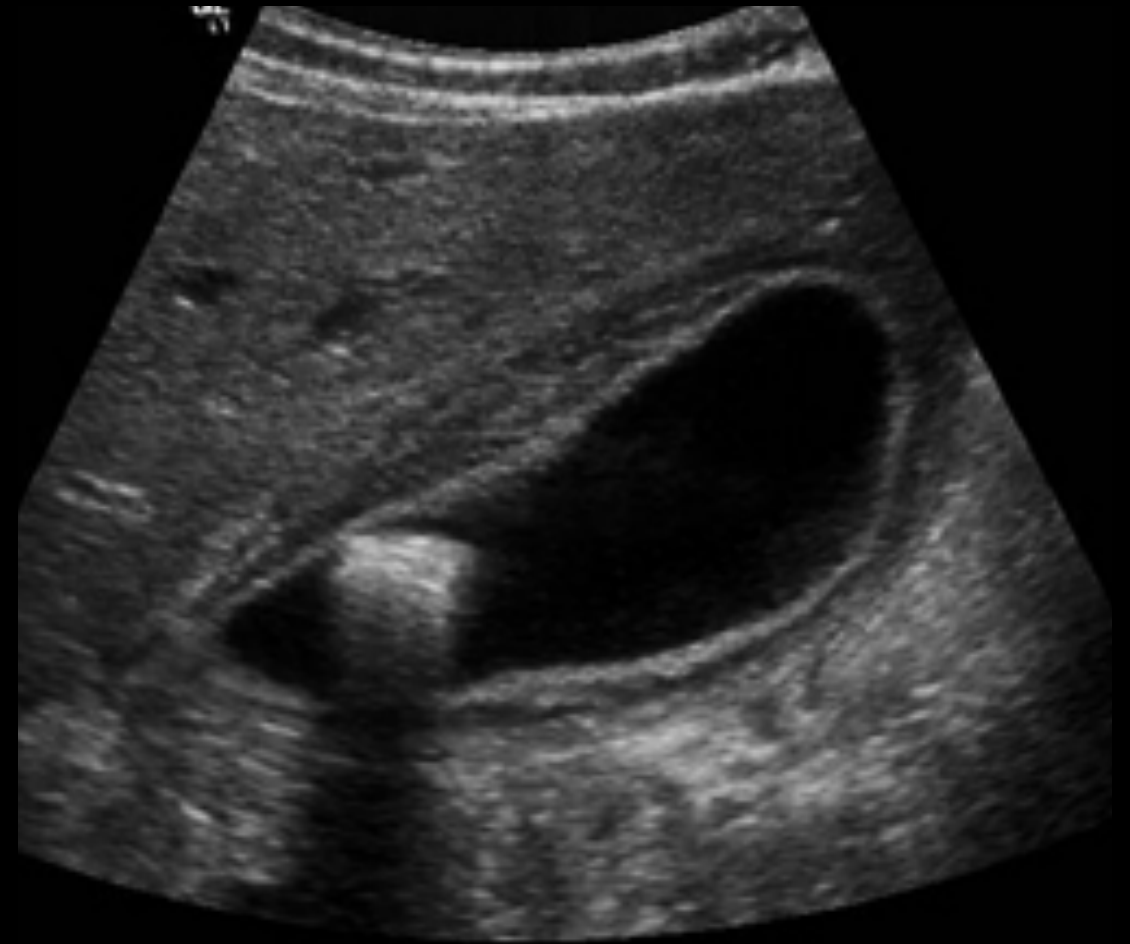Normal



Abnormal



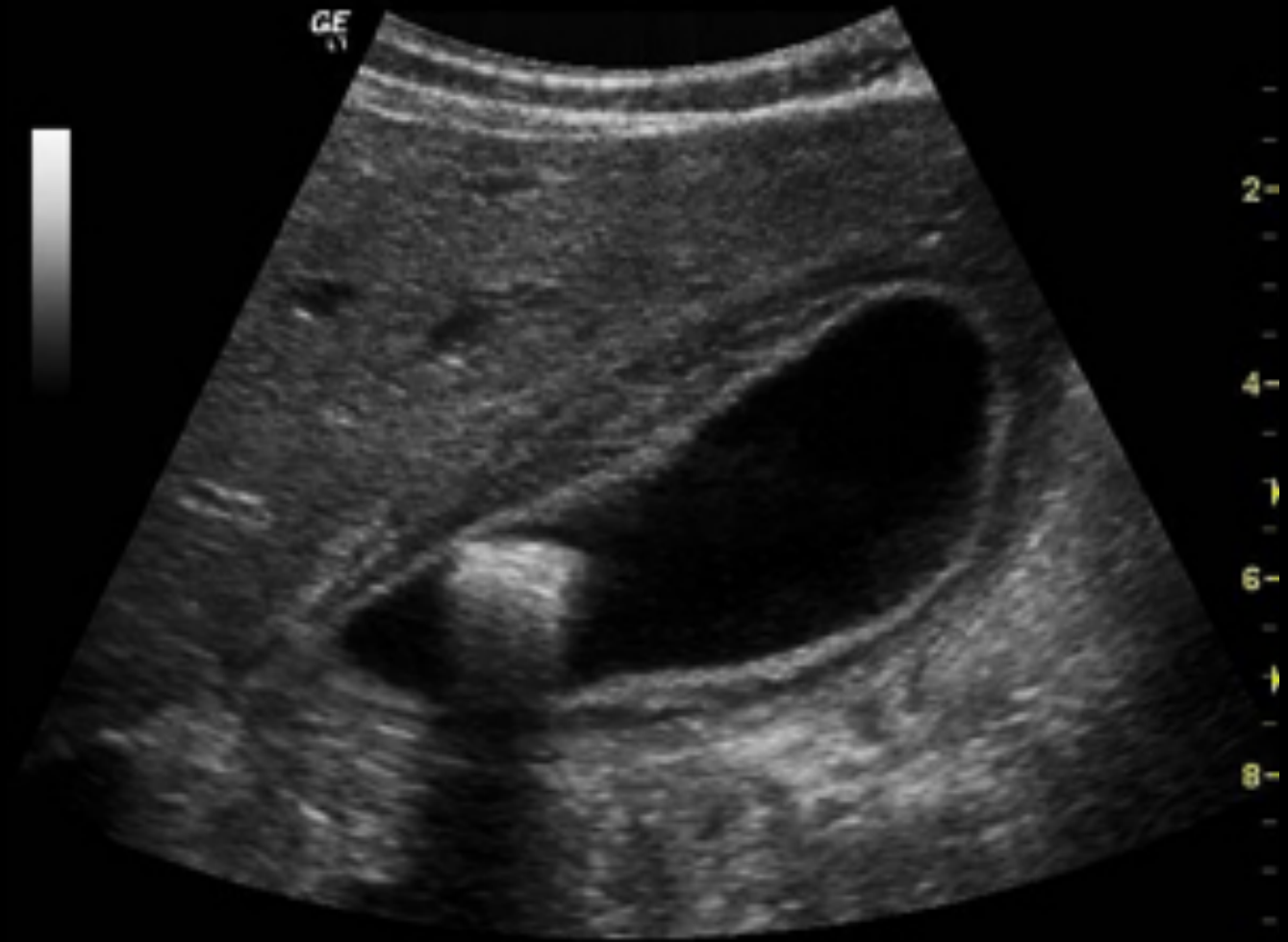Normal



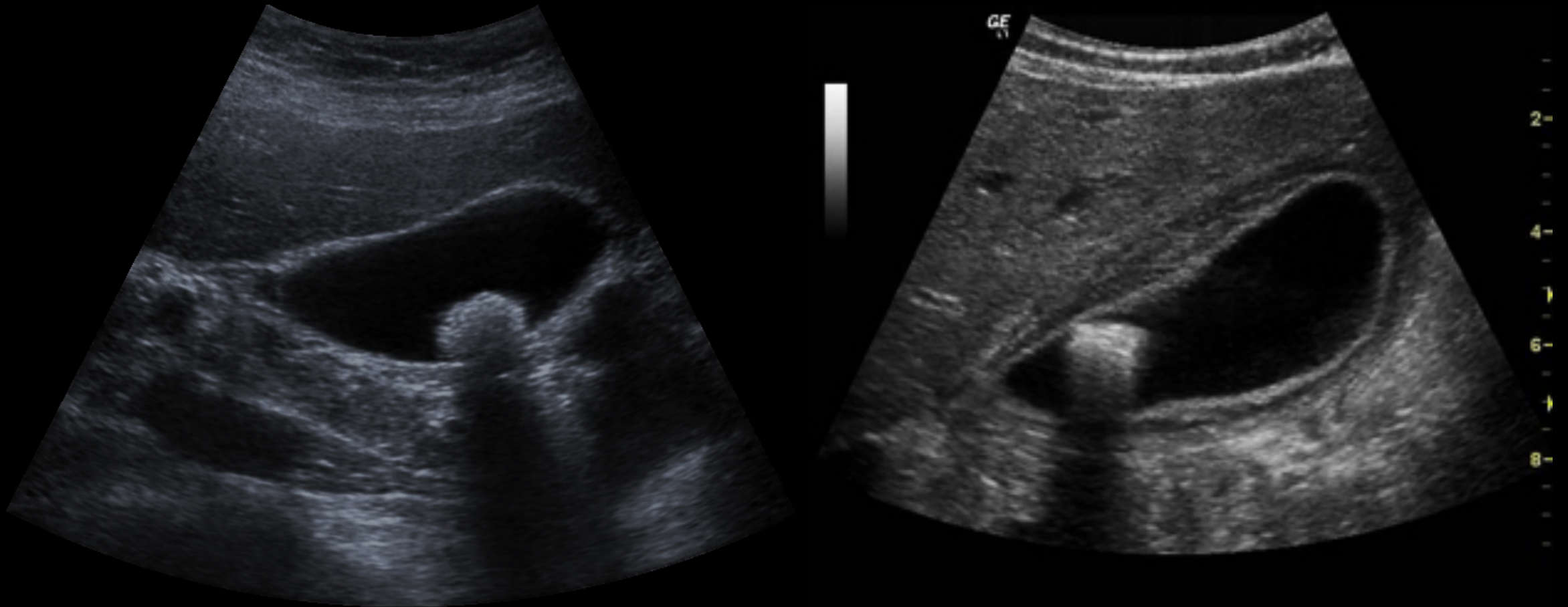
Acute calculous cholecystitis

Acute cholecystitis:

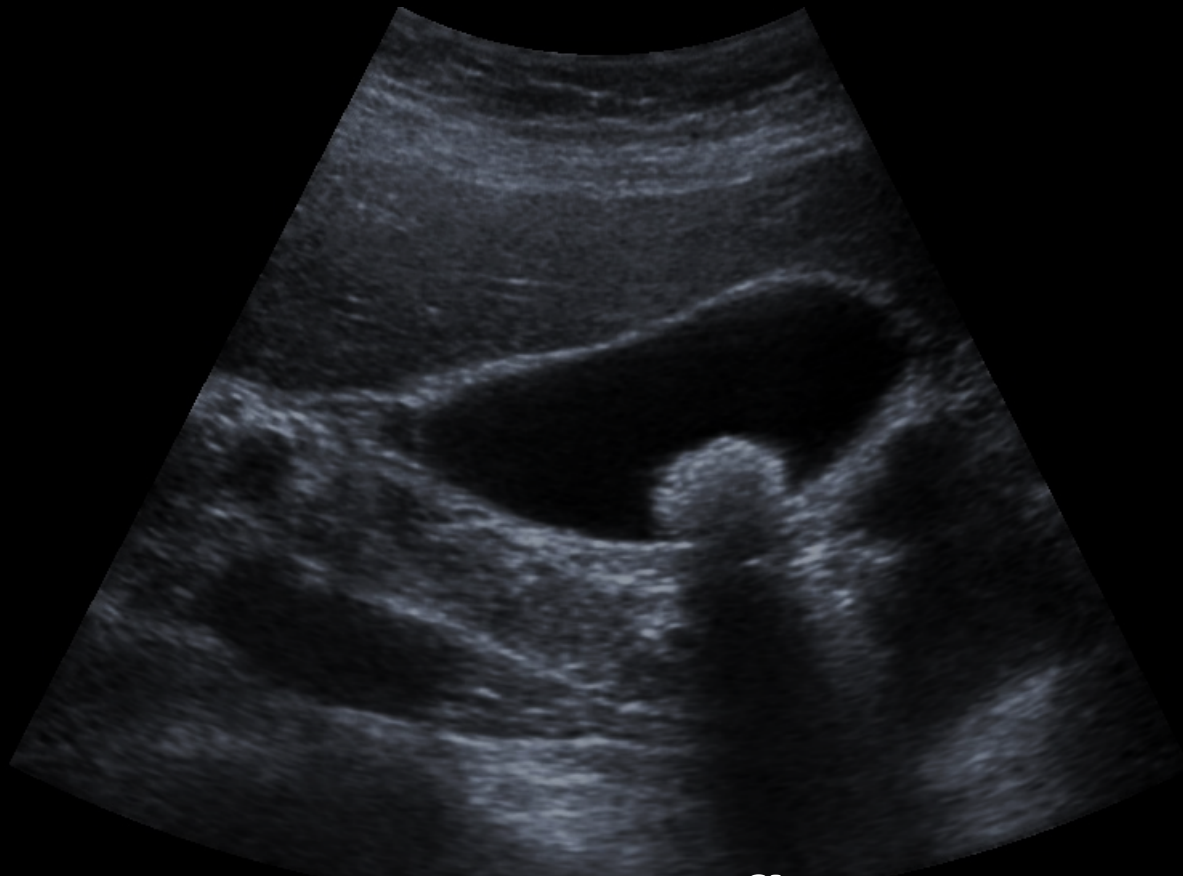
- Gallbladder wall **thickening** (more than 3mm)
- Gallbladder **distension**
- Surrounding **fluid**
- Gallstone (**calculous** cholecystitis) without stone (**Acalculous** cholecystitis)



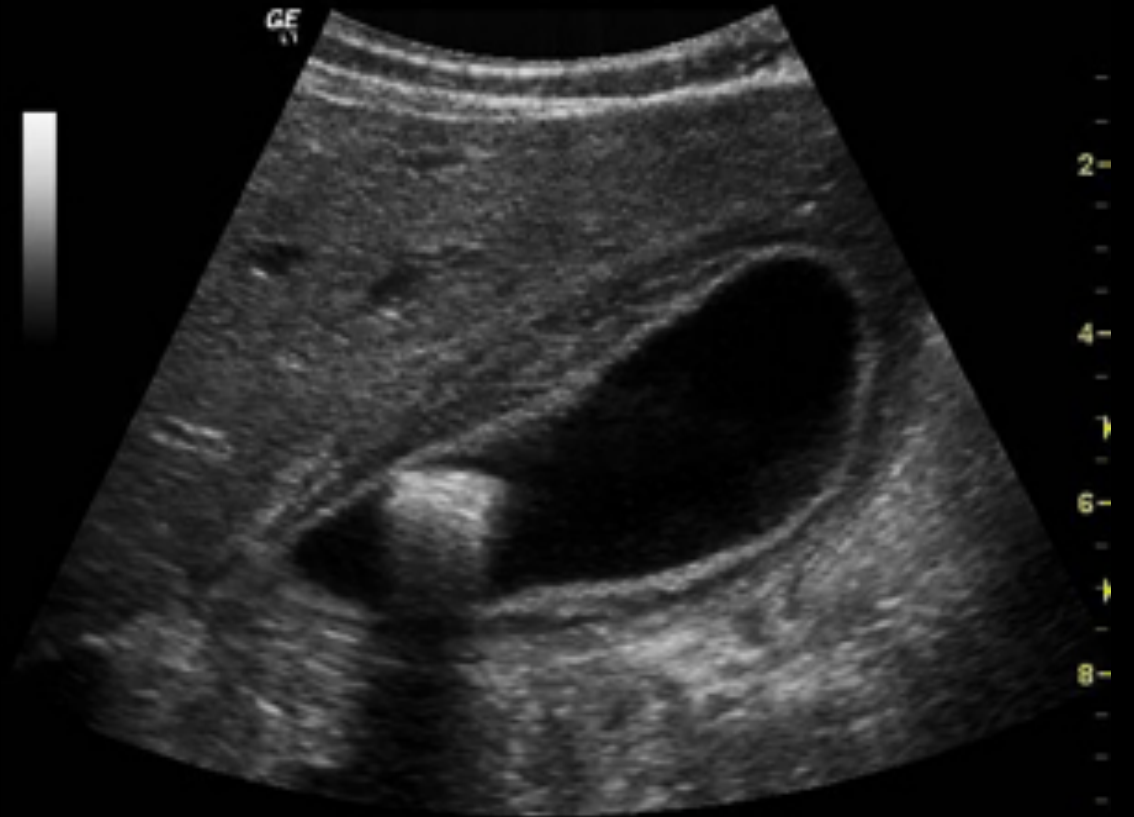
What is the difference between the two images?



What is the difference between the two images?

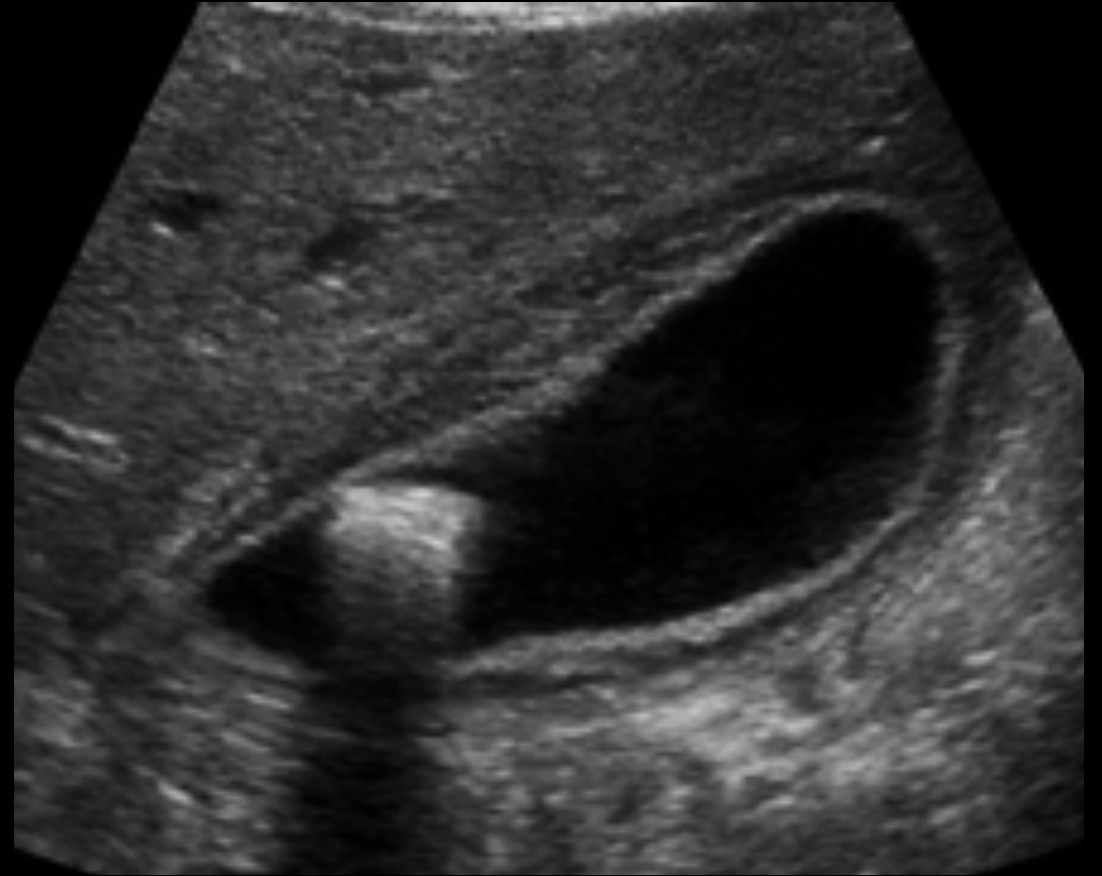
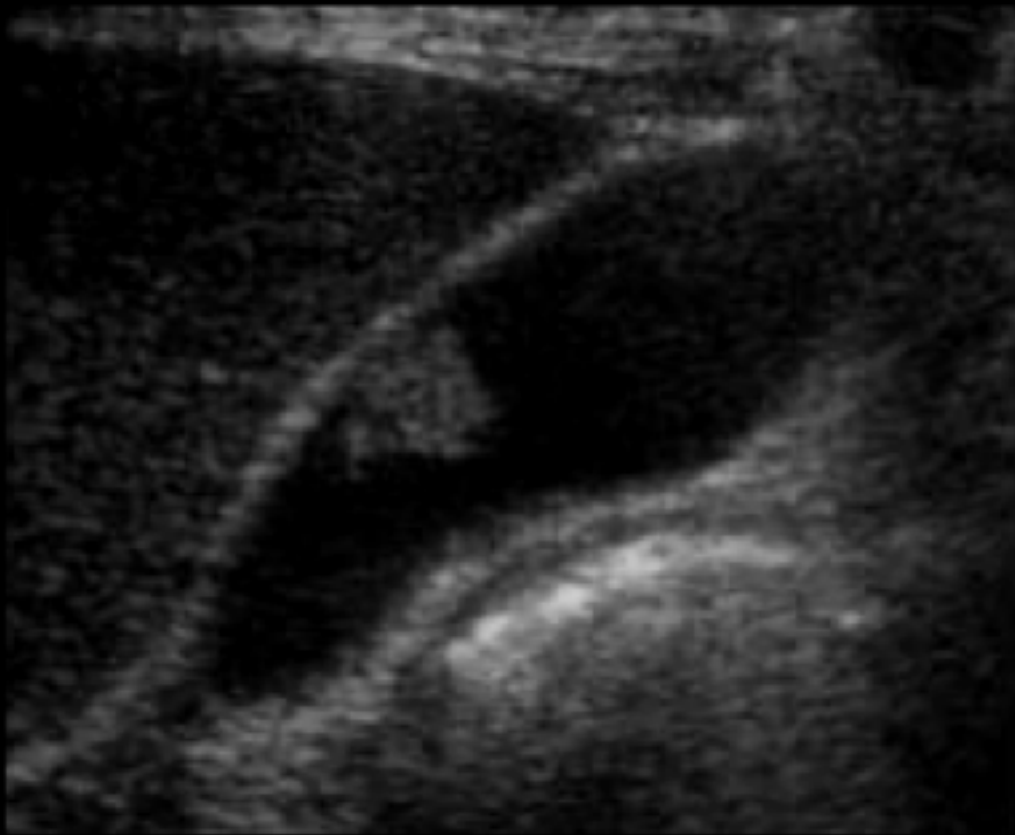


Stone **WITHOUT** inflammation

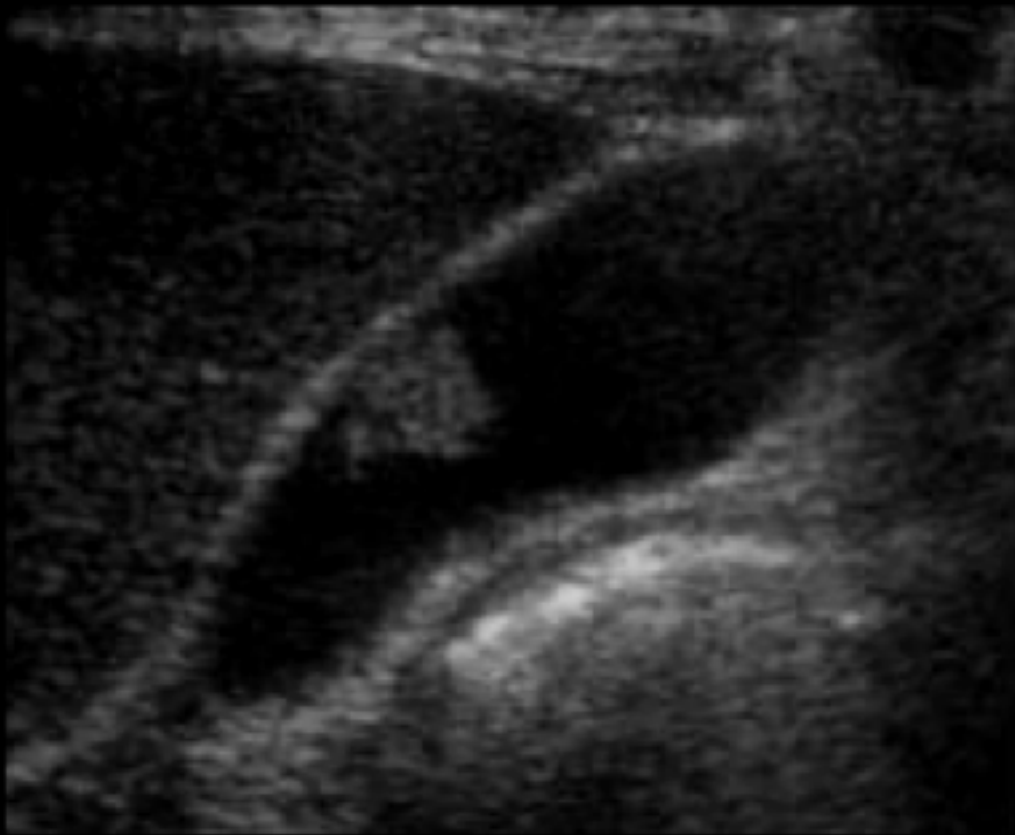


Stone **WITH** inflammation

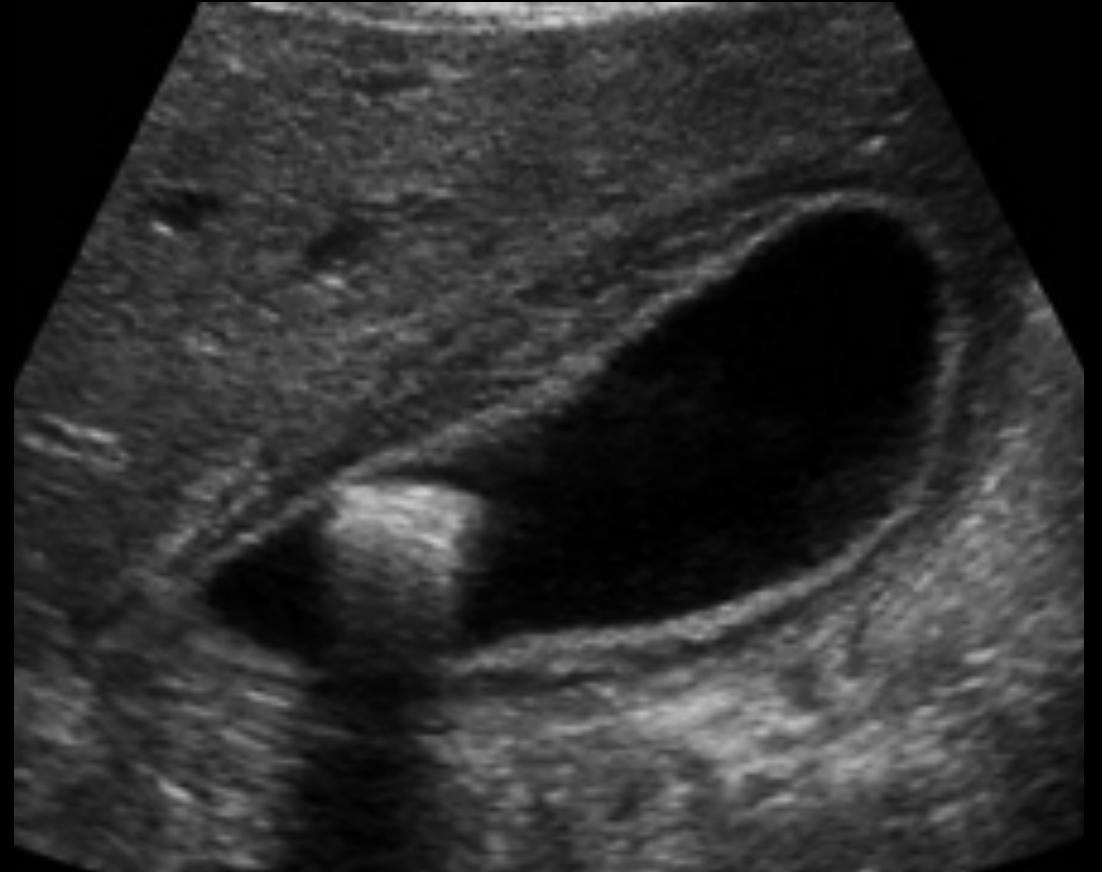
What is the difference between the two images?



What is the difference between the two images?

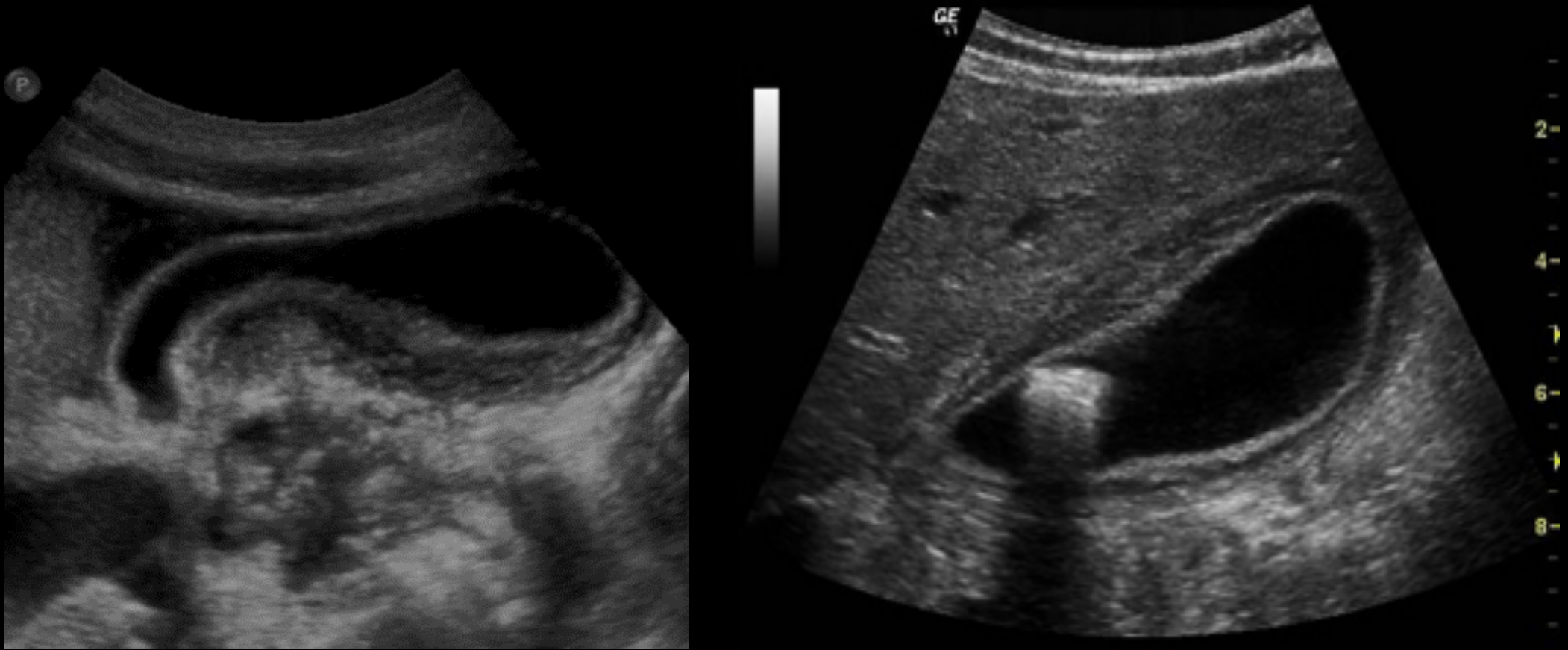


WITHOUT acoustic shadow (GB **polyp**)

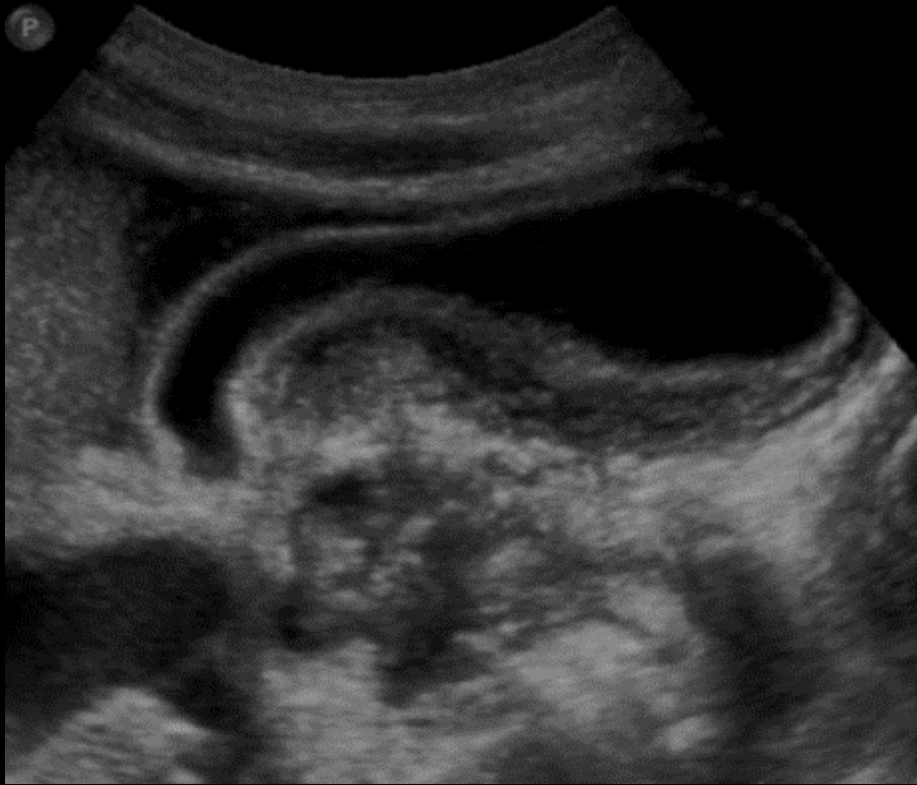

WITH acoustic shadow (GB **stone**)

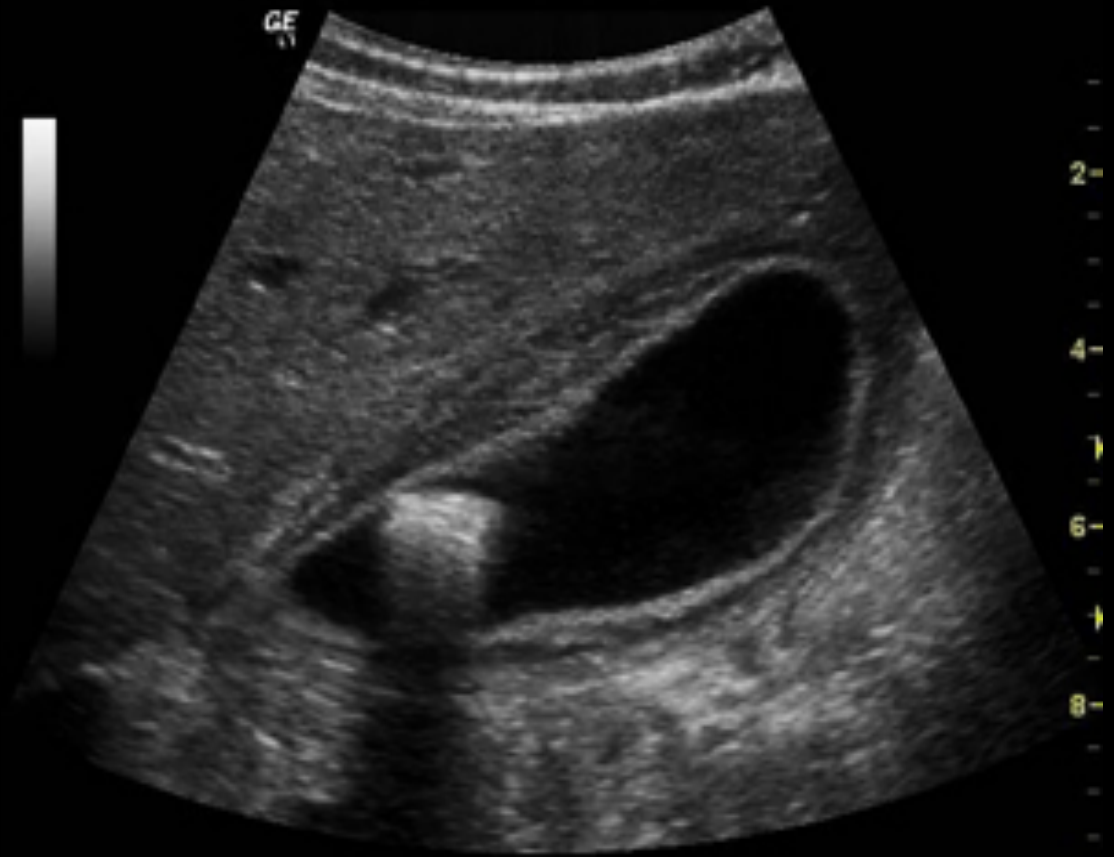What is the difference between the two images?



What is the difference between the two images?

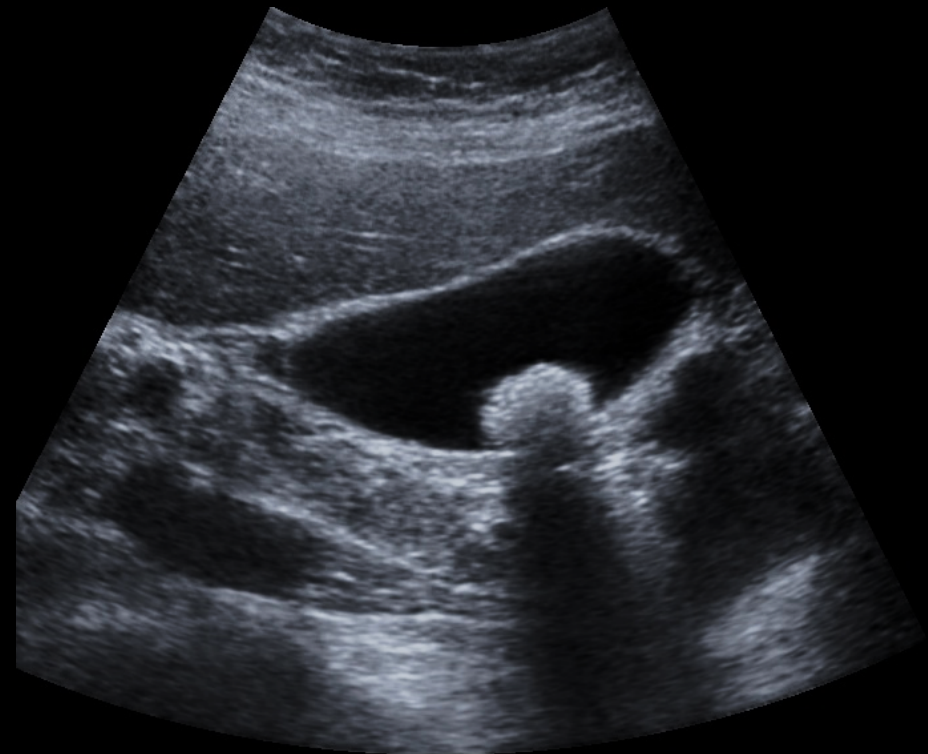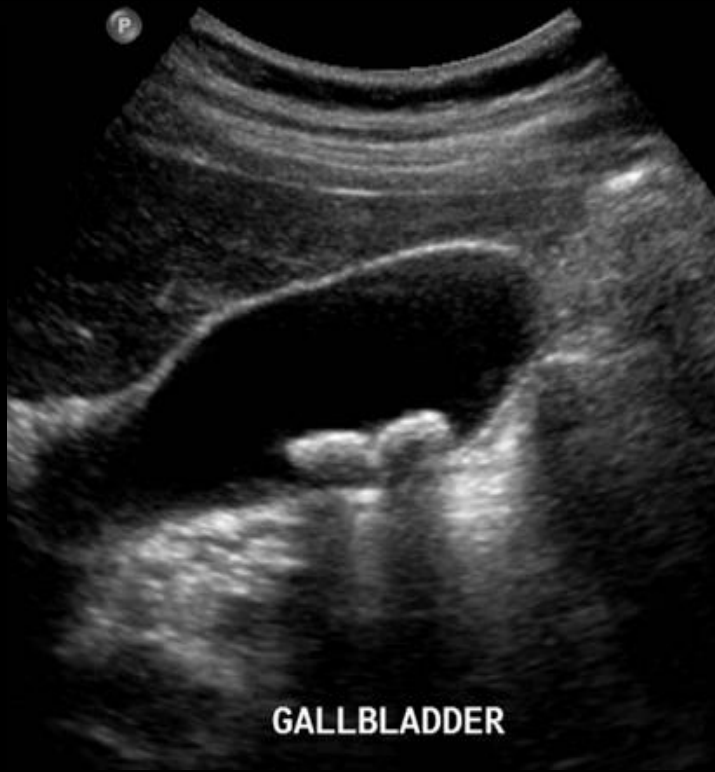

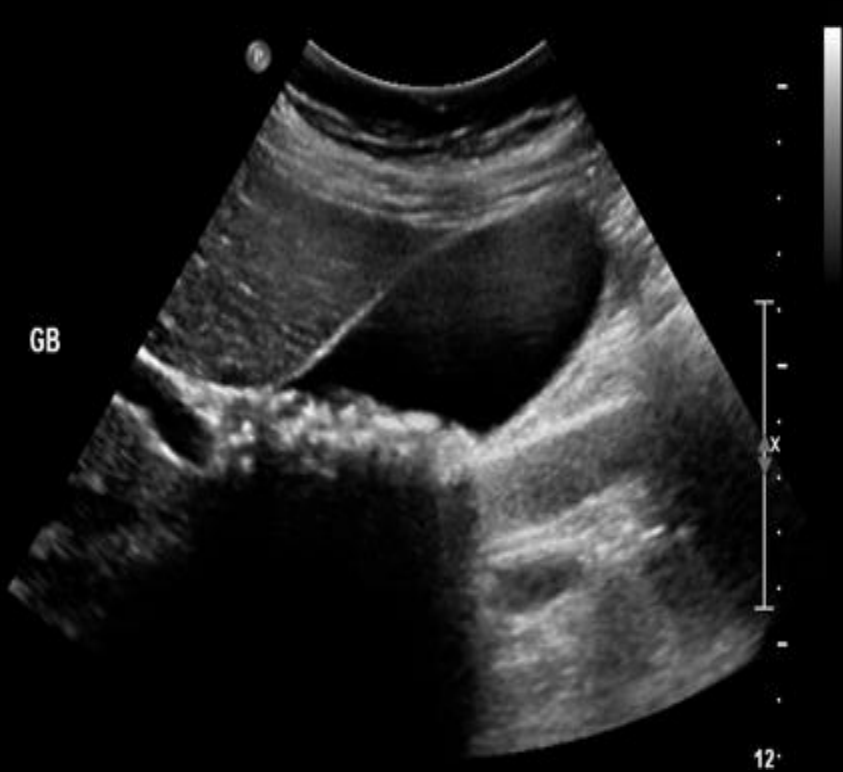
Acalculous cholecystitis

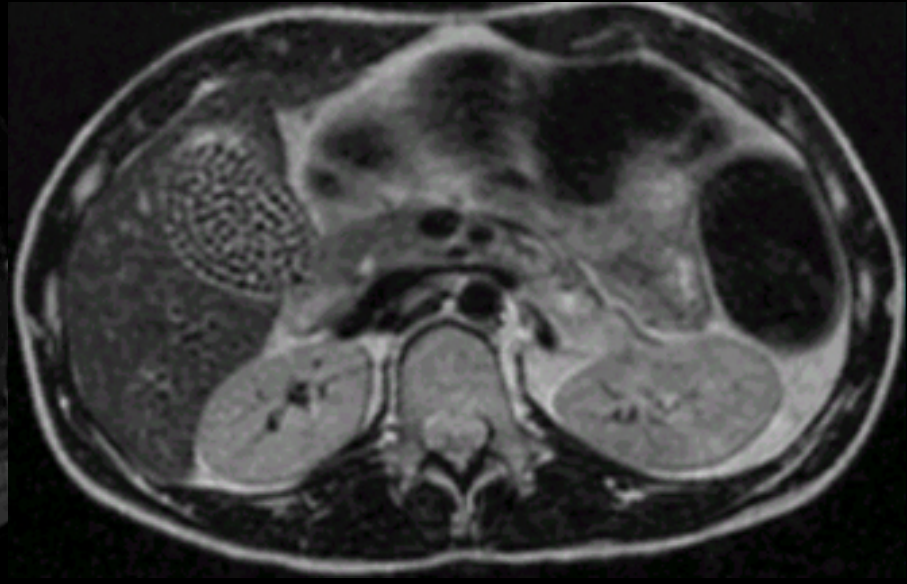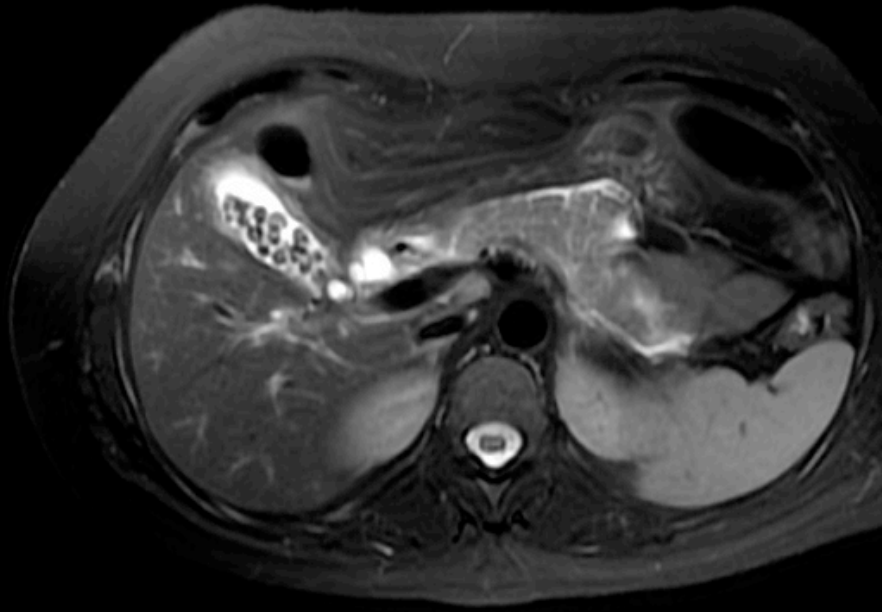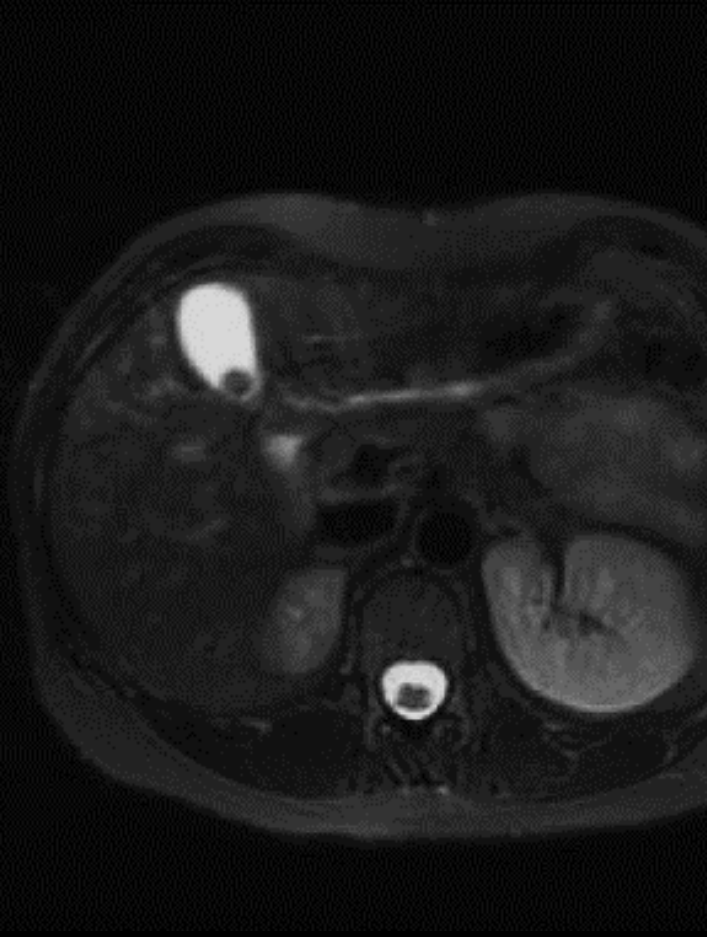


calculous cholecystitis

Different gallstones



Gallstones on MRI

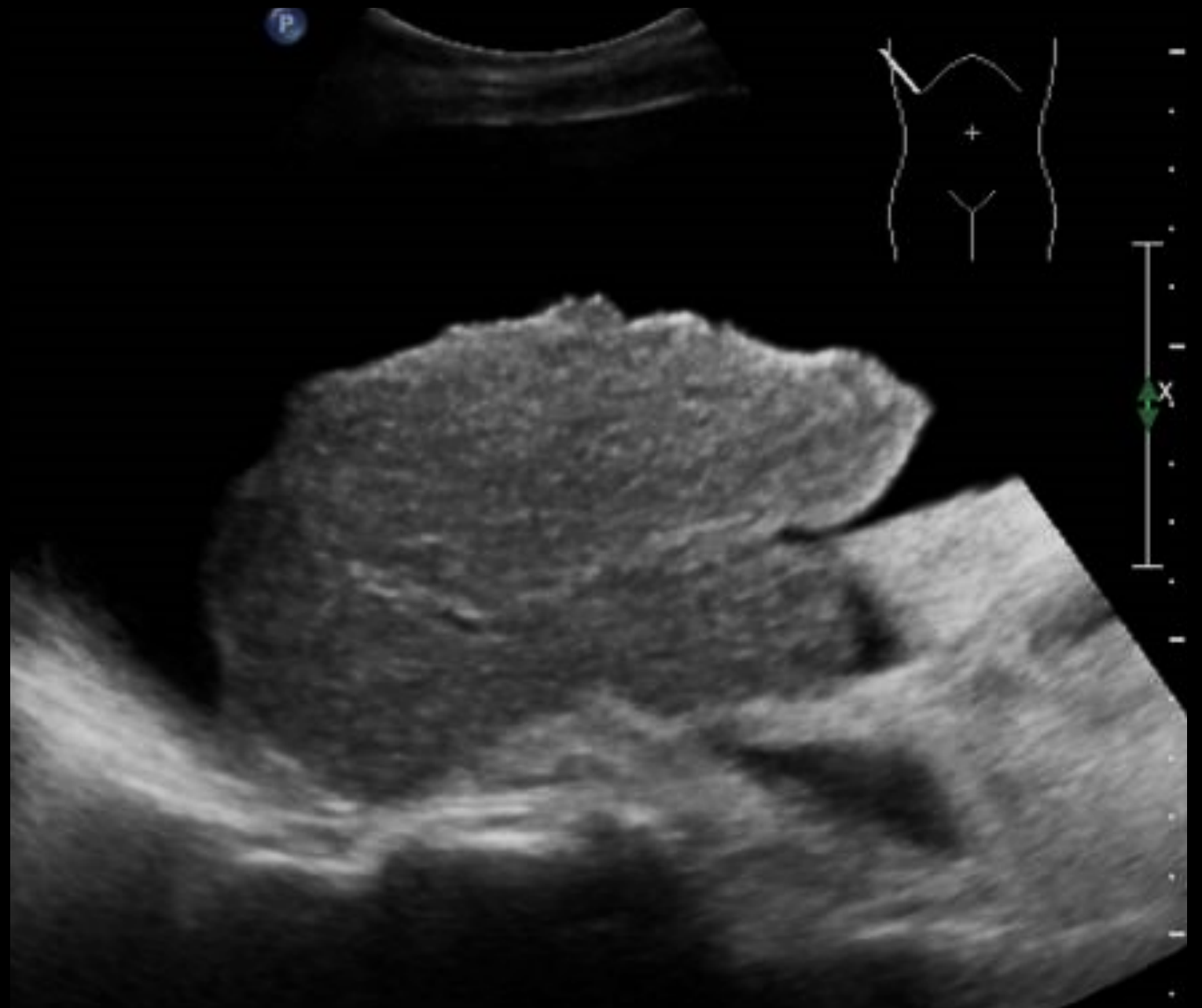

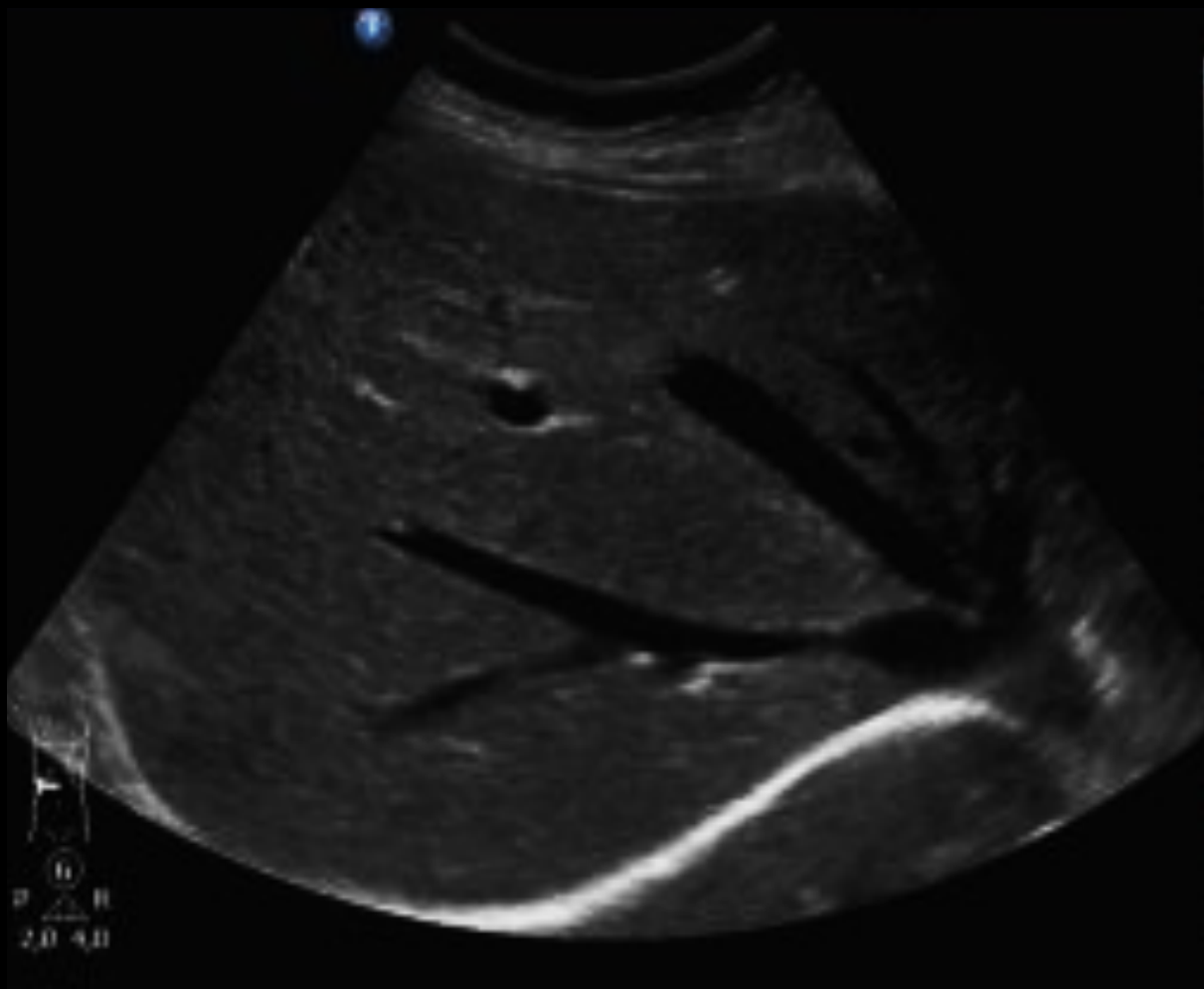Case 2

60 year-old male with chronic alcoholic consumption and complaining of fatigue, disorientation and abdomen distension.

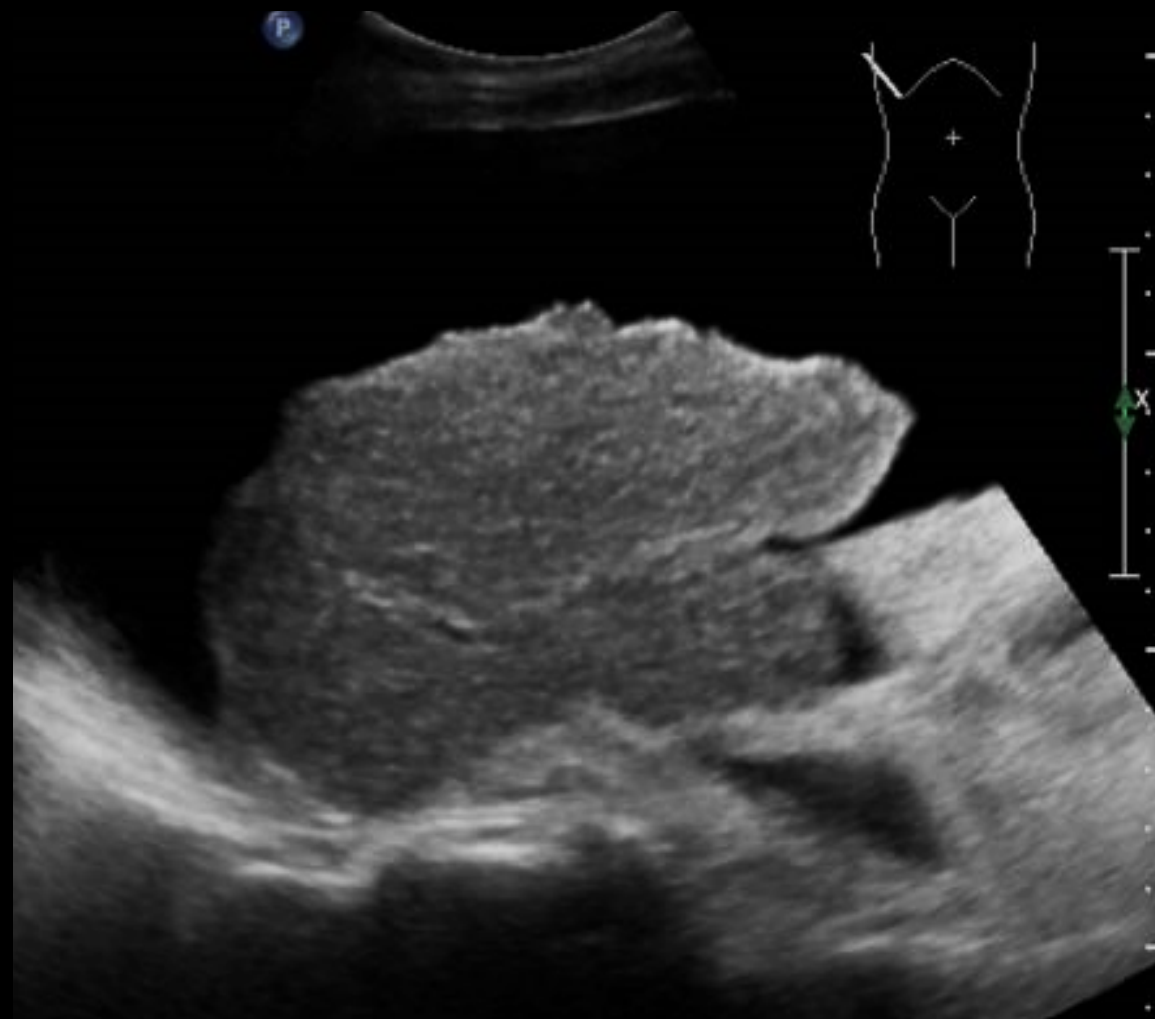- What do you think this patient has?
- What radiology modality you will start with ?

What is
abnormal?





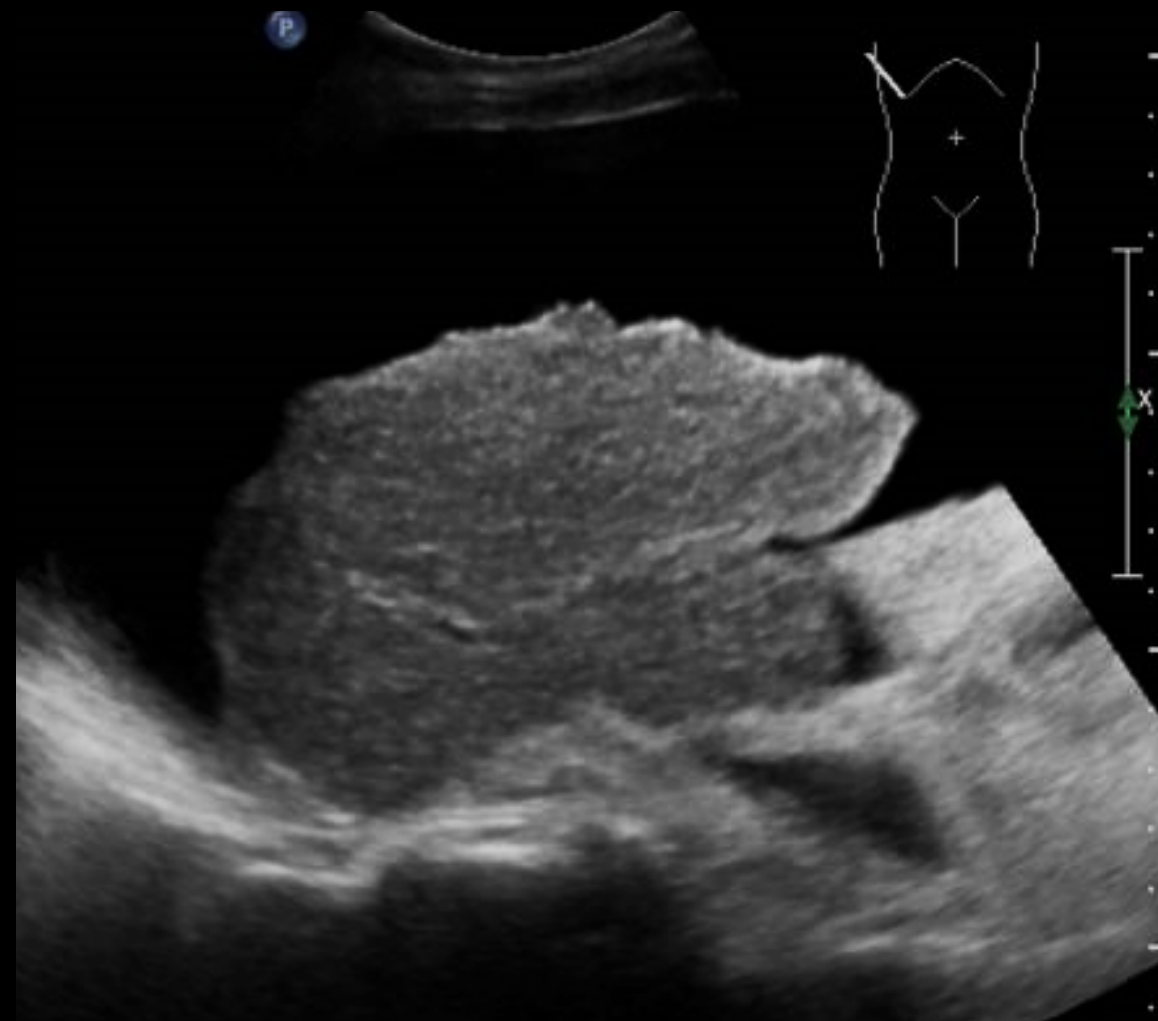Normal



Abnormal



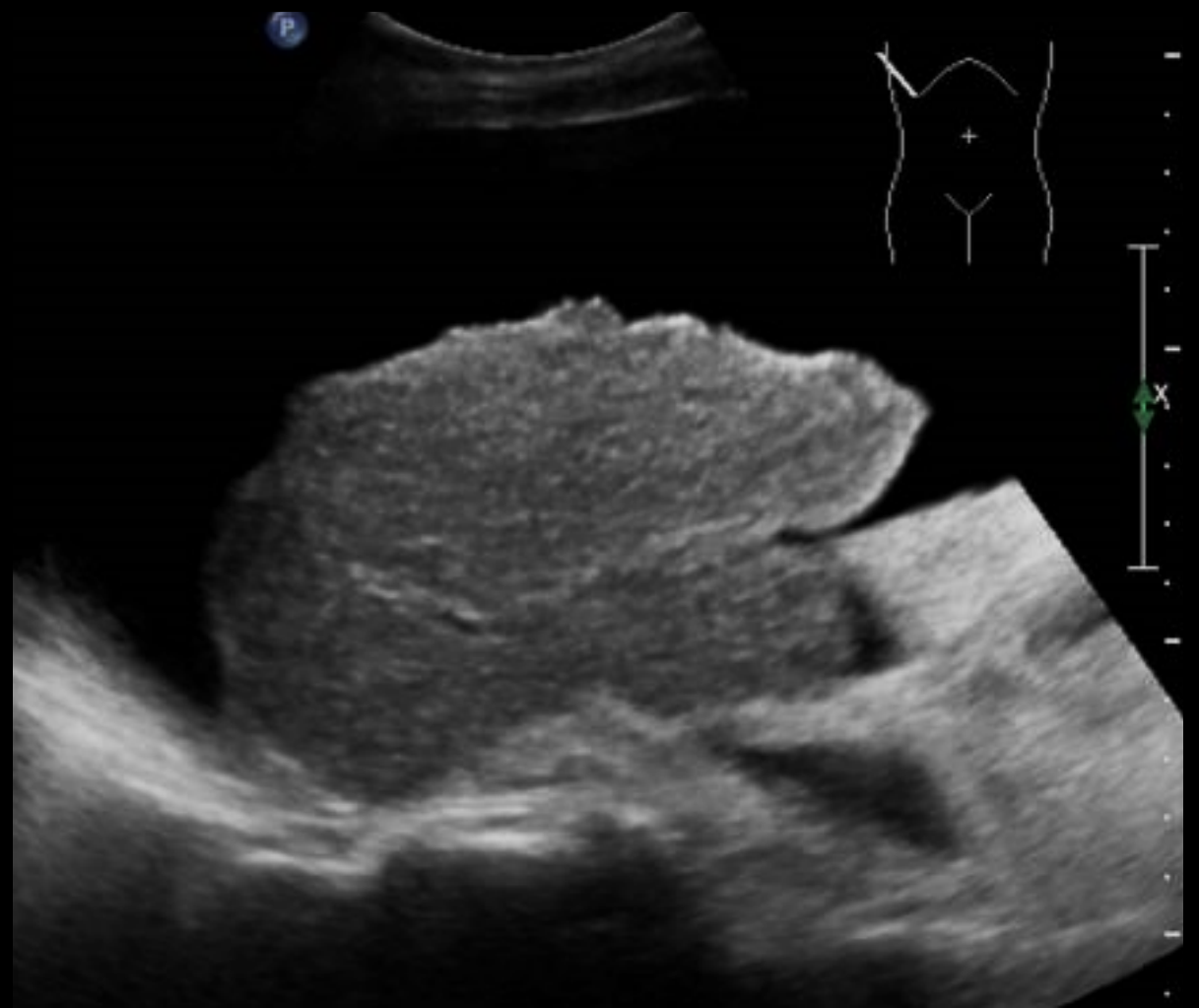Normal



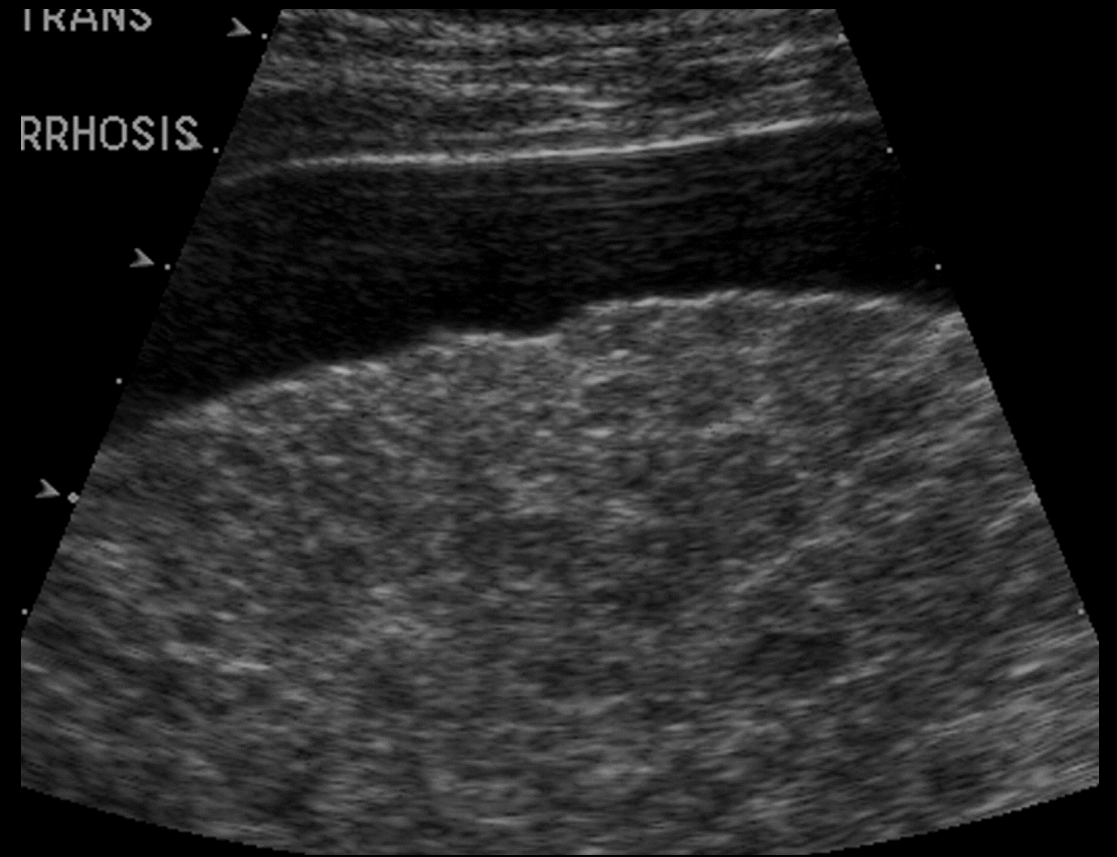
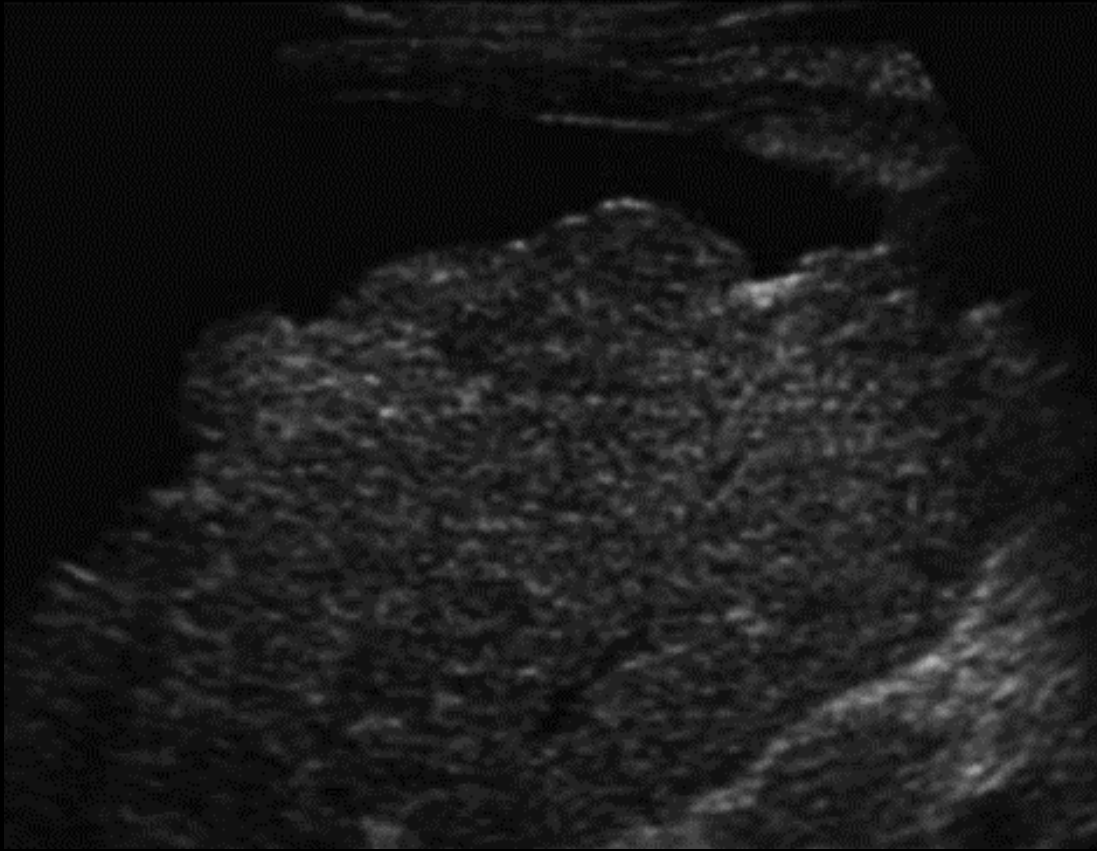
cirrhosis

Liver cirrhosis:

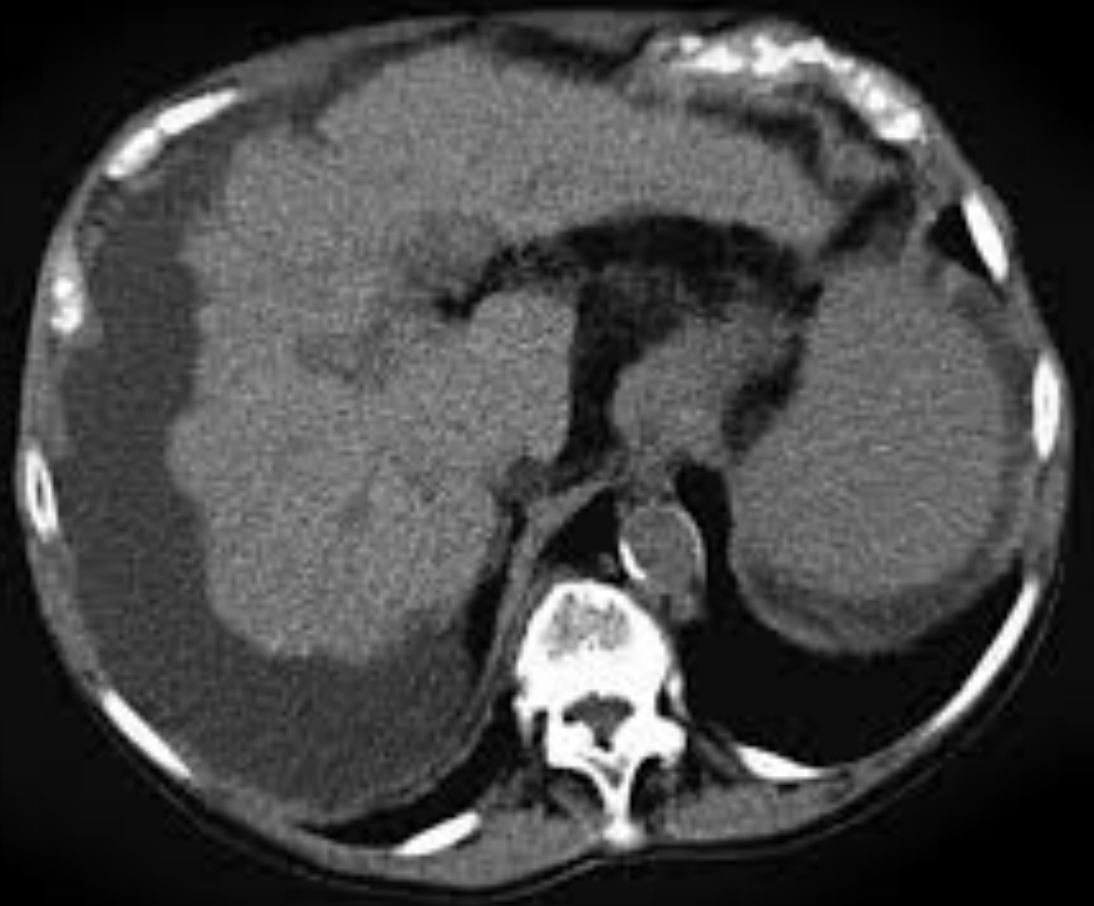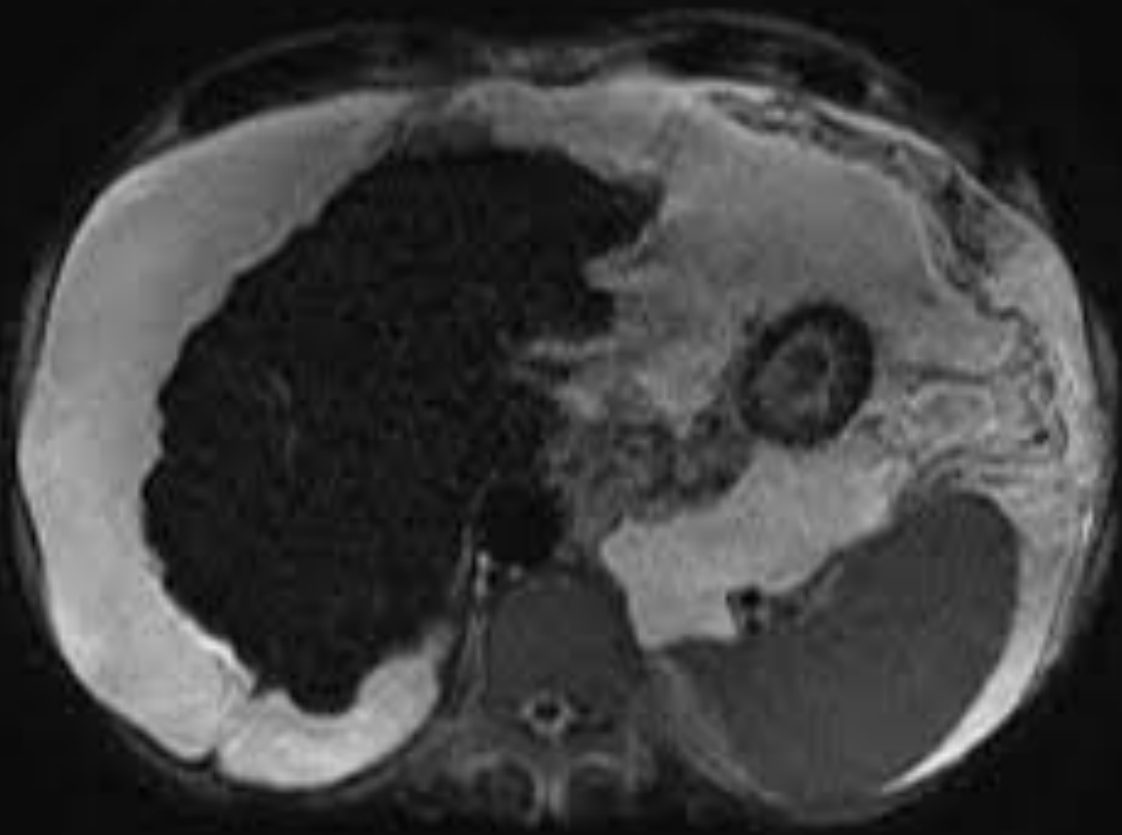
- Nodular surface
- Shrunken size
- Hyper echoic parenchyma
- Ascites



Other examples of cirrhosis



Cirrhosis on CT scan and MRI:

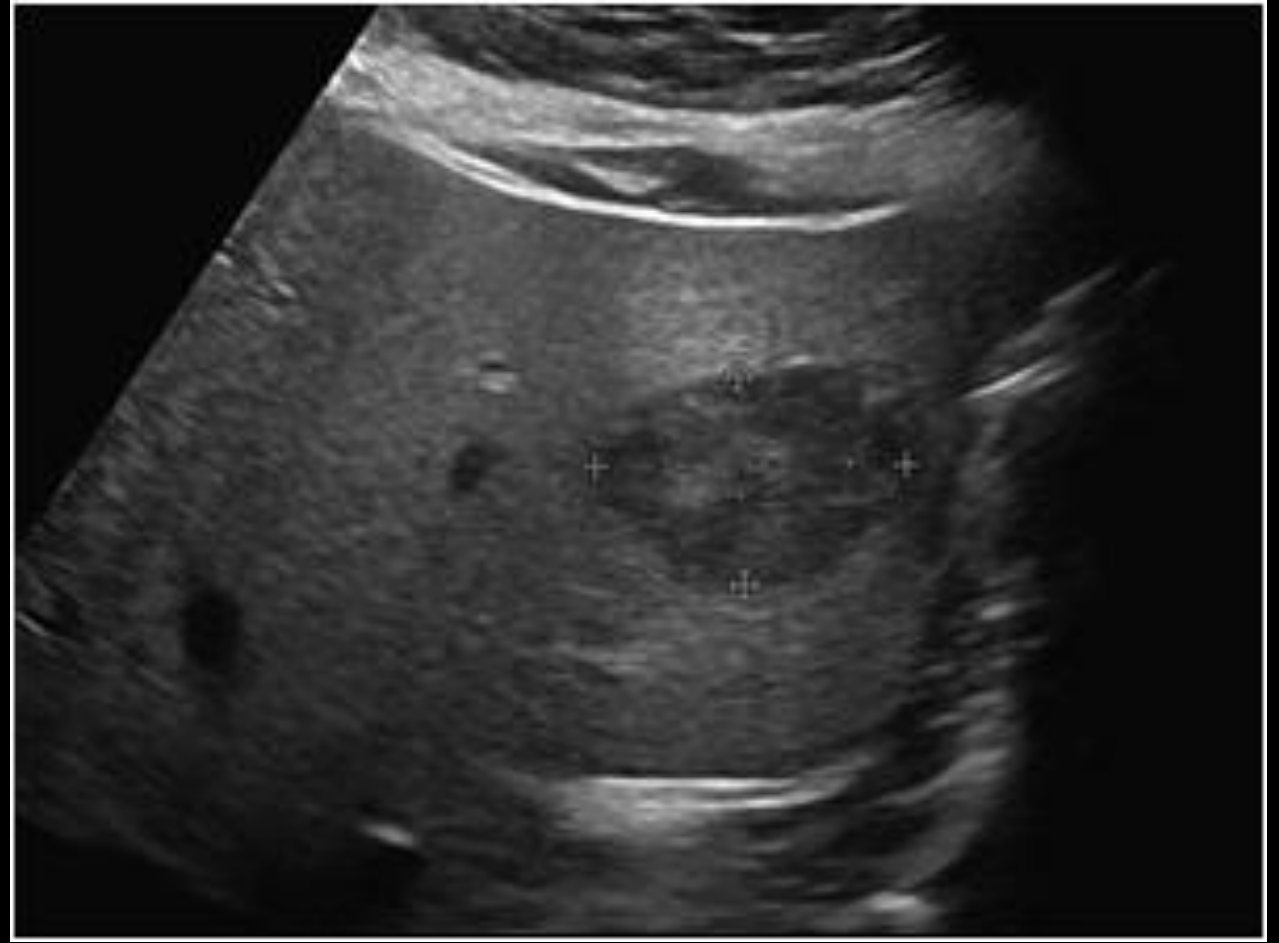


Case 3

US for chronic hepatitis B virus patient. What is your diagnosis?

What is DDx?

Next step?



DDx:

Benign:

Hemangioma

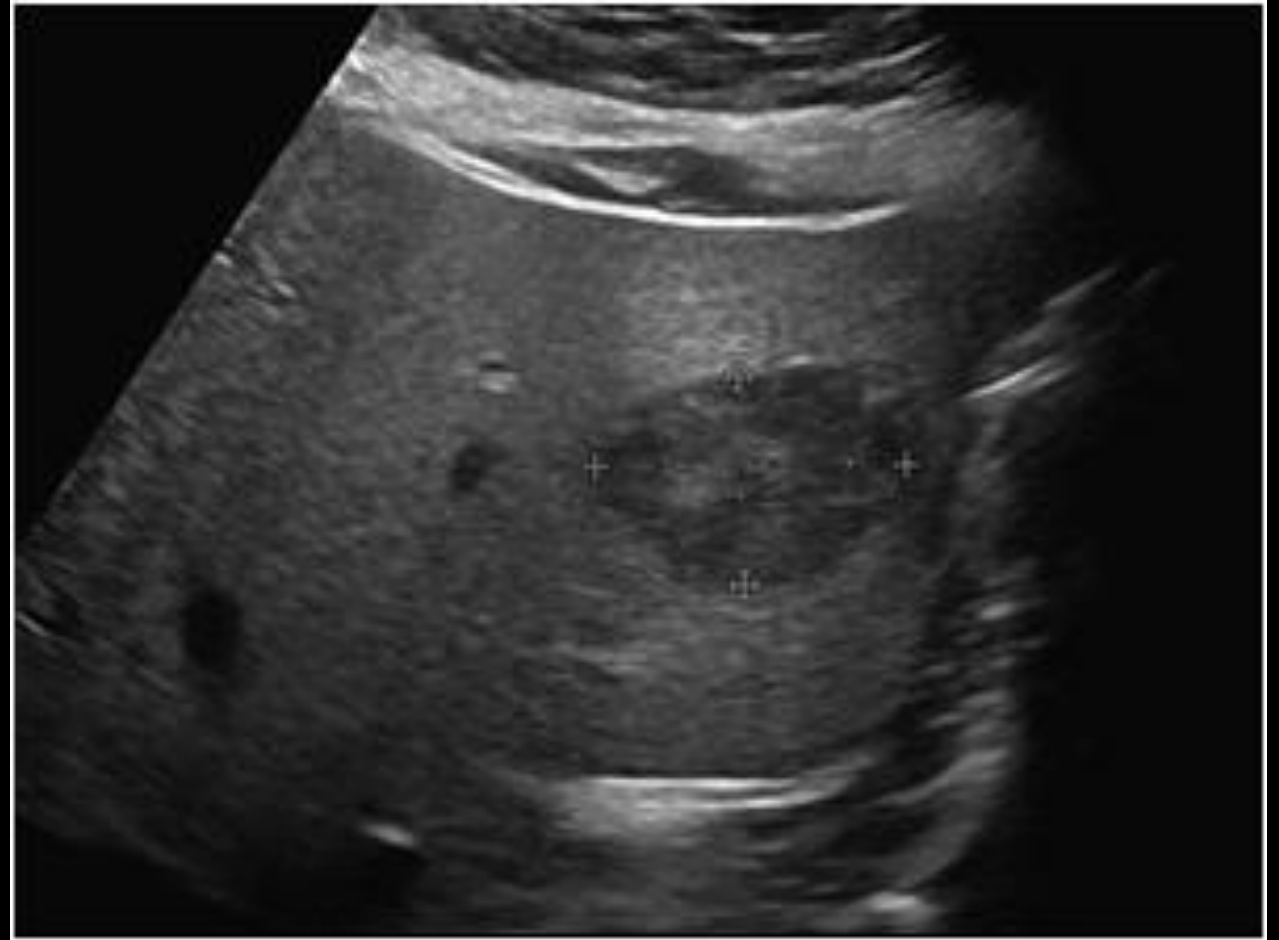
Adenoma

Focal nodular hyperplasia

Malignant:

Hepatocellular carcinoma

Metastasis



DDx:

Benign:

Hemangioma

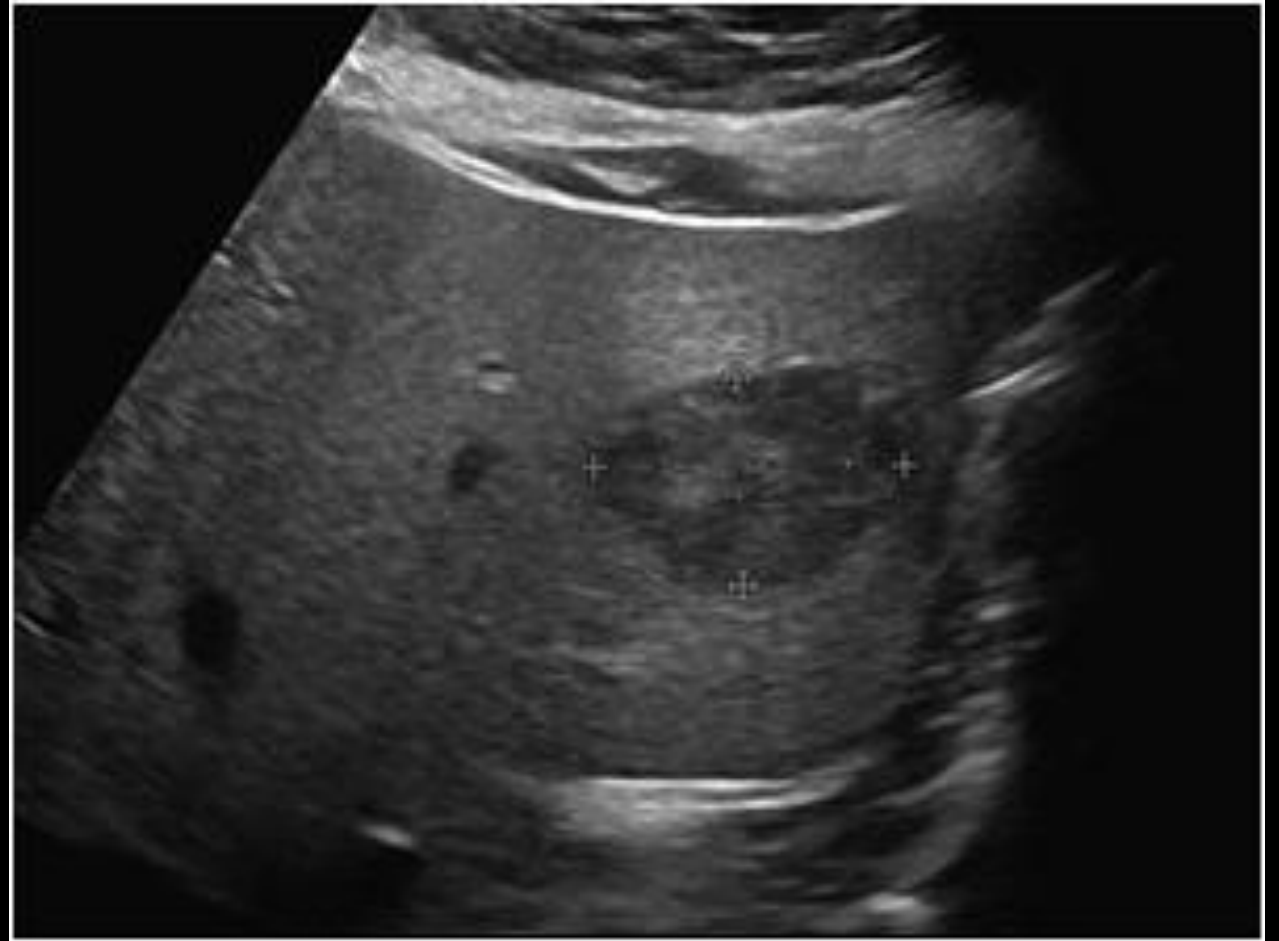
Adenoma

Focal nodular hyperplasia

Malignant:

Hepatocellular carcinoma

Metastasis



How to tell if its benign or malignant ????

DDx:

Benign:

Hemangioma

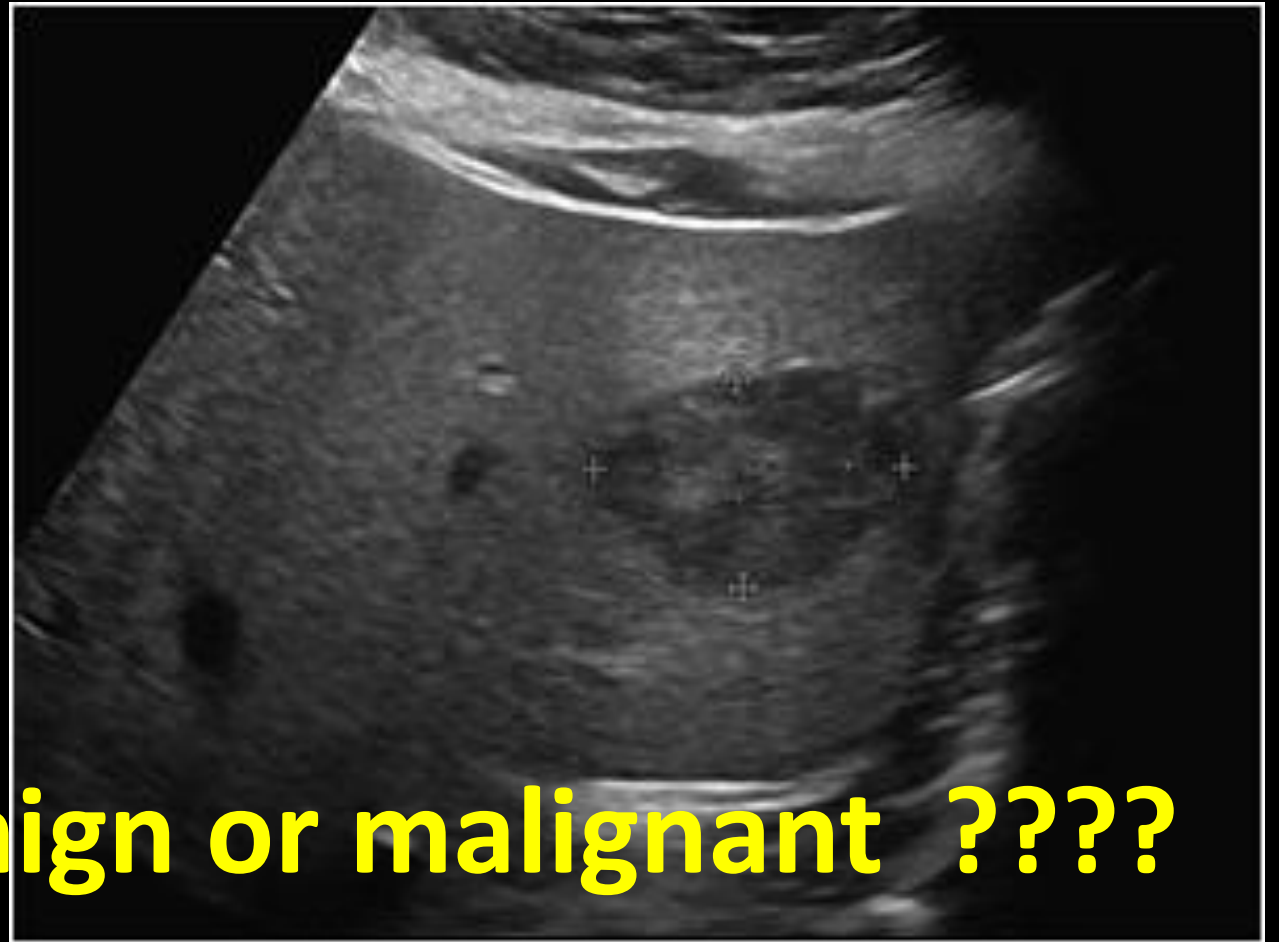
Adenoma

Focal nodular hyperplasia

Malignant:

Hepatocellular carcinoma

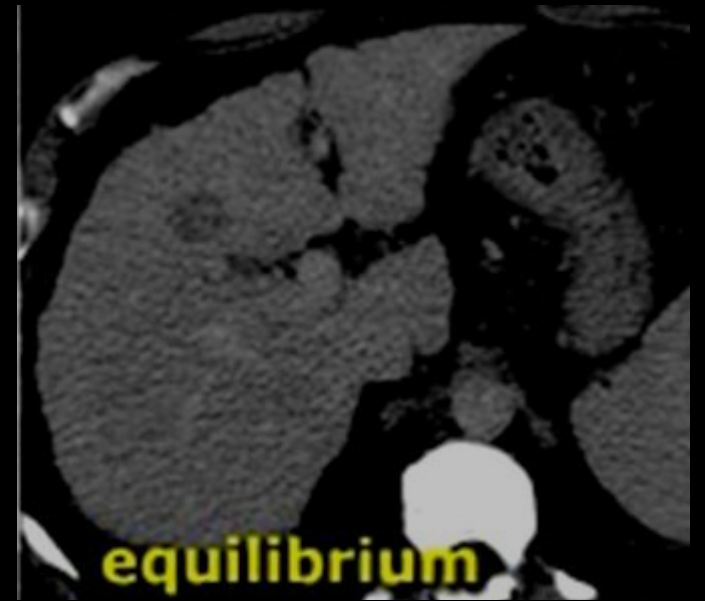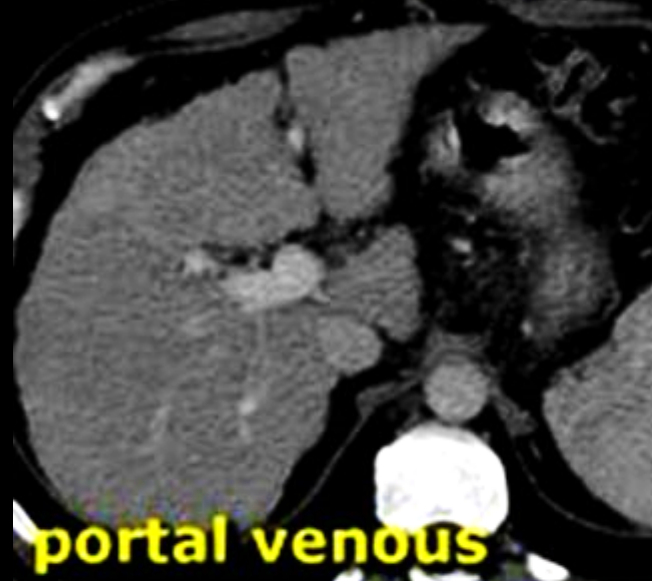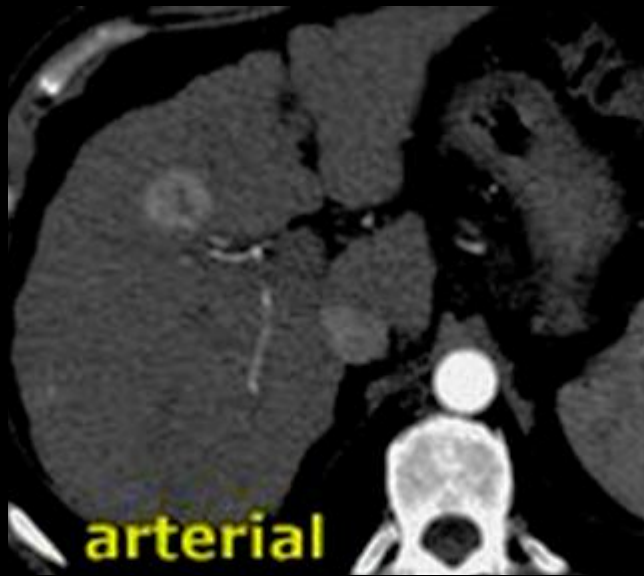
Metastasis



How to tell if its benign or malignant ????

**DO CT scan or MRI with
intravenous contrast**

CT scan with IV contrast (triphasic scan)

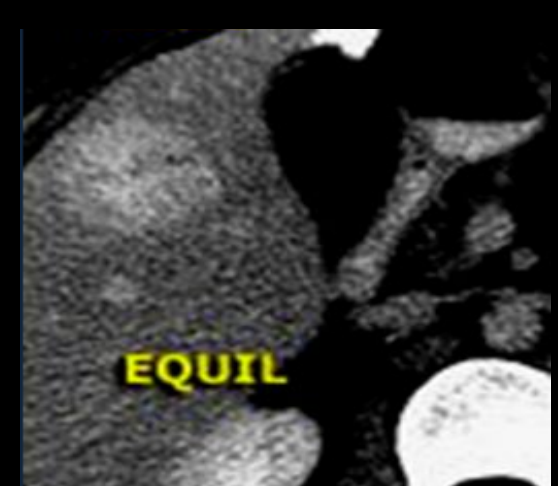
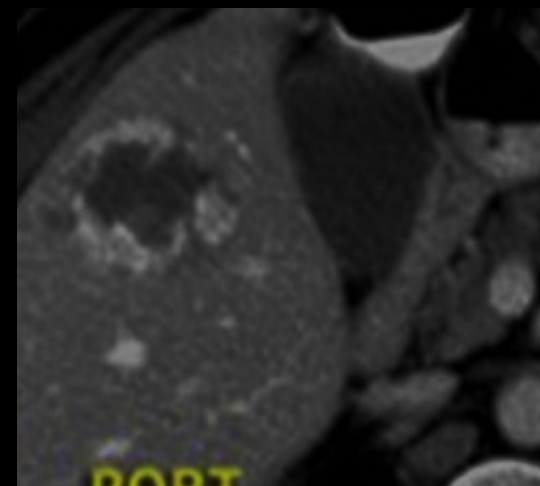
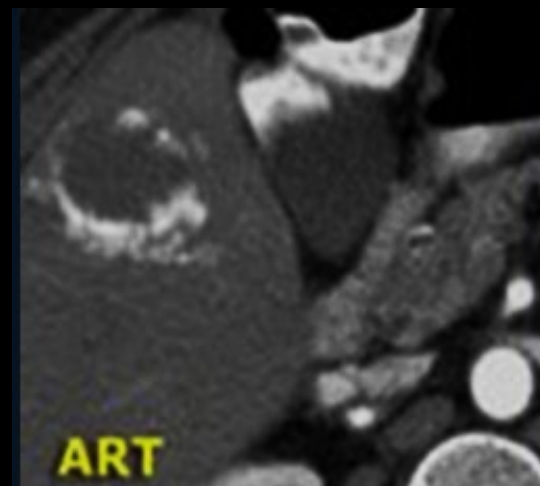
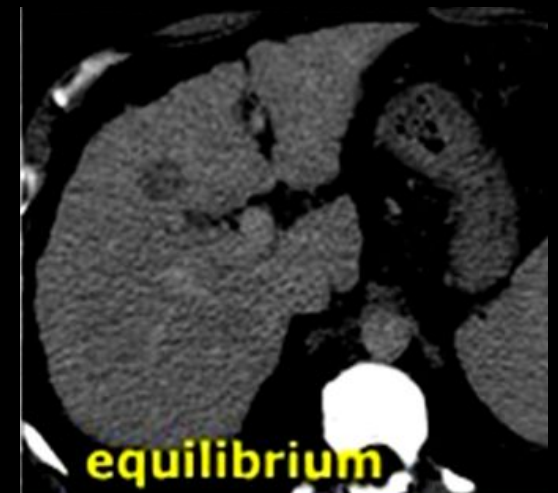
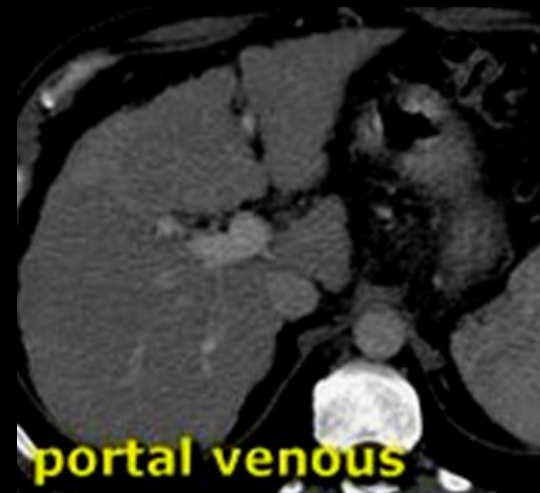
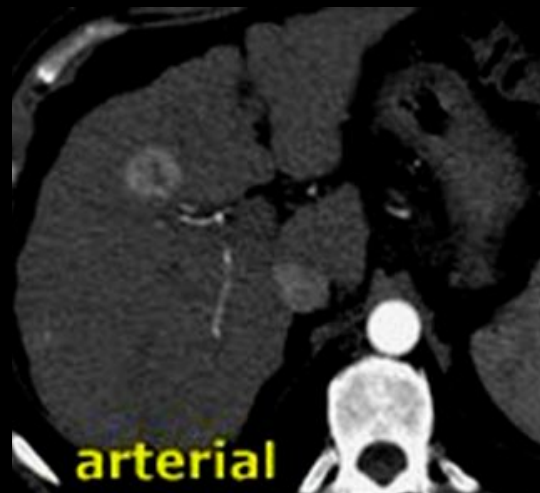Hepatocellular carcinoma

Triphasic liver CT scan

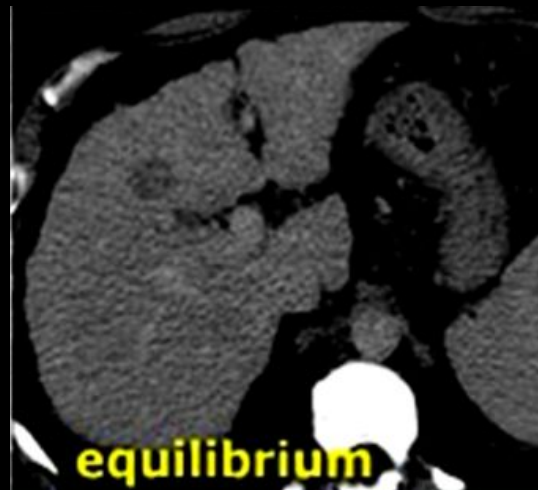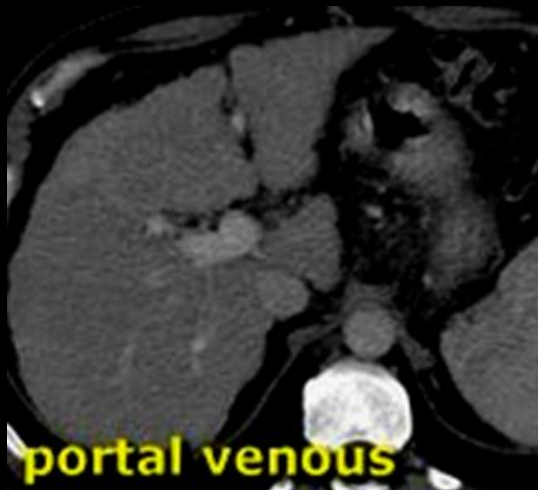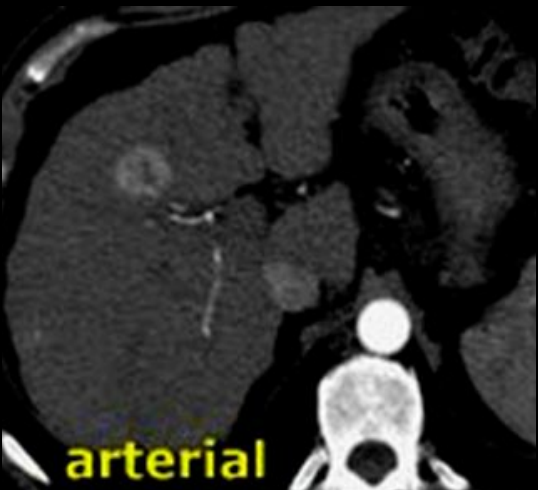- Scanning liver with intravenous (IV) contrast in three different phases:
 - **Phase 1 (arterial):** when IV contrast in arteries/ 30 to 40 seconds after IV contrast injection.
 - **Phase 2 (portal-venous):** when IV contrast in veins/ 60 to 70 seconds after IV contrast injection.
 - **Phase 3 (delayed or equilibrium):** after 3 to 5 minutes after IV contrast injection.
- Triphasic scan helps in differentiating benign from malignant masses:
 - Benign = BLACK (no enhancement) in **phase 1** / WHITE (enhancement) in **phase 3** (e.g. hemangioma)
 - Malignant = WHITE (enhancement) in **phase 1** / BLACK (no enhancement) in **phase 3** (e.g. HCC)

What is the difference between both cases?

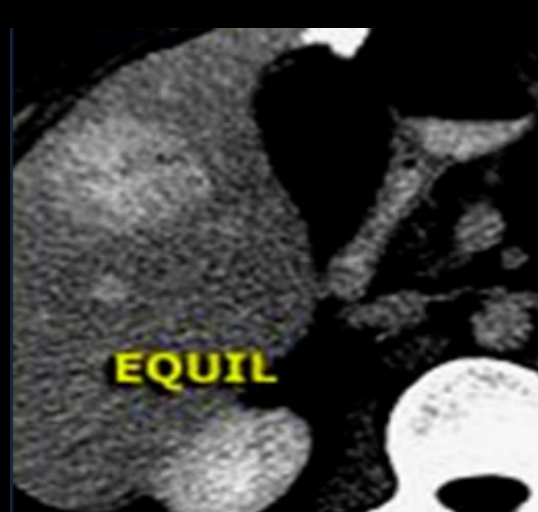
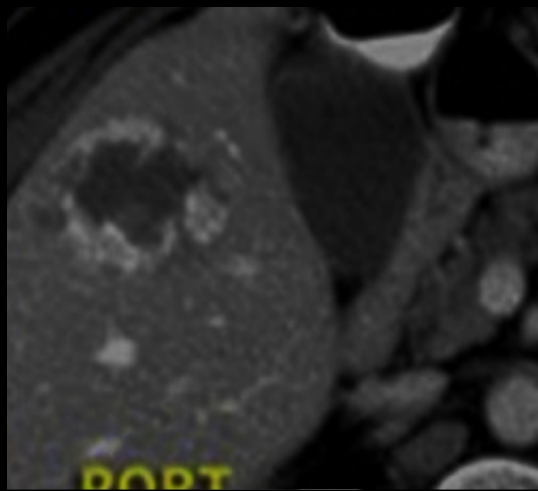
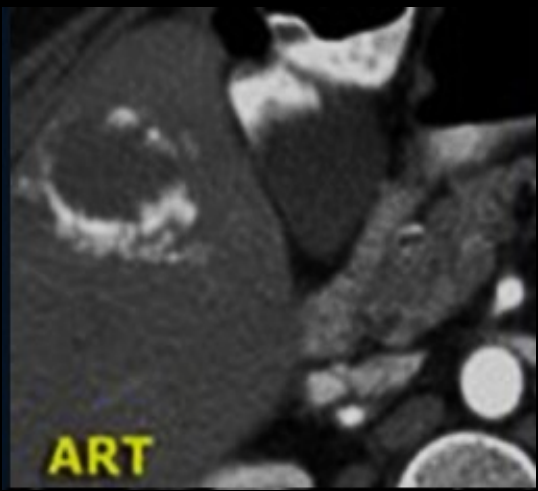


What is the difference between both cases?

Hepatocellular carcinoma

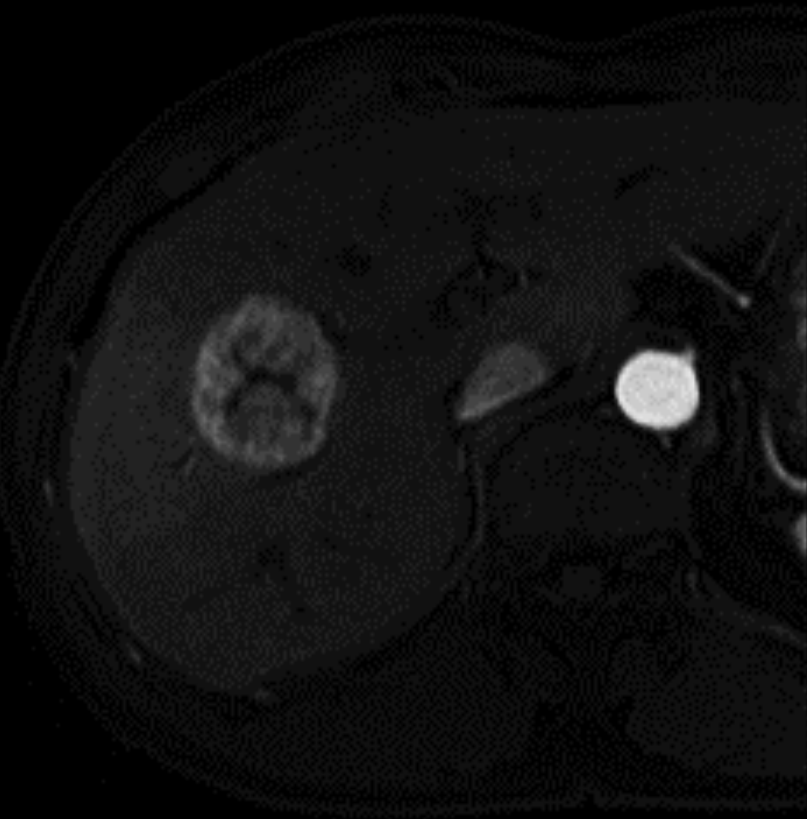


Hemangioma

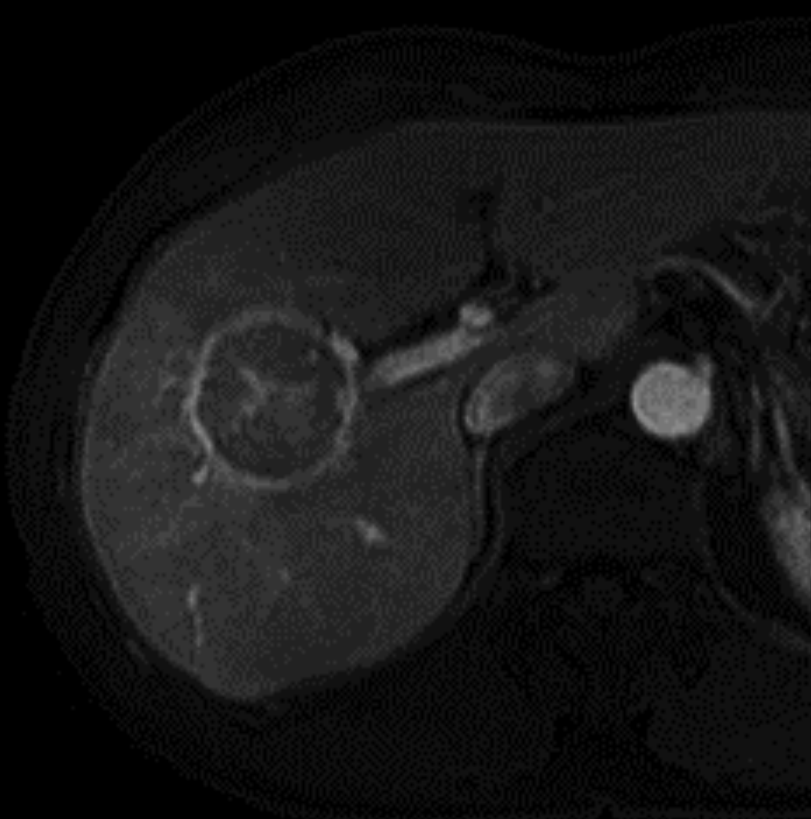


Benign or malignant ????

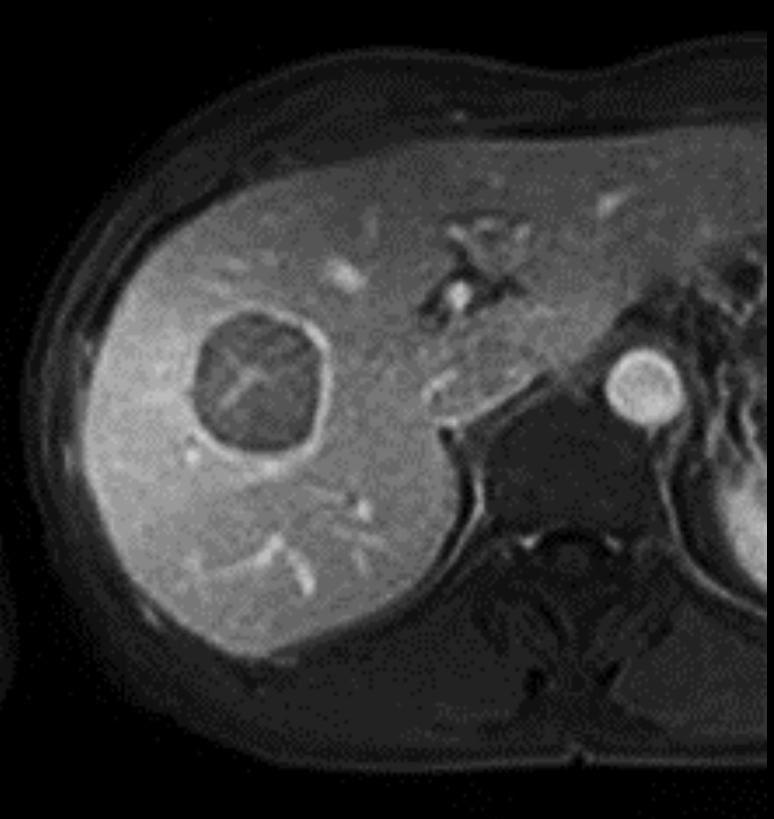A



B

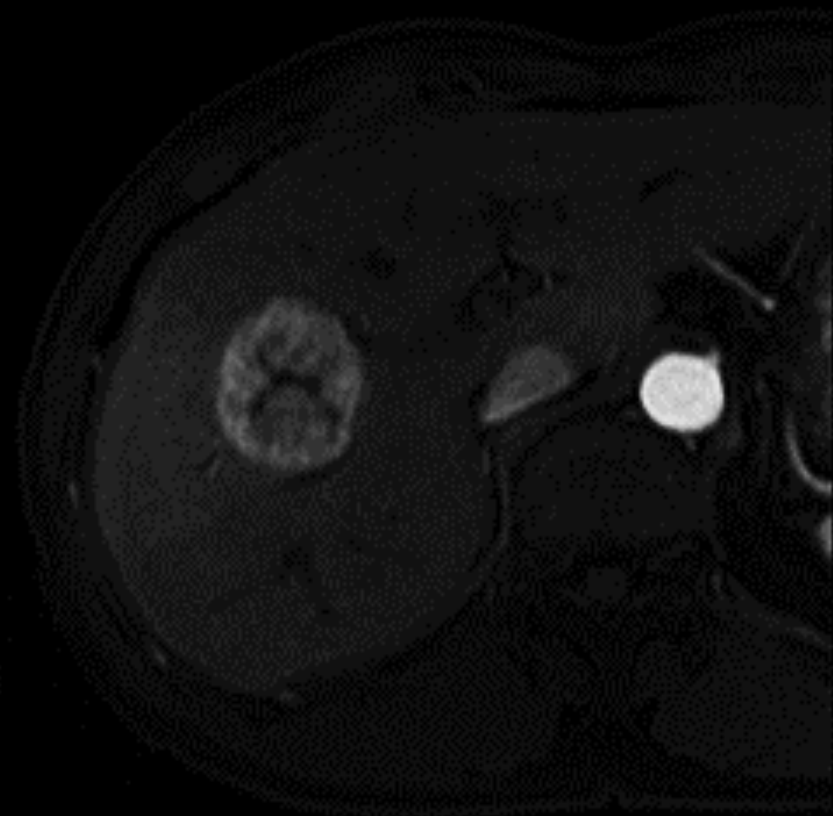


C

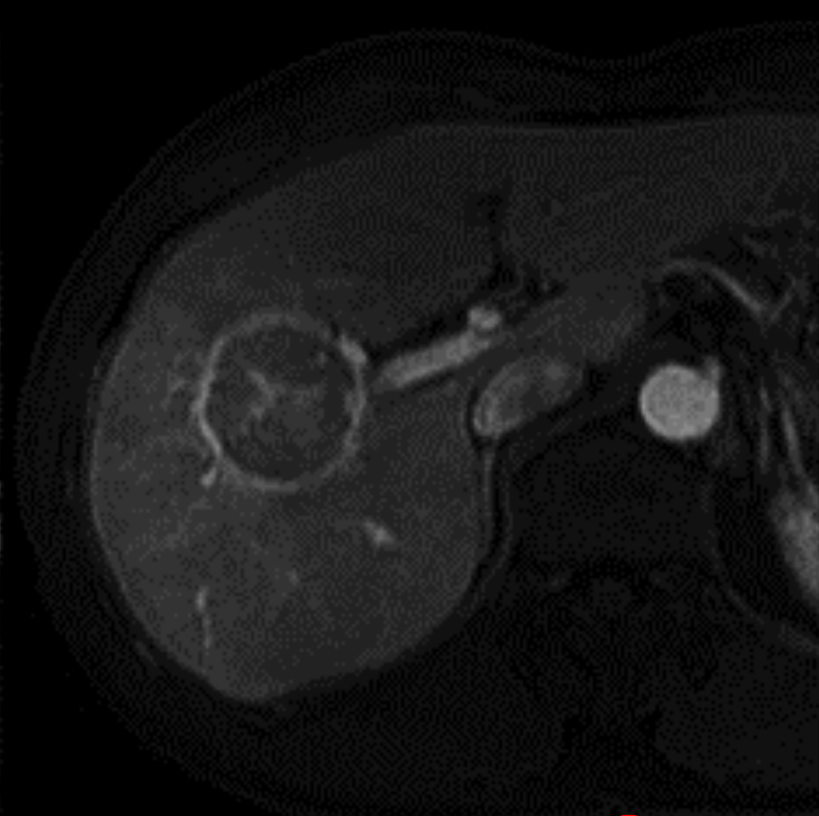


Benign or Malignant ????

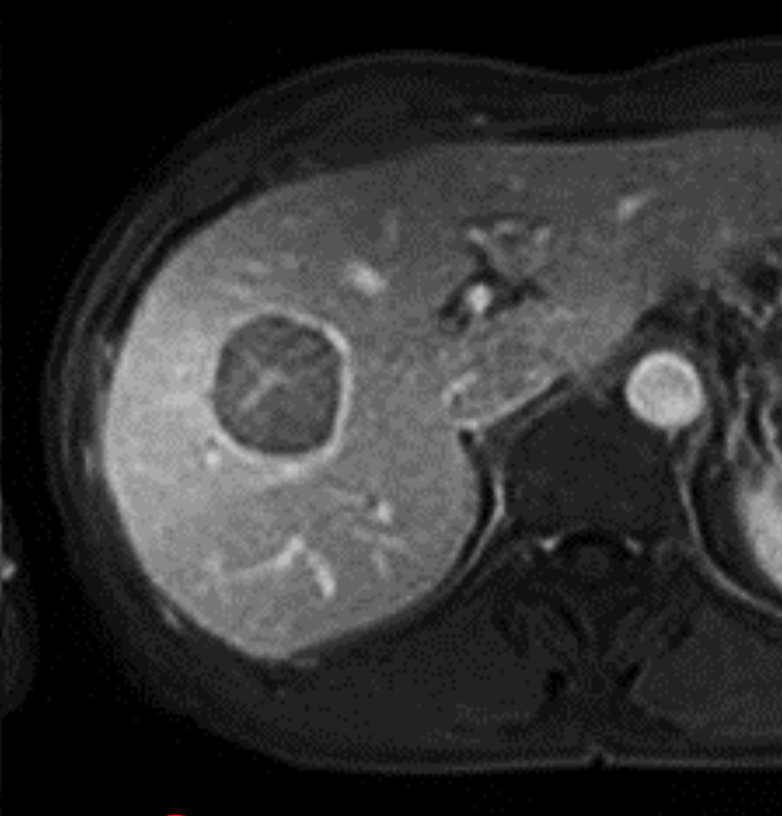
A



B



C

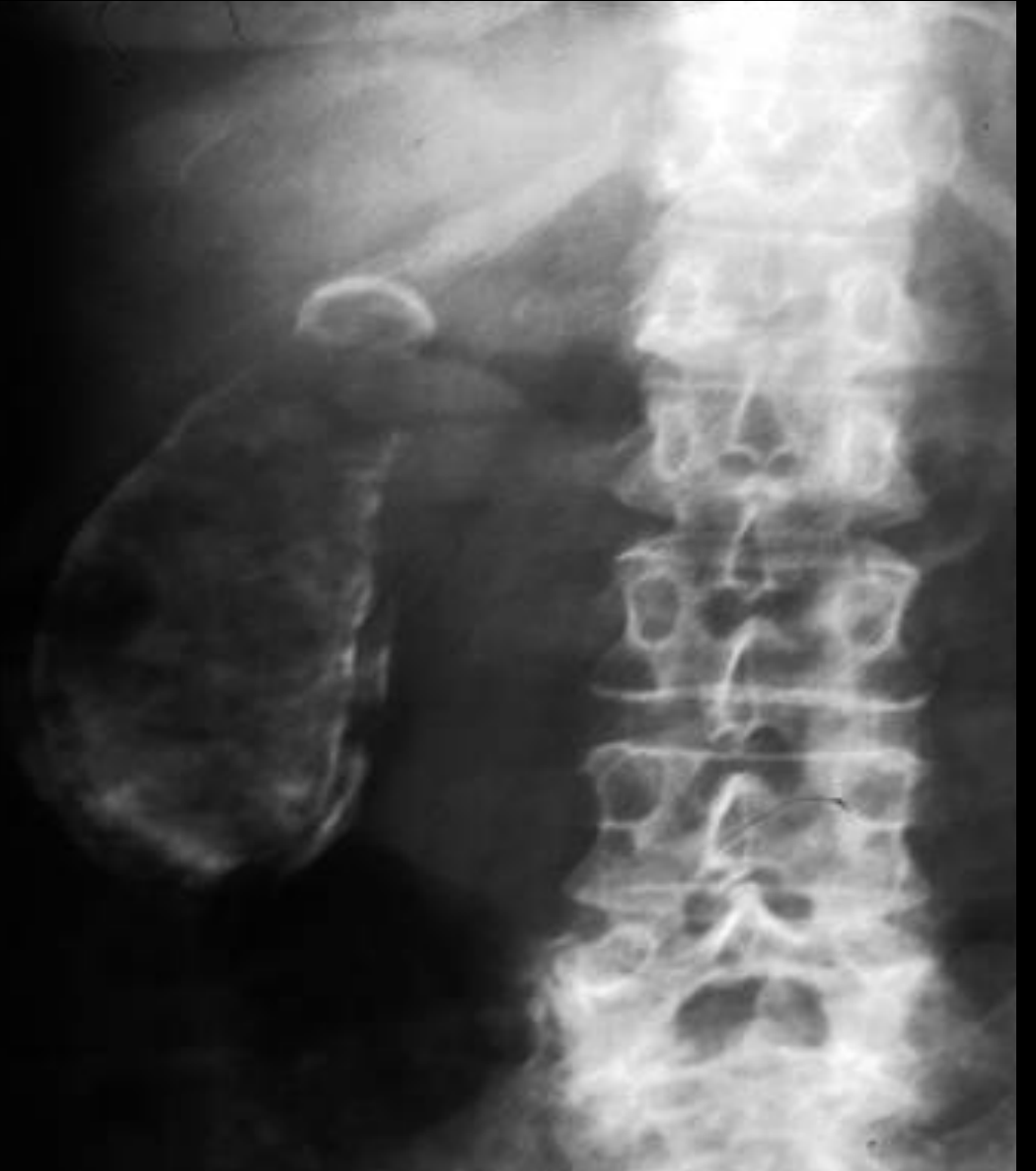

Malignant (HCC)

Case 4

Male patient with chorionic abdomen pain.

- What is abnormal?
- How to confirm the diagnosis?

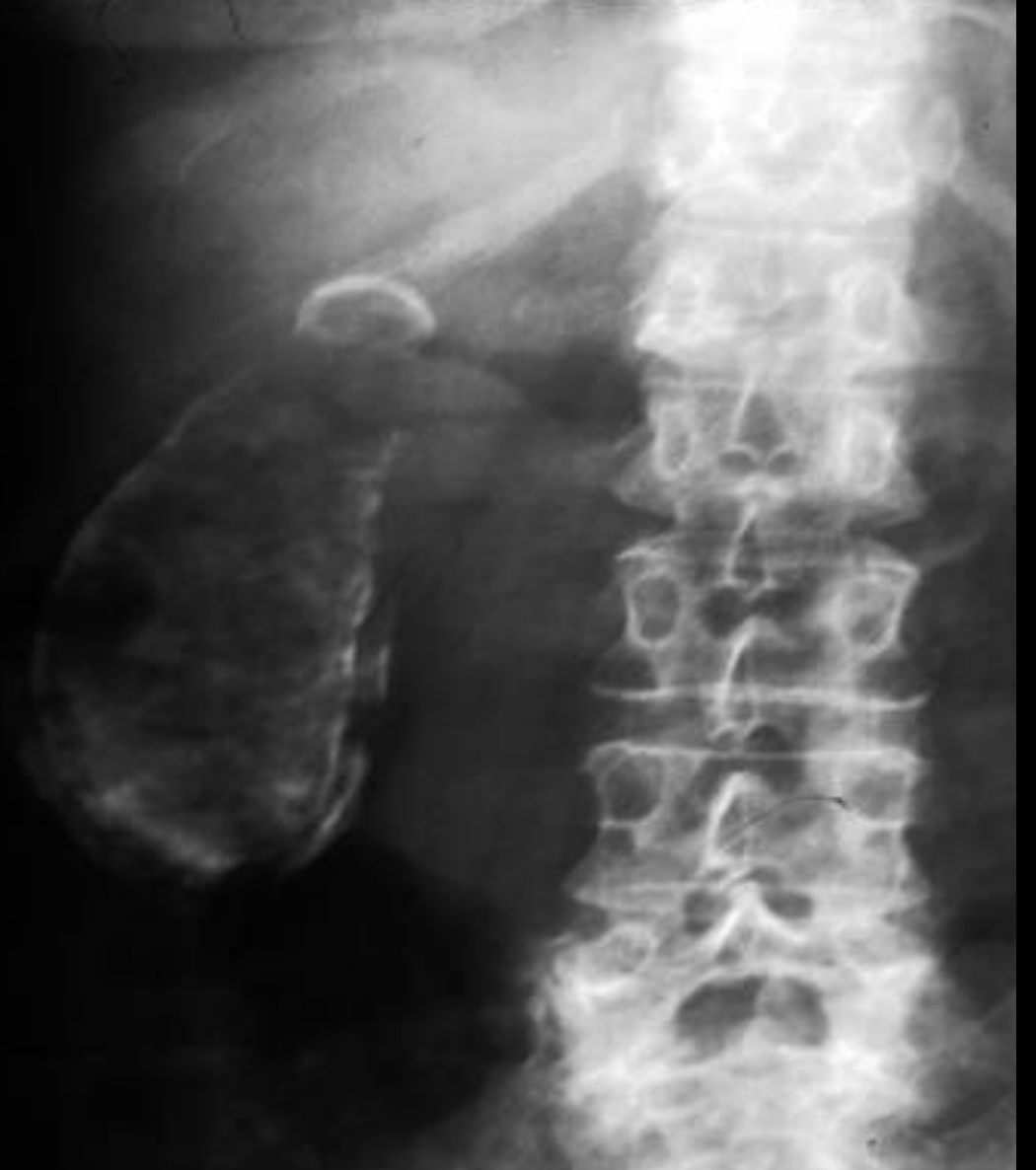

Gallbladder calcification:

- Porcelain gallbladder (calcification in GB wall).
- Gallbladder stones (NOT common to see on X-ray).

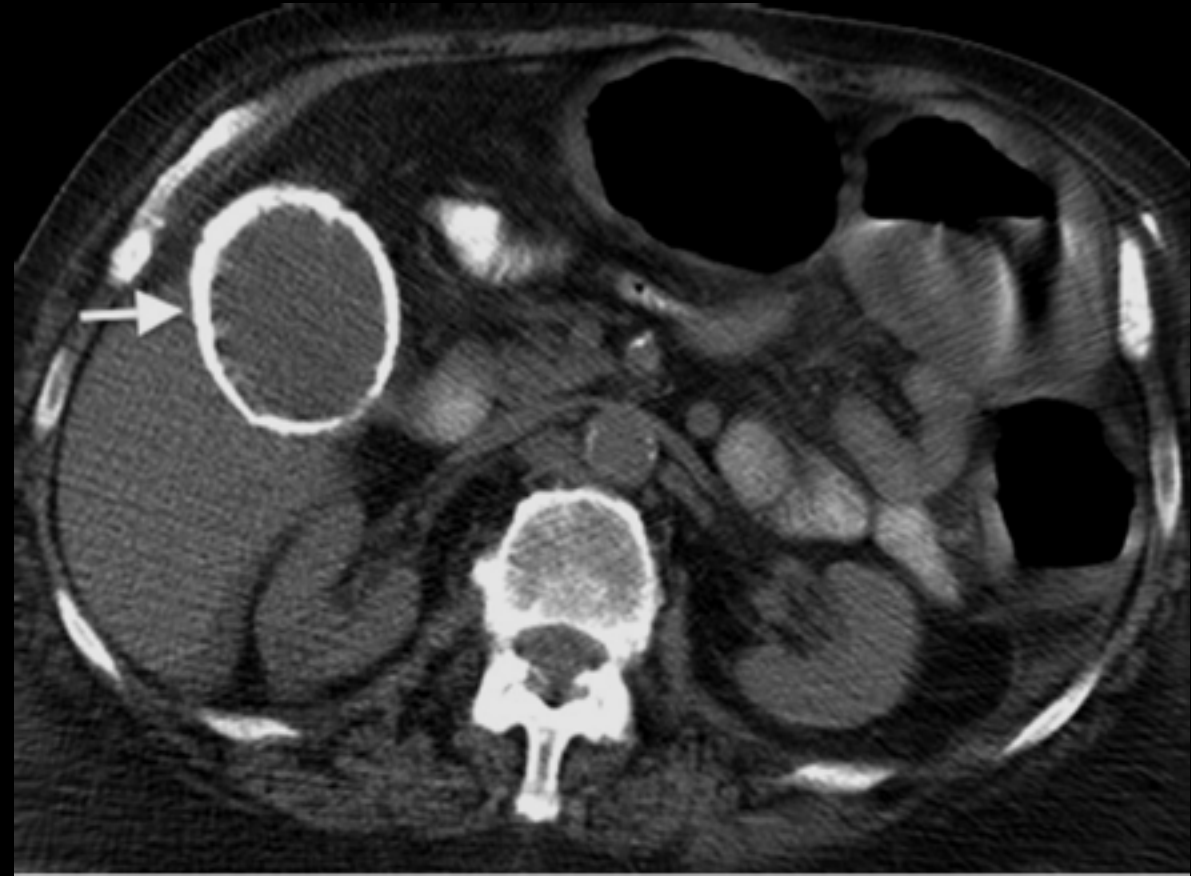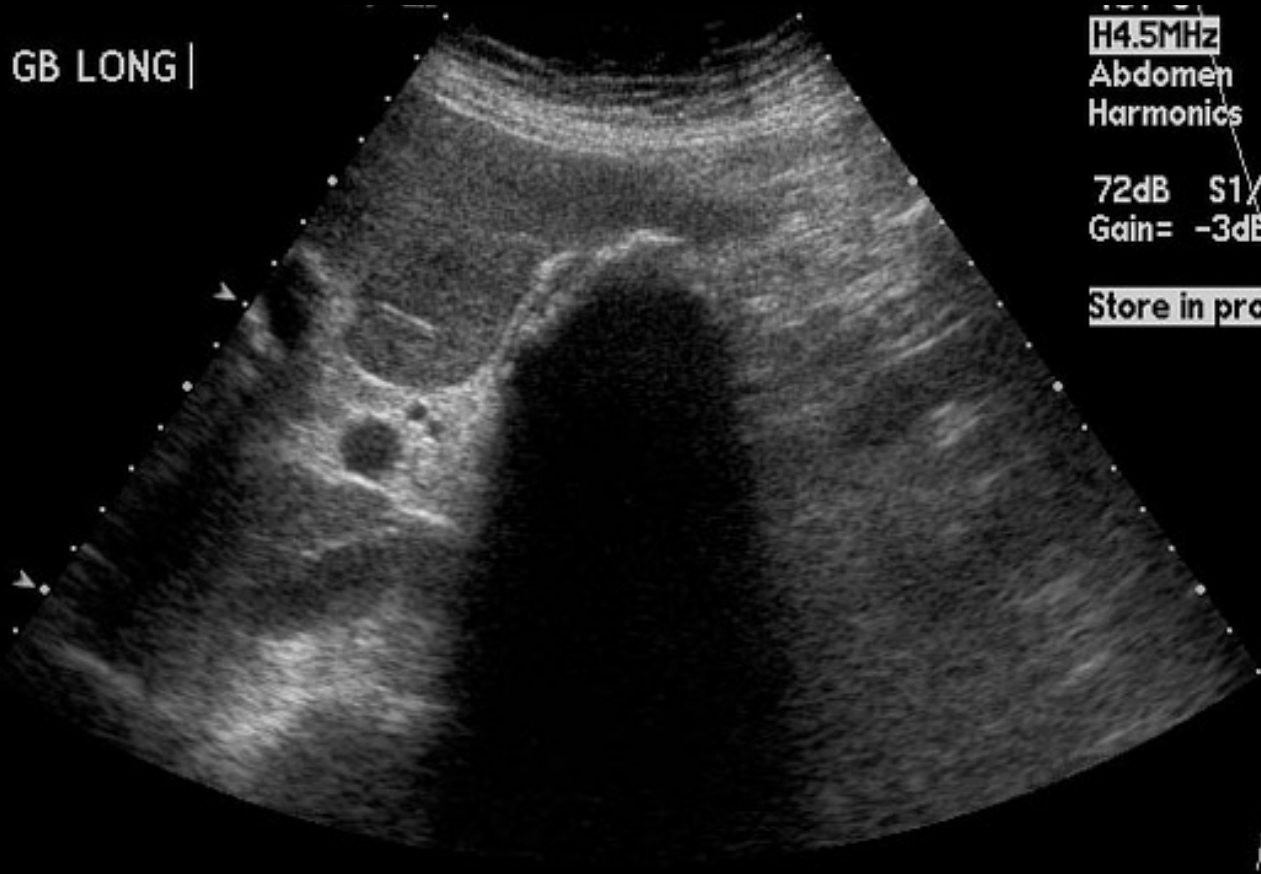
How to confirm ?

CT scan or US ?



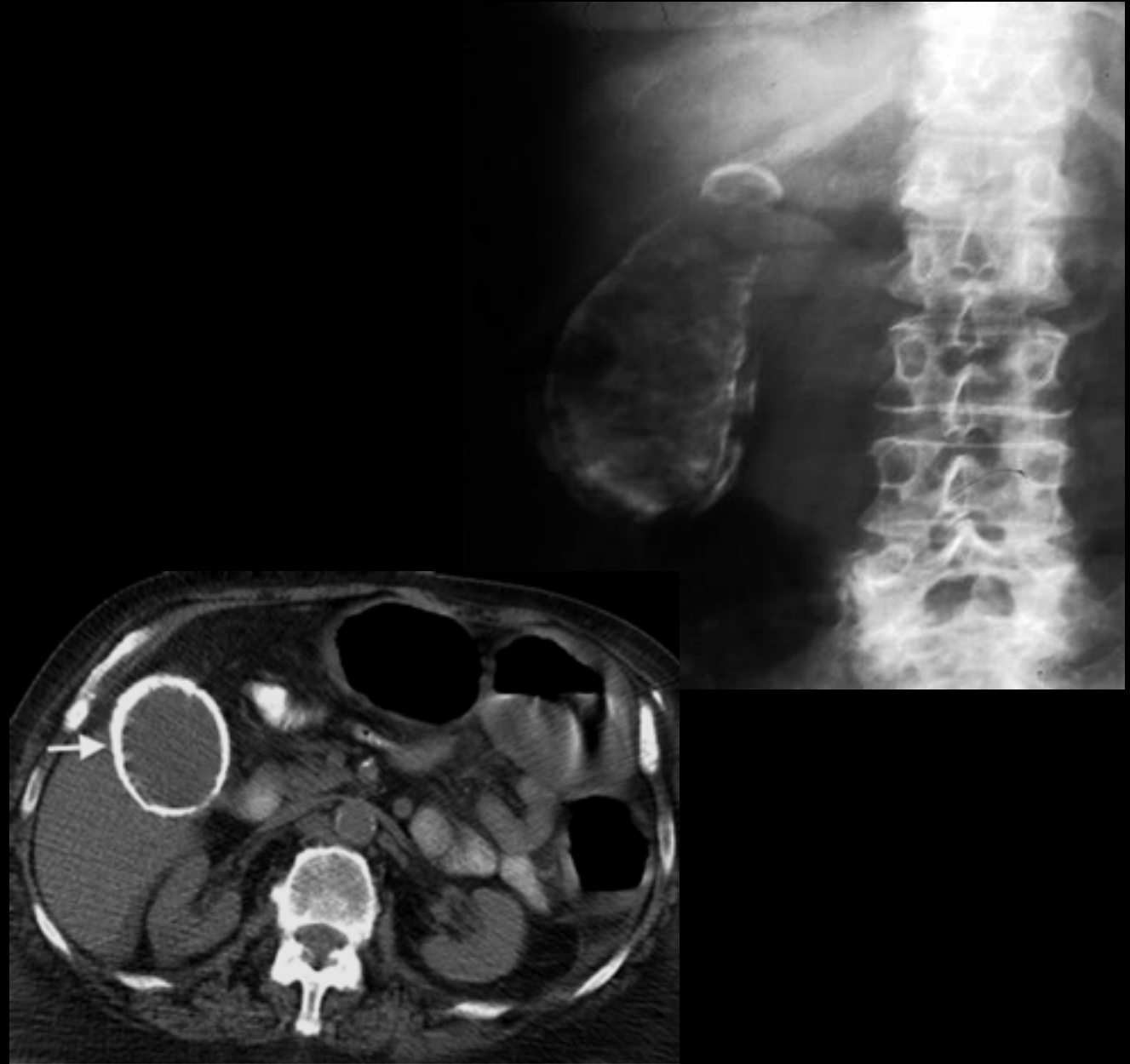
Which modality is better?

GB LONG |



Porcelain GB:

- Complete or partial GB wall Ca+.
- Risk of developing cancer 5 - 7%.
- Needs follow every year or surgical resection.



Case 5

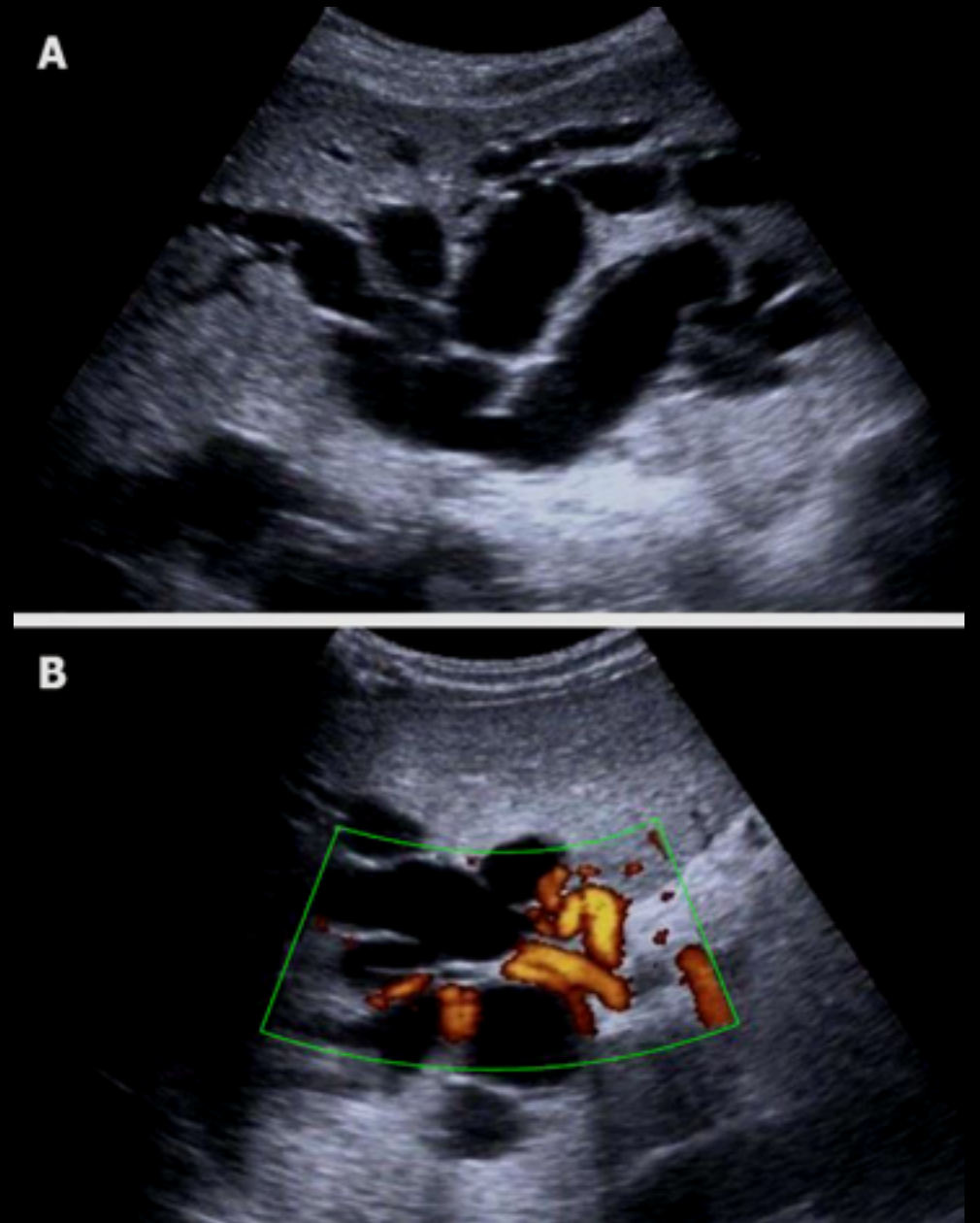
50 year-old lady presenting to emergency with **RUQ pain** and **yellow** discoloration of **sclera**, **pale stool** and **dark urine**.

- What is the most likely diagnosis?
- Which radiology modality you prefer to start with ?

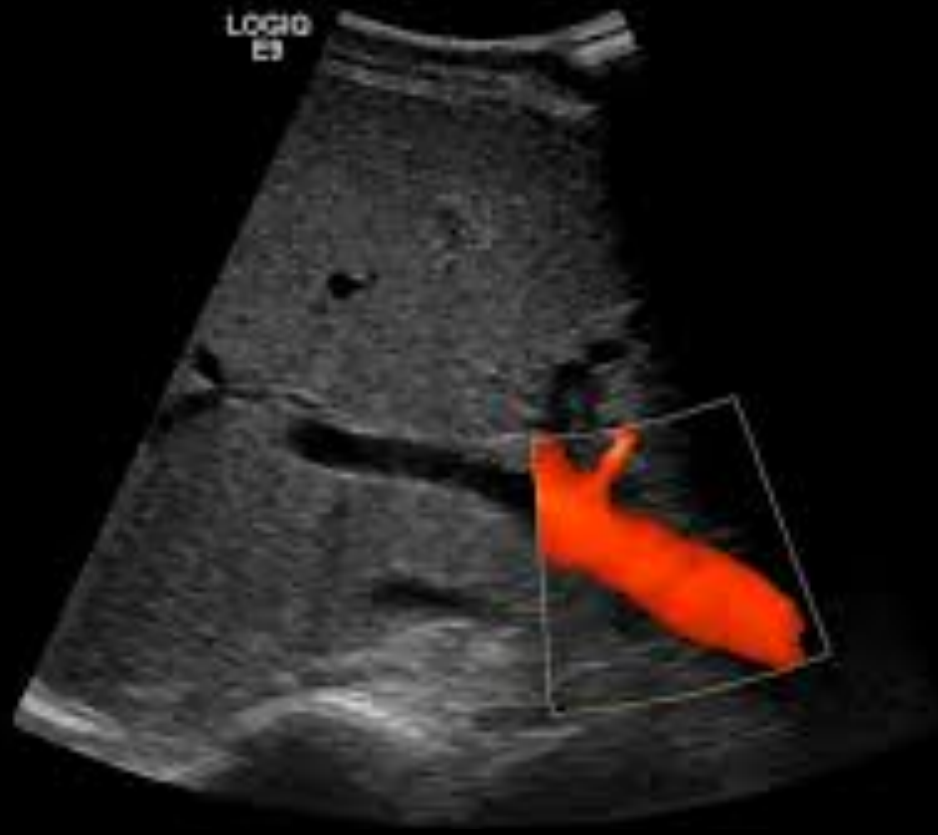Here is US you asked for.....

What do you think ??????

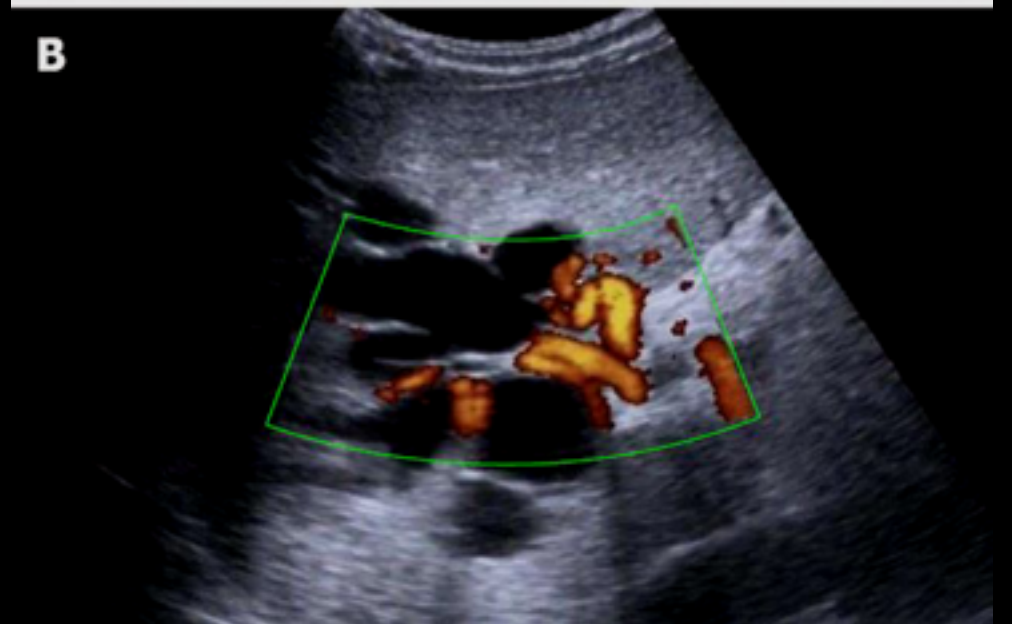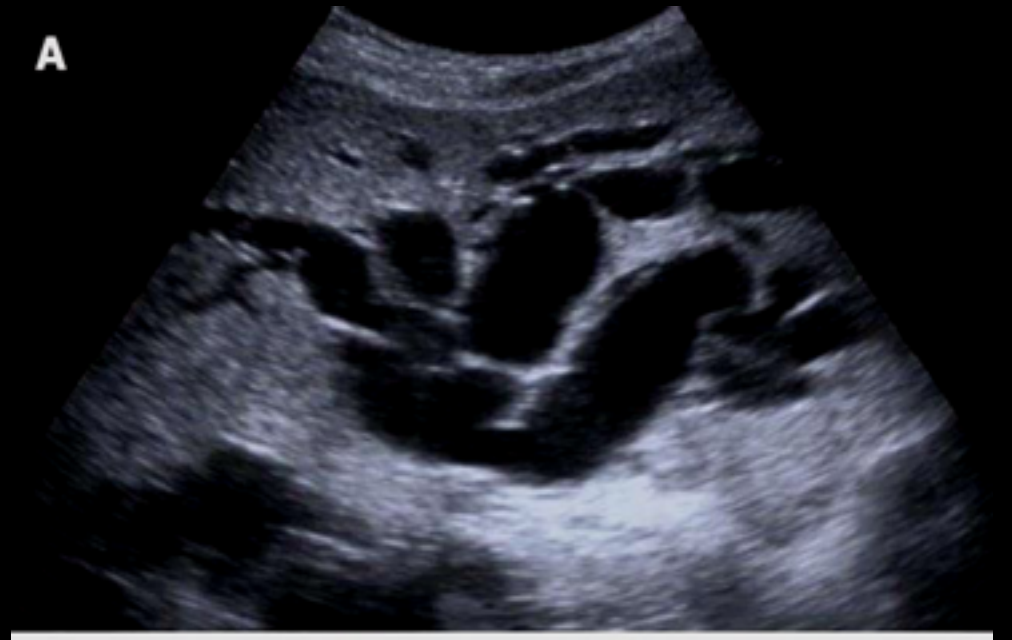Is it **normal** or **abnormal** ????



Here is US you asked for.....



Normal US



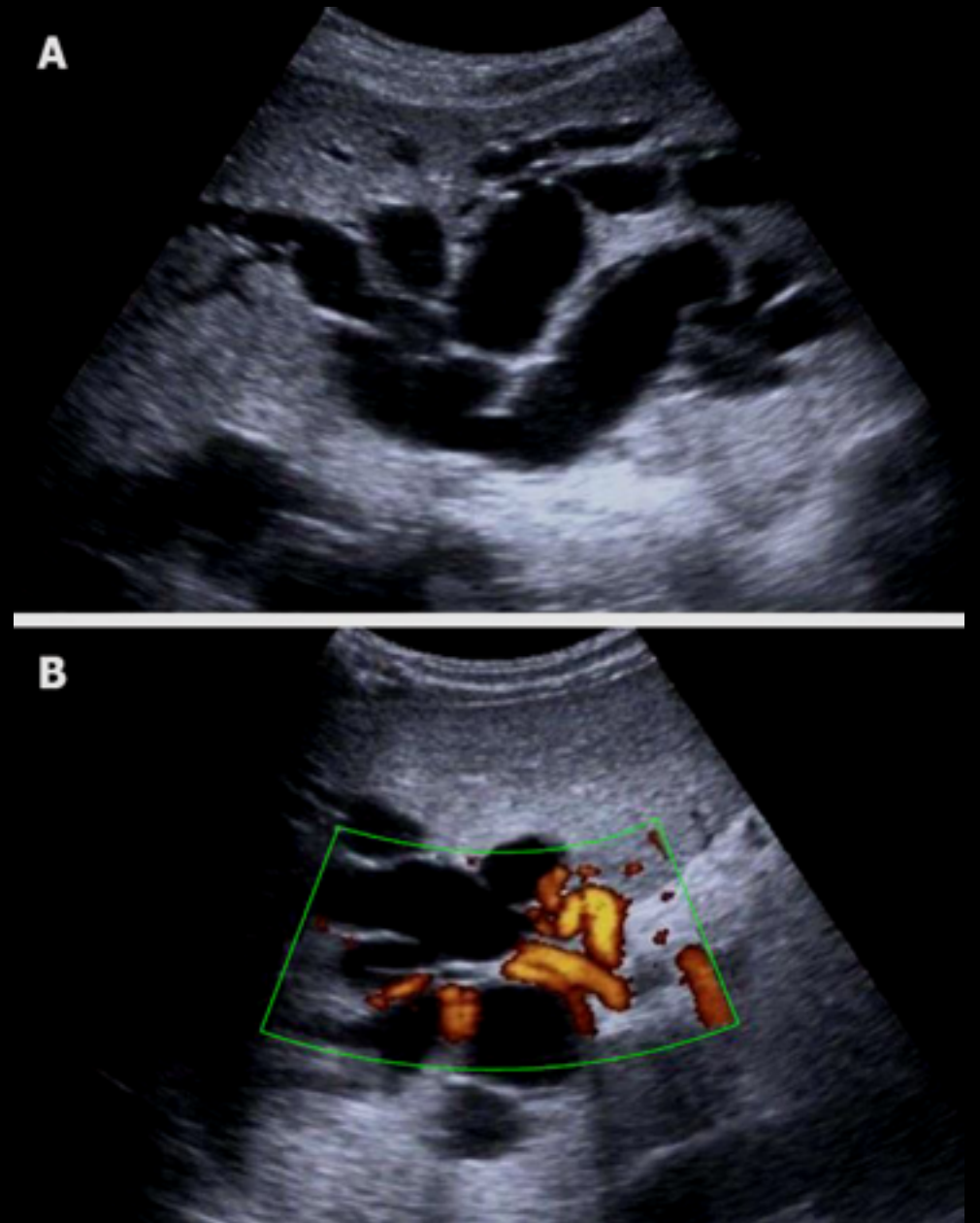
Abnormal US

Here is US you asked for.....

Sever intra hepatic **bile duct dilatation**

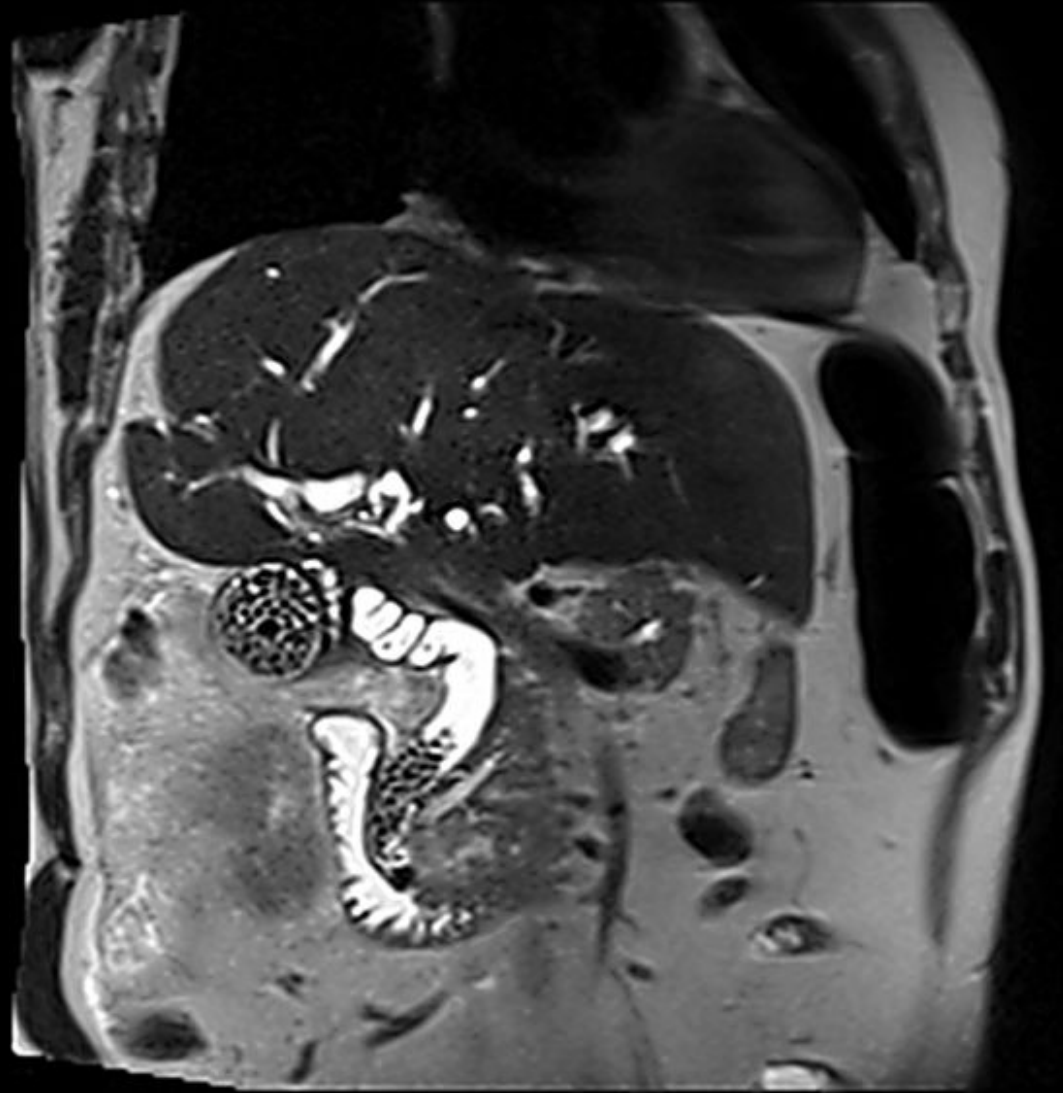
Can you tell the cause from this US???

What to do next?????



MRI

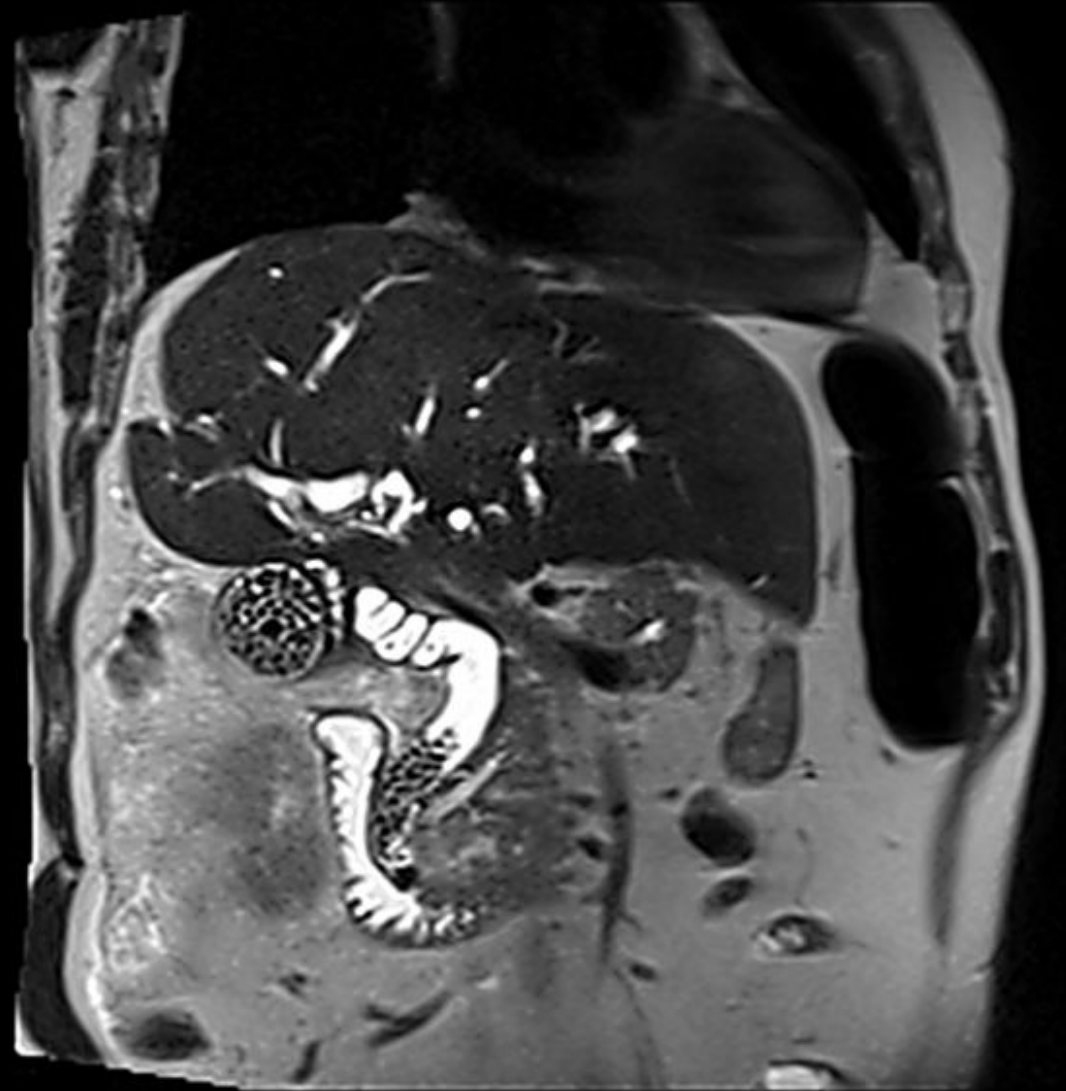What is abnormal?



MRI

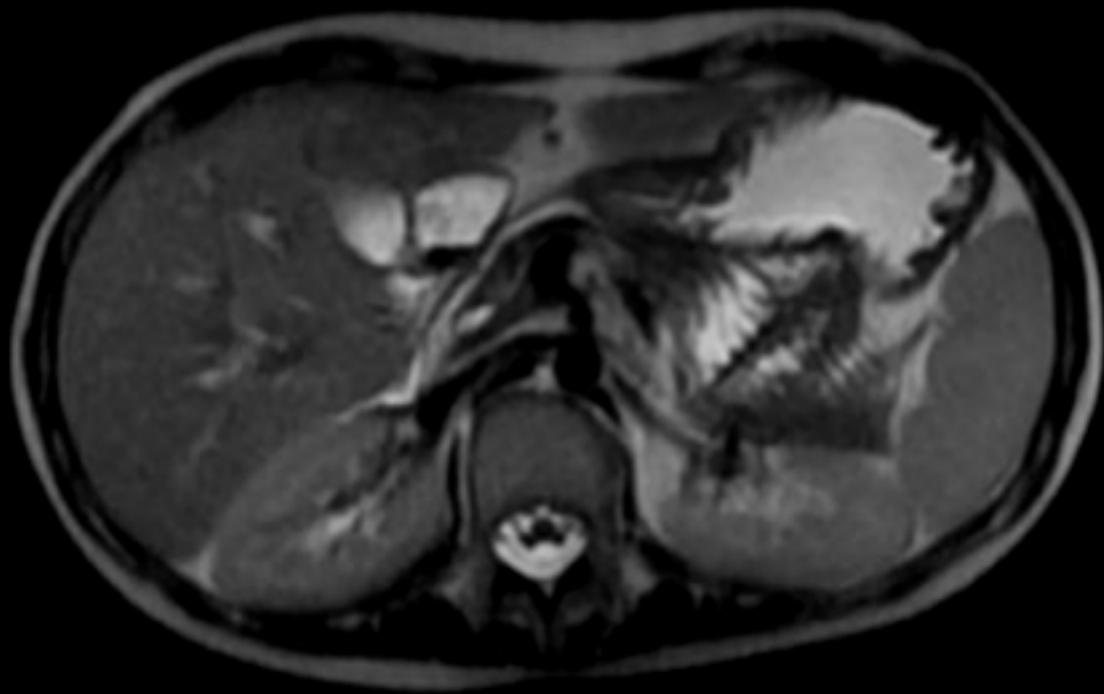
What is abnormal?

Multiple **gallstones** in GB
and common bile duct
(**CBD**).

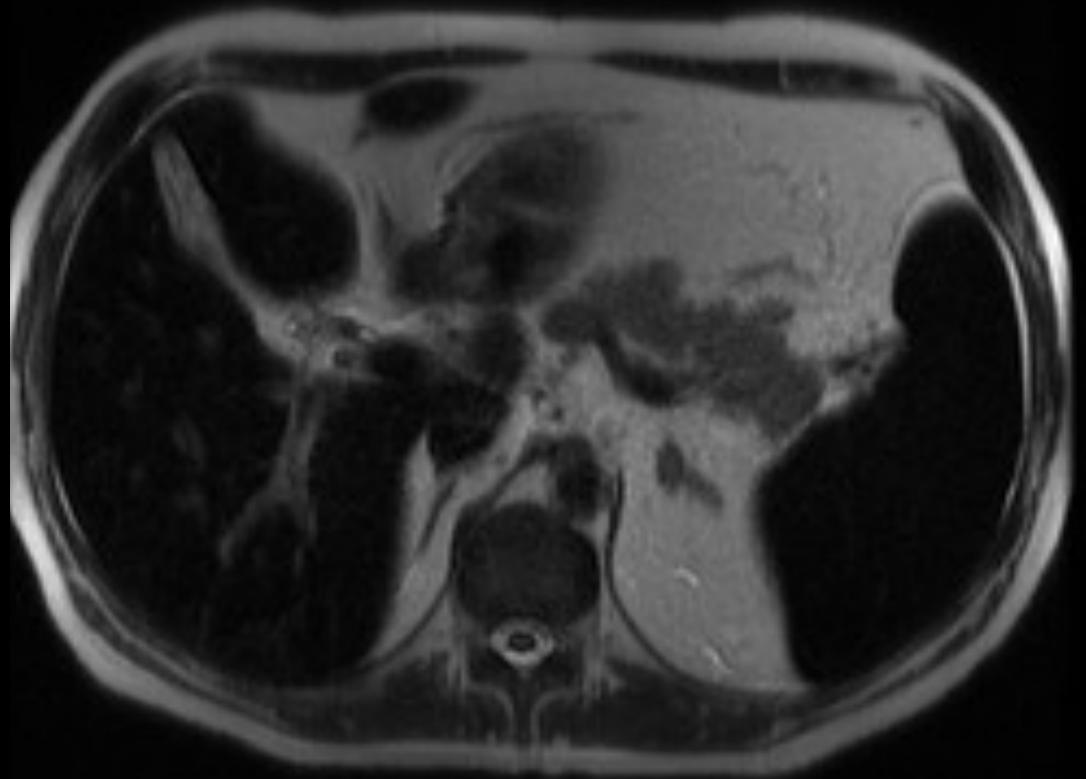


Case 6

20 year-old case of Thalassemia with repeated blood transfusion



Normal MRI (for reference)



What is abnormal here???

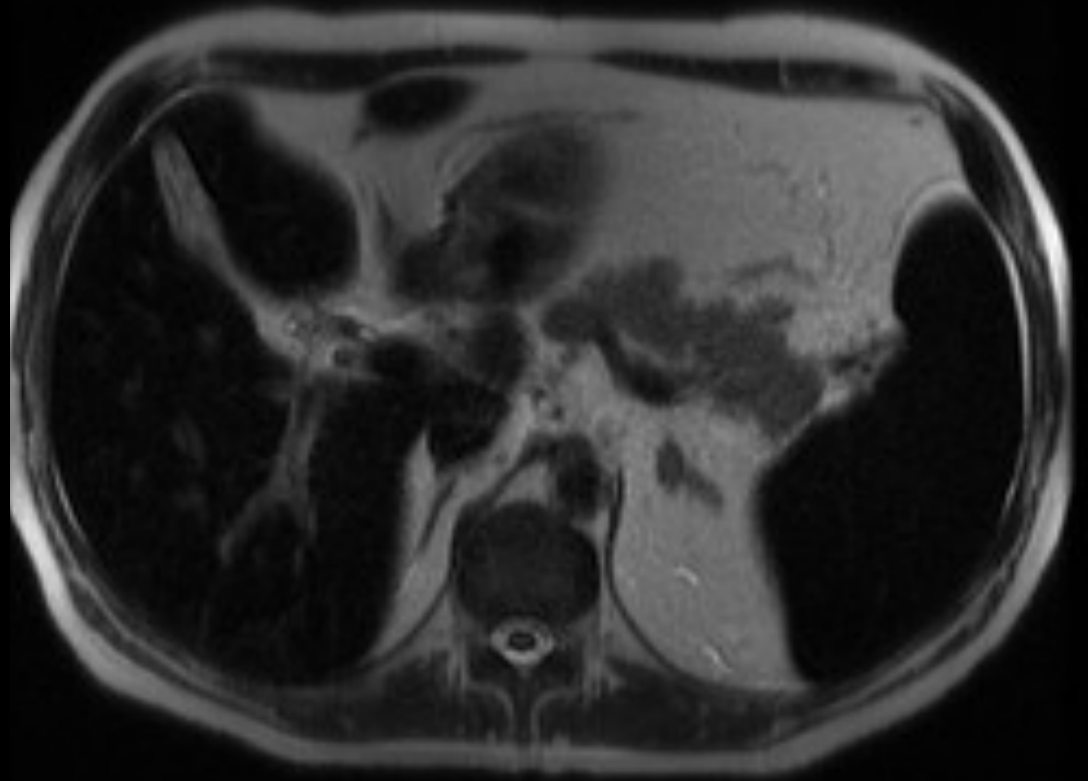
20 year-old case of Thalassemia with repeated blood transfusion

What is abnormal here???

The liver and spleen of dark in signal (**hypo intense**)

Because of iron overload, repeated blood transfusion.

MRI is the modality of choice to assess and quantify iron in solid organs.



Case 7

Patient with RUQ pain suspecting cholecystitis. US and MRI were not conclusive.

What to do next????

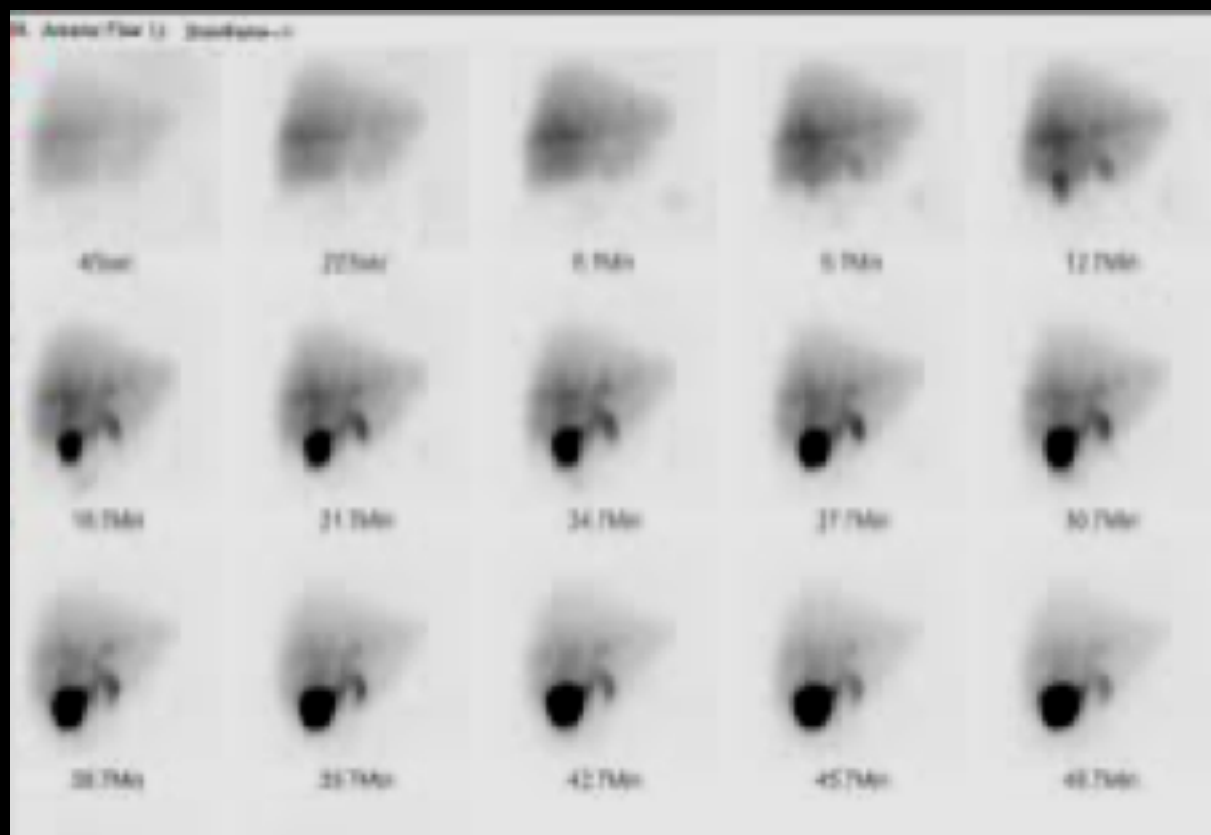
? CT scan ? MRI or ? Nuclear scan.

Patient with RUQ pain suspecting cholecystitis. US and MRI were not conclusive.

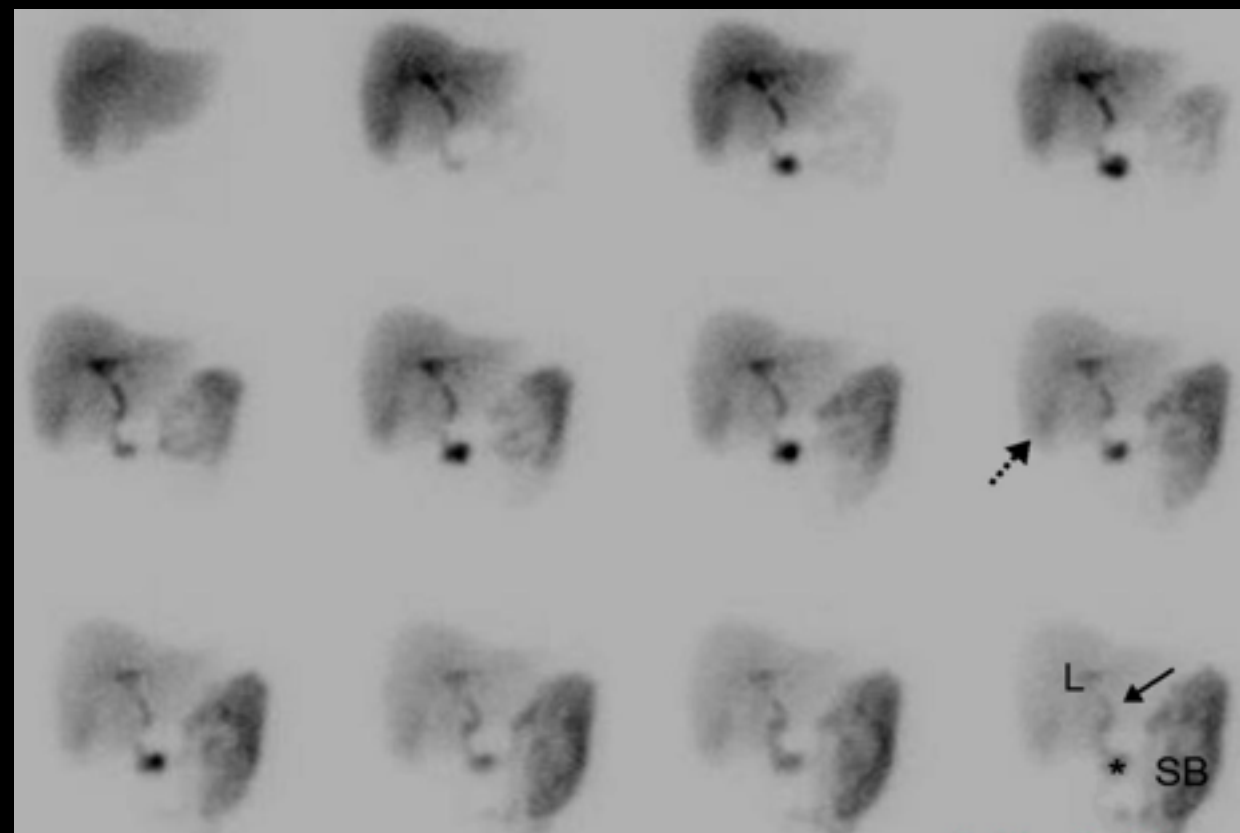
What to do next????

? CT scan ? MRI or ? **Nuclear scan.**

Nuclear scan (HIDA scan)



NORMAL (for reference)



What is abnormal here???

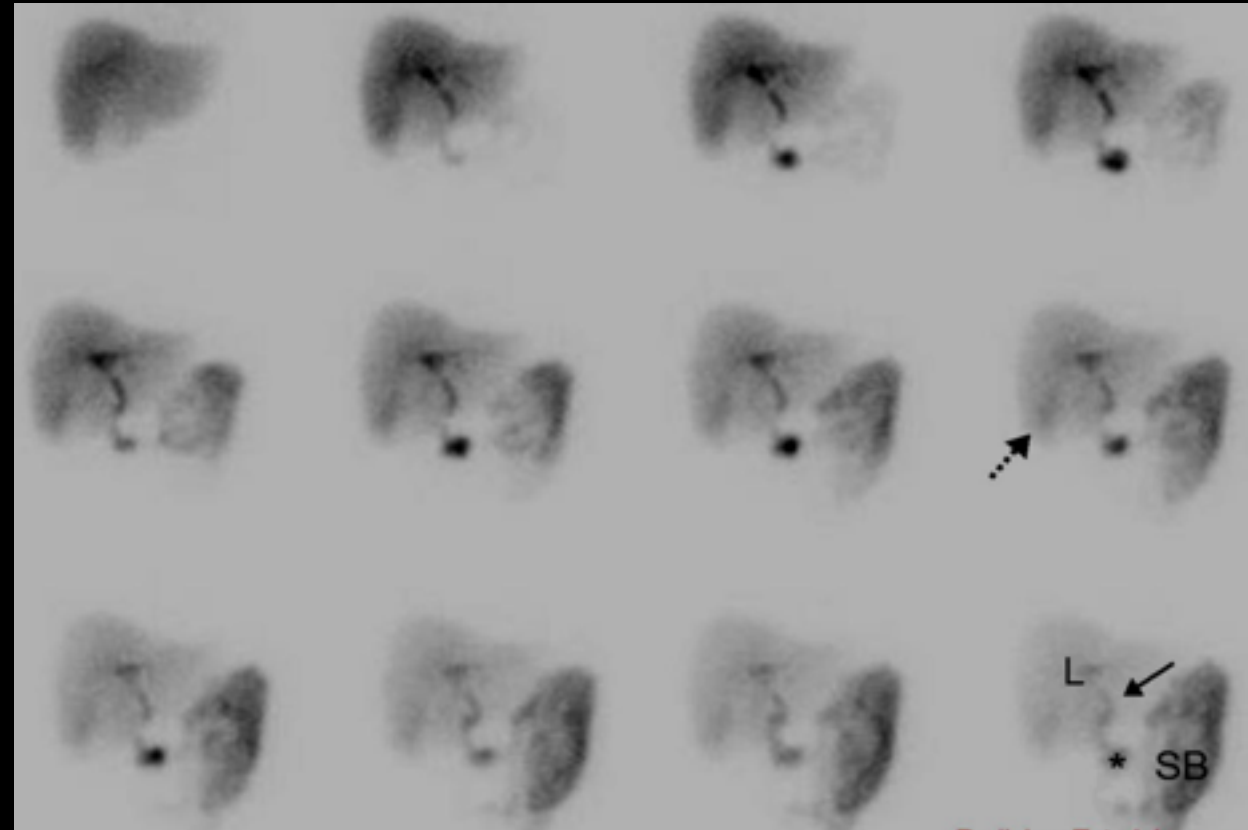
Nuclear scan (HIDA scan)

Acute cholecystitis

No up take in gallbladder

Other indication of HIDA scan:

- Biliary atresia (children)
- Bile injury post surgery.
- Bile obstruction.



What is abnormal here???

The End