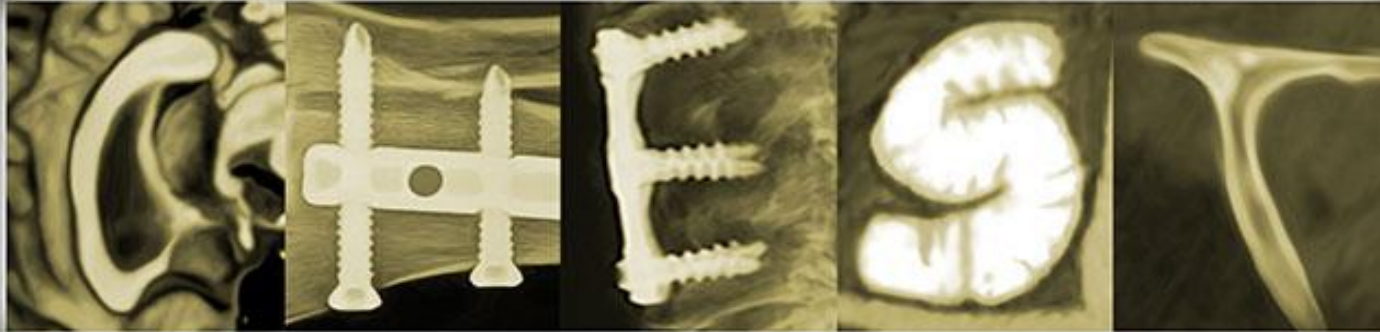

Dr Majid Al-Homiedan
Head Cardiothoracic Imaging division
ER/Trauma, Cardiothoracic and abdominal subspecialty consultant
King Saud University Medical City

Lecture outline

1. Chest X-ray interpretation skills
2. Common Chest X-ray cases

Objectives

I. Technique

- Learn the difference between PA vs. AP CXR
- Learn the utility of a lateral decubitus CXR
- Understand the terms inspiration, penetration, and rotation as they apply to determining a technically adequate film

II. Anatomy

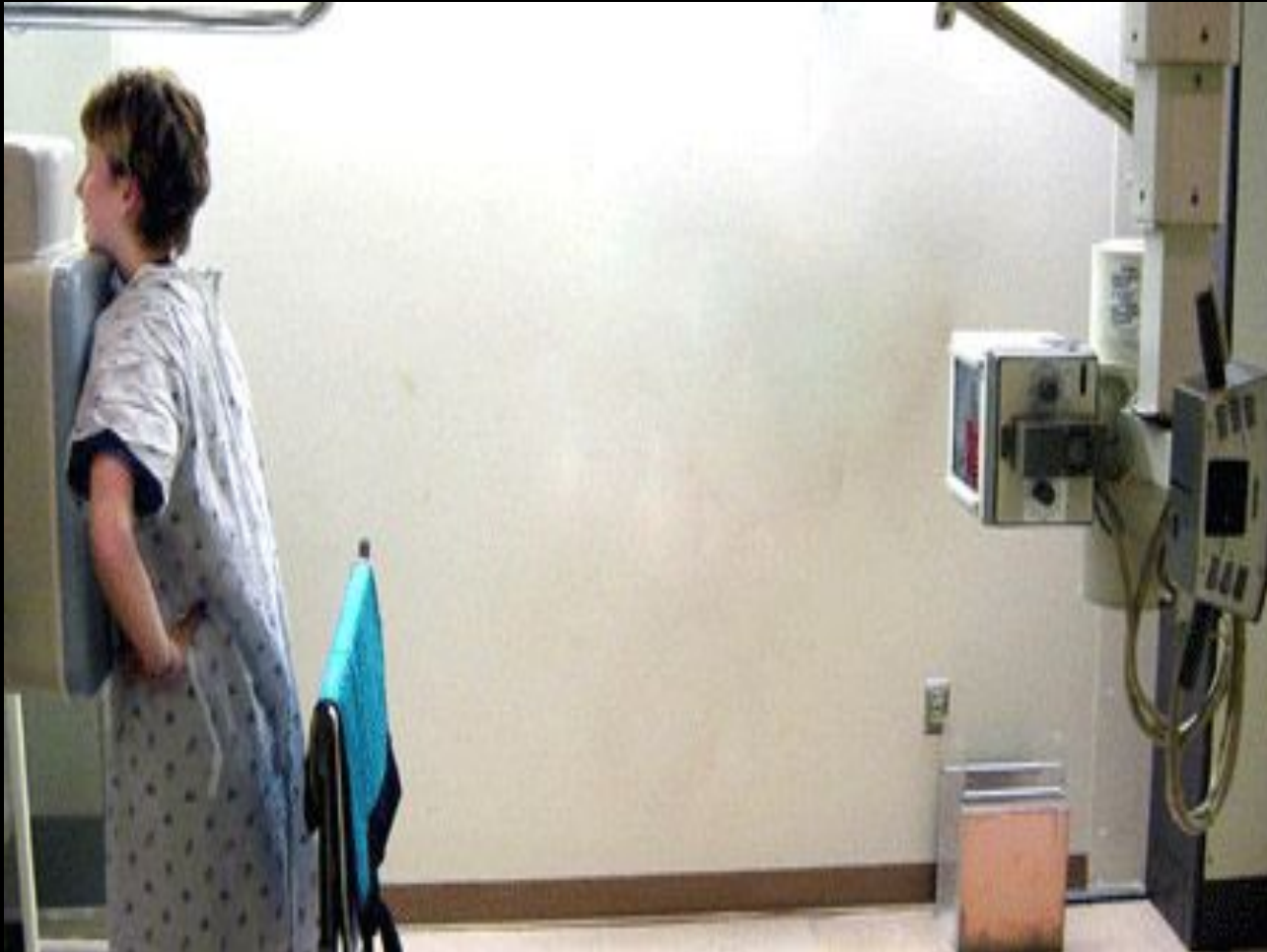- Learn the basic anatomy of the fissures of the lungs, heart borders, bronchi, and vasculature that can be seen on a chest x-ray

III. Interpretation

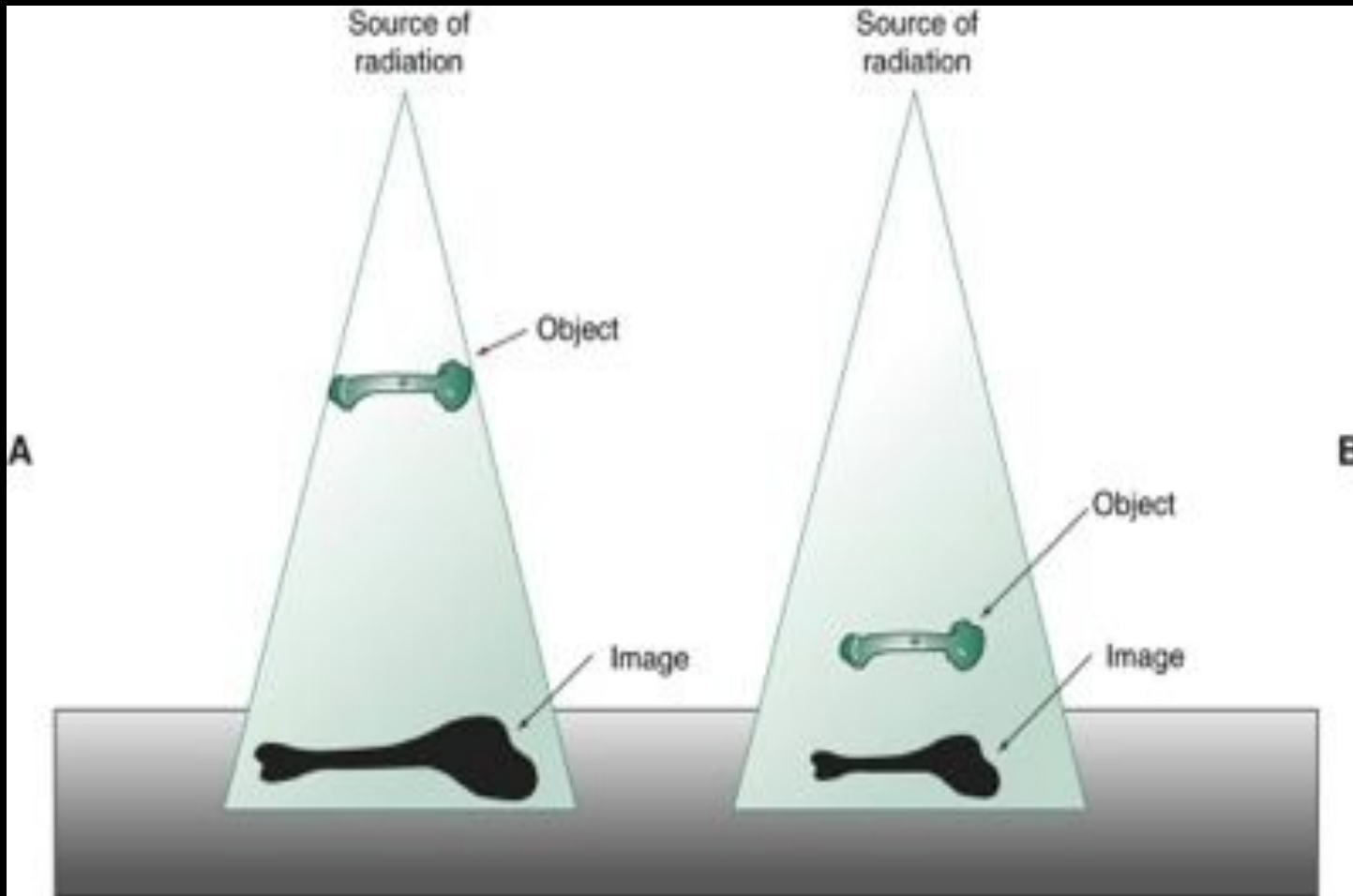
- Develop a consistent and thorough technique for reading images
- Learn how the silhouette sign can help localize pathology

IV. Pathology

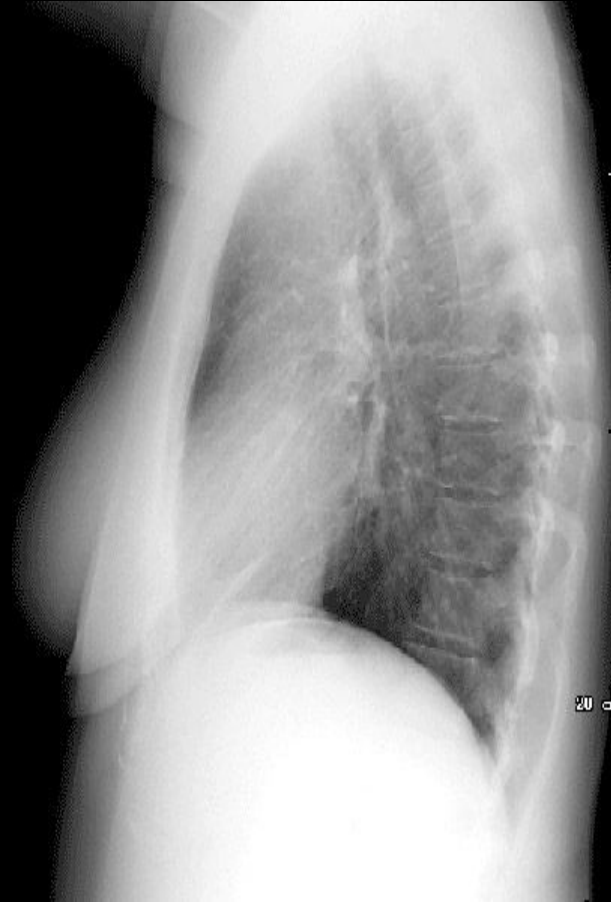
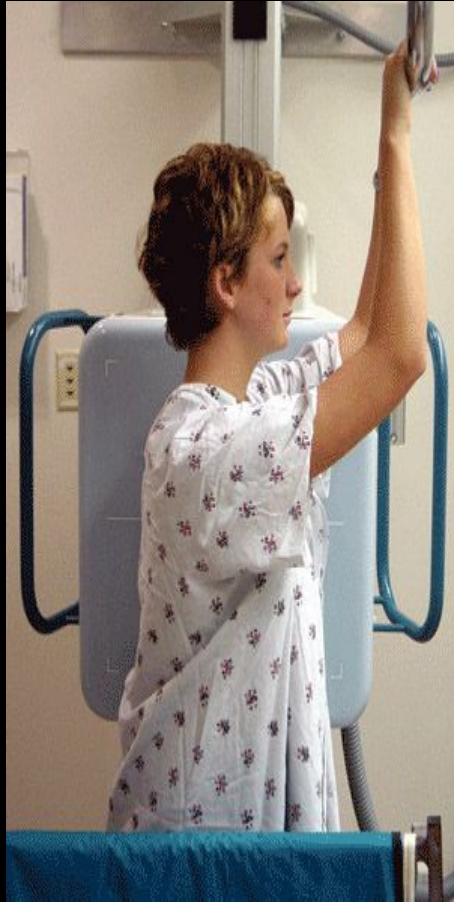Positioning PA



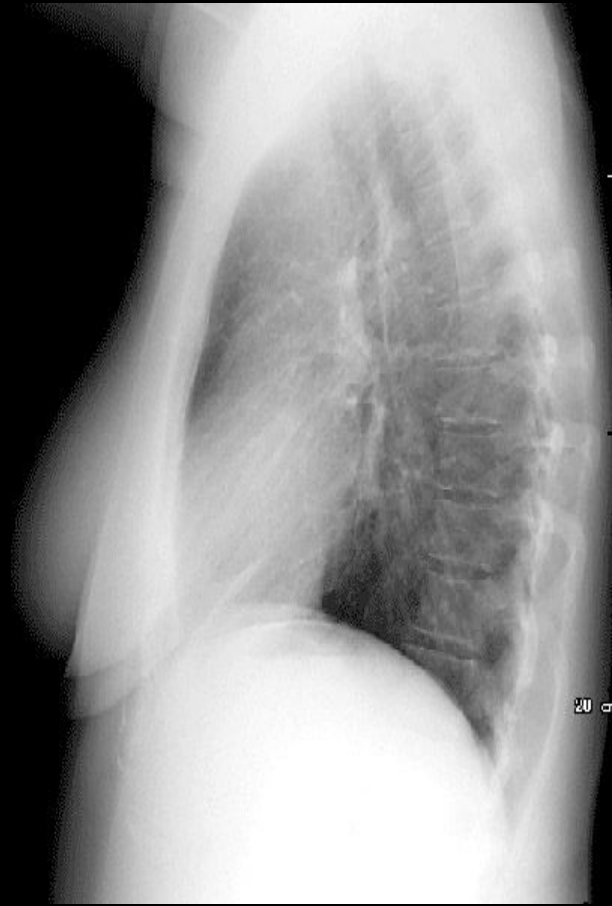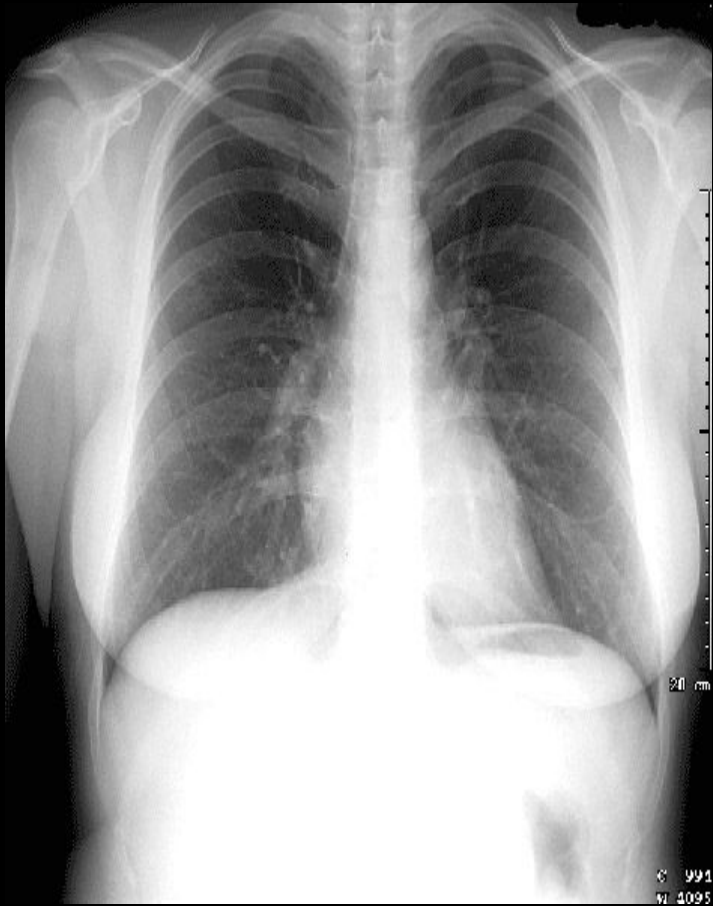Positioning PA



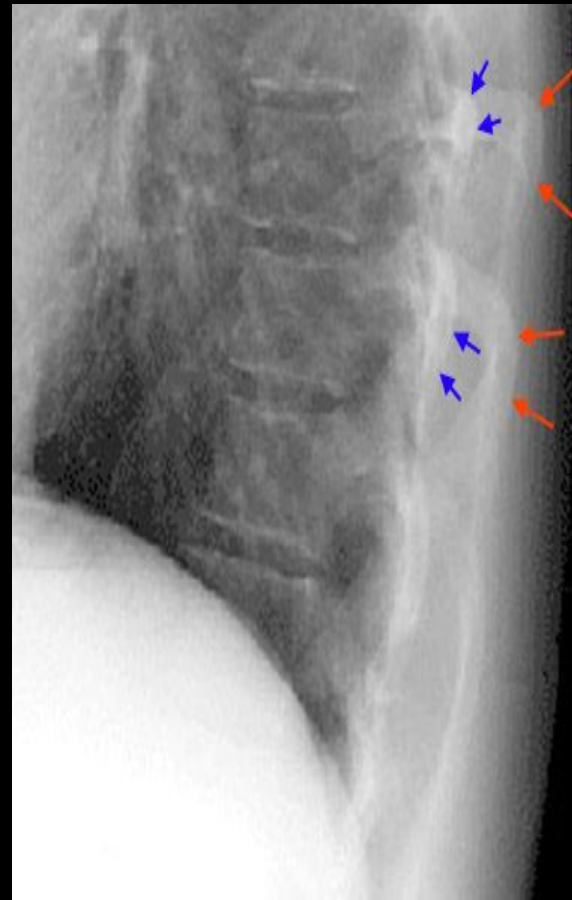
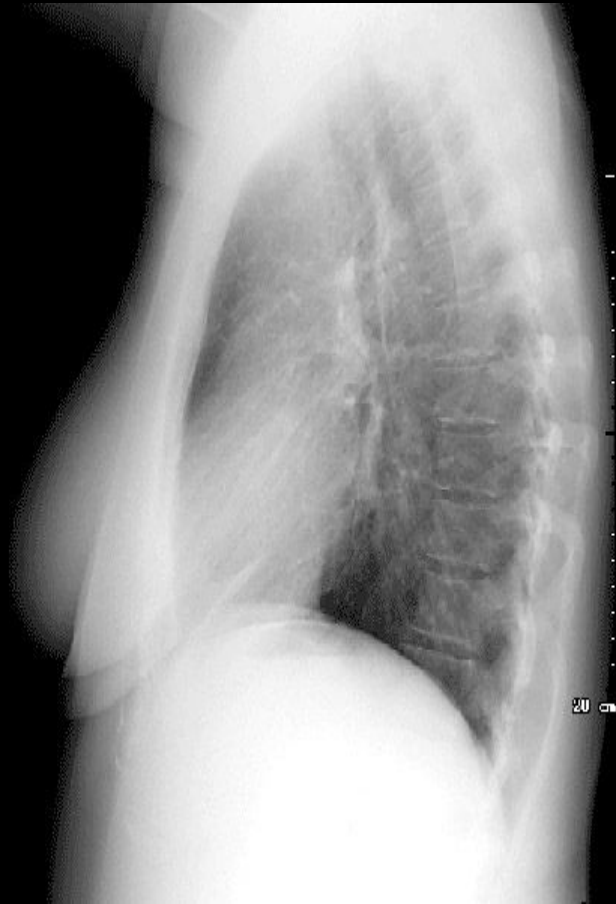Positioning lateral

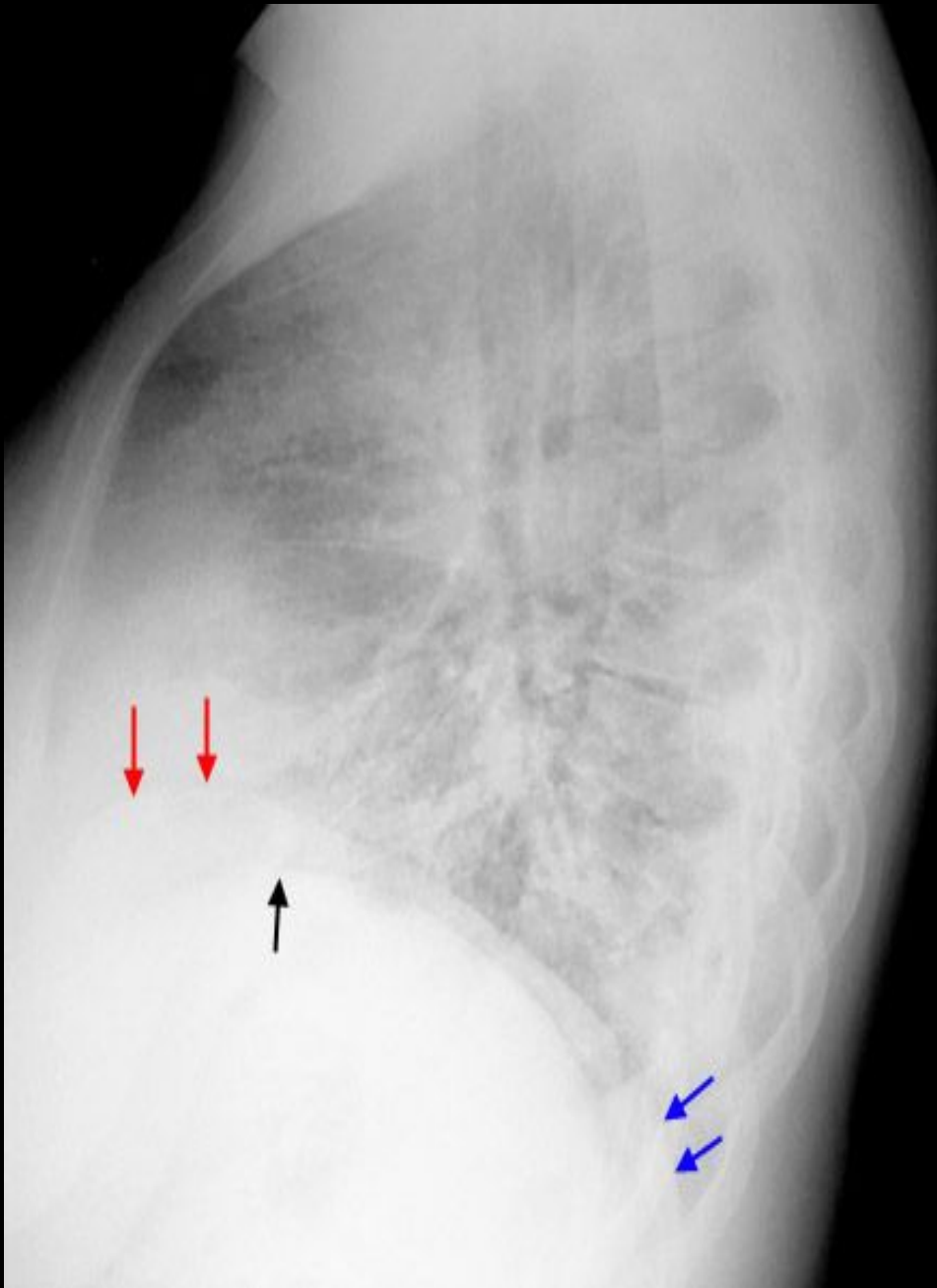


Always read together

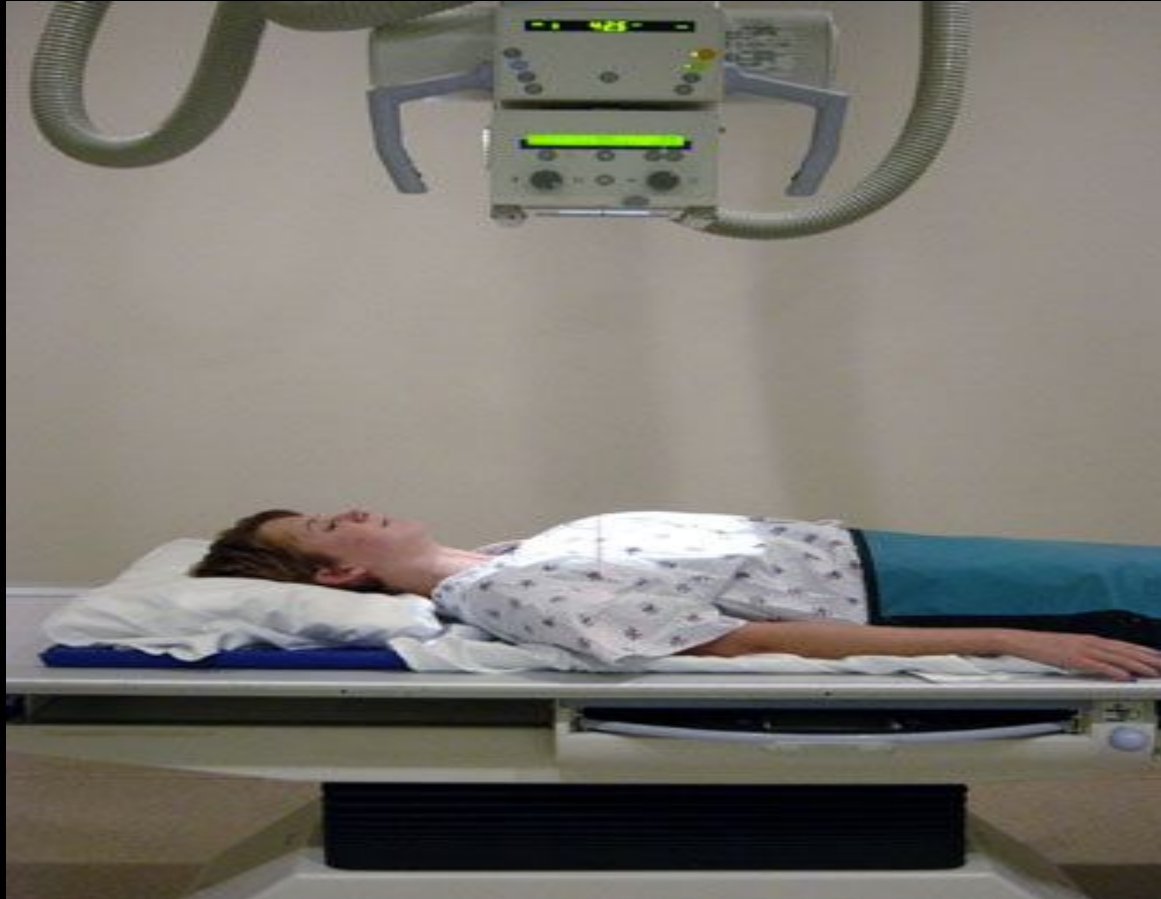

Positioning





Positioning AP

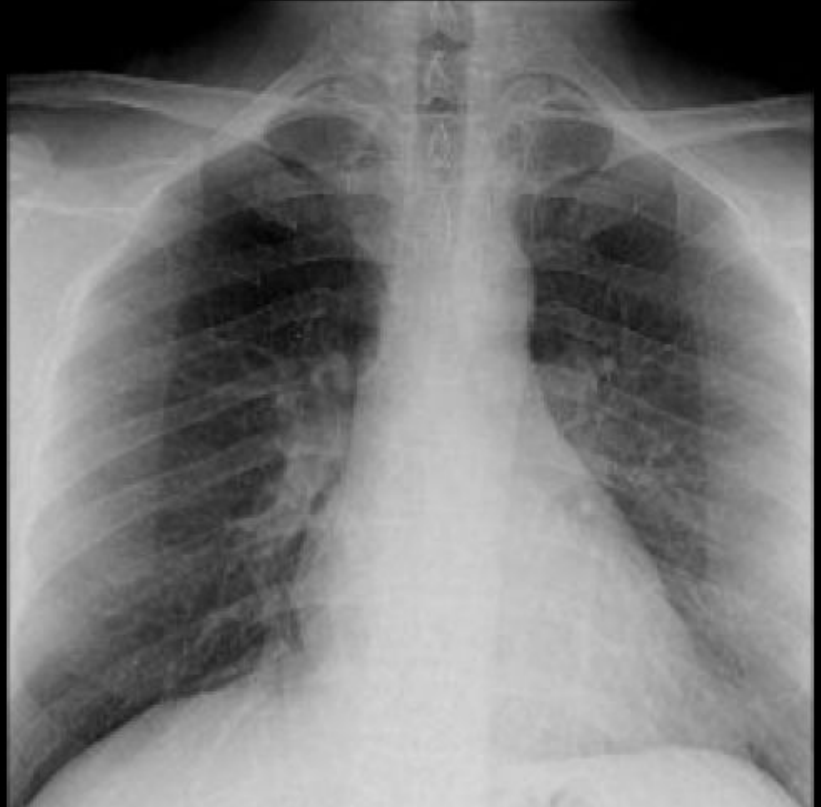
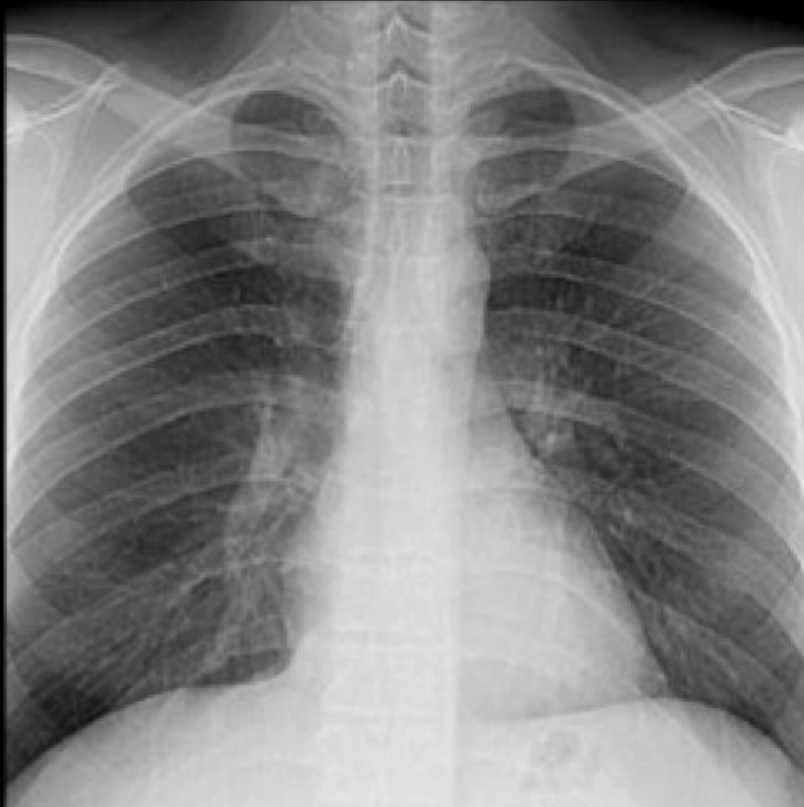
Positioning

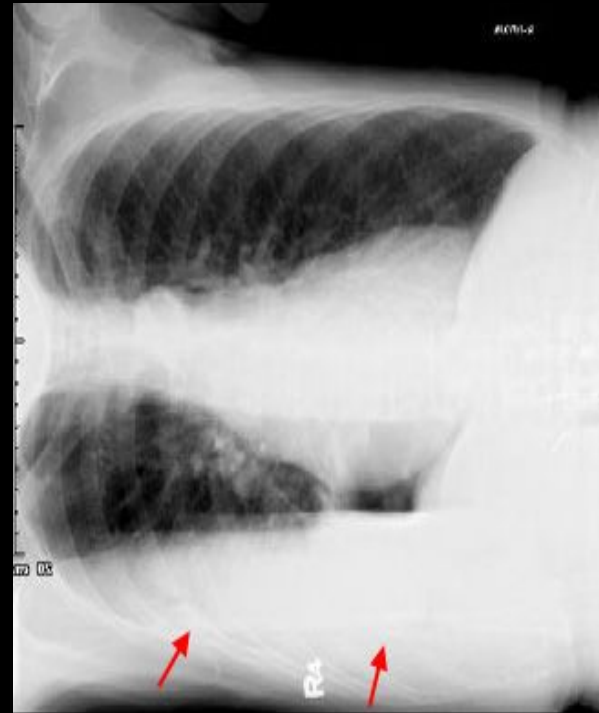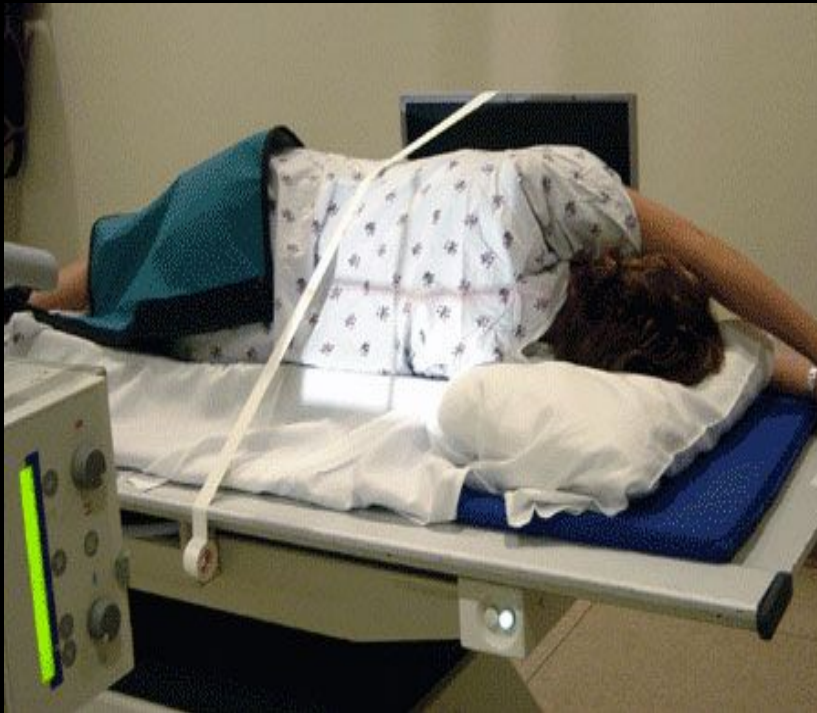PA

vs

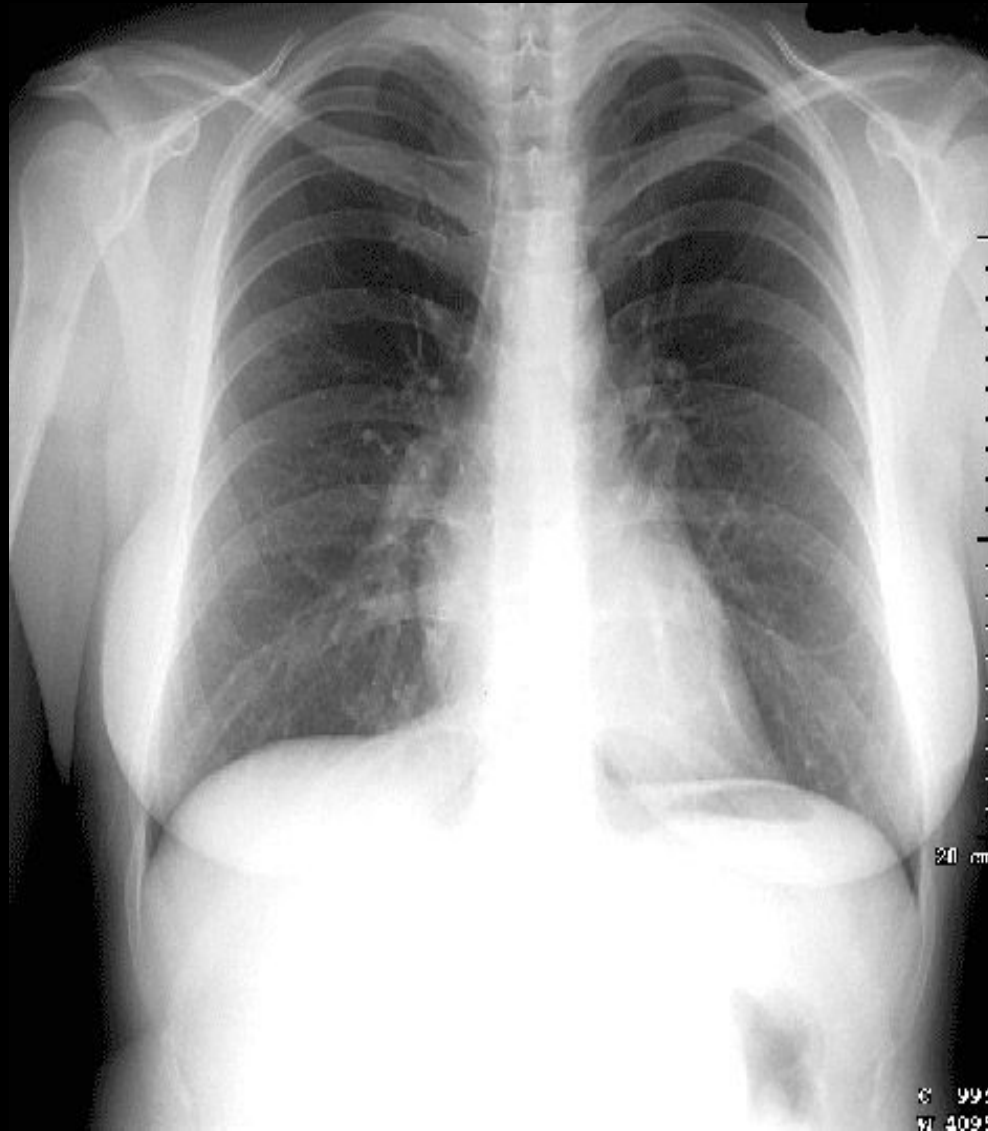
AP



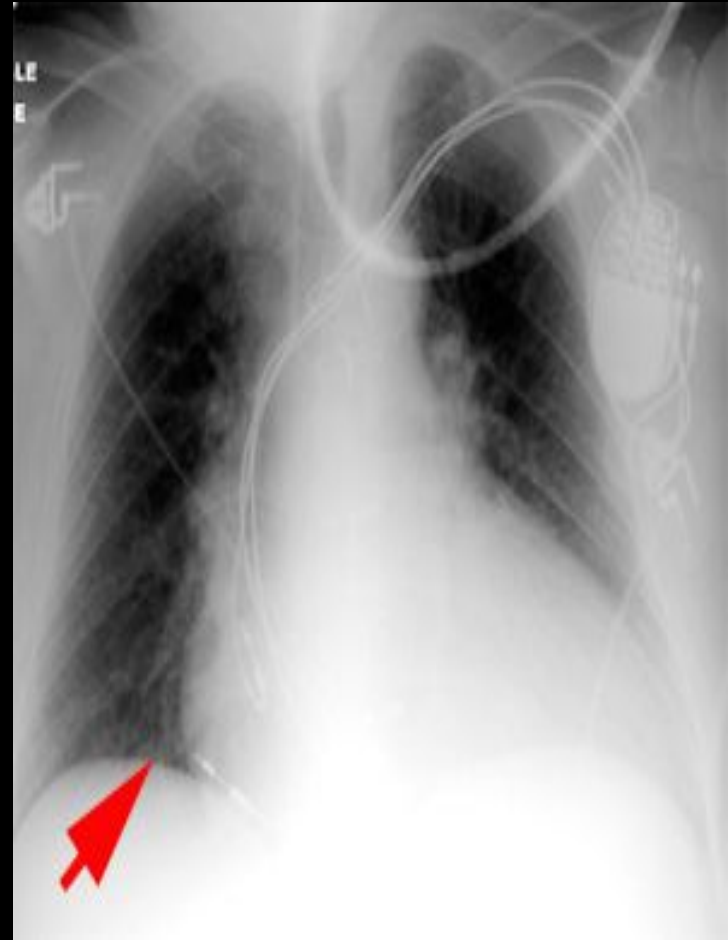
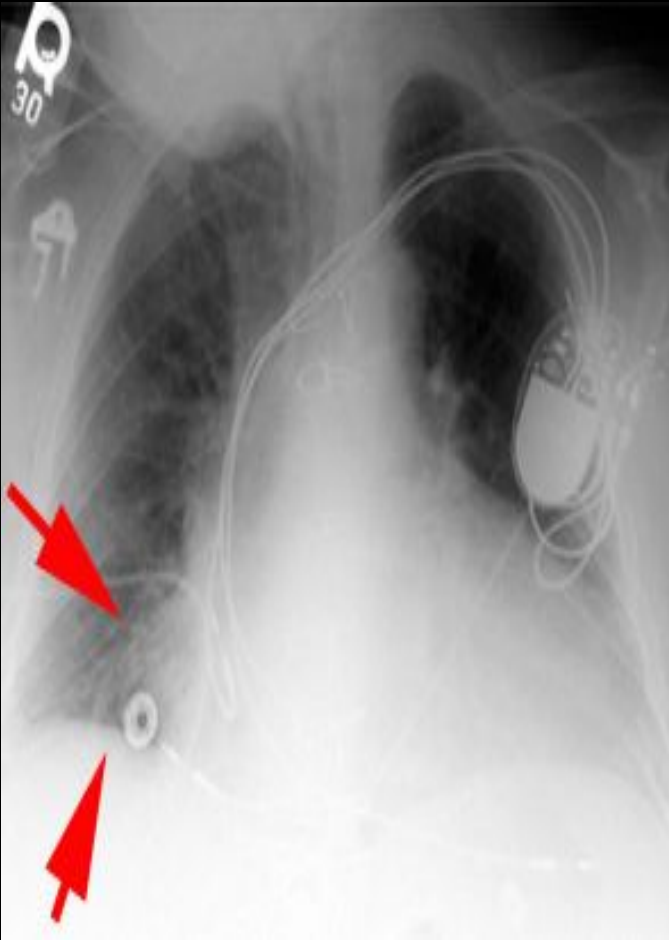Positioning Lateral decubitus



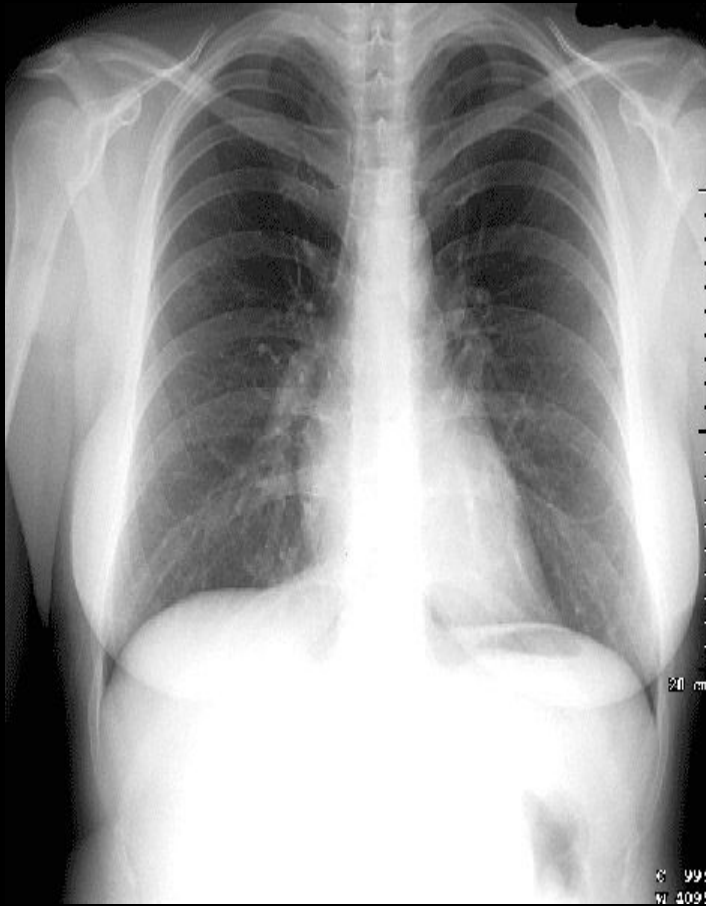Technically adequate inspiration



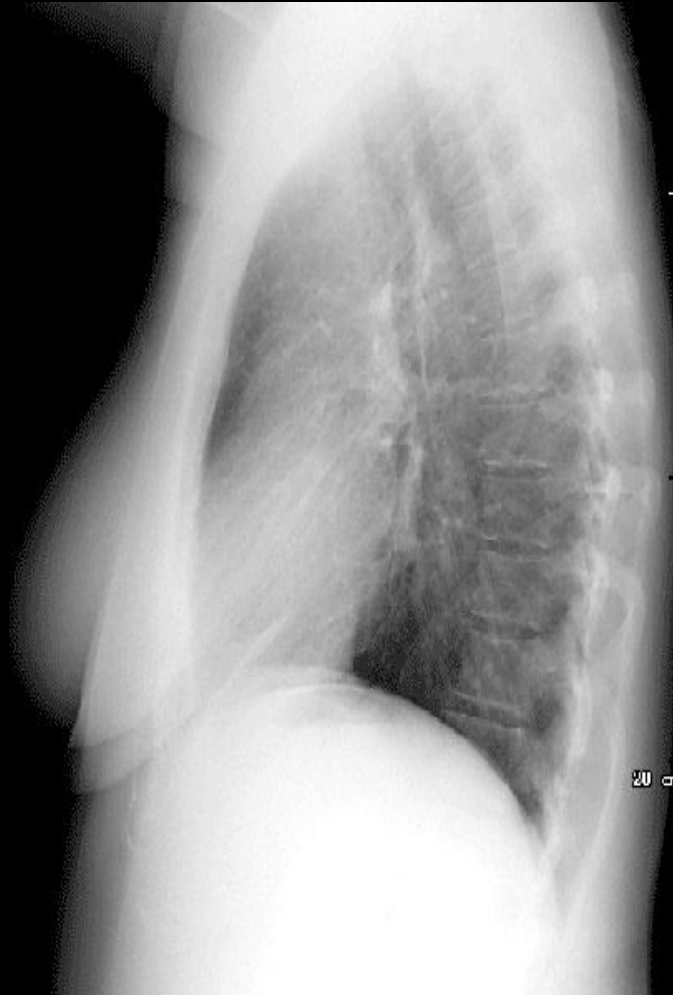Technically adequate inspiration

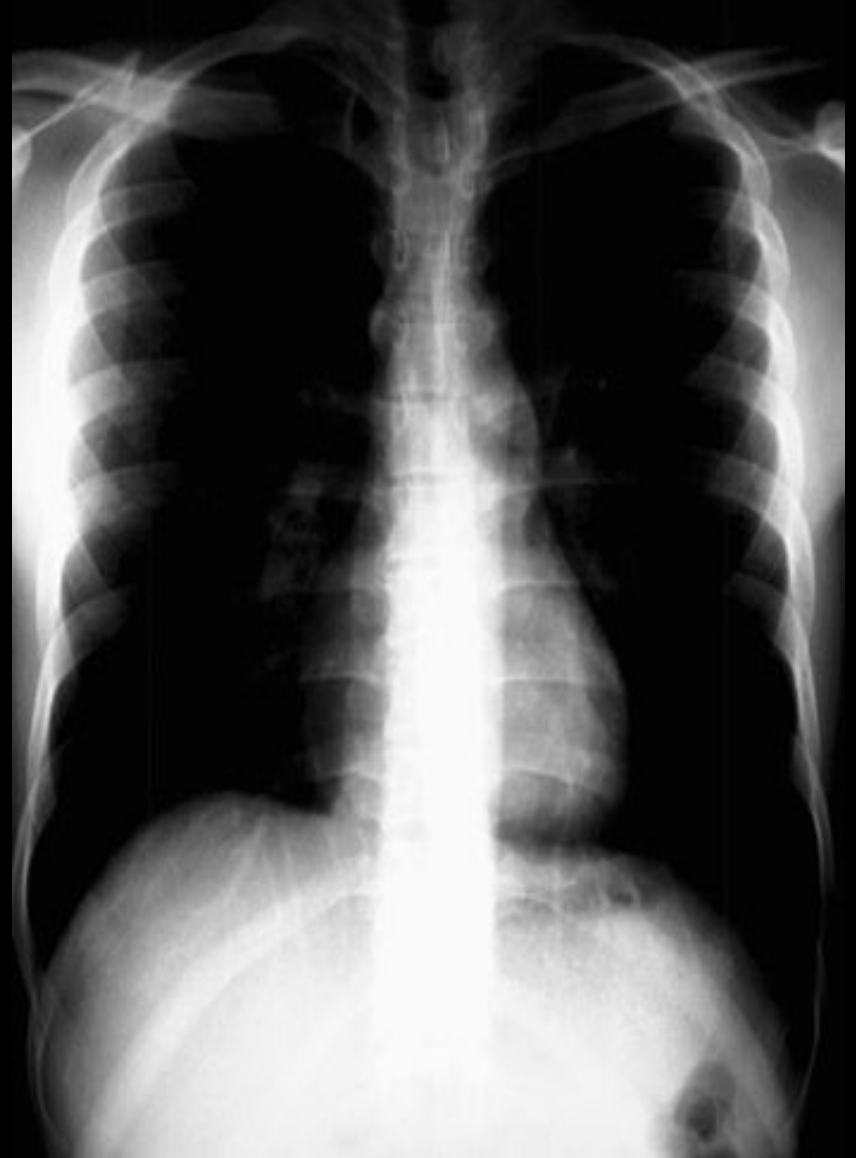
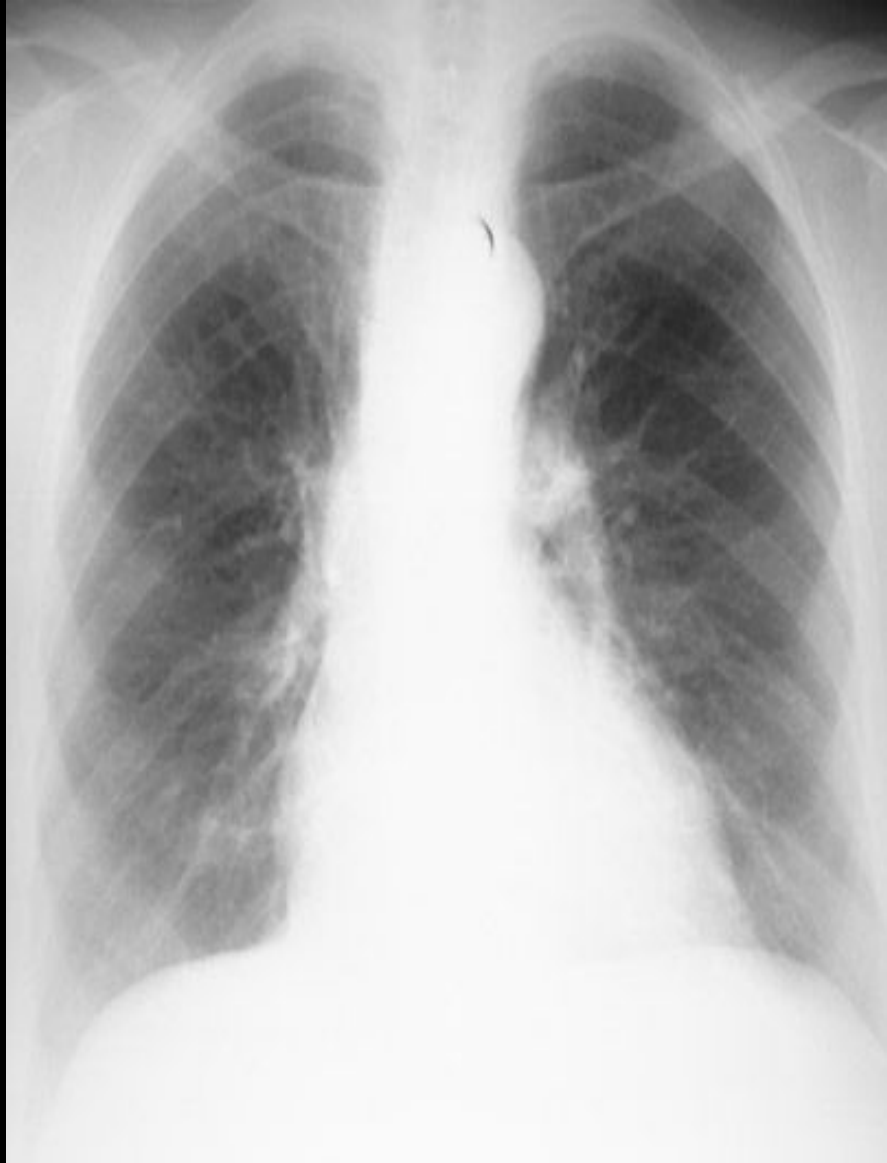
Technically adequate Penetration

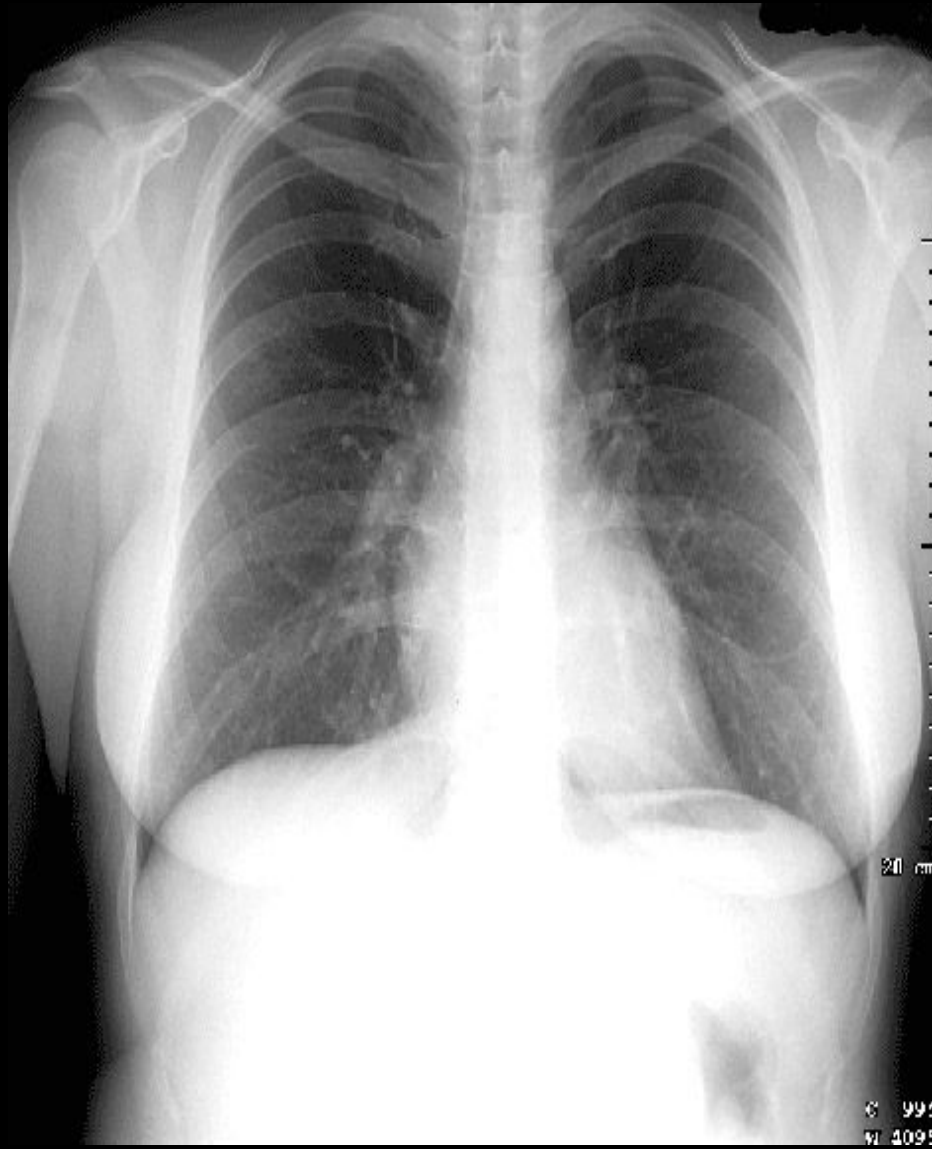

Technically adequate Penetration

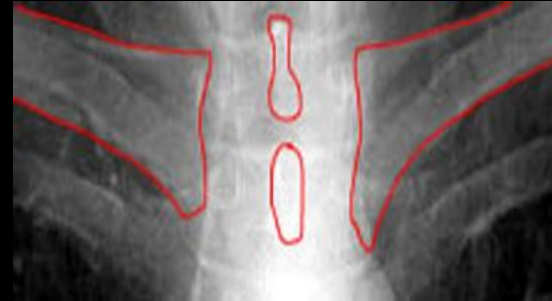
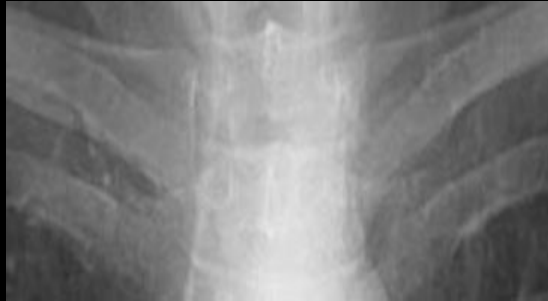


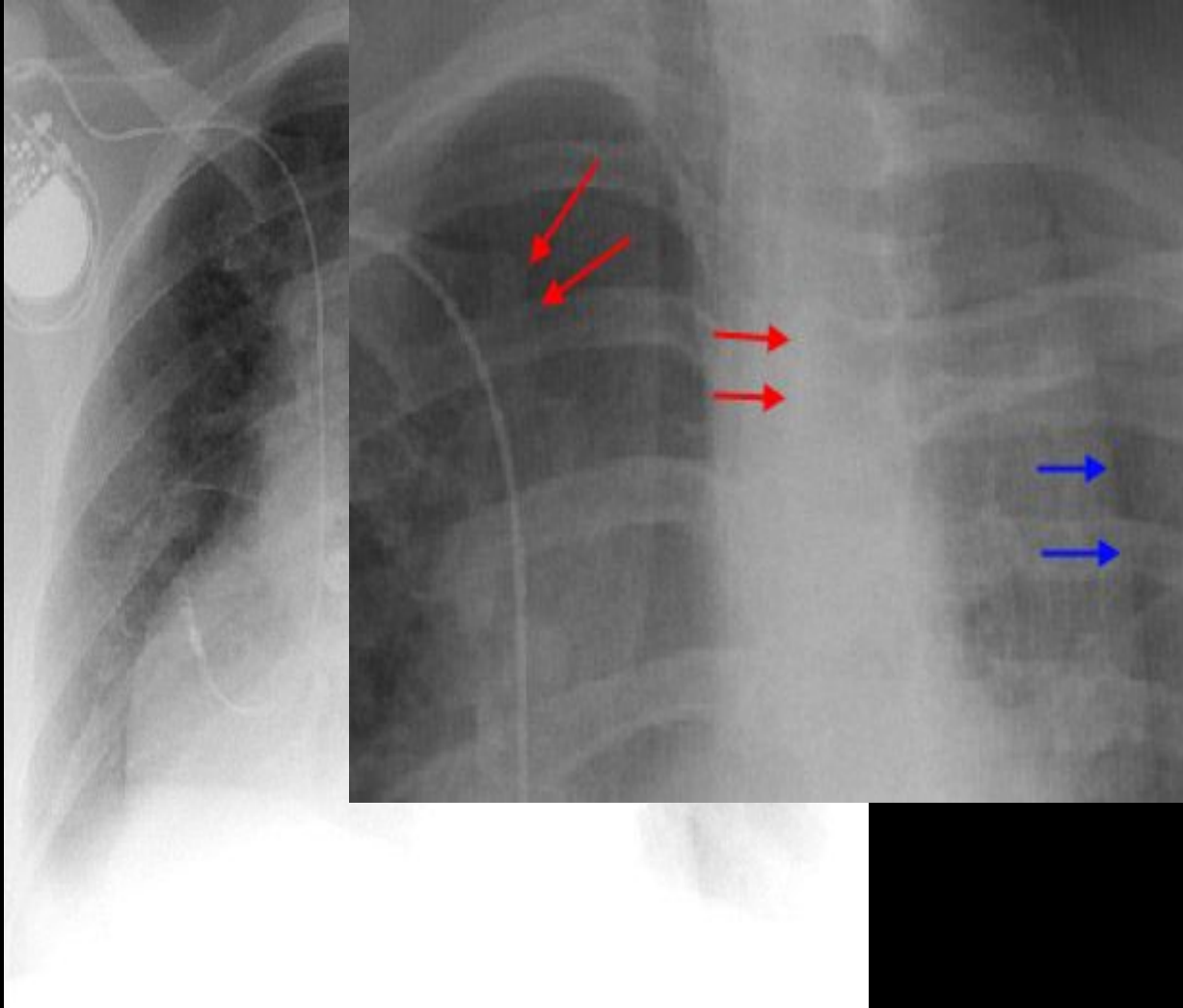
Technically adequate Rotation



Technically adequate Rotation

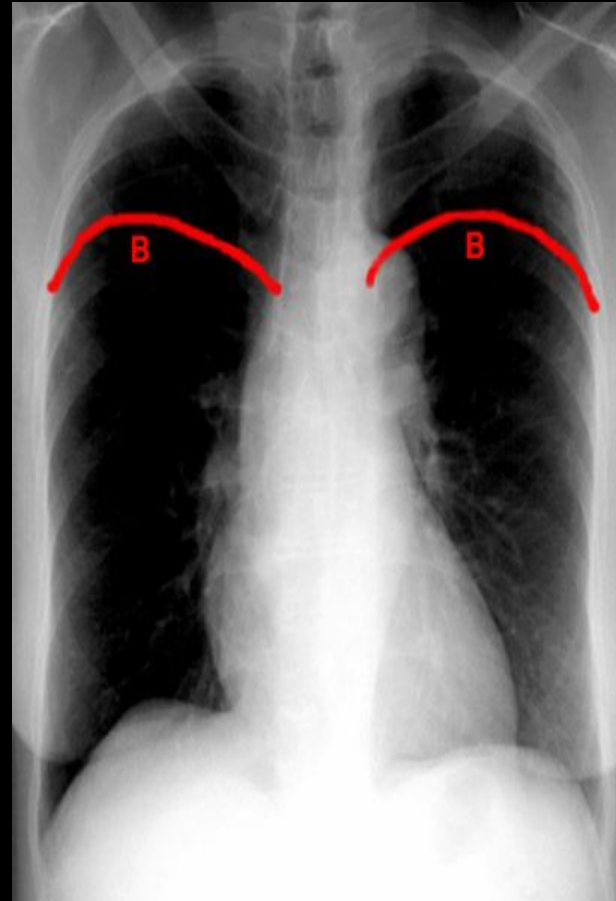
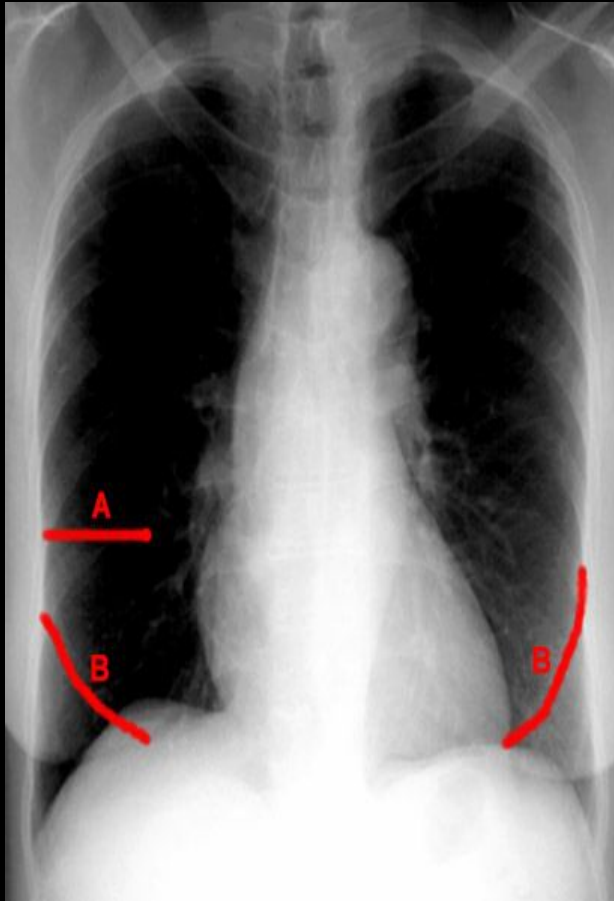


Technically adequate Rotation



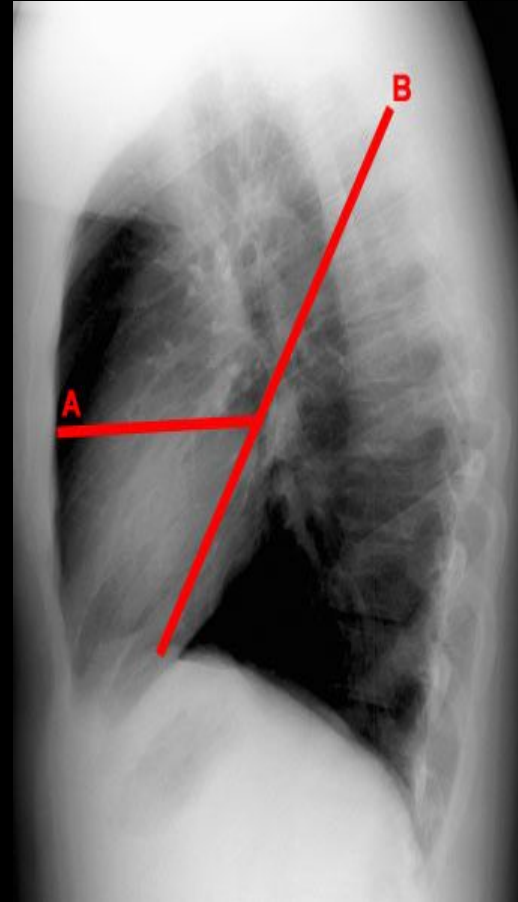
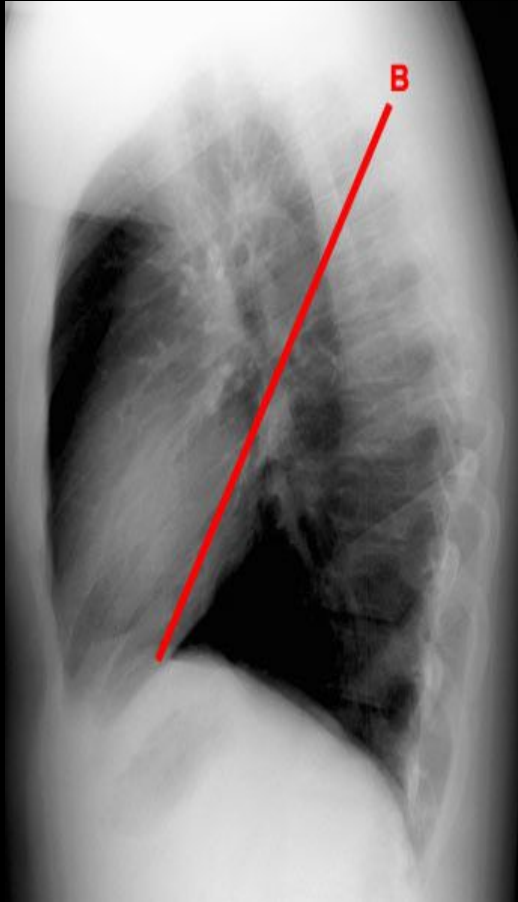
Anatomy

Lobes and Fissures



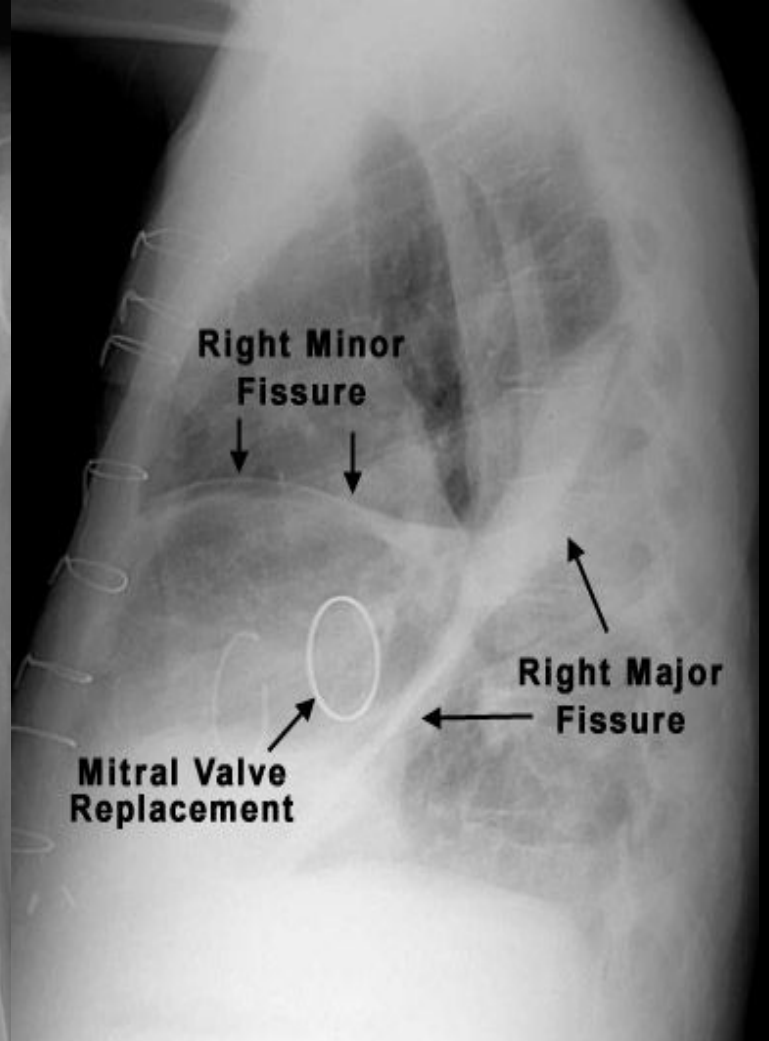
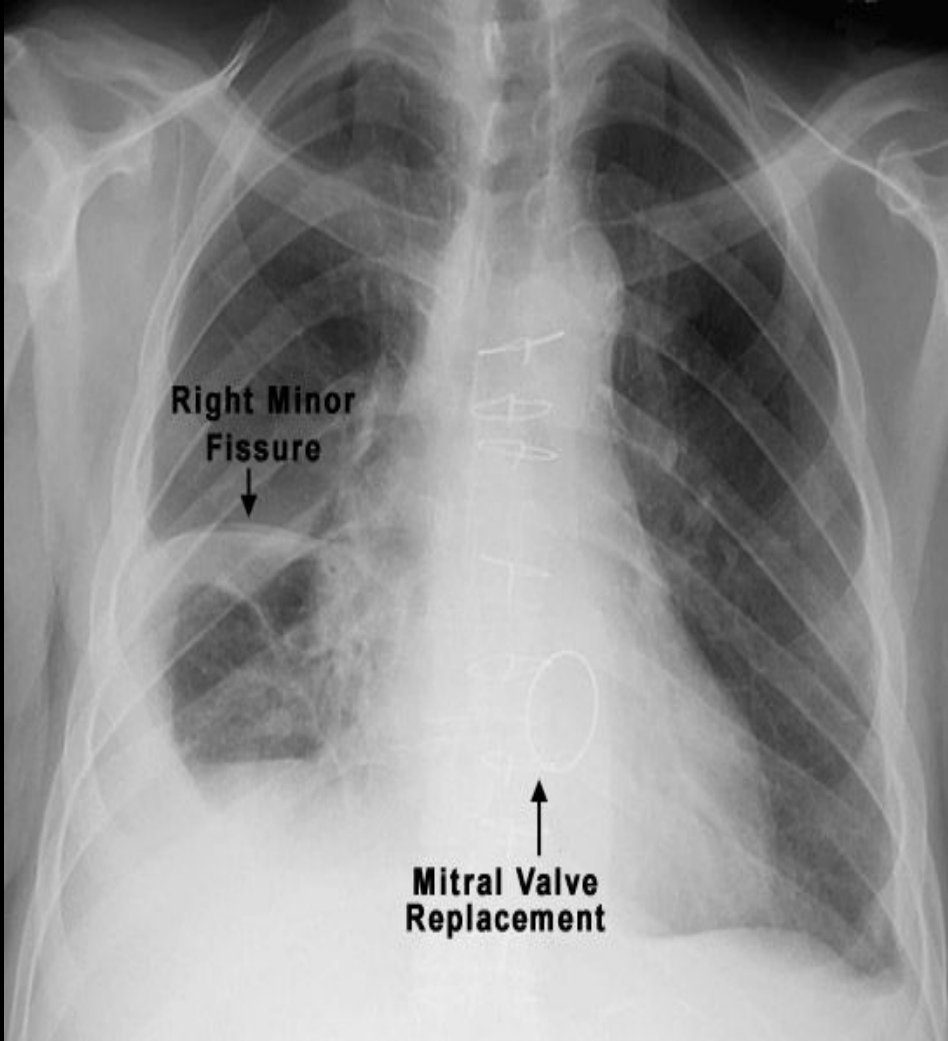
Anatomy

Lobes and Fissures



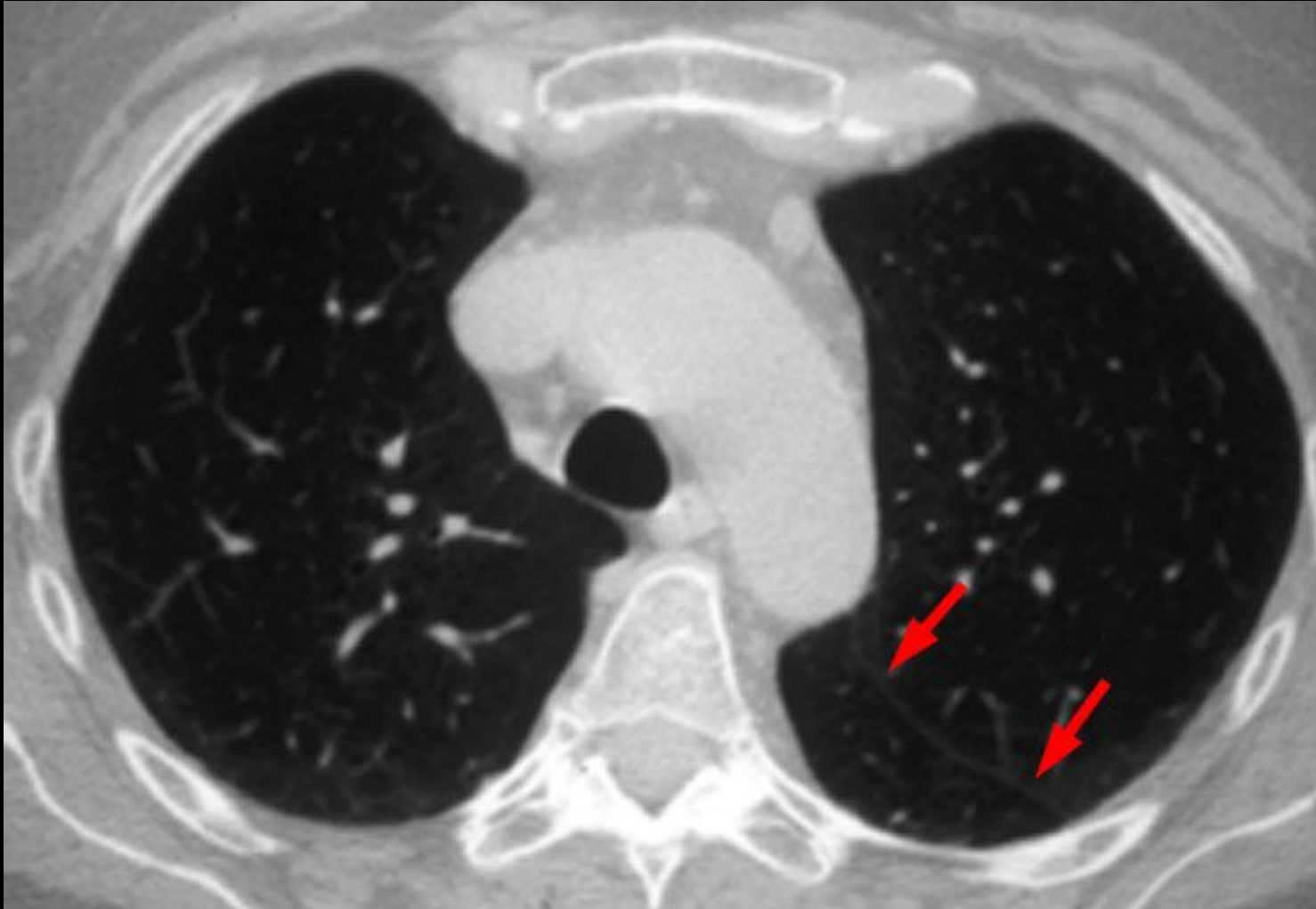
Anatomy

Lobes and Fissures



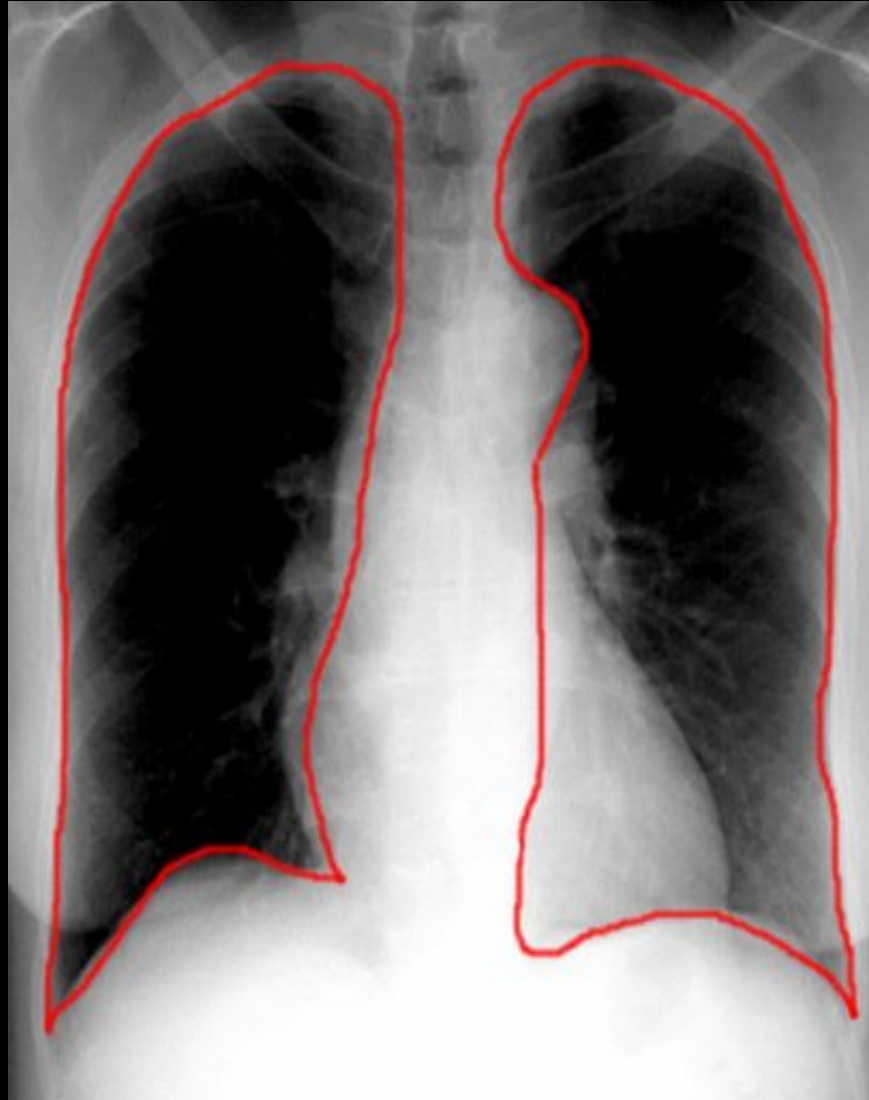
Anatomy

Lobes and Fissures

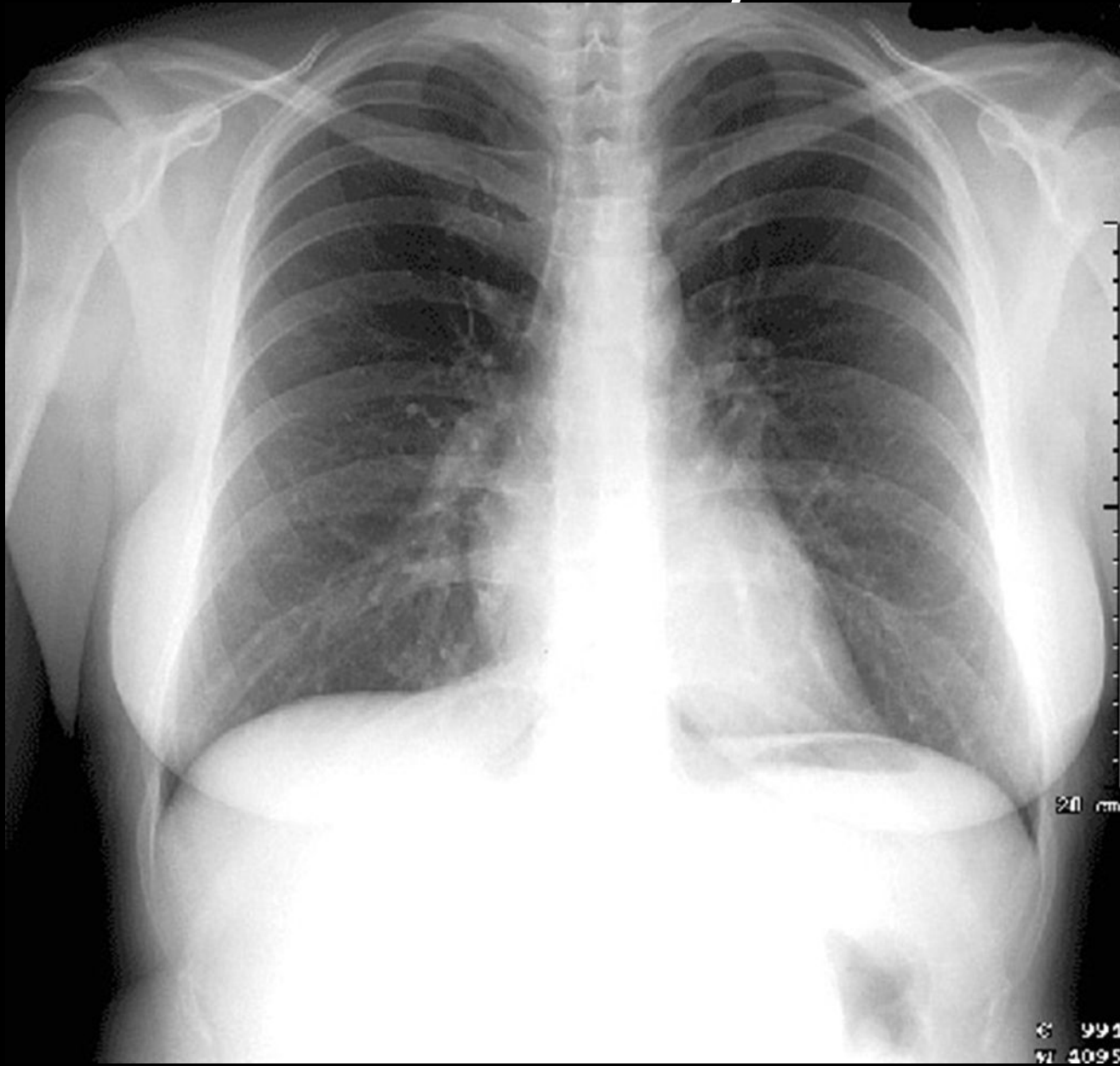


Anatomy

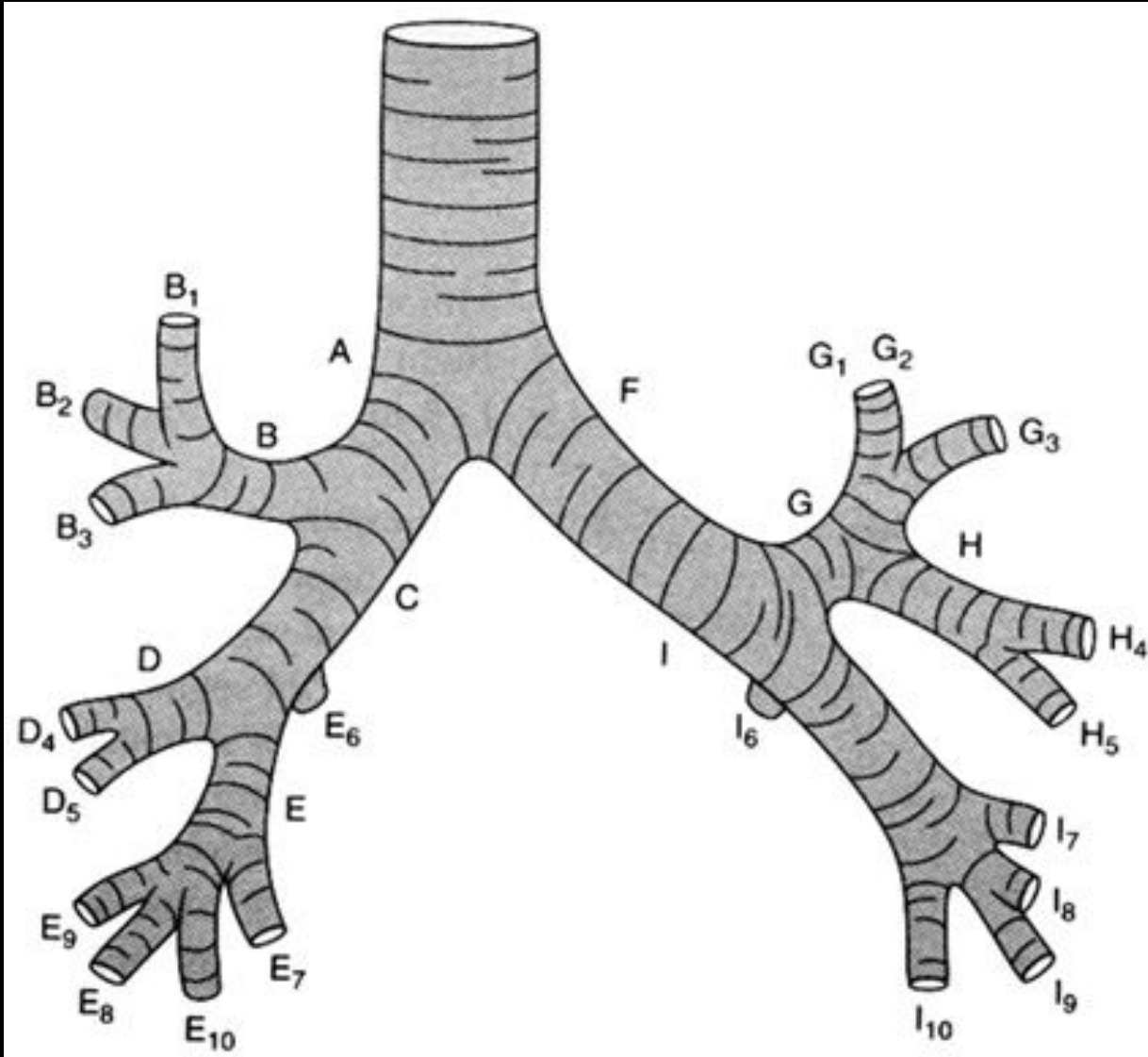
Mediastinum and Lungs



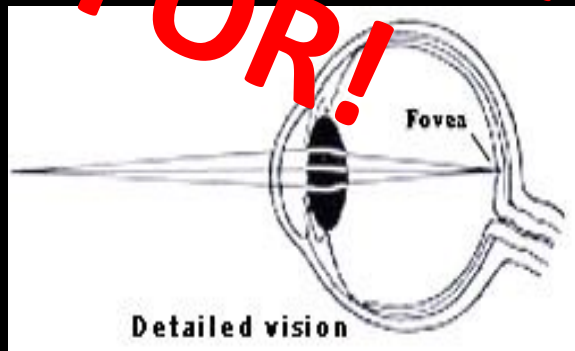
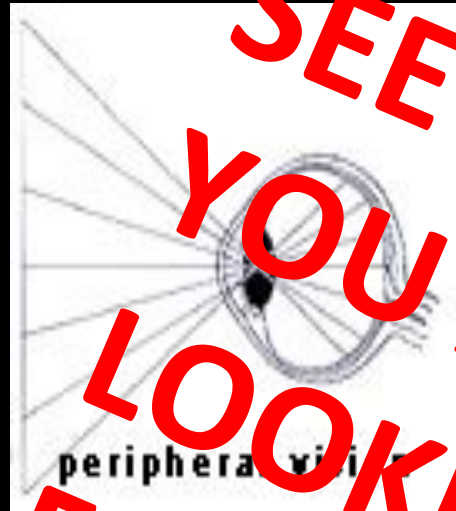Anatomy



Anatomy Bronchi

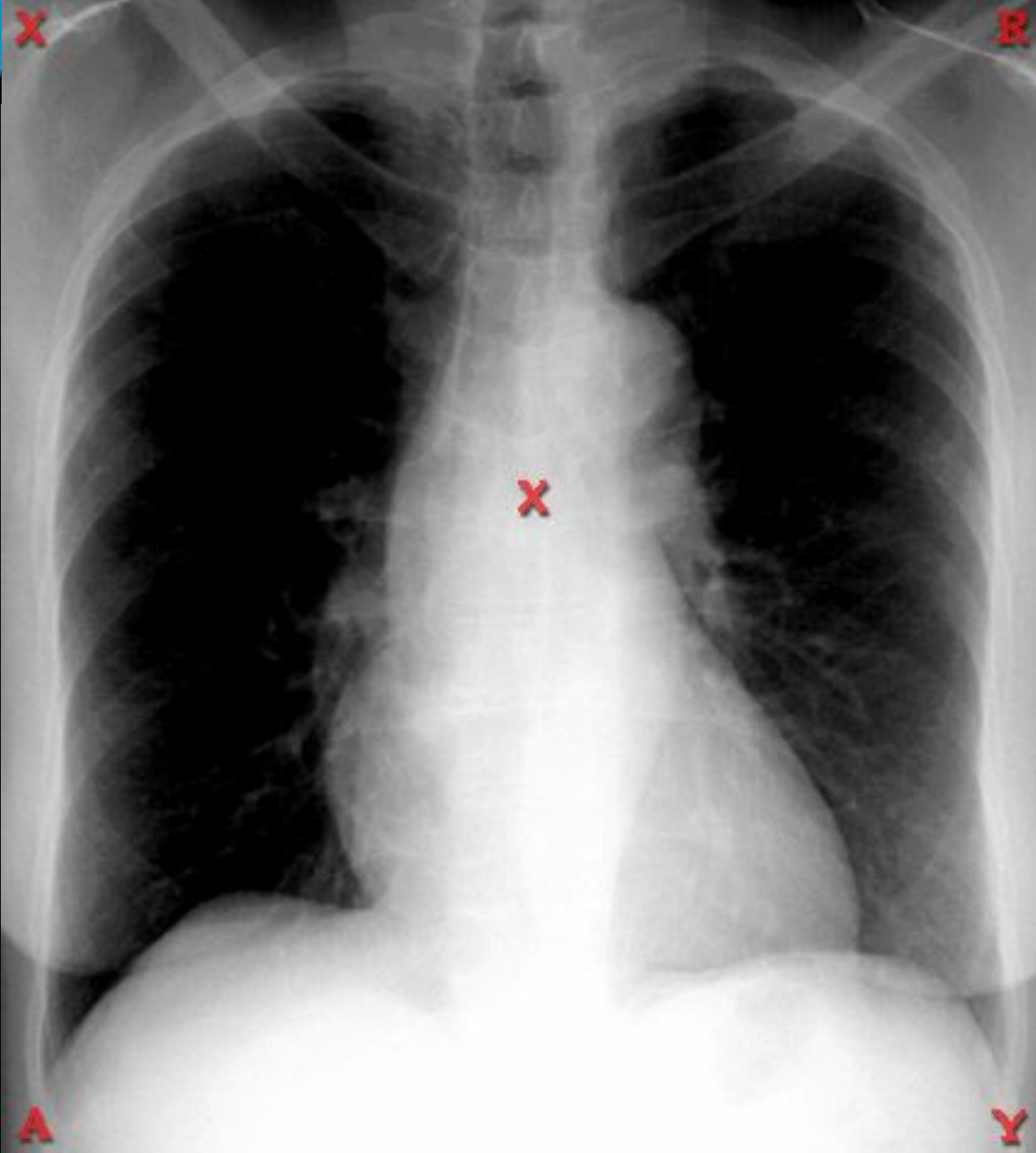


Looking for abnormalities

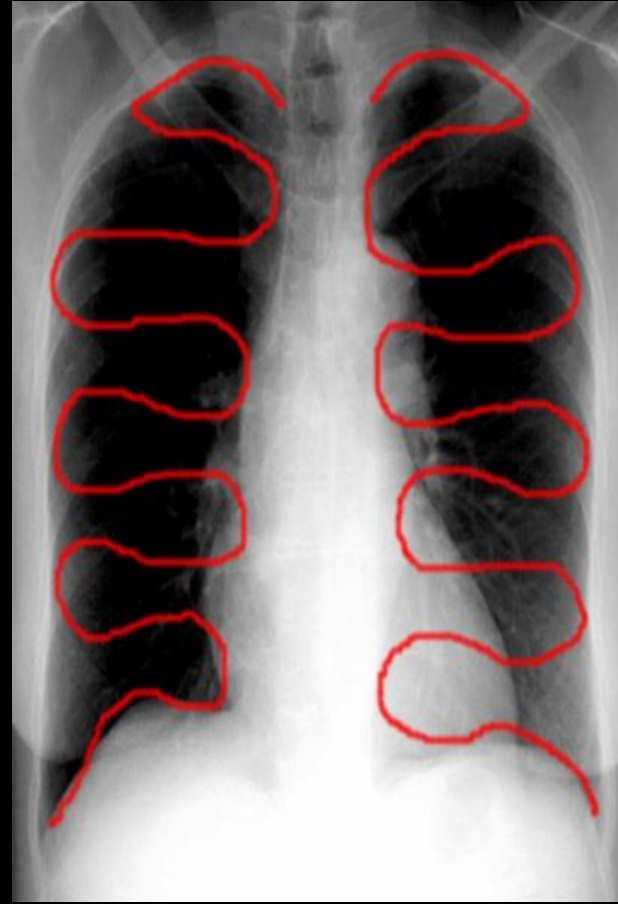
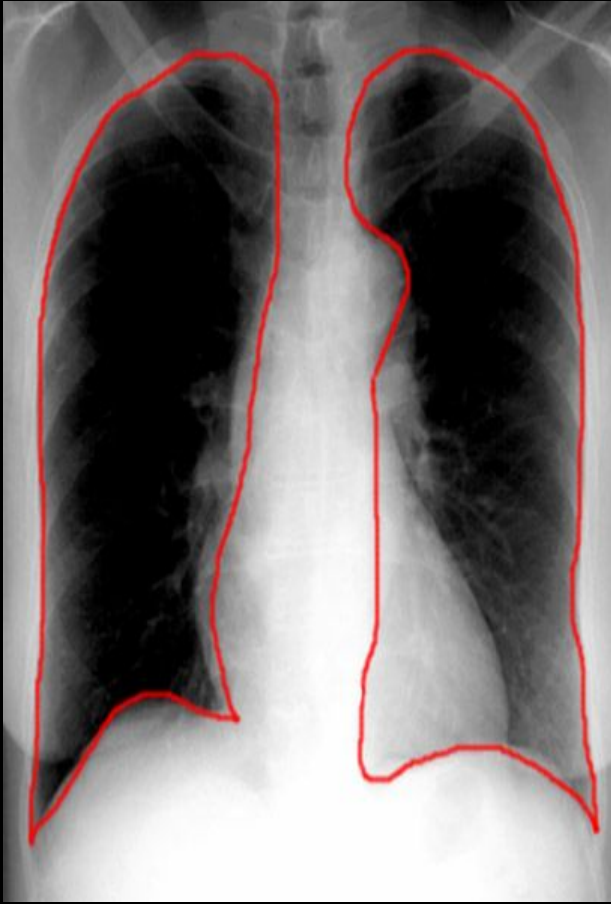


YOU ONLY SEE WHAT YOU ARE LOOKING FOR!

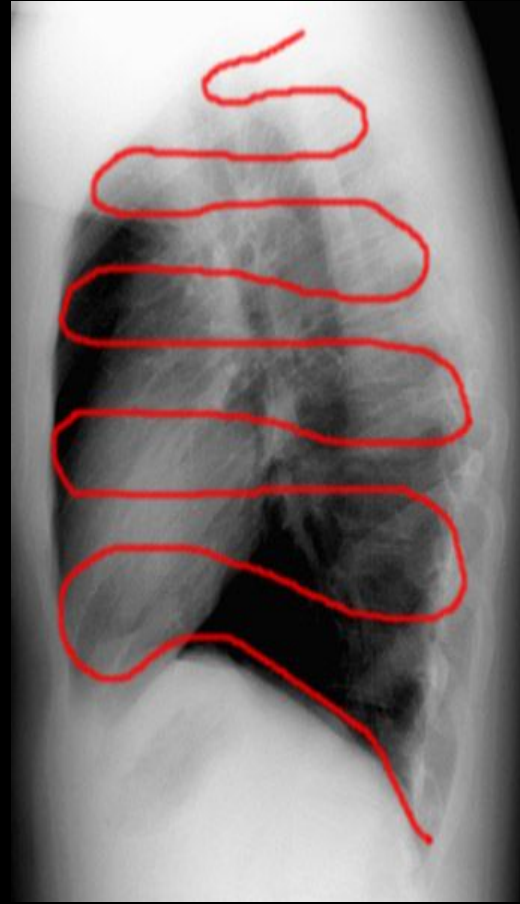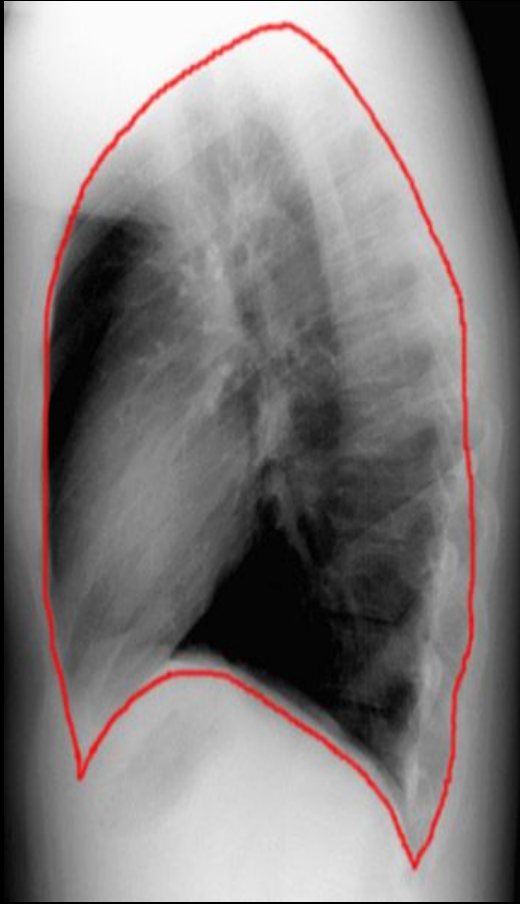
Your eye gaze should scan all portions of the film, follow lines/mediastinal interfaces and look again carefully in areas where you know that mistakes are easily made, such as over the spine on the lateral view and in the apex on the PA view.



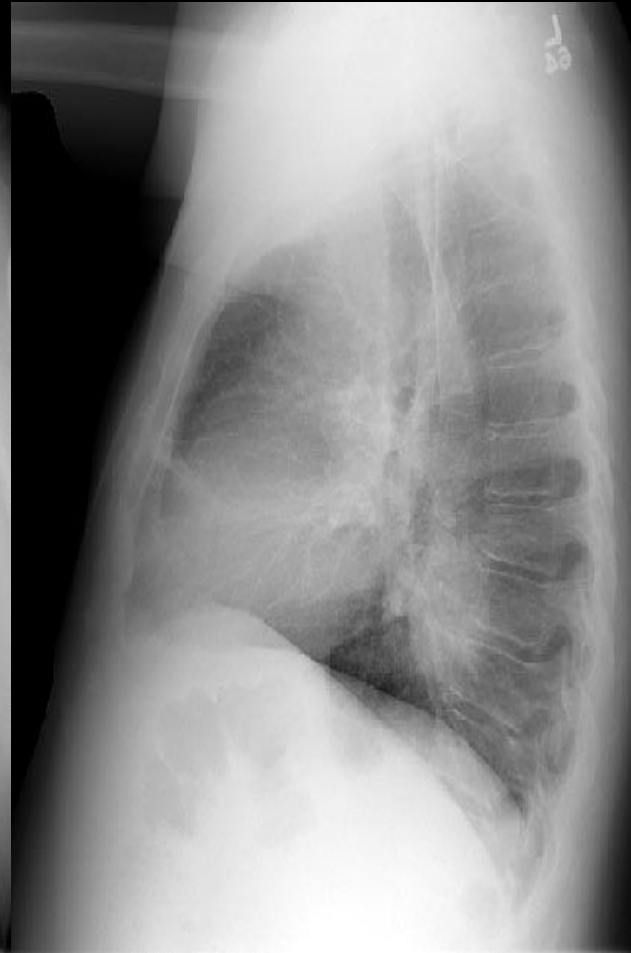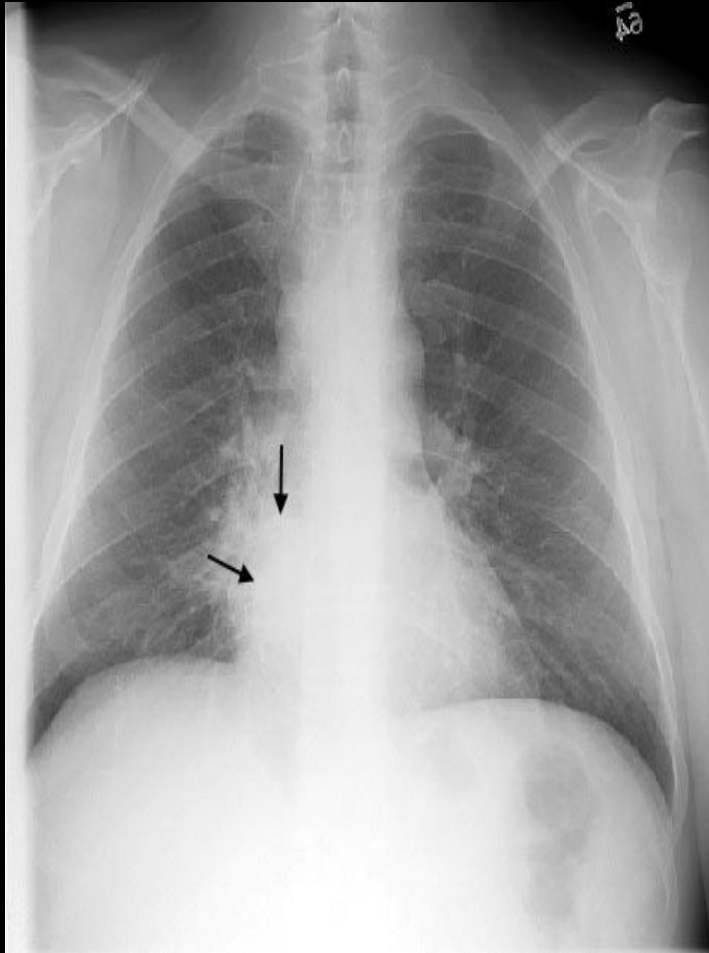
Looking for abnormalities



Looking for abnormalities



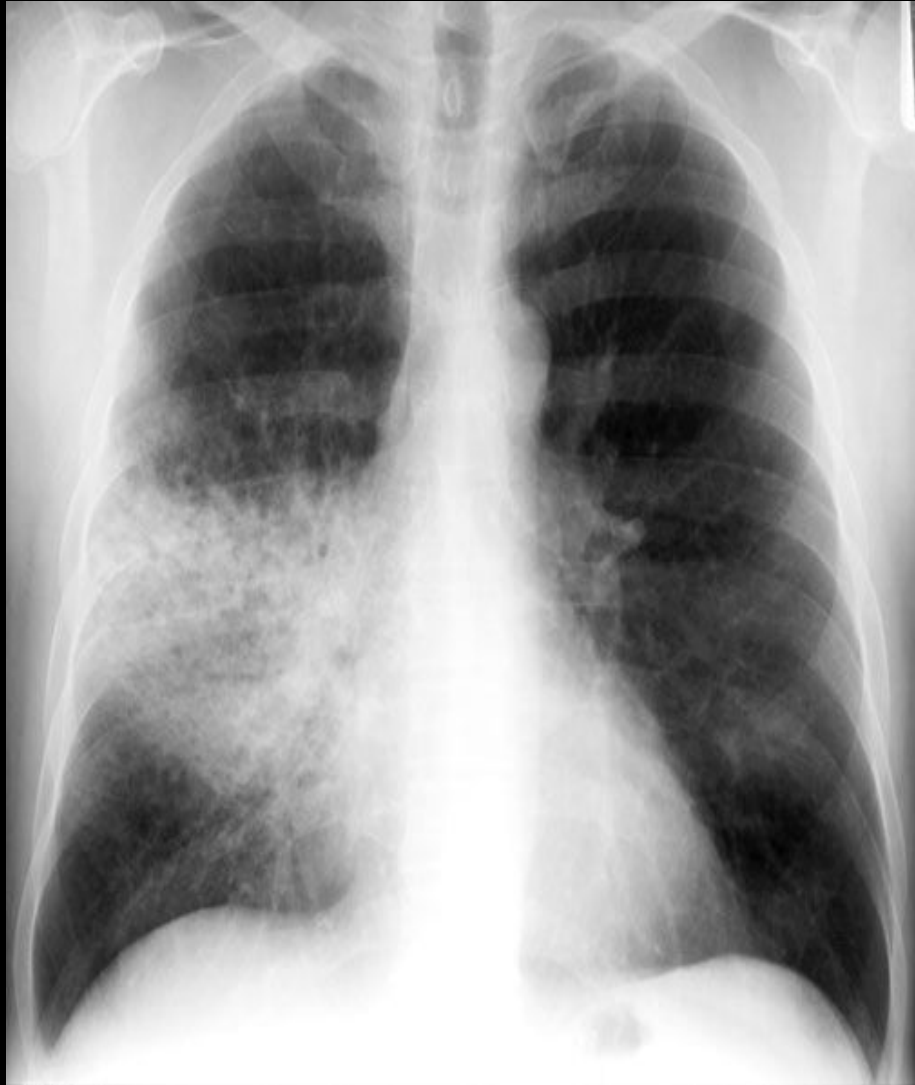Cont.



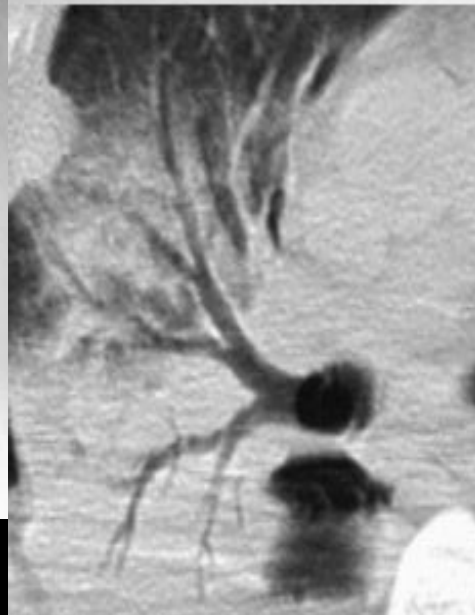

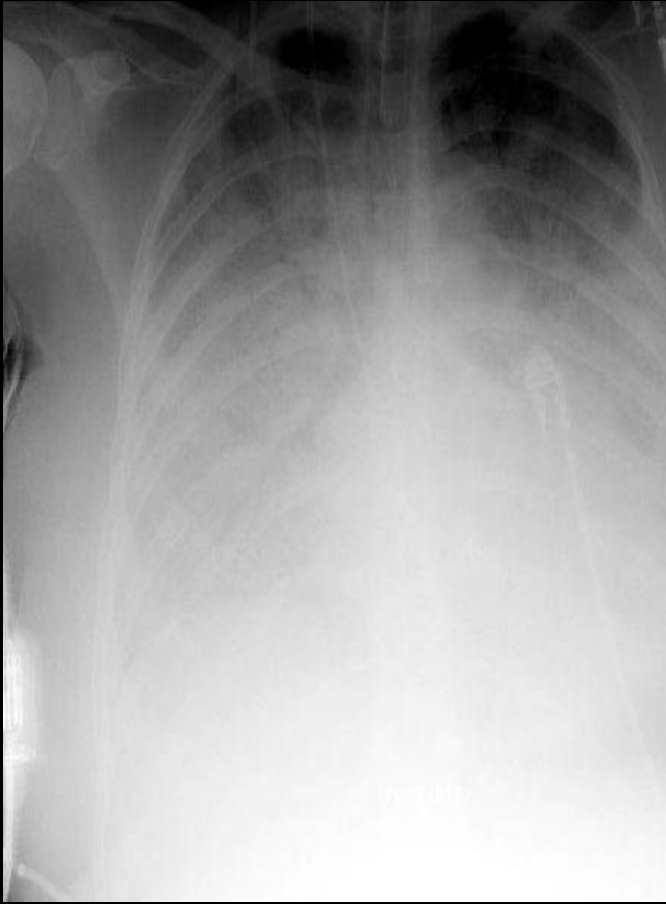
Silhouette

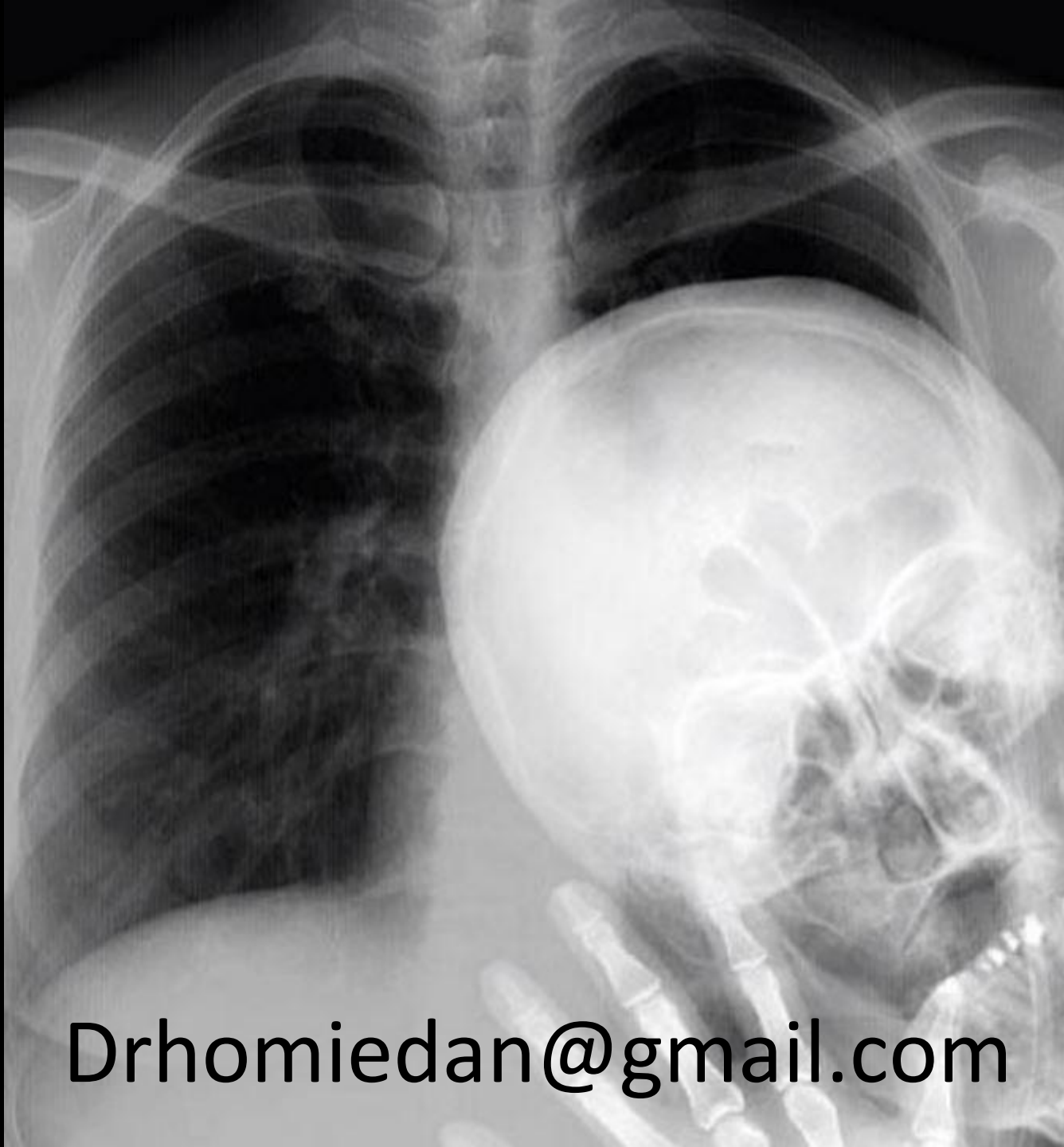

Silhouette sign



Air Bronch





Thanks !

Drhomiedan@gmail.com