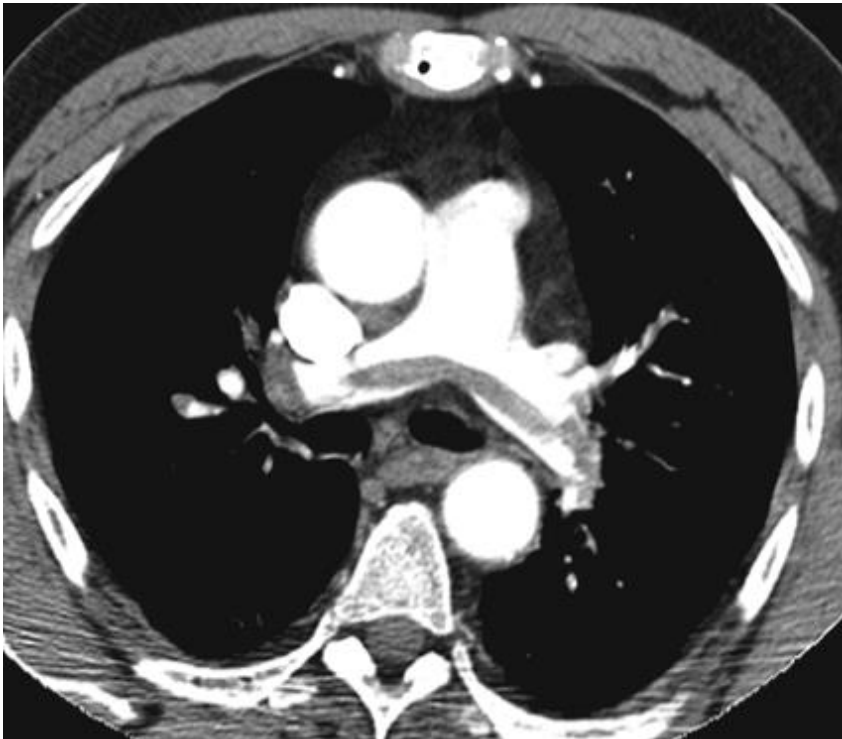


**Interactive**  
**CHEST IMAGING**  
**lecture**

**366 COURSE**

**October 2020**

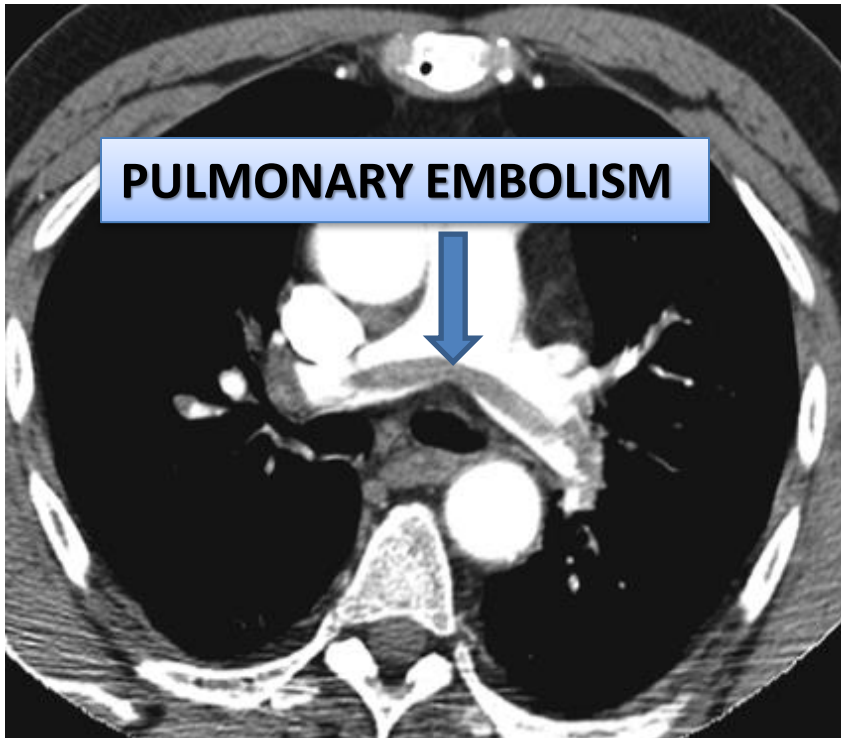
# Question ?



- Patient presented to ER with acute chest pain and SOB
- Past history of pelvic fracture with hospital admission for 5 weeks.
- **Answer the following question by selecting the SINGLE BEST ANSWER**

1. -----
2. ----- **X**
3. -----
4. -----

# Answer ?

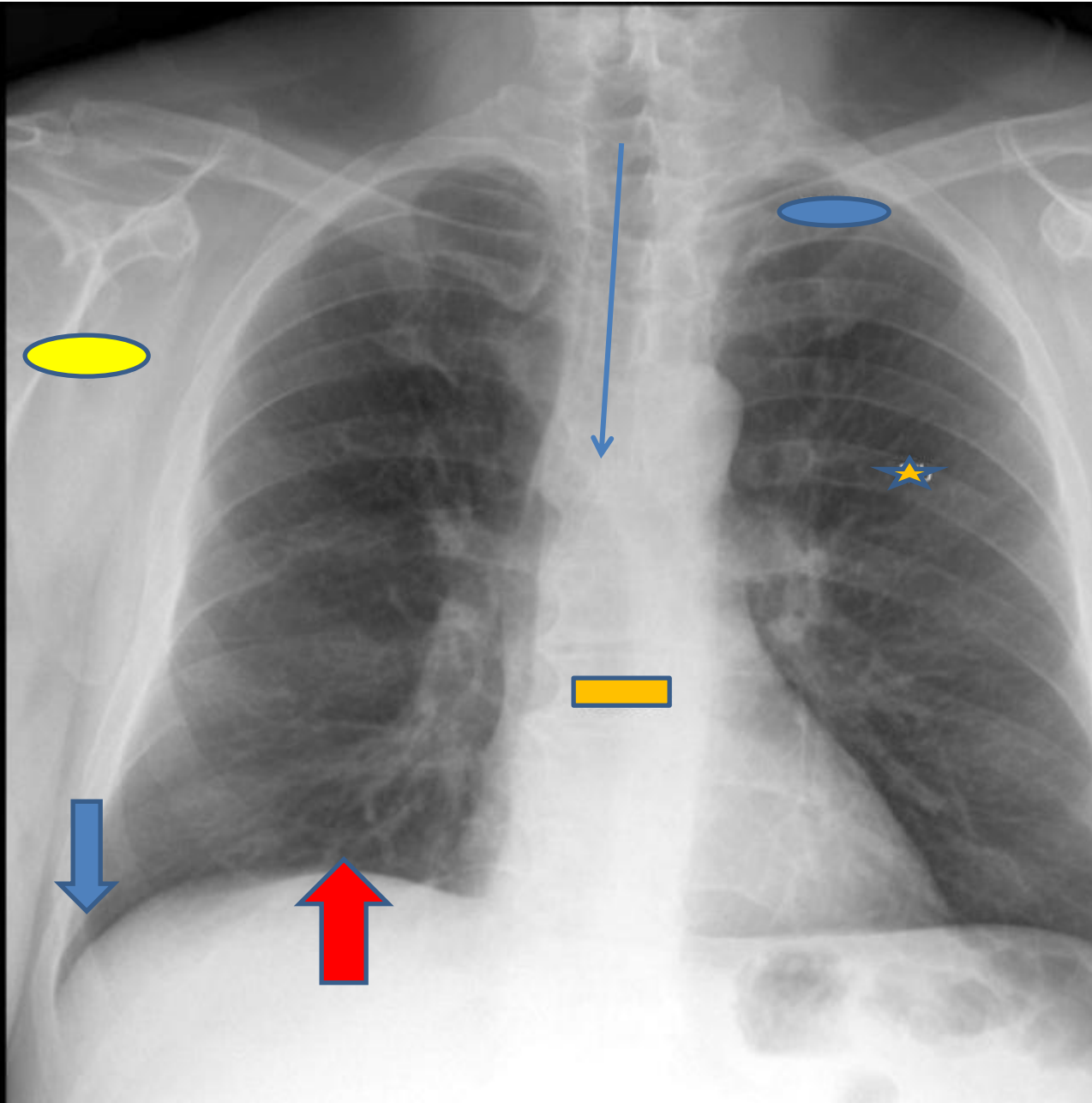


- Patient presented to ER with acute chest pain and SOB
- Past history of pelvic fracture with hospital admission for 5 weeks.

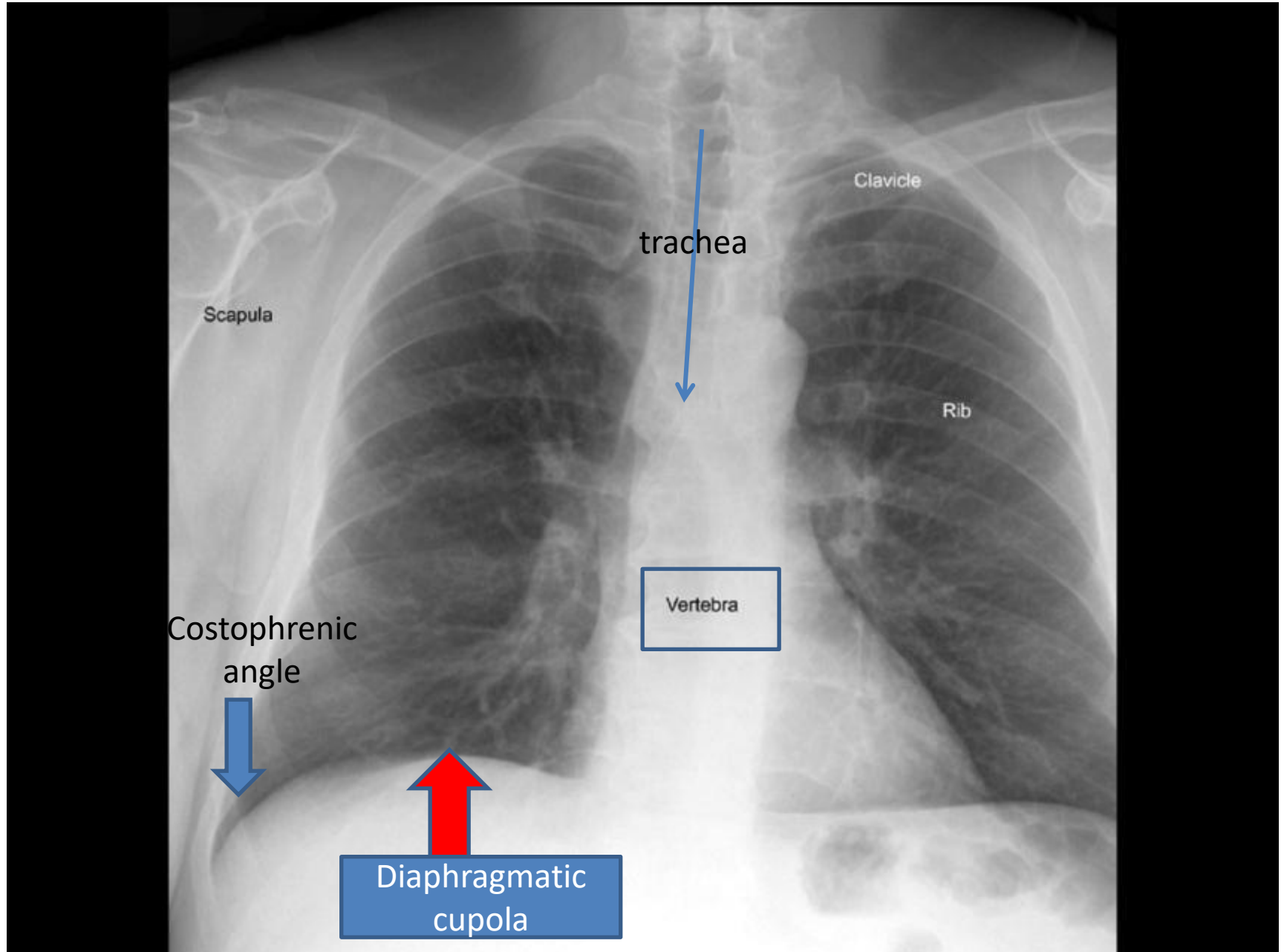
## Q-SINGLE BEST ANSWER

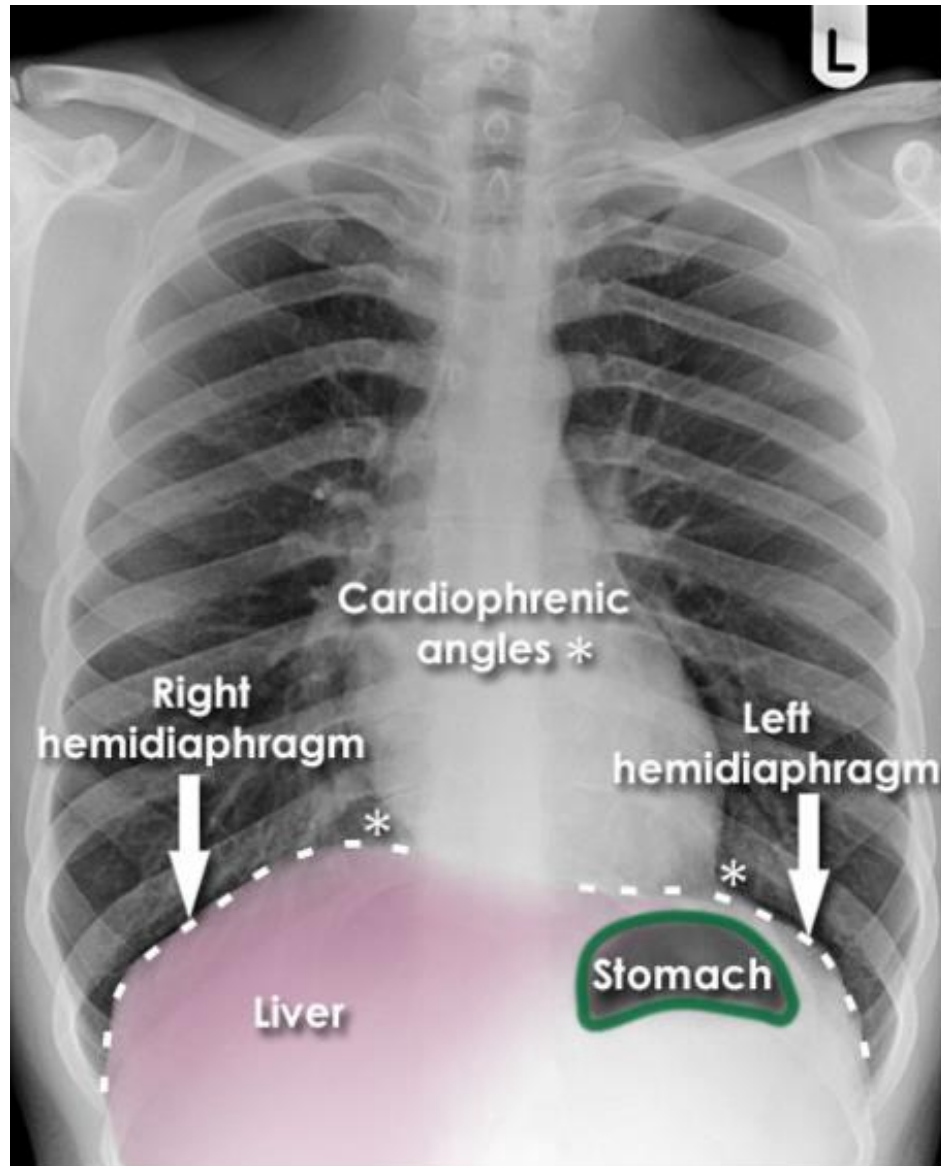
1. -----
2. CTA showing PULMONARY EMBOLISM **X**
3. -----
4. -----

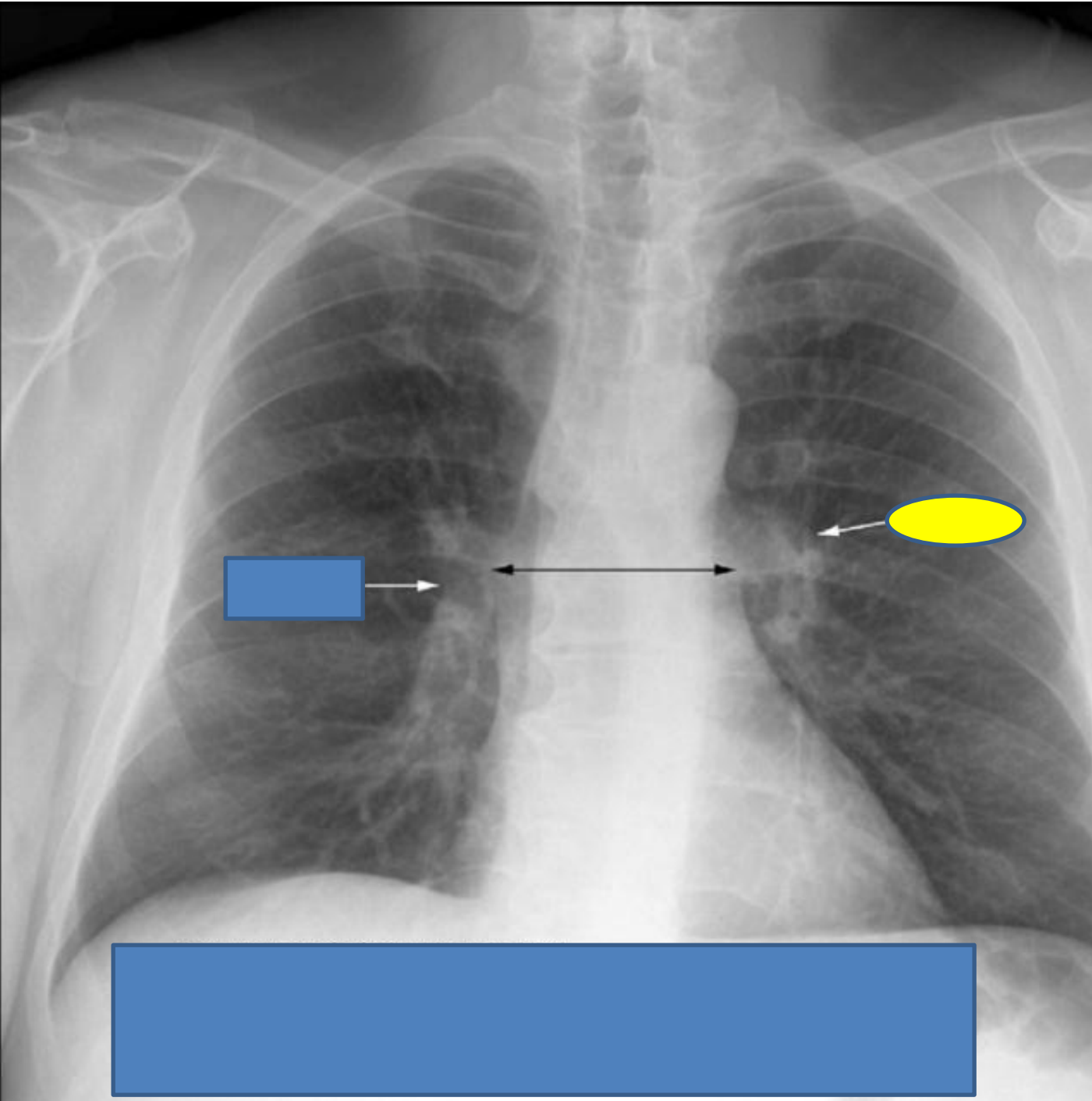
# Anatomy



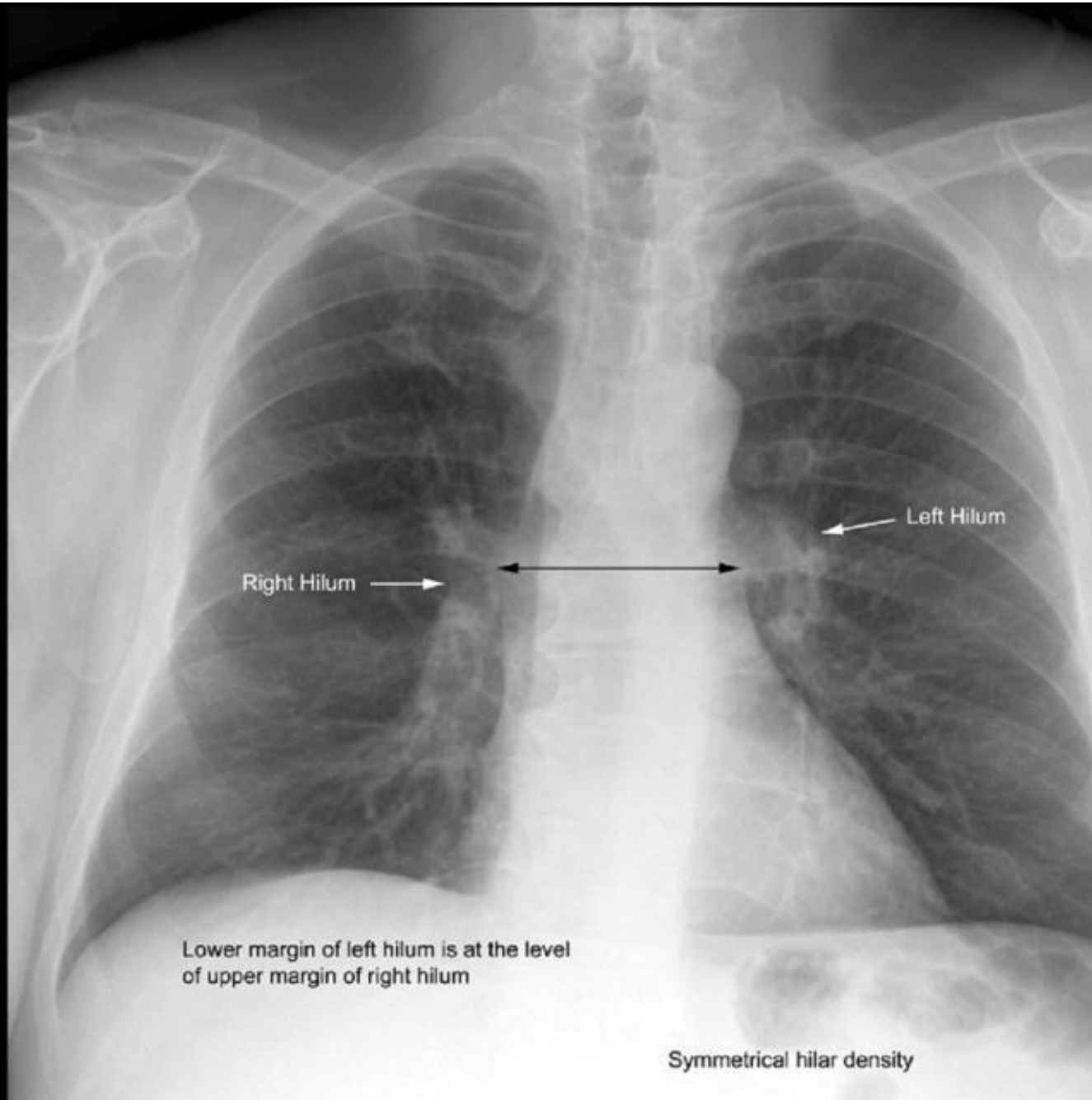
# Anatomy





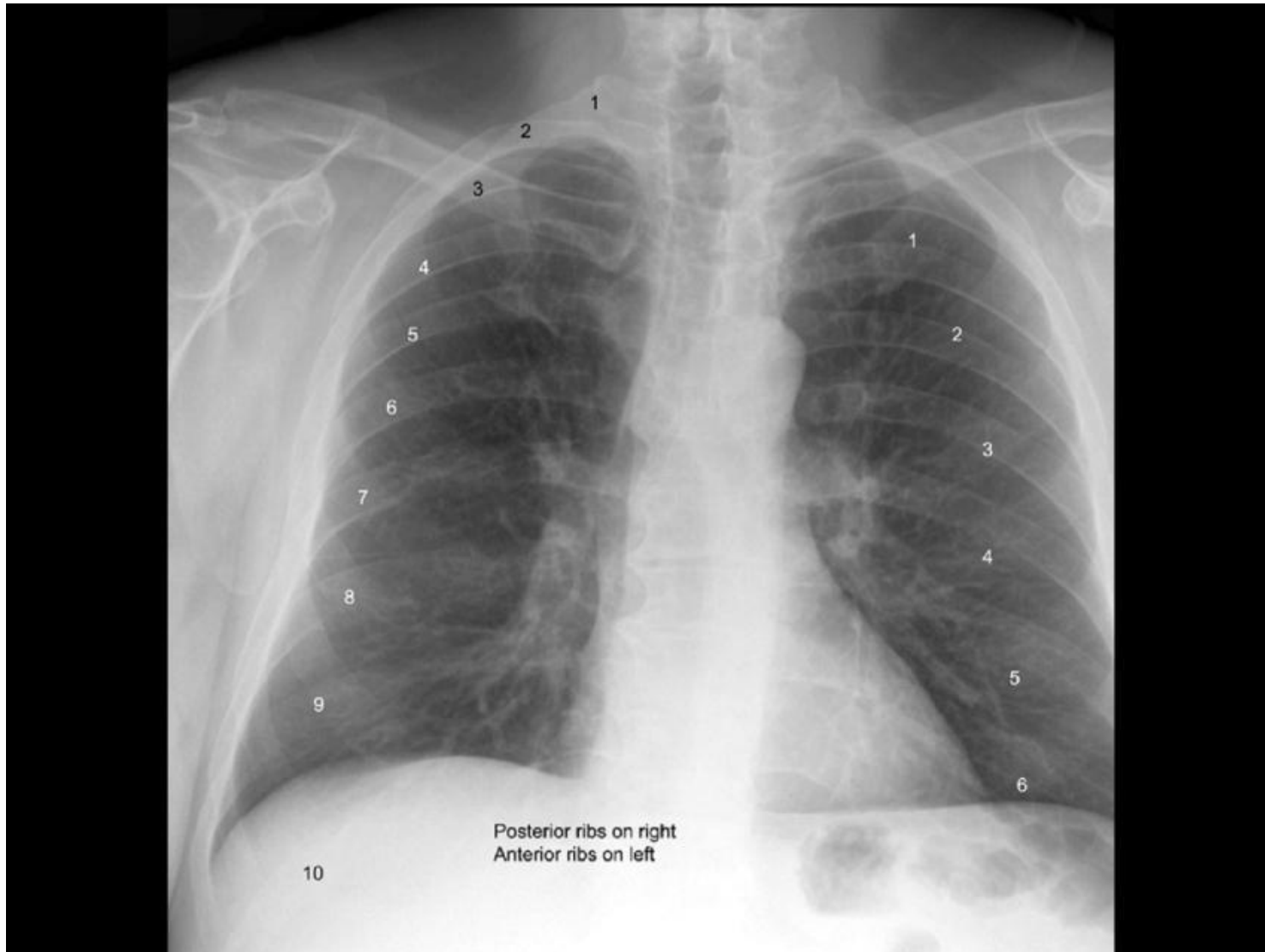


# Hilum

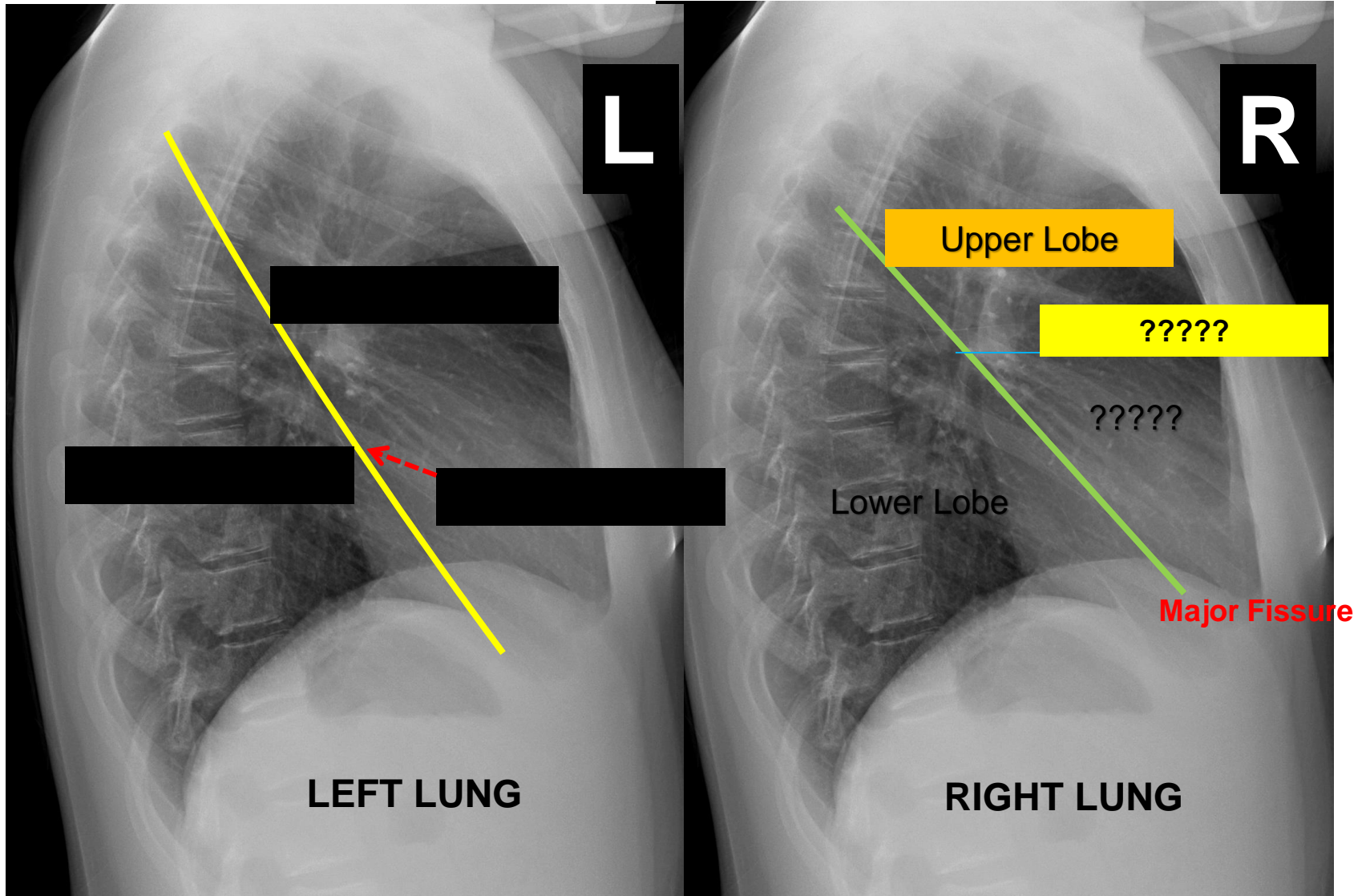




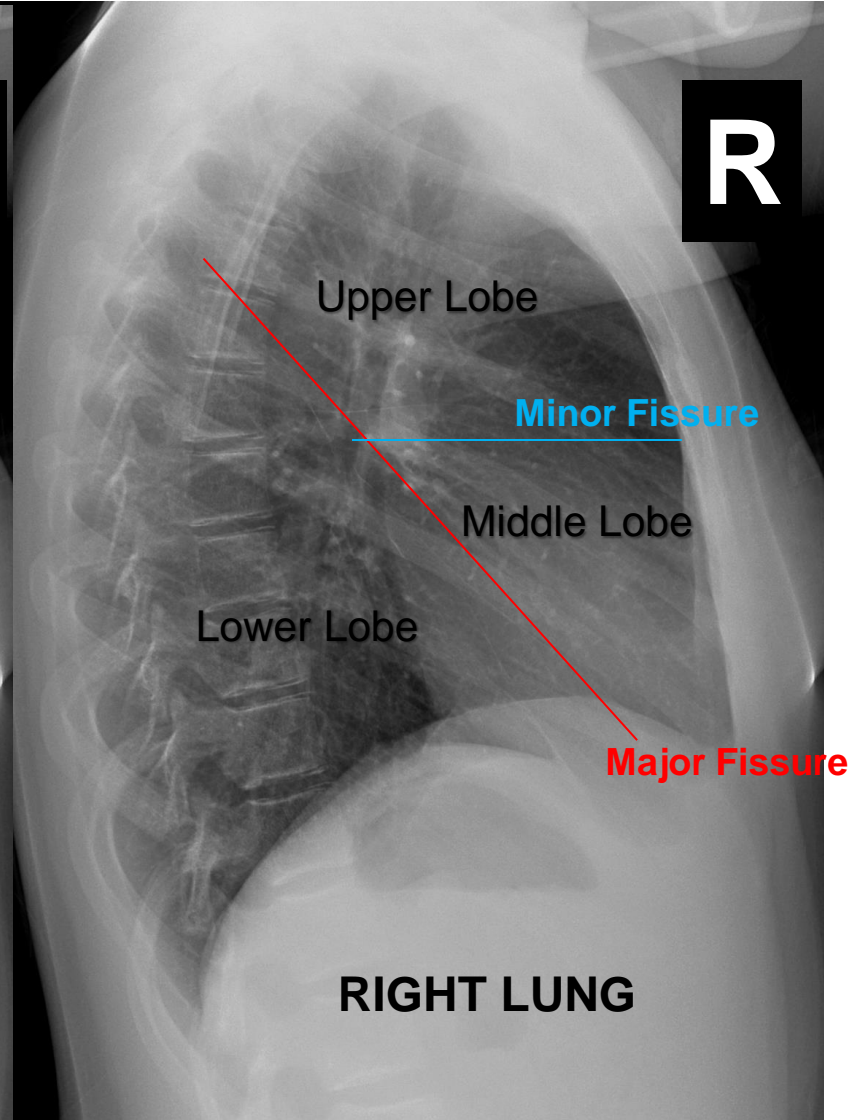
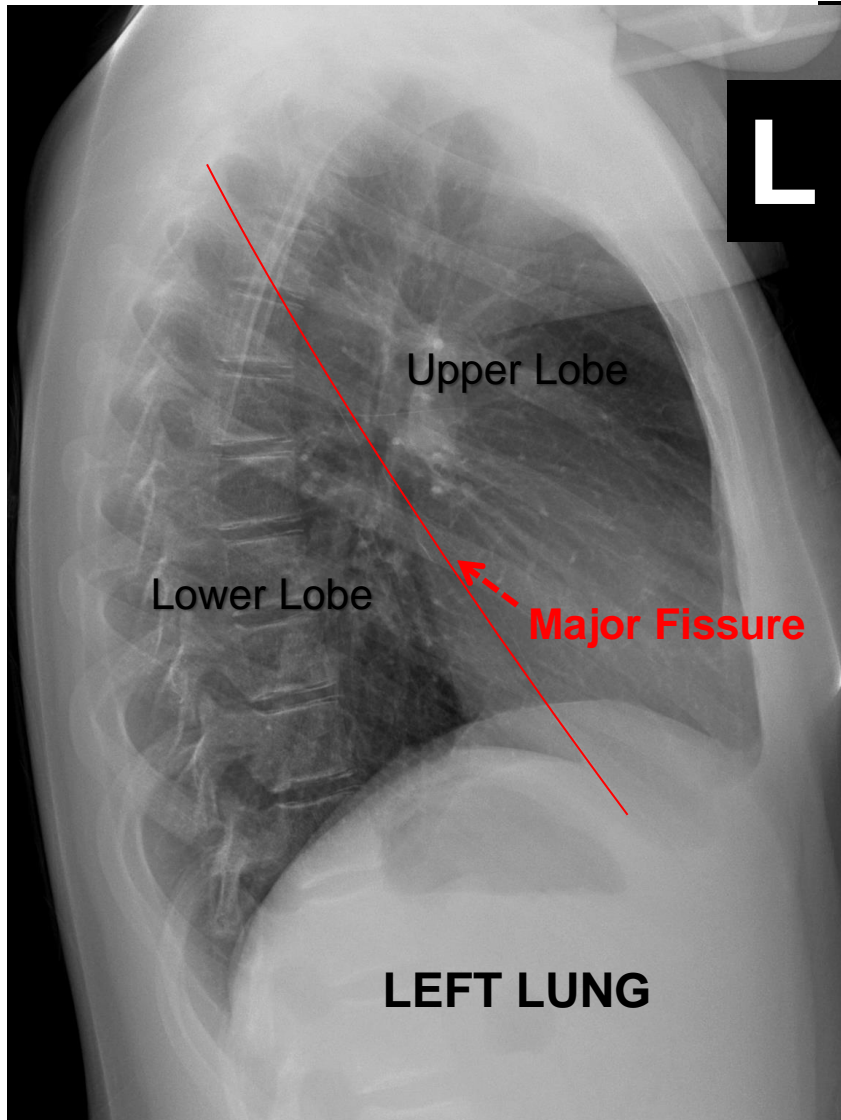
# COUNTING RIBS



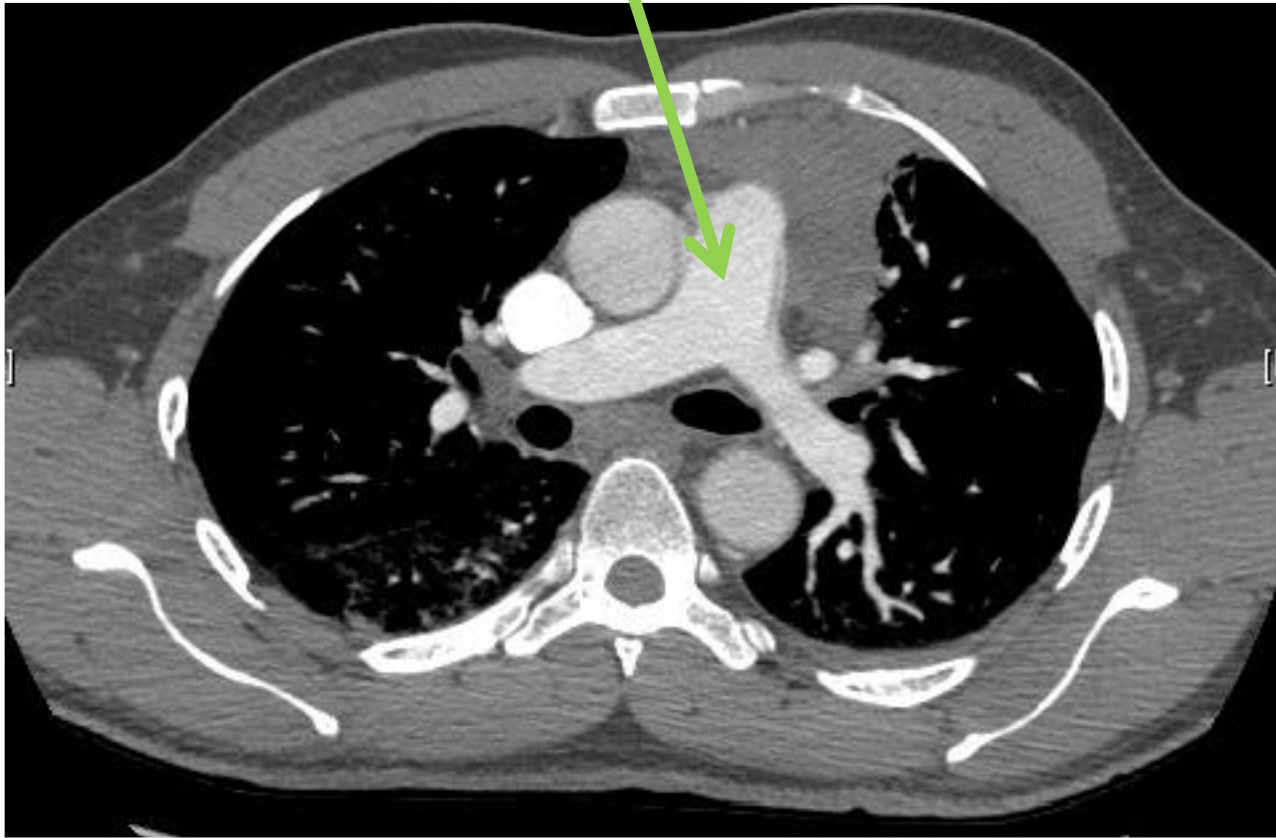
# Radiological Anatomy of the Chest



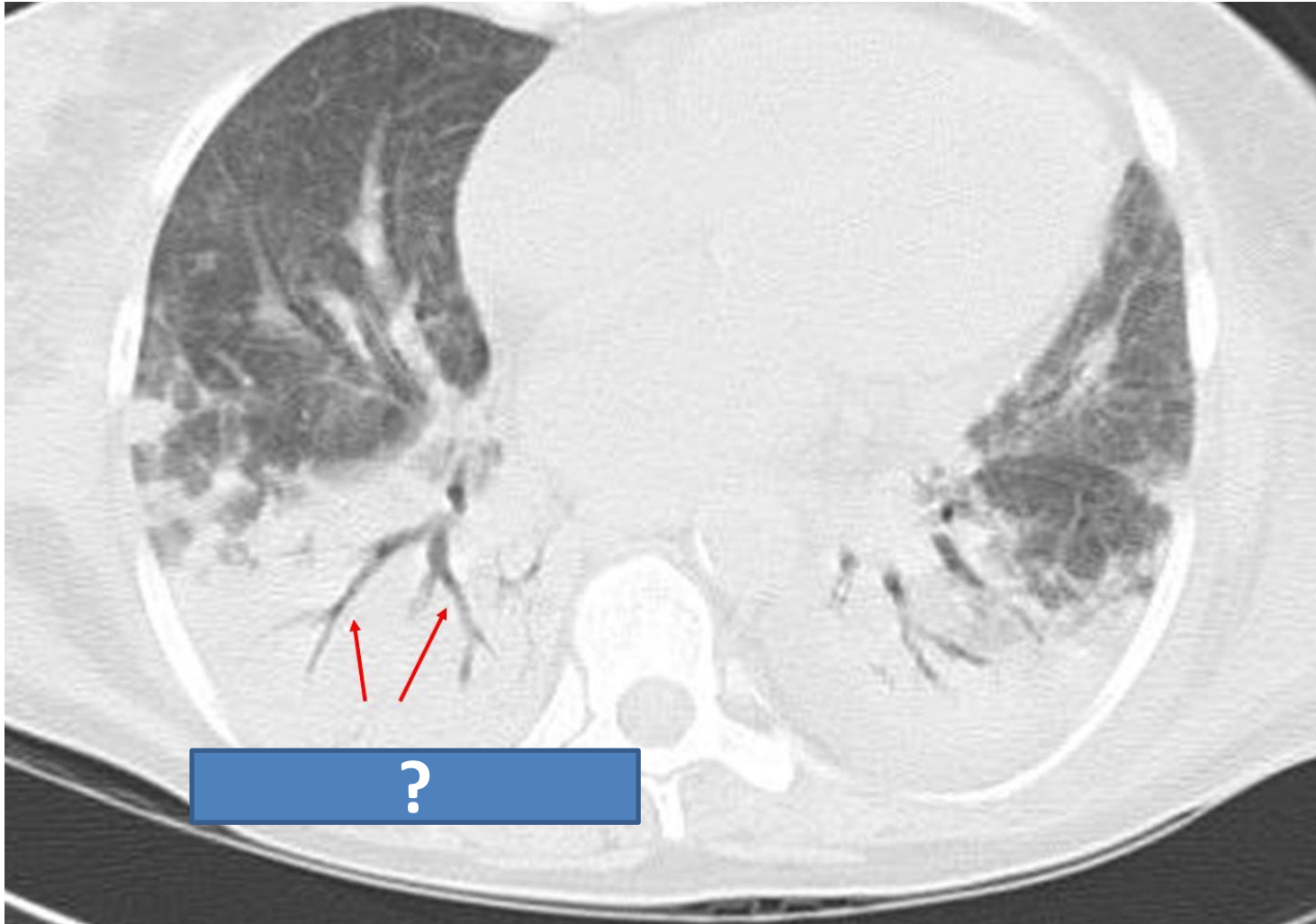
# Radiological Anatomy of the Chest

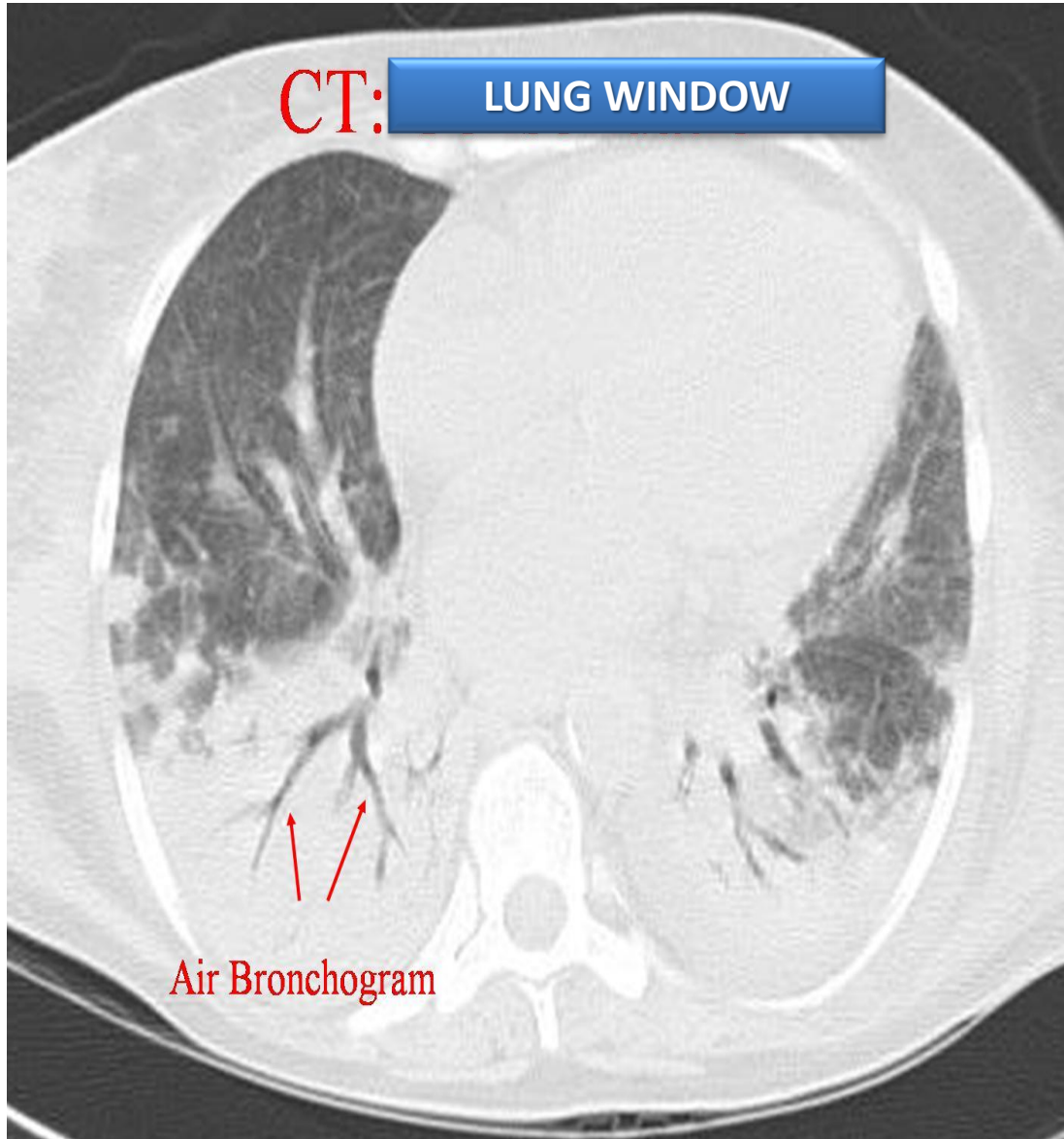


EXAM?  
NORMAL/ABNORMAL?

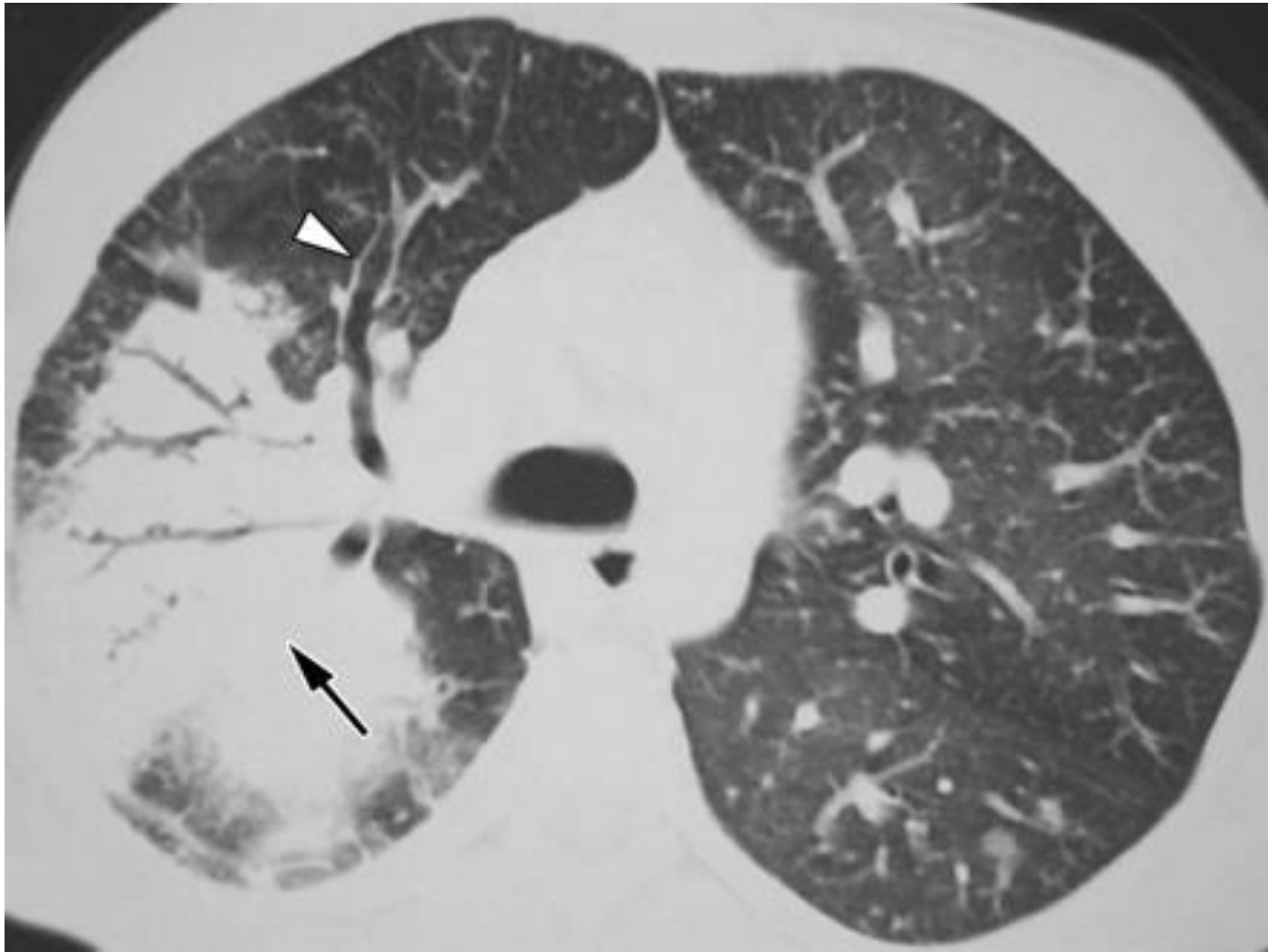


**1-EXAM**  
**2-SIGN?**  
**3-DIAGNOSIS?**



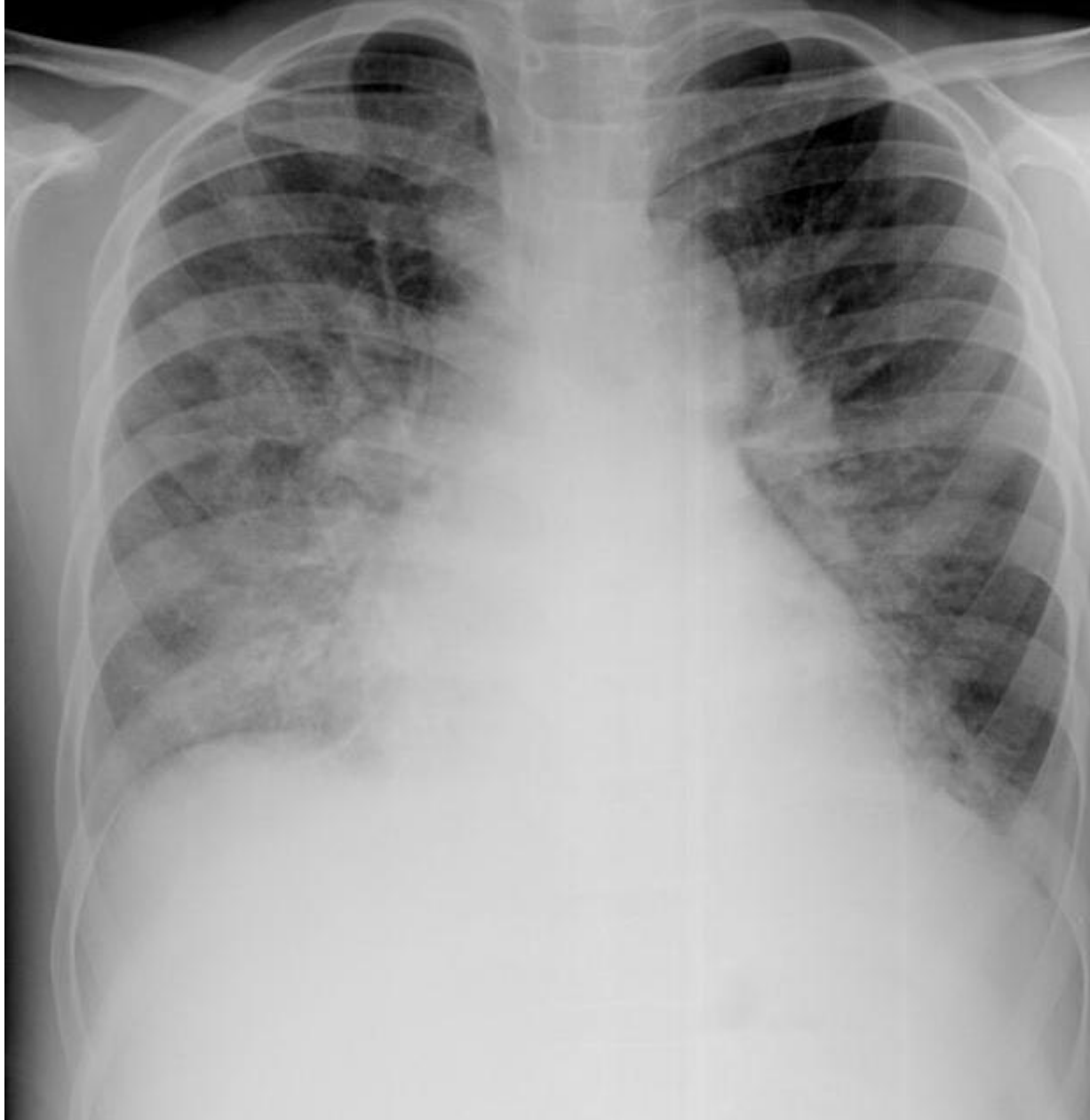

# Consolidation



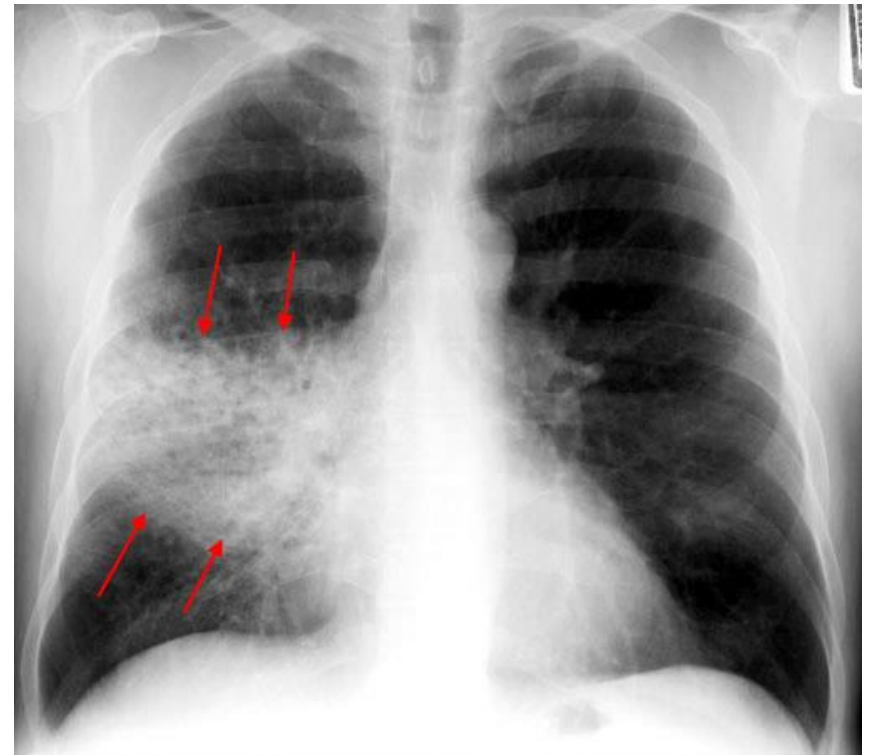
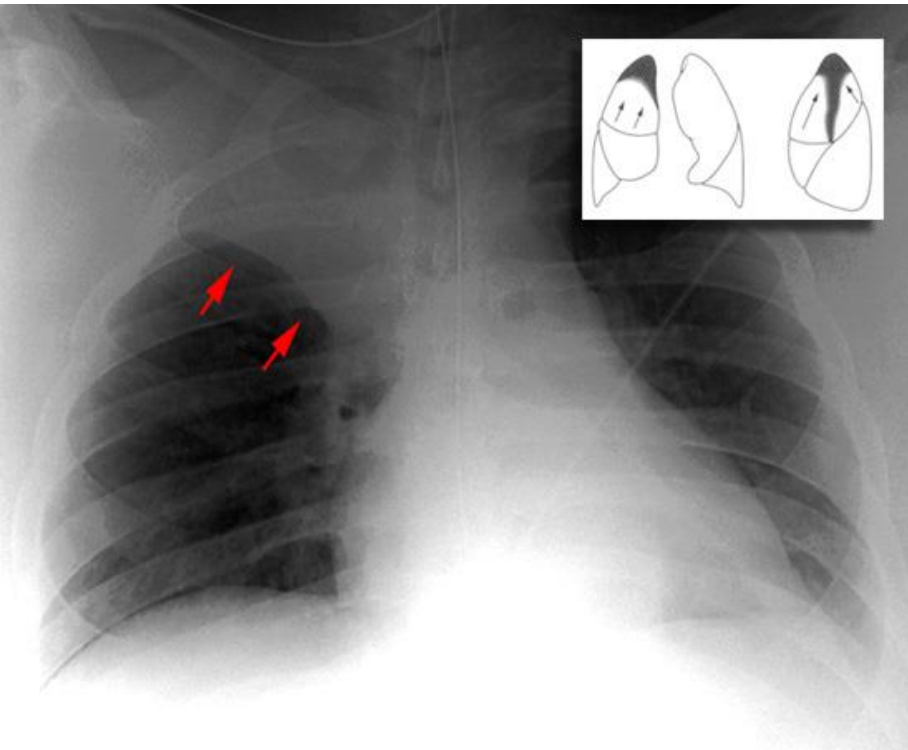
**1-EXAM**  
**2-SIGN?**  
**3-DIAGNOSIS?**

# MASS OR INFILTRATION

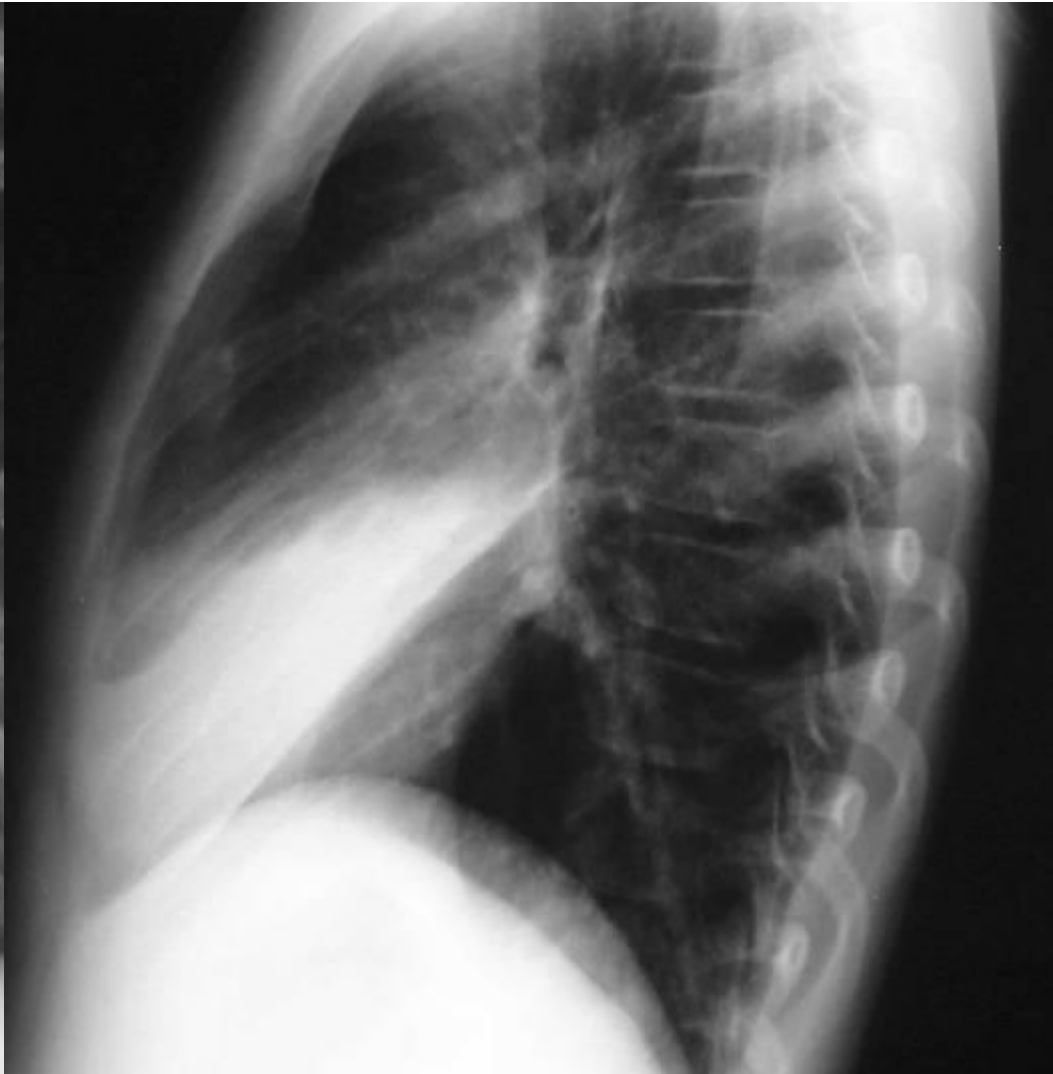
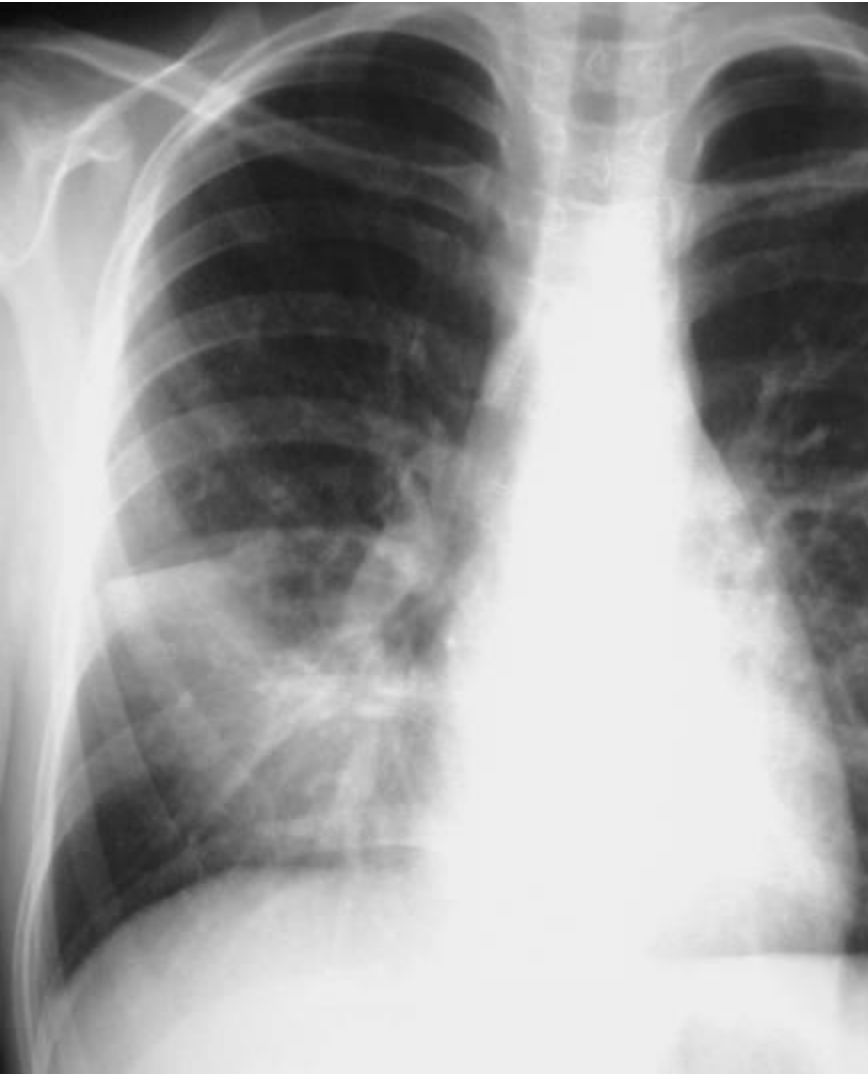


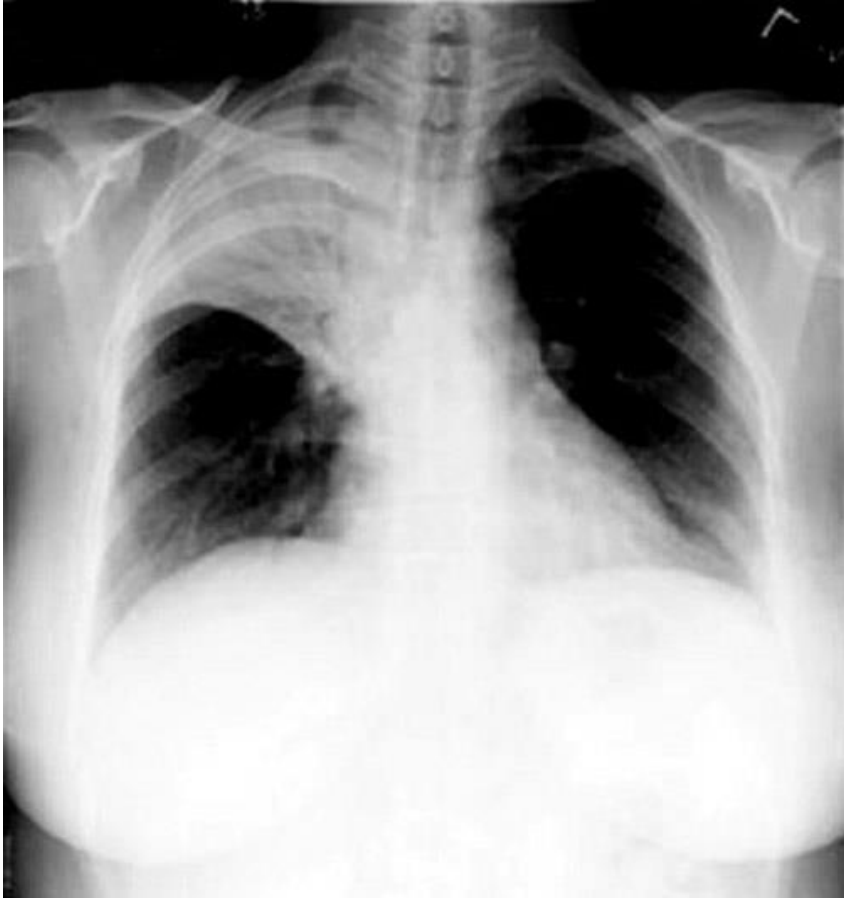# ATELECTASIS Vs PNEUMONIA



Right ????? lobe ??????

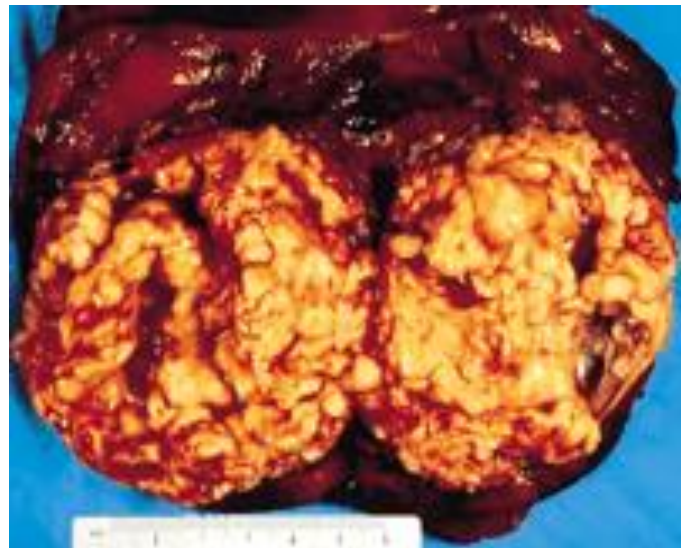
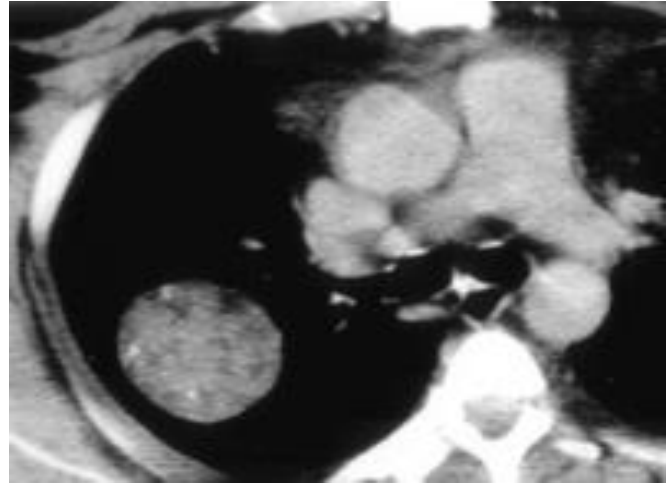
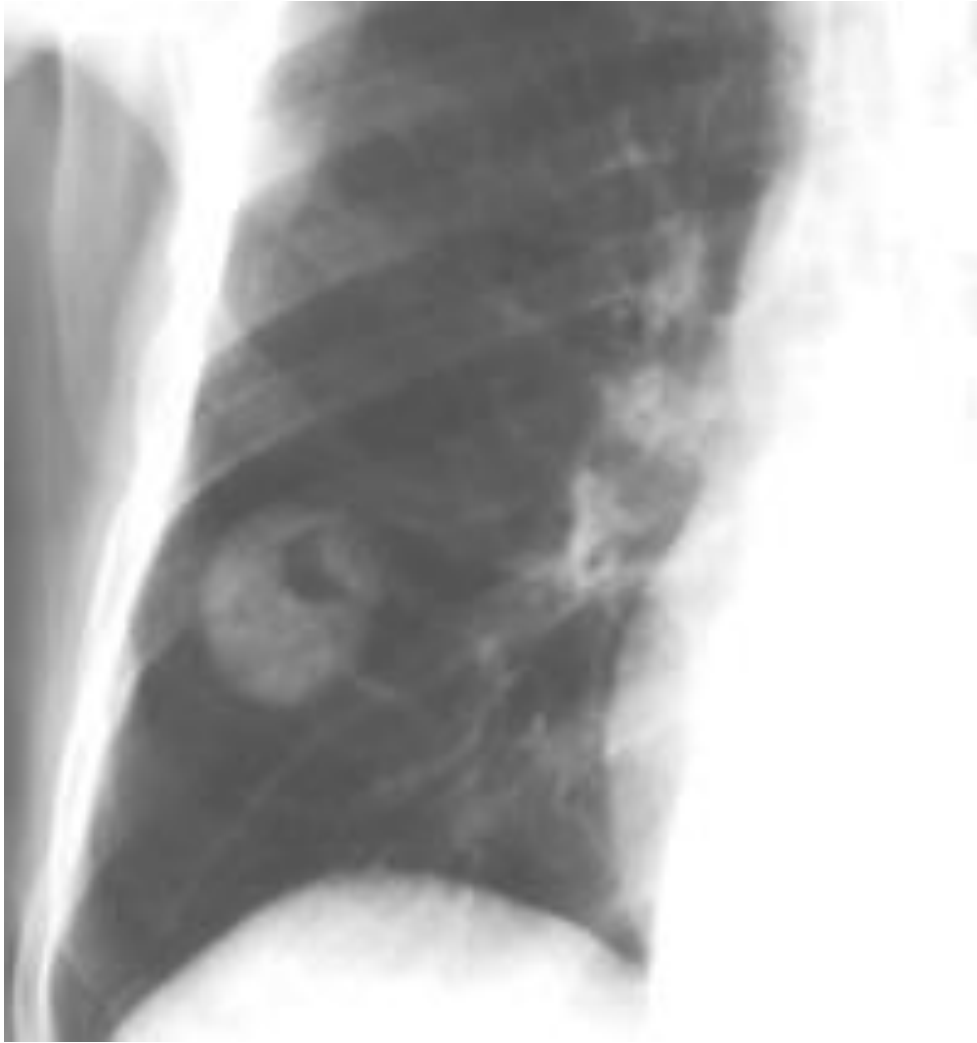

# DIAGNOSIS

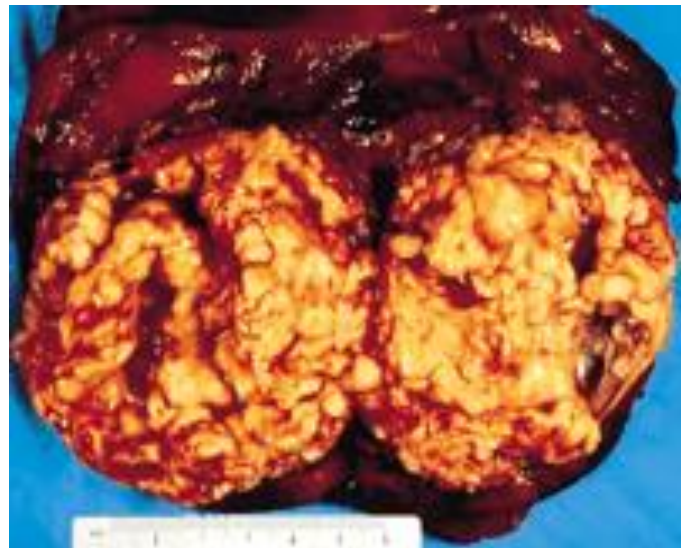
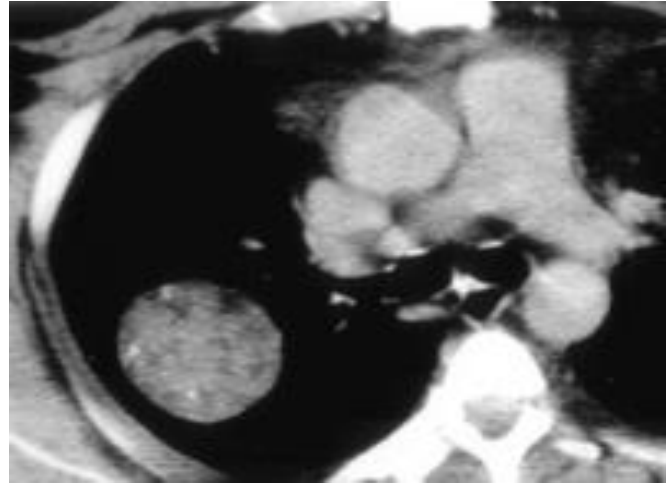


- 37 YEARS OLD PATIENT WITH SOB AND FEVER.

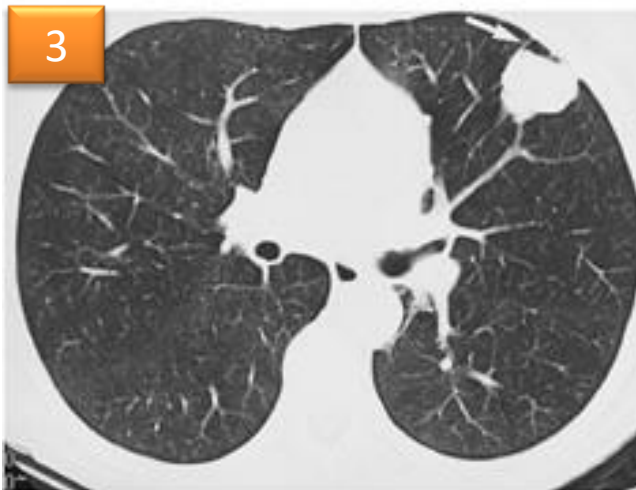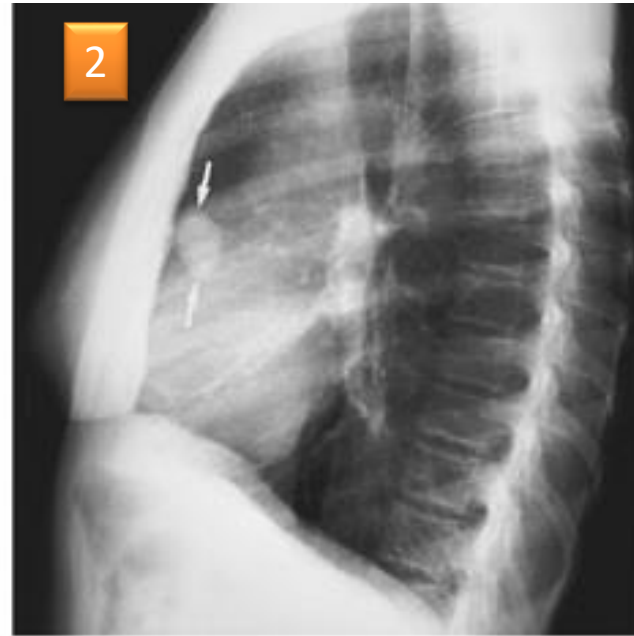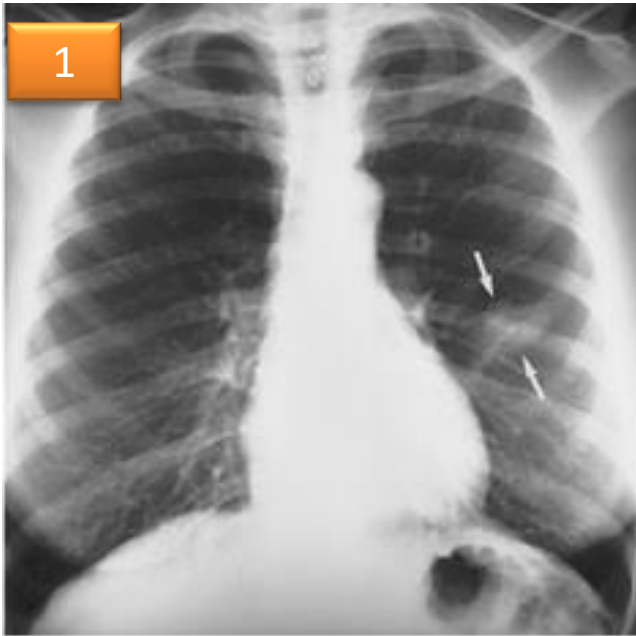
# MASS OR INFILTRATION ?



# *Neoplastic: MASS*

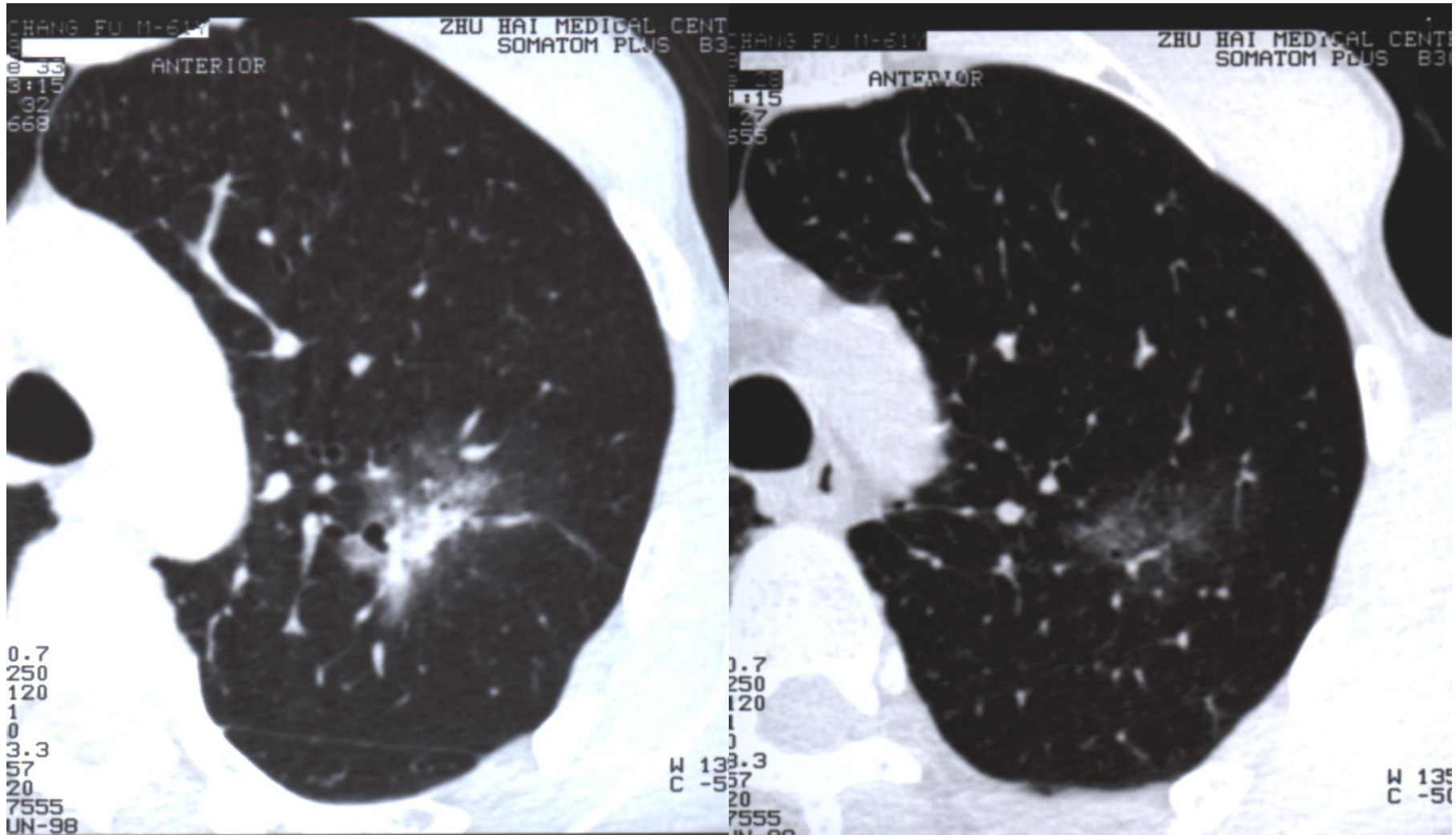


# MASS OR INFILTRATION ? STEPS

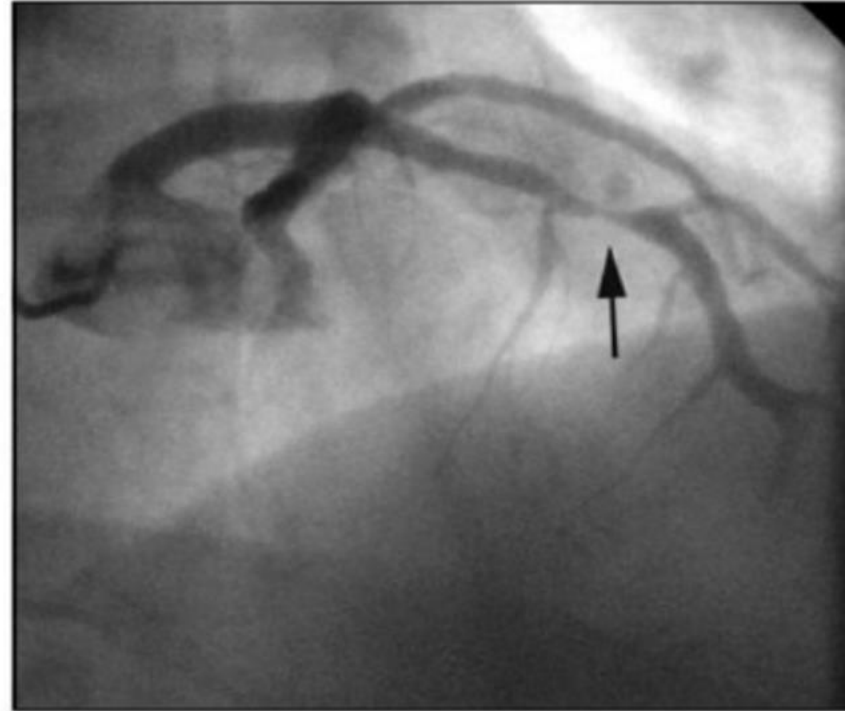
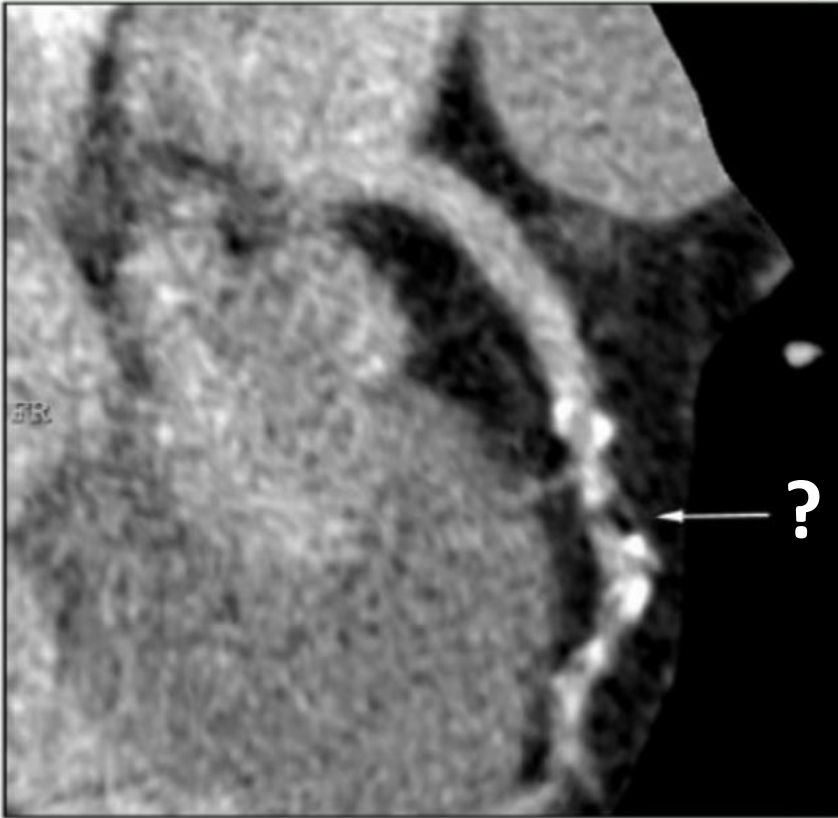


← ---?--- WINDOW

# MASS OR INFILTRATION?

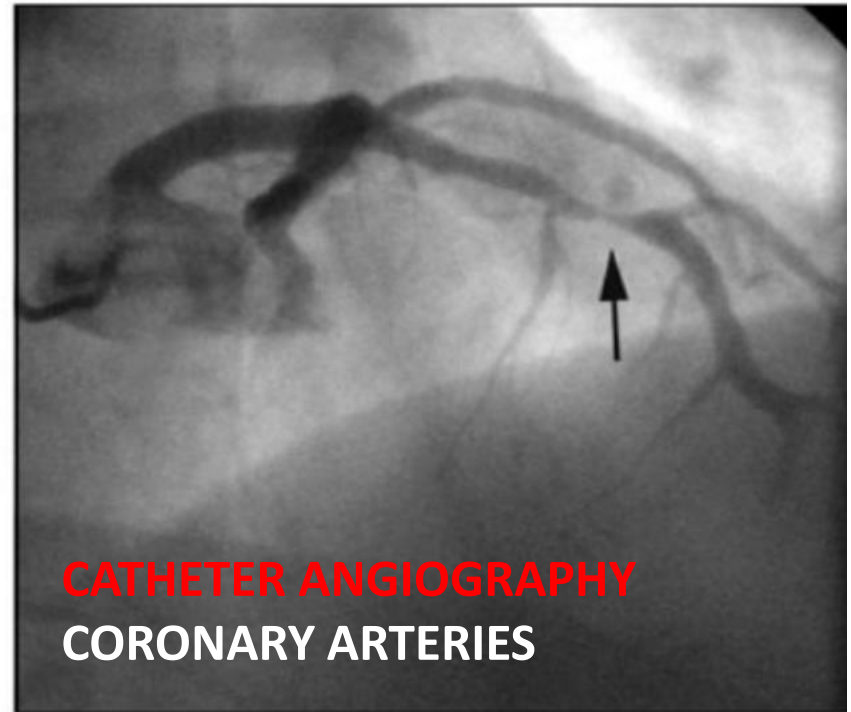
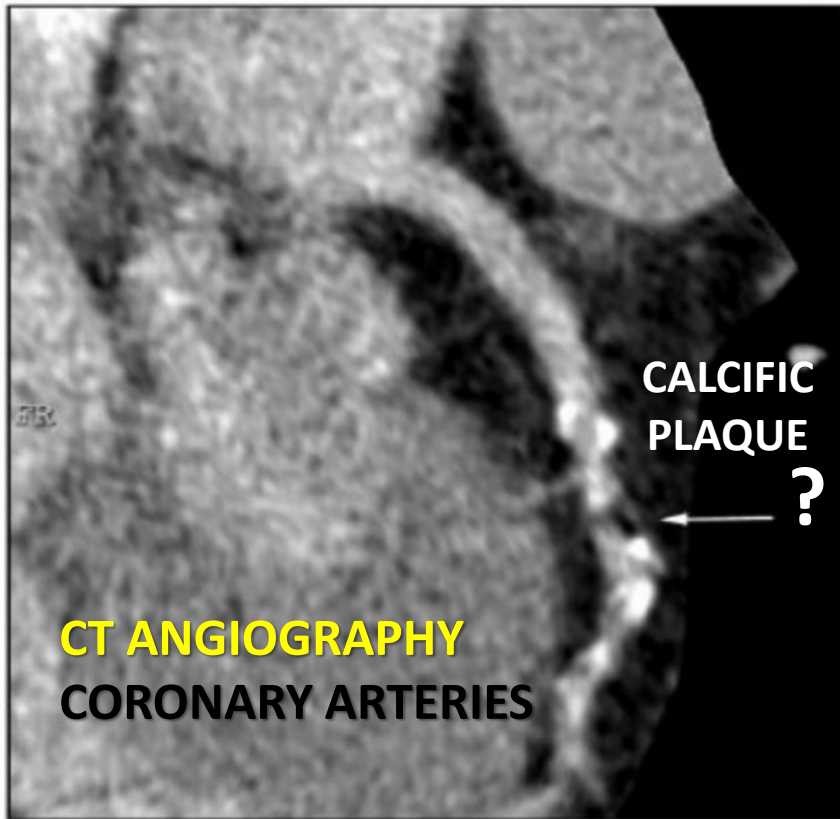


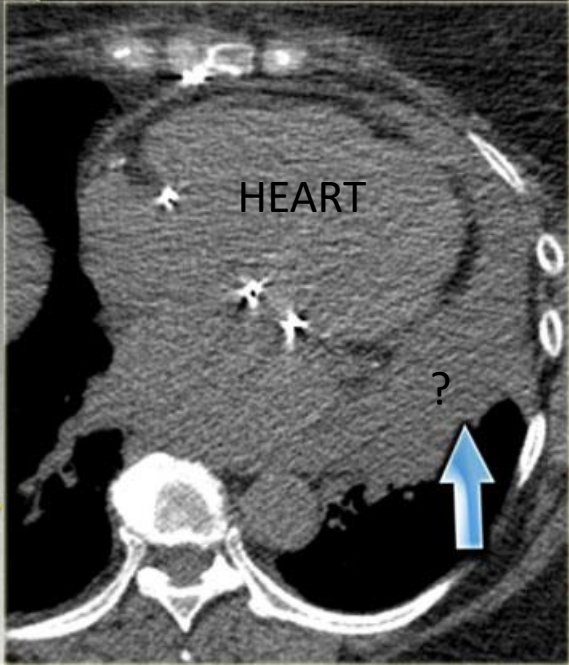
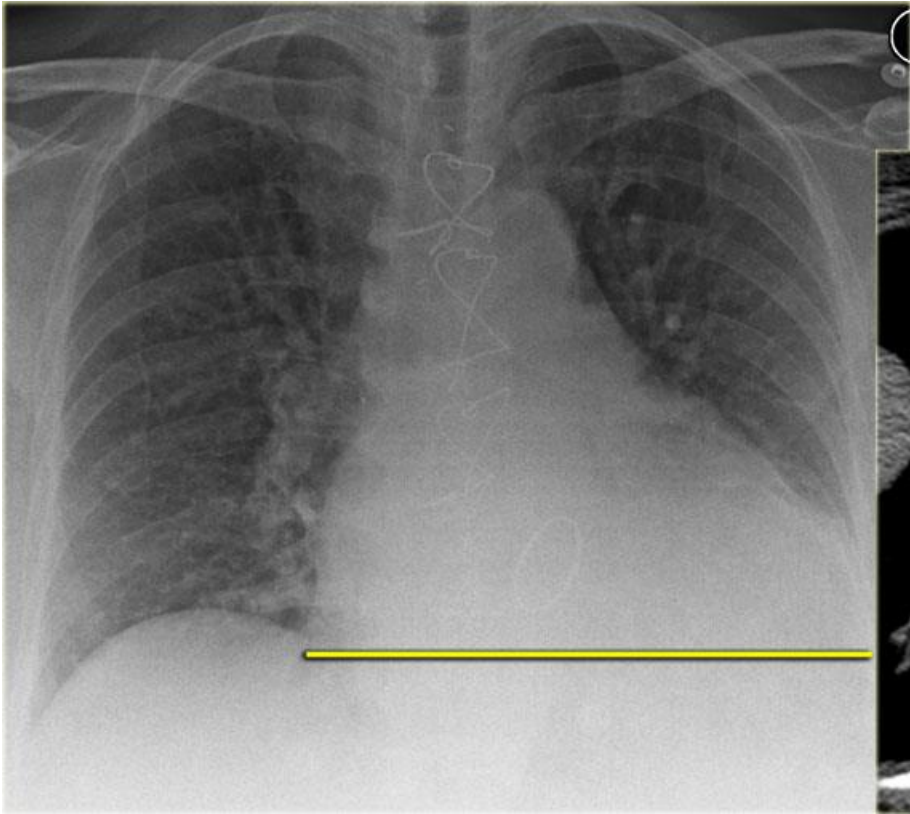
# EXAM?



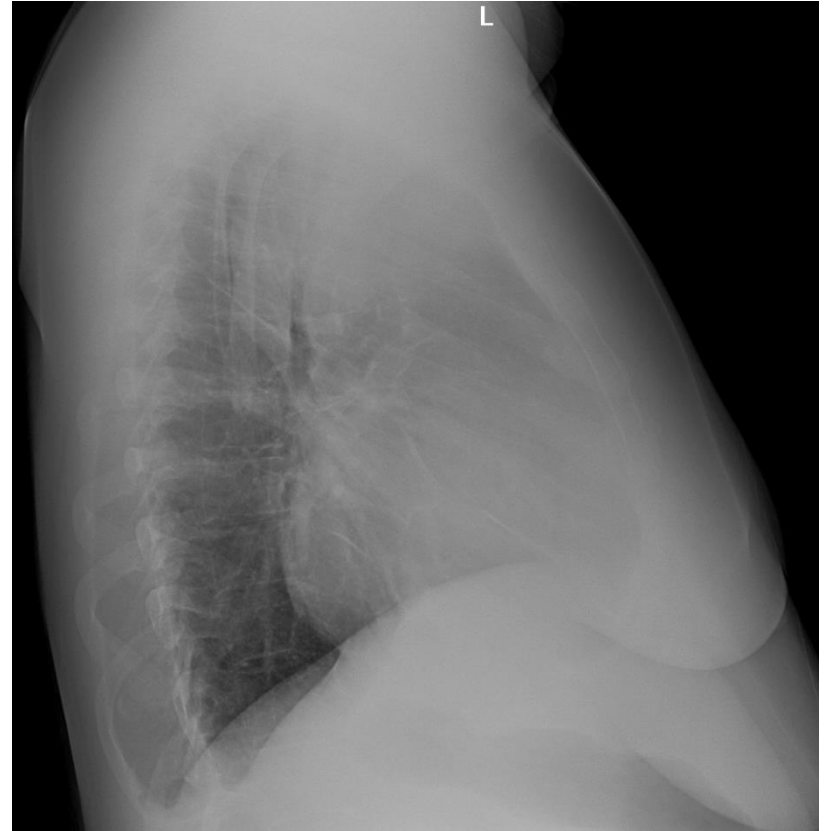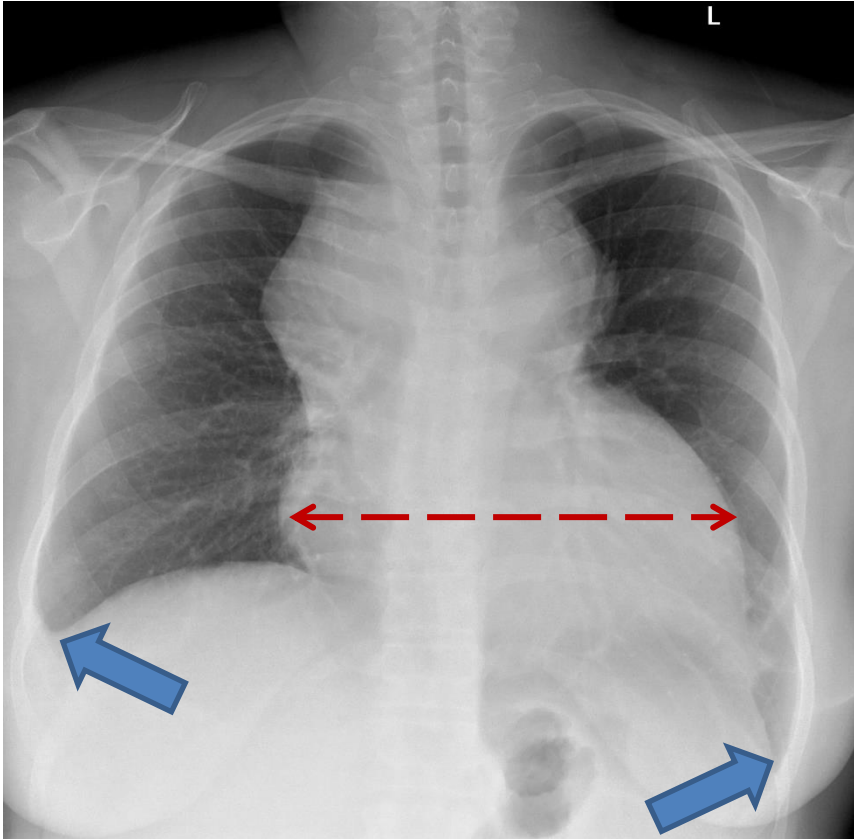


# EXAM?

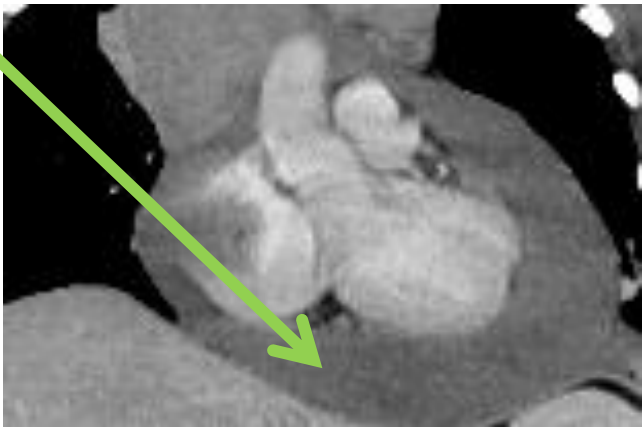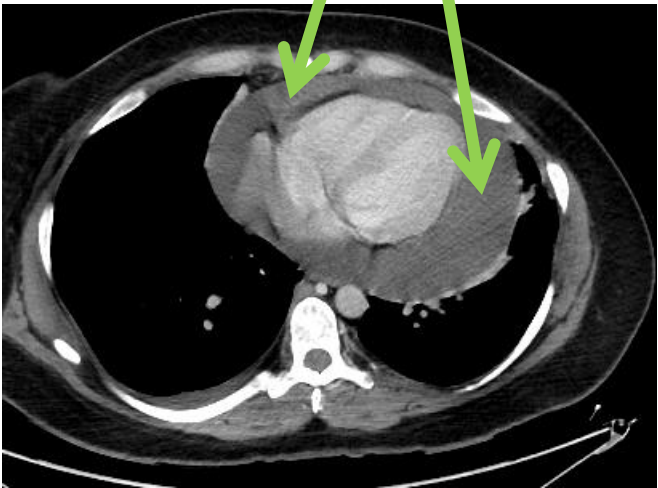
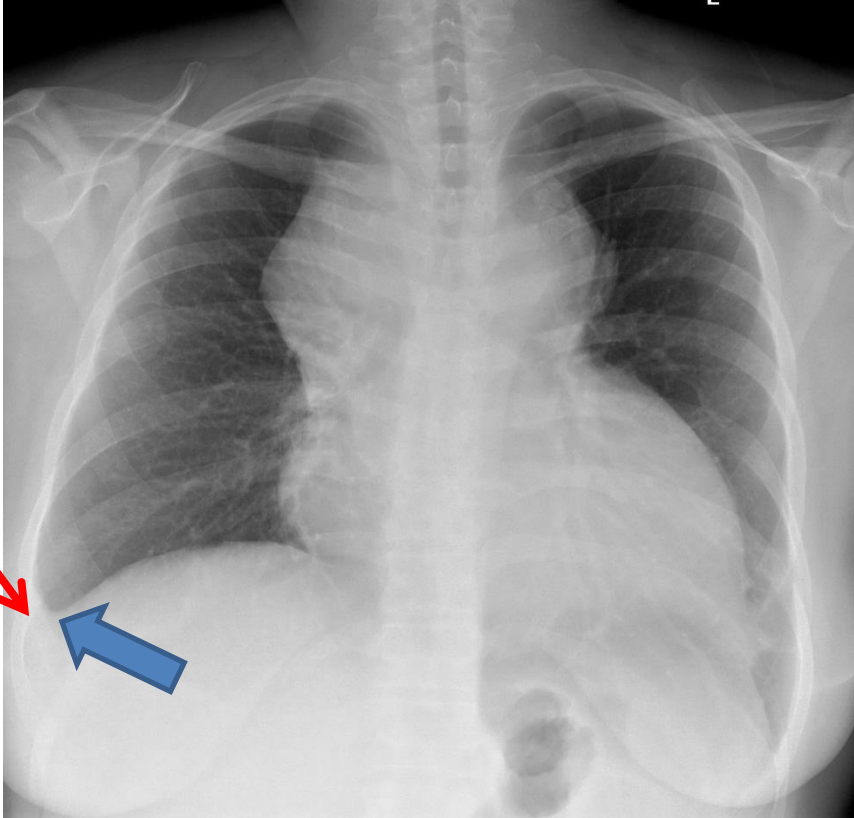




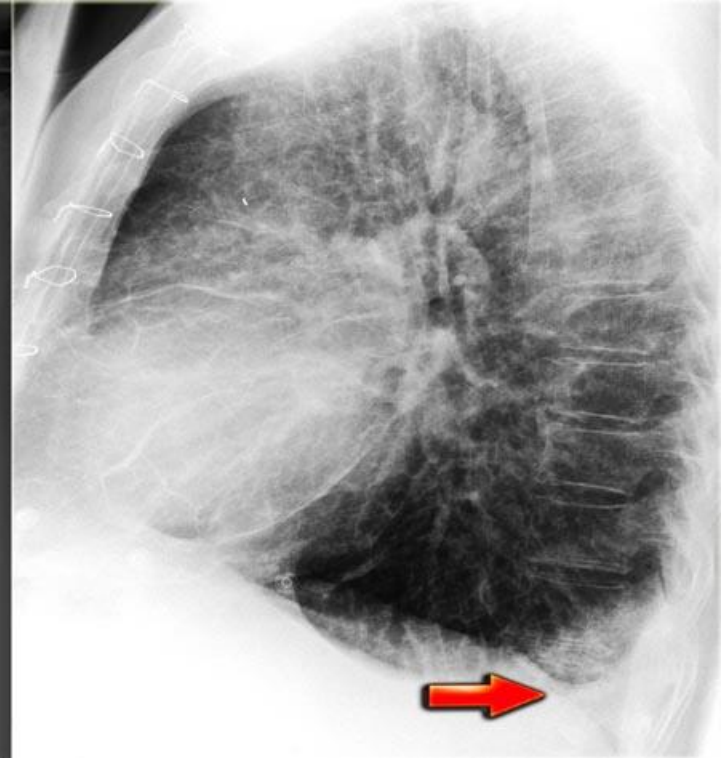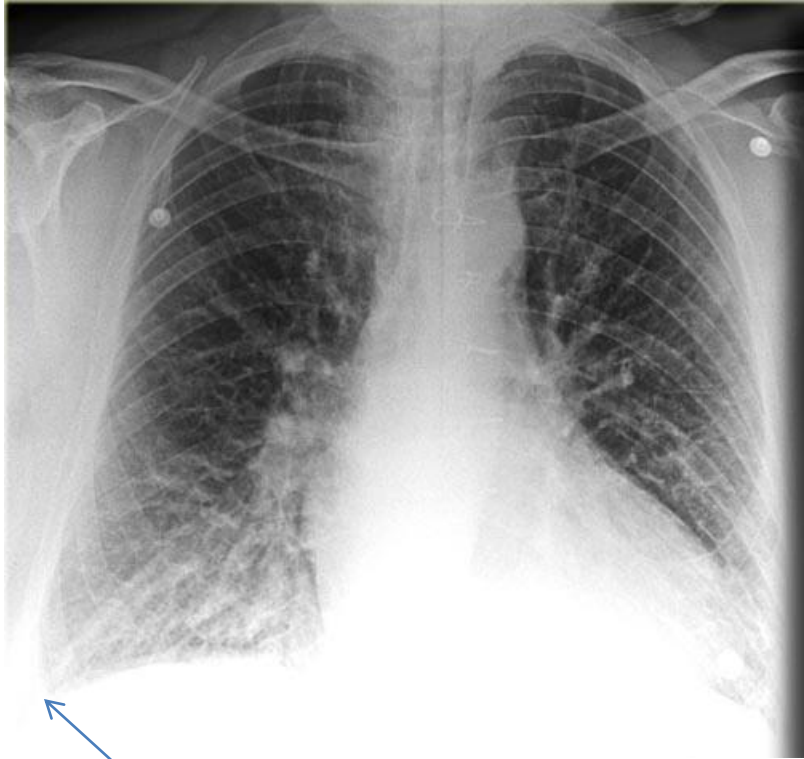
# Heart ?



# Pleural effusion and pericardial effusion

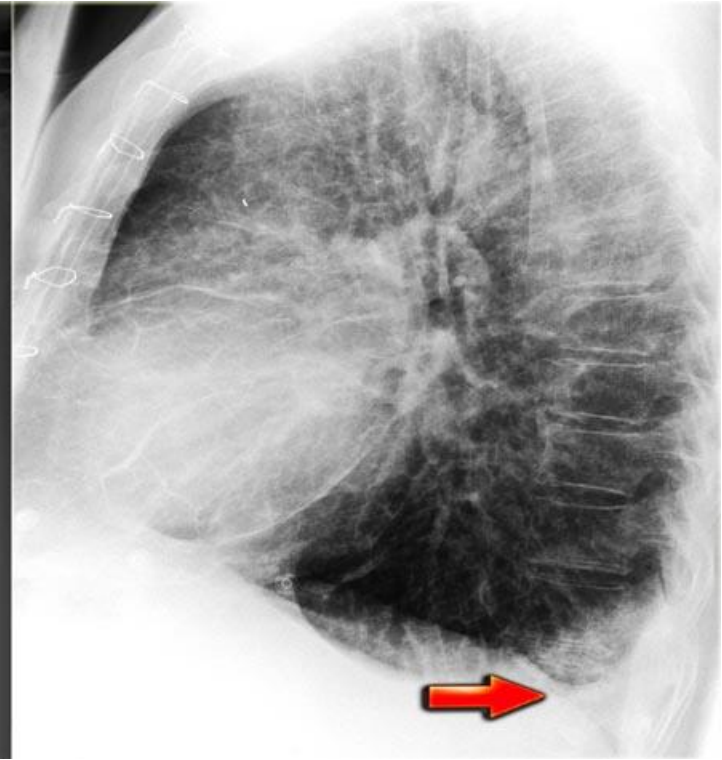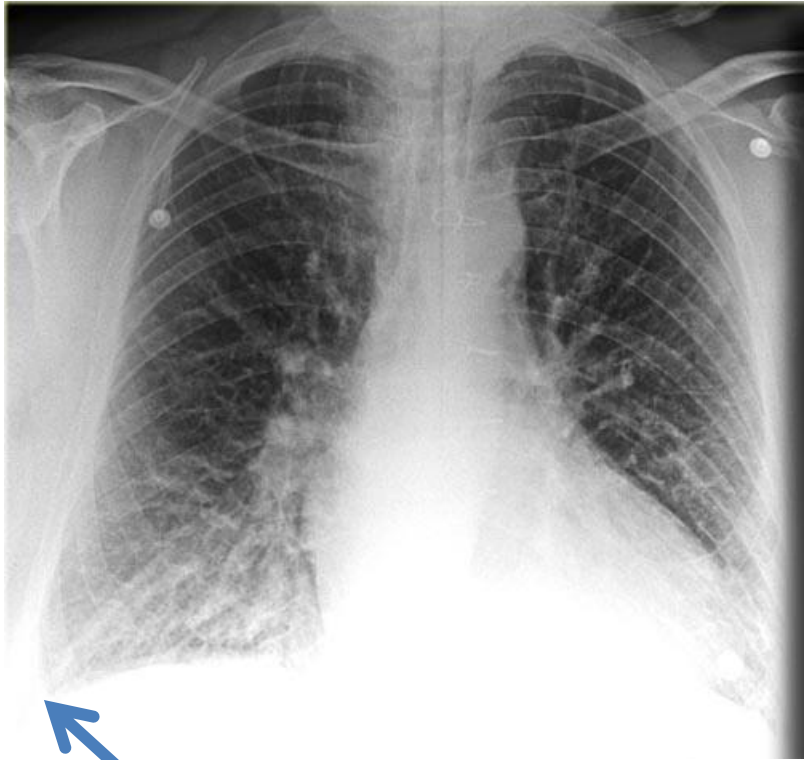


# ABNORMAL? DIAGNOSIS?

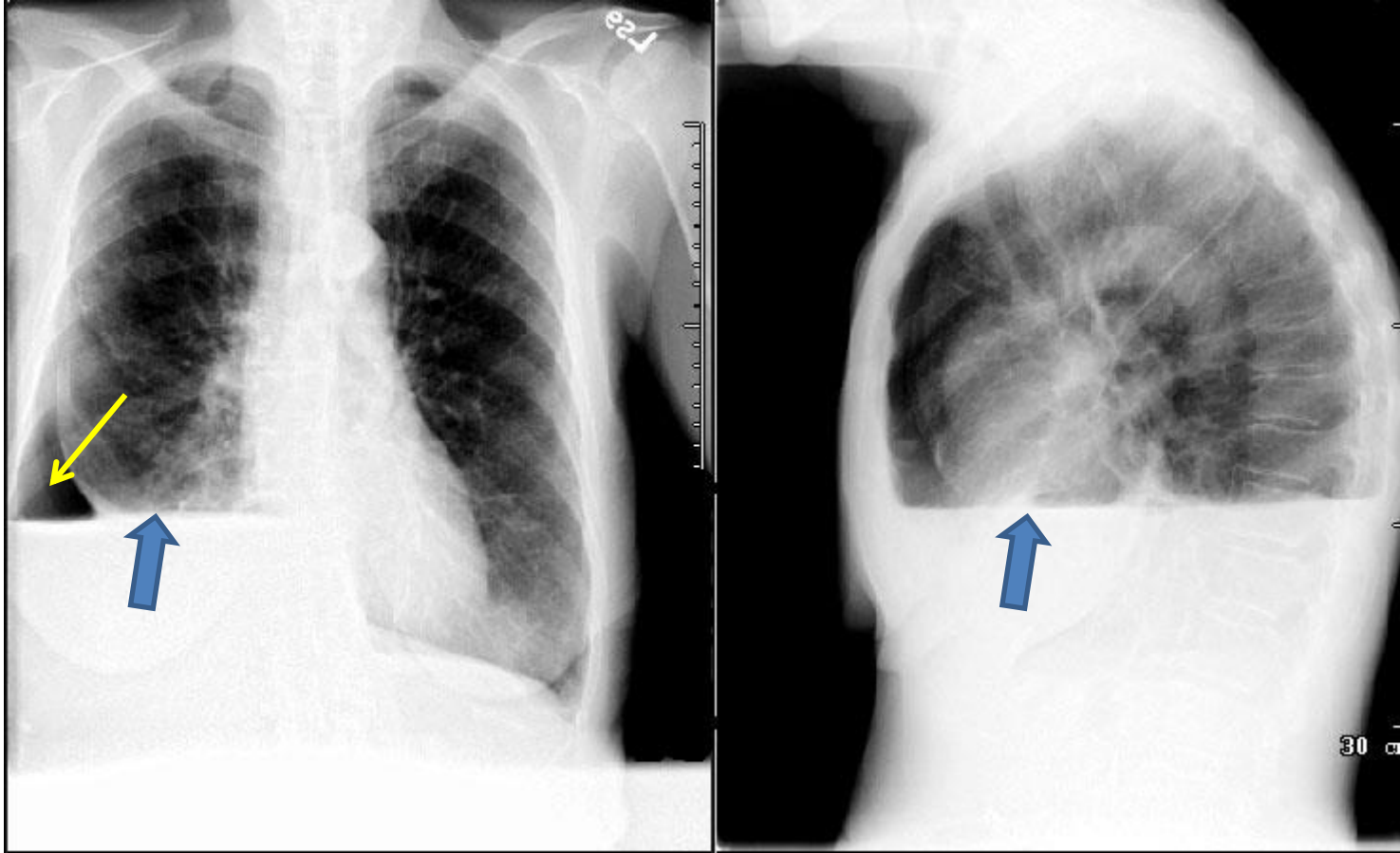


# BLUNTED RIGHTCOSTOPHRENIC ANGLE

DIAGNOSIS: PLEURAL EFFUSION.



?????



# HYDRO-PNEUMOTHORAX

