



### Objectives

- ❖ There is no lecture objectives so,
- ❖ You're off to great places, today is your day.
- ❖ No one is perfect - that's why pencils have erasers.
- ❖ Winning is fun, but those moments that you can touch someone's life in a very positive way are better
- ❖ (اللهم لا سهل إلا ما جعلته سهلاً، وأنت تجعل الحزن إذا شئت سهلاً)

Reviewed By



Noura Alturki  
Jehad Alorainy

Color Index:

♦ Important

♦ Doctor's Notes

♦ Extra

♦ Female slides

♦ male slides

### Team Leaders



Omar Aldosari



Leena Alnassar



Shahd Alsalamh

Done by:

Abdullah Alassaf

Revised by:

# Name 5 radiological modalities

- **X-Ray**

- To see normal bowel gas distribution
- If there's any air fluid level
- The standard X-ray view is erect(for air fluid level) and supine(for bowel dilatation)

- **Fluoroscopy**

- Stomach=barium meal
- Small bowel=barium follow through
- Colon=barium enema

- **Ultrasound**

- **Nuclear medicine**

- **CT scan**

- If we discovered any lesion on abdominal X-ray or fluoroscopy and we want to characterize it we do CT SCAN
- in all cases of acute abdomen or trauma patients we start with CT scan

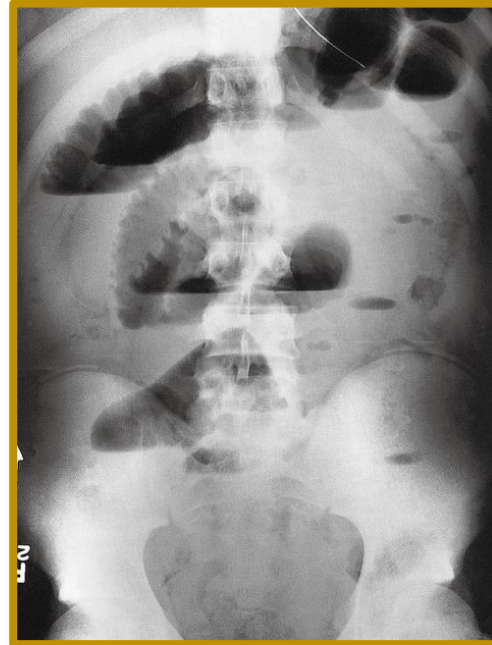- **MRI**

- For more details we do MRI

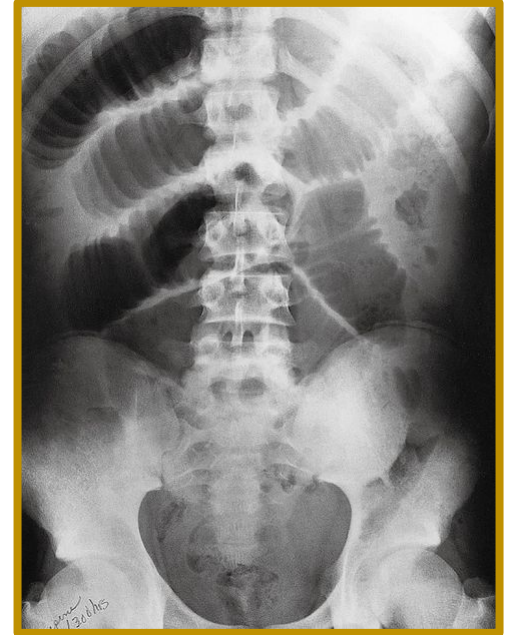
- **Angiography**

# Case 1

- What is the modality?
- Mention 2 abnormalities?
- What is the diagnosis?



Picture 1



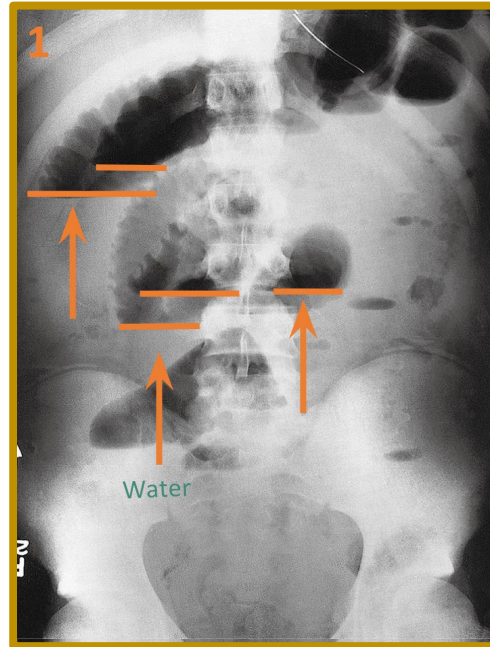
Picture 2

- **What is the modality?**

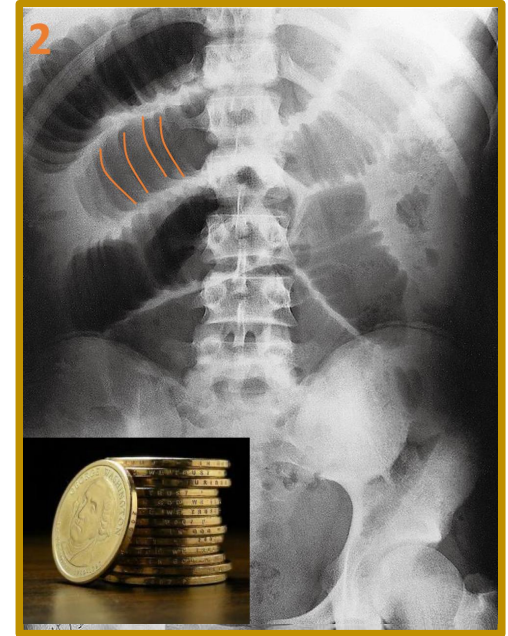
- Plain abdominal X-RAYS.
- No contrast unlike fluoroscopy.
- Pictures 1 : Erect position.
- Picture 2 : Supine position .

- **Mention 2 abnormalities?**

- **Picture 1:**
  - Multiple air-Fluid levels.
  - colon cannot be seen
  - there is opacity within the rectum
- **Picture 2:**
  - Stack of coins signs (indicate mucosal fold thickening)
  - **multiple dilated bowels**(the maximum bowel dilatation regarding the small bowel=3cm ,more than 3=dilated loop)



Picture 1



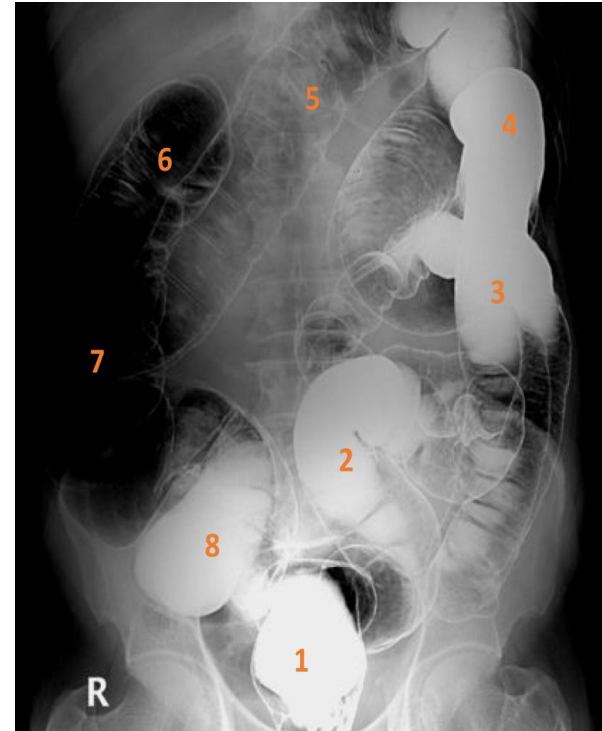
Picture 2

- **What is the diagnosis?**

- **Mechanical bowel obstruction**

## Case 2

- What is the name of the study?
- Name the labelled structures?

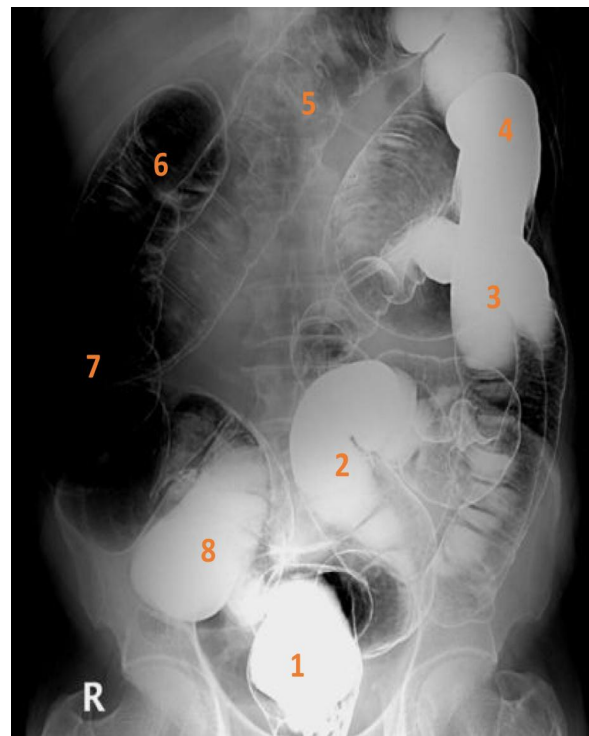


- **What is the name of the study?**

- Air double contrast **barium enema**.

- **Name the labelled structures?**

1. Rectum.
2. Sigmoid colon.
3. Descending colon.
4. Splenic flexure.
5. Transverse colon.
6. Hepatic flexure.
7. Ascending colon.
8. Cecum.

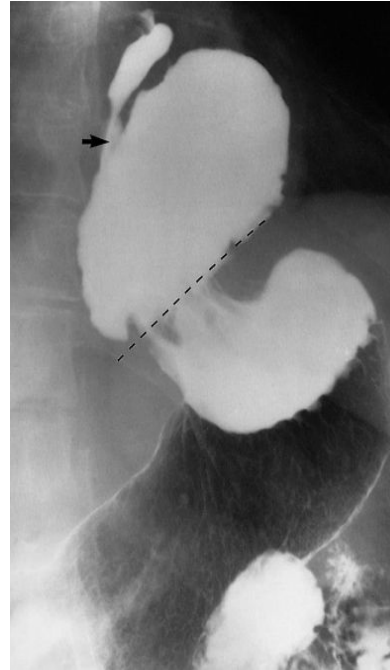

- Barium enema has two types:

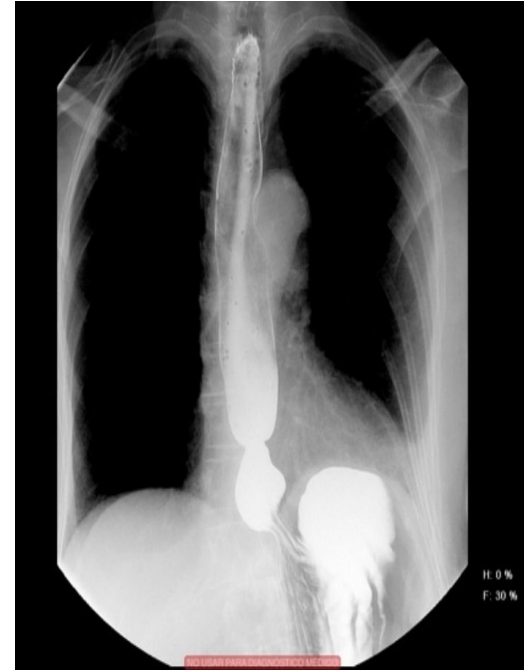1. **Single contrast barium enema** (No air). For example 8,1,2,3,4 are seen with single contrast and the rest in double contrast
  2. **Double contrast barium enema** (Air & barium) If you see clear bowel wall with gas it's double as in this image, it gives better idea about any mucosal abnormality (ulceration, lesion. etc..).so we evaluate the area using double contrast
- Normally we shouldn't see ileocecal valve or terminal ileum in barium enema of a normal patient.

# Case 3

- What is the modality? (picture 1)
- What is the diagnosis? (picture 1)



Picture 1



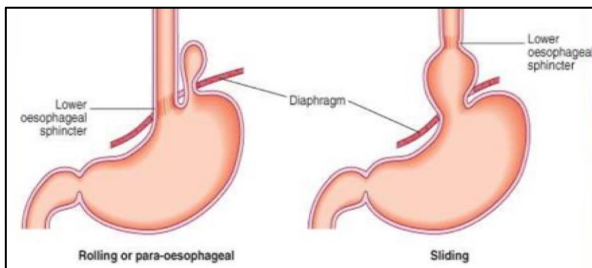
Picture 2

- **What is the modality?**

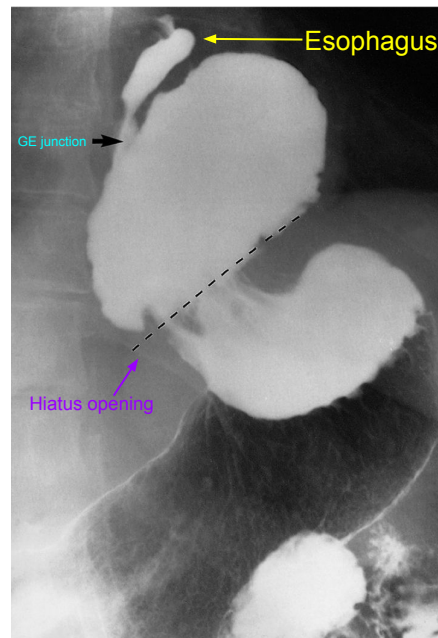
- **Fluoroscopy** (Barium meal).

- **What is the diagnosis?**

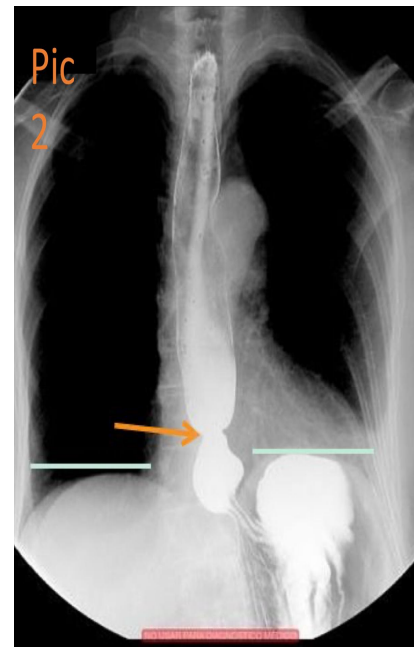
- **Hiatus hernia. pic1=(large) pic2=(small)**
- The lower esophageal sphincter normally will be **on the line with diaphragm** But here it's not and part of the gastric fundus is seen above the level of hiatus opening, so it's sliding hernia (as the green lines in pic2 represents the normal level of the **diaphragm**).



Types of hiatus hernia



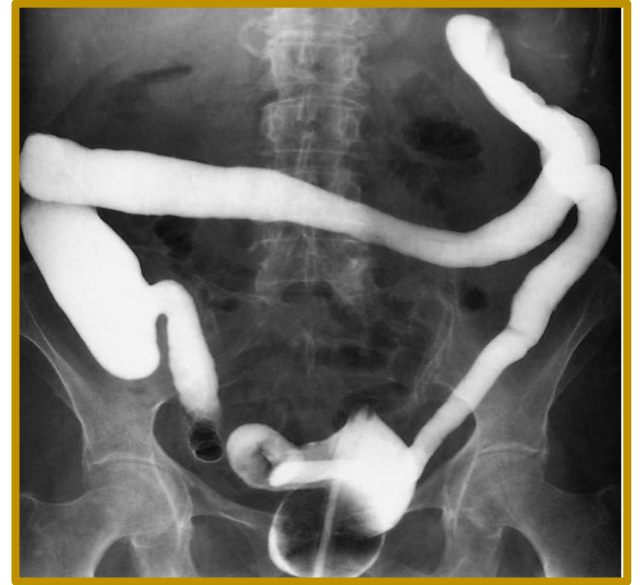Picture 1



Picture 2



- What is the modality?
- What is the name of the sign?
- What is the diagnosis?



- **What is the modality?**

- Barium enema- Fluoroscopy
- Single because we don't see the wall of bowel nor we see gases.

- **What is the name of the sign?**

- Lead pipe sign.
- The colon is identified by its haustration(mucosal folding) but here we cannot see any haustration and the whole colon is of small caliber

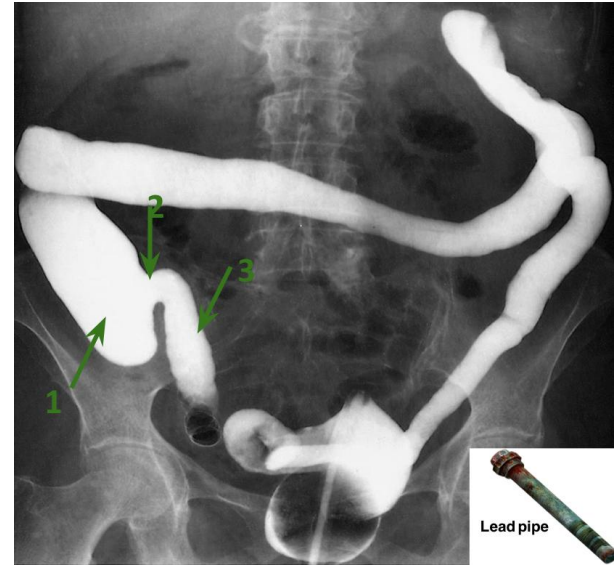
- **What is the findings?**

- Rigid colon with no haustration

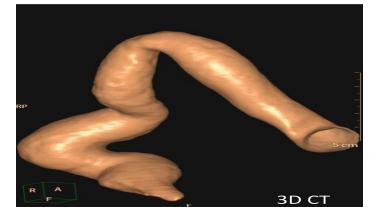
- **What is the diagnosis?**

- IBD - Ulcerative colitis

(Continuous start from rectum then extends proximal even terminal ileum can be involved sometimes calling it **backwash ileitis** )



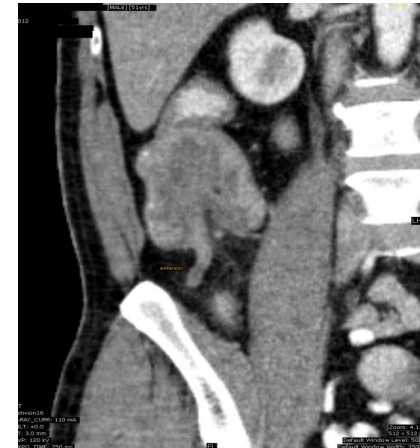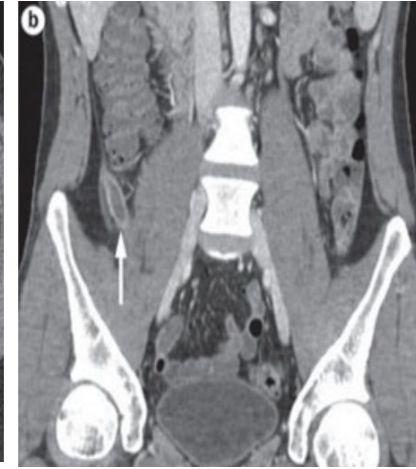
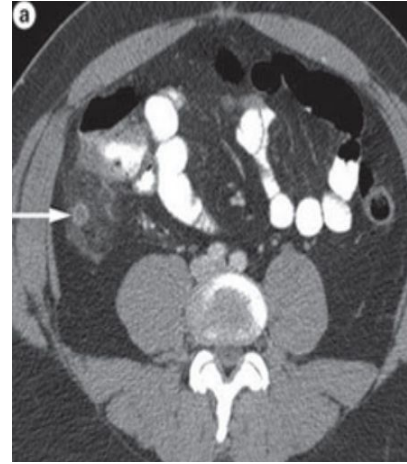
1. Cecum.
2. Incompetent ileocecal valve.
3. Terminal ileum.



Another example of lead pipe colon  
(featureless colon)

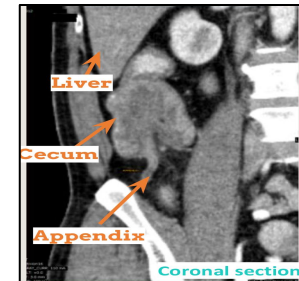
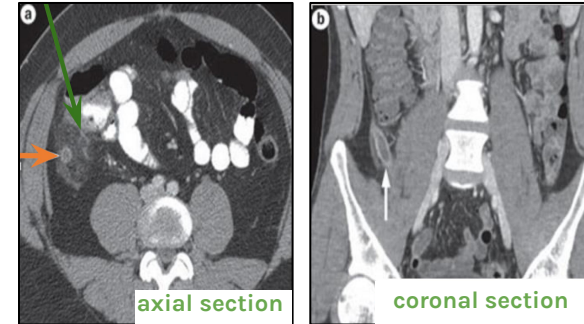
# Case 5

- What is the name of the study?
- What is structure labeled on the image a ?
- What is the findings?
- What is the diagnosis of the patient on image b ?
- What is the gold standard imaging modality for such diagnosis? And what is the alternative image modality in pregnant/pediatric patients?



# Case 5

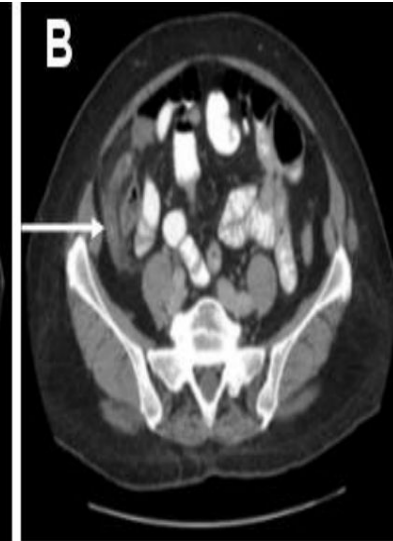
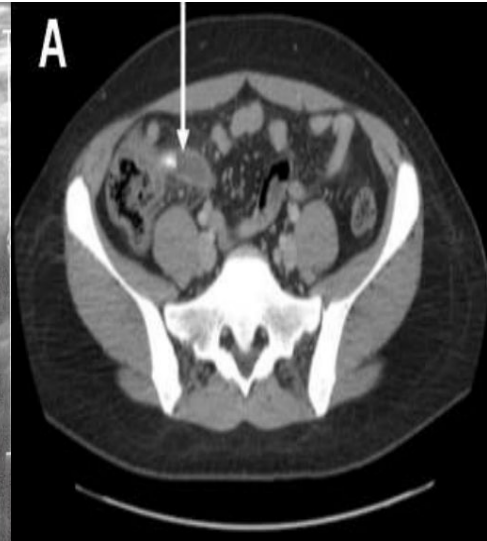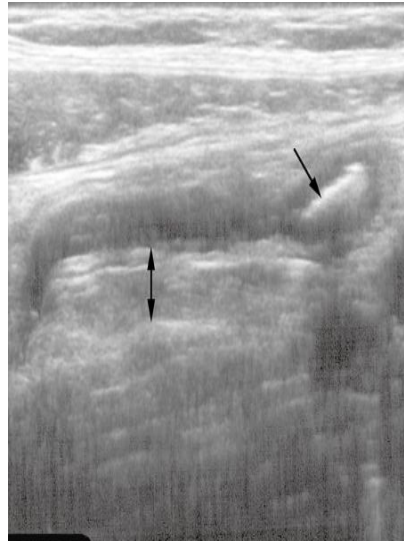
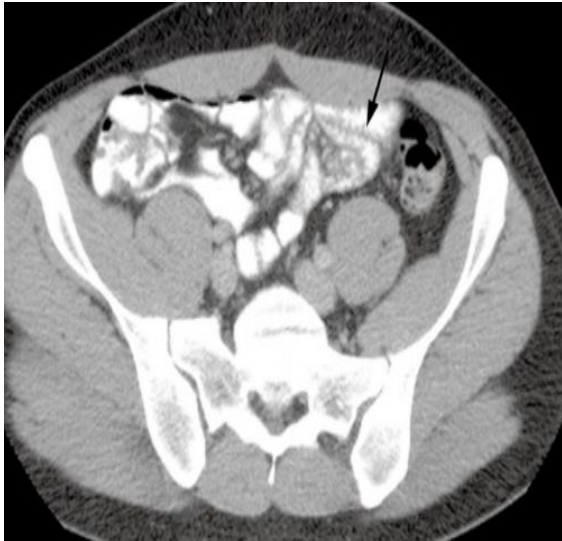
- **What is the name of the study?**
  - **CT scan** (with IV and oral contrast. The oral contrast is seen within the bowel lumen).
- **What is structure labeled on the image a (axial section)?**
  - **Appendix**
- **What is the findings?**
  - **enlarged appendix**
  - **Enhanced wall**
  - **Fat around the appendix is inflamed**
- **What is the diagnosis of the patient on image b (coronal section )?**
  - **Simple appendicitis.**
- **What is the gold standard imaging modality for such diagnosis? And what is the alternative image modality in pregnant/pediatric patients?**
  - **CT scan + contrast** is the gold standard, **U/S** is the alternative for pediatric & pregnant.



Abnormal appendix

## Case 5, Cont...

- Appendix should not exceed **6mm** in diameter..
- The surrounding fat should be **clear**.
- Appendix normally is **compressible** by US probe. but here the wall is rigid so the the appendix as whole will get lower when pushed with the probe (**not compressible = abnormal = appendicitis**).
- Normally, there will be no appendicolith (lith=**stone**, in appendix).

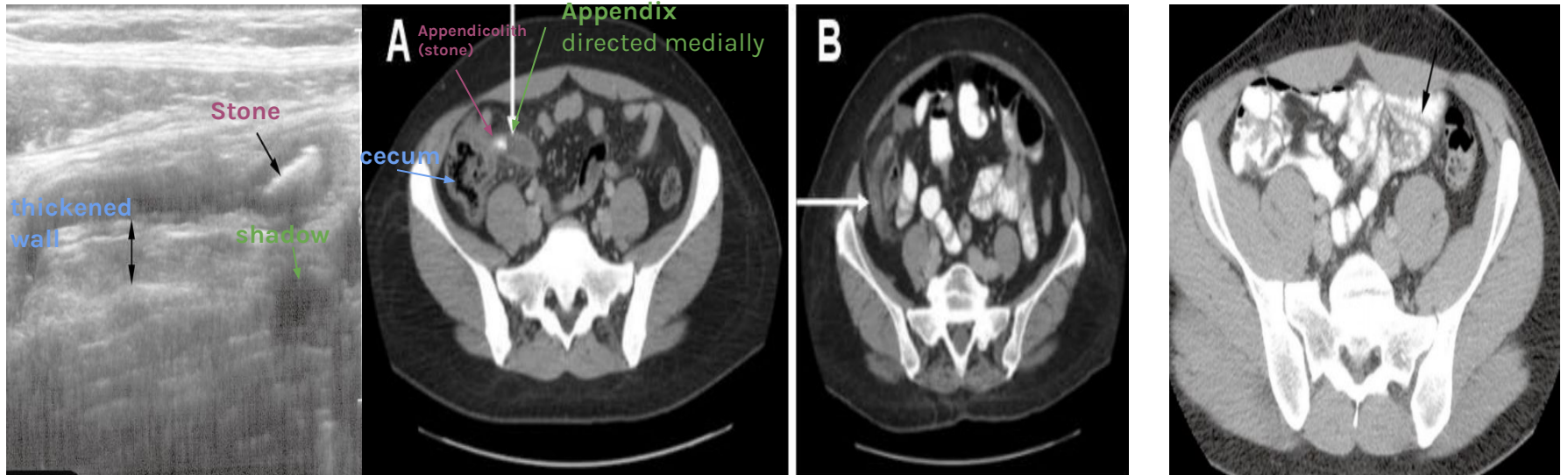


## Appendicitis on Ultrasound

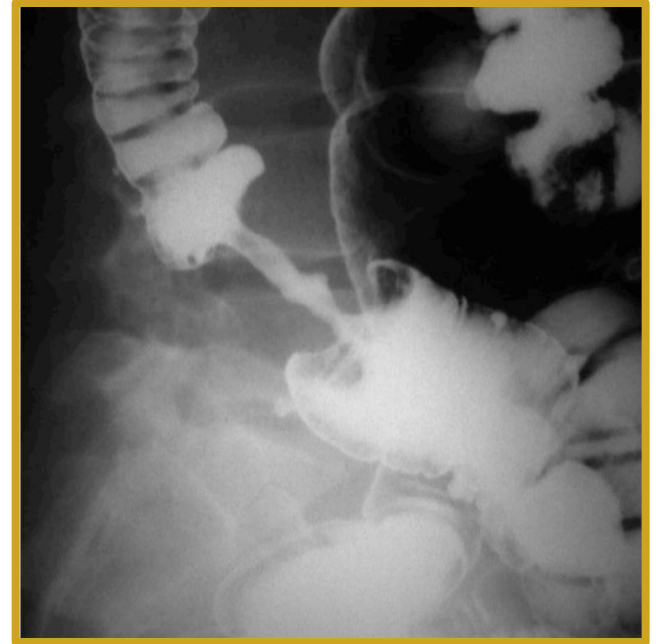tubular end structure within the right iliac fossa with diameter more than 6mm and when we try to compress it by probe it won't be compressible and you can see appendicolith within the lumen

## Signs of appendicitis:

- Dilated diameter (normal diameter of appendix is 0.6 cm or 6 mm).
- Hyper-attenuation (or stranding) of periappendicular fat.
- Enhancing of wall (thick wall).



- What is the name of the study?
- What is the findings?
- What is the pertinent sign?
- What is the diagnosis?



- **What is the name of the study?**
  - **Double contrast Barium enema.**
- **What is the findings?**
  - **Focal area of luminal narrowing with irregular outline**
- **What is the pertinent sign?**
  - **Apple-core sign.**
- **What is the diagnosis?**
  - **Colon cancer, 100% until proven otherwise.**

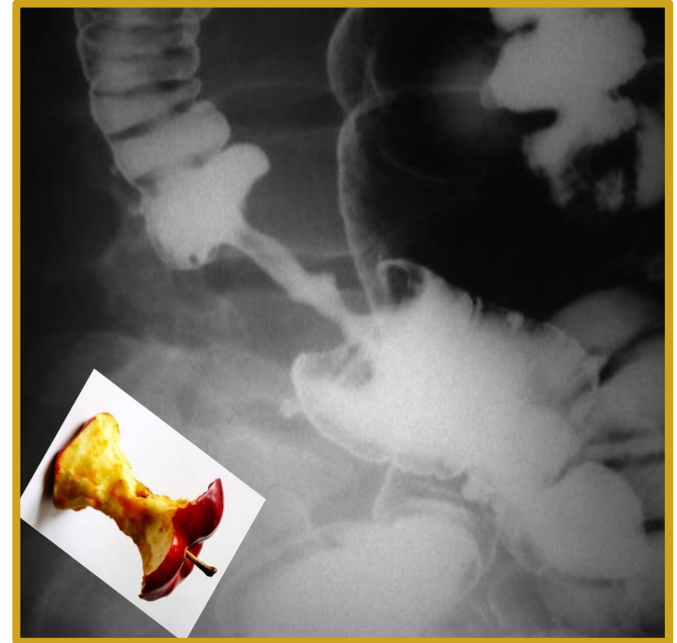(You have to differentiate between malignant stricture and benign stricture)

Malignant strictures show=

1-focal area

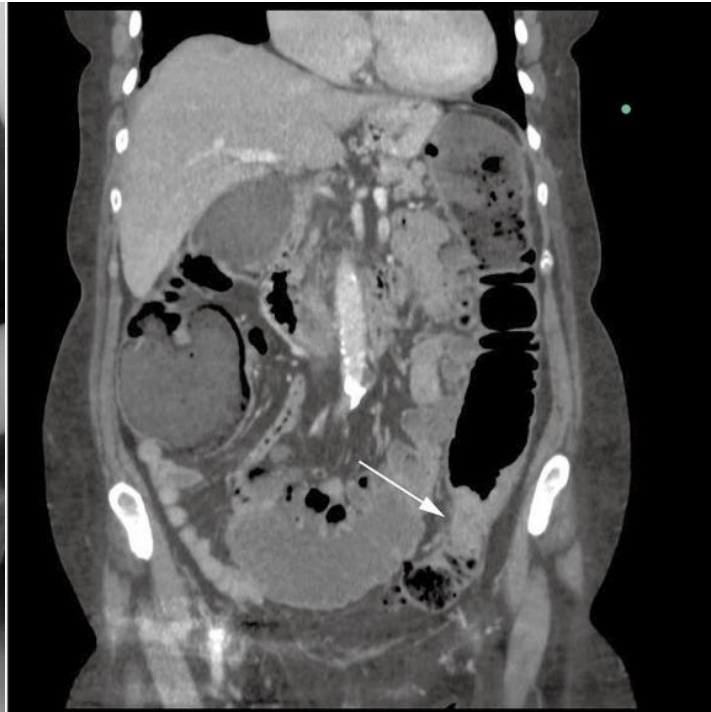
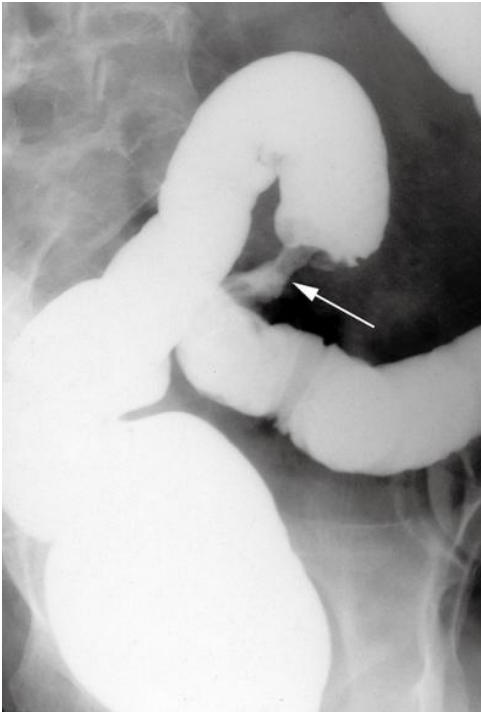
2-there is shouldering

3-irregularity in the outline

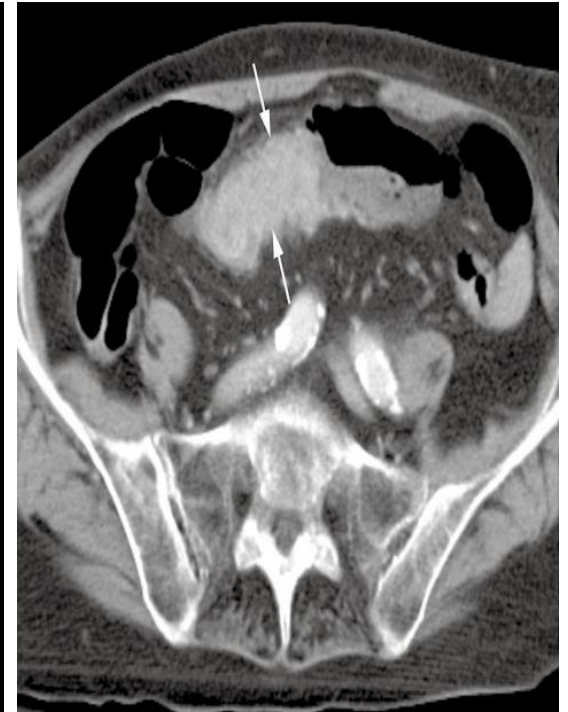



## Examples of colon cancer in barium enema and CT scan

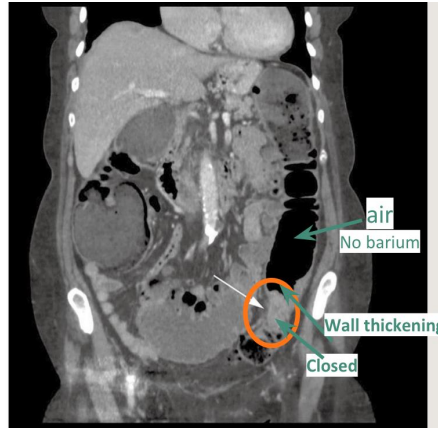
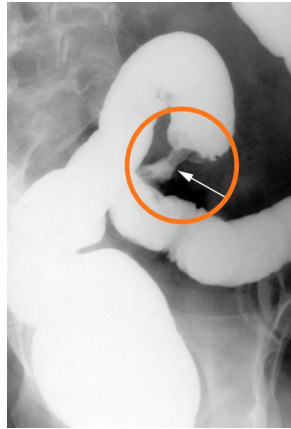


Coronal section of CT

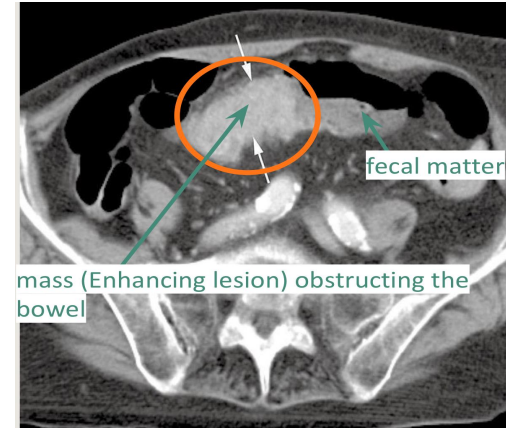


Axial section of CT

## Examples of colon cancer in barium enema and CT scan



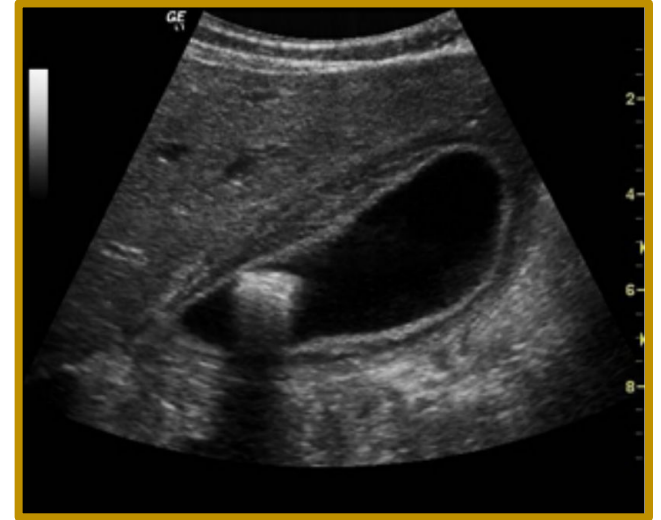
- **Left picture** : Barium enema represents apple core sign (malignant)
- **Right picture** : coronal CT showing a short, circumferential narrowing which started with wall thickening and then obstruction in the sigmoid colon (arrows) from a tumor.



Standard axial CT acquired on thin sections showing a tumor (arrows) in the transverse colon.

# Case 7

- What is the name of the modality?
- What is the diagnosis?
- What are the expected symptoms the patient has?
- Treatment :



- What is the name of the modality?

- Ultrasound of gallbladder

- What is the findings?

- We can see echogenic structure(gallstone)seen within lumen of the gallbladder showing distal acoustic shadowing
- echogenic mucosa
- thickened and edematous wall of gallbladder
- Lumen is distended

- What is the diagnosis?

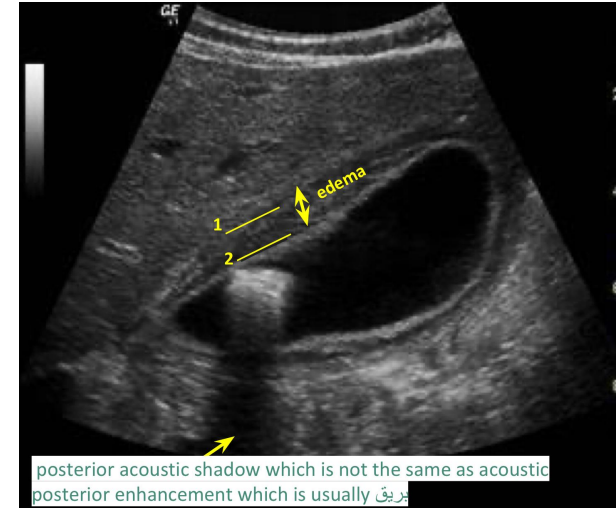
- Gallstone with Acute cholecystitis (or called calcular cholecystitis).

- What are the expected symptoms the patient has?

- RUQ pain radiating to right shoulder aggravating by fatty meal.

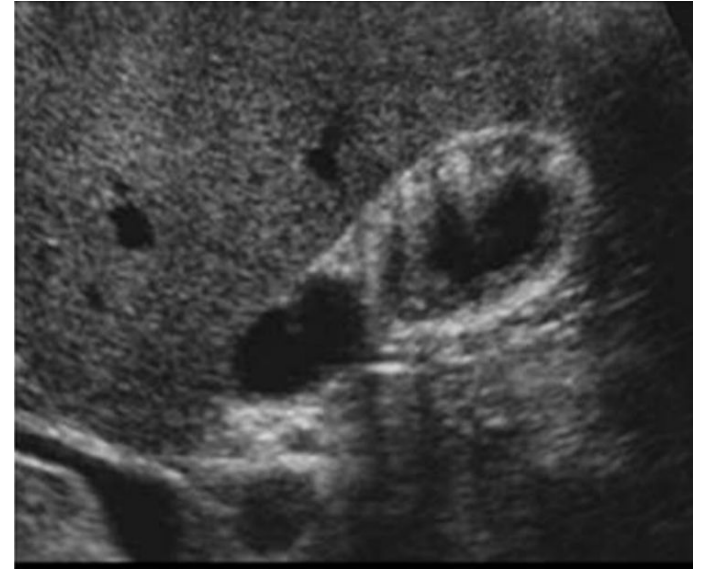- Treatment :

- Surgery (cholecystectomy) but wait for the inflammation to subside first.

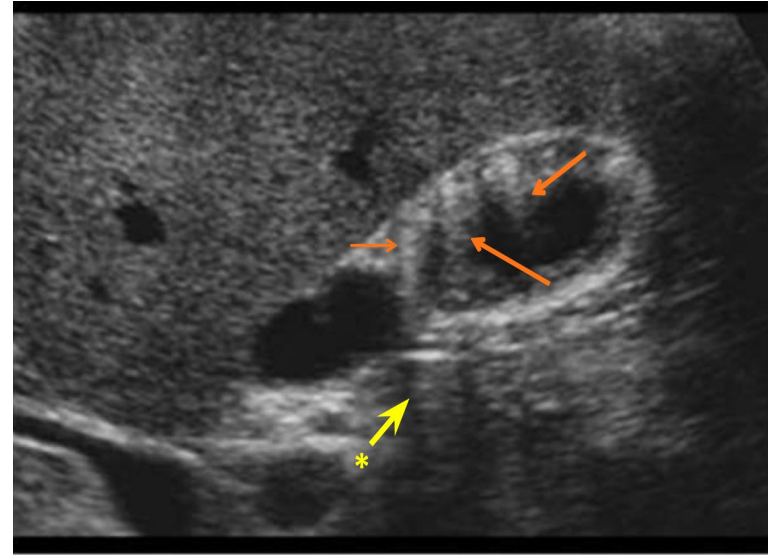


1. Outer wall of the gallbladder.
2. Inner wall of the gallbladder.

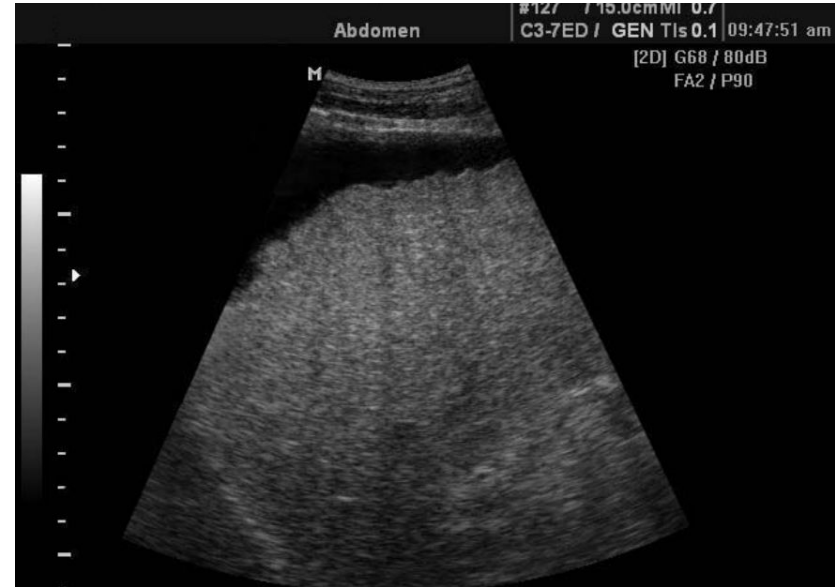- What is the name of the modality?
- What is the findings?
- What is the diagnosis?
- What is the important of this disease?



- **What is the name of the modality?**
  - Ultrasound of gallbladder
- **What is the findings?**
  - Hyperechoic lesions within the wall. Whole wall of gallbladder is involved with acoustic shadow and its either focal or diffuse
- **What is the diagnosis?**
  - Gallbladder adenomyomatosis (fat + muscle in wall of gallbladder).
- **What is the important of this disease?**
  - Misdiagnose with stone, benign lesion and can convert to malignant lesions, F/U follow up is needed.
  - Posterior acoustic enhancement = fat (arrows), unlike stones which give shadows (enhancement → white / shadow → dark)
  - The yellow arrow is normal area and not hyperechoic and didn't represent acoustic shadow!!it appears hypodense because it separates two enhancements



- What is the name of the modality?
- What is the findings?
- What is the diagnosis?



- **What is the name of the modality?**

- Ultrasound.

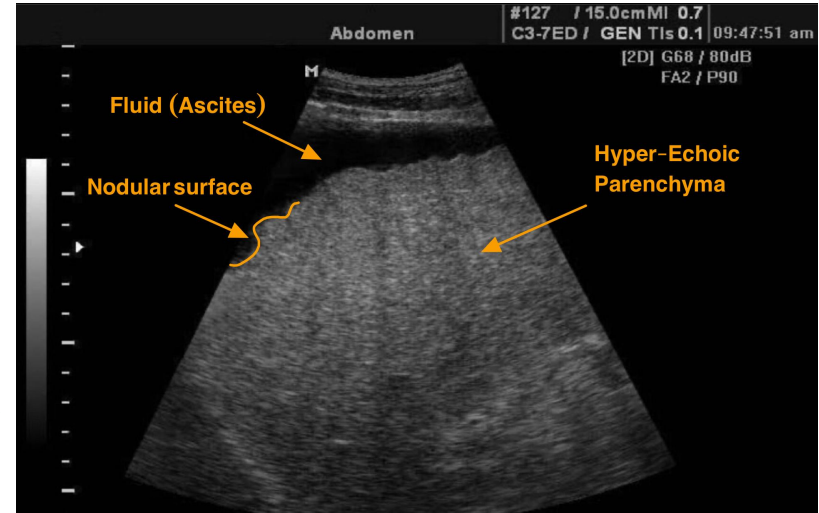
- **What is the findings?**

- Shrink,
- irregular nodular surface
- hyperechoic texture (in fatty liver and liver cirrhosis)
- ascites.

(Usually craniocaudal dimension of liver is more than 16cm)

- **What is the diagnosis?**

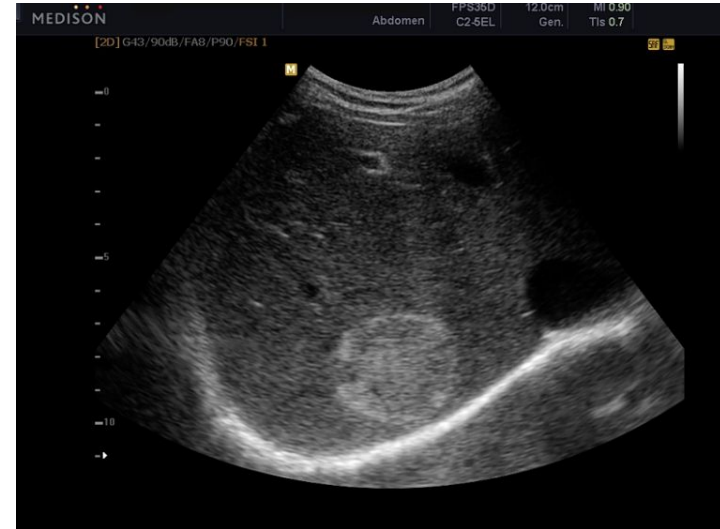- Liver cirrhosis.



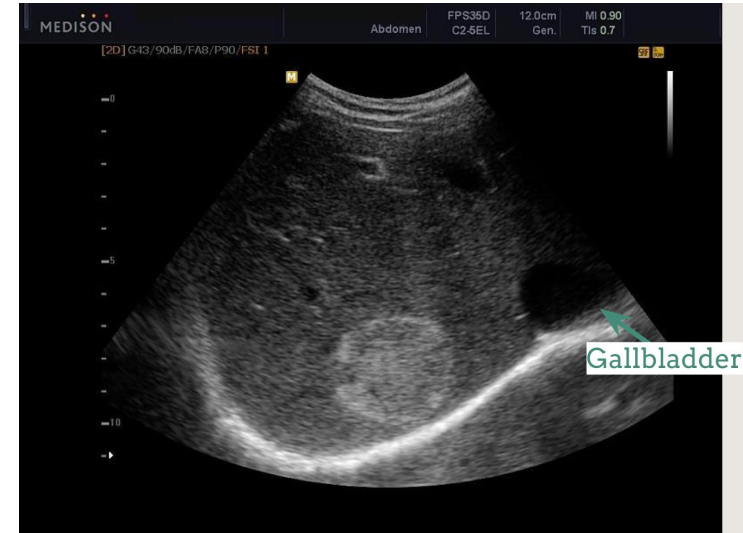

# Case 10

- What is the name of the modality?
- What is the findings?
- What is the diagnosis?
- What is other imaging modality to confirm the diagnosis?

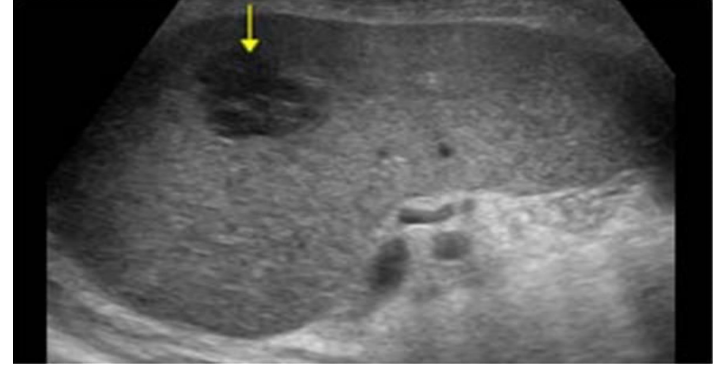
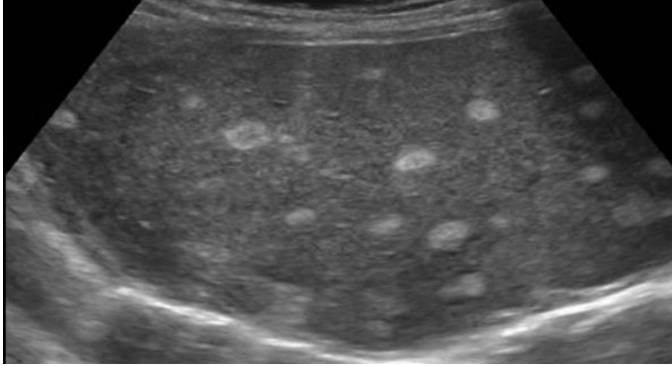


- **What is the name of the modality?**
  - **U/S of the liver.**
- **What is the findings?**
  - First you have to start looking at the liver parenchyma here we see:
    - 1-the surface is smooth not nodular
    - 2-normal liver size
    - 3-echogenicity of liver is normal**So;liver parenchyma is normal.Then look for other lesions**
  - **Rounded well demarcated Hyperechoic focal hepatic nodule** with smooth outlines;no nodules or lobulations
- **What is the diagnosis?**
  - **Hemangioma.=benign**
- **What is other imaging modality to confirm the diagnosis?**
  - **Triphasic liver CT scan.**
  - **MRI.**

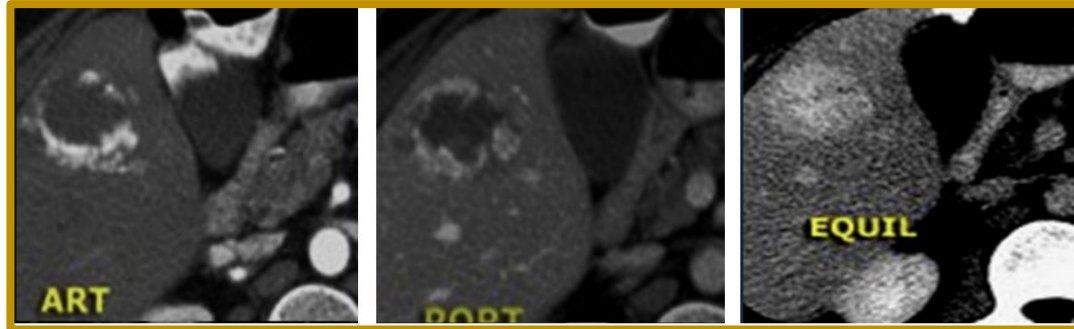


Most of Hyper-echoic solitary nodules which are well defined are hemangioma “benign”.

- Describe the following nodules?

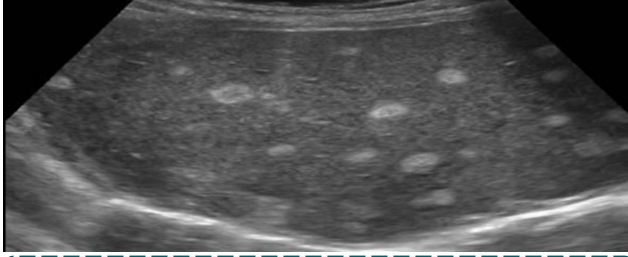


- Triphasic liver CT scan of the same patient, what is the diagnosis?



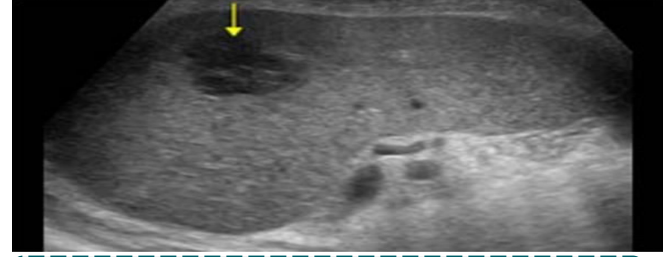
# Case 11

## Hyperechoic lesions



Metastatic or HCC Multiple lesions with varying size > metastatic

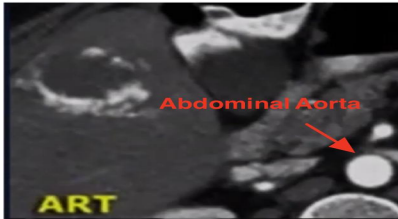## Hypoechoic lesions



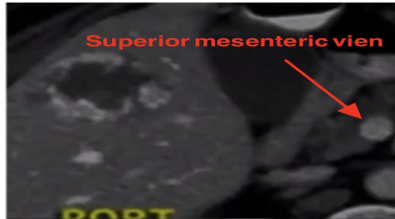Most of hypoechoic mass are malignant = metastasis or HCC. This is not a cyst! the cyst will be very black

- **Triphasic liver CT scan of the same patient :**

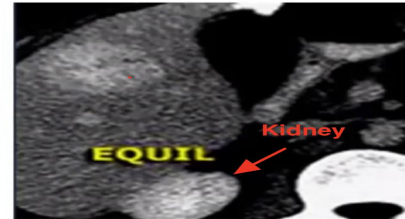### Characteristic enhancement of **hemangioma** of CT scan



**Arterial phase:** Peripheral nodular enhancement , How to know its the arterial phase? **Abdominal Aorta** filled with contrast

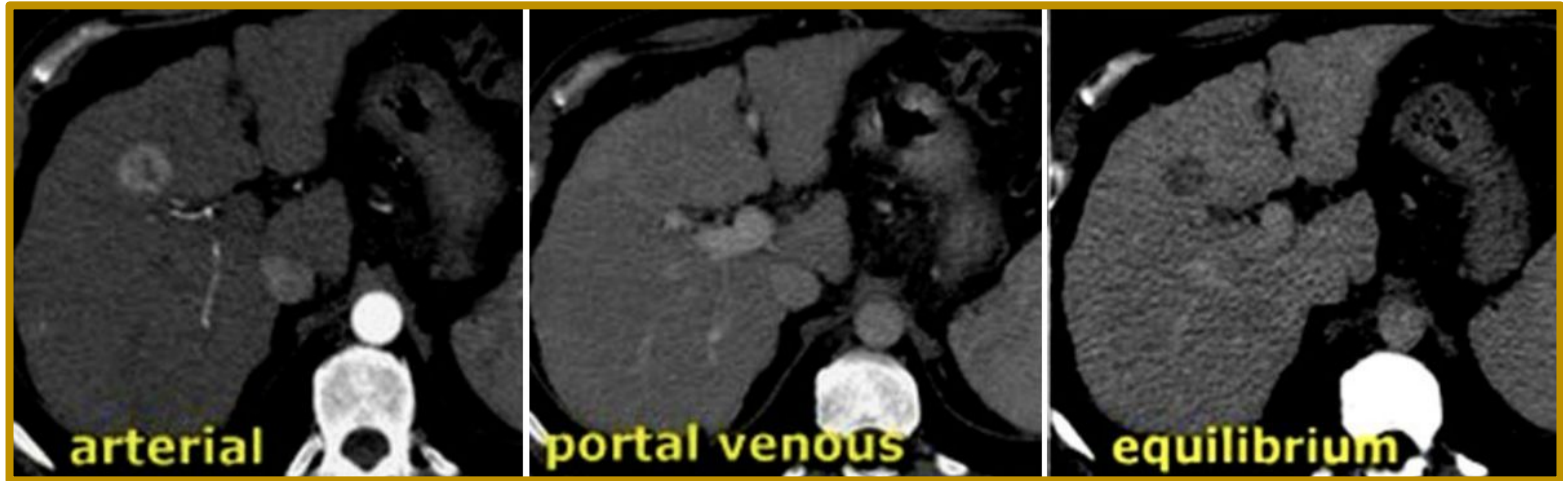

**Portal venous phase:** Peripheral nodular enhancement , How to know its the portal phase? **Abdominal Aorta and IVC and portal vein** filled with contrast



**Delayed or Equilibrium phase:** Homogenous enhancement  
It is the delayed phases because the kidneys appear with the contrast.

- What is the modality?
- What is the findings?
- What is the diagnosis?



- What is the modality?

- Triphasic Liver CT scan .

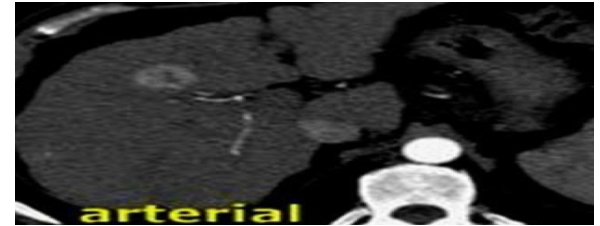
- What is the findings?

- Focal hepatic lesion with fill-in enhancement
- Like we said earlier, we start with assessing the liver parenchyma so;
  - 1-there is nodularity of liver surface
  - 2-right liver lobe is small
  - 3-coarse textureAll Indicating liver cirrhosis

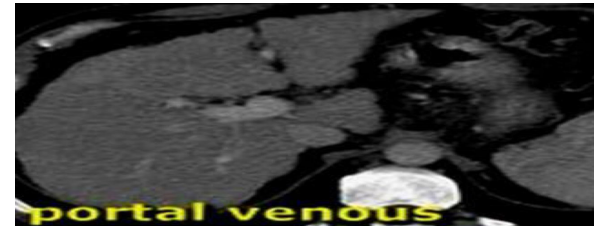
- What is the diagnosis?

- HCC or metastatic.

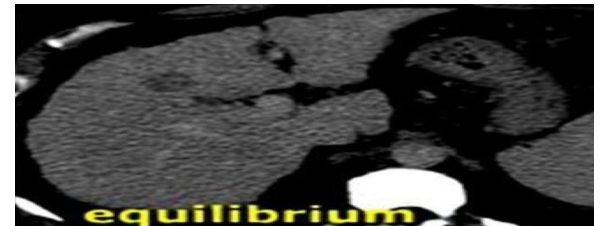
- In the arterial phase there is early enhancement then there will be iso-enhancement in the venous phase (same as the surrounding tissue).
- And the late phase it will be washout of the contrast and this represent hepatocellular carcinoma or metastasis.
- So remember in hemangioma (benign) the full enhancement (tumor uptake of contrast ) will be in the **delayed phase** , while in HCC (malignant) the full enhancement will be in the **arterial phase** .



Arterial Phase: Homogenous enhancement

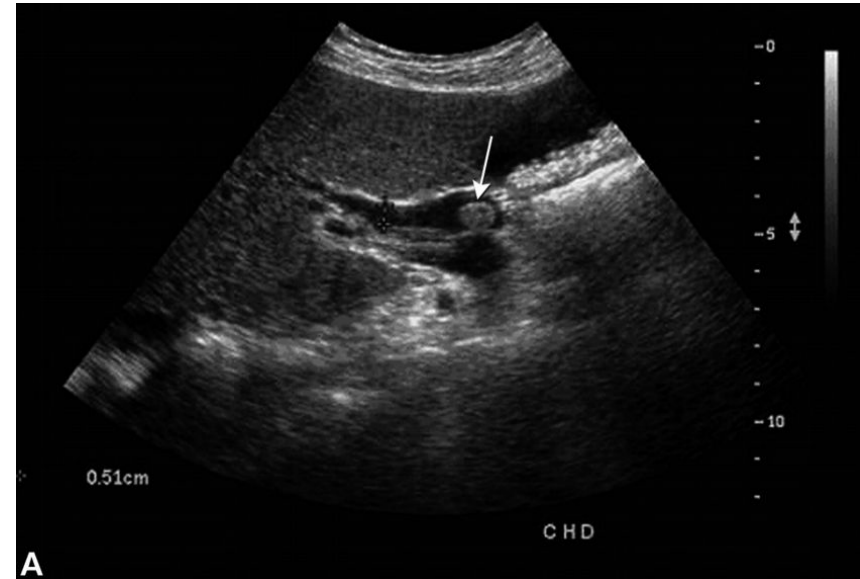


Portal venous Phase: Isodense  
(we can't see it anymore)



Delayed or Equilibrium phase: Hypodense  
(Washout)

- What is the modality?
- What is the findings?
- What is the diagnosis?
- What is the expected symptoms and signs the patient has?

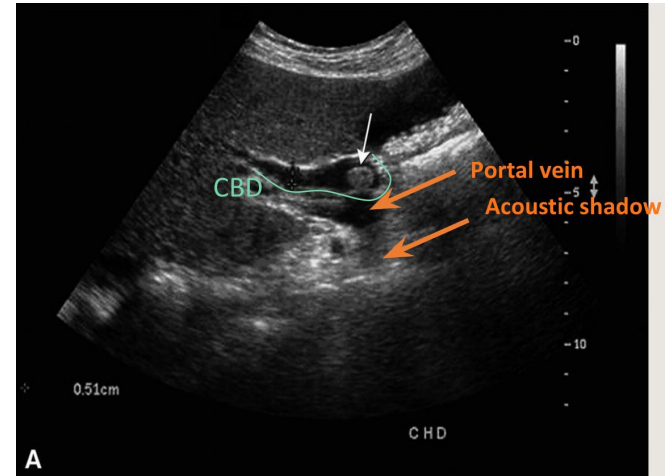


- **What is the modality?**

- U/S.

- **What is the findings?**

- Hyperechoic rounded lesion with acoustic shadow (stone) in CBD (common bile duct).
- dilation of CBD
- Normal diameter of CBD is 5mm but in the pic 0.51cm. So, CBD is dilated.



- **What is the diagnosis?**

- CBD stone (white arrow) → obstructive jaundice.

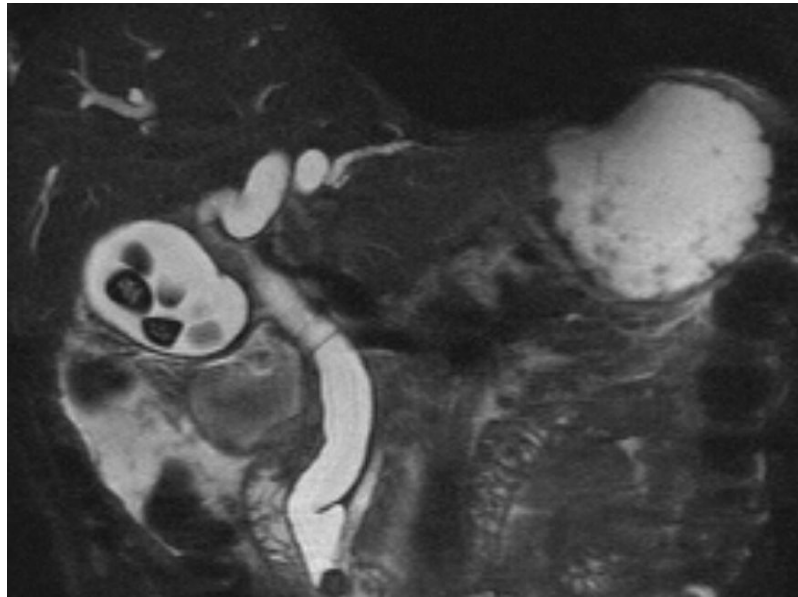
- **What is the expected symptoms and signs the patient has?**

- Yellow discoloration, RUQ pain, Hyperbilirubinemia and dark urine.

How to confirm the CBD stone? →

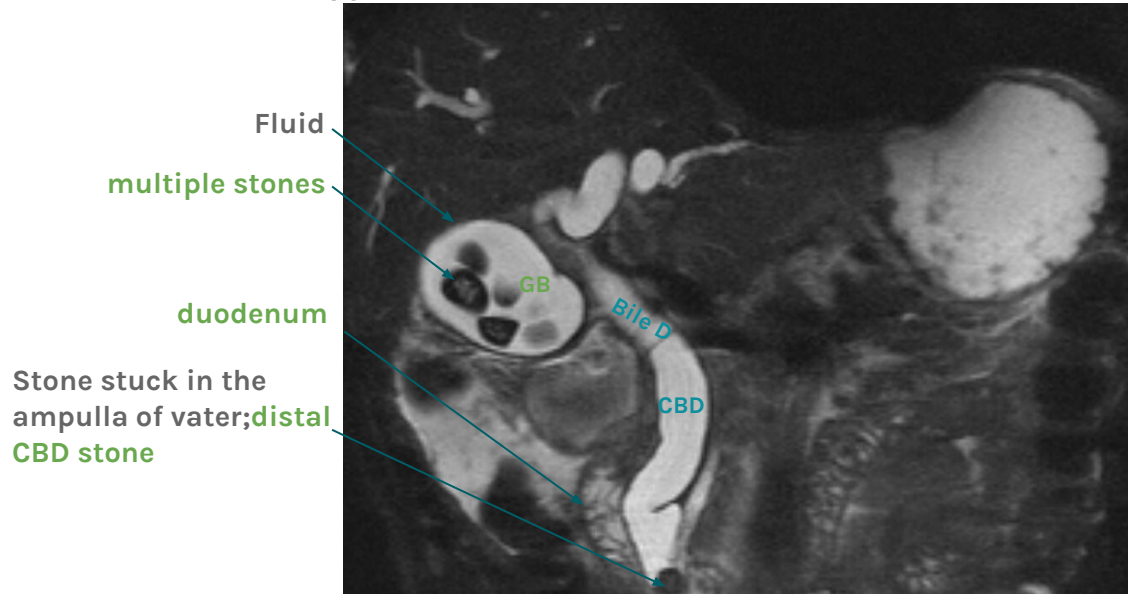


- **MRCP is ?**
- **The dark signals in the gallbladder is ?**
- **The dark signal in the distal CBD is ?**



# Case 14

- MRCP = **MRI Cholangio-Pancreaticography** (imaging of the bile ducts with the pancreas). **It's non invasive so we usually start with it (MRCP) or ERCP for diagnosis of CBD stone**
- The dark signals in the gallbladder is stone, **impacted in distal CBD and dilatation of the bile ducts.**
- The dark signal in the distal CBD (common bile duct) is stone.
- Fluids (water, bile, urine) appear white in MRI while black structures are dense materials.

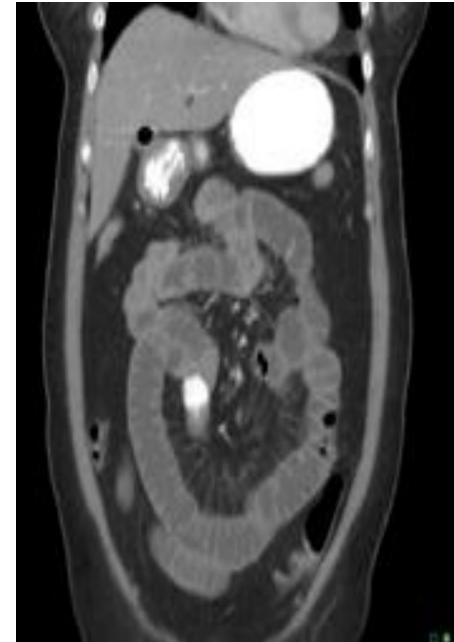
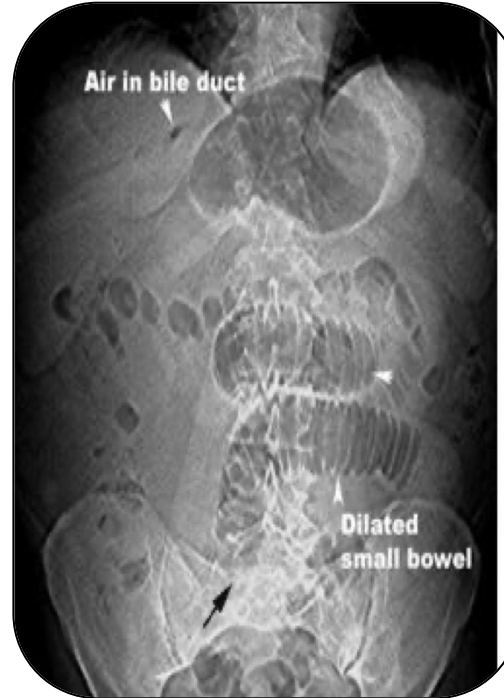
- Triad of Gallstone ileus:

- 1.
- 2.
- 3.

- Diagnosis by?

- Treatment



- **Triad of Gallstone ileus:**

1. **Air** in the bile ducts, Pneumobilia.
2. **Dilatation** of the small bowel (stacked coins).  
(Gallstone ileus)
3. **Calcified** stone in the distal bowel. Not clear in Pic 1, clear in CT Pic 2..  
**(Acute bowel obstruction)**

- **Diagnosis by?**

- Radiology

- **Treatment**

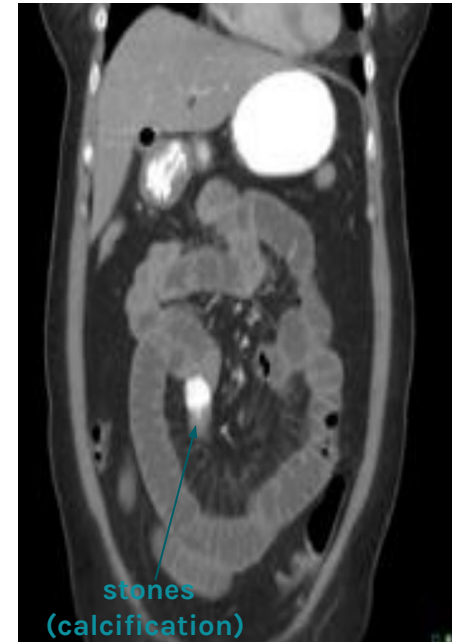- Surgery.

**gallstone ileus** → **obstruction of small bowel due to gallstone.**

- Rare disease, happens when there is chronic inflammation which causes adhesions to form between the gallbladder and the duodenum.

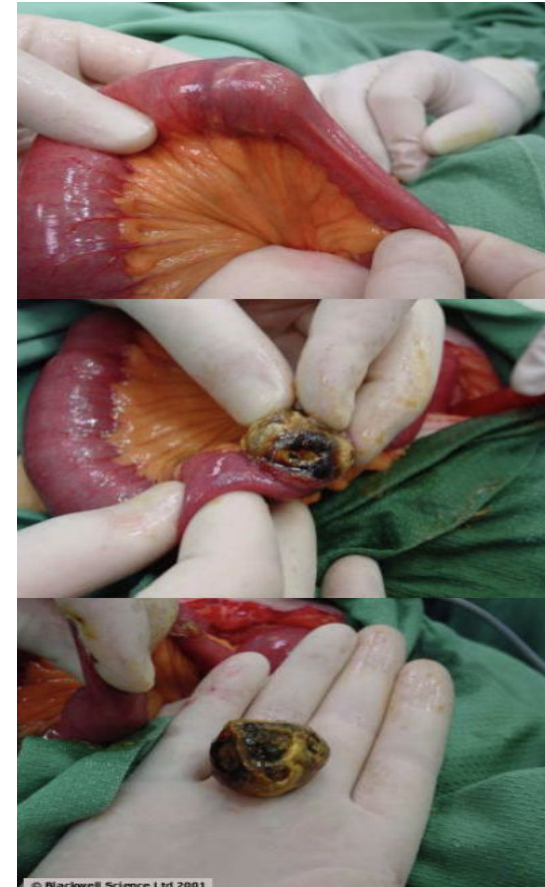
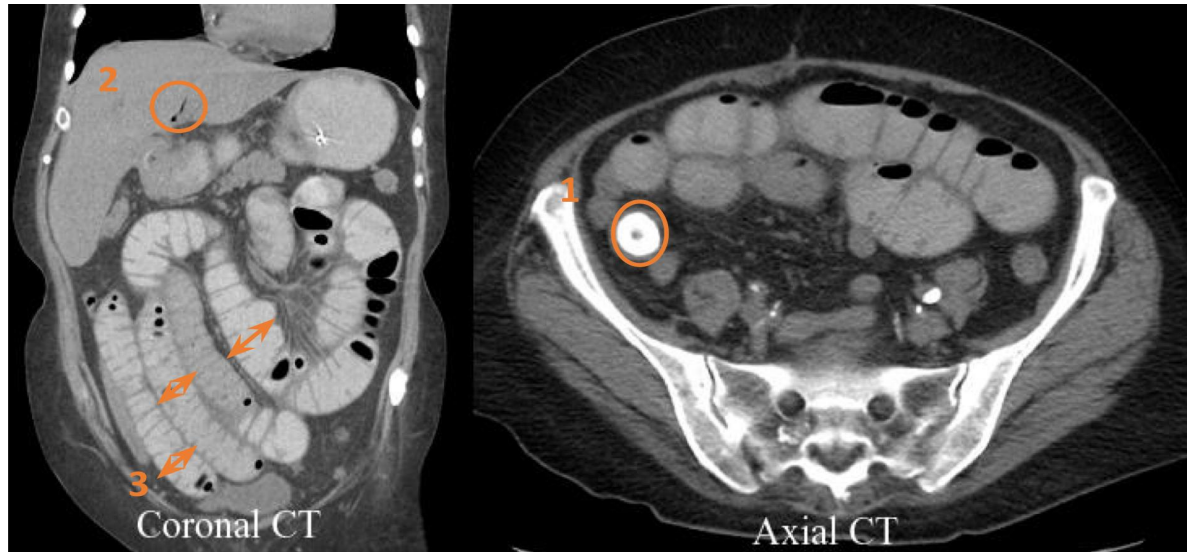
- After time fistula will form and then stones may pass through this fistula and pass until it reaches the narrowest part of the duodenum (ileocecal valve) and obstruct it.

- Air enters the gallbladder so we have air inside the bile duct.



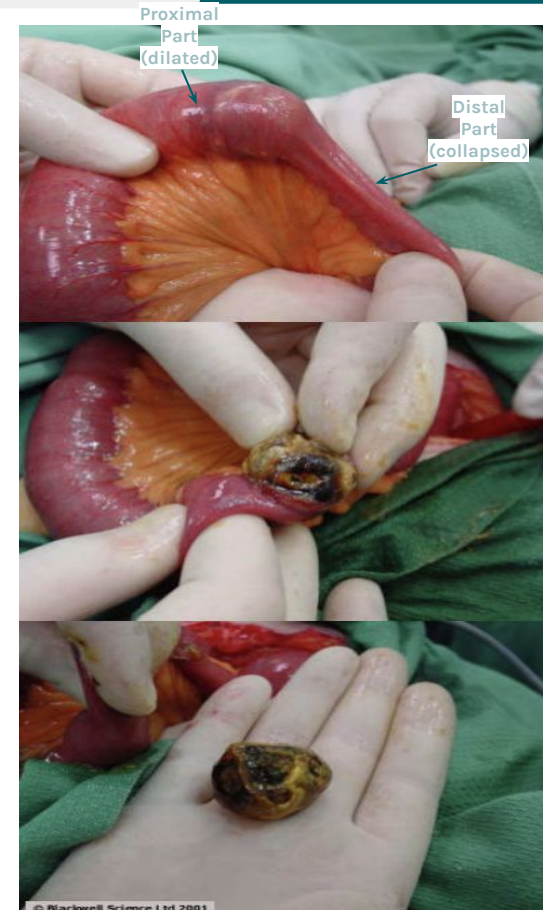
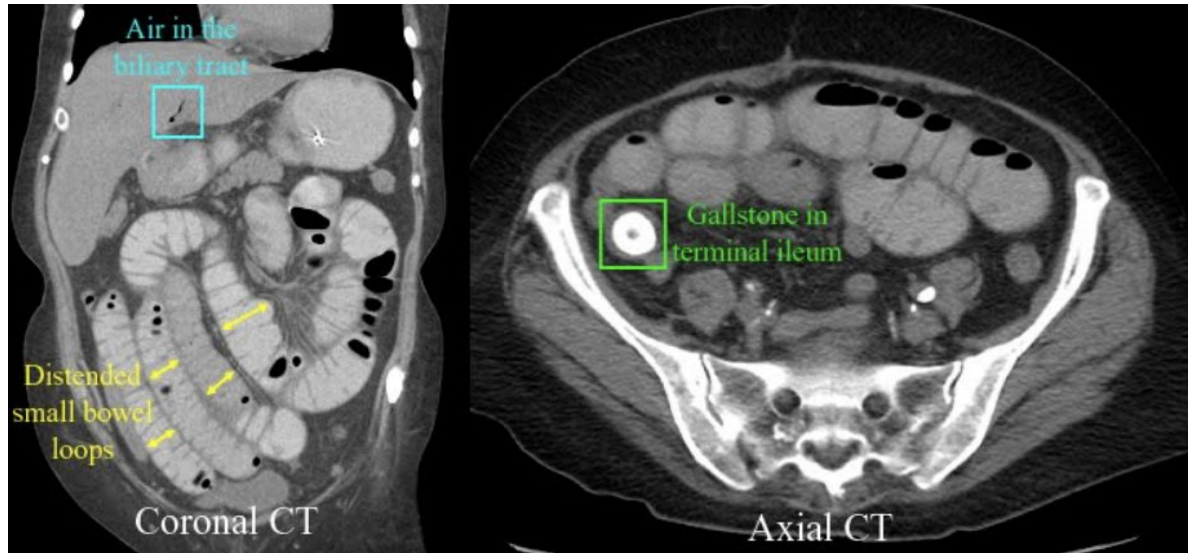Dilation is distal to the obstruction

- What are the findings?

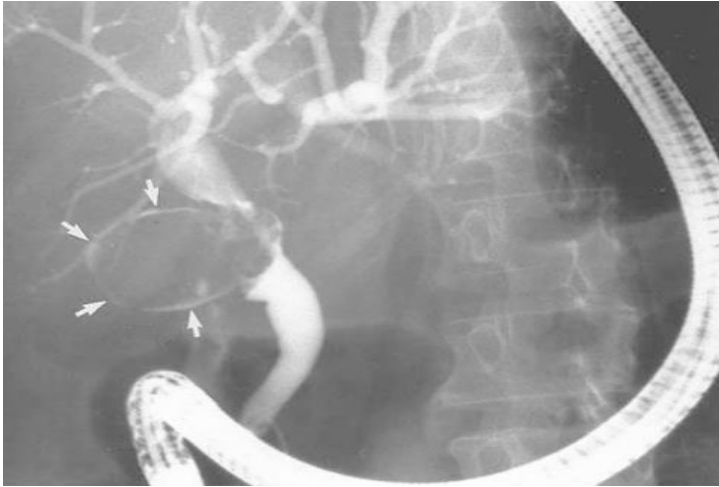

- What are the findings?

- Gallstones in terminal ileum.
- Air in biliary tract.
- Distended small bowel loops.



Terminal ileum stone → surgery (they cut proximally to the stone and remove it).



This is **ERCP** shows large filling defect of gallbladder which is large gallstone and we can see the contrast around the stone (white arrows) the gallbladder causes compression and dilatation of the common hepatic or common bile ducts by indirect obstruction (from outside) it is called "**Mirizzi's syndrome**".

# Thank you

To All Of The Amazing Members Of Our Radiology Team Who worked hard and Did a Fantastic Job, **Lots And Lots Of Love For All Of You**

- Alhanouf Alhaluli
- Lama Alzamil
- Norah Almazrou
- Nouf Alhumaidhi
- Arwa Alemam
- Sarah Alarifi
- Njoud bin Dakheel
- Rana Alshamrani
- Roaa Aljohani
- Rahaf Alshuaniber
- Norah Alharbi
- May Babaeer
- Mohammed Al-Huqbani
- Zyad Aldosari
- Alwaleed Alsaleh
- Mohaned Makkawi
- Fahad Alsultan
- Abdullah Almuamar
- Mohmmmed Ajarem
- Abdullah Alassaf

## Dark Theme Night Owls

- Yasmeen Almousa
- Shahd Alsalamh



## Special Thanks

- Taif Alotaibi
- Amirah Alzahrani



A **Huge** thank you to our Academic leaders

- Noura Alturki
- Jehad Alorainy

