



**Radiology**  
Team 438

# Nuclear medicine in thyroid and parathyroid

## Lecture 19

### Objectives

- ❖ Describe the physiologic principles of underlying Tc-99m parathyroid scintigraphy .
- ❖ Describe the various methods used for parathyroid scintigraphy with emphasis on SPECT and SPECT /CT .
- ❖ Identify the common imaging features of pathologic parathyroid glands.
- ❖ Discuss causes of false negative and false positive scans.

Reviewed By



Noura Alturki  
Jehad Alorainy

Color Index:

♦ Important ♦ Doctor's Notes ♦ Extra ♦ Female slides ♦ male slides

### Team Leaders



Omar Aldosari



Leena Alnassar



Shahd Alsalamh

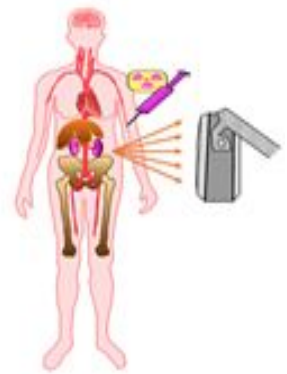
### Done by:

Rahaf Alshunaiber

Alhanouf Alhaluli

## » Nuclear Medicine Procedure

- Patient **ingest** or injected with small amount of radioactive material. known as **radiopharmaceuticals** which have short **half-lives** to not harm the patient.
- Radiopharmaceutical localizes in patient according to metabolic properties of that drug.
- Radioactivity decays, emitting gamma rays.
- Gamma rays that exit the patient are imaged. using a **Gamma Camera** (the grey box in the image) where the patient is the source of radiation.



Example : For the Bones

A phosphate compound is used and it's Labeled by a radioactive material  
The labeled phosphate compound will stick to the bone, Radiation will come from the bone  
Which will be detected by Gamma camera, Showing normal distribution or an Abnormal uptake in the skeleton

\*This apply to all organs using different radiopharmaceuticals; as each organ has its own radiopharmaceuticals

- ❖ In **Nuclear medicine** – Radiation comes from the **patient** and is detected by gamma Camera
- ❖ In **Radiology** – The radiation comes from the **x-ray tube (machine)**

## » What are the nuclear medicine imaging methods?

### Conventional tumor imaging :

Planar : 2D

SPECT : 3D

SPECT-CT : 3D (Function and anatomy)

SPECT:Single Photon Emission computed tomography.  
for precise detection of abnormal uptake site

### Onco PET :

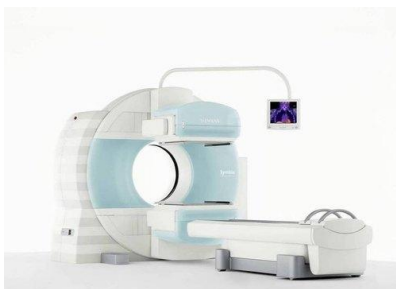PET : 3D

PET CT : 3D (Function and anatomy)

PET:Positron emission tomography (2 photons)

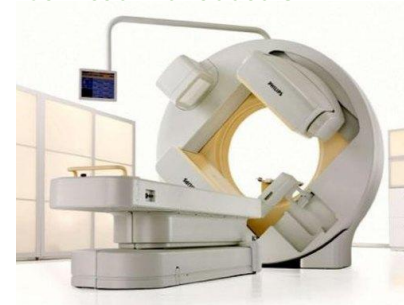### PET-CT

Dual head with added CT

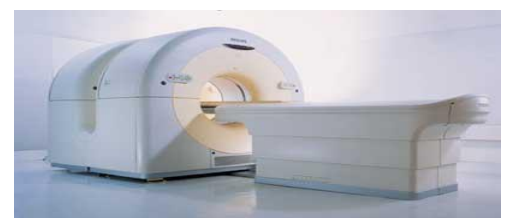


### SPECT -CT

Dual head with added CT



### PLANAR / SPECT



# Thyroid Scan

## Physical Properties SPECT Radionuclides

There are two groups of radioactive materials that are used in nuclear medicine:  
**SPECT Radionuclides and Positron emitting (PET) Radionuclides**

Radionuclide	T/2 (Half life) Physical	Type of Radiation	E (Kev)
<b>Technetium-99m (Tc-99m)</b> Most common	<b>6 Hours</b>	Gamma	140
<b>Iodine I 131</b> Mainly used for therapy	<b>8 Days</b>	Gamma / Beta	364/606
<b>Iodine I 123</b> 2nd most common	<b>13.2 Hours</b>	Gamma	159
<b>Gallium citrate (Ga-67)</b>	<b>78.3 Hours</b>	Gamma	90,190,290
Thallium chloride 201 (Tl201)	73.1 Hours	X-ray	68-83
Indium 111 (In 111)	2.8 Days	Gamma	173-247
Xenon 133	5.2 Days	Gamma	81
Krypton 81m	13 Seconds	Gamma	190

Doctor said:

**“Know the first 4 half-life”**

- they're the most commonly used
- 80% of procedure in KCUH uses (Tc-99m).
- One day When you order a nuclear study the patient will ask how much of the material will stay in my body?

**Iodine I 131:**

Mainly used for **therapy** (hyperthyroidism, cancer), It has a long half life and emit **beta rays**

**Iodine 123:** is used for diagnosis of thyroid problems and cancer

## Physical Properties of positron emitting (PET) Radionuclides

**“Know the Fluorine 18 and Gallium 68 half-life”**

- Fluorine-18 is labeled with glucose, so wherever there is increased glucose consumption the body it will be taken up.
- As in tumors where there is **increased glycolysis**

Radionuclides	T/2 Physical (min)	Positron	Productivity
Carbon 11	20	0.96	Accelerator
Nitrogen-13	10	1.19	Accelerator
Oxygen-15	2	1.73	Accelerator
<b>Fluorine 18</b>	<b>110</b>	0.635	Accelerator
<b>Gallium 68</b>	<b>68</b>	1.9	Generator (germanium 68)
Rubidium 82	1.3	3.15	Generator (germanium 68)

# Thyroid Scan

## » Thyroid Scan : Procedure

Can be done using Tc-99m Pertechnetate or I-123

	Tc -99m Pertechnetate	I-123
Dose	0.5-4.0 mCi given IV that mean of the injected amount only 0.5-4.0% of the tracer will appear	0.5 mCi orally
Half life	6 Hours	13 Hours
Cost	<b>Not Expensive (Generator)</b> Available All The Time "Quickscan".	<b>Expensive</b> (It needs Cyclotrone) only available once a week
Time of imaging	<b>20 min post injection</b> <b>only one visit</b> patient comes department , we inject the material, after 20 mins image will be taken	<b>6 and 24 hours post</b> <b>ingestion</b> <b>3 visits</b> (to take the capsule, take image after 6H , take image after 24H)
Remarks	<b>Trapped only not organified</b> gives information only about the trapping (step before organification)	<b>Trapped and organified</b>

## » I-123

- Can be used to prepare the patient for I-131 therapy , it calculate the dose for I-131 therapy by measuring the amount of thyroid uptake
- Gives Information About Trapping and about organification
- **organification** : is the synthesis of thyroxine (T4,T3). Benefits: looking for enzymes ,hormones deficiency.

### Limitations :

- ❖ Expensive
- ❖ Patient have to come 3 times

## » Tc-99m Pertechnetate

Alternative for I-123

### Limitation:

- ❖ Trapped not organified.

### Advantages:

- ❖ Cheap and fast

**To assess the organification we use I- 123 not technetium.**

When Iodine trapped By The Thyroid gland Thyroid Hormones Are synthesized, then it would be organified to form Thyroxine.

In Tc-99m its not organified so when there's problem organification,we can't use it.

## ⇒ Normal Values Of Thyroid Uptake

**I-131 OR I-123 RAIU :** if the patient is given 100  $\mu$ Ci


- Normal 4 hour RAIU : 5 - 15%.
- Normal 24 hour RAIU : 8 - 35%

**Tc - 99m Uptake (20 min Uptake):** if the patient is given 5 mCi

- Normal (0.5 -4.0%)

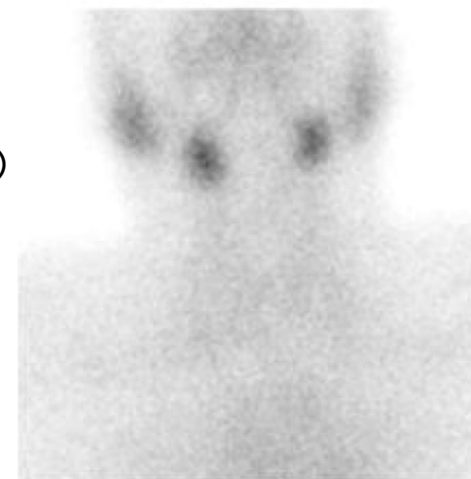
## ⇒ Causes of High Thyroid Uptake

- **Hyperthyroidism :**  
Grave's Disease or TSH-secreting pituitary adenoma
- **Autonomous toxic nodule**
- **Multinodular toxic goiter** (Plummer's disease)
- **Enzyme defects :** Dyshormonogenesis.
- **Iodine starvation** (Iodine deficiency)
- **Lithium Therapy**
- **Recovery phase of thyroiditis.**
- **Rebound following abrupt withdrawal of antithyroid meds**



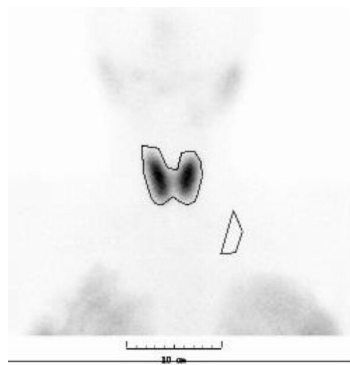
## ⇒ Causes Of Low Thyroid Uptake

- **Parenchymal Destruction:**
  - Acute, Subacute and Chronic Lymphocytic Thyroiditis
- **Hypothyroidism:**
  - Primary or Secondary (insufficient pituitary TSH secretion)
  - Surgical/Radioiodine Ablation of Thyroid
- **Blocked Trapping:**
  - Iodine load (most common): Iodinated contrast
  - Exogenous thyroid hormone replacement depressing TSH levels (thyrotoxicosis factitia)
  - Ectopic thyroid: Struma Ovarii
- **Blocked Organification:**
  - Antithyroid medication (PTU): Note Tc-99m uptake should not be affected

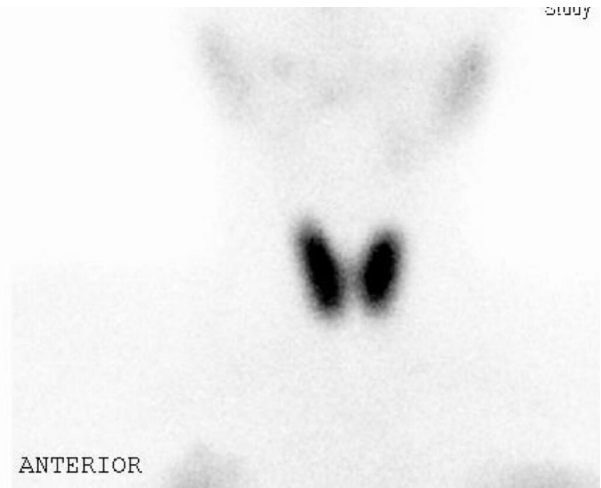

THYROID UPTAKE  
TC99M

## » Tc-99m Thyroid scan and uptake Imaging plus uptake studies



THYROID UPTAKE : 2.96 %  
 Area 29.8 (sqcm)  
 Mass 53.0 g



atient Name  
 atient ID :  
 scan Date : 03Jun2007  
 THYROID UPTAKE

Adac Laboratories BV  
 Maarssen  
 The Netherlands

Thyroid uptake here is 2.96% which is normal - No Defects or Nodules

## » THYROID METASTASES STUDY (I-123 or I-131 as Sodium Iodide)

### Indications

- Detection and localization of persistent or recurrent functioning thyroid cancer

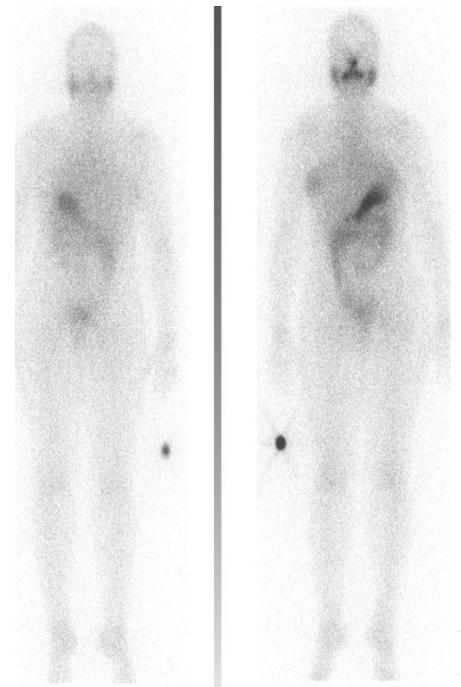
I-123 is commonly used in thyroid cancer patient post thyroidectomy  
 - Assess the extent of surgery after thyroidectomy  
 - Detect Lung or Bone metastases

#### Image A

thyroid cancer patient that underwent thyroidectomy

**Anterior view** → No thyroid tissue with normal physiological uptake of iodine in the stomach and bladder

**Negative Iodine whole body scan** (there's no remnant; no local disease or metastases, patient is free from the disease)



Posterior view

Anterior view

### Patient Preparation

- **Stimulation of potentially functioning thyroid tissue:**
  - A. Inject recombinant human thyrotropin on 2 consecutive days and administer the radiopharmaceutical on the 3rd day
  - B. Withdraw thyroid replacement hormones :
    1. Thyroxine (T-4) for at least 4 weeks.
    2. Triiodothyronine (T-3) for at least 10 days.
- The patient must not have had i.v iodinated contrast material (IVP, CT with contrast, myelogram, angiogram) for at least 3 weeks
- The patient should be NPO for at least 4 hours prior to radiopharmaceutical administration and for at least 1 hour afterwards

\* Also The patient must avoid Iodine-containing food such as fish.

**A**  
 Negative Iodine whole body scan



## Radiopharmaceutical, Dose, & Technique of Administration

- Radiopharmaceutical: Oral administration

- I-123 as sodium iodide : 2 mCi
- I-131 as sodium iodide : 2-10 mCi

Thyroid tissue uptake is TSH dependent, so prior to whole body scan 2 Exogenous TSH injections must be given to the patient to find out any metastases after thyroid cancer treatment

- Imaging using Gamma camera : Whole body scan

## » I-123 or I-131 Whole Body Scan (WBS) » Planar Vs SPECT CT

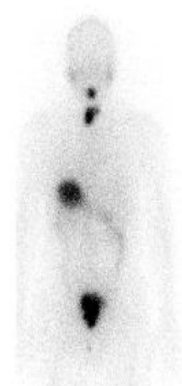
### Local Recurrence

#### Partial thyroidectomy

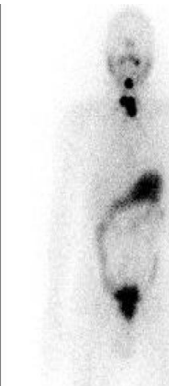unsuccessful thyroidectomy (multiple thyroid tissue is left in planar image )

\* This patient is post- operative which supposed there is no uptake of iodine in the neck (the thyroid is removed!). Which means this is **Local Recurrence**

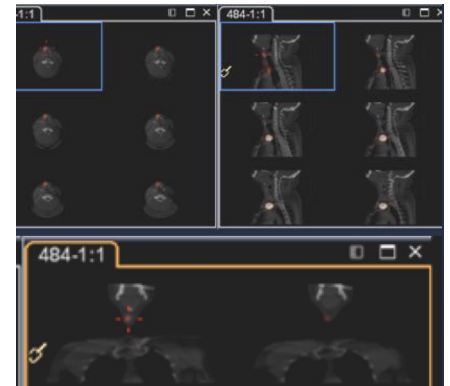
Posterior view



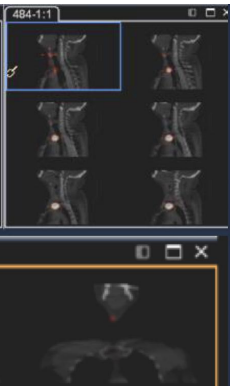
Anterior view



Trans Axial



Sagittal



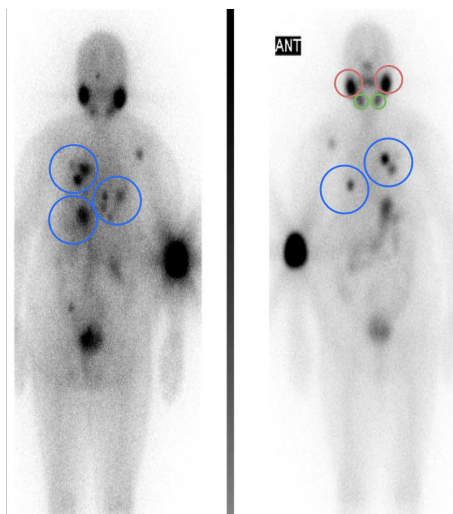
Coronal

To know the exact location of abnormality, you have to do **SPECT CT** (knowing the exact site helps the surgeon decide which surgical approach to use)

- **Sagittal view** shows remnant in front of the trachea
- **Trans Axial view** shows that is antero-lateral to the trachea  
Red thing → Remnant in thyroglossal cyst

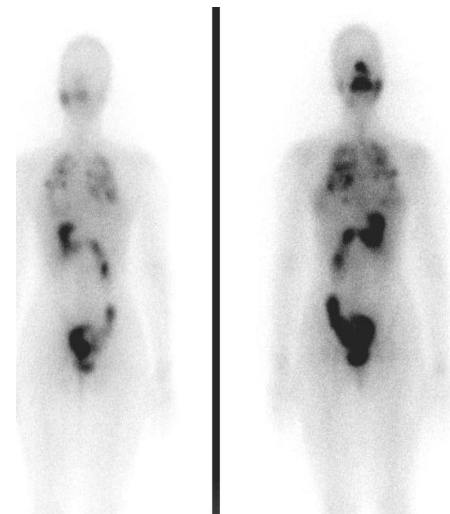
How to completely remove it? Give the patient **I-131**

### Bone Metastases



- No thyroid uptake ; because it's removed
- Abnormal uptake in the ribs and left humerus "Indicates bone metastases "
- Normal iodine uptake in salivary glands  
Pink → parotid gland    Green → Submandibular gland

### Lung Metastases



- Diffuse lung uptake with focal area of higher uptake; Indicating Lung metastases
- Especially follicular type because it has hematogenous spread

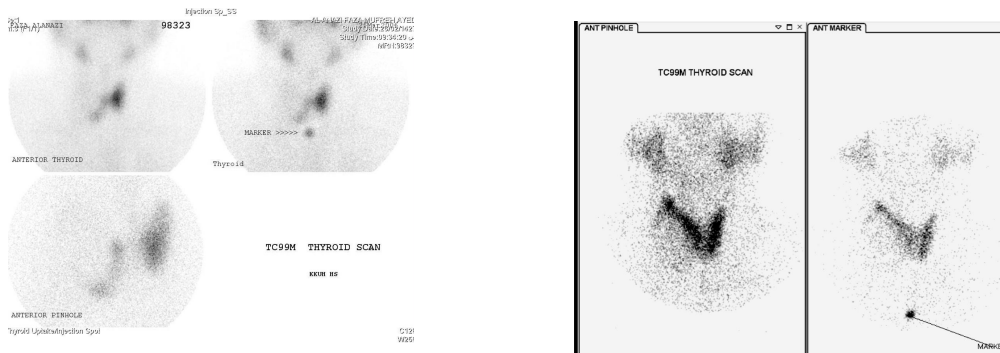
## » When is thyroid scanning helpful?

### » Indications for Thyroid Scan

- Evaluation of thyroid nodules : Number & type
- Evaluation of congenital hypothyroidism : Agenesis Vs. Dyshormonogenesis.
- Evaluation of neck masses : ectopic thyroid, thyroglossal cyst.
- Evaluation of thyrotoxicosis.

## » Evaluation of thyroid nodules : Single vs MNG

### Solitary cold nodule (Single raised nodule)



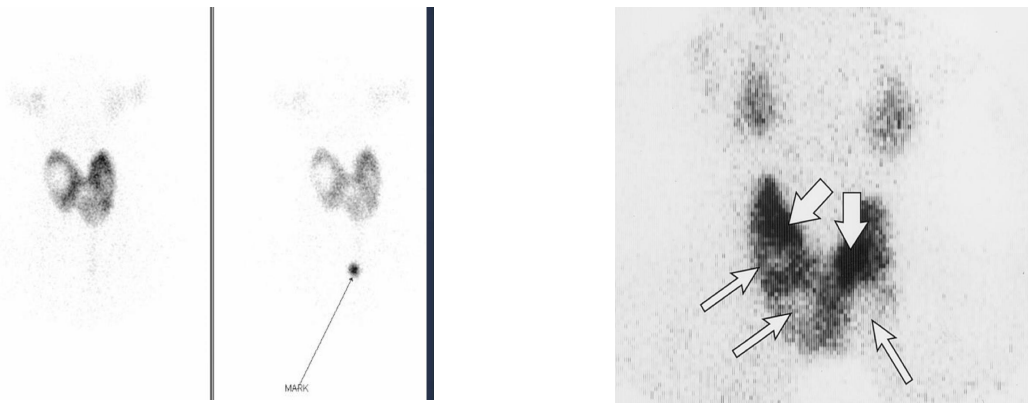
**Left lobe** → Normal uniform uptake, No defect

**Right lobe** → Large defect (No uptake at all)

**Marker in Suprasternal notch** → to see if there is retrosternal extension or not

**Cold** → No uptake of iodine or Technetium

### Multinodular goiter (Multiple cold [nox-toxic] nodules)



There are Multiple defects

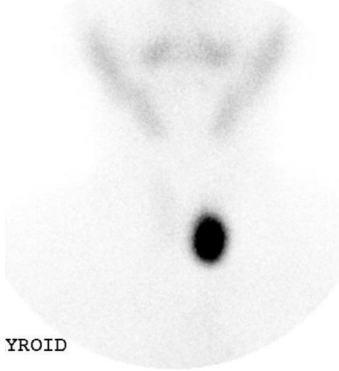
**The chance of malignancy is more in Solitary cold nodule than in MNG**

As the number of nodules increase, the chance of malignancy decrease.



## ➤ Evaluation of thyroid nodules : Hot vs Cold vs warm

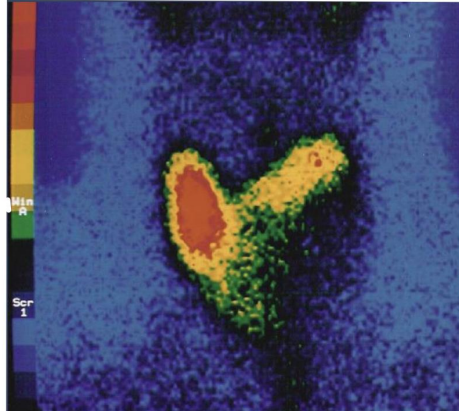
you can't see extra-nodular thyroid tissue  
(normal thyroid around the nodule)



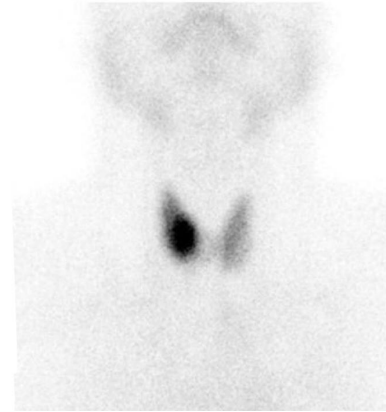THYROID

THYROID SCAN

Tc-99



you can see the the  
extra-nodular thyroid tissue



**Hot : < 5% Malignant**  
(Autonomous toxic nodule)

a hot nodule that takes up all the tracer, suppressing the rest of the gland and independent on pituitary thyroid axis

**Cold : 15-20% Malignant**

15% (Female) - 20% (Male)  
**Malignant**

No uptake at all in the affected gland

**Warm : Suspicious**

There is uptake more than the rest of the gland without suppressing the gland (the rest of the gland is seen, Unlike in Hot nodule the rest of the gland is Not seen)

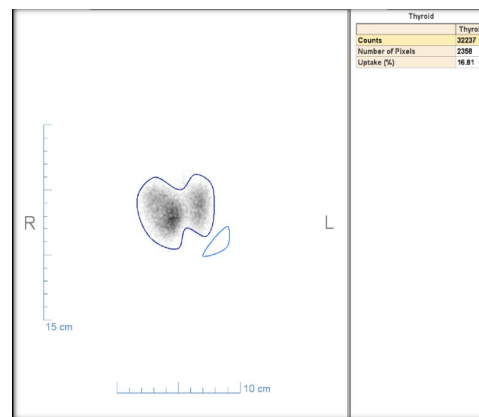
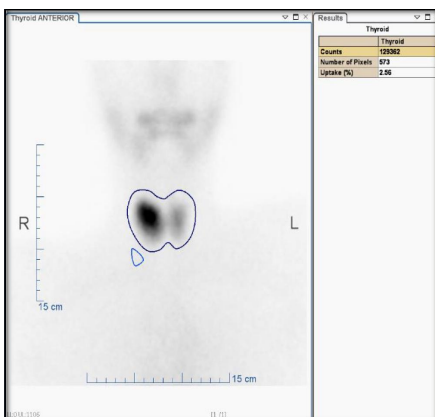
- this image is taken by technetium.

(Warm nodule on Technetium Should be of followed by **iodine 123** to see if it is really hot or cold)

## ➤ Discordance Tc-I 123 Scan

A warm nodule in Tc is worrying it can be cold when done by I123. **Why?**

because Tcm99 is only a trap test whereas I123 is both trap and organification test.

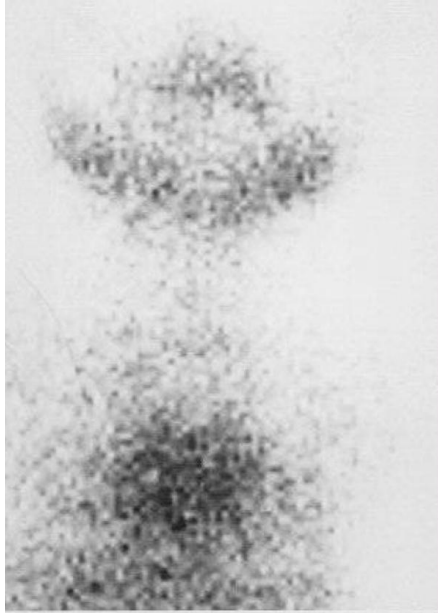


The chance of malignancy of a discordant nodule about **20%**

## ➤ Evaluation of congenital hypothyroidism

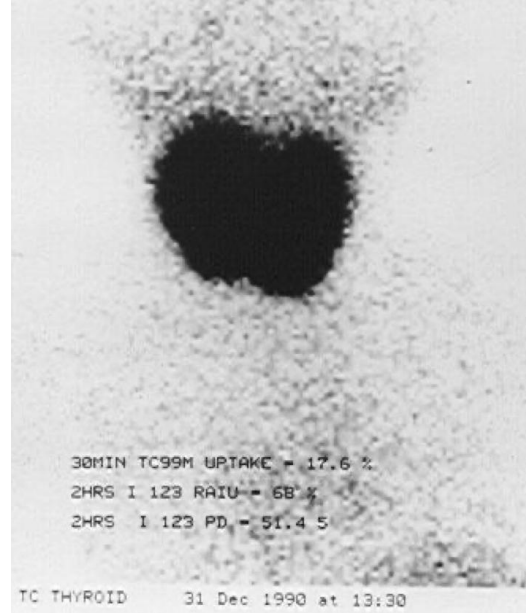
### ➤ Agenesis vs Dyshormonogenesis

TSH tests are routinely ordered for newborns. **If TSH is high** Thyroid scan is done to detect the presence of thyroid gland (US is not used because the base of the tongue can't be seen in case of ectopic thyroid at the base and it can't evaluate the function.)



#### Agenesis

- High TSH
- absent thyroid gland
- Treatment: lifelong thyroxine

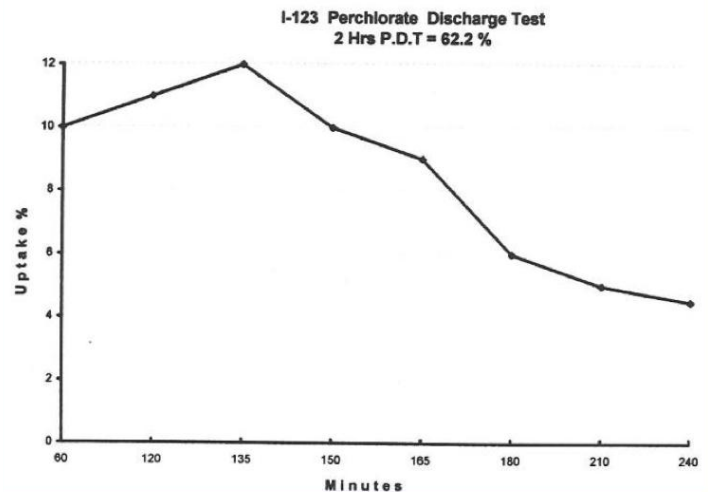


#### Dyshormonogenesis

- High TSH
- Enlargement of the gland
- Hypothyroidism
- Thyroid is present (Abnormal)
- Organification defect  
( Defect in thyroid hormone synthesis due to an enzyme defect )
- It uptake more iodine trying to produce thyroxine

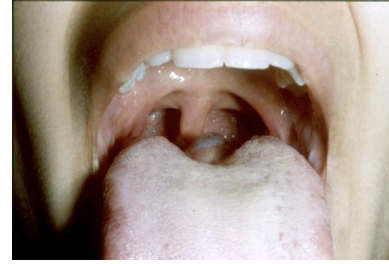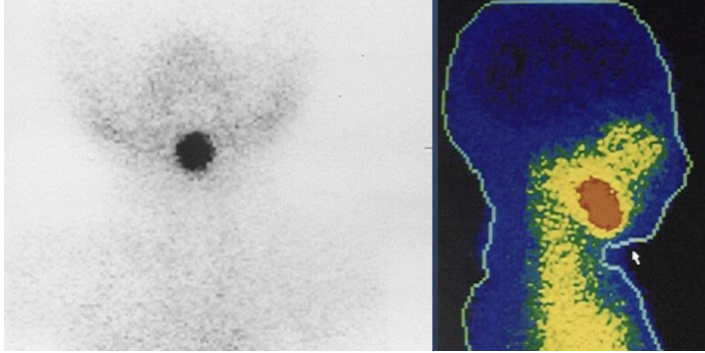
## ➤ Perchlorate Discharge Test

50 - 80 uCi I-123 orally  
 2 hrs RAIU 400 mg Kclo<sub>4</sub>  
 RAIU/ 15 min for 2 hours  
 Positive test :  $\geq 15$  fall of RAIU below 2 hours. uptake



## ⇒ Evaluation of neck masses ectopic thyroid vs thyroglossal cyst

### Lingual thyroid



If a patient presented with Mass at the base of the tongue – You should order a thyroid scan

**A** → Mass at the midline of the neck submental?..

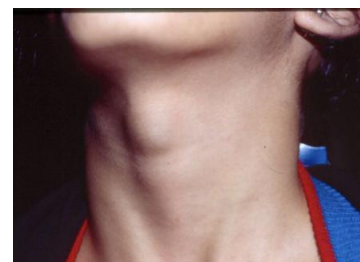
**Lateral view** (to confirm the diagnosis) → Mass appears at the base if the tongue

**Management** : removed surgically , and implanted in the arm or in the wall of the abdomen , it will function normally producing thyroid hormone

(Remember, Thyroid gland is derived from third pouch )

For Unknown reasons Sometimes it doesn't migrate to its normal position (in front of the thyroid cartilage) It remains arrested at the base of the tongue

## ⇒ Thyroglossal cyst



### Patient with midline neck mass

As the thyroid descend through the thyroglossal duct sometimes this duct remains producing a cyst (remnant of thyroid tissue)

**Management** : Removed surgically

## » Evaluation of Thyrotoxicosis

Thyrotoxicosis **IS NOT** synonymous to Hyperthyroidism

**Thyrotoxicosis** : Is a complex of signs and symptoms due to elevated thyroid hormones in the blood

**Hyperthyroidism** : Overproduction of thyroid hormones by the thyroid gland (hyperactive gland)

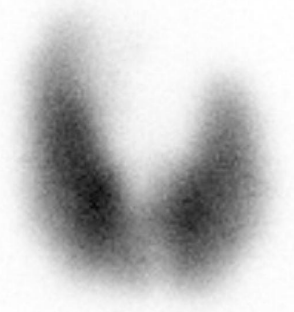**Thyroid scan In thyrotoxicosis is imp ;**

- can help in differentiating between thyrotoxicosis with hyperthyroidism from thyrotoxicosis without hyperthyroidism.
- therapy decision is based on the scan results if its hyperthyroidism or not

## » Thyrotoxicosis with hyperthyroidism

- **Graves' Disease**
- **Neonatal hyperthyroidism**
- **Toxic nodular goiter :**
  - MNTG or Plummer's disease
  - ATN or toxic adenoma
- **Iodine induced ( Jod-Basedow disease )**
- **Rare causes :**
  - Excessive HCG by trophoblastic tumor
  - Hypothalamic pituitary neoplasms (TSH induced)

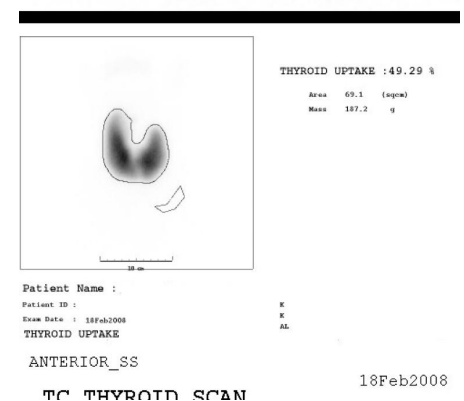
Diffuse enlargement of the thyroid gland in Graves disease  
With high uptake (49%)



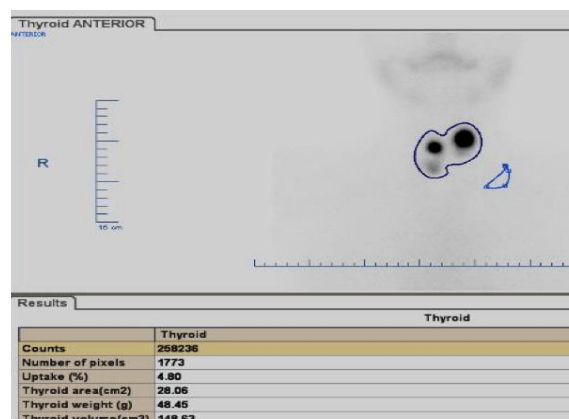
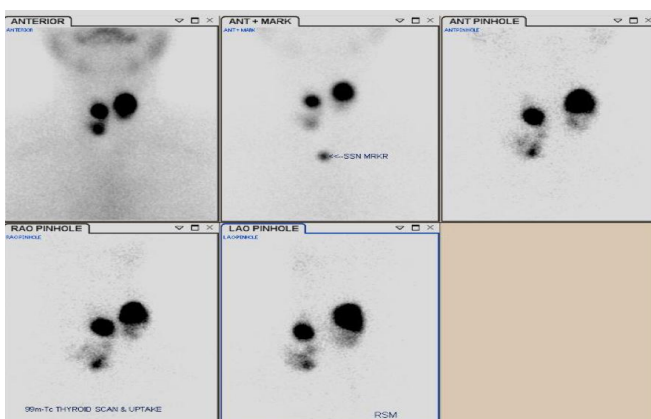
SN MRKR--->

Patients with overproduction of thyroid hormone need definitive treatment:

- Antithyroid drugs, Complications: Agranulocytosis
- I 131 therapy
- surgery



## » Multinodular toxic goiter (MNTG) (Plummer's Disease)





## Thyrotoxicosis with Hyperthyroidism

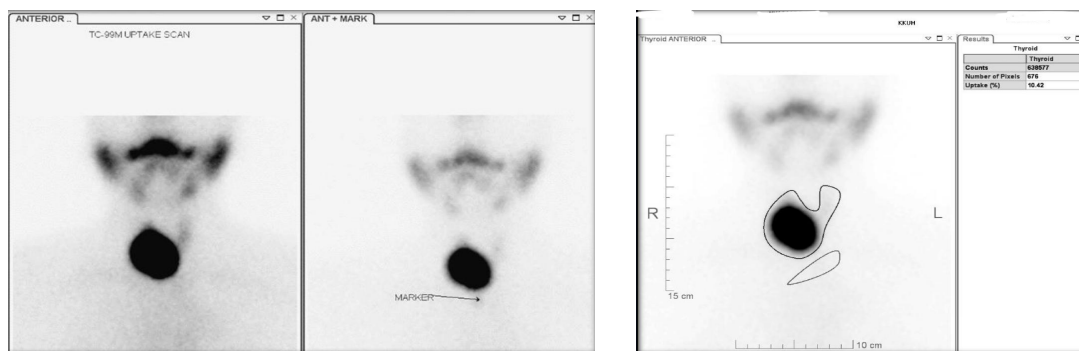
### Graves' Disease on top of MNG Nodular Graves Disease (Marine-Lenhart syndrome)

The normal thyroid tissue between the nodules developed hyperthyroidism (graves disease)



High uptake (47%)  
"Hyperactive"

### Autonomous toxic nodule (ATN)



- Very hot nodule, the rest of the gland is not seen
  - High uptake ( 10.4%)
  - Autonomic: Not depended on TSH (Releases hormones without the need of TSH)
- Management:** Iodine therapy \* Best case for iodine therapy

## Thyrotoxicosis without Hyperthyroidism

### • Subacute thyroiditis

Usually the history tells you that the patient had recent infection, 95% normally recover, 5% will have complete hypothyroidism..

### • Chronic thyroiditis with transient thyrotoxicosis

### • Thyrotoxicosis factitia (exogenous hormone) taking thyroxine to lose weight

### • Thyroid extract (e.g.Hamburger thyrotoxicosis)

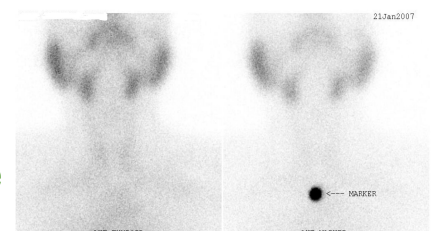
“ingestion of thyroid hormone from contaminated meat”

### • Ectopic thyroid :

- Metastatic thyroid carcinoma
- Struma ovarii

Treatment: symptomatic relief.

they don't need definitive treatment; once the underlying cause is treated function of the thyroid gland returns back to normal



Subacute thyroiditis

## ⇒ Radioactive Iodine Therapy for Hyperthyroidism

- **Isotope used** : I 131 used for therapy; because it emits beta rays
- **Physical Properties** : Solution or capsule
- **Main side effect** : Hypothyroidism  
because you're destroying the thyroid tissue by I-131
- **Dose** :
  - a. Calculated : Considering weight and uptake of the gland
  - b. Empirical :
    - Graves: 5-15 mCi
    - ATN : 15-20 mCi

## ⇒ Radioactive Iodine Therapy for Thyroid Cancer

**Isotope used** : I 131 To destroy thyroid remnants and treat metastasis  
**Physical Properties** : Solution or capsule

- **Thyroid remnant** : 80-100 mCi
- **Lymph Node Mets** : 100 mCi
- **Local Recurrence** : 100 mCi • **Lung Mets** : 150 mCi
- **Bone Mets** : 200 mCi

Doctor said: you don't have to memorize the doses BUT know that I 131 can be used to :

- Therapy of Graves, ATN and hyperthyroidism
- Treat metastasis and remnant in thyroid cancer



## Normal and Ectopic Parathyroid Glands

The **third** pair of pouches:

proliferates into the **inferior** parathyroid glands and the thymus

The **fourth** pair of pouches:

proliferates into the **superior** parathyroid glands and the lateral angle of the thyroid gland.

Because the inferior parathyroid glands undergo more extensive migration during embryogenesis, they are more likely to be found in ectopic locations.

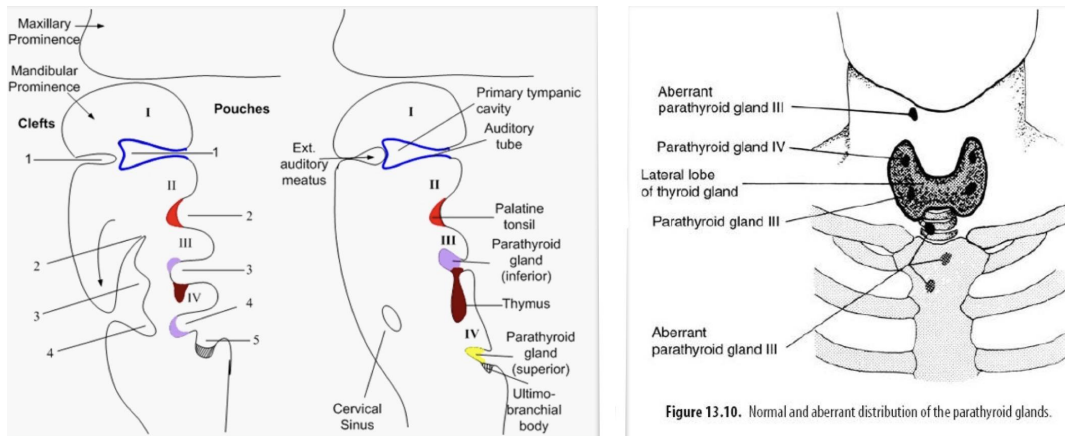


Figure 13.10. Normal and aberrant distribution of the parathyroid glands.

## Ectopic Parathyroid Glands

Location of an ectopic parathyroid glands

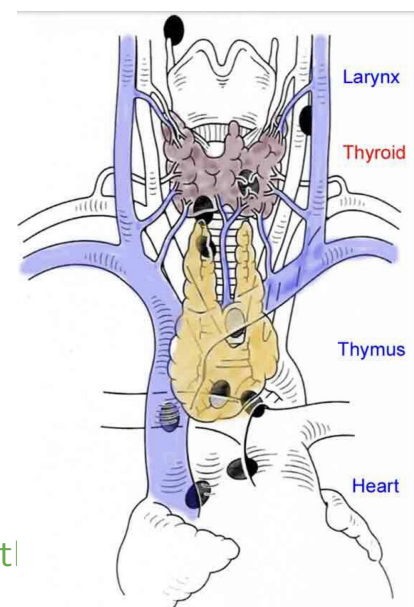
- Submandibular
- Retropharyngeal
- Retroesophageal
- Posterosuperior mediastinal
- Intrathyroidal
- Within the tracheoesophageal groove Carotid sheath
- Thyrothymic ligament
- Intrathymic
- Antero-superior mediastinal.

Value of parathyroid scan :

- screening for ectopic parathyroid gland  
(Screen the neck from the submandibular area to the upper mediastinum)
- Localization of ectopic (abnormal) parathyroid gland

Diagnosis of hyperparathyroidism by :

its tumor marker the Parathyroid hormone (PTH) and high calcium



## ➤ Parathyroid Scan Techniques

- TL-201 – Tc-99m subtraction
- Tc -99m Sestamibi ( Dual Phase ) Gold standard
- Tc -99m Tetrofosmin ( Dual Phase )

Radiopharmaceutical	99mTc / 201Tl Subtraction	99mTc sestamibi
Activity administered	80 MBq (2 mCi) 201Tl; 370 MBq (10 mCi) 99mTc	925 MBq (25 mCi)
Images acquired	Inject Tl .rst and acquire 15-min 100 000 count view of neck and mediastinum. Then acquire similar Tc images without moving patient. Subtract Tc data from Tl after normalization to equal count densities	Anterior (and oblique) views at 15 min and at 2-3 h; SPECT as needed

## ➤ Tc -99m-Sestamibi

The Parathyroid Study depicts hypertrophied parathyroid tissue, probably because of uptake of Tc-99m-sestamibi in the mitochondria of hyperactive cells.

**Indications :** Detect and localize parathyroid adenomas .

**Patient Preparation :** None

**Radiopharmaceutical, Dose, & Technique of Administration**

- **Radiopharmaceutical:** 25 mCi Tc -99m-sestamibi I.V
- **Patient position:** Supine with head and neck extended and immobilized.
- **Gamma camera Imaging field:**
  1. Neck.
  2. Upper two thirds of the mediastinum

**Acquire images at 15 minutes and 2-3 hours post injection.**

**SPECT/SPECT CT images improves localization.**

Give the patient 25 mCi. Scan the patient after 15-20 min and after 2-3 hours.

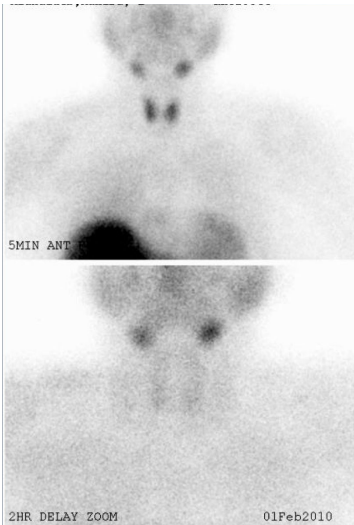
If there is an abnormal uptake proceed to do SPECT; to localize the abnormal parathyroid gland

## ➤ Tl-Tc99m subtraction :

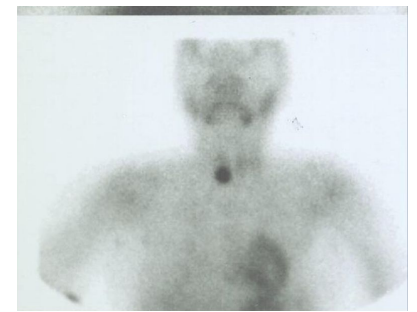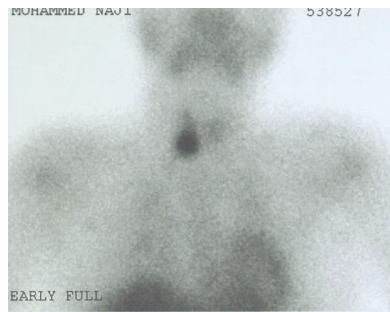
Several protocols have been developed for routine subtraction of thyroid tissue from parathyroid tissue. rarely used

# Parathyroid Scan

## » Dual phase MIBI Scan ( Or Tetrofosmin )



Normal parathyroid glands are small and not visualized (5mg)



Abnormal parathyroid glands can be visualized  
Right lower parathyroid adenoma

### Early image

Sestamibi goes to the thyroid and abnormal parathyroid

### 2-3 Hours image

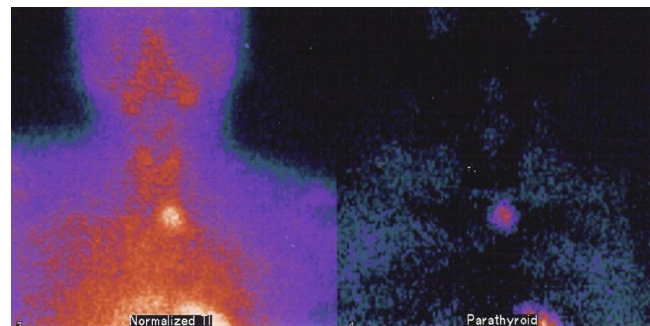
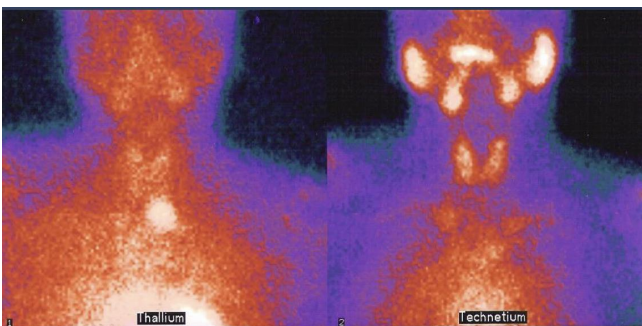
Washout from the thyroid and remain in the abnormal parathyroid

Don't request Sestamibi scan to see the normal parathyroid gland

It should be requested to:


- Determine from where the high PTH is coming from
- patient with abnormal parathyroid gland

## » Tc-Tl Subtraction Scan



1. thallium is given to the patient, it will go to the thyroid and abnormal parathyroid.
2. Then only technetium is given which goes to the thyroid only
3. Subtract the images of technetium thyroid scan from the thallium scan, to visualize the parathyroid gland

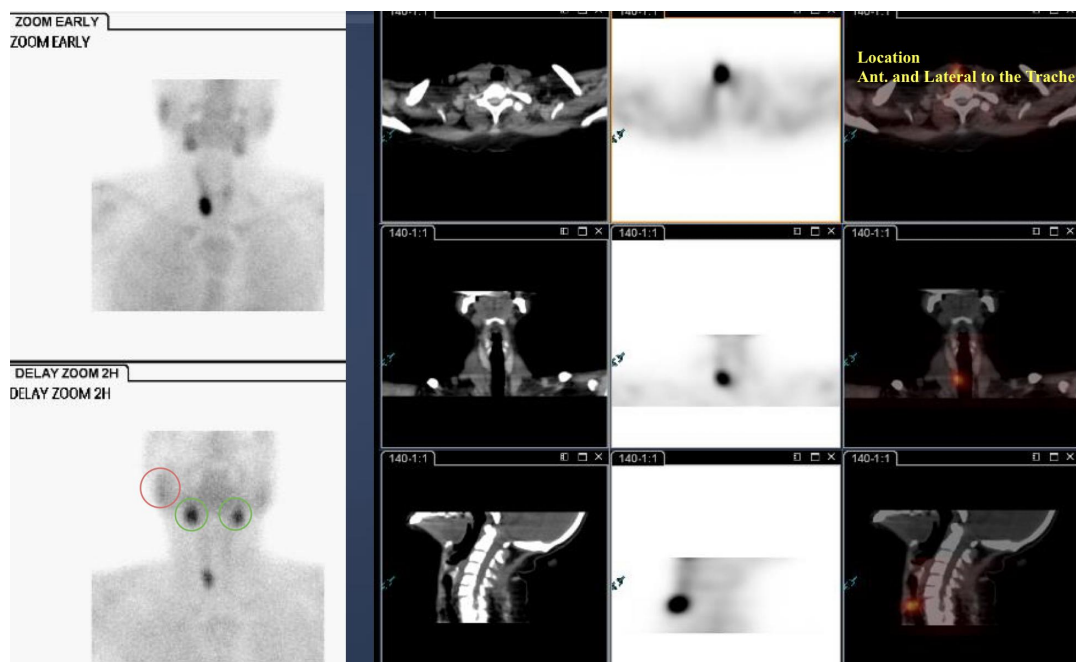
## ➤ Sestamibi dual phase



**Early image:** goes to thyroid and abnormal parathyroid

**2H delay image:** washout from the thyroid gland and retention of activity in right lower parathyroid adenoma

## ➤ Sestamibi Dual Phase ( Planar vs SPECT CT)



### Planar image

**Early image:** goes to thyroid and abnormal parathyroid

- Pink: Submandibular gland - Green : parotid gland

**delay image:** washout from the thyroid gland and retention in the right inferior parathyroid lobe

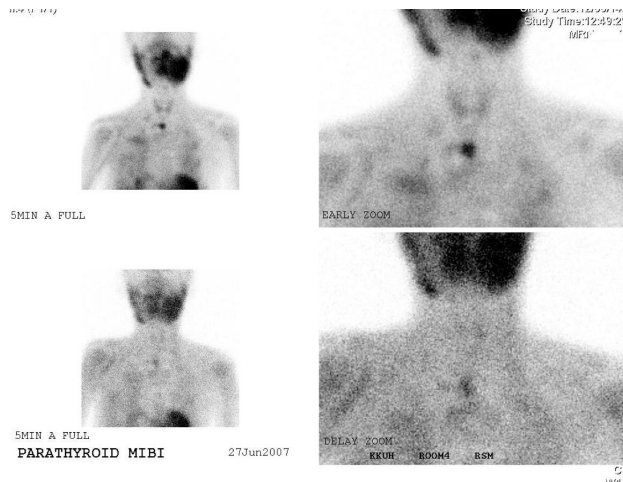**SPECT CT :** For precise localization of the parathyroid adenoma

Site of adenoma : Lateral and anterior to the trachea (easy to remove it by a small anterior incision)



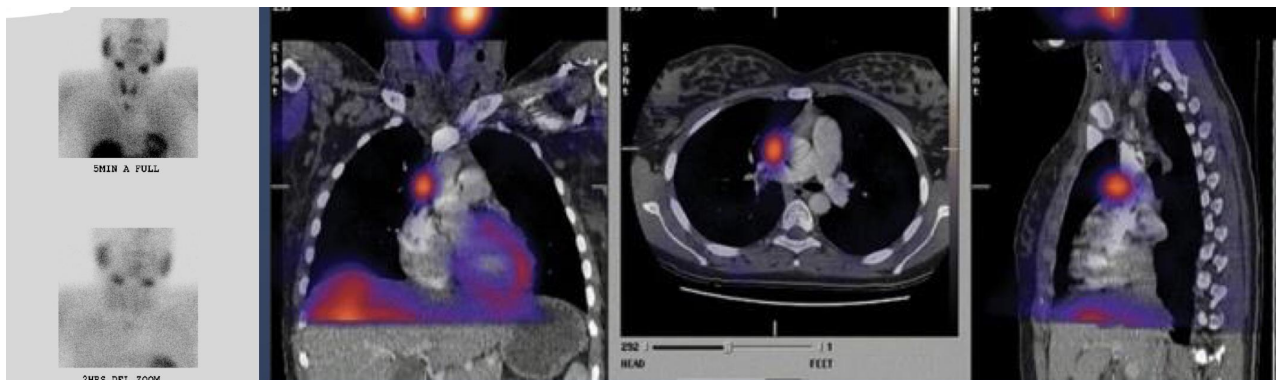
## » Ectopic Parathyroid : 16% of total adenomas

Focal retention of tracer in the upper mediastinum, for precise localization of the parathyroid adenoma request SPECT CT



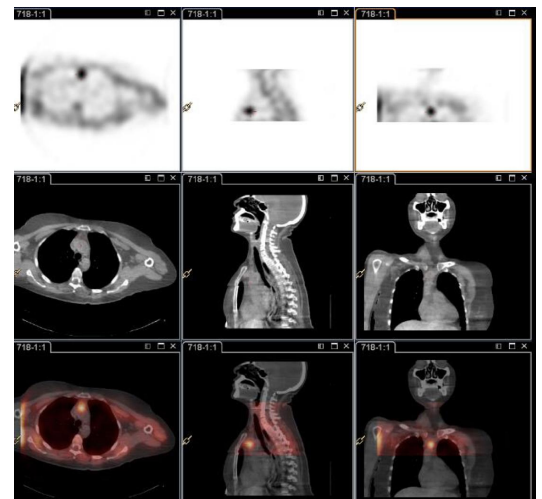
## » Ectopic Parathyroid Adenoma PLANAR vs SPECT/CT

- Abnormal uptake is close to the aortic arch, need help from thoracic surgeon
- SPECT-CT images accurately localize the adenoma and guide the surgeon to the best surgical approach




## » Ectopic parathyroid adenoma Antero-superior mediastinum

Lesion is Easy to be managed as it's located posterior to the sternum (retrosternal) parathyroid adenoma can be removed by a small incision superior to the mediastinal area

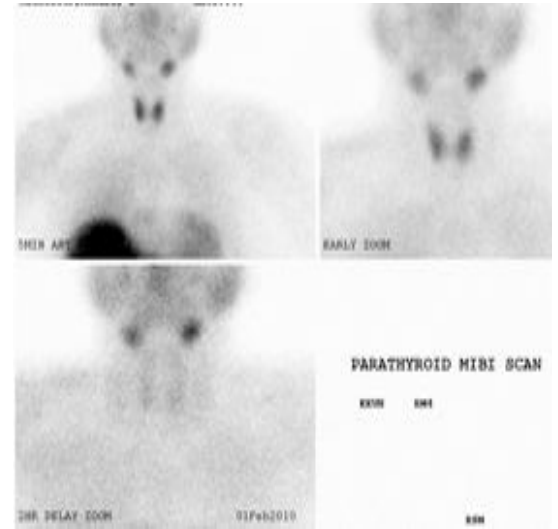


## » Sestamibi Parathyroid Scan Results :

High PTH / High Ca “TP:True Positive”



High PTH / High Ca “FN:False negative”



## » Mechanism of sestamibi uptake: >is the cause of the FN result

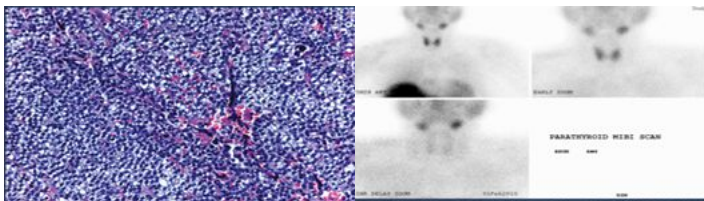
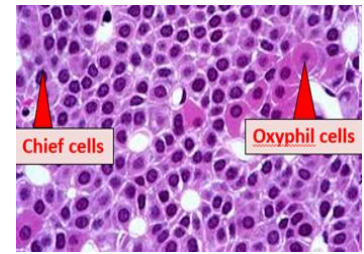
### SESTAMIBI : METHOXYISOBUTYLISONITRILE.

- Its parathyroid uptake was first reported by Coakley et al. in 1989.
- Mechanism of MIBI uptake and retention is still unclear. Multifactors have been proposed:
  - **Biochemical properties of the tracer:**  
**Lipophilicity:** The lipophilic sestamibi molecule is concentrated by mitochondria. This explains why adenomas with an abundance of mitochondrial-rich oxyphil cells retain the sestamibi Cationic charge.
  - **Cell Type:** A predominance of oxyphil cells within an adenoma is more likely to lead to a positive scan.
  - **Local factors:** Blood flow, trans-capillary exchange, interstitial transport and negative intracellular charge of both mitochondria and membranes.

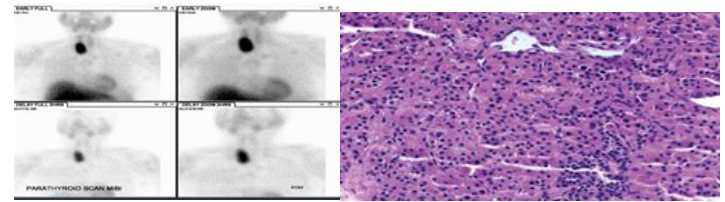


## ➤ Normal parathyroid glands comprise 2 cell types:

- **Chief cells:** responsible for PTH production.
- **Oxyphil cells:** eosinophilic cells whose cytoplasm is composed almost entirely of mitochondria.
  - **While the normal oxyphil cell does not synthesize and secrete PTH, the oxyphil cells of pathologic parathyroid glands do secrete the hormone.**
- Sestamibi concentrates in the mitochondria. if the adenoma derived from oxyphilic cell it will show on sestamibi (the scan will be **positive**) and if the tumor derived from Chief cell it will not show on sestamibi (it will not uptake the sestamibi and the scan will be **negative**) we do MRI -and ultrasound- to confirm adenoma from chief cells.



Parathyroid adenoma composed entirely of **glycogen-rich chief cells.**



Parathyroid adenoma composed mainly of **mitochondrial-rich oxyphil cells.**

## ➤ What is the cause of the FN Sestamibi scan results?

- **Histologic type:** False-negative scans can occur with parathyroid glands containing predominantly clear cells.
- **Size and Location:** Smaller-volume parathyroid adenomas and those in the upper position are less likely to be localized with sestamibi scans.
- **Number of adenomas:** FN rate is increased with MGD compared with patients with a single adenoma.
- **Decreased tracer concentration:** Possible association:
  - P-glycoprotein expression.
  - Multidrug resistance-related protein expression.
- **Variability of radiotracer uptake in parathyroid adenomas:** Related to differences in perfusion and metabolic activity. Even with refinements in sestamibi scanning, the fact that all parathyroid adenomas are not created equal on a cellular level may inevitably lead to FN scans in a certain number of cases.

### » False-Positive Scintigraphic Findings:

In the clinical setting of hyperparathyroidism, false-positive findings are uncommon.

- Solitary thyroid adenoma or a multinodular goiter.
- Benign or malignant tumors: breast, lung, and head and neck carcinomas and their lymph node and osseous metastases, as well as bronchial carcinoids.
- Primary thyroid lymphomas.
- Cervical L.N. metastasis from PTC carcinoma.
- Reactive lymph nodes.
- Remnant thymus.
- PTH-secreting paraganglioma.
- Enlarged submandibular salivary gland.

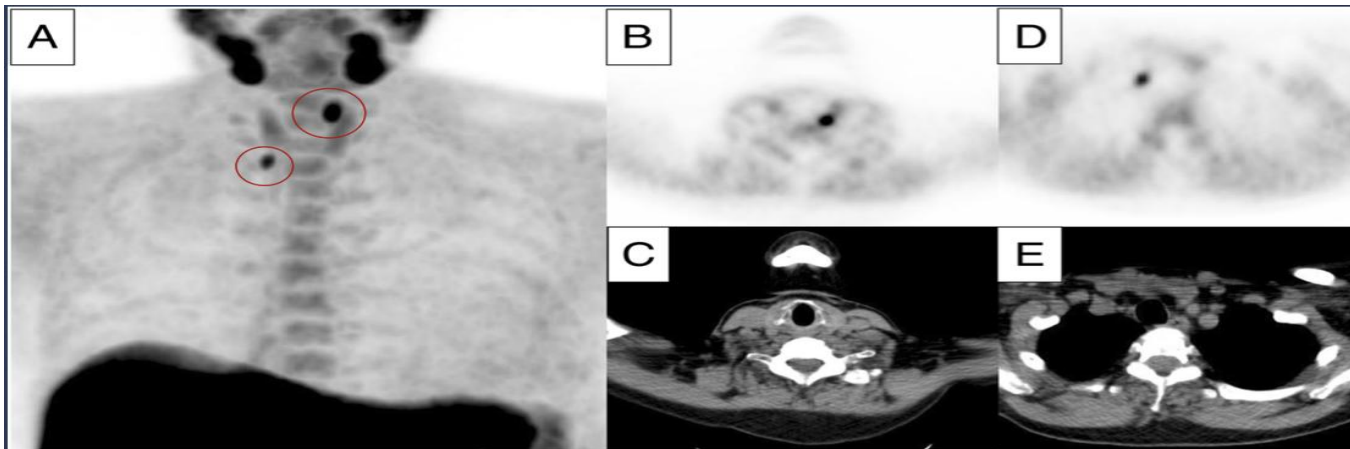
### » Points To Remember Before Proceeding For Parathyroid Imaging:

- Imaging is not for diagnosis: High Ca and PTH establish the diagnosis.
- Imaging does not identify normal parathyroids: These are too small to be seen (20-30mg).
- Imaging should detect abnormal parathyroid(s) and indicate the approximate size and the precise relationship to the thyroid gland: lateral, SPECT and SPECT /CT.
- Imaging should identify ectopic glands: SPECT and SPECT/CT. "Full neck and upper mediastinum"
- Optimal imaging should be able to **differentiate** patients with single adenoma from those with MGD.
- Imaging should identify **thyroid nodules** which may require concurrent surgical resection.

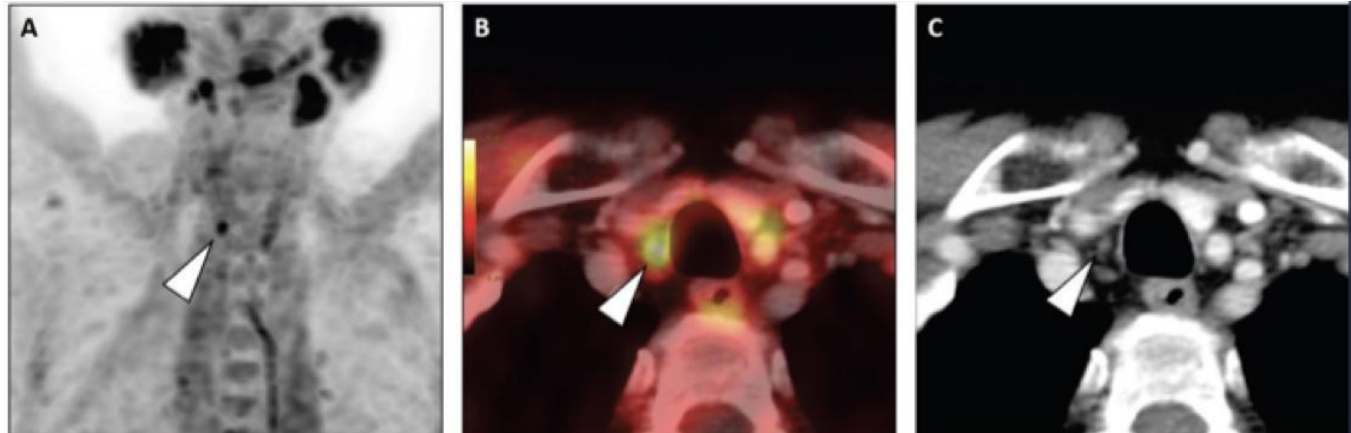
## ➤ 18f-fluorocholine PET/CT:

- New radiopharmaceuticals for parathyroid imaging
- Very sensitive for chief cells and oxyphils.
- Very expensive “one dose could cost 16000 SR!”.

## ➤ 18f-fluorocholine parathyroid scan:



Double parathyroid adenoma (SESTAMIBI scan was negative)



Focal hyperactivity posterior to the right caudal pole of right thyroid lobe and, histologically confirmed as parathyroid adenoma. Previous imaging by neck US and MIBI was inconclusive

## » DON'T FORGET ( by 432 team)

- Technetium half-life is **6 hours**.
- **To assess the organification we use I123** not Tc-99.
- **The gold standard tracer in RAIU is 123.**
- **If patient is on thyroxine s/he should stop it 3-4 weeks before thyroid scan.**
- If patient is on antithyroid s/he should stop it 3-5 days before thyroid scan.
- The patient **should not** have any I.V contrast for at least 3- weeks before scan.
- RAIU is to determine how much of the dose we give to the patient is taken by the thyroid gland.
- I 123 is used for **diagnosis** while I 131 for **therapy** (cancer or hyperthyroidism).
- Causes of abnormal thyroid uptake. (either high or low)
- A common cause of thyroid cancer is **irradiation**.
- In thyroid cancer the uptake is most likely **normal**.
- **Hot nodules have no chance (<5%) of being malignant.**
- Cold nodules have 15% chance of malignancy in females and **higher in males 20%.**
- **The most common cause of hot nodule is ATN.**
- **Indication of thyroid nuclear imaging include:**
  - Evaluation of thyroid nodules.
  - Evaluation of congenital hypothyroidism: Agenesis Vs. Dyshormonogenesis.
  - Evaluation of neck masses: ectopic thyroid, thyroglossal cyst.
  - Evaluation of thyrotoxicosis.
- Perchlorate discharge test is used **to confirm dyshormonogenesis.**
- **RAIU is used also to evaluate:**
  - Thyroiditis : subacute and chronic thyroiditis.
  - Thyroid Cancer : Remnants uptake in preparation for therapy. (after surgery how much remnants is left, to prepare for I 131 therapy).
- **Lactating mothers should stop breastfeeding according to the following:**
  - **Completely after I 131 therapy**
  - **3 weeks before diagnostic I 131**
  - **12 h after 99mTc.**
- **The main side effect of radioactive iodine therapy for hyperthyroidism is hypothyroidism.**
- Parathyroid imaging needs combination of several modalities. Sestamibi and MRI are the best combination.
- Parathyroid scan results depends on the **histological type of adenoma.**
- Normal parathyroid scan doesn't exclude parathyroid adenoma.

# Summary

## Thyroid scan procedure

Tc-99m	I-123
Not expensive, half time is 6 hrs, 20 mins after injection in one time visit. Trapped NOT organified.	Expensive, half time is 13 hrs, 3 time visit. Trapped AND organified

## Thyroid scan indication

Evaluation of thyroid nodules: No. & type (hot vs cold nodule).  
Evaluation of congenital hypothyroidism.  
Evaluation of neck masses.  
Evaluation of thyrotoxicosis.

## Evaluation of thyroid nodule

Hot	Cold	Warm
due to high activity, suppresses the other parts of the gland, <5% of malignancy, ATN as an example	no uptake of the affected part, higher chance of malignancy	the uptake is slightly higher than the others, suspicious....

## Evaluation of neck masses

Ectopic thyroid	Thyroglossal cyst:
Ex. lingual thyroid(base of the tongue), functional	forms from remnants of thyroglossal duct

## Parathyroid gland

<sup>99m</sup> sestamibi (dual phase) is the GOLD STANDARD.  
adenoma rising from chief cells will have negative parathyroid scan (false -ve)  
adenoma rising from oxyphil cells will have positive parathyroid scan (true +ve)

1- Which ONE of the following agents is used for parathyroid

- a. Tc-99m MDB
- b. Tc-99m SESTAMIBI
- c. Gallium-67
- d. Tl201

2- which of the following is true in parathyroid imaging:

- a. Imaging doesn't identify ectopic glands
- b. Imaging doesn't identify normal parathyroid
- c. Imaging is considered a diagnostic method
- d. Imaging doesn't identify thyroid nodules

3- half time of I-123 is:

- a. 16 hrs
- b. 13 hrs
- c. 8 hrs
- d. 24 hrs

4- Sestamibi scan concentrates in:

- a. Nucleus
- b. Golgi
- c. Mitochondria
- d. Endoplasmic reticulum

5- the nodule with the lowest chances of being malignant:

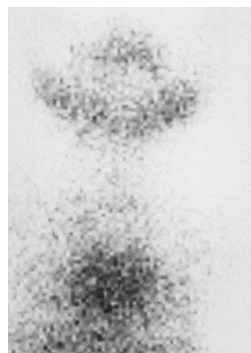
- a. hot nodules
- b. cold nodules
- c. warm nodules

6- Thyrotoxicosis with hyperthyroidism

- a. subacute thyroiditis
- b. thyroid extract
- c. jod-basedow disease
- d. ectopic thyroid

7- newborn presented with Elevated TSH and low T4, thyroid Scan shows :

- a. dyshormonogenesis
- b. Agenesis
- c. thyroid aplasia.



Answers  
1) B  
2) b  
3) b  
4) c  
5) a  
6) c  
7) b