



**Radiology**  
Team 438


# Radiology of endocrine diseases

## Lecture 20

### Objectives

- ❖ There is only one way to happiness and that is to cease worrying about things which are beyond the power of our will
- ❖ Happiness is when what you think, what you say, and what you do are in harmony
- ❖ The successful warrior is the average man, with laser-like focus.
- ❖ No objectives, :)

Reviewed By



Noura Alturki  
Jehad Alorainy

Color Index:

♦ Important

♦ Doctor's Notes

♦ Extra

♦ Female slides

♦ male slides

### Team Leaders



Omar Aldosari



Leena Alnassar



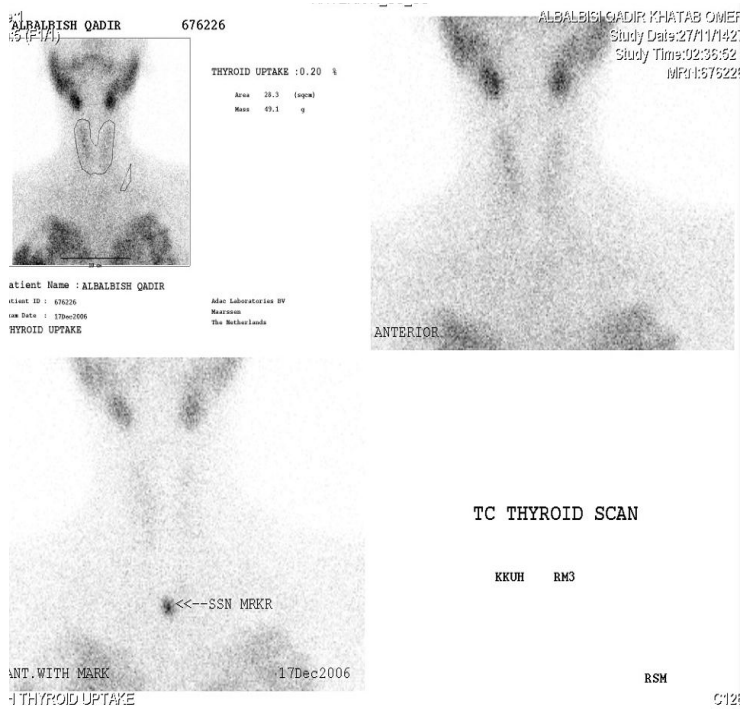
Shahd Alsalamh

### Done by:

Bassam AL Khuwaitir

## Case 1

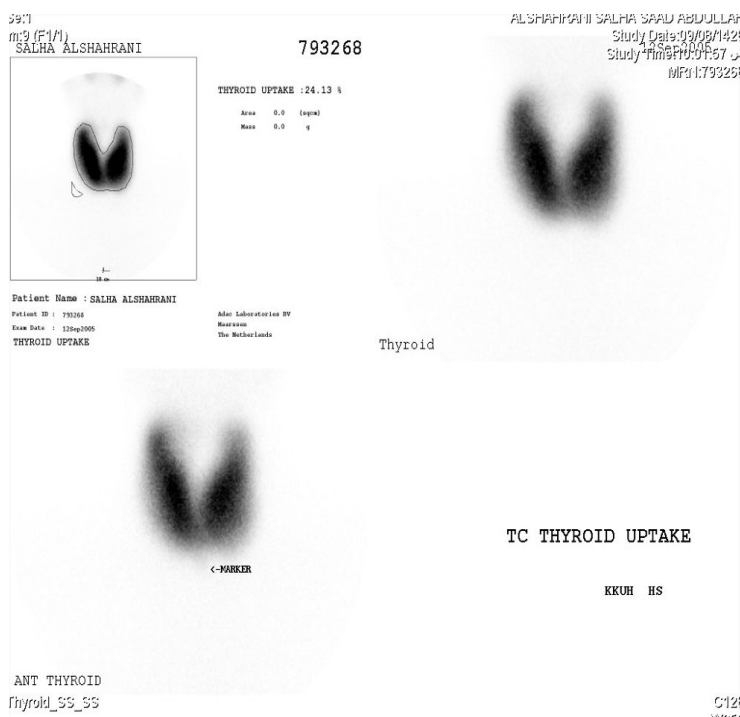
Elevated T4 and suppressed TSH.



- What is the study?  
Nuclear scan of the thyroid.
- What is the agent used?  
Tc-99m Pertechnetate.
- What are the imaging findings?  
Decreased uptake in both lobes 0.20% (thyroiditis).  
(Normal 0.5%-4%).
- DDx of Thyrotoxicosis with reduced uptake:
  - factitious thyrotoxicosis Iodine induced
- What is the most likely diagnosis?  
Subacute Thyroiditis (postpartum thyroiditis).
- What is the treatment?  
Symptomatic treatment give beta blockers.

## Case 2

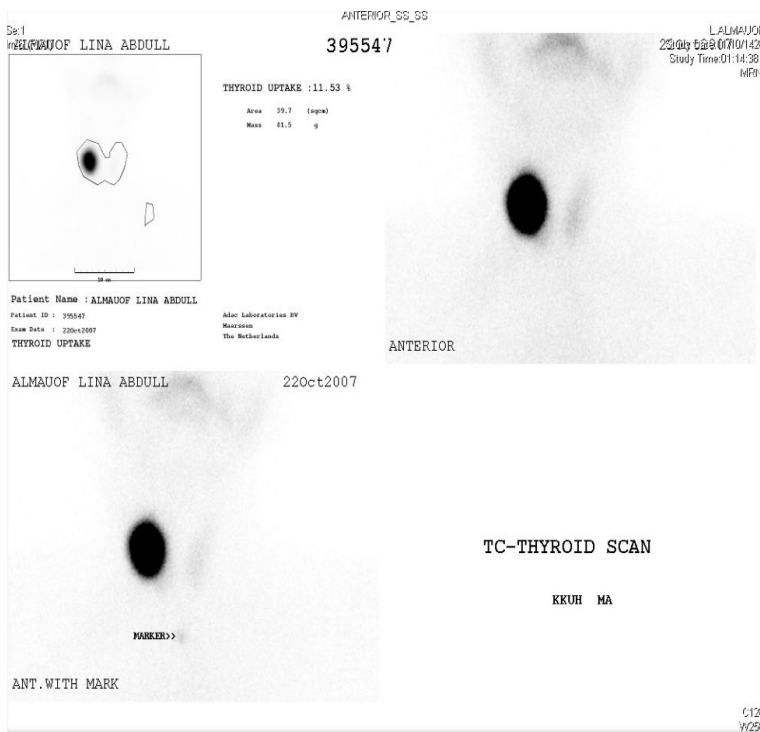
Elevated T4 and suppressed TSH. (Thyrotoxicosis)



- What is the study?  
Nuclear scan of the thyroid.
- What is the agent used?  
Tc-99m Pertechnetate.
- What are the imaging findings?  
Bilateral diffuse uptake 24.13% (Normal 0.5%-4%)
- What is the most likely diagnosis?  
Grave's disease (because it is diffused) (hyperthyroidism).
- What is the treatment?  
Need definitive treatment (3 modalities) : 1) Medical (Antithyroid). 2) Surgical. 3) Radioactive iodine (RAI).
- Give 4 causes of increased thyroid uptake?
  - 1) Autonomous toxic nodule.
  - 2) Multinodular toxic goiter (Plummer's Disease).
  - 3) Enzyme defects (Dyshormonogenesis).
  - 4) Iodine starvation > Iodine deficiency.

## Case 3

Elevated T4 and suppressed TSH.

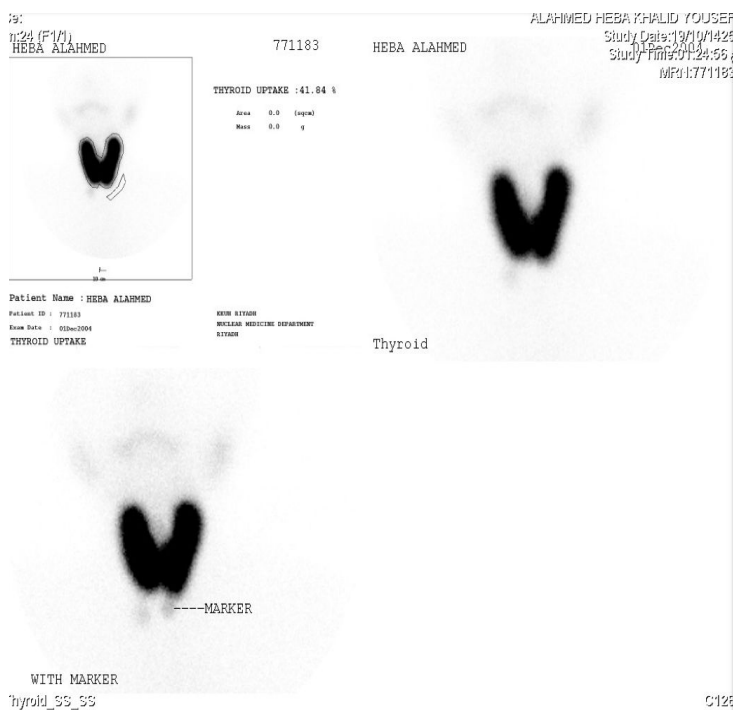


- What is the study?  
Nuclear scan of the thyroid.
- What is the agent used?  
Tc-99m Pertechnetate.
- What are the imaging findings?  
Hot nodule on the right lobe suppressing the left Elevated uptake 11.53% (Normal 0.5%-4%)
- What is the most likely diagnosis?  
Single toxic nodule.
- What is the treatment?  
1st option: RAI (Iodine 131) 1st line therapy.  
2nd option: surgery.
- What is the chances of this nodule of being malignant?  
low chance of being malignant < 5%.

Teaching point: In patients with **thyrotoxicosis**, thyroid scan is used to differentiate thyrotoxicosis with hyperthyroidism from thyrotoxicosis without hyperthyroidism (Thyrotoxicosis = Elevated T4, if it was from the thyroid it is hyperthyroidism)

## Case 4

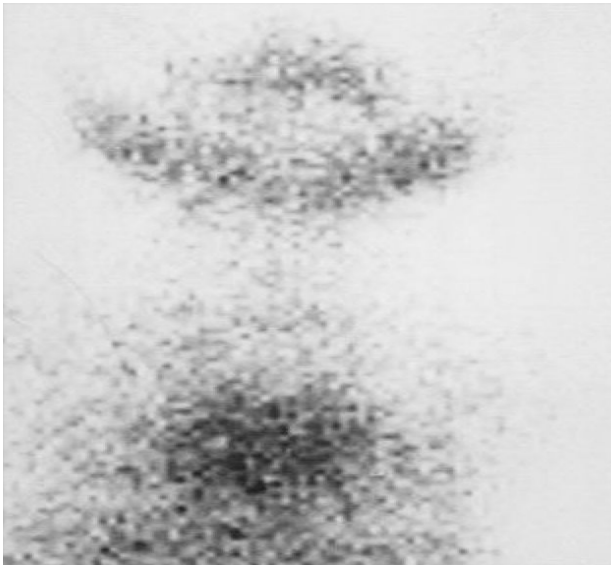
2 year old elevated TSH and low T4.



- What is the study?  
Nuclear scan of the thyroid (for a child).
- What is the agent used?  
Tc-99m Pertechnetate.
- What are the imaging findings?  
Enlarge gland with diffuse elevated uptake (41.84).
- What is the most likely diagnosis?  
Dyshormonogenesis.  
Iodine deficiency will have the same scenario except it's unlikely to appear in a 2 y.o.  
Hypothyroidism ---> Hashimoto  
Congenital hypothyroidism  
Considering the patient's age --> enzyme defect

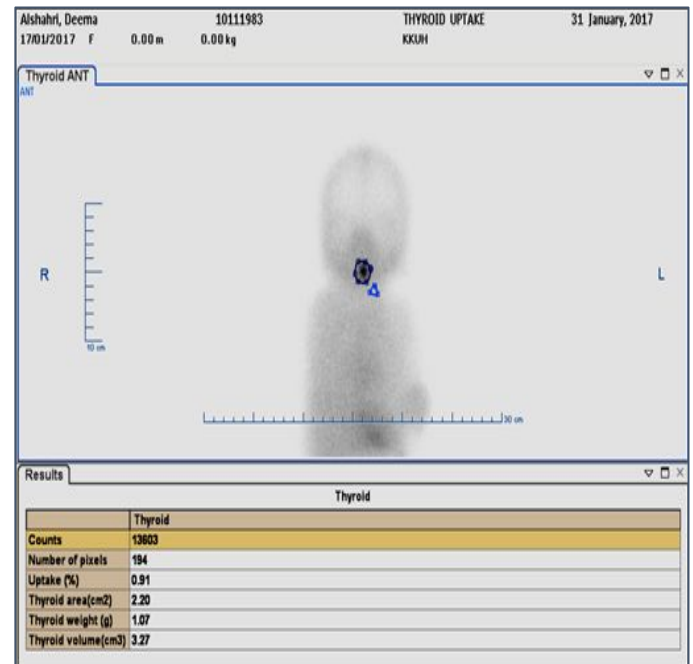
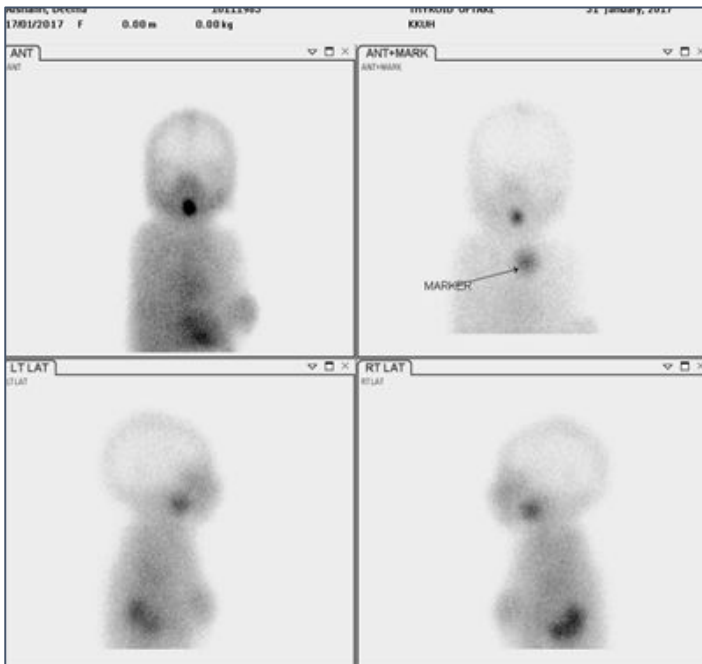
## Case 5

Young patient presented with elevated TSH and low T4.



- **What is the study?**  
Nuclear scan of the thyroid (for a child).
- **What is the agent used?**  
Tc-99m Pertechnetate.
- **What are the imaging findings?**  
Absence of thyroid gland.
- **What is the most likely diagnosis?**  
Agenesis. (Congenitally absent gland)
- **What is the treatment?**  
Thyroxin.

## Case 6

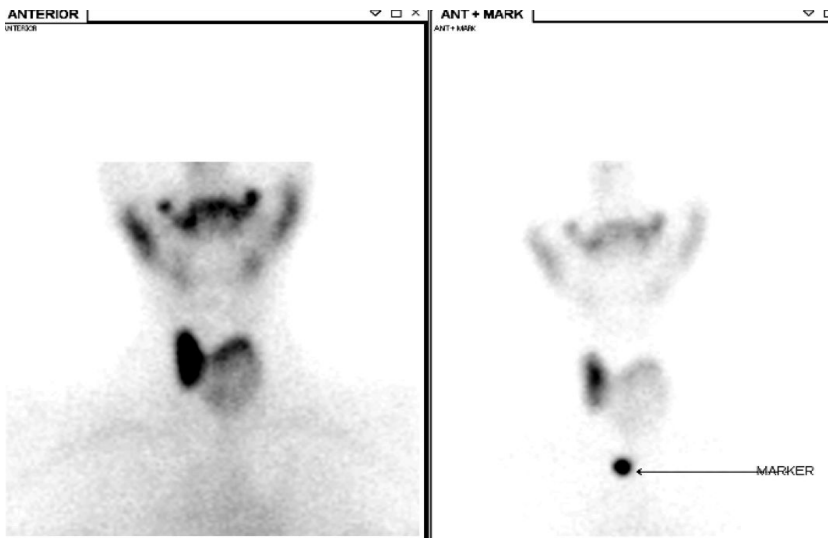


- **What is the study?**  
Nuclear scan of the thyroid
- **What are the imaging findings?** Sublingual thyroid (ectopic thyroid).
- **What is the most likely diagnosis?** Sublingual thyroid (ectopic thyroid).
- **What is the treatment?**
- The uptake here = 0.91% (normal).
- Normal range 0.5-4%.

**Teaching point:** In patients with neonatal hypothyroidism, thyroid scan is used to differentiate dysmorphogenesis from ectopic thyroid and thyroid aplasia.

## Case 7

A young female patient presented with a palpable neck mass.



- **What is the study?**

Nuclear scan of the thyroid.

- **What is the agent used?**

Tc-99m Pertechnetate.

- **What are the imaging findings?**

Enlarged cold nodule on the left with low uptake.

- **What is the most likely diagnosis?**

Mass on the left side with 15% chance to be malignant in females and 20% in males .

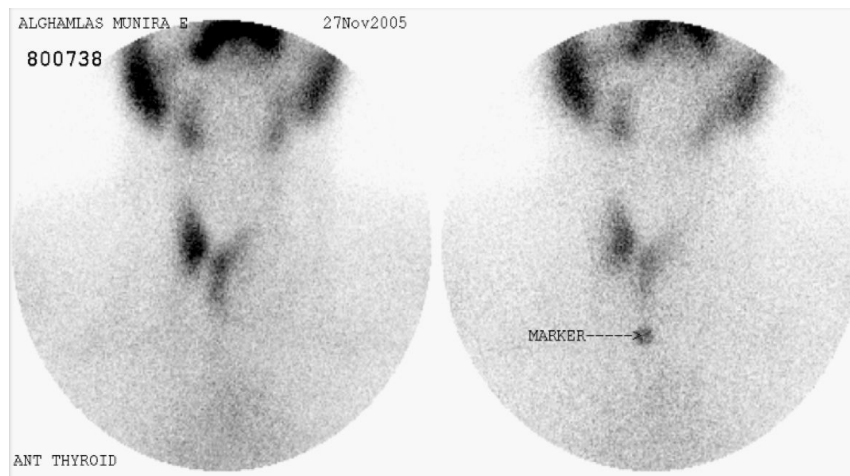
- **What is the treatment?**

FNA to confirm.

If it turns malignant next step is surgery to remove it.

## Case 8

A patient presented with a palpable neck mass.



- **What is the study?**

Nuclear scan of the thyroid.

- **What is the agent used?**

Tc-99m Pertechnetate.

- **What are the imaging findings?**

Decrease uptake in left thyroid lobe (Cold nodule). A mass in the left lobe pushing the thyroid to right.(marker is useful here to tell if there is tracheal shift because it is always below the isthmus. here it is under the nodule so it is pushed). To confirm the tracheal deviation do X-Ray.

- **What is the most likely diagnosis?**

Mass on the left side.

- **What are the chance of this nodule to be malignant?**

15%-20%.

- **What is the treatment?**

FNA to confirm.

If it turns malignant next step is surgery to remove it.

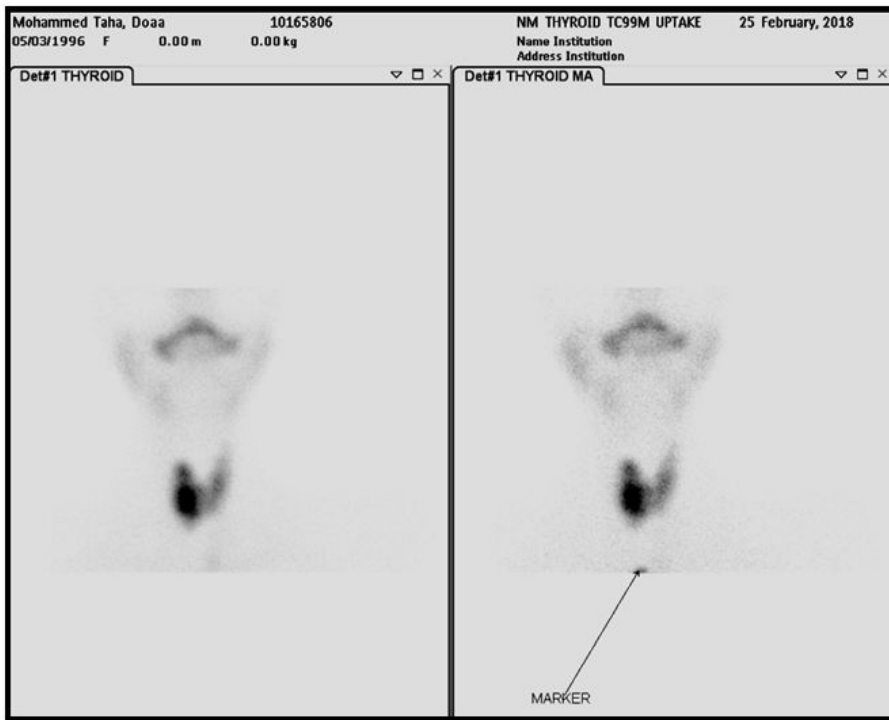
- **Name some compression symptoms?**

1-Dysphagia 2-Hoarseness of voice 3- Dyspnea.



## Case 9

A patient presented with a palpable neck mass.



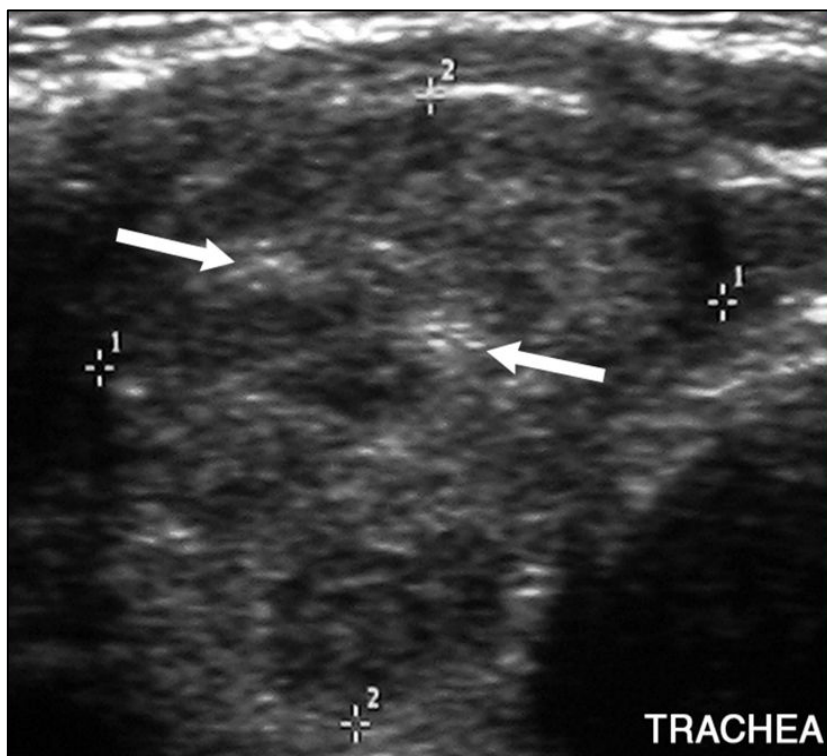- **What is the study?**  
Nuclear scan.
- **What are the imaging findings?**  
Warm nodule on the right lobe (because we can see normal thyroid).
- **What are the chance of this nodule to be malignant?**  
Less than 5%.

patients with neck mass, thyroid scan is used to differentiate cold from hot thyroid nodules.

In patients with **neck mass**, thyroid scan is used to differentiate cold from hot thyroid nodules.

## Case 10

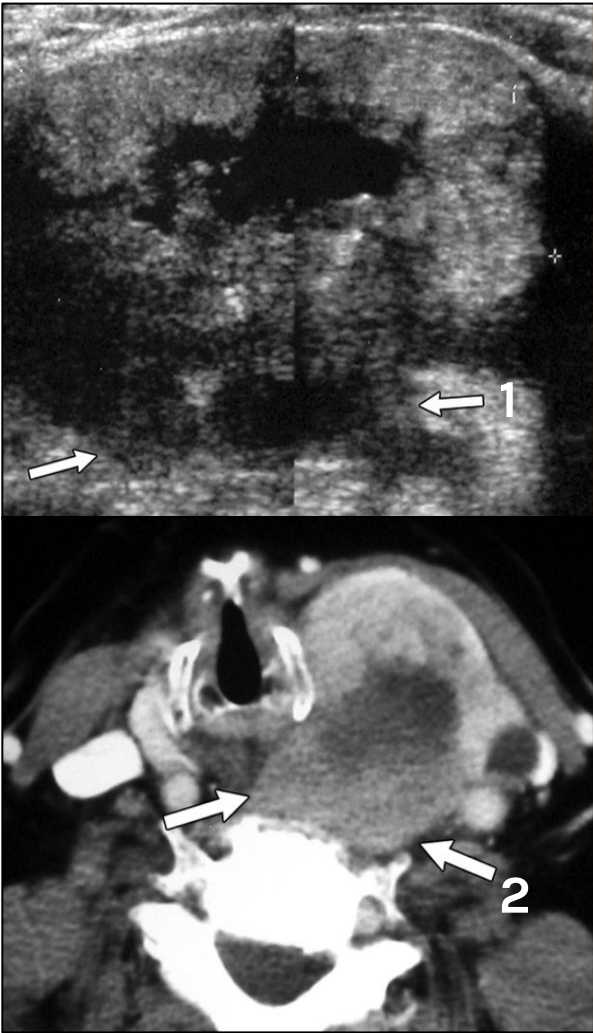
Right Thyroid lobe : Papillary thyroid carcinoma in a 42-year-old man.



- **What is the study?**  
Sonogram (Ultrasound).
- **What are the imaging findings?**  
Transverse sonogram of the right lobe of the thyroid demonstrates:  
Punctate echogenic foci without posterior acoustic shadowing, findings indicative of microcalcifications (arrows).
- **What is the most likely diagnosis?**  
Thyroid carcinoma, do FNA to confirm.

## Case 11

Anaplastic thyroid carcinoma in an 84-year-old woman



- **What is the study?**

Ultrasound (upper Pic) & Contrast-enhanced CT (Lower Pic).

- **What are the imaging findings?**

1. Transverse sonogram of the left lobe of the thyroid shows an advanced tumor with infiltrative posterior margins (arrows) and invasion of prevertebral muscle.
2. Axial contrast-enhanced CT image shows a large tumor that has invaded the prevertebral muscle (arrows).

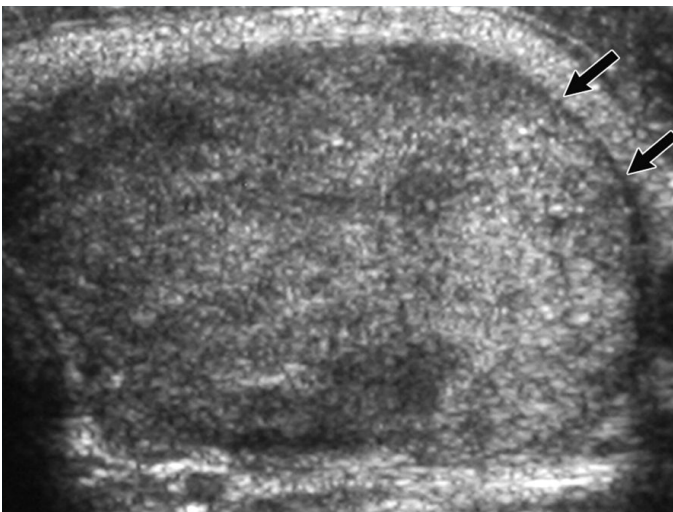
- **What is the most likely diagnosis?**

You need FNA to confirm but most likely it's Anaplastic thyroid carcinoma (anaplastic is very aggressive it usually invades the surrounding tissue).

- In the CT, the capsule invaded. We think it is anaplastic carcinoma which has bad prognosis. Invasion indicates malignancy. In the US, the mass has irregular margins.

## Case 12

30 year old woman presented with a neck mass.



- **What is the study?**

Sonogram (Ultrasound).

- **What are the imaging findings?**

Transverse sonogram of the left lobe of the thyroid shows a follicular adenoma with a hypoechoic halo (arrows).

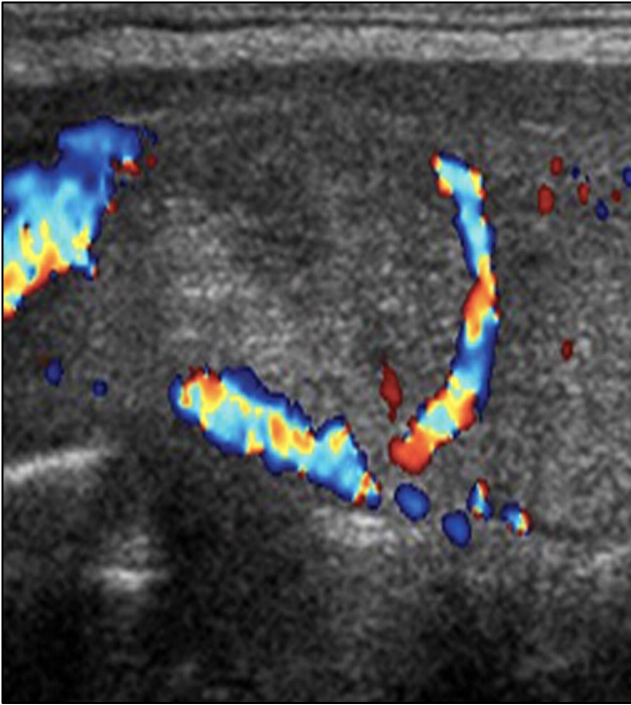
- **What is the most likely diagnosis?**

Follicular adenoma, FNA to confirm.

- Halo shows smooth regular margins, indicating benign condition.

## Case 13

36 year old woman presented with a neck mass.



- **What is the study?**

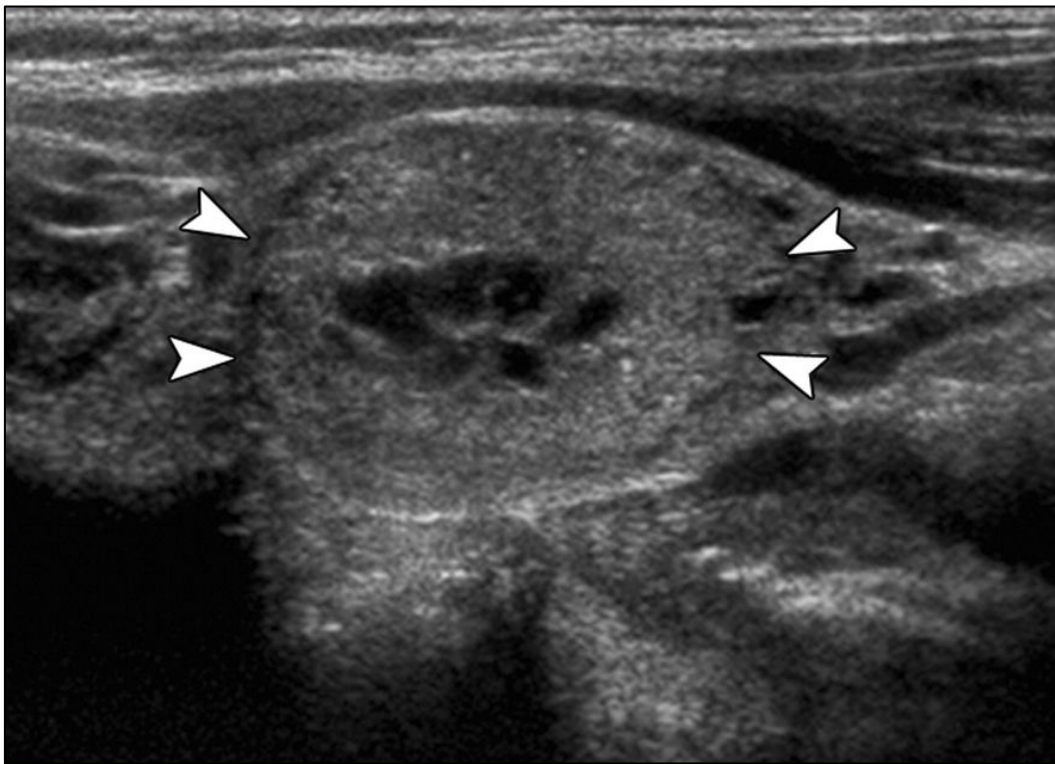
Doppler ultrasound.

- **What are the imaging findings?**

Longitudinal color Doppler sonogram of the right lobe of the thyroid shows perinodular blood flow around a follicular adenoma (benign nodules are less vascular than malignant nodules).

- **What is the most likely diagnosis?**

Follicular adenoma, do FNA to confirm.

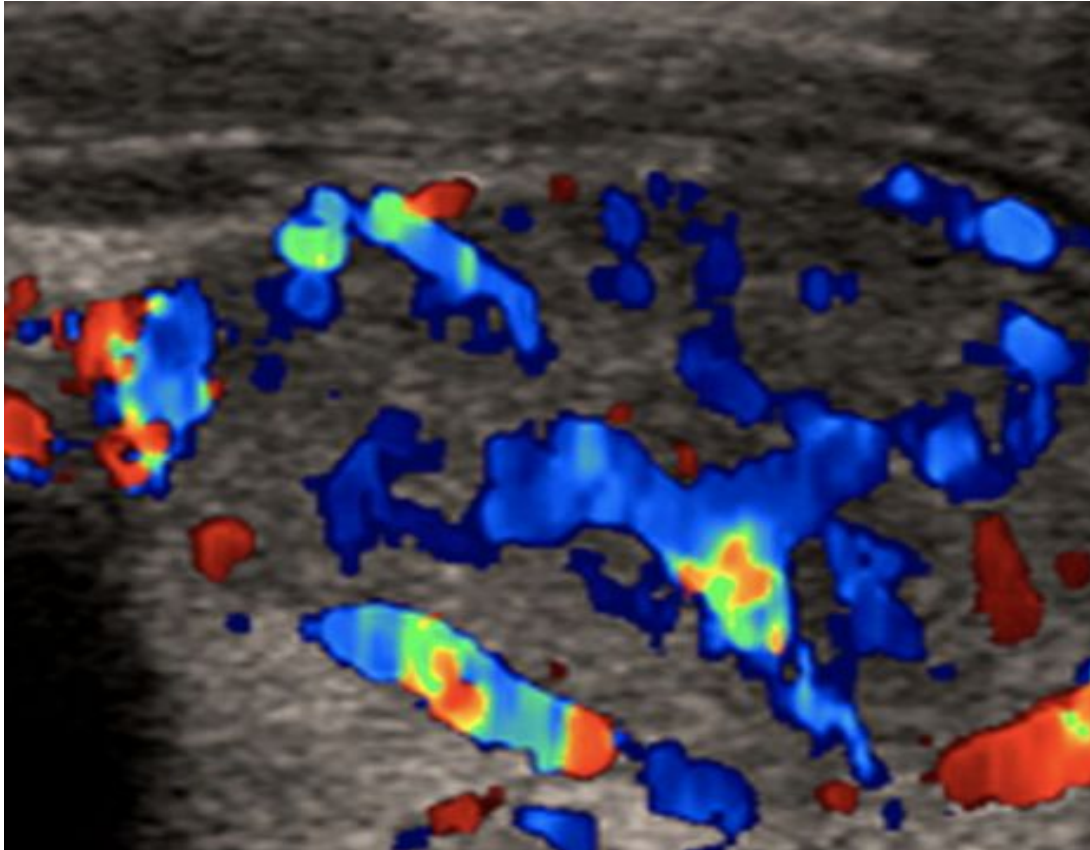


US images of thyroid nodules of varying parenchymal composition (Solid to cystic = Mixed). Halo indicates no invasion. no microcalcifications. Proved to be benign by cytologic exam “No psammoma bodies”.



## Case 14

36 year old woman presented with a neck mass.



- **What is the study?**

Doppler ultrasound.

- **What are the imaging findings?**

Colour Doppler mode shows marked internal vascularity, indicating increased likelihood that the nodule is malignant.

- **What is the most likely diagnosis?**

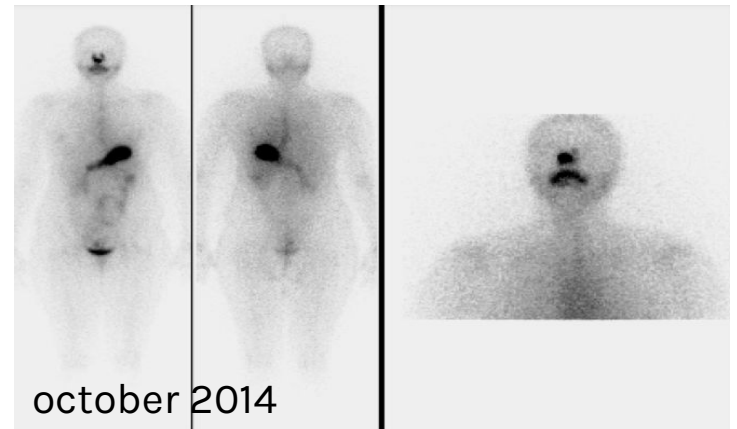
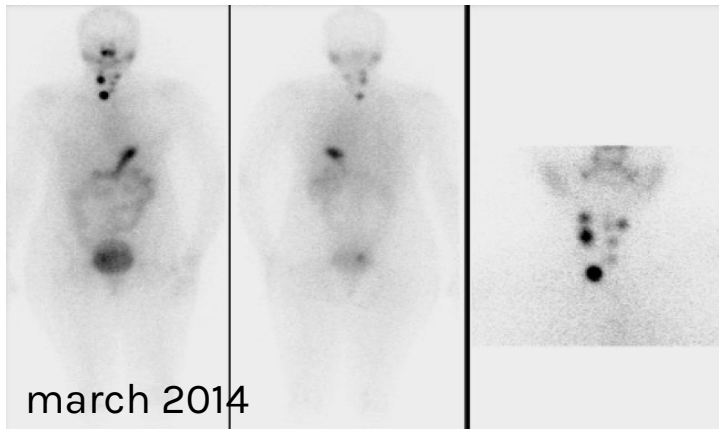
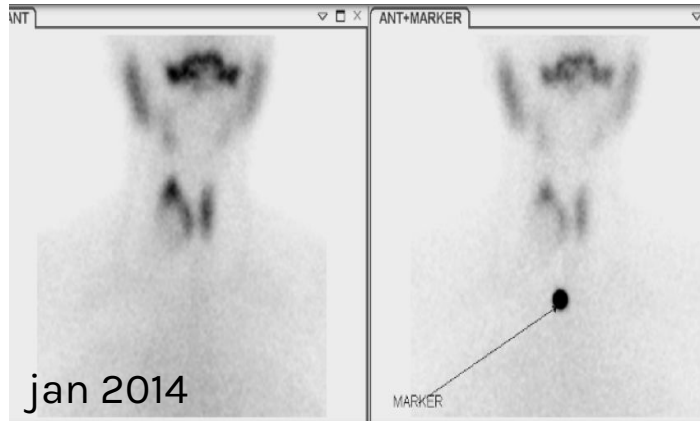
papillary carcinoma

In patients with thyroid nodules ultrasound and color doppler is used to:

1. Determine number of nodules.
2. Differentiate solid from cystic nodules.
3. Characterize thyroid nodule : Benign versus malignant.
4. Assess for regional associate lymph node involvement.

## Case 15

32 years old female patient presented with neck swelling.



- What is the study?

Nuclear thyroid scan.

- What is the agent used?

Technetium

- What are the imaging findings?

In **Jan 2014** we have cold nodule with low uptake in the right lower lobe of thyroid (Next step? FNA)

We did thyroidectomy. we didn't operate on lymph node. **On March 2014** We see multiple hot nodules that spread locally in the neck to lymph nodes we suspect this patient to have papillary carcinoma (Due to mode of transmission) we give her radiation therapy with iodine-131 100 mg.

**Oct 2014** we do scan to exclude any remnant. The patient responds to treatment.

- What is the most likely diagnosis?

Papillary carcinoma.

- Prognosis?

It is good because papillary has only lymph node metastasis, so usually it spreads locally.

(Follicular has hematogenous metastasis -bad prognosis-)

- What is the marker for well-differentiated thyroid tumors?

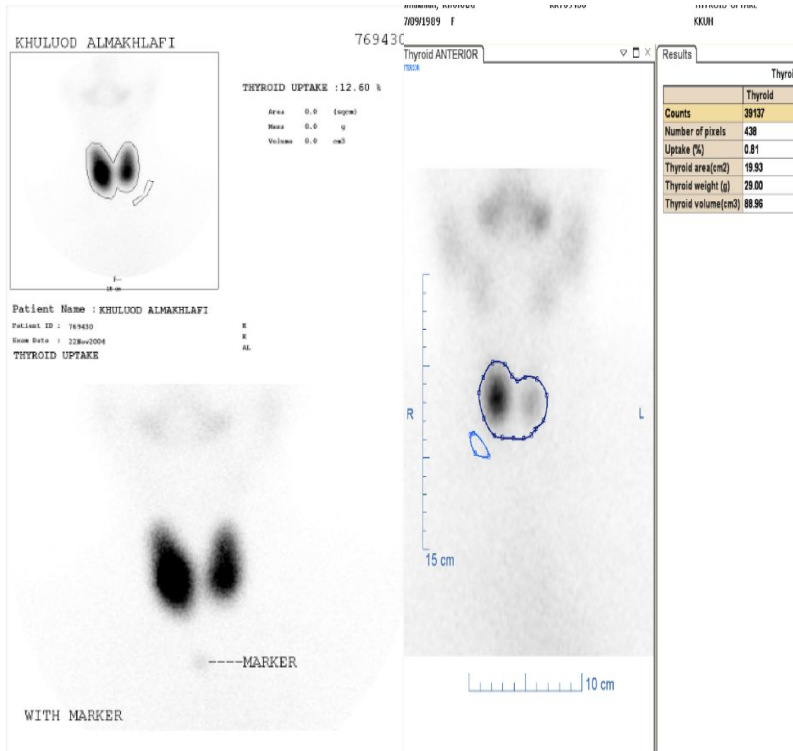
Thyroglobulin.

- What is the marker for Medullary carcinoma?

Calcitonin.

## Case 16

26 years old female patient presented with thyrotoxicosis symptoms.

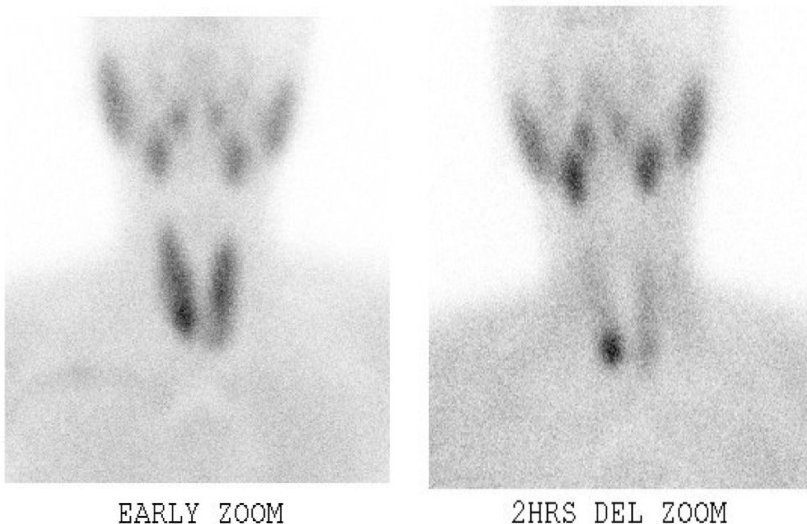


- **What is the study?**  
Nuclear scan of the thyroid.
- **What is the agent used?**  
Tc-99m Pertechnetate.
- **What are the imaging findings?**  
Diffuse enlargement with Increased uptake 12.6%. In (November 2004 left picture) patient received treatment and had a good response. In (April 2005 right picture) another image taken found to have a decrease in uptake with 0.81%.
- **What is the most likely diagnosis?**  
Graves (November). treated with iodine-131, 5-15 mg.
- **what is the main side effect of iodine 131?**  
Hypothyroidism (April).

Iodine 131 is used to treat thyroid disorders including thyroid cancer and hyperthyroidism

## Case 17

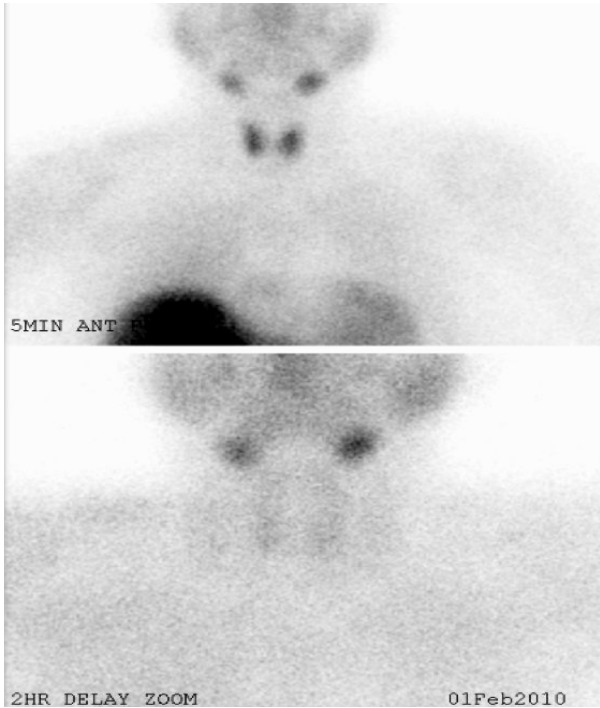
A patient with High PTH and High Ca.



- **What is the study?**  
Parathyroid scan.
- **What is the agent used?**  
Tc-99m Sestamibi (Dual Phase).
- **What are the imaging findings?**  
Right lower parathyroid nodule.
- **What is the most likely diagnosis?**  
Parathyroid adenoma.

## Case 18

A patient with High PTH and High Ca.



- **What is the study?**

Parathyroid scan. ask for MRI if you can not tell.

- **What is the agent used?**

Tc-99m Sestamibi (Dual Phase), which usually concentrates in cells with mitochondria.

- **What are the imaging findings?**

False negative because it is from the clear cells which has no mitochondria.

- **What is the most likely diagnosis?**

Parathyroid adenoma.

- **Remember:**

Sestamibi is taken up by mitochondria in parathyroid.

Parathyroid has two types of cells: Chief cells with no mitochondria and Oxyphil cells (Rich in mitochondria)

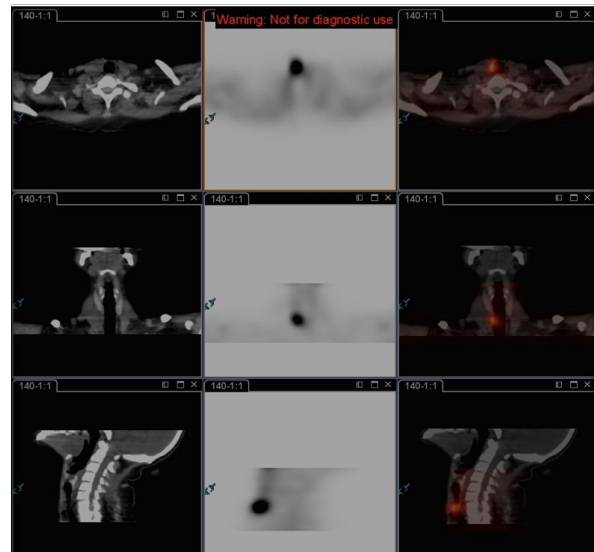
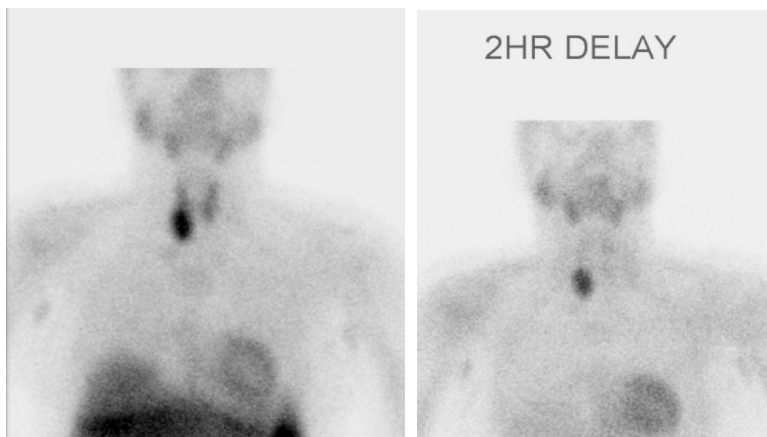
Low mitochondria = Low uptake

- **Next step?**

**18F-choline PET/CT**

## Case 19

A patient with High PTH and High Ca.



- **What is the study?**

Parathyroid scan & SPECT CT.

- **What is the agent used?**

Tc-99m Sestamibi (Dual Phase).

- **What are the imaging findings?**

Adenoma anterolateral to the trachea approved by SPECT CT. (Adenoma close to the the skin. Superficial on sagittal view).

- **What is the most likely diagnosis?**

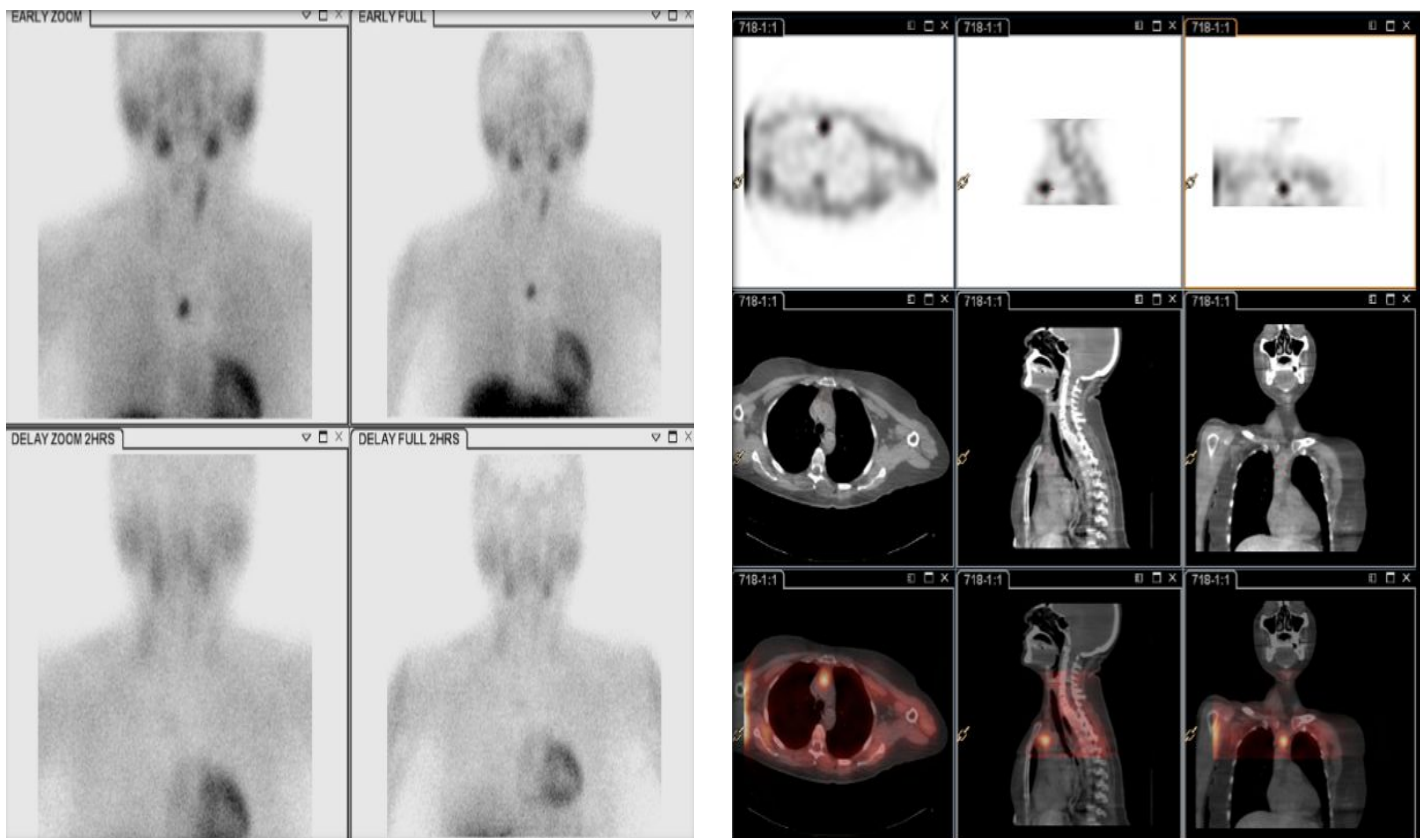
Ectopic Parathyroid adenoma.

To help the surgeon we order SPECT CT to localize tumor.



## Case 20

30 year old male patient with suspected hyperparathyroidism.



- **What is the study?**

Parathyroid scan and SPECT CT.

- **What is the agent used?**

Tc-99m Sestamibi (Dual Phase), (SPECT CT).

- **What are the imaging findings?**

Ectopic retrosternal nodule (PT adenoma).

- **What is the plan of treatment?**

Both Thoracic and endocrine surgeons need to be involved in this surgery.

In patients with **hyperparathyroidism**, parathyroid scan is used to detect and localize ectopic and ectopic parathyroid adenoma.

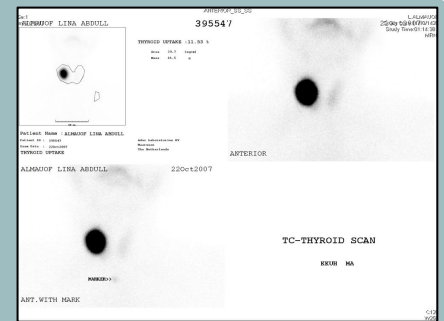
1-what is the main side effect of iodine 131?

- a. Hyperthyroidism
- b. Itching skin
- c. Hypothyroidism
- d. Nausea and vomiting

2-25 year old female presented with thyrotoxic symptoms 2 weeks after delivery. Lab: Elevated T4 and suppressed TSH.

Most likely diagnosis?

- A) Single toxic nodule
- B) Dyshormonogenesis
- C) Sublingual thyroid (ectopic thyroid).

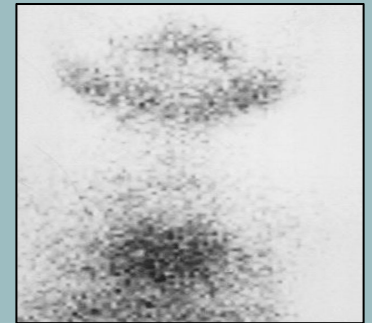


3-Young patient presented with hypothyroidism symptoms.

Lab showed elevated TSH and low T4.

Most likely diagnosis?

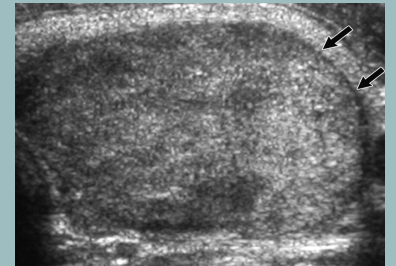
- A) Single toxic nodule
- B) Agenesis of the gland
- C) Sublingual thyroid (ectopic thyroid).



4-30 year old woman presented with a neck mass.

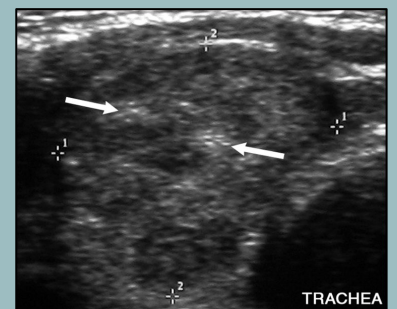
Most likely diagnosis?

- A) Single toxic nodule
- B) Agenesis of the gland
- C) Sublingual thyroid (ectopic thyroid).
- D) Follicular adenoma,



5-42 year old man presented with Right Thyroid mass?

- A) Single toxic nodule
- B) Thyroid carcinoma
- C) Sublingual thyroid (ectopic thyroid).
- D) Follicular adenoma,



Answers  
1) C  
2) A  
3) B  
4) D  
5) B