



Radiology
Team 438


Radiology of GI system diseases

Lecture 11

Objectives

- ❖ To know the common GIT pathologies presentation.
- ❖ To understand step wise approach in requesting GIT radiology investigations.
- ❖ To know common radiologic pathologies in GIT.

Reviewed By



Noura Alturki
Jehad Alorainy

Color Index:

♦ Important

♦ Doctor's Notes

♦ Extra

♦ Female slides

♦ male slides

Team Leaders



Omar Aldosari



Leena Alnassar



Shahd Alsalamh

Done by:

Roaa Aljohani

Rahaf Alshuaniber

Notes:

Taif Alotaibi

» Esophagus

» Clinical Signs and symptoms

- ❖ Dysphagia, Odynophagia (pain oropharynx).
- ❖ Chest pain (Regurgitations or obstruction, it is complicated sometimes with esophagitis or esophageal ulcer),
- ❖ Vomiting.
- ❖ Age is also important (some diseases are common in specific age, a young patient will most likely have achalasia, but old one most likely have cancer).
- ❖ Constitutional symptoms (Fever, Night Sweat, Weight Loss).
- ❖ Recurrent chest infection (TOF). Some patients present with tracheoesophageal fistula and they are susceptible to recurrent infections, also during reflux some food regurgitate into the pulmonary system (particularly pediatric age group)

» Imaging Modalities

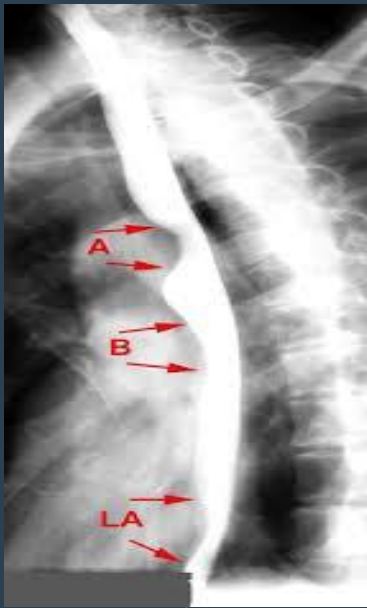- X-ray. Helps in esophageal perforation secondary to trauma or foreign body. Also in cases of distal esophageal obstruction e.g. achalasia, or esophageal tumor in lower esophagus, the esophagus proximally become dilated, showing air-fluid level or fluid-fluid level → significant widening of the mediastinum.
 - **Fluoroscopy (contrast-dynamic study - barium swallow) "1st choice"** (Barium swallow = shows us the lumen and mucosal lining) we do not use it if we suspect perforation.
 - Ultrasound (rarely used), we use the endoscopic US. Helps to see the extent of the disease (locally staging of the tumor).
 - CT helps in diagnosis, staging, and metastasis. but it's not the study of choice.
 - MRI helps in characterization of the lesion (limited role).
 - Nuclear Medicine > Of limited use.
 - Angiography > of limited use.
- *The most important thing in this lecture is to differentiate benign from malignant conditions.



wow, such empty

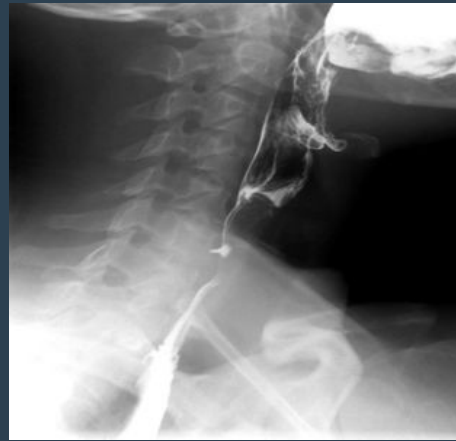Normal study

Normal Study-Double contrast

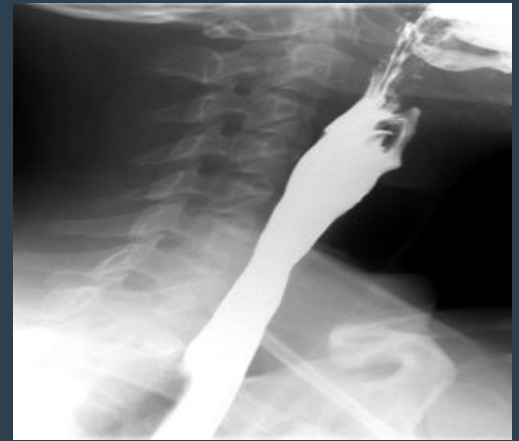

extra picture

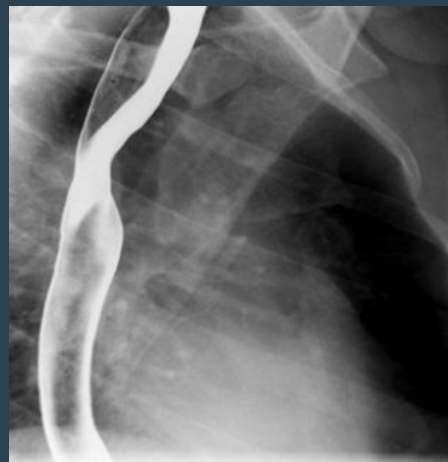
- Aortic arch
- Left main bronchus
- Left atrium



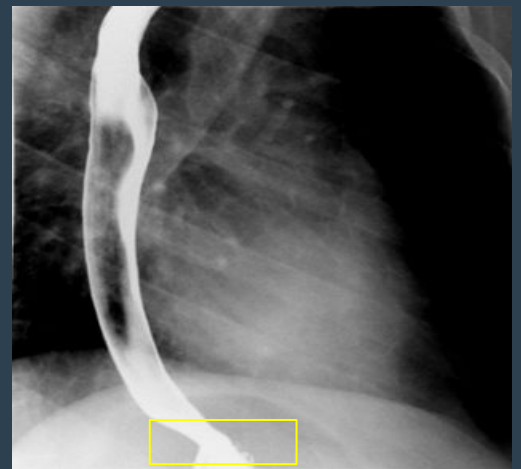
Double contrast (helps in mucosal details)
- upper esophagus



single contrast (helps in gross pathology and anatomy)
- upper esophagus



Mid esophagus



Lower esophagus

- Yellow: gastroesophageal junction

Dysphagia, Esophageal stricture (Barium swallow)

Benign stricture

- corrosive esophageal stricture
- peptic esophagitis stricture
- Achalasia

malignant stricture

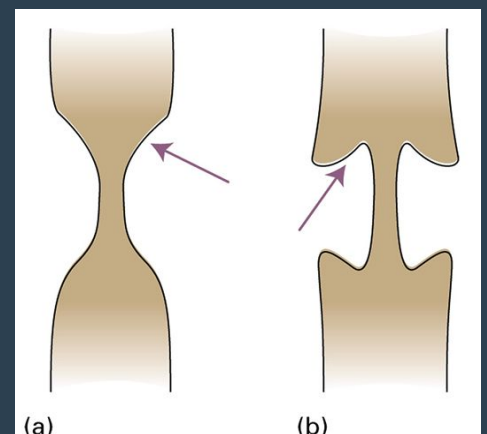
- esophageal carcinoma stricture

Esophageal Stricture

a) Tapering ends **with smooth outlines** → benign

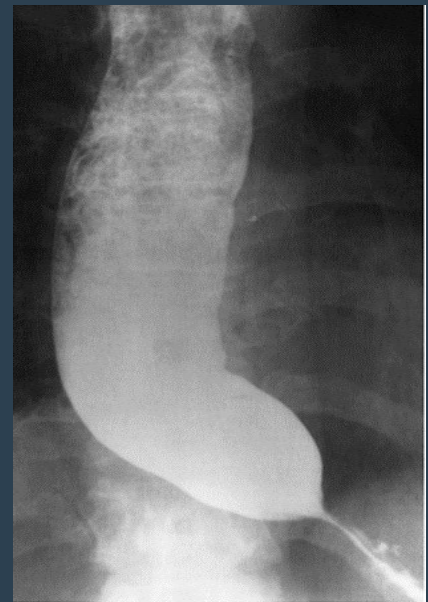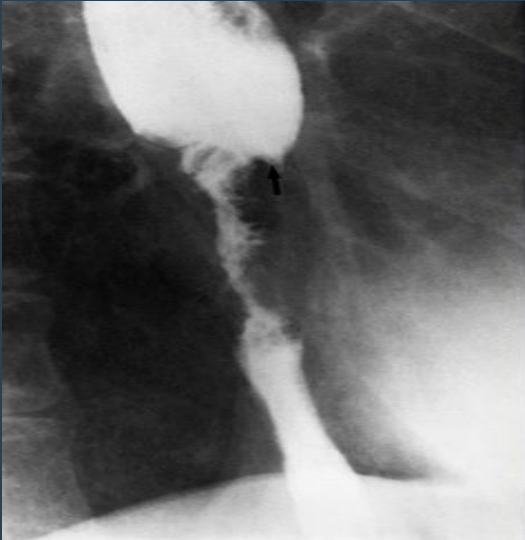
b) Overhanging edges or **shouldering with irregular outlines** → malignant

- (shouldering indicates overgrowth of the wall "mass" so we can not see the wall clearly on barium swallow).
- Short segment of strictures with luminal narrowing. Irregular outline. Deep ulceration. Shouldering proximally. All of these manifestations are of malignant strictures



» Dysphagia, Esophageal stricture

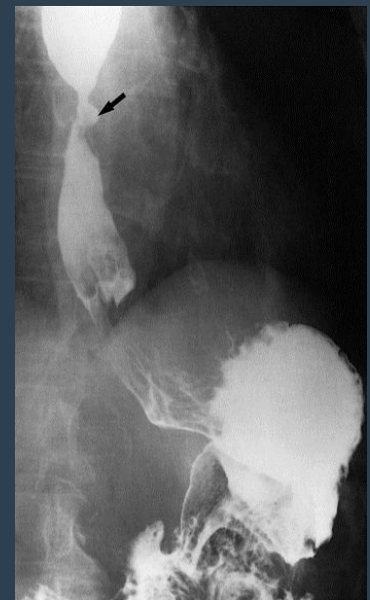
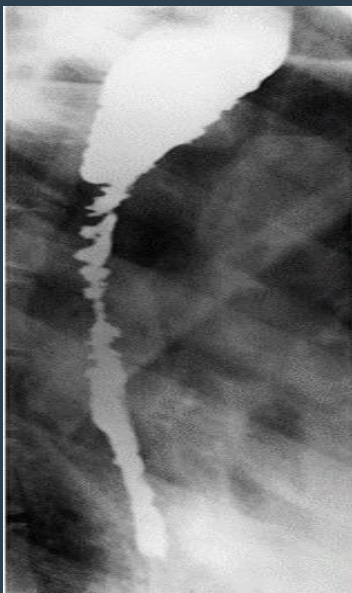
Barium swallow



Esophageal Carcinoma

Short segment of strictures with luminal narrowing. Irregular outline. Deep ulceration. Shouldering proximally. All of these manifestations are of malignant strictures. there is always dilatation before any stricture.

Achalasia Most of esophagus is dilated with food residuals and smooth narrowing at the lower end. Rat tail and bird beak sign with no shouldering > benign. Significant esophageal dilation proximally, some food particles and barium is pooling in the lower esophagus. Beak bird appearance of the distal esophagus with smooth tapering.



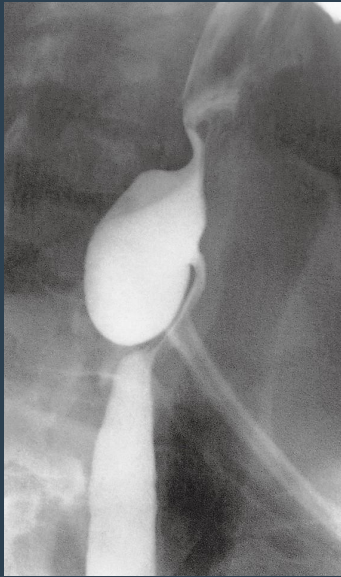Corrosive Stricture

Irregular narrowing in the whole esophagus with dilated inflow. **no shouldering** > benign *Corrosive are chemicals like acids or bases. (long segment of esophageal stricture and narrowing with lobulated outline involving the mid and lower esophagus)

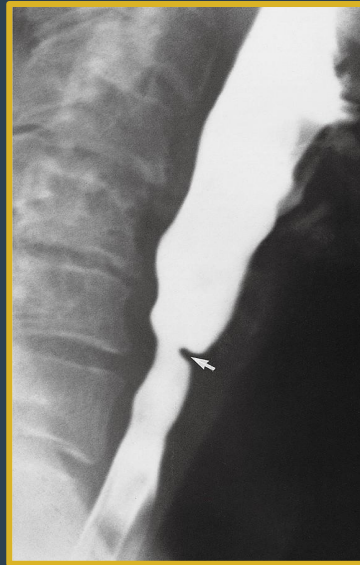Peptic stricture due to GERD in a patient with hiatus hernia. There is smooth narrowing of the mid esophagus we see it in gastroesophageal junction with an ulcer within the stricture (arrow). Short segment of stricture and narrowing with ulcer (arrow) and smooth outline

»» Dysphagia, Esophageal web/Diverticulum

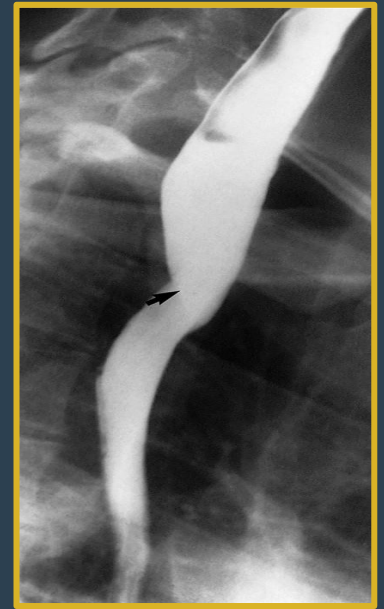Barium swallow



Esophageal diverticulum (mucosa bulging outside and filled with contrast), no dilation proximally and normal esophagus



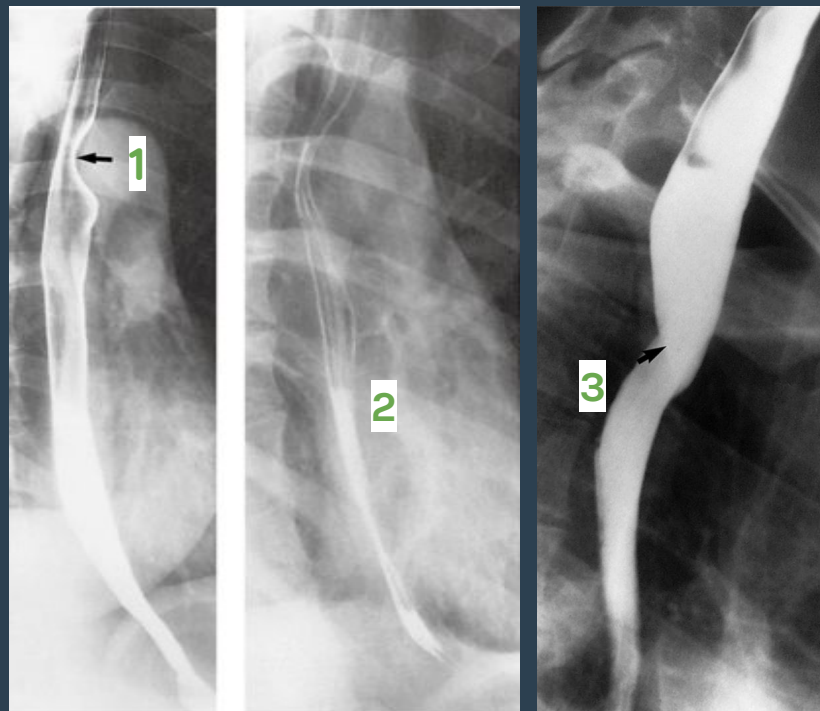
Esophageal web. Shelf-like indentation (arrow) from the anterior wall of esophagus, **no shouldering**



External posterior compression causes narrowing of esophagus due to apparent subclavian artery¹ as it passes behind the esophagus (arrow) anomalous right subclavian artery.

»» Esophageal impressions (normal)

Physiological impressions (indentation):
1- related to aortic arch
2- related to atrial enlargement
3- left main bronchus¹



¹In the reference as well as the golden notes this was said to be a pathology caused by the subclavian artery, but the doctor mentioned it as a normal physiological narrowing caused by the left main bronchus

» Stomach

» Clinical signs and symptoms

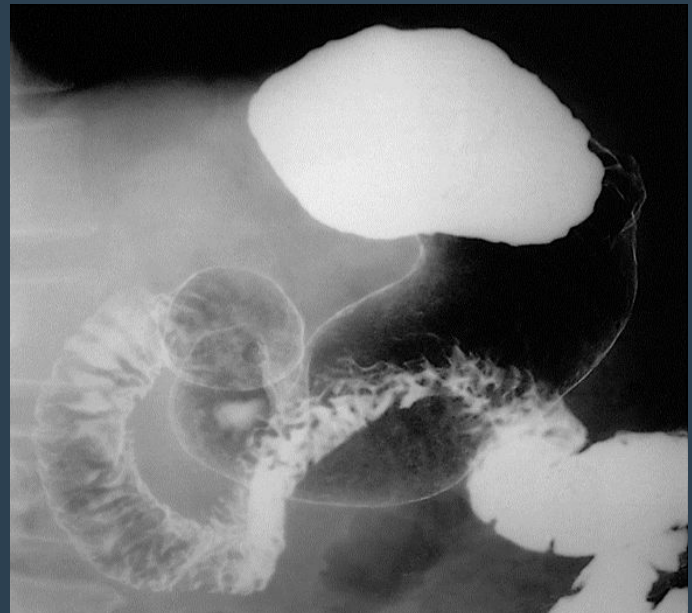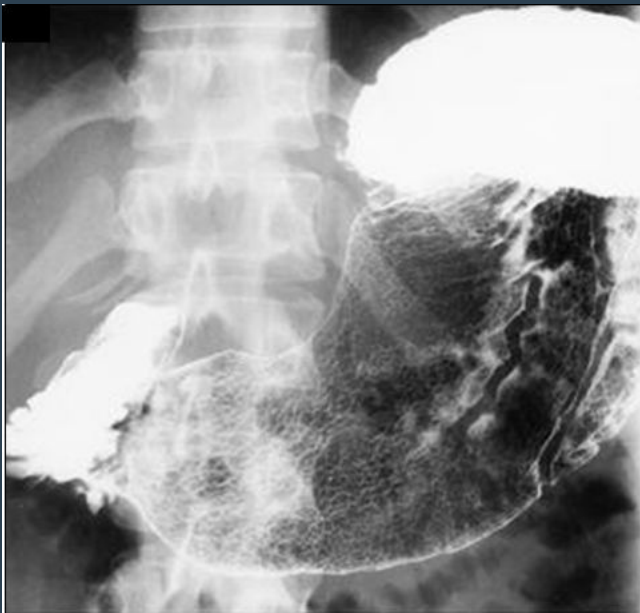- ❖ Epigastric pain.
- ❖ Vomiting.
- ❖ Hematemesis.
- ❖ Age is also important (some diseases are common in specific age).
- ❖ Constitutional symptoms (Fever, Night Sweat, Weight Loss).

» Imaging Modalities

- X-ray. (initial), we can see stomach filled with gas
- Fluoroscopy, contrast study (Barium meal). (used to visualize stomach mucosa).
- Ultrasound > in pediatric for pyloric stenosis.
- CT. (For staging and characterization of the disease)
- MRI.
- Nuclear Medicine not used.
- Angiography not used

» Barium meal

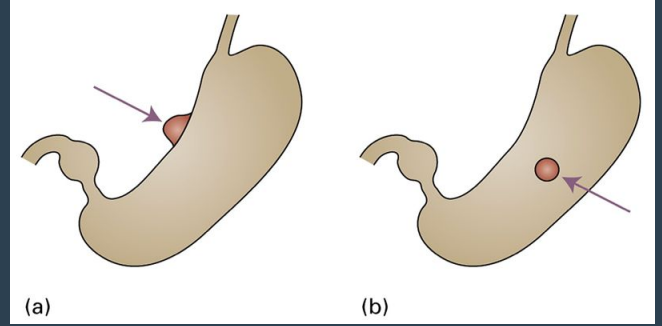
» Normal



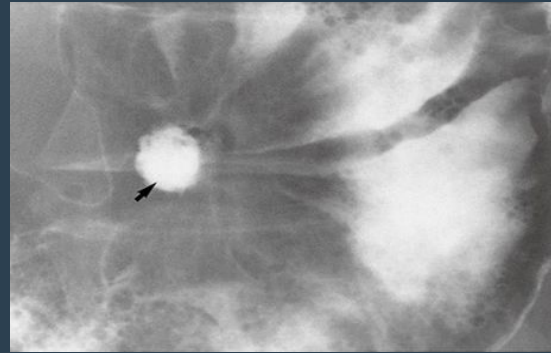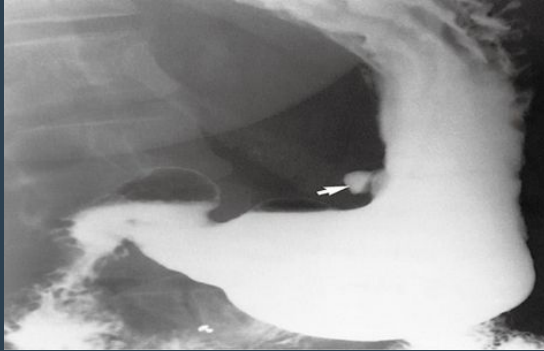
Normal Stomach and Duodenum on double contrast barium meal. On this supine view, barium collects in the fundus of the stomach. The body and the antrum of the stomach together with the duodenal cap and loop are coated with barium and distended with gas. Note how the fourth part of the duodenum and duodenojejunal flexure are superimposed on the body of the stomach.

» peptic ulcer disease (Epigastric pain)

- a) In profile the ulcer is seen as an outward projection
- b) En face (facing forward, **out profile**) the ulcer appears rounded.



Barium meal:



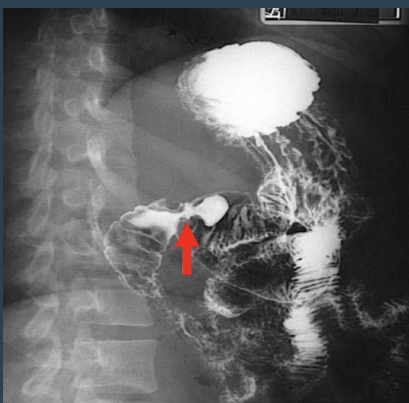Benign ulcer due to its regular lining

White arrow: In profile ulcer, outpouching filled with contrast in the lesser curve of the stomach (arrow).

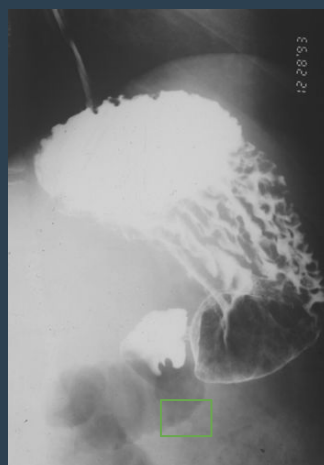
Black arrow: En face of an ulcer (arrow) is seen as rounded collection of barium, **زي الحفر** and edematous mucosa adjacent to it and directed towards the ulcer **تدخل فيها الصبغة**.

» Duodenal ulcer involving the duodenal cap

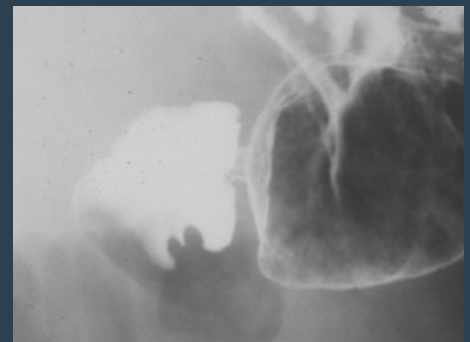
Barium meal



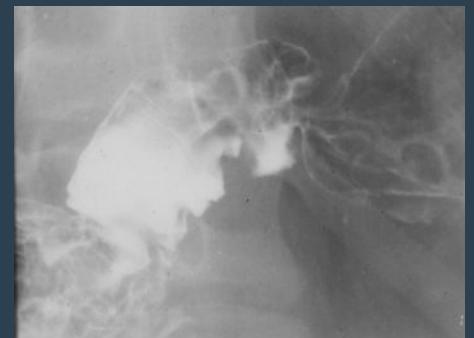Narrowing, area of contrast pool, mucosal edema (distal gastric antral ulceration)
No proximal obstruction



A filling defect within the inferior aspect of the duodenal wall



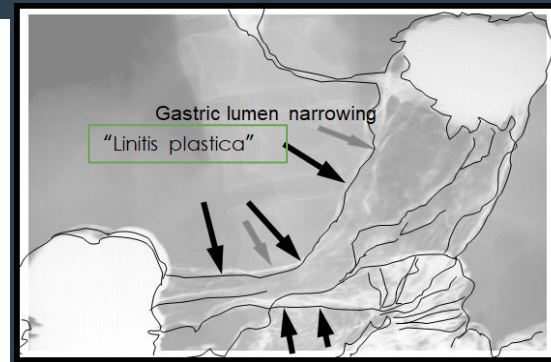
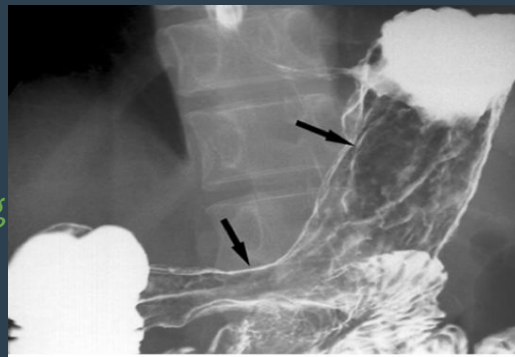
Single contrast study - filling defect



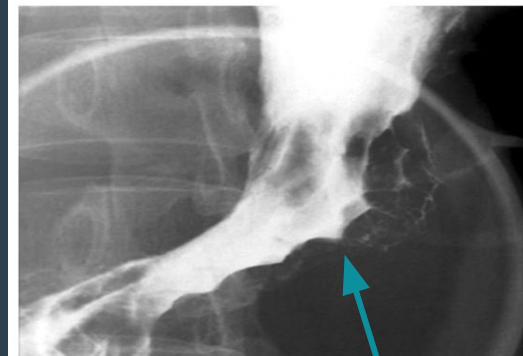
Double contrast study (thickened edematous mucosal fold directed toward the ulceration)

» (Epigastric pain) Gastric carcinoma Barium meal

Thickened mucosal fold, narrowing of gastric lumen with lobulation in the outline (seen in diffuse infiltrative process involving the gastric wall e.g. infiltration by malignancy)

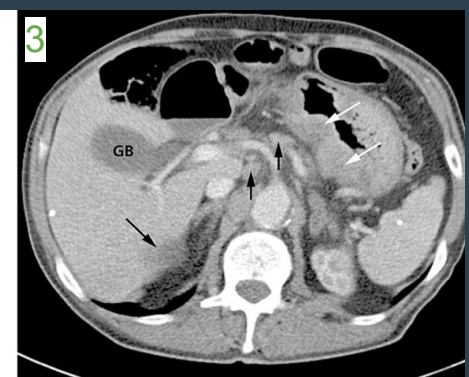
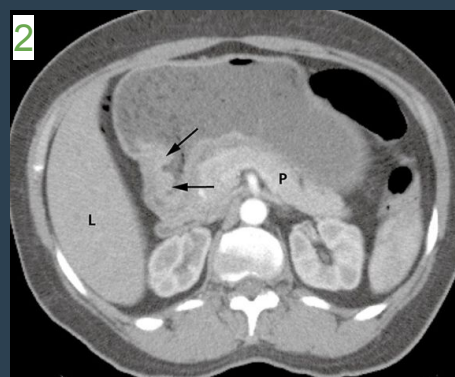
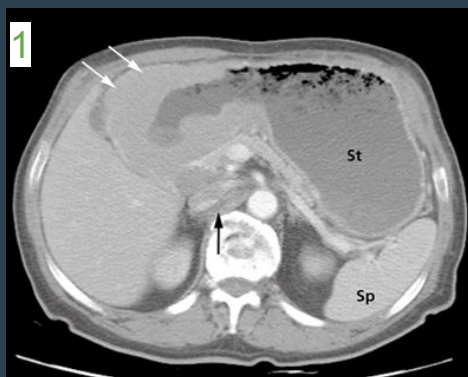

Linitis plastica related to the diffuse gastric luminal narrowing



Gastric Carcinoma on Barium study

Black areas (black clouds) are large **filling defects** in the antrum and body of stomach which indicates mucosal abnormality (**infiltration**). The difference between gastric masses and ulcer is that the ulcer will accumulate the contrast in ulcer site which will appear as dense but in case of mass, **the mass will clear the contrast and will appear black**.



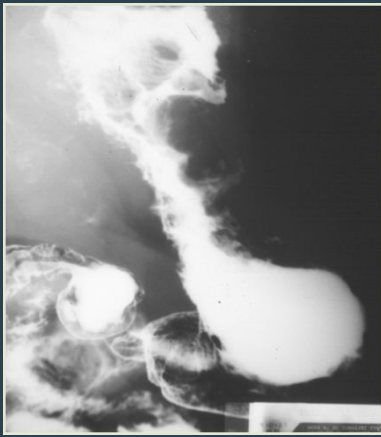Gastric Carcinoma on CT

1- In the first picture (white arrows) indicate wall thickening, and it's what appeared in the barium study as filling defects. **Mass in the gastric antrum**

2- Black arrows on the **second picture** indicate a mass arising near the pyloric canal

3- In the **third picture**, there is **diffuse thickening of the wall of the stomach** (white arrows), several lymph nodes (short black arrows in the middle) and a liver metastasis (long black arrow) are also seen. These thickened walls could be: **1.Primary Gastric Cancer 2.Infiltration 3.Metastasis 4.Lymphoma**. (it is Gastric Carcinoma here) thickened walls and narrowed lumen with different axial levels.

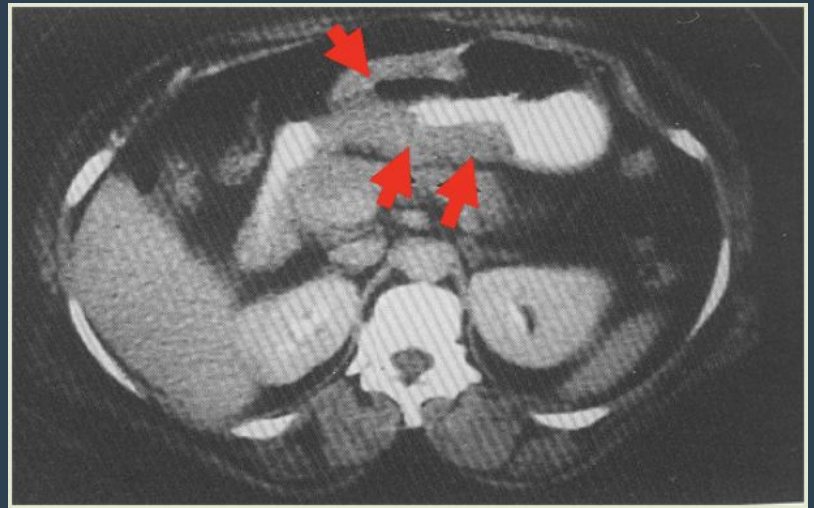
» Gastric lymphoma



Barium meal

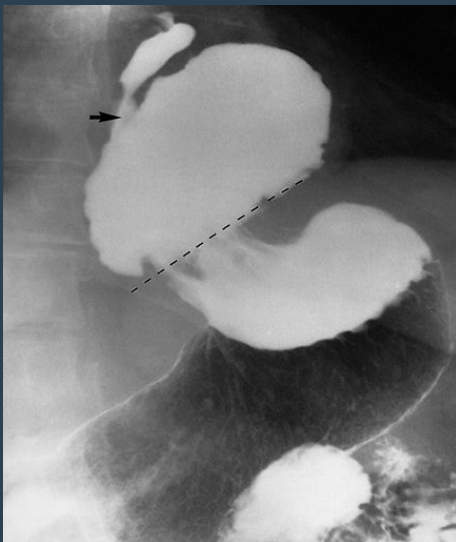Shouldering of the stomach

Diffuse luminal narrowing of stomach, with irregular outline, without significant obstruction proximally



Thickening of the gastric wall
Diffuse thickening involving the gastric antrum without proximal obstruction

» Sliding hiatal hernia

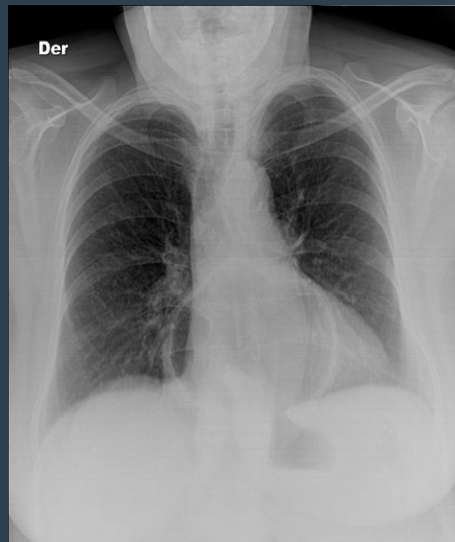

Barium meal

Two types of hernia:

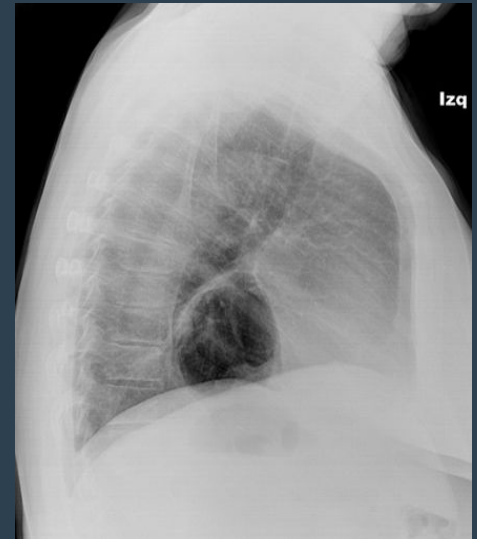1- sliding hiatus hernia: the gastroesophageal junction is above the level of the diaphragmatic crus

2- paraesophageal hernia: gastroesophageal junction is below



Gas filled cavity projecting over the cardiac shadow

What is the next step after x-ray? Barium meal and swallow



» Small bowel

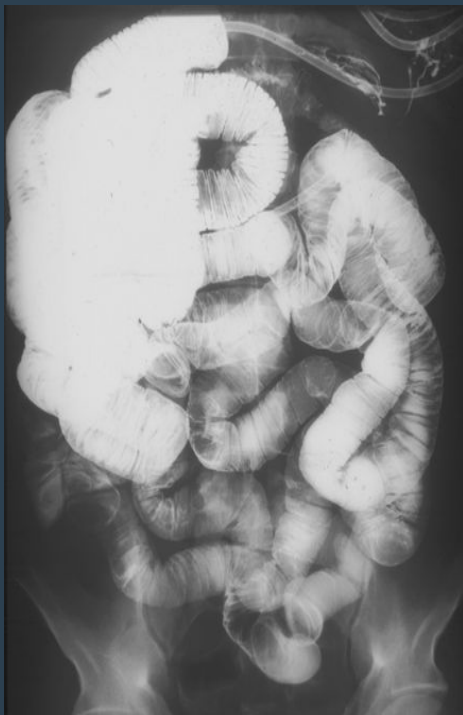» Clinical signs and symptoms

- Malabsorption.
- Vomiting.
- Diarrhea.
- Age is also important (some diseases related to specific age).
- Constitutional symptoms (Fever, sweating and weight loss).

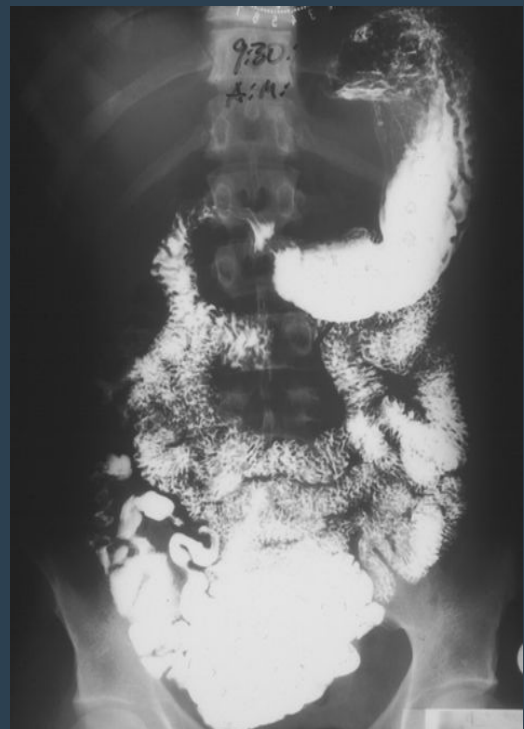
» Imaging modalities

- **X-ray** (Bowel obstruction and perforation) best initially.
- **Fluoroscopy** (Barium follow through/Small bowel enema).
- **Ultrasound** (we don't use it because small bowel is filled with gas and US can't read gas).
- **CT** replacing the fluoroscopy these days.
- **MRI** replacing the Fluoroscopy and CT.
- **Nuclear medicine** > not used.
- **Angiography** > not used.

» Normal



small bowel enema

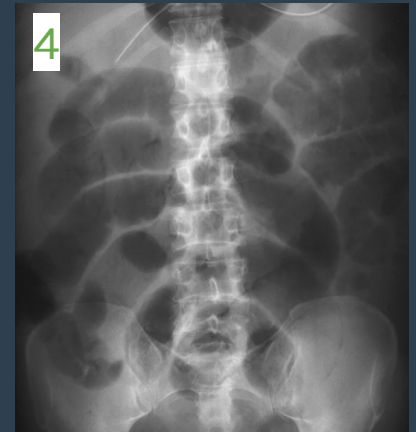


barium meal- follow through

Small Bowel obstruction

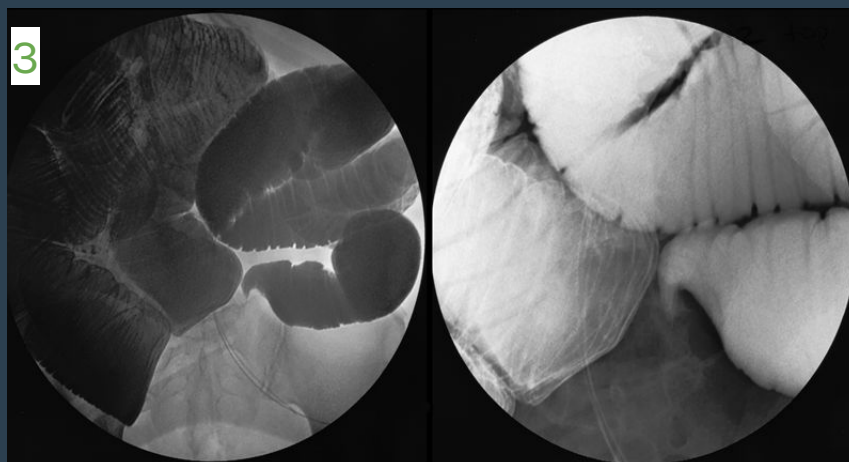
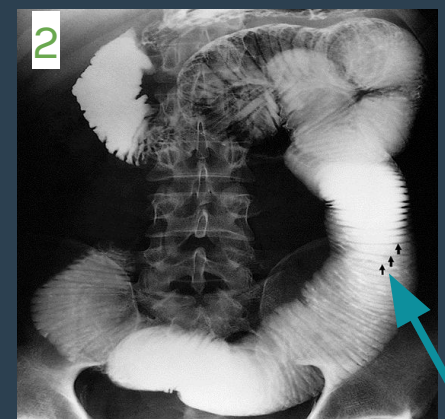
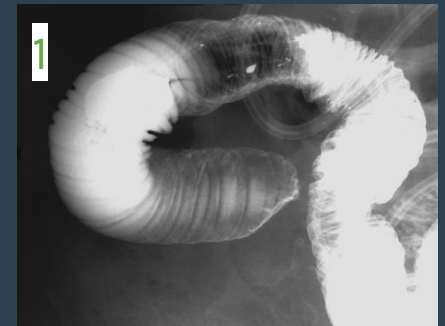Patient presenting with abdominal pain and distension

Picture 4: This is a plain x-ray. We see significantly dilated small bowel loops which centered in the mid-abdomen. Also there is Cutoff sign distally, thickened, mucosal folds, edema and complete cutoff distally and smooth tapering



Small bowel enema :

- Significant dilation of the small bowel obstruction. The diameter of the wall is greatly increased. The feathery mucosal pattern is lost and the folds appear as thin lines traversing the bowel, known as valvulae conniventes (arrows).
- Picture 2: The signs of small bowel obstruction secondary to adhesion :
 - 1- Dilated small bowel loops proximally
 - 2- Thickened mucosa (valvulae conniventes)
 - 3- Cutoff sign distally
- The diameter of the bowel is greatly increased.
 - (Keep in mind that The upper limit of normal diameter of the bowel is generally accepted as 3cm).



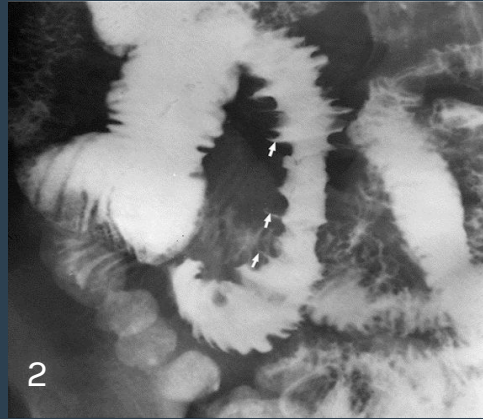
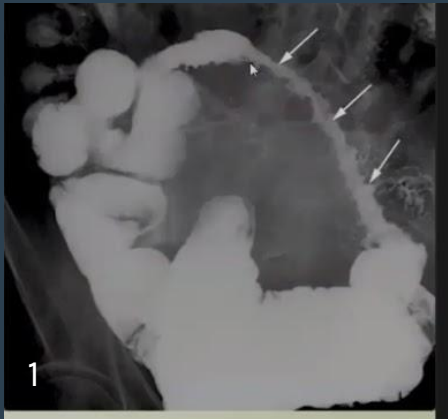
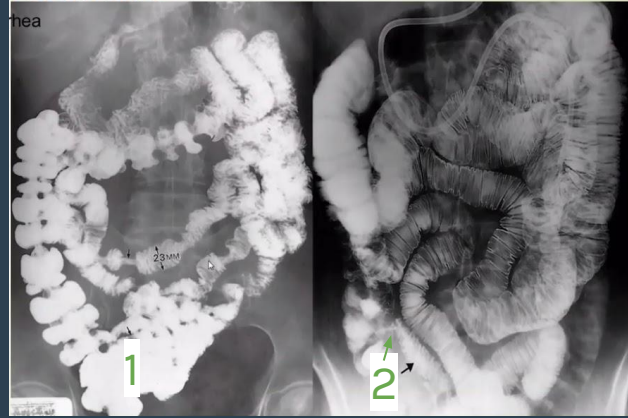
» Crohn's disease

A patient presenting with Abdominal pain & weight loss and diarrhea

1-normal barium swallow

2-ileocecal narrowing on enema

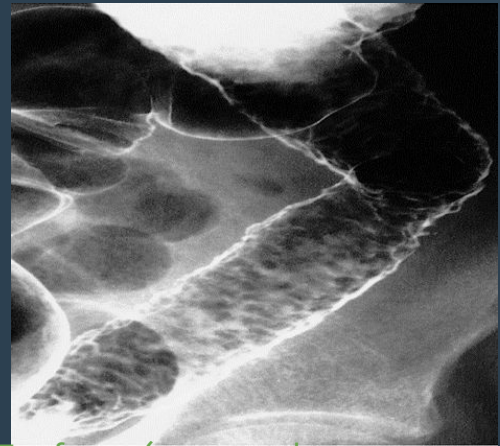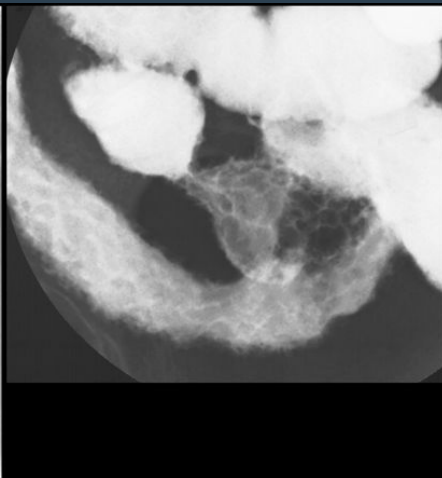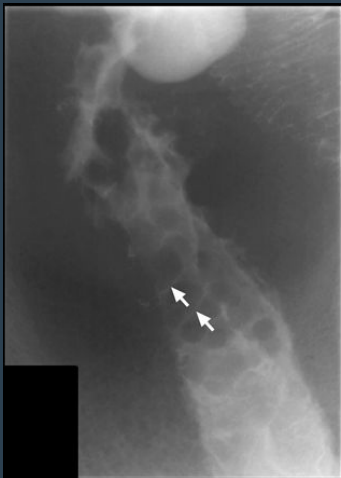small bowel inflammatory process



Picture 1: Small bowel loops separation due to fibrofatty proliferation

picture 2: **Deep Ulceration** abnormal loops of bowel in crohn's disease showing the ulcers as outward projections (arrows). If the erosion extends to submucosa we will see the contrast filling the submucosa (**thorns rose**) Streak of contrast filing the wall both of these changes are seen in the crohn's disease (cobblestone sing & thorns rose)

picture 3: **thickening of the mucosal folds**



Cobblestone appearance due to edema of the mucosa

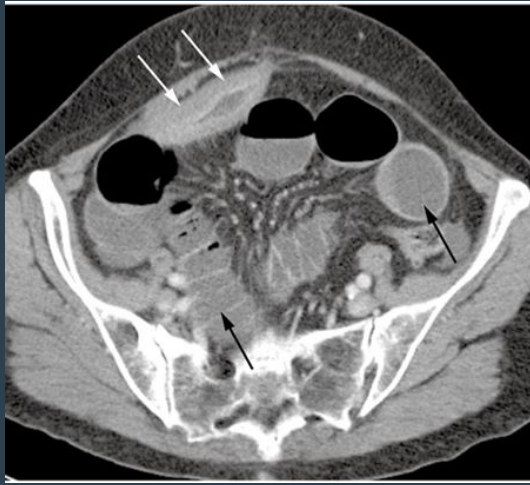
Fibrofatty proliferation with separation of the bowel loops

En-face: (mucosal ulceration the black spots in the picture) small erosions of the mucosal lining (**cobblestone sign**)
سطح القمر المبتقع

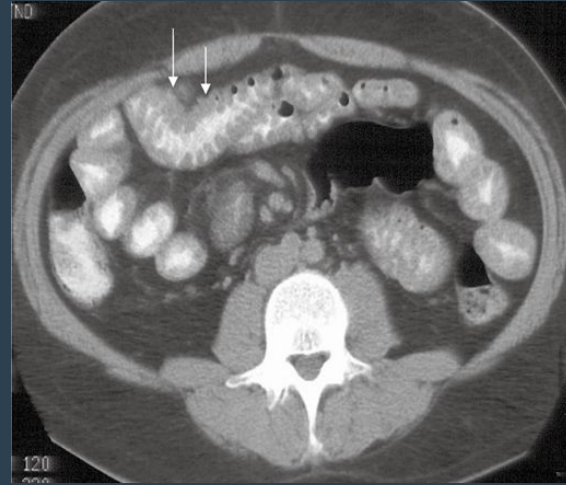
FINDINGS:

1. Lumen narrowing & multiple stenotic segments (skip lesion)
2. Deep Ulceration with mucosal edema in between → Cobblestone Appearance
3. Bowel loop separation (fibrofatty proliferation)

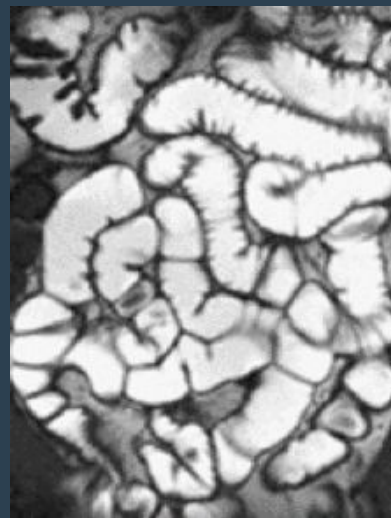
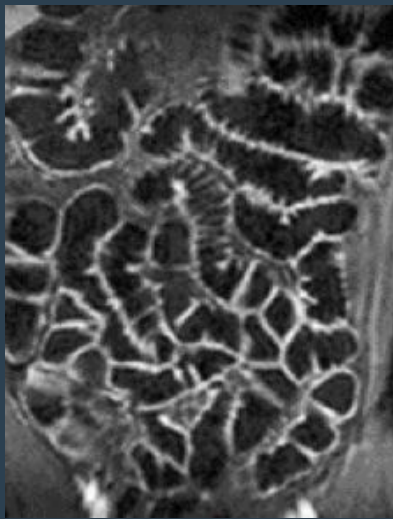
» Crohn's disease



CT in the same patient demonstrating **marked Non-uniform thickening with mucosal enhancement** of the abnormal loop of small bowel, with a narrowed lumen (white **arrows**). As compared to the normal bowel loops (black **arrows**)

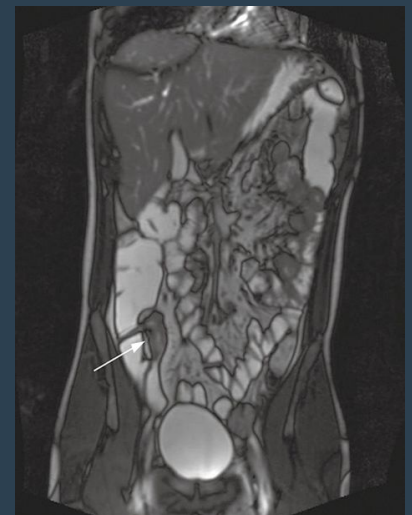
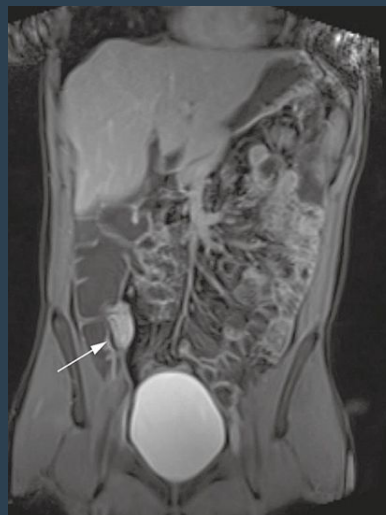
Normal CT scan of the small bowel



MRI enterography - normal

- Mucosal thickening and enhancement involving the terminal ileum (arrows), characteristic of Crohn's disease.
- Narrowing of the lumen and thickening in the wall of ileocecal junction are seen by MRI enterography.



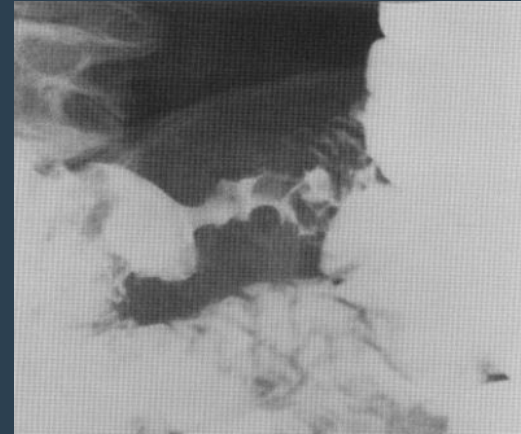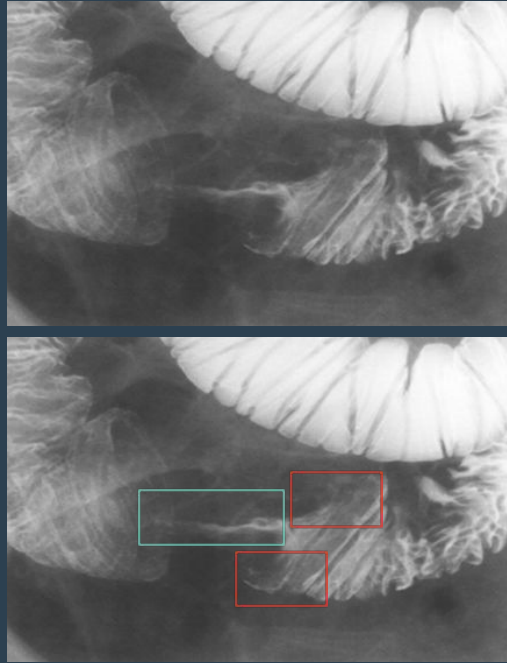
MRI enterography - CD

» Small bowel Carcinoma

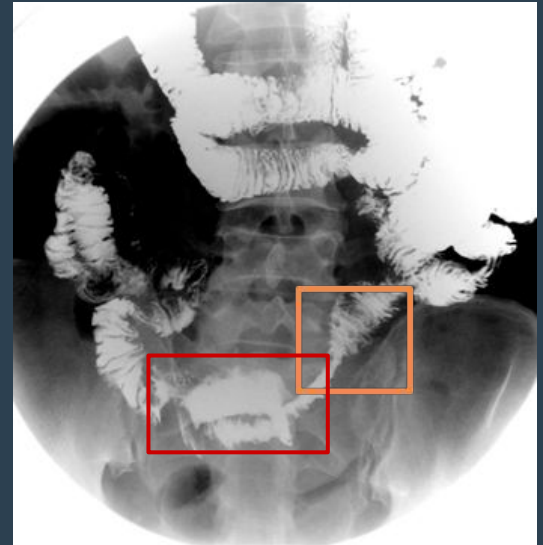
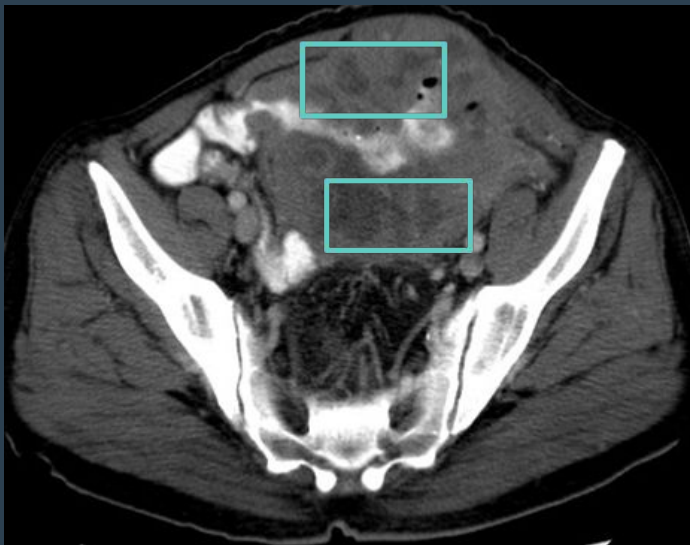same here, add The patient presented with GI bleeding and weight loss
FINDINGS in small bowel enema:

Lumen narrowing irregular with ulceration & shouldering margins.

Focal luminal narrowing, irregular outline, shouldering



» Small bowel lymphoma



FINDINGS:

Lumen narrowing irregular

Mural wall thickening & bowel separation

Aneurysmal dilatation

no bowel obstruction

» Large bowel

» Clinical signs and symptoms

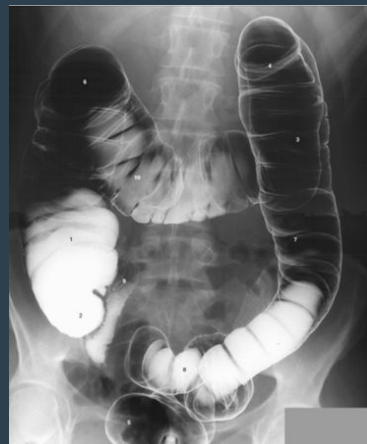- Abdominal Pain.
- Diarrhea.
- Hematochezia.
- Vomiting (not always).
- Anal pain and Discharge.
- Age (some diseases related to specific age).
- Constitutional symptoms (Fever, sweating and weight loss).

» Imaging Modalities

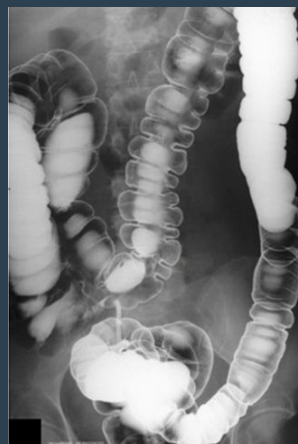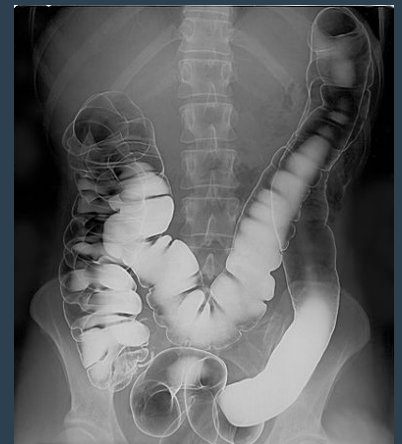
- X-ray. > for obstruction
- Fluoroscopy - Barium enema (Contrast study)
- Ultrasound
(we don't use it because large bowel is filled with gas but we can use it to detect colonic mass).
- CT.
- MRI.
- Nuclear medicine > not used.
- Angiography > not used.

» Normal large bowel

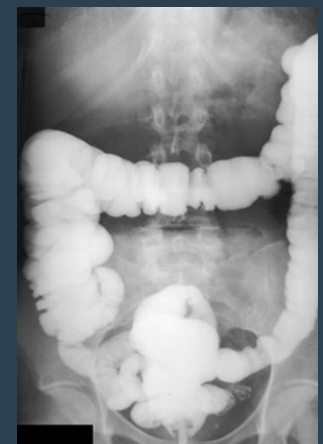
Normal appearance of double contrast in the colon and it has normal mucosal lining and Haustration. Normally, haustration must be seen clearly in ascending and transverse colon.



enema study



double contrast

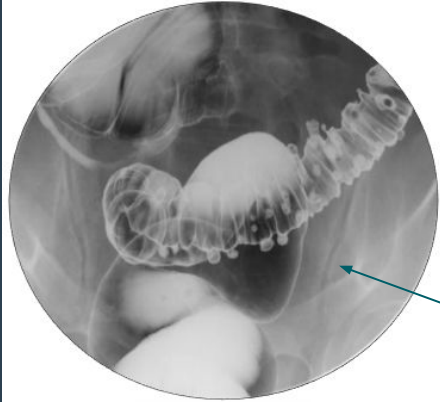


single contrast

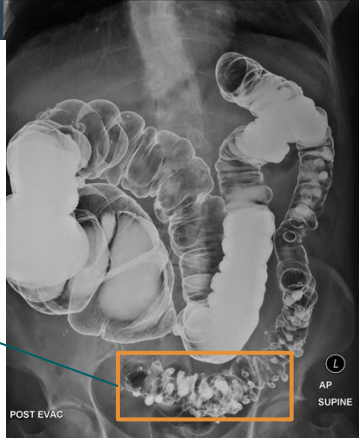
Colonic diverticulosis

Hx of abdominal pain.

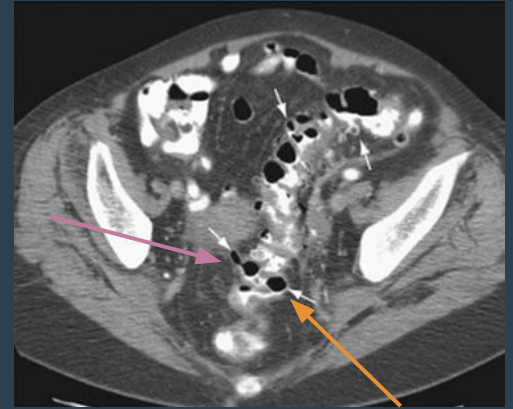
CT shows : Colonic Diverticulitis → inflammation



Barium enema
(magnified view)

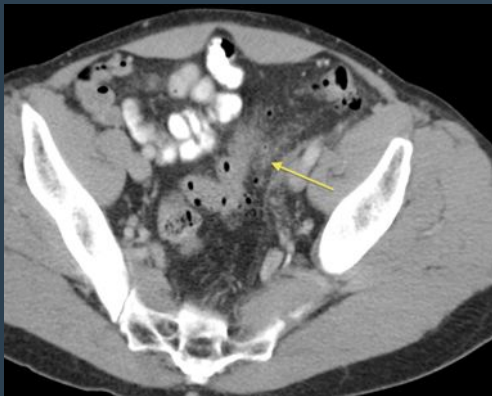

Multiple outpouching
related to the sigmoid
colon, smooth outline

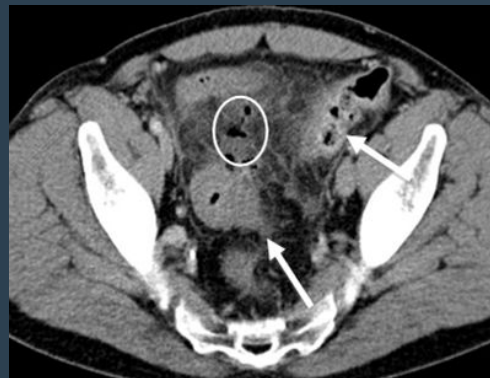

- En face
- In profile

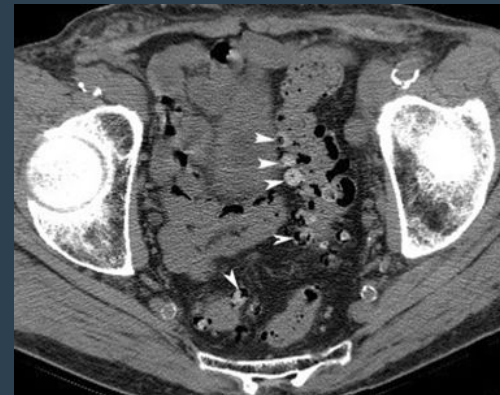Complication:
Acute inflammation, Perforation,
abscess



Inflammatory process adjacent
to the colon diverticulitis (likely a
complication)

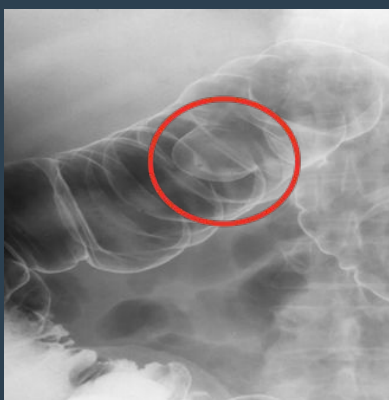


Gas dissecting to the
inflammatory process which
means there is some sort of
perforation



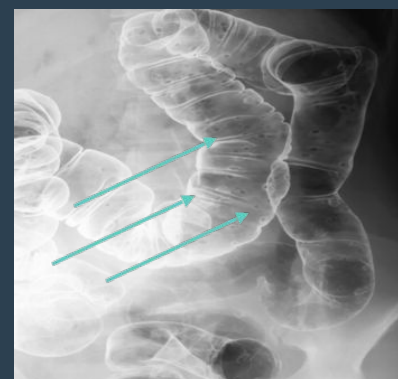
Colonic Polyps

abdominal pain and GI bleeding

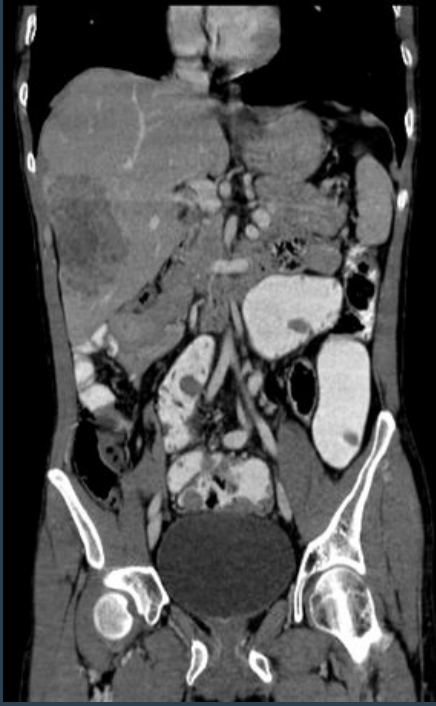

Colonic polyp

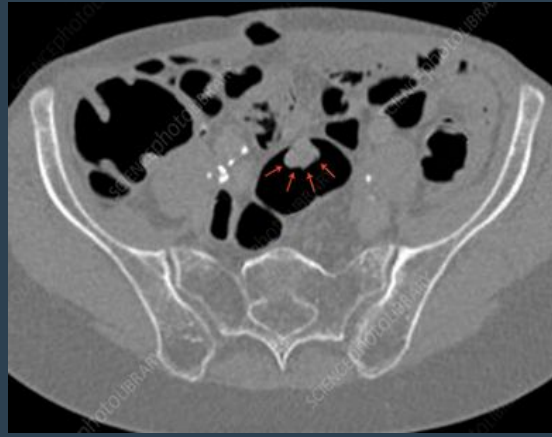
Double contrast
barium enema



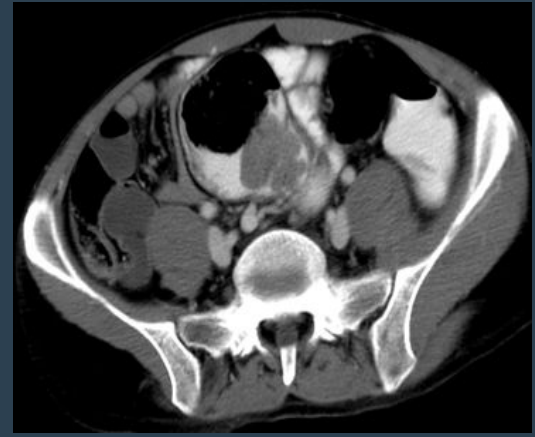
Colonic Polyposis



metastatic deposits within the liver



view the polyp by ct scan

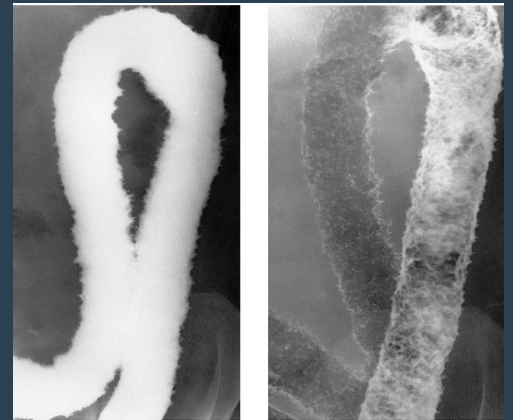

» Ulcerative Colitis

abdominal pain and diarrhea

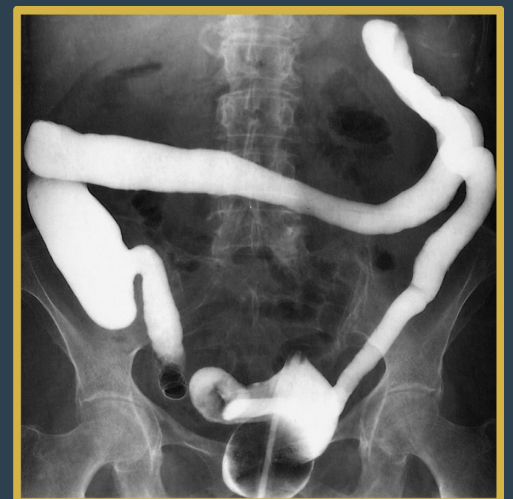single and double contrast enema

colonic Ulceration → inflammation
the ulceration causes the normally smooth outline of the colon to be irregular. NO HAUSTRA which indicates ulceration due to repeated episodes of inflammation. Double contrast study shows multiple mucosal black dots represents mucosal ulceration causes the normally smooth outline of the colon to be irregular.



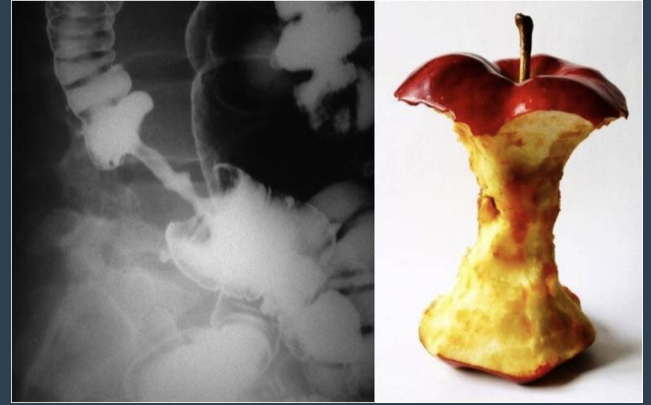Ulcerative colitis with longstanding disease. We can see clearly the **lead pipe** appearance, and reflux into the ileum through an incompetent ileocecal valve has occurred.

We know the incompetence of the valve by the backflow of the contrast from the colon into the ileum + NO HAUSTRA.

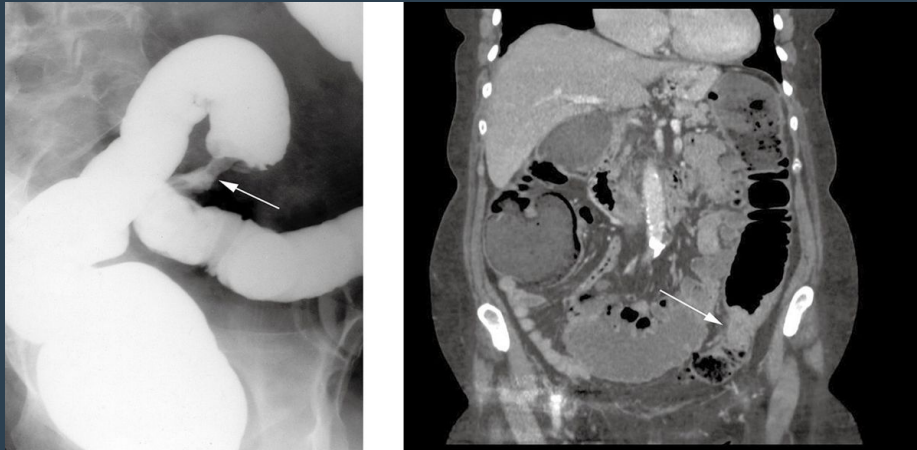

» Colon cancer (Apple core sign)

abdominal pain and lower GI bleeding
colonic Stricture → colonic cancer.
Short segment with focal narrowing and
shouldering effect which gives us Apple-core
appearance

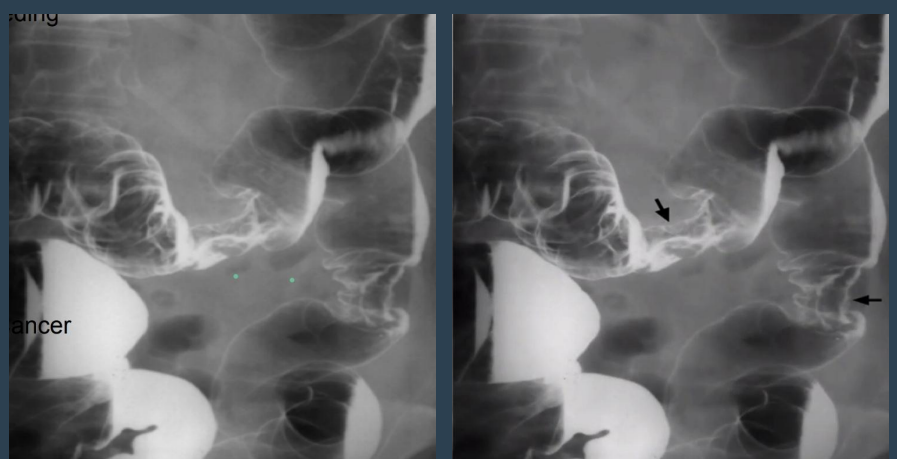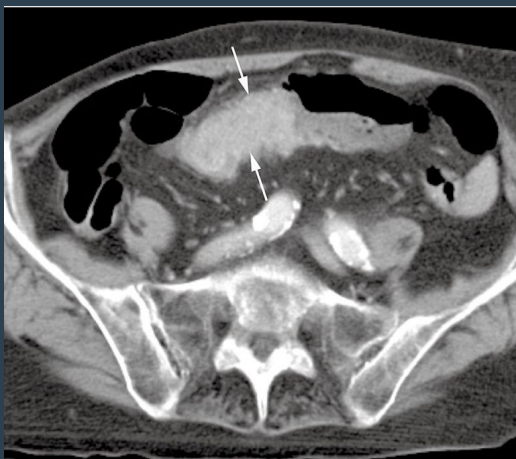


double contrast enema



Barium Enema and coronal CT showing a short, circumferential narrowing in the sigmoid colon (arrows) from carcinoma.

- Barium enema (left image) shows narrowing of the lumen due to presence of soft tissue mass “Apple core sign” = (narrowing + shouldering).
- We can't see the mass in the FLUOROSCOPY (only narrowing) BUT we can see it in the CT.



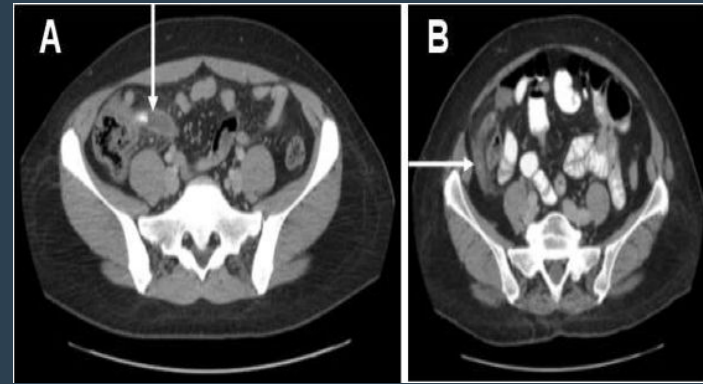
Multiple lesions

Colon carcinoma standard axial CT acquired on thin sections showing a tumor in the transverse colon. (thickened wall, tumor plugging into the lumen)

» Acute Appendicitis

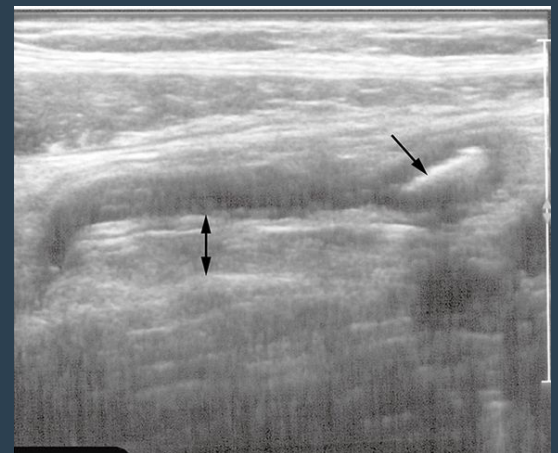Right iliac fossa (RIF) pain - Acute Abdomen

- Blind ended tube in right iliac fossa. could present with white spot.
- Enlarged appendix measures **more than 6mm**.
- **Appendicolith** the white spot in the appendix (white arrow in image A), The white arrow points at the appendix.
- The complications of acute appendicitis: **perforation, abscess formation and mass formation.** tient has appendicitis!!!

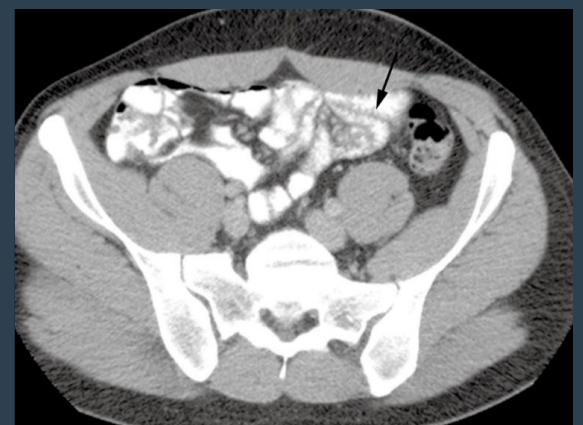


Appendicitis

- In US there is thickening of the wall (double headed arrow) and we can see appendicolith in the tip of the appendix (single headed arrow).
- CT has higher sensitivity than US is assesing appendix but in situations like (pregnant lady or neonate) we can use US with 60% sensitivity.

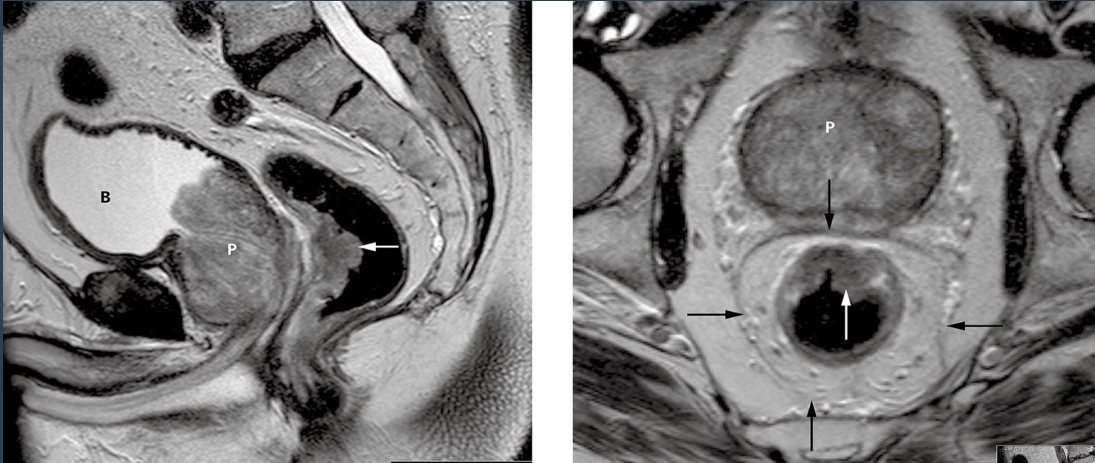


What is the Diagnosis? **Appendicitis.**
What is the best modality to diagnose ?
CT Scan (If it is a pregnant lady or pediatric patient then we do ultrasound).



extra pic CT scan showing Normal appendix

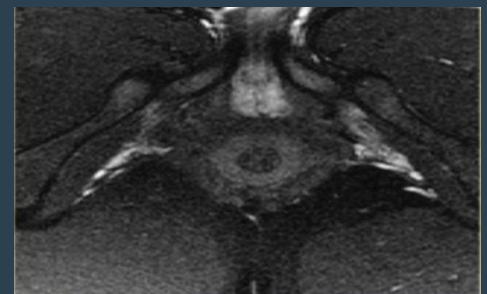
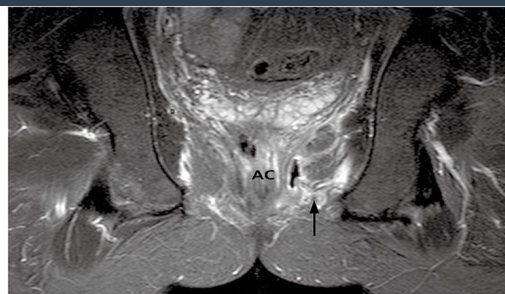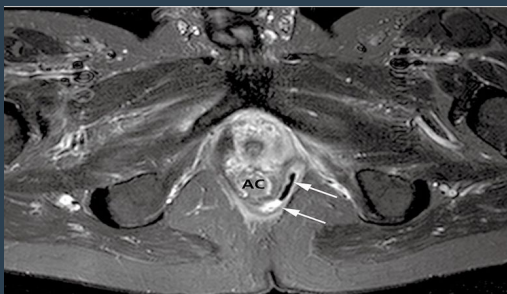
» Rectal Carcinoma



MRI can help stage Rectal Carcinoma

1. Sagittal T2-weighted image demonstrating a **polypoid growth** (arrow) arising from the anterior wall of the rectum. Note the benign hyperplasia of the prostate (P) and a slightly trabeculated bladder (B).
 2. Axial image of the same tumor (white arrow). Note the mesorectal fascia (black arrows) encases the mesorectal fat and the rectum.
- Posterior wall of the rectum is normal and in the lumen there is gas.
 - In The anterior wall there is fungating mass (polypoid growth, A fungating lesion is a lesion that fungates, that is, becomes like a fungus in its appearance or growth rate). **And because there is fat between the mass and the prostate, the mass is not invading.** use MRI to search for lymph nodes metastasis

» Perianal Fistula



Perianal fistula in crohn's disease. MRI with contrast is the best in perianal disease

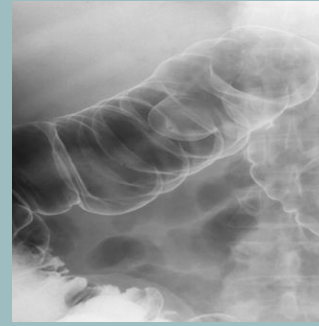
Normal perianal area

Summary

Sign	Indication
Most of esophagus is dilated with food residuals and smooth narrowing at the lower End (bird beak sign)	Achalasia
Mass will clear the contrast and will appear black (filling defects)	Gastric Carcinoma
Cobblestone sign + thorns rose	Crohn's disease
Lead pipe appearance	Ulcerative colitis
<ul style="list-style-type: none">- Enlarged appendix measures more than 6mm.- marked thickening of the wall of appendix	Appendicitis
White spot in the appendix	Appendicolith
Apple core sign	Colon cancer

1- what can you see in the picture?

- a. Ulcerative colitis
- b. Colon cancer
- c. Lymphoma
- d. Colonic polyp



2-which one of the following is complication of acute appendicitis

- a. thickening of the wall
- b. abscess formation
- c. Swelling
- d. Bleeding

3-in gastric carcinoma there is diffuse thickening of the wall of the stomach which can be ...?

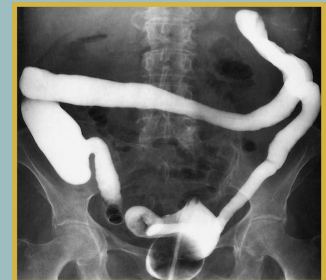- a. Primary Gastric Cancer
- b. Infiltration
- c. Metastasis
- d. all

4- 32 years old, female, have peptic ulcer, came with severe abdominal pain, you suspect peptic ulcer perforation. What is the initial test you can order for her?

- a. X-ray
- b. MRI
- c. CT
- d. US

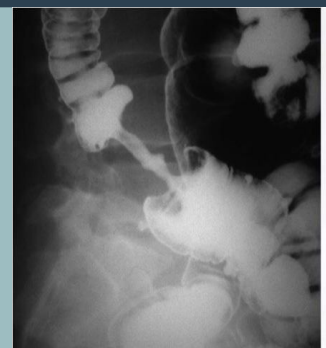
5-Patient with bloody diarrhea and vomiting

- a. Ulcerative colitis
- b. Crohn's disease
- c. Colon cancer
- d. Celiac disease



6- Elderly patient with progressive dysphagia, what is the diagnosis?

- a. Ulcerative colitis
- b. Crohn's disease
- c. Colon cancer
- d. Celiac disease



Answers
1) D
2) B
3) D
4) a
5) a
6) c