



Radiology
Team 438

Radiology of Bone Infections and Tumors

Lecture 17

Objectives


The main focus and objective of this lecture is to help student to be competent in looking at MSK images and interpreting findings, by learning:

- ❖ Normal radiological anatomic landmarks
- ❖ System of analyzing findings “Where to look & What to look for”
- ❖ Recognize features of certain disease entity

Outline

- ❖ Introduce Imaging approach to skeletal infections and Identify important findings including sequelae and complications.
- ❖ Introduce Imaging approach to skeletal neoplastic disorders and Identify important findings including sequelae and complications

Reviewed By



Noura Alturki
Jehad Alorainy

Color Index:

♦ Important ♦ Doctor's Notes ♦ Extra ♦ Female slides ♦ male slides

Team Leaders



Omar Aldosari



Leena Alnassar



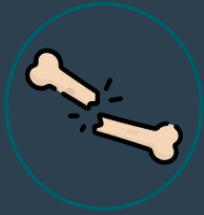Shahd Alsalamh

Done by:

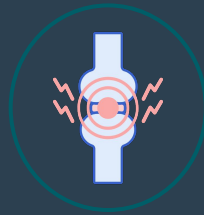
Noura Almazrou

Rana Alshamrani

Musculoskeletal system pathologies:



Trauma
(Abnormal healing)



Arthritis
Ex: Gout



Infectious



Hematological
Sickle cell disease,
thalassemia



Neoplastic



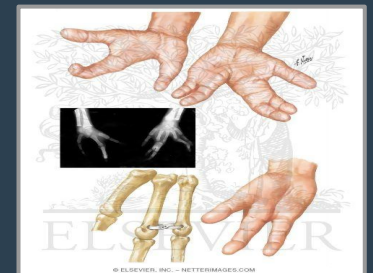
Congenital

Ex: has only one tibia or fibula, lobster claw hand deformity.



Metabolic

(80% of the issues are caused by Trauma, Infectious & neoplastic. While 20% by the rest)



EXTRA: lobster claw hand deformity

Key Features of imaging

Morphology	Behavior of lesion	Age of patient	Site (Location)
<ul style="list-style-type: none"> • Osteolytic • Osteosclerosis • Mixed • soft tissue 	<p>Is it aggressive?</p>	<p>It is important! For example, a patient in his 20s with aggressive looking tumor is most likely osteosarcoma, but if the age is >40 it would be metastasis or myeloma.</p>	-

Types Usually it does not go out of these four

1. **Osseus:** Osteoma - Osteosarcoma.
2. **Chondral:** Enchondroma - Chondrosarcoma.
3. **Fibrous:** Osseous Fibroma - Fibrosarcoma.
4. **Soft tissue:** Lipoma - Liposarcoma.

Key features

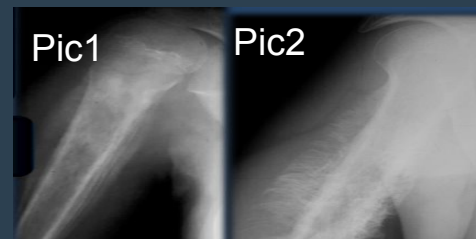
Lytic= Erased like pattern
Sclerotic=pen Scribble pattern

» Morphology

- **Pattern of bone destruction** is it lytic or sclerotic?
- **Size, Shape & Margin of lesion** Can you well-define the lesion margin with a pencil?
- **texture of lesion Matrix**
 - sclerosis or chondroid matrix or nothing specific?
- **Cortex & Periosteal reaction.** When there is increase in the bone activity and the neoplastic cells will go underneath the periosteum and rapidly grow to move to other locations

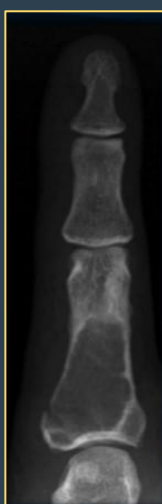
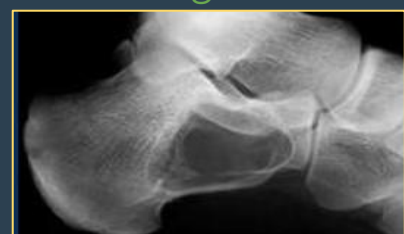Pic1: laminated periosteal reaction (Onion type)

Pic2: Hair-on-end type



» Geographic

- For example this lesion will be one of two, either **bone cyst** or **intraosseous lipoma** Based on its geographical location (calcaneus) and pattern of bone destruction (lytic)
- And for the fingers nothing comes like this image and in the fingers except for **enchondroma**



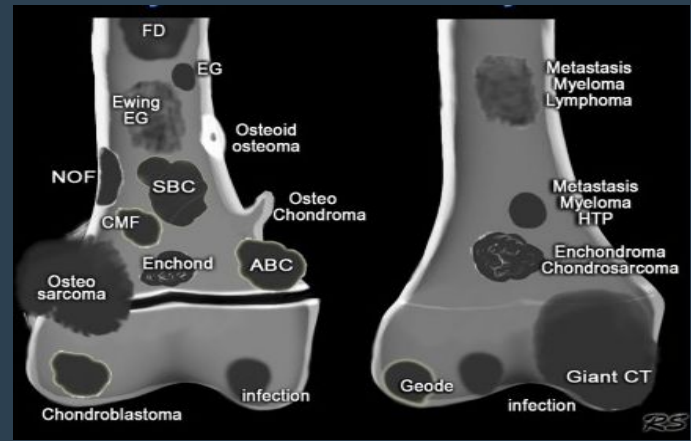
» Behavior of the lesion

- **Slow grow usually benign**
When we compare the two images before and now the lesion will have hardly noticeable change or if any which indicates benign lesion.
- **Rapid grow (Aggressive).** Usually malignant
If we had an image without any lesion 3 months ago, and a recent image was taken showing a new lesion growing.

» Age of patient

- Pediatric, Adult, Elderly.

Age plays a major role in the DDx. if the patient is a child you can't say from the radiological appearance that it's metastasis without knowing an existing primary lesion. same for old patients you can't say rhabdomyosarcoma as it is very common to children, not old patients.



< 30 years

> 30 years

» Site

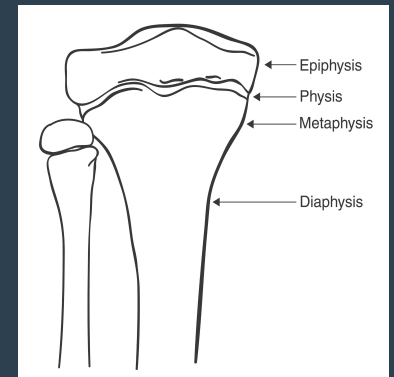
- Diaphyseal, metaphyseal or epiphyseal.
- Cortical vs. Medullary (eccentric → peripheral vs. concentric → central).

It's **important** to know the **difference** between the **diaphysis**, **epiphysis**, **metaphysis** your going to be asked about it.

💡 EXTRA

The long bone in a child is divided into four regions:

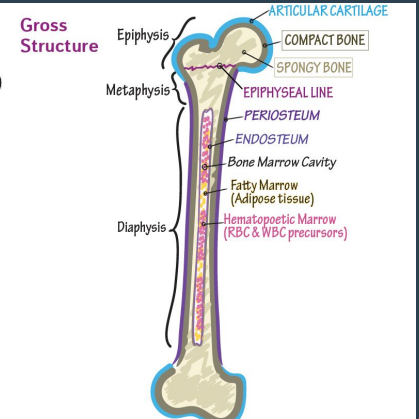
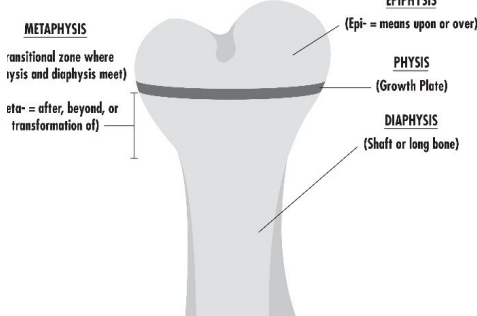
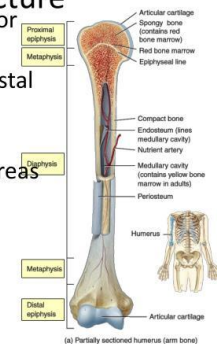
- 1) **Diaphysis** (shaft or primary ossification centre),
- 2) **Metaphysis** (where the bone flares),
- 3) **Physis** (or growth plate)
- 4) **Epiphysis** (secondary ossification centre)



. In the adult, only the metaphysis and diaphysis are present

Bone Structure

- The **diaphysis** is the shaft or body of a long bone.
- The **epiphyses** form the distal and proximal ends of a long bone.
- The **metaphyses** are the areas where the epiphyses and diaphysis join.



Example 1

- **First:** How is the pattern of bone destruction? is it lytic or sclerotic?

Answer= It's lytic.

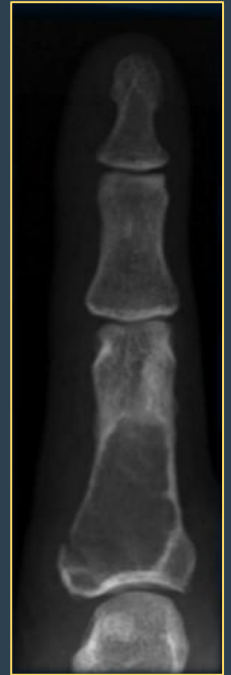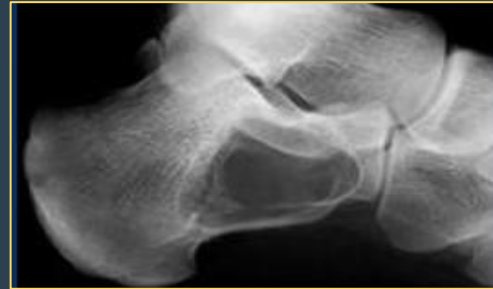"Erased like pattern"

- **Second:** how are the margin of the lesion?

Answer= well defined margins

- **Third:** is their periosteal lesion?


Answer=No



(If the lesion was lytic and well marginated it's indicative of a benign lesion)

Example 2

- **First:** How is the pattern of bone destruction? is it lytic or sclerotic?

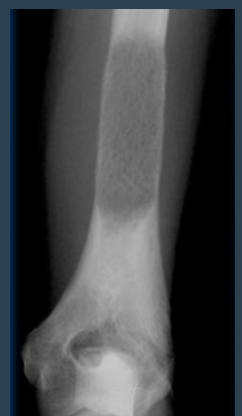Answer pic1 =It's lytic.  Ans Pic2=mixed lytic and sclerotic
like you erased with an eraser

- **Second:** how are the margin of the lesion?

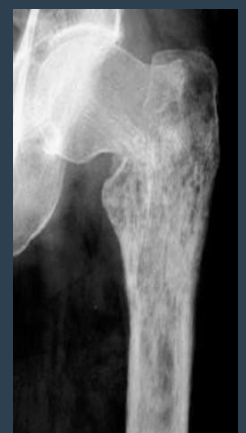Ans for both pic1 and pic2= ill defined, can't well define the margins.

- **Third:** if we for example compared this lesion with a normal x ray taken from the same patient 3 months ago, would we consider this lesion rapid or slow growing?

Answer= Rapid



Pic1=moth-eaten



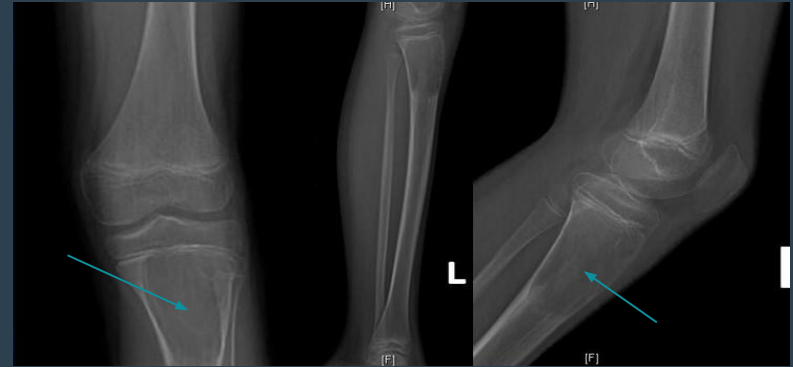pic2=permeative

» Osteolytic / Benign/pediatric

CASE 1: 13 year-old boy patient presented with knee pain and swelling.
X-ray of knee requested.

Findings:

- Expansile lytic lesion.
- Metaphyseal.
- Homogeneous, no calcification.
- No cortical destruction and no periosteal reaction.
- No soft tissue swelling.
- Well defined lesions



Aneurysmal Bone Cyst (benign)

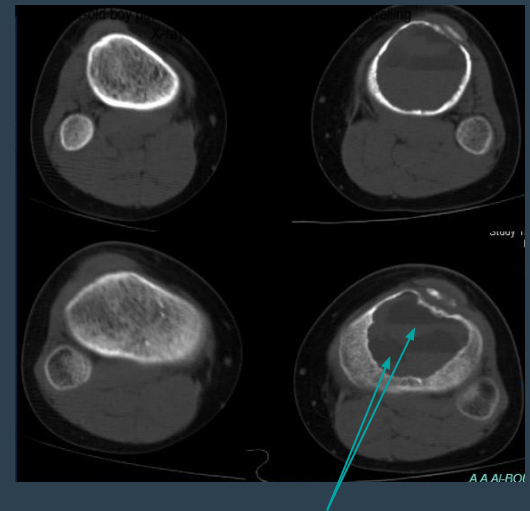
(we always start with X-ray but when the X-ray is normal we move on to CT scan, one of the advantages of CT it guides us during biopsy)

Diagnosis: Aneurysmal Bone Cyst

Extra from team 437:



[Amazing website explains the systemic approach and DDx of bone tumors.](#)



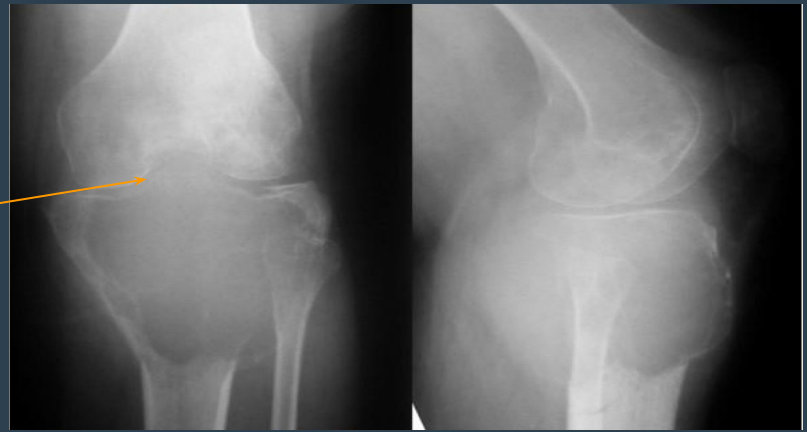
Fluid-fluid level: two densities with a straight line.

» Osteolytic / Benign /adult

CASE 2: Adult man with knee pain and swelling.

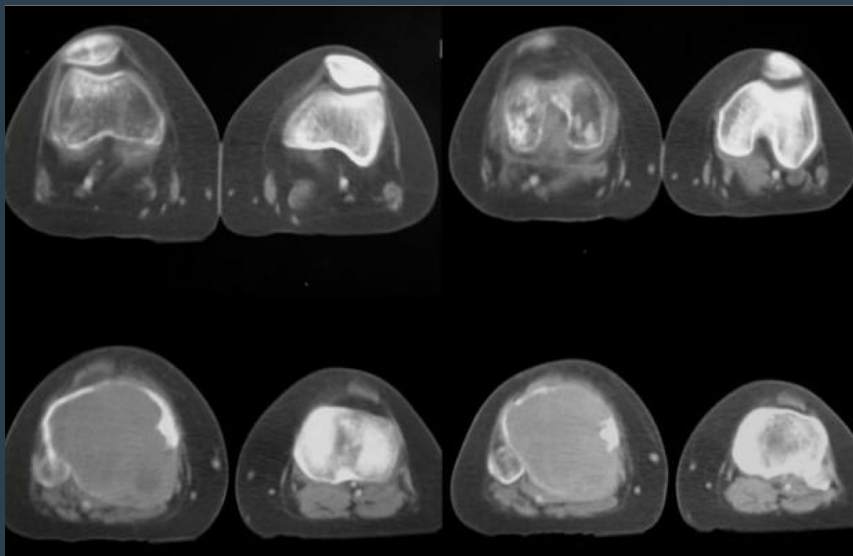
Findings:

- ❖ Expansile lytic lesion.
- ❖ Metaphyseal / Subarticular
Beneath the joint line
- ❖ Homogeneous, no calcification.
- ❖ Little Cortical destruction and periosteal reaction.
- ❖ Soft tissue swelling.

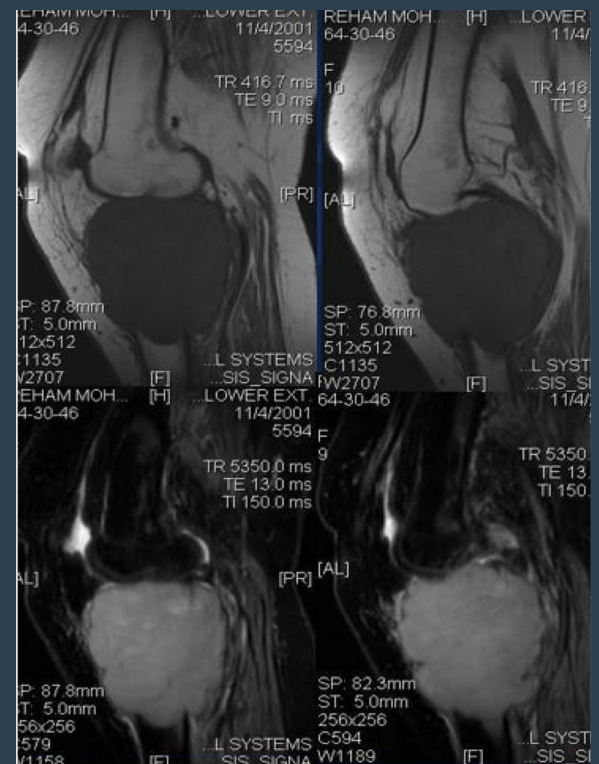


CT scan

This lesion is benign and aggressive because there is soft tissue swelling. How do we know if there is soft tissue swelling? By looking at the MRI



CT



MRI

Diagnosis: Giant Cell Tumor

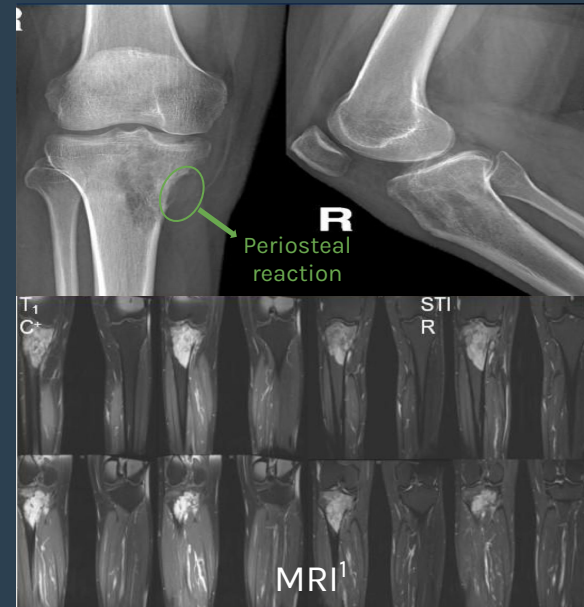(The main reason we said this is a **giant cell tumor** was because of the patient's **age**, it's very hard to differentiate between giant cell tumor and aneurysmal bone cyst but it doesn't make a big difference because their management is one)

» Osteolytic / Aggressive (Malignant) lesions in an adult

CASE 3: Adult man with knee pain.

Findings:

- ❖ Eccentric (peripheral) osteolytic + sclerotic lesion.
- ❖ Metaphyseal / Subarticular.
- ❖ **Heterogeneous** texture.
- ❖ Cortical destruction and periosteal reaction.
- ❖ Localized soft tissue extension.
- ❖ Ill defined lesion.
- ❖ Aggressive behavior (malignant).



**Permeative Pattern
Osteosarcoma / Lymphoma**

Permeative pattern is the most aggressive pattern it's seen in 2 cases:
1-malignant neoplasms 2-infections such as osteomyelitis

**Diagnosis: Osteosarcoma/
bone lymphoma**

'Why do we do MRI for a patient with bone lesion?

1-if there's any soft tissue involvement

2-any lymph nodes

3-any involvement of the vascular bundle,
we do MRI to **stage** the lesion not to **diagnose**

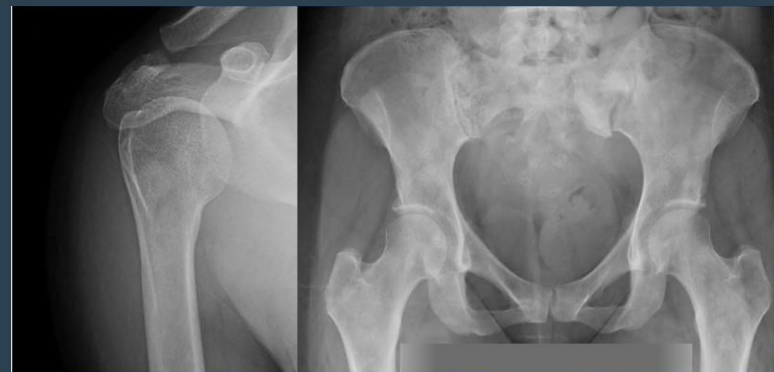This will help the surgeon to know the nature of the surgery is well confined, not vascular complicated or he will need to stent some vessels prior to extracting the tumor. Another example if the tumor is inside a joint, that will indicate amputation.

» Sclerotic Osseous Lesion

CASE 4: 57 years old female patient presented with bone ache had history of breast carcinoma.

Findings:

- ❖ Preserved bone density in general.
- ❖ Sclerotic foci of variable sizes (islands).
- ❖ No destructive lesion.



Sclerotic bone metastasis.

As if there was a piece of cotton on top of the bone

Diagnosis: sclerotic bone metastases

When you see sclerotic lesions throughout the bone it's either :

(3 B's and 1 P)

-breast cancer= most likely if female

-bowel cancer

-bladder cancer

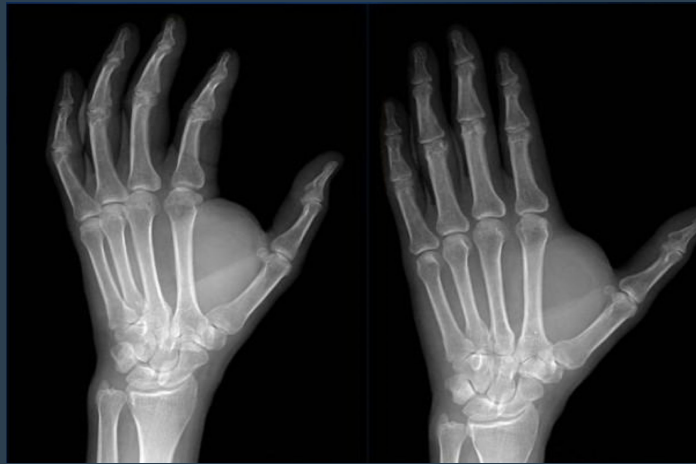-prostate cancer= most likely if male

» Soft tissue Mass

CASE 5: Adult female patient presented with hand swelling (for a long time and slowly grows in size) X-ray of hand requested.

Findings:

- ❖ Soft tissue swelling (relatively lucent).
- ❖ No calcification.
- ❖ No osseous involvement. Purely soft tissue mass.the bone is normal

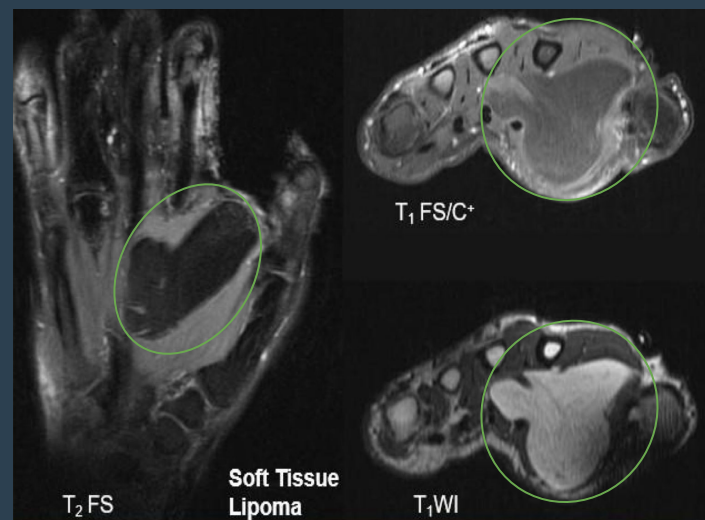


Findings in The MRI (to clarify the lesion):

- ❖ High signal on T1WI and low in T2FS → fat saturated.
- ❖ No enhancement. = of the lesion When we gave contrast. → not aggressive
- ❖ Mass in the thenar region.
- ❖ No invasion of the bone.

(We compare the lesion with the adjacent subcutaneous fat and since its lipoma it will have the same intensity of the fat)

How to differentiate between lipoma and liposarcoma? by the outline of the margins, and if there's any underlying pathology. We perform T1FS/C+ (C+ is the IV contrast that we give to the patient to see if there is any strands or vascularity) to differentiate.

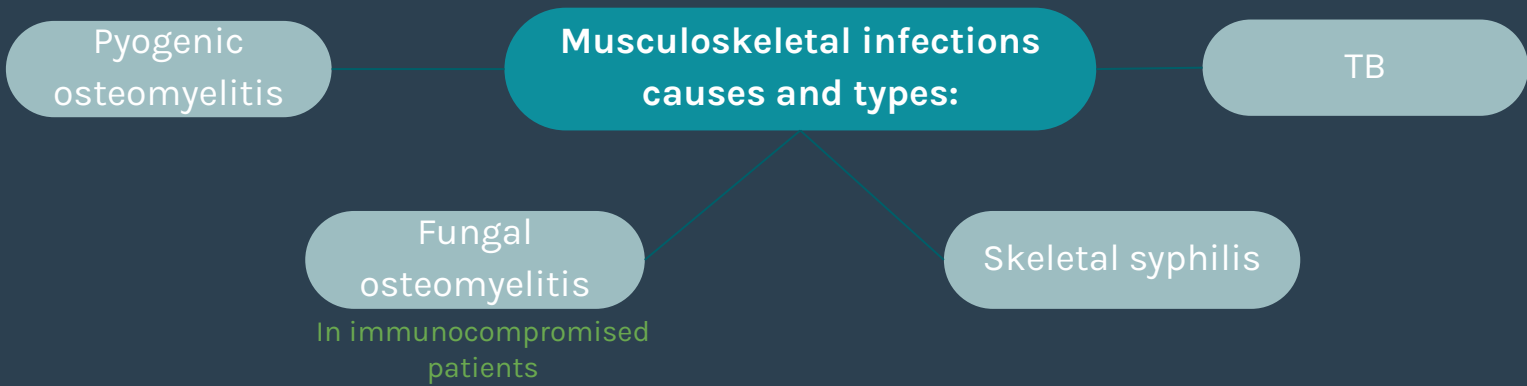


Soft Tissue Lipoma (very common)

Diagnosis: lipoma

Tx= either surgical or leave as it is.

Bone infections






» Pyogenic osteomyelitis

- ★ **Staphylococcus aureus:** 80-90% of all infections¹ (**the most common**)
- ❖ **Escherichia coli:** intravenous drug users (IVDU) and genitourinary tract infection
- ❖ **Pseudomonas spp.:** IVDU and genitourinary tract infection
- ❖ **Klebsiella spp.:** IVDU and genitourinary tract infection
- ❖ **Salmonella spp.:** **sickle cell disease**
- ❖ **Haemophilus influenzae:** **neonates**
- ❖ **group B streptococci:** **neonates**

» Location of the infection

Frequency by location, in descending order :

- 1** lower limb (most common) 
- 2** vertebrae: lumbar > thoracic > cervical 
- 3** sacroiliac joint -> Septic Arthritis² 
considered as an Emergency

» The location of osteomyelitis within a bone: ★

- 1 Neonates:** metaphysis and/or epiphysis 
- 2 Children:** metaphysis 
- 3 Adults:** epiphyses and subchondral regions 

» Radiographic features:

In some instances, radiographic features are specific to a region or a particular type of infection, for example:

- 1** subperiosteal abscess
- 2** Brodie's abscess
- 3** Pott puffy tumor

Like the periosteal reaction in neoplasm but in neoplasm there are malignant cells and here there is bacteria under the periosteum

The bacteria killed the bone and there is no vascularity.

1- Staph. Aureus is the most common cause for all of them, for example, when asked in sickle cell disease what's the most common pathogen causing osteomyelitis you will say Staph Aureus not salmonella, but in conditions where the result shows salmonella that means the patient for sure have sickle cell disease. So not every sickle cell disease come with salmonella but all salmonella come with sickle cell disease.

2- When the infection is in the joint we don't call it osteomyelitis we call it septic arthritis and it's considered as an Emergency so we have to act quickly. If the joint has destruction and you waited for the next day then it's too late and even the antibiotics will not work, not like the bone it's okay to start antibiotics after days.

» Imaging features:

- ❖ **Regional osteopenia** (decreased bone density)
- ❖ **periosteal reaction/thickening** (periostitis): variable; may appear aggressive, including the formation of a **Codman's triangle**
- ❖ focal bony lysis or cortical loss
- ❖ **Endosteal scalloping** the bone looks like it was bitten (like a cookie bite:)
- ❖ loss of **trabecular bone** architecture
- ❖ new bone apposition
- ❖ eventual peripheral sclerosis
- ❖ In chronic or untreated cases, eventual formation of a **sequestrum** (another name: **Brodie's abscess**), **involucrum**¹, and/or **cloaca**² (sinus from the bone extending to the skin) may be seen.

» Osteomyelitis

9 Year Old (=lesion in the metaphysis) Male With Hand Pain Post Trauma. He had pneumonia 1 week ago

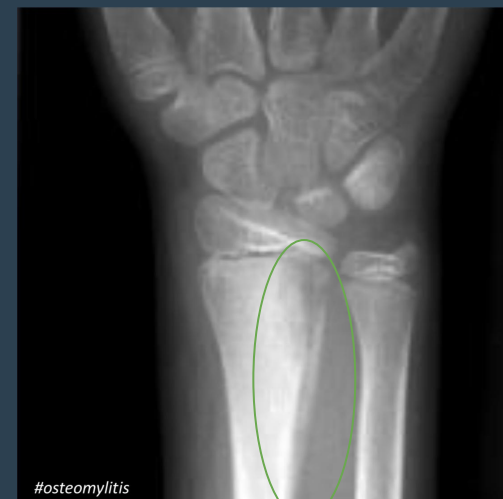Scenario from the doctor:

The patient was okay but before one or two weeks he had an infection, common cold or sore throat and after taking antibiotics he got better.

After one week he fell on his hand while he was playing.

Now the bacteria in his blood, lung or throat will go to the place with more blood which is the place of injury, so the patient will develop osteomyelitis.

This condition is treated very easily with antibiotics but the doctor's job is to detect it quickly before the lesion become chronic and not treatable.



#osteomyelitis

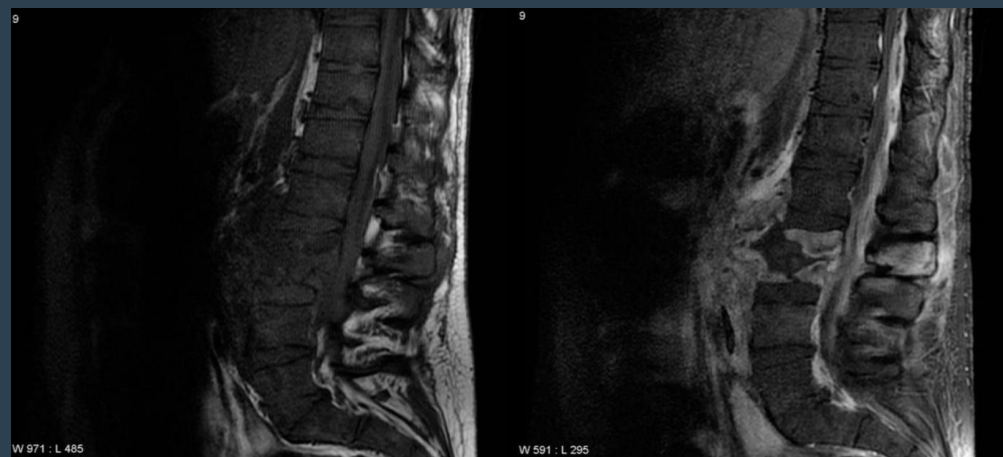Periosteal reaction and Codman's triangle

» TB spine discitis (osteomyelitis) (emergency)

very endemic in the Middle East

Destruction to the vertebrae in the lumbar spine and the disc space .

Pott's disease briefly is a hematogenous spread of TB from the lungs mainly



With contrast

Pott's disease

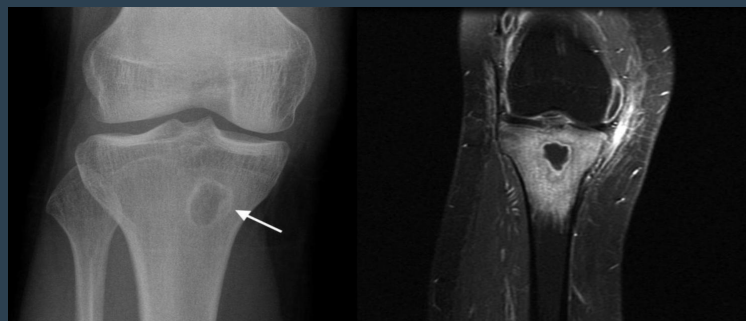
1- An involucrum is a complication of osteomyelitis and represents a thick sheath of periosteal new bone surrounding a sequestrum.

2- The cloaca is an opening in an involucrum which allows drainage of purulent and necrotic material out of the dead bone. If the tract extends to the skin surface, the portion extending beyond the involucrum to the skin surface is called a sinus tract.

» Osteomyelitis

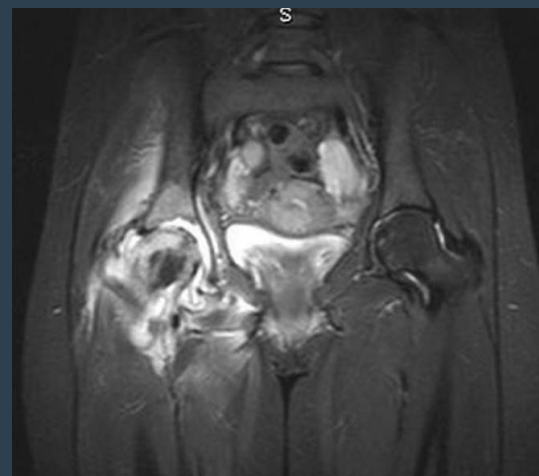
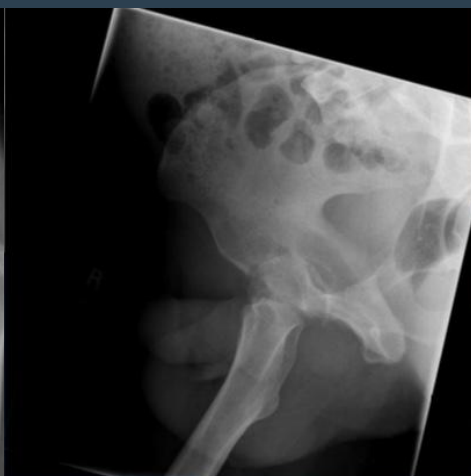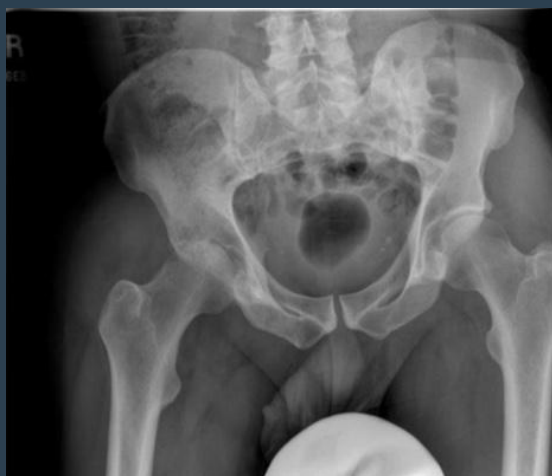30 year old leg pain for long time:

The bacteria killed the bone, this is very bad and a long term problem. So now the patient will need a big surgery and drainage not only antibiotics.



**Brodie's abscess
(Sequestrum)**
=chronic osteomyelitis

» Septic Arthritis *emergency

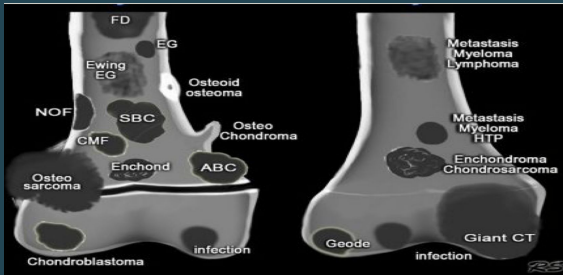


Infection in the joint.
The joint space is completely narrowed.
When the patient is presenting with limping, **fever, pain in one hip** (or with swelling and hotness) and completely narrowed joint space (monoarticular arthritis), the number one thing you wanna think about is septic arthritis.

In MRI we see septic arthritis (infection of the joint) extending to the bone.
You should take a sample of the fluid and send it for culture, sensitivity and gram stain and start the patient on empirical antibiotics ASAP.

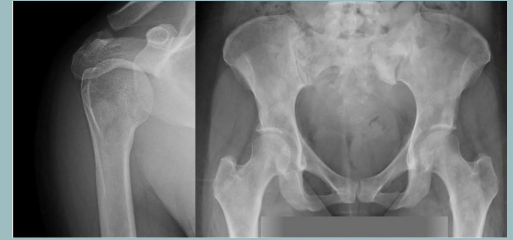Summary

Metabolic & Endocrine Disorders:

The Disease	Key features
Bone tumors	<ul style="list-style-type: none"> ● Benign: Slow growing and well margined ● Malignant: Rapid growing and ill margined
Sclerotic bone metastasis	<ul style="list-style-type: none"> ● Preserved bone density. ● Diffuse scattered white patches of osteosclerosis suggests bone metastasis. ● If the patient is female, the most likely cause of metastasize is breast cancer, while in males is prostate cancer. Bladder and bowel cancer also causes sclerotic metastasis.
Pyogenic osteomyelitis	<ul style="list-style-type: none"> ● The most common organism is Staph. Aureus. ● Haemophilus influenzae and group B streptococci in neonates only.
Septic arthritis	<p>Fever, pain in one joint and narrowed joint space in the imaging.</p>
TB spine discitis	<p>In the spine. Destruction of the vertebrae and disc space.</p>
Neoplastic by age.	 <p><30 years >30 years</p>

1-A 65 year old male known to have prostatic cancer complains to his oncologist of bone pain. An X ray was taken showing the following. What does it show?

- a. Benign bone cyst
- b. Giant cell tumor
- c. Sclerotic bone metastasis
- d. Multiple lipomas

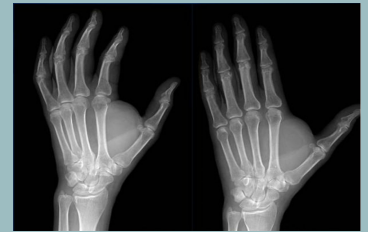

2- What are the most frequent pathogens in a sickle cell anemia patient with osteomyelitis?

- a. S. aureus and Serratia.
- b. Staph aureus. And salmonella
- c. Pseudomonas
- d. Streptococcus and Enterococcus

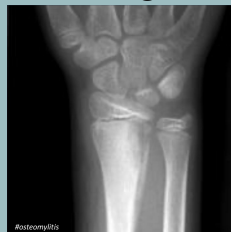3-Adult female patient presented with a hand swelling, x-ray of hand was ordered. If you want to delineate what's the possible underlying tissue character of this lesion what radiographic modality you'll order?

- a. MRI
- b. US
- c. Fluoroscopy
- d. Interventional Radiology



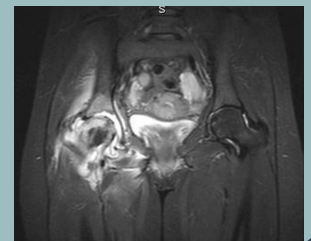
4- 9 Year Old Male With Hand Pain Post Trauma. He had pneumonia 1 week ago, what's the diagnosis?

- a. Potts disease
- b. Osteomyelitis
- c. Septic arthritis



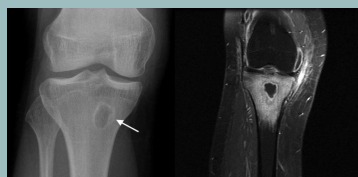
5- Patient presented with limbing, fever and right hip pain. x-ray and MRI were ordered. What is the diagnosis?

- a. Potts disease
- b. Osteomyelitis
- c. Septic arthritis



6- 30 year old male with leg pain for long time, your diagnosis?

- a. Potts disease
- b. Brodie's abscess (chronic Osteomyelitis)
- c. Septic arthritis



Answers
1)C
2)B
3)A
4)B
5)C
6)B