



**Radiology**  
Team 438

# radiology of the Respiratory disease

## Lecture 4 (2 lectures)

### Objectives

- ❖ Technique Objectives
  - Learn the difference between PA vs. AP CXR
  - Learn the utility of a lateral decubitus CXR
  - Understand the terms inspiration, penetration, and rotation as they apply to determining a technically adequate film.
- ❖ Anatomy
  - Learn the basic anatomy of the fissures of the lungs, heart borders, bronchi, and vasculature that can be seen on a chest x-ray III.
- ❖ Interpretation
  - Develop a consistent and thorough technique for reading images
  - Learn how the silhouette sign can help localize pathology IV.
- ❖ Pathology

Reviewed By



Noura Alturki  
Jehad Alorainy

Color Index:

♦ Important ♦ Doctor's Notes ♦ Extra ♦ Female slides ♦ male slides

### Team Leaders



Omar Aldosari



Leena Alnassar



Shahd Alsalamh

Done by:

Mohammed Alhuqbani

Noura Almazrou

Nouf Alhumaidhi

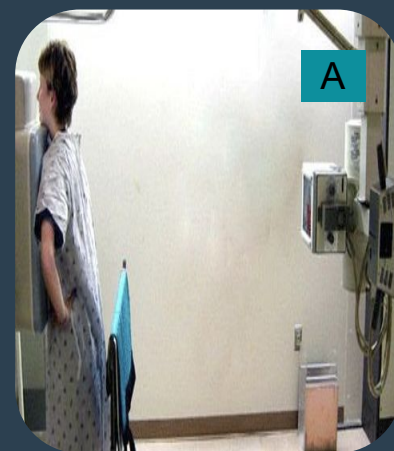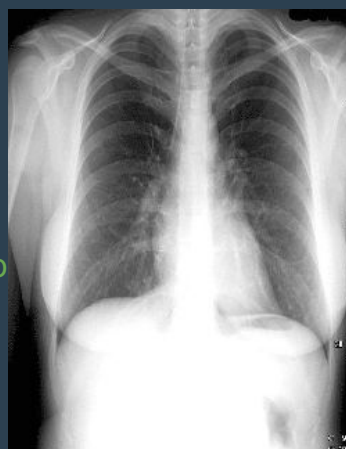
[Editing file](#)

# Positioning

## » Positioning

### » Posterior Anterior position (PA)

- It's the projection of X rays going through the patient back (posterior) then leaving through his chest (anterior).
- as shown in Image A, the patient elevate the arms and places the hands-on his waist to push the scapula away from the lungs way to get a better image of the lung
- distance between the x-ray and the film 2m



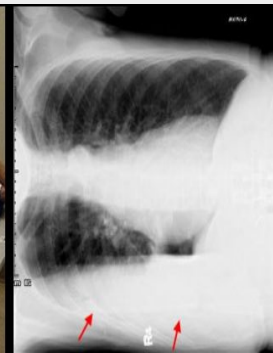
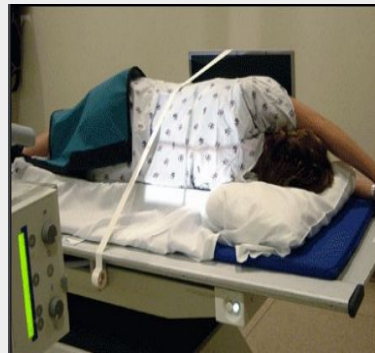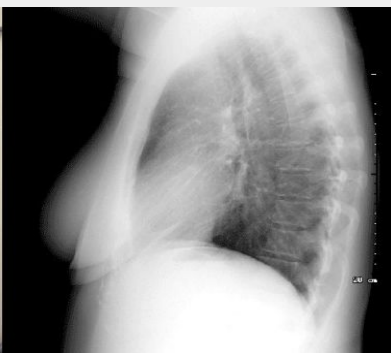
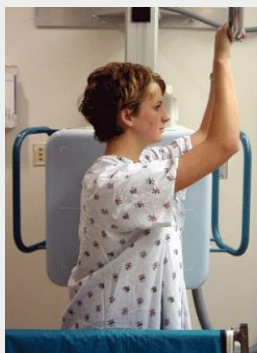### » positioning lateral



#### Lateral

#### Lateral Decubitus

Image



Position

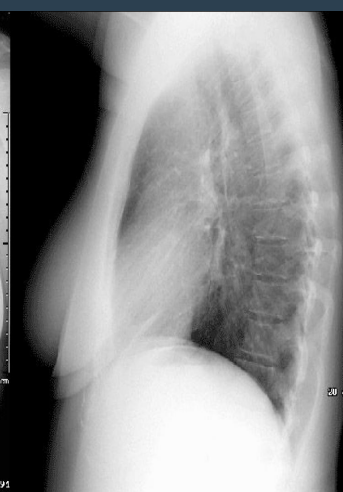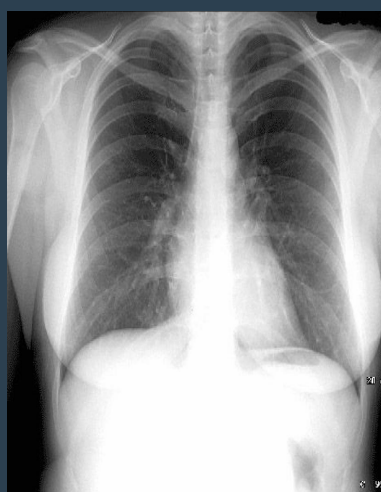- The X-ray tube is on the right of the patient and the film is on the left
- The Patient stands up with hands held high
- The Film is placed on the left to reduce heart magnification

- Helpful in assessing the volume of pleural effusion and determine whether its mobile or loculated
- the patient should roll on the suspected side

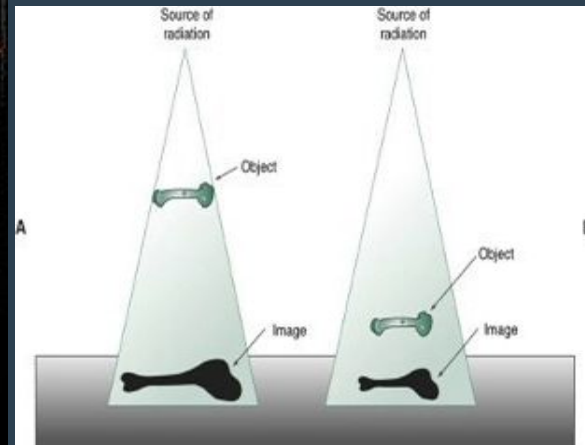
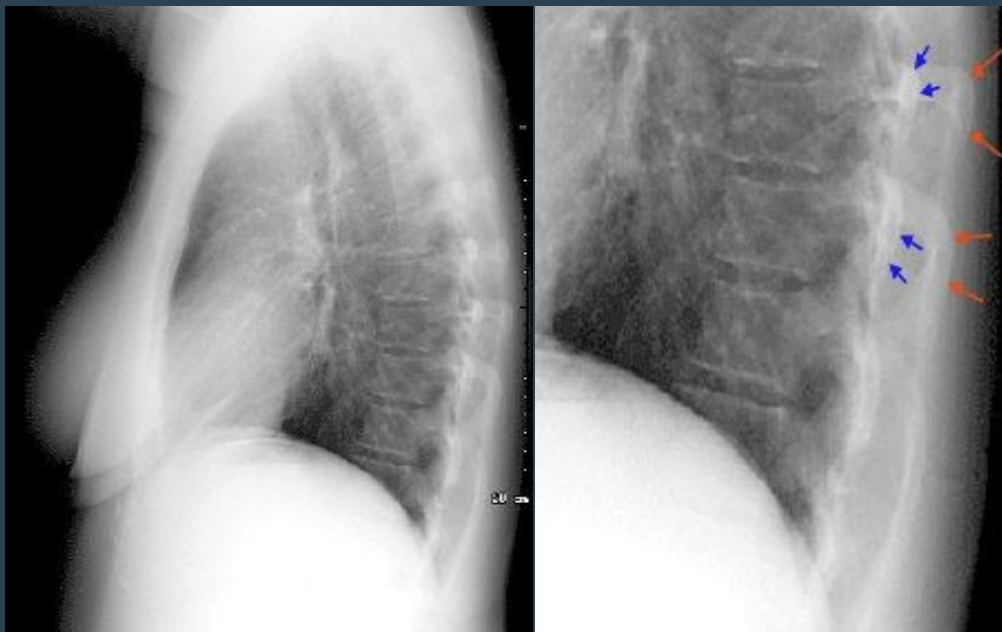### » Always read them together

since x-ray is one dimensional images are set superimposed on each other

- in the PA view we can't see behind the heart
- so lateral view can help localise the pathology



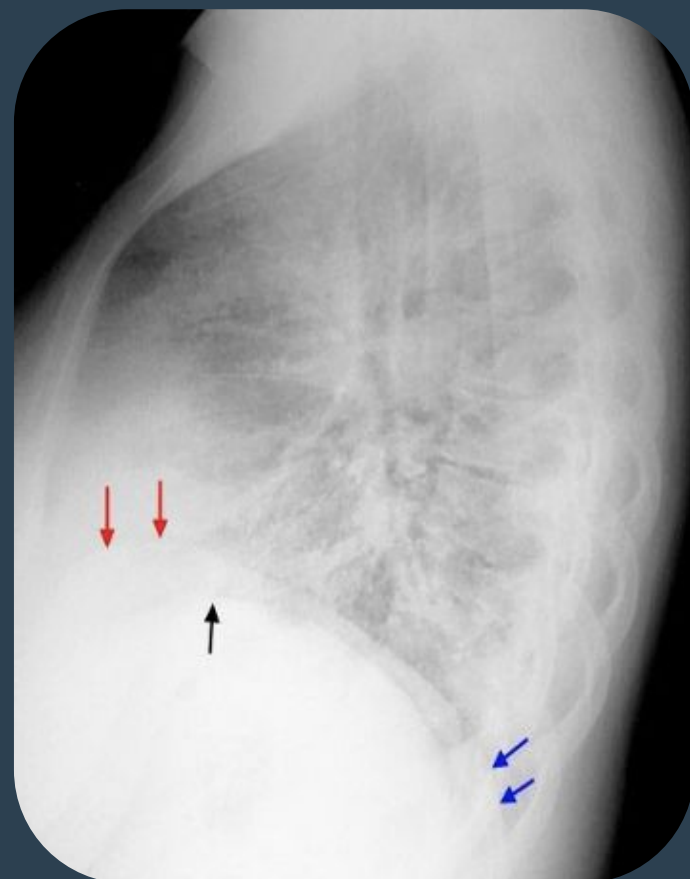## » Magnification Effect



the blue arrow represents the left ribs Red arrow represents the right ribs.  
Note: the right ribs look larger due to the divergence. (magnification effect)  
notice that one breast is larger than the other

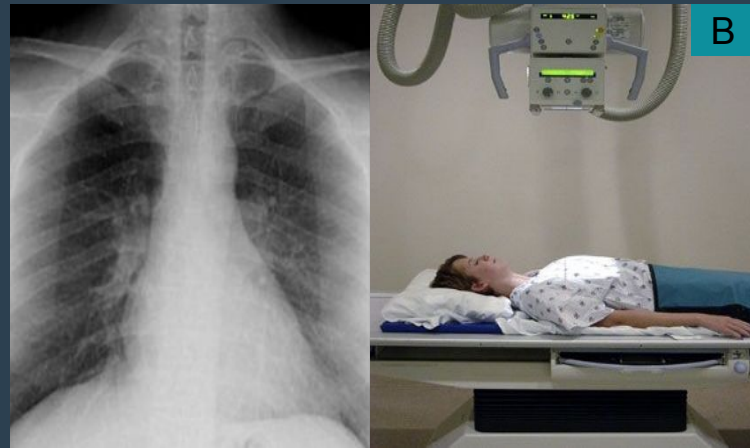
**magnification effect** the closer the object to the X-Ray source the larger the divergence of the image giving a larger image

- ❖ The Same principle applies on the diaphragm:
  - posteriorly: the right hemidiaphragm continues posteriorly to meet the right ribs and gets magnified with them.
  - anteriorly: the right hemidiaphragm continues all the way to the anterior aspect of the thorax
- ❖ The left hemidiaphragm continues anteriorly and can't be seen further because the heart sits on the left hemidiaphragm therefore it obscures its border, this phenomenon called The Silhouette sign.

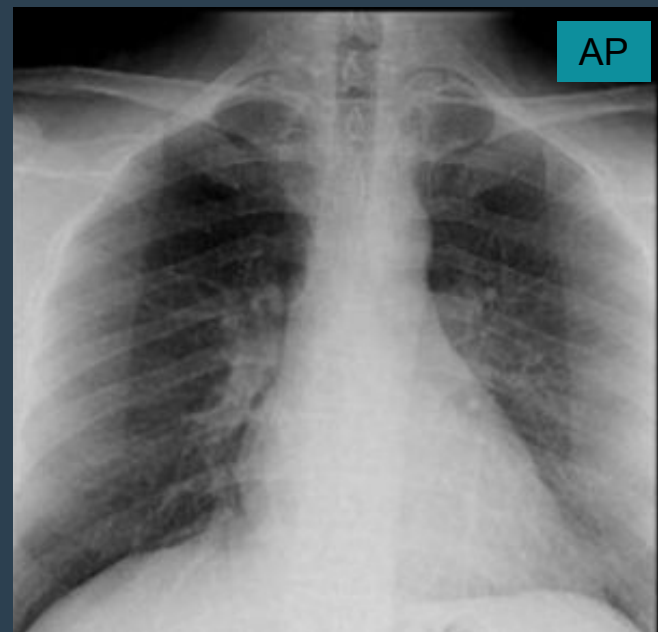
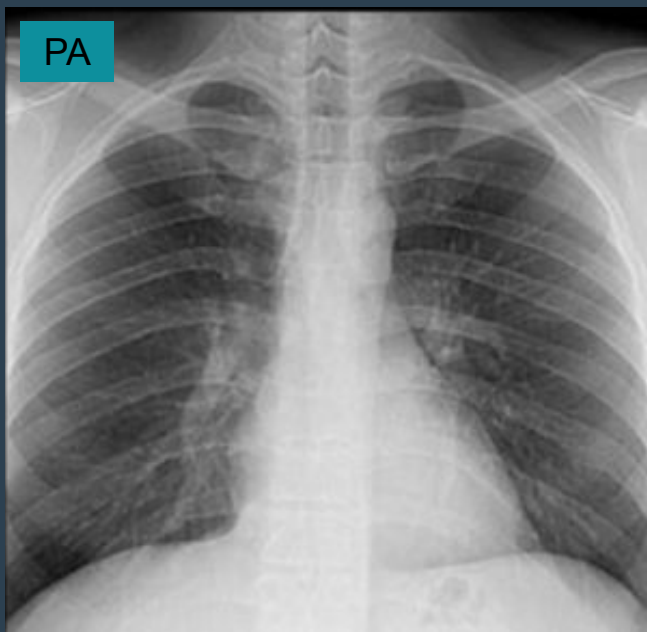


## » Anterior Posterior position (AP)

- The AP position is always done when the patient is in a supine position (image B), in this position the patient is closer to the X-ray source which causes a magnification effect.
- used only in ill patients who can't stand



## » PA VS AP View



	PA view	AP view
Clavicle	V shaped, over lung fields	straight, Above lungs apex
Scapulae	Away from lung fields, because we ask the patient to rise his hand	Over lung Fields
Ribs	Posterior ribs distinct	Anterior ribs distinct
Heart		magnification (so we don't measure the Cardiothoracic ratio). widening of the mediastinum

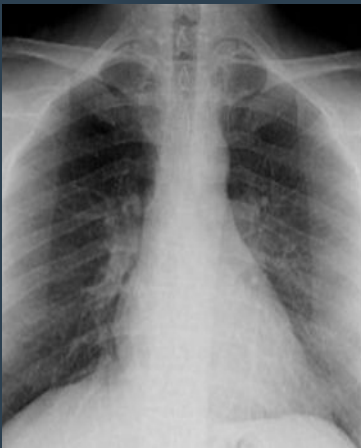PA view is superior to AP view, but in some patients who can't stand AP view is the only option

## » Adequacy of Film

- We determine technical adequacy of the film, by 3 measures:
  1. Inspiration
  2. Penetration
  3. Rotation

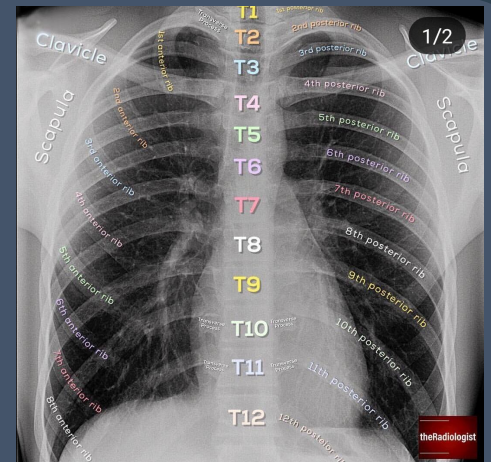
## » Inspiration

- Patients should be examined while taking full inspiration to **open up the lungs and examine the pathologies**
- During inspiration the diaphragm is pulled down and the vessels are stretched
- If blood vessels are close to each other the image will become less clear and might lead to a false diagnosis

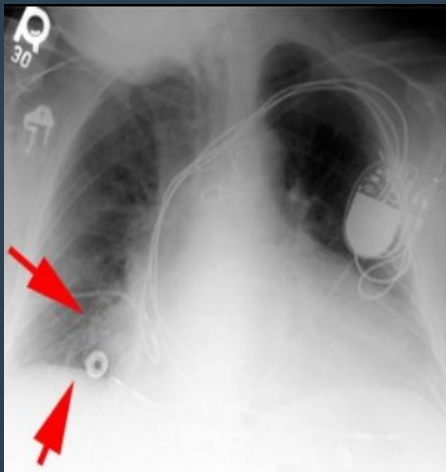

### Revision:

- Ribs on The chest X-ray have both anterior and posterior aspects for each rib
- Ribs start from the costovertebral junction (vertebrae) to the costosternal junction (sternum)

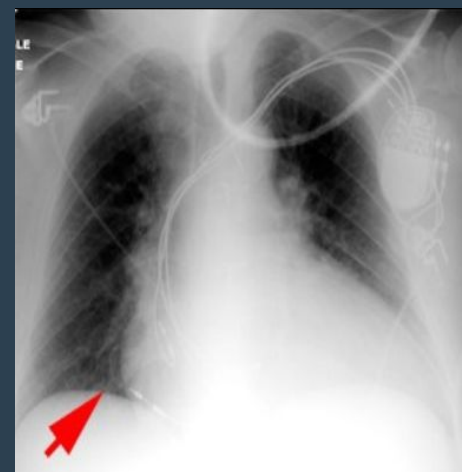


- To assess adequate inspiration 8-10 posterior ribs must appear and 5-7 anterior ribs



Inadequate films

- In inadequate films, the lungs are lighter because of the proximity between blood vessels
  - Blood is radiopaque
- cant see the cardiac outline, so we are not sure if there is abnormality

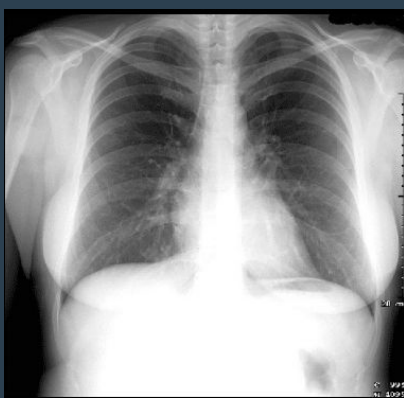
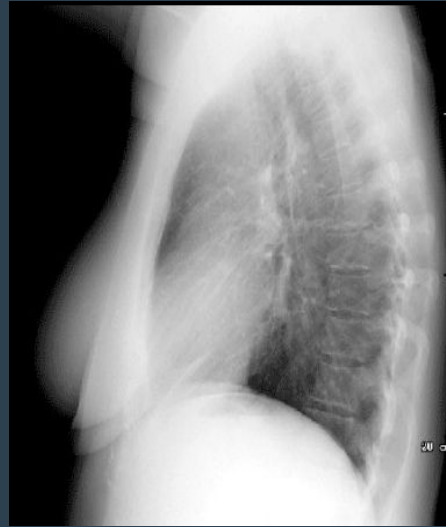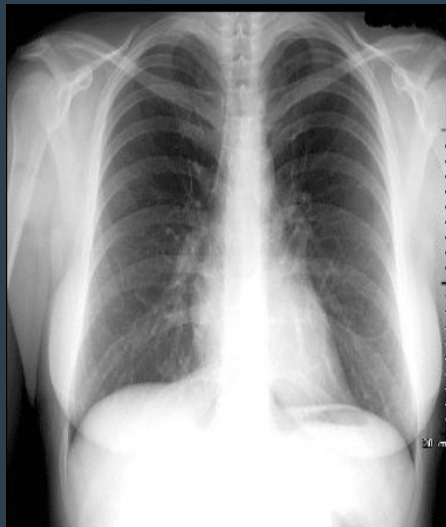


Adequate films

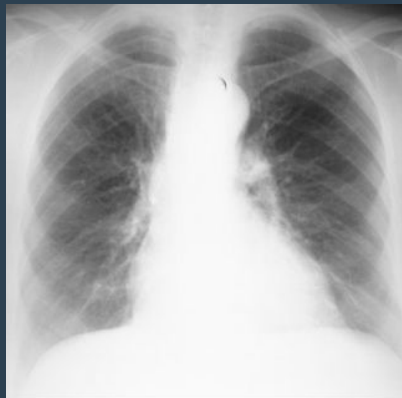- the same patient, with well inspiration
- In adequate films, the lungs are darker because of the air-filled in it
  - Air is radiolucent
- can see the cardiac outline, we can see that the patient is normal

## » Penetration

- Penetration is the degree to which the X-ray passed through the body.
- To assess penetration,
  - On a good PA film, you should see the dorsal spine through mediastinum, with few details of the disc spaces and border of vertebral bodies. Bronchovascular structures can usually be seen through the heart
  - On a good lateral film, the spine will appear darker as you move caudally (downward) because there is more air, more lungs. you can see the dorsal spine in more details
  - The sternum should be seen edge-on
  - posteriorly you should see two sets of ribs

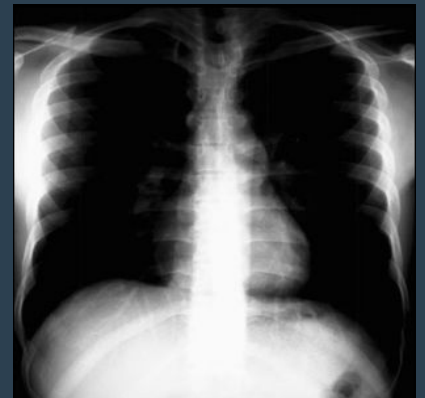

Well penetrated



Underpenetrated

underpenetrated film you can't see the the dorsal spine prominent lung vessels. pathology behind the mediastinum can be missed



Over penetrated

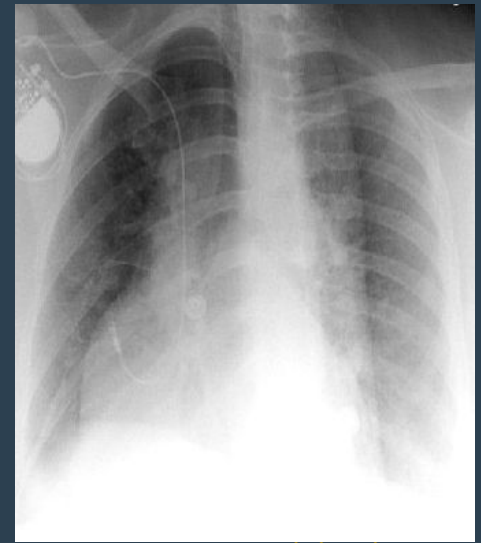
over the penetrated film you can see super details of the dorsal spines black lungs you don't see the vessels. pathology in the lung can be missed.

# Technical Adequacy

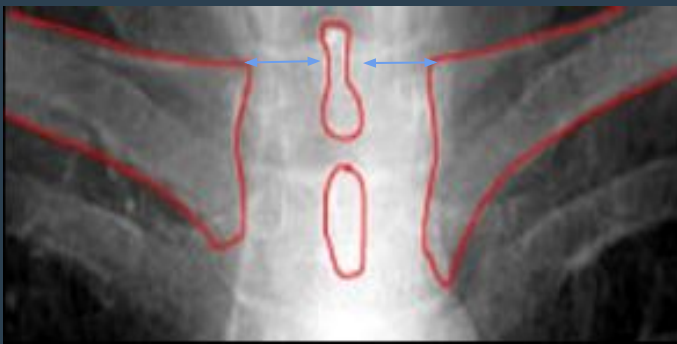## » Rotation

- If there is a rotation of the patient, the mediastinum may look very unusual
- To assess rotation,
  - Check if the clavicle medial heads are equidistant to the vertebral spinous process
- In this rotated film, notice how the clavicular head is away from the spinous process (red arrows) which lead to the widening of the mediastinum and might be falsely diagnosed with tension pneumothorax (blue arrows) but are just skin folds

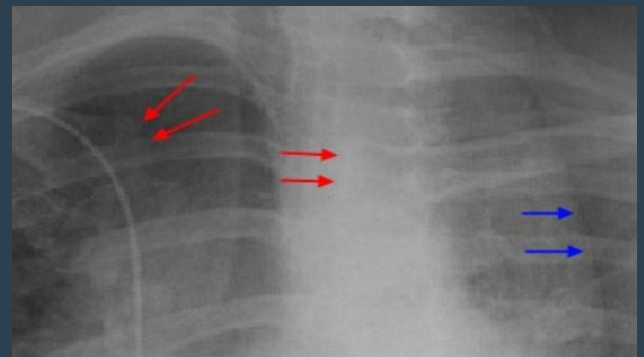
**Rotated images MUST be repeated, because most common factor that can affect the CXR quality**



Improper positioning  
Can cause: poor visualization of lung base and cardiomegaly



the distance between the blue arrows should be equal

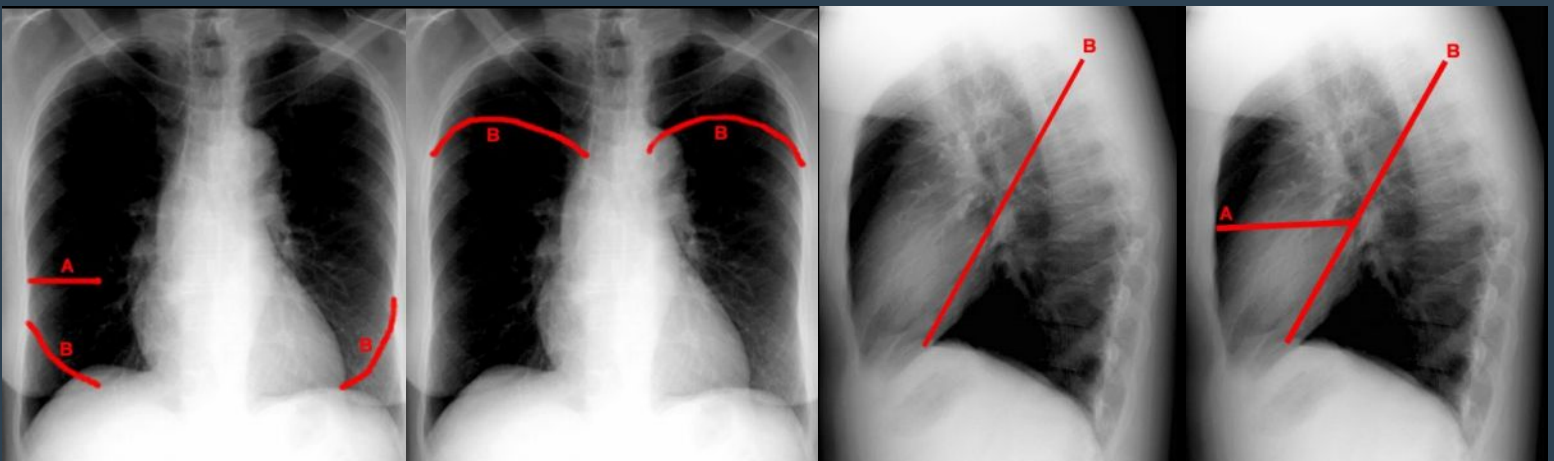


# Chest Anatomy

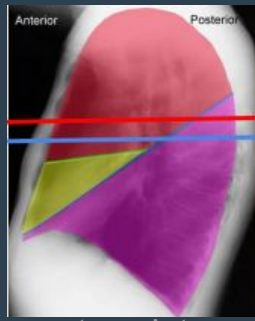
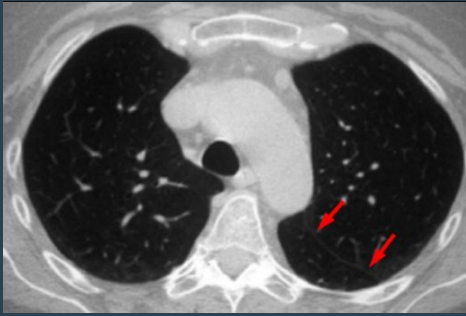
## » Lobes and Fissures

one of the landmarks for defining lobes of the lung is the interlobular septae

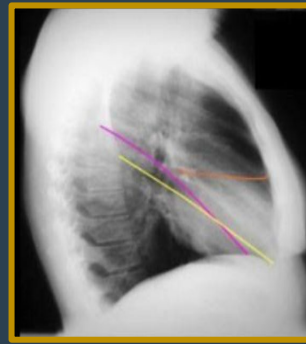
- On the PA chest X-ray, the transverse (minor) fissure divides the right middle lobe from the right upper lobe (marked A)
- The oblique fissures are usually not well seen on a PA view (marked B)
- If there is fluid in the lower lobe, it usually manifests as a density in the lower lateral margin
- Oblique fissures run from posterior to anterior aspects of the lung obliquely while the transverse is straight



# Chest Anatomy

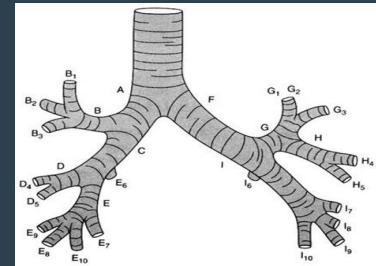


extra picture



extra picture

Pink: Left Oblique fissure  
Orange: horizontal fissure  
Yellow: Right Oblique fissure



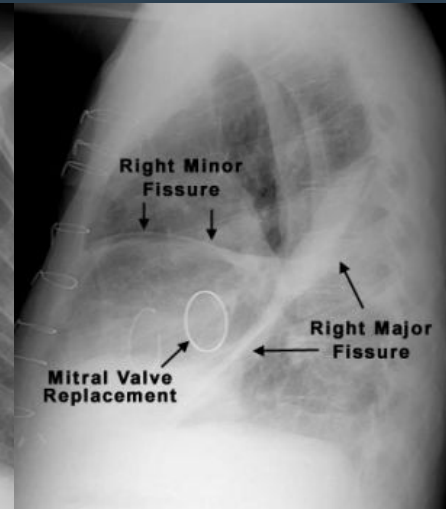
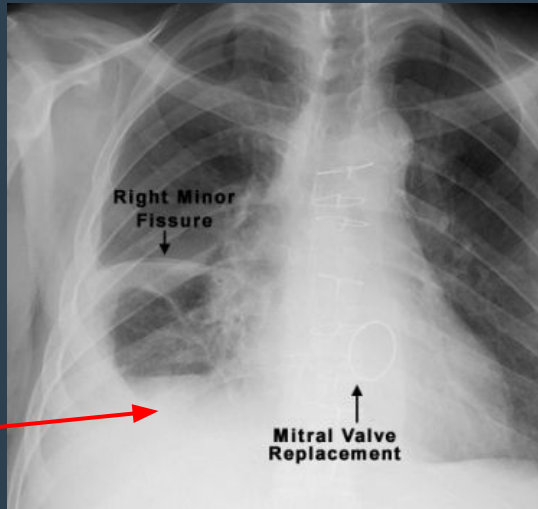
bronchial airway

- On a CT scan, the oblique fissure appears as a thin line from the most posterior aspect in the upper lobe and as you go down it moves toward the anterior aspect
- Redline shows the section that the CT was taken from

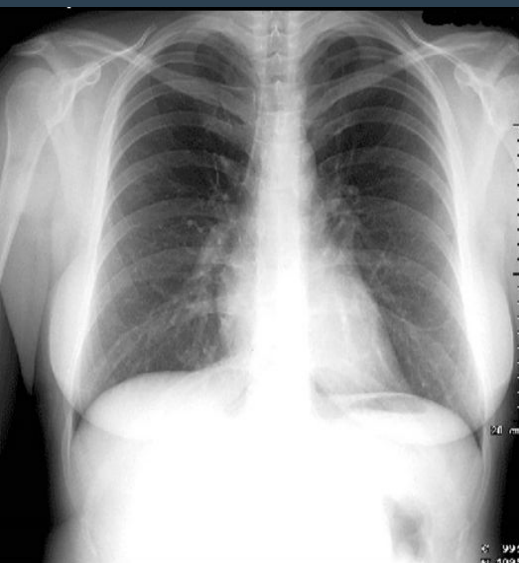## Case: HF with pleural effusion

we have here a cardiac patient with multiple valve prosthesis (mitral & tricuspid) and cardiomegaly & pleural effusion that finds its way through the lung fissures.

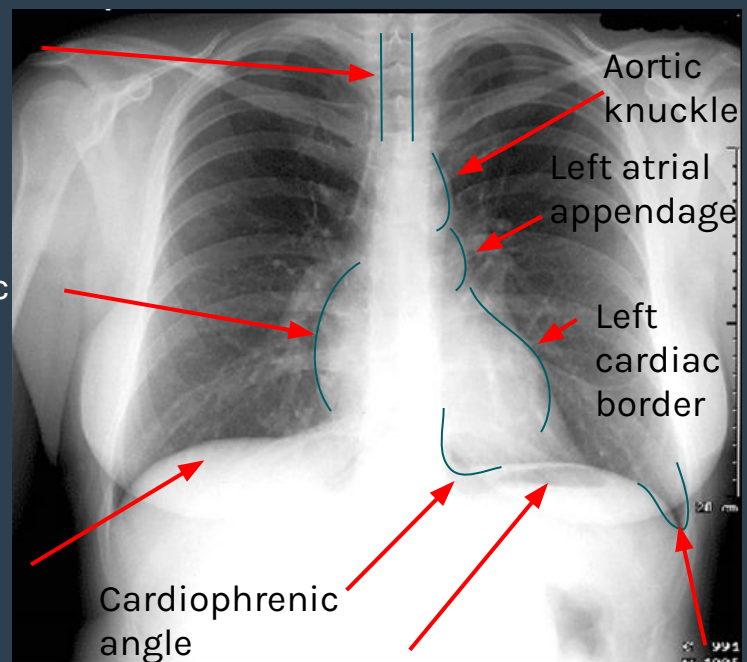
- Notice how the mediastinum is wide
- The pleural effusion extends into the right transverse fissure and to the right oblique fissure
- You can also notice that the right oblique fissure is thickened because of the fluid. (Pleural effusion)



## Mediastinum and Lungs



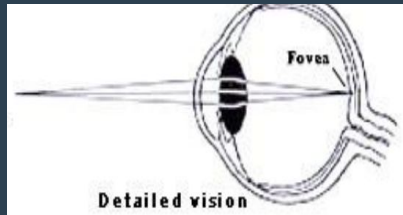

Paratracheal stripes  
Right cardiac border  
Right hemidiaphragm



Aortic knuckle  
Left atrial appendage  
Left cardiac border  
Costophrenic angle  
Left hemidiaphragm  
Cardiophrenic angle

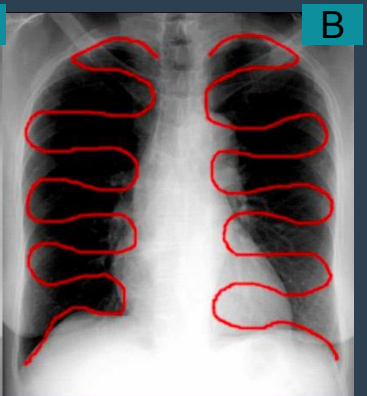
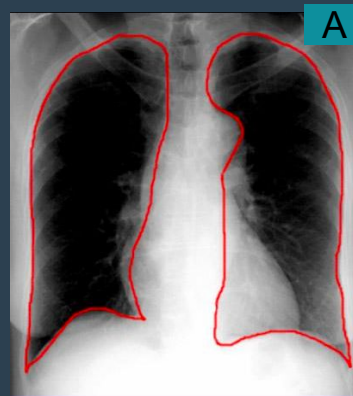
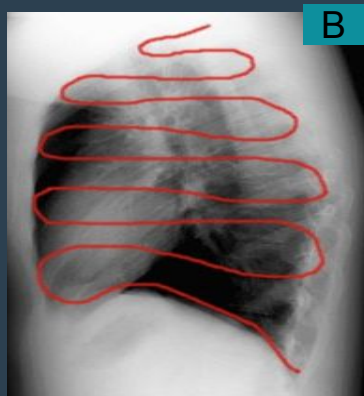
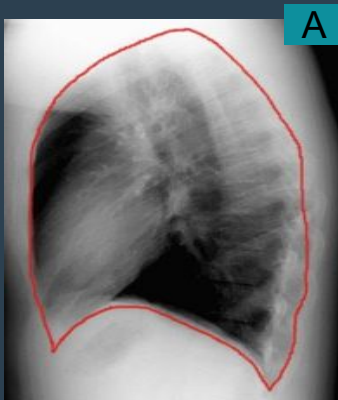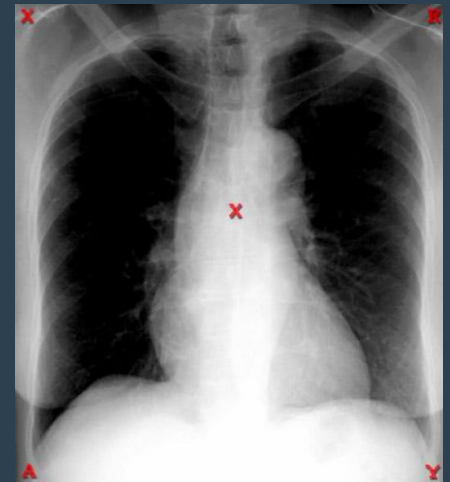


## » Looking for abnormalities



Your eye gaze should scan all portions of the film, follow lung/mediastinal interfaces and look again carefully in areas where you know that mistakes are easily made, such as over the spine on the lateral view and in the apex on the PA view.

Try to focus your gaze on the X, would you be able to read the letters in the corner?



pleural pulmonary interface (boundaries) (A)

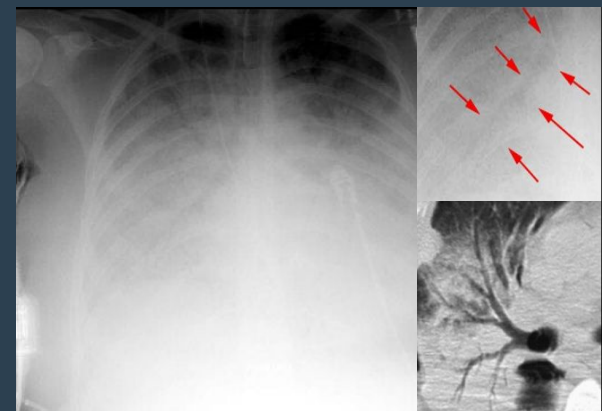
scanning entire lung following a zig zag pattern (B).

## » Air Bronchogram Sign

- Is a tubular outline of an airway made visible by filling the adjacent structures with fluid, exudate, pus, or blood
- Six diseases can cause an air bronchogram:
  1. Lung consolidation
  2. Pulmonary edema
  3. Non Obstructive atelectasis
  4. Neoplasm
  5. Severe interstitial disease
  6. Normal expiration
  7. pneumonia

### Examples

1. Bilateral lower lobe pulmonary edema makes the bronchi visible as an air bronchogram

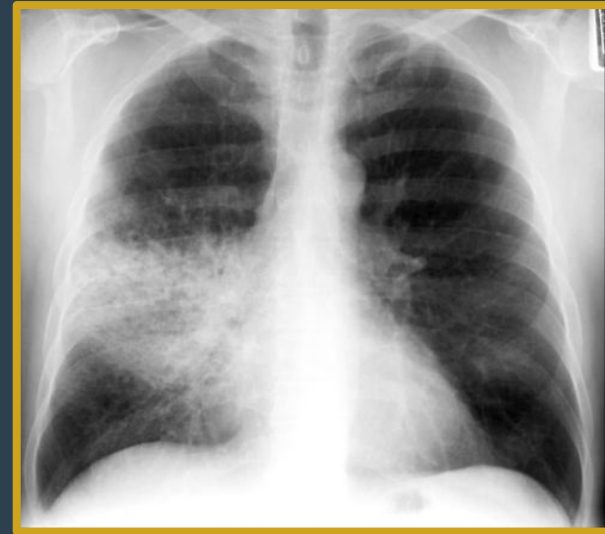

## » Silhouette<sup>1</sup> Sign

- Loss of lung/soft tissue interface caused by a mass or fluid in the normally air-filled lung.
- Which means if there was opacity in the lung in an anatomic contact with a structured border, the opacity will obscure the border
- This sign is commonly applied in the heart, aorta, and chest wall

### Examples

1. **Pneumonia** in the right middle lobe will obscure the right cardiac border (image)
2. The right hemidiaphragm will be silhouetted by a right lower lobe pathology



<sup>1</sup>shadow

You can Localizing disease from the **silhouette sign**:

Ex:

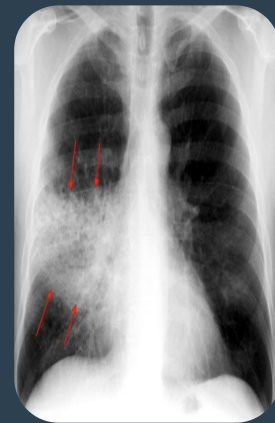
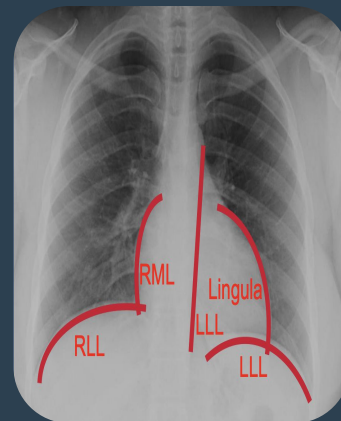
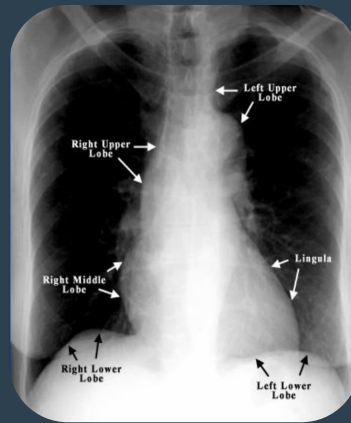
RLL → Diaphragm

RML → R heart border

RUL → Ascending Aorta

LUL → Aortic Arch

LLL → Left hemidiaphragm

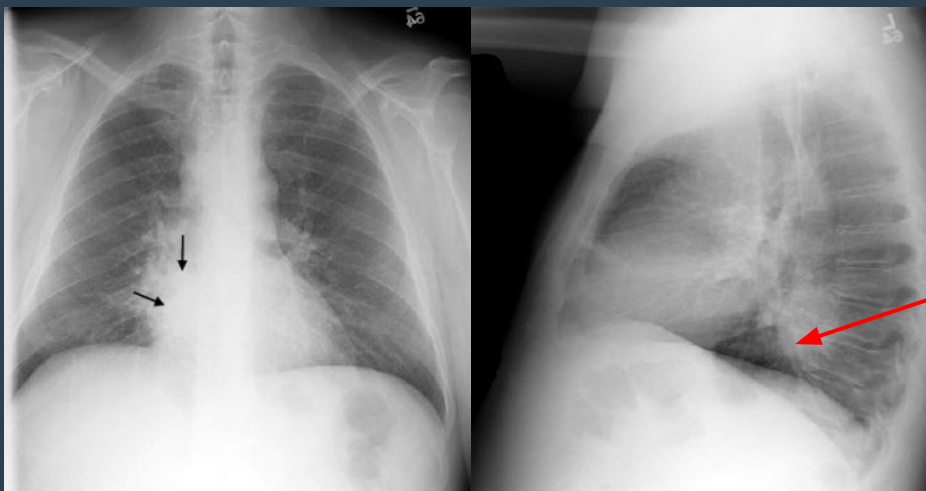

## » Double Border Sign

- You're only allowed to have one cardiac border

### Examples

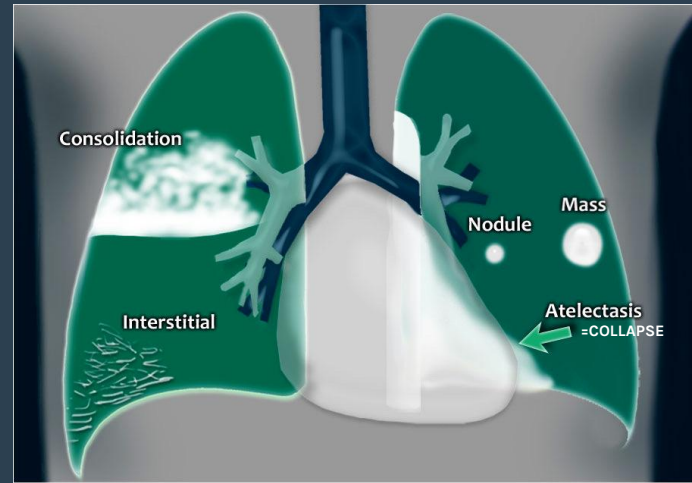
1. A problem posterior to the heart, mediastinum or lungs will show double cardiac border
  - a. The image shows a double right cardiac border which is very clear in the lateral view



Site of the pathology posterior to the heart (tumor)

# Lung Diseases

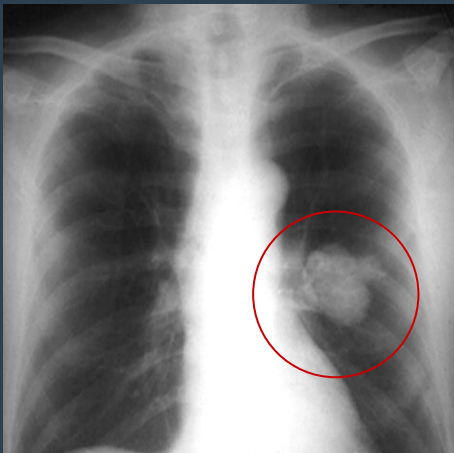
- ❖ Consolidation= pneumonia.
- ❖ Nodules= small. <3cm.
- ❖ Mass= large. >3cm.
- ❖ Atelectasis= lung collapse.
- ❖ Interstitial= diffuse lung disease.
- ❖ Air space disease= consolidation
  - fills already present air space
- ❖ Mass or nodule= starts as single cell And grow to push not replace causing (mass effect).



## ➤ Mass VS. Diffuse Infiltration

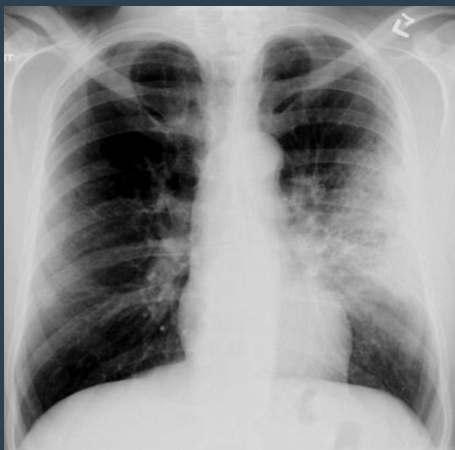
- ❖ The basic diagnostic instance is to detect an abnormality.
- ❖ In both of the cases, there is an **abnormal opacity**, left upper zone.

### Mass



- In this case, the opacity would best be described as a **mass because it Has edges well-defined (clear outline) 3D structure.**
- We can see the mass in PA and lateral views which prove the 3D nature of the mass.
- In lateral view appears oval like shape “3D”.

### Diffuse Infiltration



- In this case, has an opacity that is poorly defined (**Not clear outline**). This is airspace disease such as pneumonia (diffuse disease).
- Involve large space of the lung, flat and diffused.
- In lateral view there will be a change in its appearance.

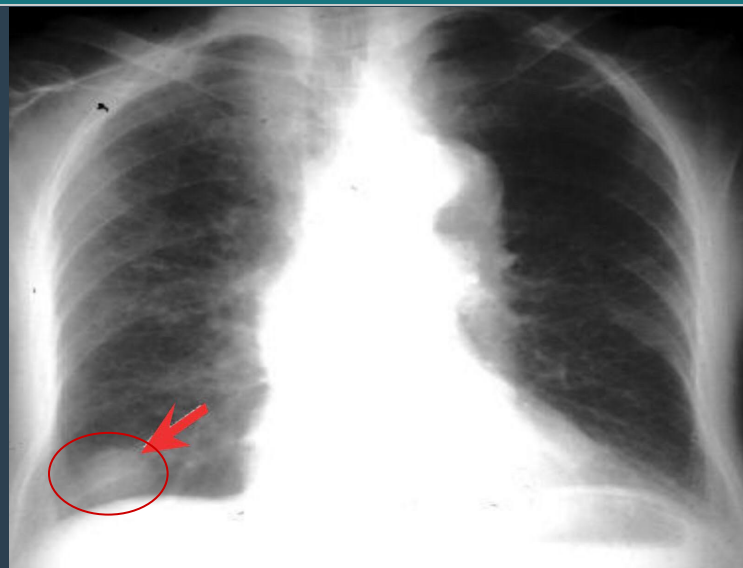
## » Solitary Nodule In The Lung

- 1 A solitary nodule in the lung can be totally innocuous "harmless" or potentially a fatal lung cancer.
- 2 After detection the initial step in analysis is to compare the film with prior films if available.
- 3 A nodule that is unchanged for two years is almost certainly benign.
- 4 Be sure to evaluate for the presence of **multiple nodules** as this finding would change the differential entirely.
- 5 If the nodule is indeterminate after considering old films and calcification, subsequent steps in the work-up include ordering a CT and a tissue biopsy.

X-Ray can't detect nodules smaller than 1 cm so we do a CT to:

- make sure it's solitary.
- To characterise the nodule further.

### Mass



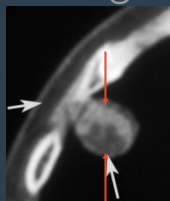Hamartoma

Well defined mass lesion .

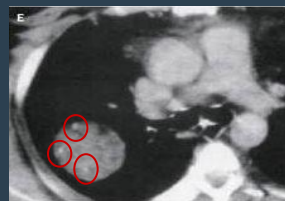If nodule is > 3cm it's a mass.

Mass: Rounded structure (contains fat and soft tissue in other segments).

CT scan help to characterize the mass and if it's benign or malignant.



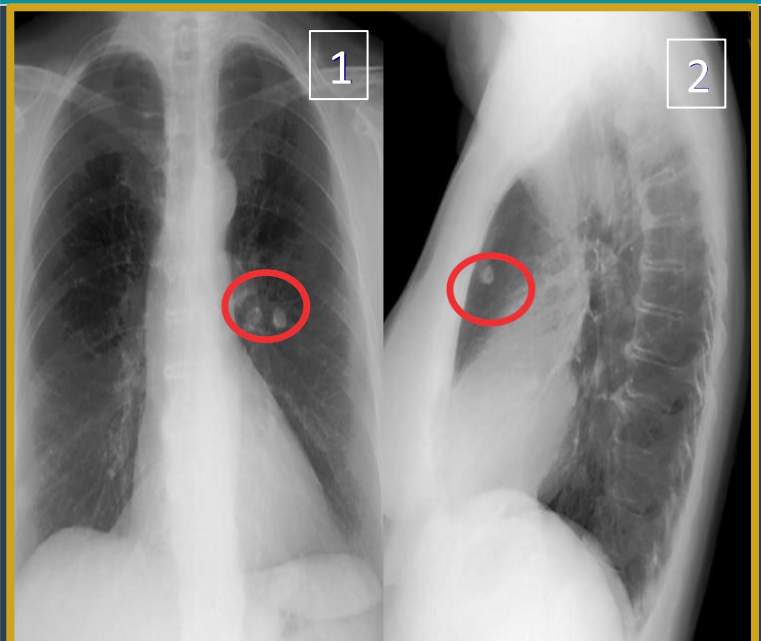
The dark area consists of Fat



Small calcifications

Trick: If the mass silhouette the hilum that means it's in the middle if not its in anterior or posterior. (Lateral view will further help in specifying the location).

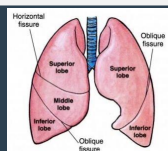
### Solitary Nodule



If you see Pic 1 you can tell that there is a small rounded lesion.. But is it a small infiltration or a mass lesion? We will do lateral view (Pic 2) and we will see the lesion in 3D, we can know what is the exact location of that nodule which is anterior lung solitary nodule.

So, in order to locate if it was anterior/posterior/middle we take lateral view.

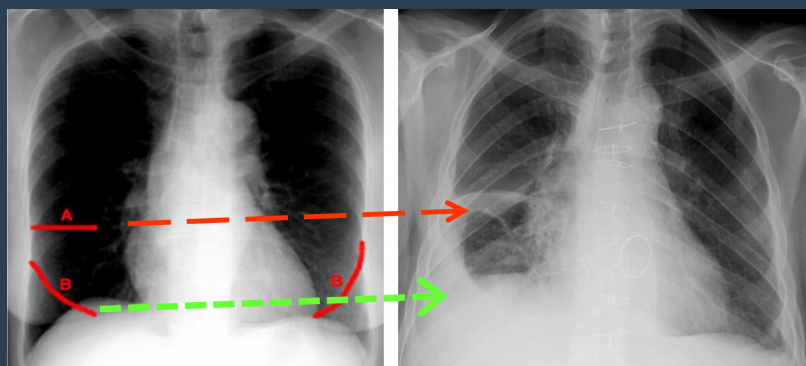
## » Fissures



❖ One of the most important things in lung X-Ray is the fissures: It has 2 benefits:

- 1 It shows us the lung anatomy (upper, middle, lower lobes)
- 2 The fissure are movable, if it moves up or down on x-ray it may indicates a pathology.

How to differentiate between fissures and vessels?  
vessels are branching, while fissures continue to the lateral side.



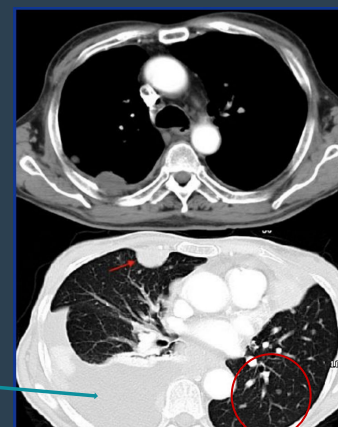
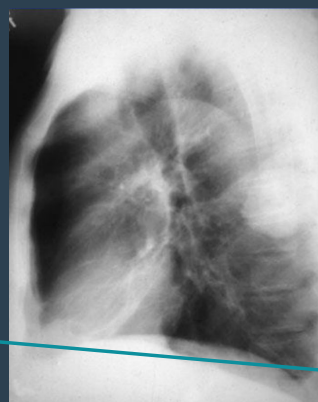
What is the most important sign for pleural effusion?  
**meniscus sign (C)** a crescent-shaped inclusion of air surrounded by consolidated lung tissue.

**Encysted pleural effusion** of transverse fissure (A) red arrow) and oblique fissures (B) green arrow), so when we see the pathology the fissure outlines becomes more clear and thick ( as they contain fluid in this case ).

## » Pleural based lesion metastasis

Metastatic pleural tumor is a type of cancer that has spread from another organ to the thin membrane (pleura) surrounding the lungs

Causing pleural effusion



Multiple pleural based lesions

## » Recognizing Air Space Disease (Alveolar Lung Disease):

Alveolar spaces are filled with...Something. (Replacement of volume → there is no volume loss in consolidation.)

Radiologist's report:

- “consolidation”
- “air space opacity”
- “fluffy density”
- “infiltrate”

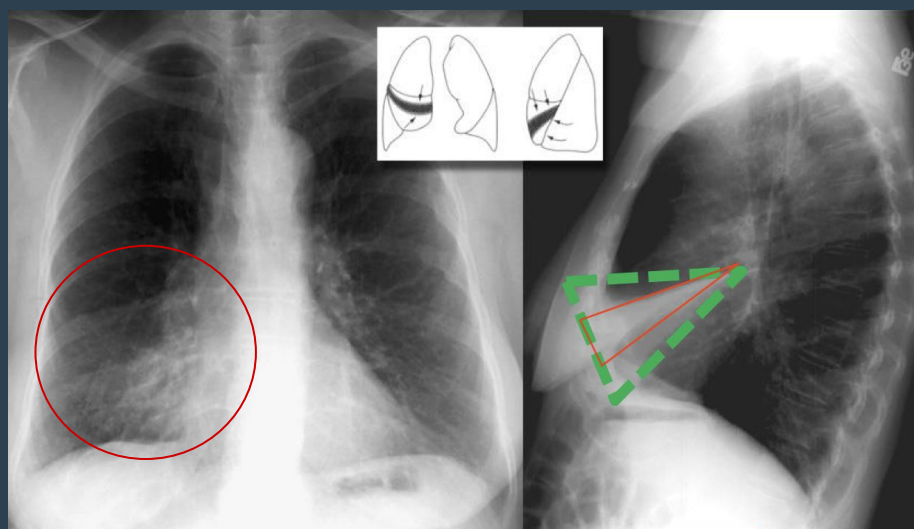
**Nonspecific:**

Atelectasis, pneumonia (infection so filled with pus), bleeding (Pulmonary hemorrhage in patients taking anticoagulants), edema (Heart failure), tumor, atelectasis

## ➤ Major differentiating factors between atelectasis and pneumonia

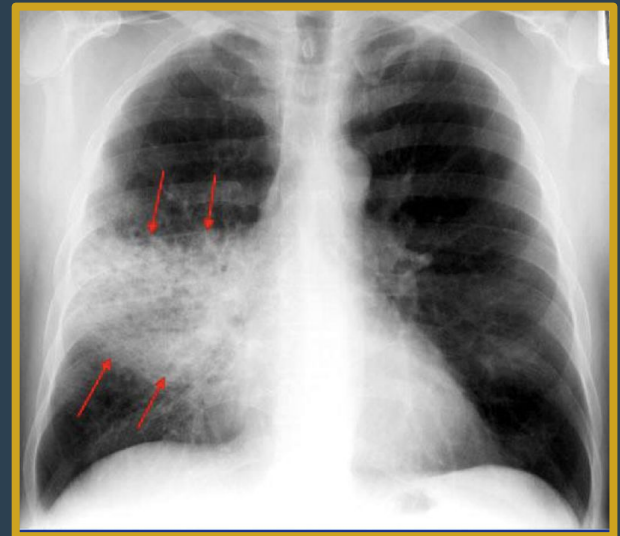
<b>Atelectasis</b> (Which leads to collapse)	<b>Consolidation</b>
<p><b>Loss of volume</b> of lobe, segment or sub segment of the lung.                      Because of <b>obstruction to the bronchus</b>.</p>	<p><b>Loss of air</b> in lobe, segment or sub segment of the lung.                      The air <b>is replaced</b> by something else</p>
<p>Example: <b>collapse</b> (lung)                      collapse of the lung if the obstruction is in the main bronchus.</p>	<p>Example: <b>pneumonia</b> (lobe)</p>
<p>Major differentiating factors between atelectasis and pneumonia:</p>	
<ul style="list-style-type: none"> <li>• <b>Volume loss.</b></li> <li>• Associated <b>ipsilateral</b> shift (trachea and pleura will try to fill the collapsed area).</li> <li>• <b>Linear</b>, Wedge-shaped.</li> <li>• Apex at hilum (points at hilum).</li> </ul>	<ul style="list-style-type: none"> <li>• <b>Normal or increase volume.</b></li> <li>• No shifting, or if present then <b>contralateral</b>.</li> <li>• <b>Consolidation</b>, Air space process.</li> <li>• Not centered at hilum.</li> </ul>
<p>Air bronchograms (fluid inside the bronchioles) can occur in both.                      Sometimes consolidation and collapse happens together but it's rare, so there will be loss of volume and some replacement of air.</p>	

## ➤ Atelectasis VS Pneumonia

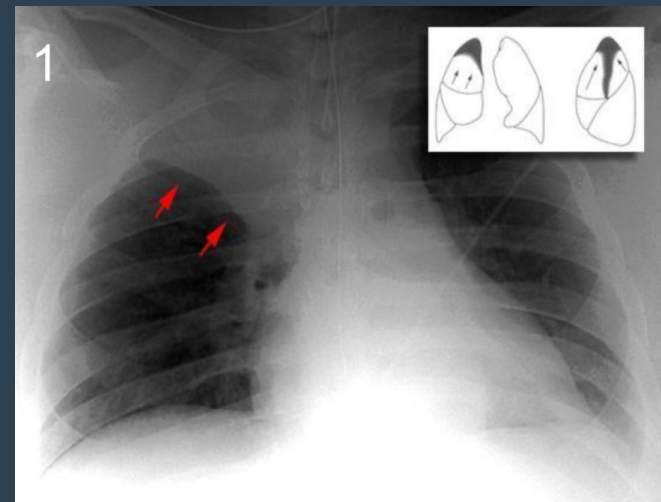


### Right middle lobe collapse

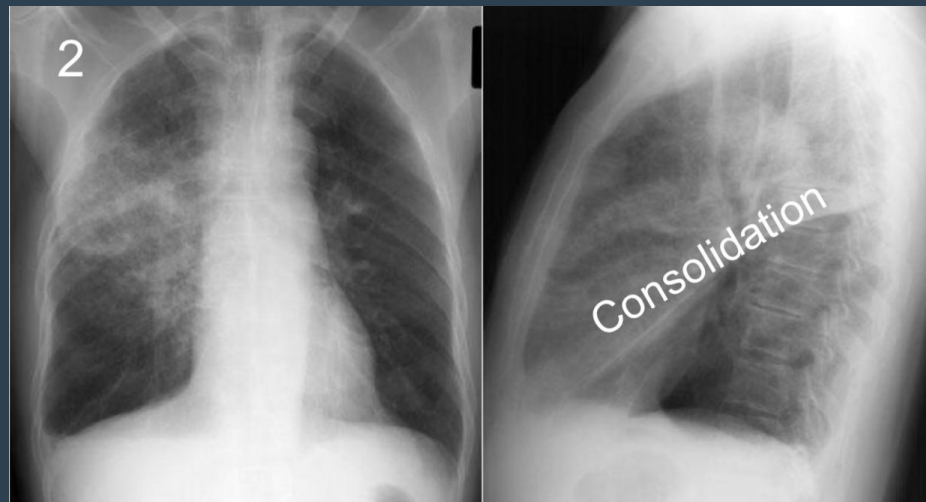
Opacity seen at the right mid zone silhouetting the right heart border.  
Lateral view: we can see triangular or wedge shaped structure with the apex toward the hilum.



Right middle lobe consolidation. Poor defined infiltration is limited by the horizontal fissure and silhouetting the right heart border with central lucency (this could be air bronchogram).



**Pic 1:** chest x-ray shows consolidation in the right upper lobe and very clear line (red arrow) which represents the transverse fissure, these findings indicates upper lobe atelectasis.



**Pic 2:** diffuse area of consolidation in PA view, we don't know if there is loss of volume or not, so we will do lateral view. And the lateral view shows normal location of oblique fissure, so the area of consolidation that involves the upper and middle lobe is pneumonia (normally we don't see the oblique fissure this clear, but because of white contrasting pneumonia in the upper lobe, it will be obvious).

## ➤ Lobar Atelectasis

- ❖ Best sign is → Shift of a fissure.
- ❖ Rapid development and clearance. Unlike pneumonia the opacity persist for days.
- ❖ Air bronchograms if non-obstructive
- ❖ Secondary signs:

Air bronchograms means fluid inside the bronchioles, if there is obstruction in the level before the bronchioles, the fluid will not be able to reach it, so this sign will not be obvious.

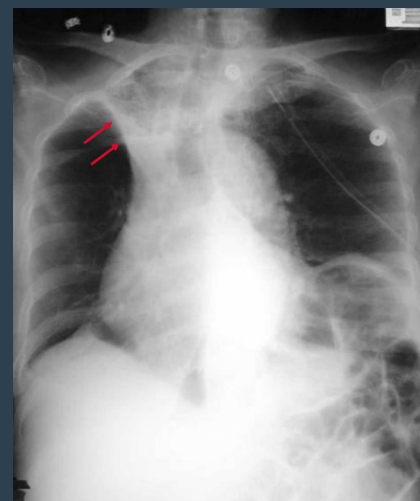
- 1 Mediastinal shift 
- 2 Elevated diaphragm 
- 3 Ribs closer together 
- 4 Vague increased density 

All these 4 signs because of volume loss.

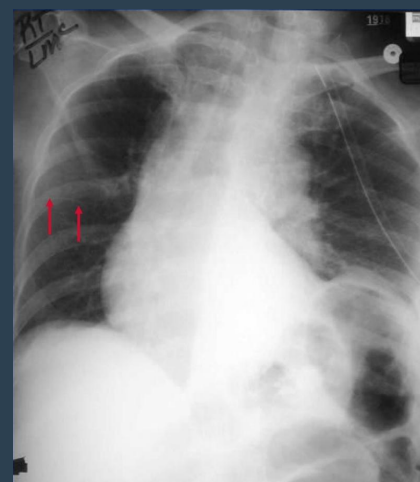
## ➤ Right Upper Lobe Atelectasis

1: A patient presented with fever, they put endotracheal tube and after that, he got dyspnea and after that a chest x ray was done. They found: **right upper lobe atelectasis.**

Shift of a fissure

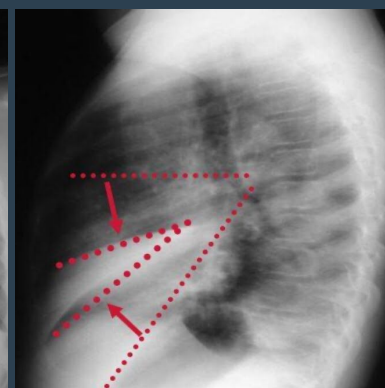
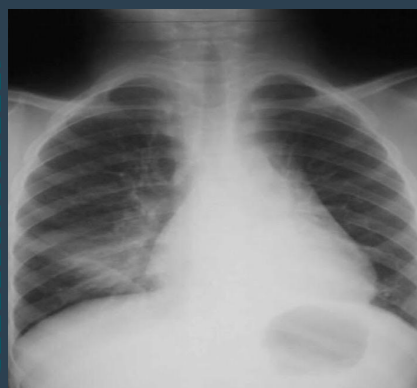

2: The patient took antibiotic and the proper treatment. They also removed the tube and they did follow up chest X-ray. They found the transverse line came back to its normal position.



## ➤ Right Middle Lobe Atelectasis

As far as I know there is 2 pathologies here: right middle lobe collapse and right lower lobe consolidation. In the middle area of the right lung there is opacity (consolidation), is it collapse? We did lateral view and **we can see that the transverse and oblique fissures moved from their normal position which indicates right middle lobe atelectasis.**

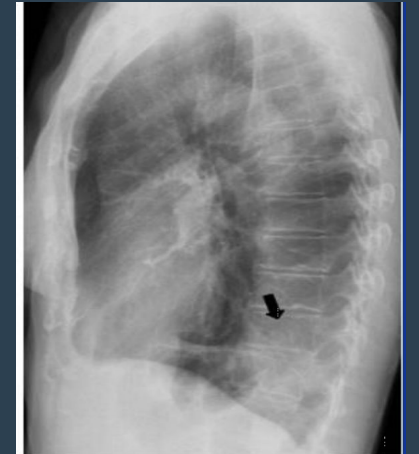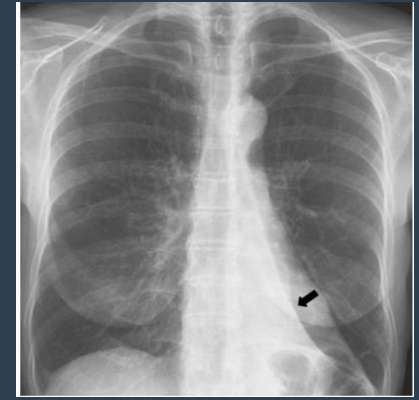




## » Left Lower Lobe Atelectasis

Atelectatic left lower lobe silhouette the left hemidiaphragm:

- Well defined border, marginated by fissure.
- Volume loss because the fissure shifted medially.
- Points toward the hilum.
- The lungs are filled of air and also the bronchi, we can't see bronchial tree because it's also filled with air as the lungs, so both appear in black color while vessels appears in white because it is filled with blood.
- In case of pneumonia it appears as consolidation of lungs. The air is replaced by fluid or inflammatory cells. However, the Bronchial tree remains as it is patent so we will be able to see bronchial tree on background of consolidation.



Positive spine sign.  
Opacity overlying the spine



wow, such empty

## » Pneumonia

### ❖ Signs

#### 1 Air bronchogram sign

It's either collapse or consolidation

#### 2 Silhouette

Positive or negative

#### 3 Dense Hilum

#### 4 Spine sign

Dorsal spine sign

❖ All are signs of any air space process.

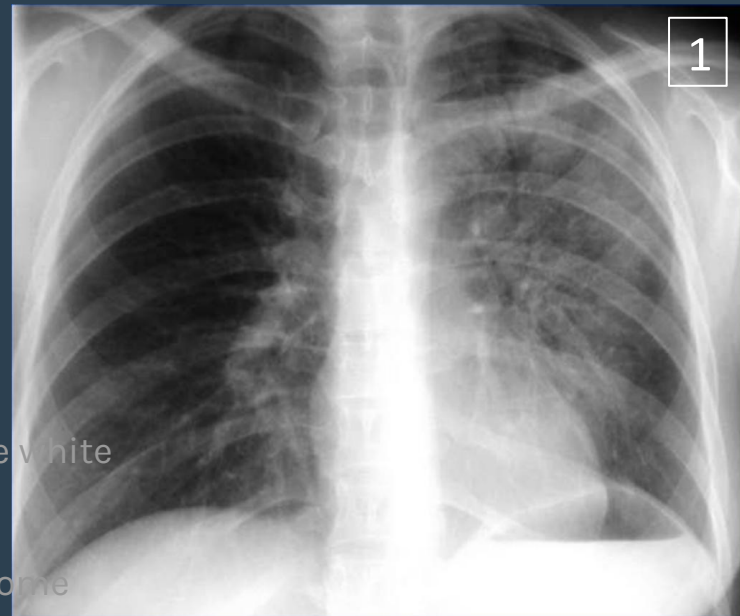
❖ Dx of pneumonia Depends on appropriate clinical scenario.

## » Air - Bronchogram It is a sign not a modality

**Pic1:** The Right lung is normal; no obvious bronchial tree, all air spaces in normal lung will have the color black on x-ray because it contains air and also bronchial tree will appear black because it contains air.

In the Left lung there are very thin like lines "hair branching lines" which is bronchial tree called AIR-BRONCHOGRAM.

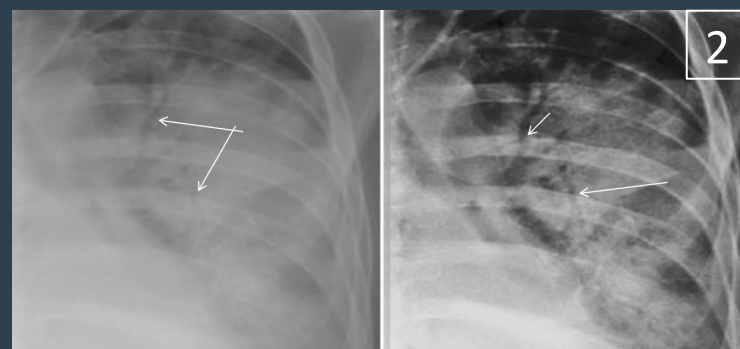
If there is pneumonia (left lung) the lung will be white in color because the air can't go through the lung spaces and alveoli, but we may see bronchi in some cases because the bronchi are not affected.



### **Pic2:** Air bronchogram sign

- Air consolidation in the right upper lobe and we can see some dark grey lines on x-ray (arrows) which represent the the bronchial tree.

- AIR-BRONCHOGRAM very clear it's a sign of pneumonia.

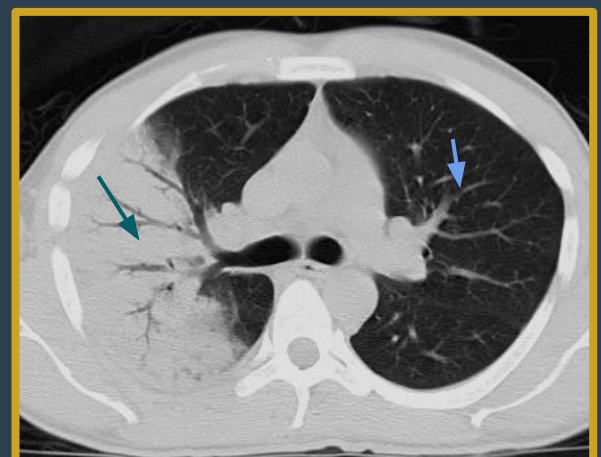


## » Air Bronchograms - CT

green: bronchi    blue: vessels

The Left side is completely healthy lung and we can't see the bronchial tree clearly because the whole lung contains air and the bronchial tree contains air so they will be all black.

The Right diseased lung we see consolidation caused by loss of air in the lung so it will be white, but the bronchial tree is still have some air so it will be back.



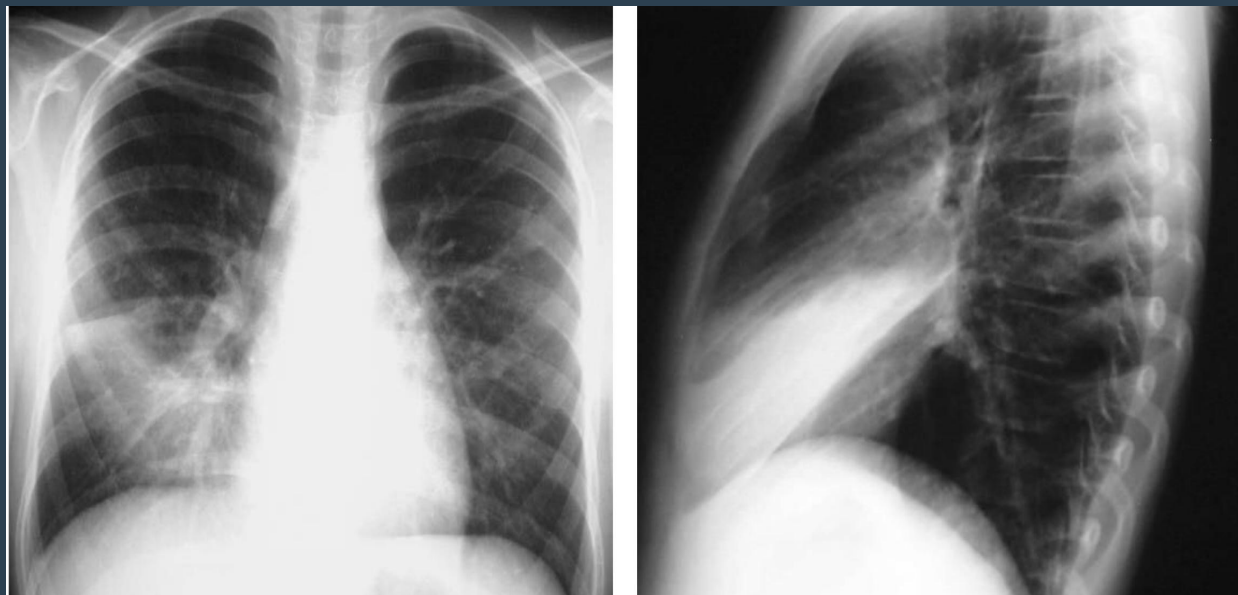
Pseudomonas pneumonia

Collapsing Pneumonia

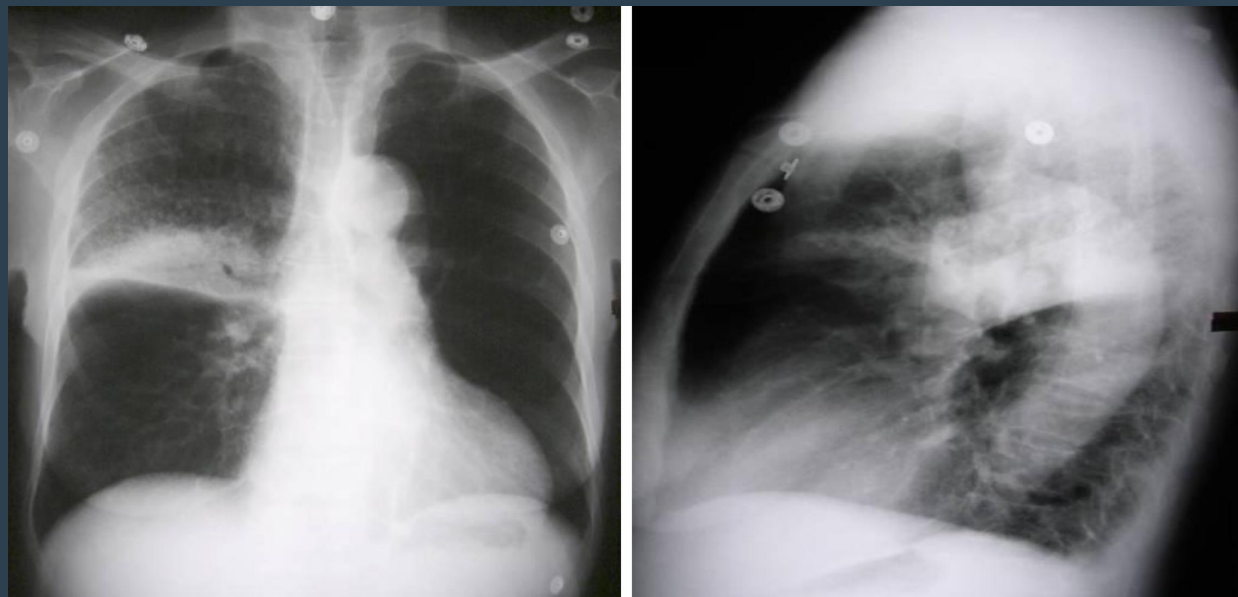
Remember this is lung window:)

# Pneumonia

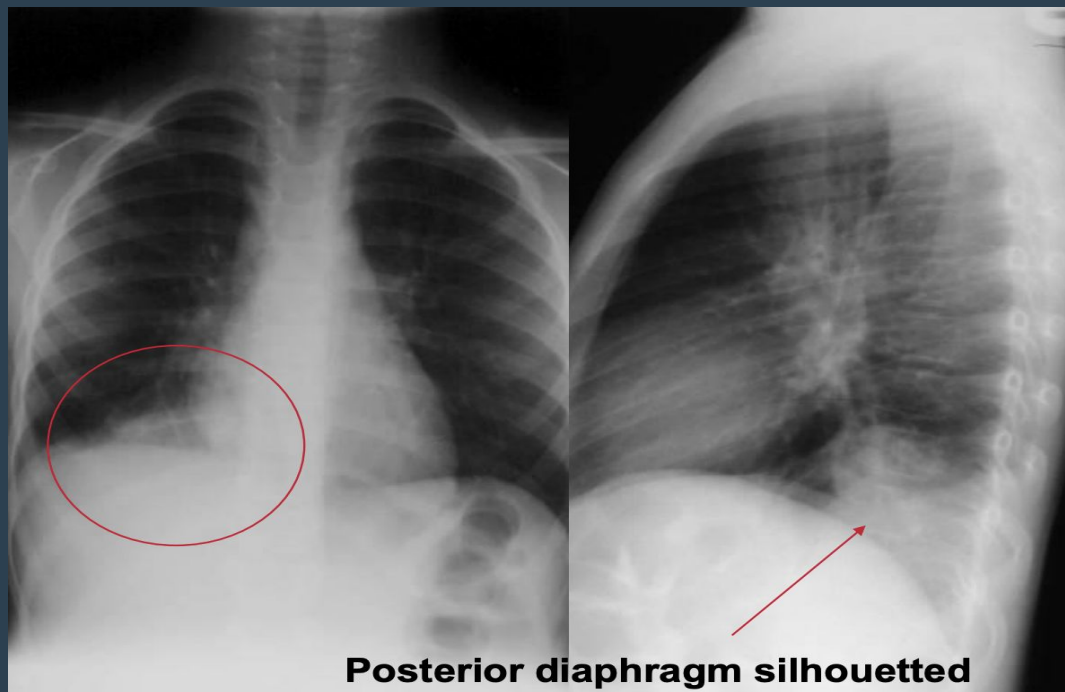
## Right Middle Lobe



## Right Upper Lobe



## Right Lower Lobe



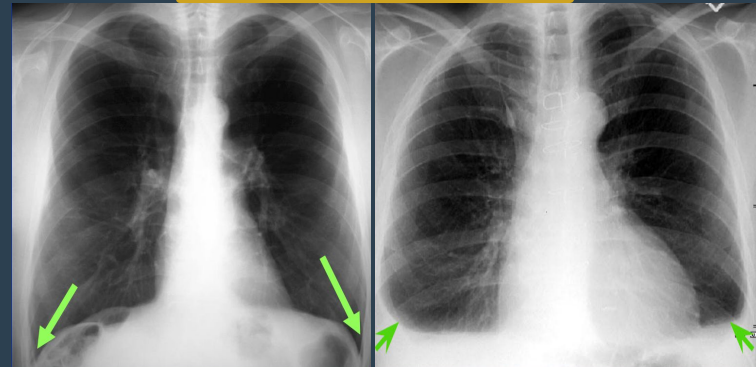
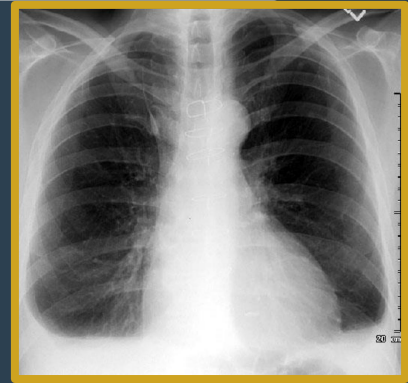
Posterior diaphragm silhouetted

# Pleural Effusion

## » Pleural Effusion

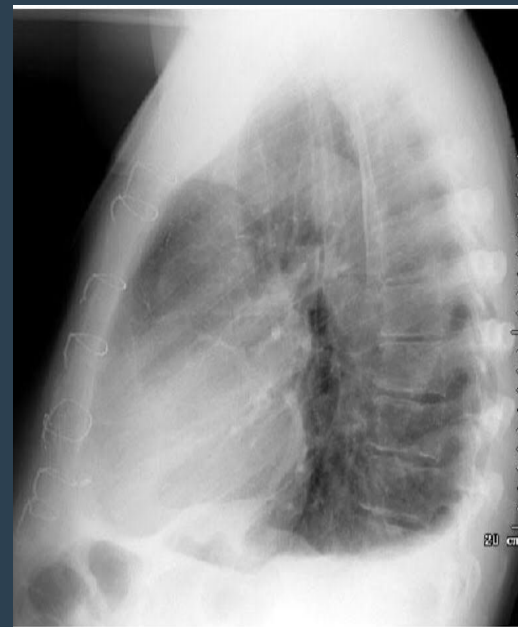
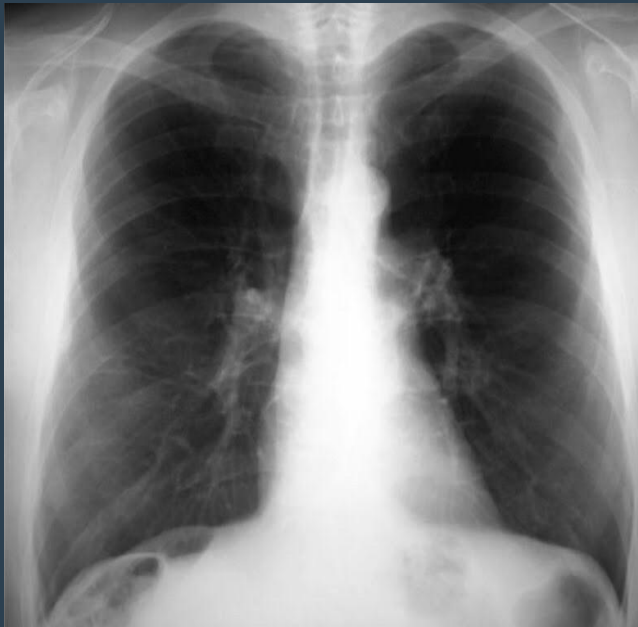- ❖ what is pleural effusion?  
we have little **fluid** in the pleural cavity.

In normal image of chest we are suppose to see costophrenic angle peaks but once there is a fluid in the pleural cavity it causes blunted costophrenic angle. So we have bilateral costophrenic angle blunting.



Normal costophrenic angles (sharp)      Blunted costophrenic angles

## » Compare Costophrenic angles



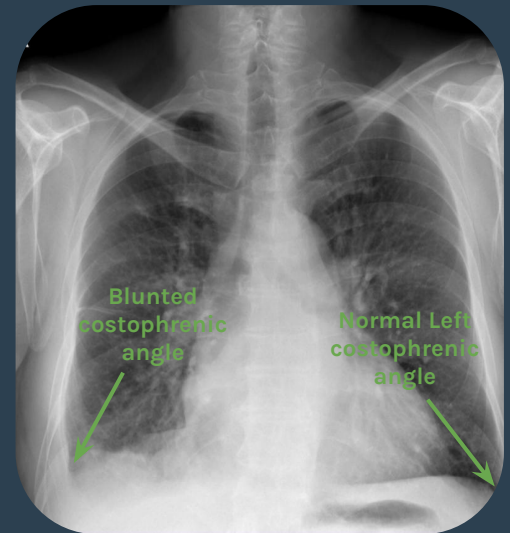
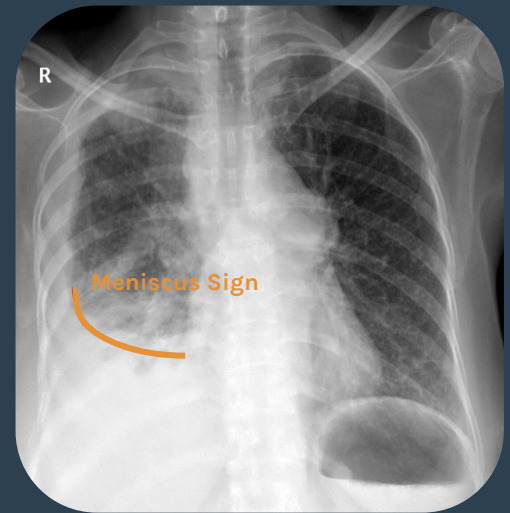
- On an upright film, an effusion will cause blunting on the lateral and if large enough, the posterior costophrenic sulci.
- Sometimes a depression of the involved diaphragm will occur.
- A large effusion can lead to a mediastinal shift away from the effusion and opacity the hemithorax.
- Approximately 200-250 ml of fluid are needed to detect an effusion in the frontal film vs. approximately 50-75ml for the lateral.
- Larger effusions, especially if **unilateral**, are more likely to be caused by **malignancy** than smaller ones.

# Pleural Effusion

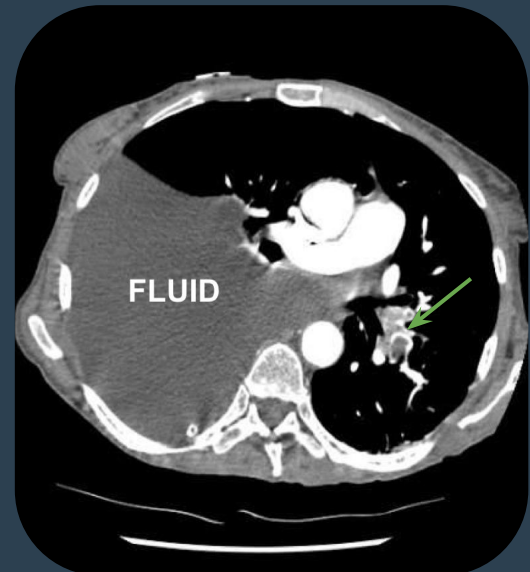
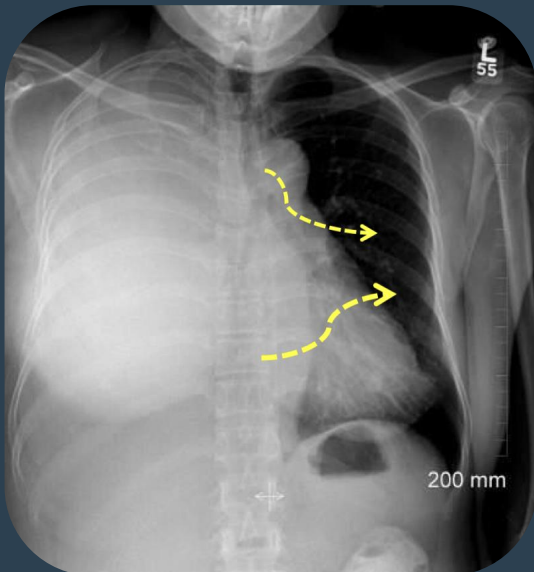
- Once fluid increase it goes up in curve line level (**Meniscus Sign**), it is not like a cup of water with flat line level.

## Team 436:

- The doctor mentioned an experience in school we used to do it, we bring cup of water half empty when we see it from outside we see fluid level in flat line, but if we cover and sucked air inside it it goes up in curve line.  
→ because there is no air & no pressure so it will be curved.
- Always fluid in costophrenic angle given curve line however this is mild or moderate pleural effusion.
- If we have mild pleural effusion we will get curve like in lower figure, if we have moderate pleural effusion we will get like the upper figure.



## Sever Pleural Effusion



- **Unilateral pleural effusion.**
  - Think of malignancy.
  - The reason for this massive heart & mediastinal shift is the massive fluid accumulation.

- **CT-scan:**
  - Fluid density filling the right hemithorax, compressing the major vessels & the heart toward the other side.
  - **Green arrow:** notice that the artery is blocked with thrombus.

## Pneumothorax

- ❖ A pneumothorax is defined as **air** inside the thoracic cavity but outside the lung. **Could be spontaneous or traumatic or due to lung pathology.**
  - A spontaneous pneumothorax is one that occurs without an obvious inciting incident.

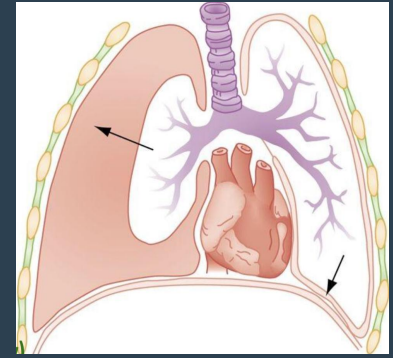
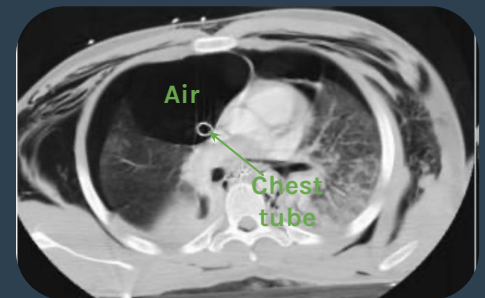
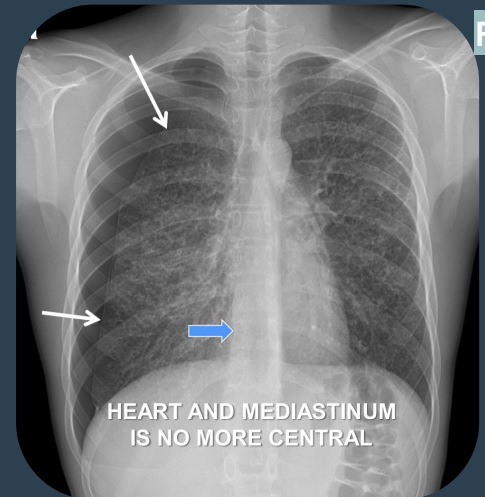


Fig. 1

- **Fig. 1 Right pneumothorax:**
  - It shows **increased lucency** outside the lungs with **no vascular marking inside.** There will be loss of lung markings (blood vessels) and it will appear as extremely black structure.
  - The most important sign: **Pleural lines** of the lungs, which is a very clear outline by the free air in the pleural cavity (**White arrows**).
  - The lungs is compressed a little bit with middle mild shifting of the mediastinum structures to the other side (**Blue arrow**).



- **Fig. 2 Tension pneumothorax (clinical emergency):**
  - Massive compression of the lungs.
  - More shifting of the mediastinum and the heart to the other side.
  - Left pneumothorax (no lung margin).
  - There is a flattening of the left hemidiaphragm (the normal hump is lost)
  - There is widening of intercostal spaces (**when you do examination you will hear the chest hyperresonance + decrease chest expansion**).

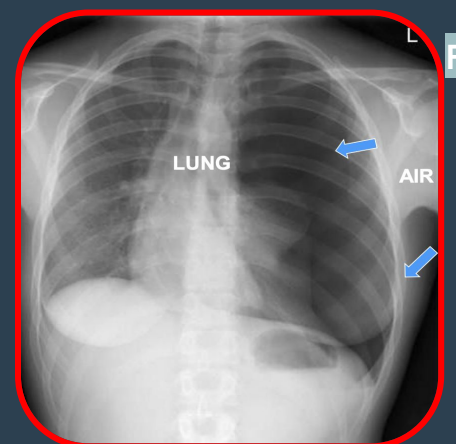
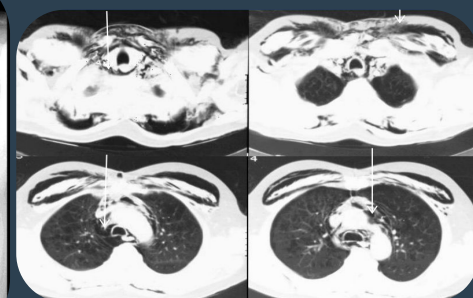
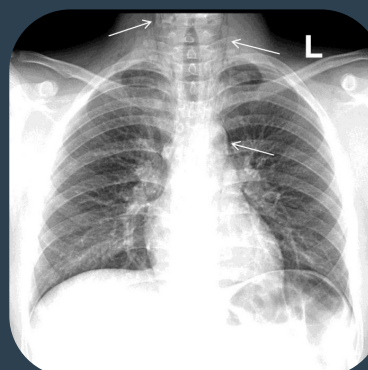


Fig. 2

Tension pneumothorax

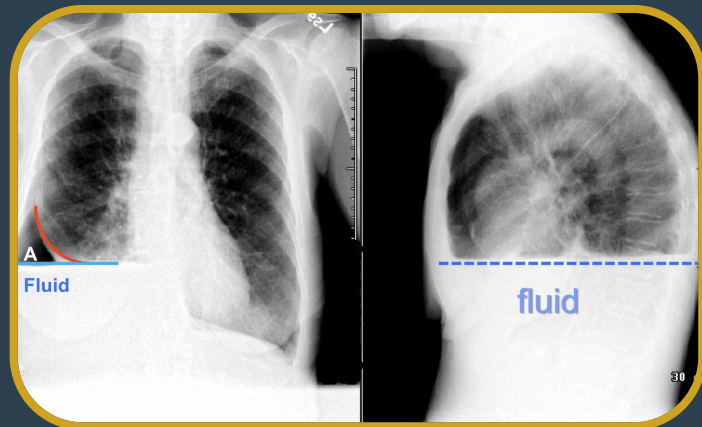
## Pneumomediastinum

- ❖ It's the abnormal presence of air or another gas in the mediastinum. Could be spontaneous or because of trauma (e.g. tracheal injury, esophageal perforation) or leakage from the lungs or windpipe.



## Hydropneumothorax

- ❖ The presence of both air and fluid within the pleural space (**pleural effusion + pneumothorax**).
- When will have air fluid level appears flat as this image?
  - In Hydropneumothorax.**
  - No meniscus sign because of the air pressure (Remember the example of covered cup filled with fluid).
  - **We have three things in the right side: air-fluid level, above it jet black air so we have fluid, air and the lung.**
  - Hydropneumothorax can be a complication of TB or AIDS.



## Emphysema

- ❖ Emphysema is **loss of elastic recoil of the lung** with destruction of pulmonary capillary bed and alveolar septa.
- **It's caused most often by cigarette smoking and less commonly by alpha-1 antitrypsin deficiency.**

### Signs

1

Increased Lung Volume:

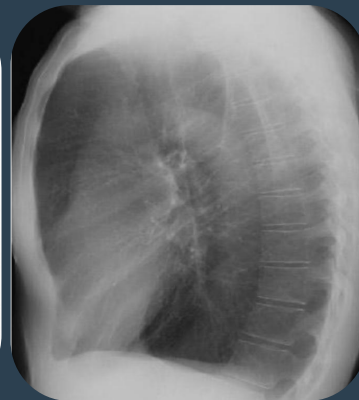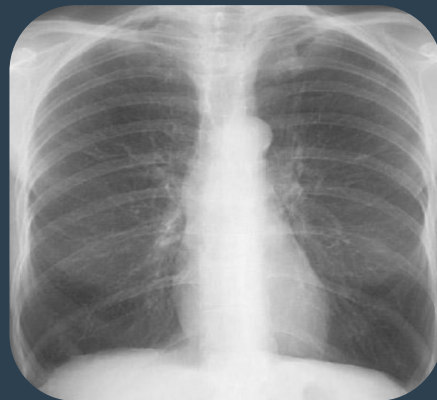- Flattened Diaphragm.
- Increase in Retrosternal Airspace.
- Barrel chest.

2

Small vessels

3

Small, narrow cardiac shadow



We usually see 8-10 ribs but here we can see more than 10 ribs (11) due to **hyperinflation**.

### Emphysema is commonly seen on CXR as:

- Diffuse hyperinflation with flattening of diaphragms.
- Increased retrosternal space, bullae (lucent, air-containing spaces that have no vessels that are not perfused).
- Enlargement of PA/RV (secondary to chronic hypoxia) an entity also known as cor pulmonale.
- Hyperinflation and bullae are the best radiographic predictors of emphysema.

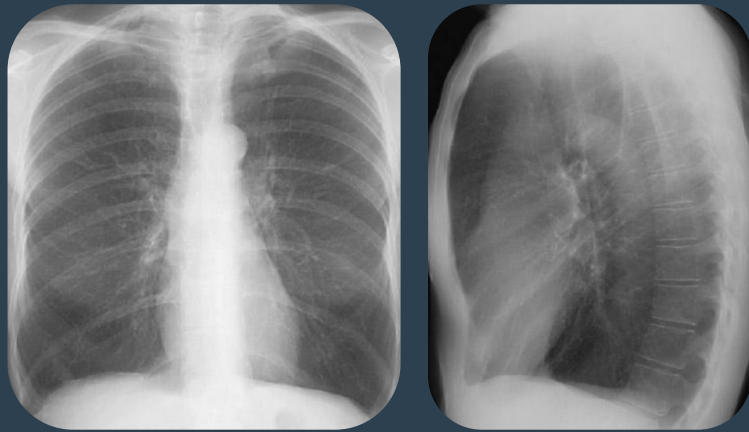
### Clinical signs of emphysema:

- 1) Shortness of breath
- 2) Cyanosis

# Emphysema & Giant Bulla

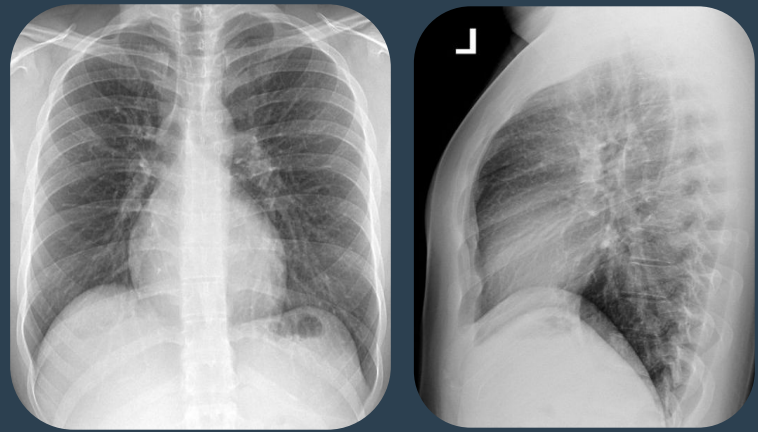
## » Emphysema

### Emphysema



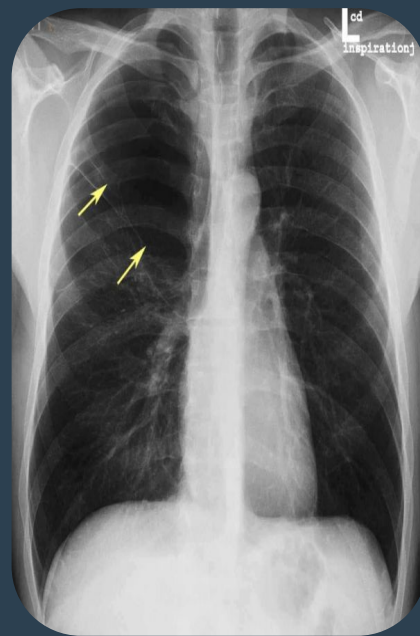
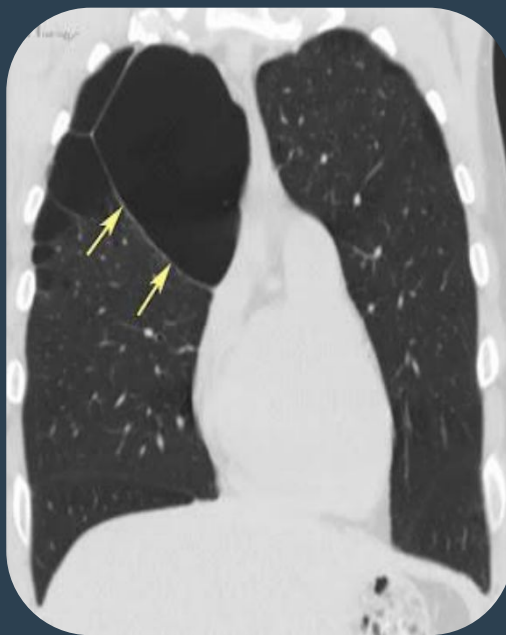
- Diaphragmatic cupola flattened.
- Heart decrease in size.
- Retrosternal air increased.
- Barrel chest.

### Normal



- Normal curved diaphragmatic cupola.
- Normal sized heart.

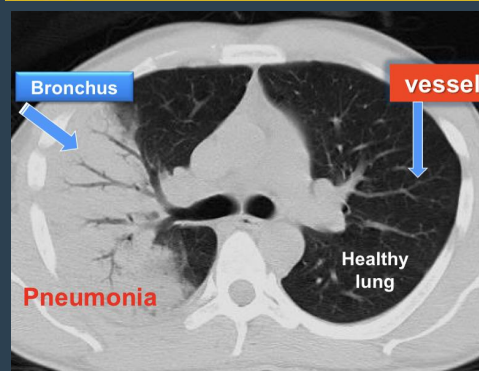
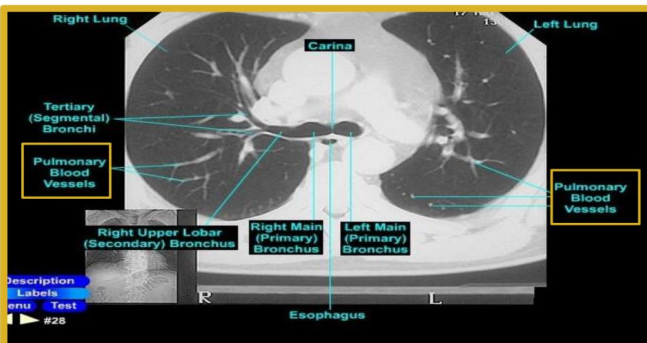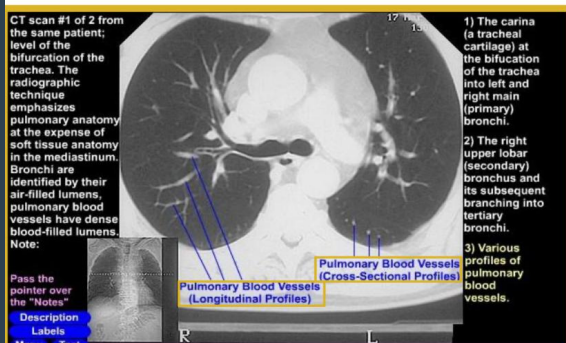
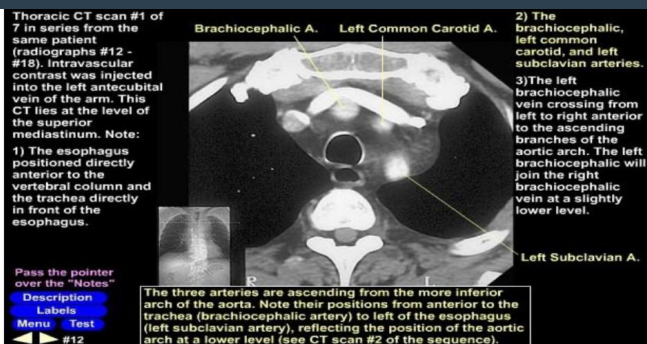
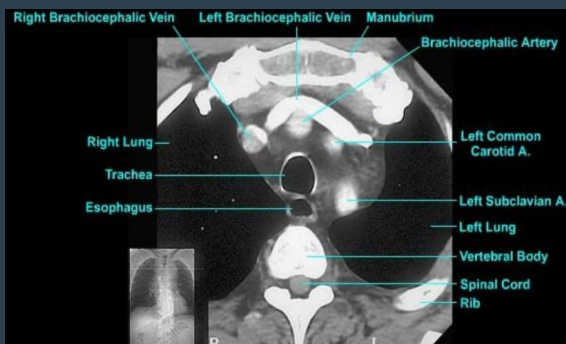
## » Giant Bulla



- A **giant bulla** is a complication of emphysema.
- In areas of the lung completely damaged by the disease, air pockets can develop. These areas threaten the patient's health not only because of the underlying emphysema.
- As a bulla grows, it takes up space in the chest cavity and can encroach on the lungs.
- **complications:** pneumothorax and superinfection, and It can cause compressive atelectasis of the adjacent normal lung parenchyma



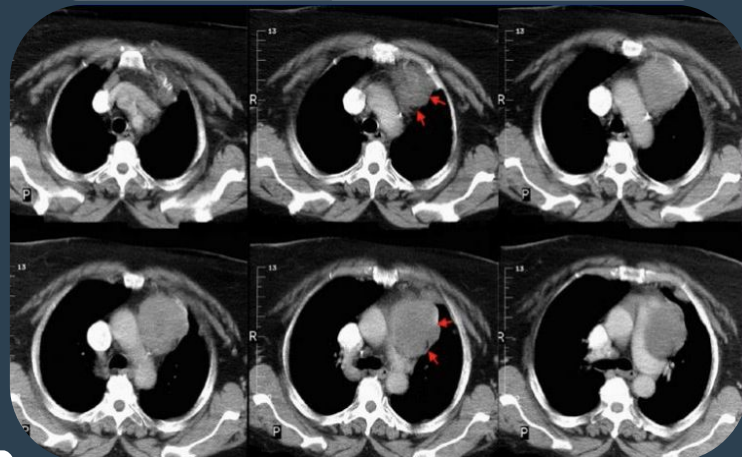
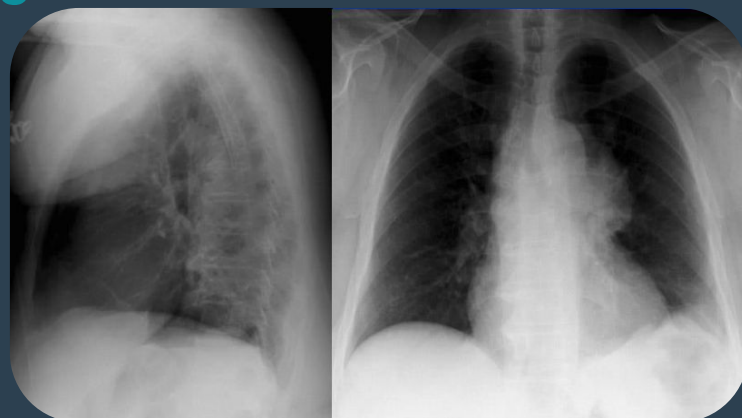
## CT Anatomy



Air bronchograms – CT

## Anterior Mediastinal Mass

- Anterior mediastinal masses consist of the 4 "T's"
  1. Terrible lymphadenopathy
  2. Thymic tumors
  3. Teratoma
  4. Thyroid mass
- Usually CT or fine needle aspiration is needed to make the definitive diagnosis of an anterior mediastinal mass.



## Case 1. Tension Pneumothorax

- **History:**  
27-year-old woman with chest tightness and shortness of breath presents to the Emergency Department.
- **Findings:**
  - Initial chest radiograph (Fig. 1.1) clearly demonstrates increased lucency in the right hemithorax with minimal displacement of the right hemidiaphragm inferiorly and shift of the mediastinum left ward. Note the increased distances between the ribs on the right, compared with those on the left. The right lung is partially collapsed.
  - Visceral pleural surface (white arrows in Fig. 1.2) can be seen as a thin white line, allowing distinction from a skin fold. No pulmonary vessels are seen lateral to the pleural line. The anterior junction line (black arrow in Fig. 1.2) is also displaced left ward.

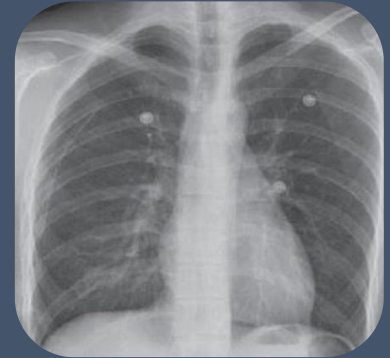


Fig. 1.1

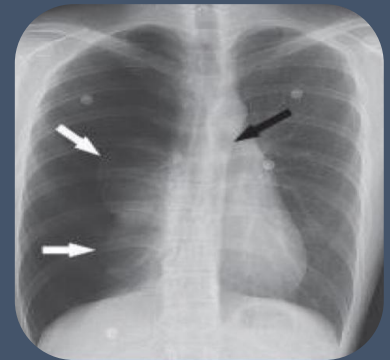


Fig. 1.2

## Case 2. Pneumothorax with Deep Sulcus Sign

- **History:**  
19-year-old man after a motor vehicle collision is imaged in the trauma suite.
- **Findings:**
  - Supine radiograph (Fig. 2.1) shows increased lucency at the left base, but no pleural line is seen. The left costophrenic sulcus extends more inferiorly than the right. Wires represent ECG leads overlying the patient.
  - Follow-up abdominal CT (performed because of the history of trauma) and upright radiograph confirm the small pneumothorax (black arrows in Fig. 2.2).

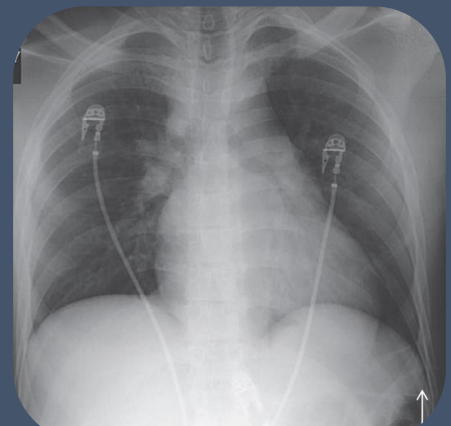


Fig. 2.1

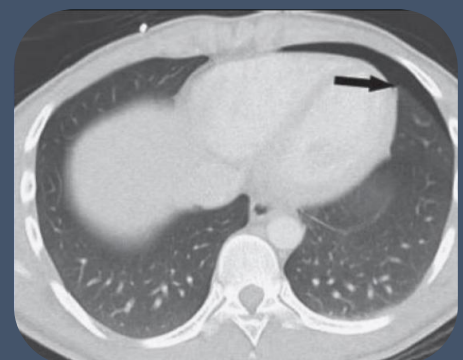


Fig. 2.2

## Case 3. Spontaneous Pneumomediastinum

- **History:**  
22-year-old man complains of severe sudden onset of chest pain.
- **Findings:**
  - Chest radiograph shows lucency adjacent to the left heart border (arrow in Fig. 3.1) on the frontal radiograph. Increased lucency is also seen around the aortic arch and in the right paratracheal region.
  - On the lateral radiograph, the anterior wall of the trachea is very well seen (arrow in Fig. 3.2). Gas is also seen anterior to the ascending aorta.
  - CT (Fig. 3.3) confirms the presence of gas centrally without fluid or evidence of tracheal rupture.

Fig. 3.1

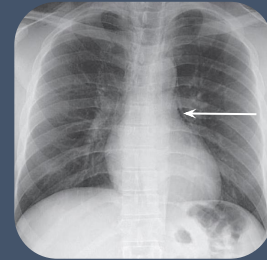


Fig. 3.2

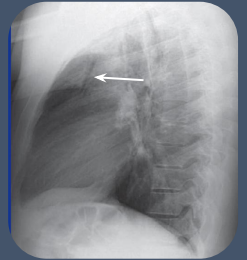
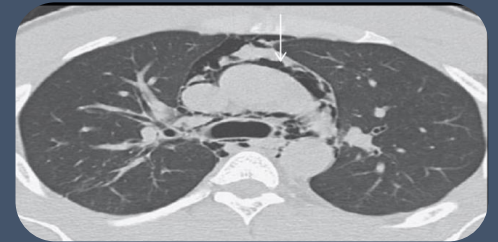


Fig. 3.3

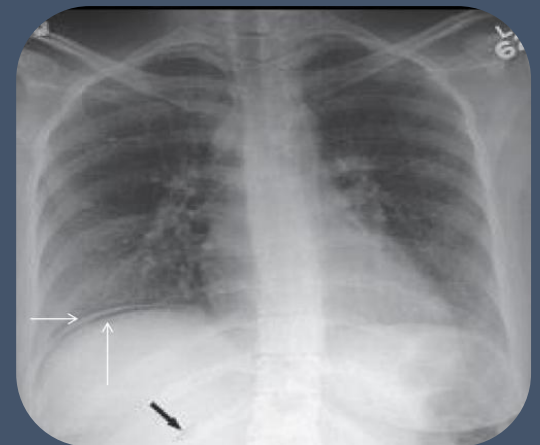

## Case 4. Pneumoperitoneum (from a Perforated Ulcer)

- **History:**  
26-year-old woman presents with sudden onset of chest and shoulder pain.
- **Findings:**
  - Chest radiograph shows a crescentic lucency below the right hemidiaphragm (Fig. 4.1).

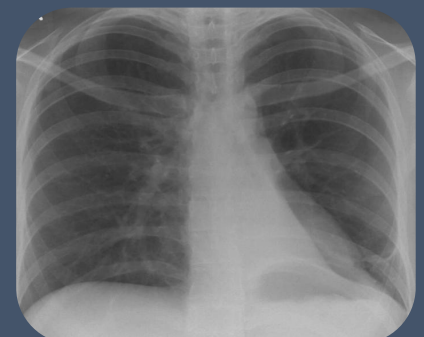
Another lucency is seen above the right kidney (White arrow). This gas within the hepatorenal fossa has been called the “Doge’s cap” sign, as it is said to resemble the headgear of the former leaders of Venice.

Fig. 4.1



## Case 5. Left Lower Collapse (from a Mucus Plug)

- **History:**  
28-year-old man with a history of myasthenia gravis is noted to be hypoxic.
- **Findings:**
  - Initial chest radiograph shows a retrocardiac opacity. The left hemidiaphragm cannot be seen behind the heart and the left heart border appears straightened. Also note the inferior location of the left hilum.



## Case 6. Anterior Mediastinal Mass (Diffuse Large B-cell Lymphoma)

- **History:**  
21-year-old man with exertional dyspnea is sent for a chest radiograph.
- **Findings:**
  - On the frontal radiograph, a soft -tissue-density mass (arrow in Fig. 6 ) silhouettes the aortic arch and aortopulmonary window. The left hilar vessels (asterisk in Fig. 6.1) can be seen through the mass (hilum overlay sign) and the descending thoracic aortic line is preserved.
  - On the lateral, the mass fills in the retrosternal clear space. The trachea is also displaced posteriorly and compressed against the spine.
  - CT images demonstrate a slightly heterogeneous soft tissue mass (asterisk in Figs 6.3 and 6.4 ) centered within the anterior mediastinum, encasing the great vessels (arrow in Fig. 6.3 ) and displacing the trachea and left main stem bronchus posteriorly (arrow in Fig. 6.4 ).

Fig. 6.1

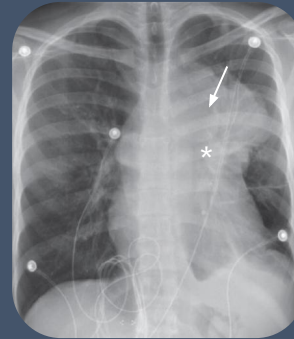


Fig. 6.2

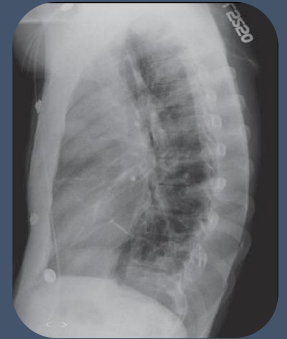


Fig. 6.3

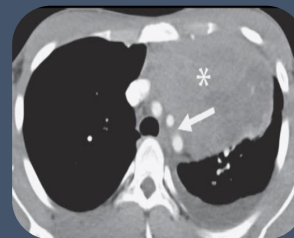
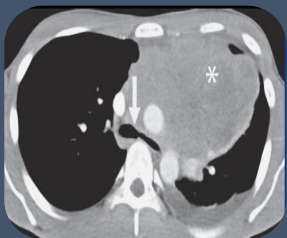


Fig. 6.4



## Case 7. Achalasia

- **History:**  
21-year-old man complains of chest pressure after eating.
- **Findings:**
  - Chest radiograph shows a tubular soft tissue density mass (white arrows in Figs. 7.1 and 7.2 ) with mottled air extending through the middle mediastinum from the thoracic inlet to the diaphragm. The trachea is deviated anteriorly (black arrow in Fig. 7.2 ).
  - Upper gastrointestinal study confirms the marked dilatation of a debris-filled esophagus with beak-like tapering (thick white arrow in Fig. 7.3 ) at the gastroesophageal junction. Intermittent emptying of the esophagus into the stomach was noted at the time of the exam, as well as tertiary contractions.

Fig. 7.1

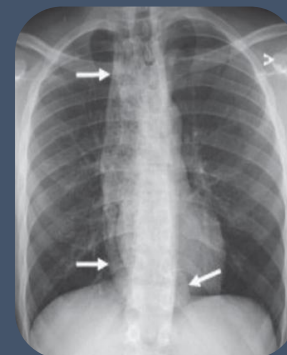


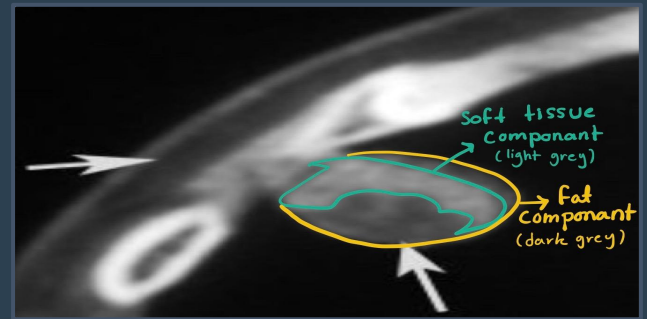
Fig. 7.2

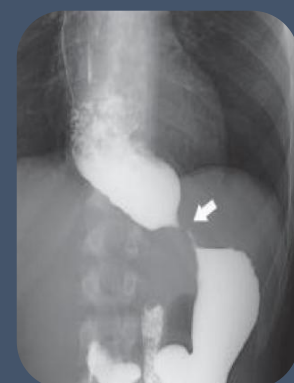
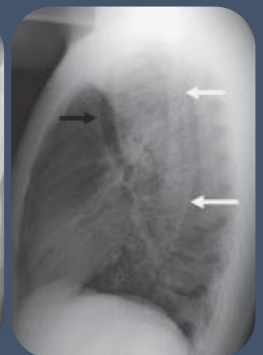
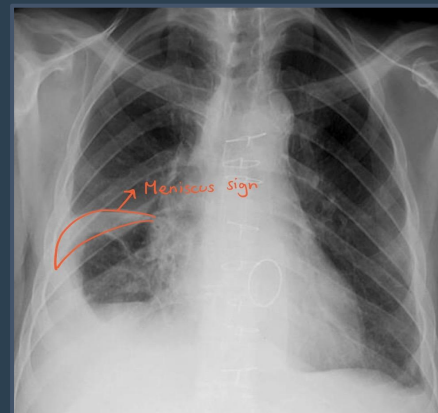
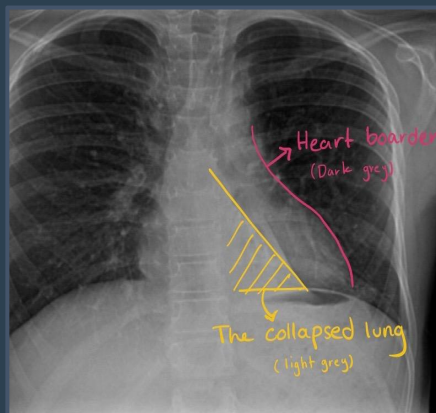
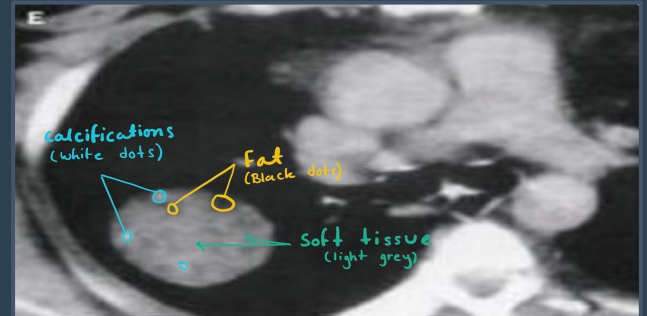
Fig. 7.3

## Team 436 explanation notes:

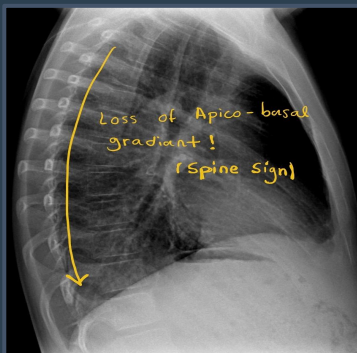
- Notice that the two arrows points to the same color gradient, which tells as that we know it is fat (Right arrow) because it has the same color of the subcutaneous fat (Left arrow) once you see fat, you don't need to do biopsy to rule out any other pathology.



- When the fat is a component of a lesion or a mass, it is a sign that it is benign.

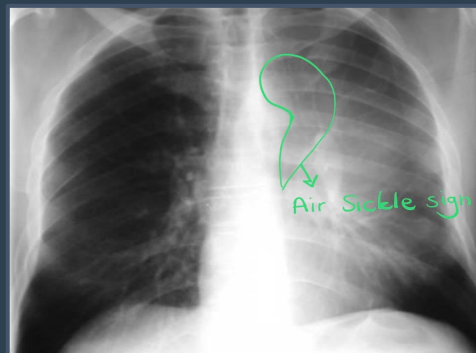


### Dorsal Spine Sign:



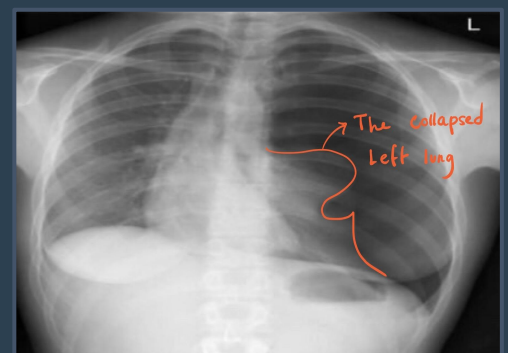
The whole spine appears with no change in color gradient. (It could be grey or white, but no change in gradient).

### Air sickle sign:



Air crescent which may be seen between the aortic arch and medial border of the collapsed lung especially with the left lung.

### Pneumothorax slide

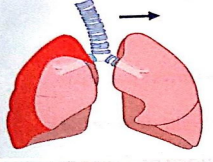
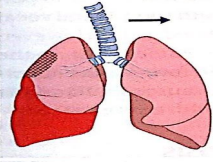
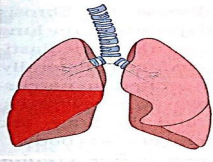
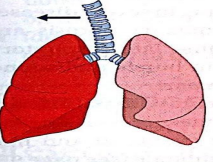


The lung condensed in a small area which increases its thickness and appear whiter than the surroundings.

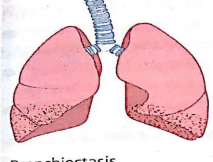
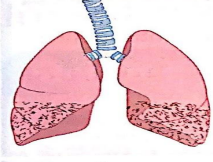
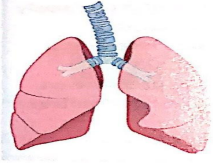
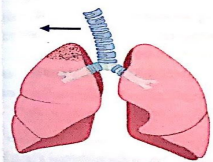
# Extra information

These tables are extra from outer source.

Source: Respiratory Medicine - eureka

Examination findings for common respiratory presentations					
Respiratory presentation	Trachea	Expansion	Percussion	Auscultation	Vocal resonance
<b>Pneumothorax</b> 	Central or deviated away, depending on size	Reduced on affected side	Hyper-resonant	Absent breath sounds No added sounds	Reduced or absent
<b>Pleural effusion</b> 	Central or deviated away, depending on size	Reduced on affected side	Dull ('stony dull')	Absent breath sounds Pleural rub (sometimes) Bronchial breathing at the top (sometimes)	Reduced or absent
<b>Lobar consolidation</b> 	Central	Reduced on affected side	Dull (if dense; resonant if less dense)	Bronchial breathing (if dense) Coarse crepitations	Increased or bronchial
<b>Lobar collapse</b> 	Deviated towards	Reduced on affected side	Dull	Absent breath sounds No added sounds	Reduced

**Table 2.19** Examination findings for common respiratory presentations. *Continued opposite.*

Examination findings for common respiratory presentations <i>continued</i>					
Respiratory presentation	Trachea	Expansion	Percussion	Auscultation	Vocal resonance
<b>Pulmonary fibrosis</b> 	Central	Reduced bilaterally	Resonant	Fine inspiratory bibasal crepitations (Velcro crepitations)	Normal
<b>Bronchiectasis</b> 	Central	Reduced bilaterally	Resonant	Coarse inspiratory bibasal crepitations	Normal or increased
<b>COPD or asthma</b> 	Central	Reduced bilaterally	Resonant	Prolonged expiration Quiet breath sounds throughout Expiratory wheeze	Normal or reduced throughout
<b>Apical scarring (post-tuberculosis)</b> 	Deviated towards	Reduced unilaterally	Resonant or dull	Bronchial breathing (tracheal) Focal crepitations	Normal or increased

**Table 2.19** Examination findings for common respiratory presentations (*continued*).

## main symptoms occurring with each disease

(golden notes)

Pneumothorax	Pneumonia	Pulmonary edema	Pleural effusion	Pulmonary emboli
<ul style="list-style-type: none"> <li>-car accident</li> <li>-acute chest pain</li> <li>-smoker</li> </ul>	<ul style="list-style-type: none"> <li>-fever</li> <li>-cough</li> </ul>	<ul style="list-style-type: none"> <li>-cough</li> <li>-dyspnea</li> <li>-lower limb edema</li> <li>-Orthopnea</li> <li>-diabetic</li> </ul>	<ul style="list-style-type: none"> <li>-chest pain</li> <li>-shortness of breath</li> <li>-discomfort</li> </ul>	<ul style="list-style-type: none"> <li>-long immobilization</li> <li>-taking oral contraceptive</li> </ul>

this works most of the time just by knowing those symptoms, BUT dont 100% rely on it.

Also i know dyspnea is the same as shortness of breath but whenever asked about:  
 -dyspnea; they're mostly referring to pulmonary edema  
 - shortness of breath; they're mostly referring to pleural effusion

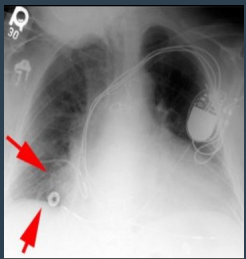
# Summary

## » Positioning «

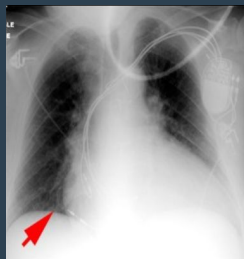
Position	X-ray direction
<b>PA</b>	X-ray beam passes from posterior aspect to the anterior side
<b>AP</b>	X-ray beam passes from anterior aspect to the posterior side
<b>Lateral</b>	X-ray beam passes from one lateral to other lateral, and the film is placed at the latter lateral.
<b>PA and Lateral</b>	<b>AP and Lateral Decubitus</b>
first choice, better quality.	for ill patients who can't stand up

## » Adequacy of Film «

### Inspiration

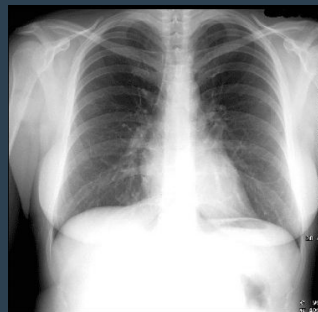


Poor inspiration



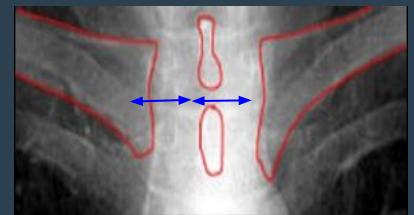
Adequate inspiration

### Penetration



Penetration is the degree to which the X-ray passed through the body.

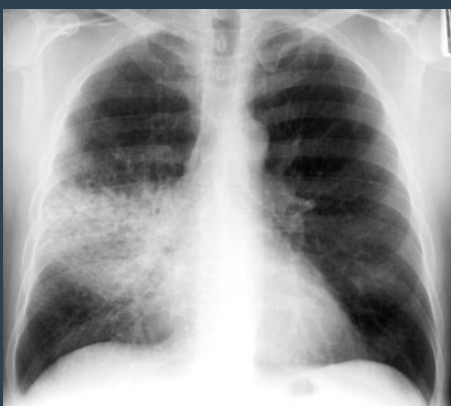
### Rotation



the distance between the spinous process and the medial side of the clavicles (blue arrow) should be equal on both sides

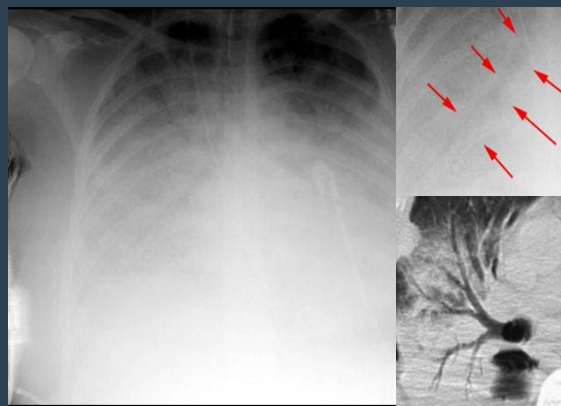## » CXR Signs «

### Silhouette



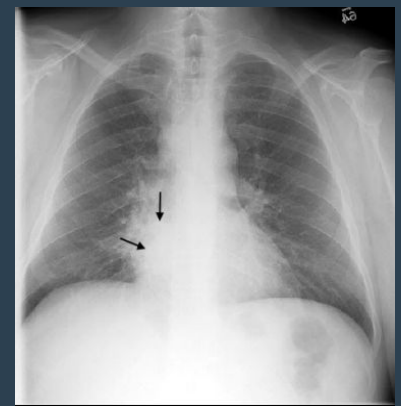
Loss of lung/soft tissue interface caused by a mass or fluid in the normally air-filled lung.

### Air Bronchogram



Bronchial airway made visible by filling the adjacent structures with fluid, exudate, pus, or blood

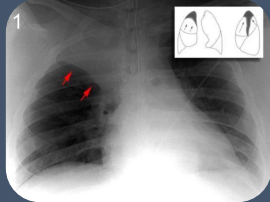
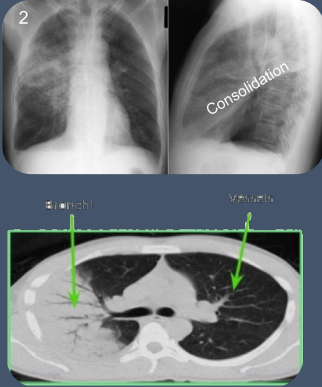
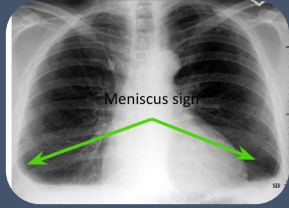
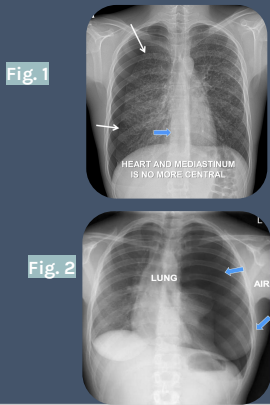
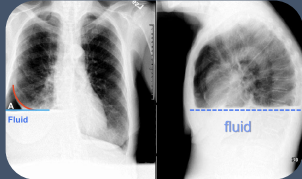
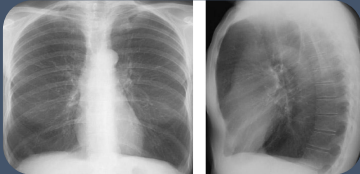
### Double Borders



You're only allowed to have one cardiac border. A problem posterior to the heart, mediastinum or lungs will show double cardiac border

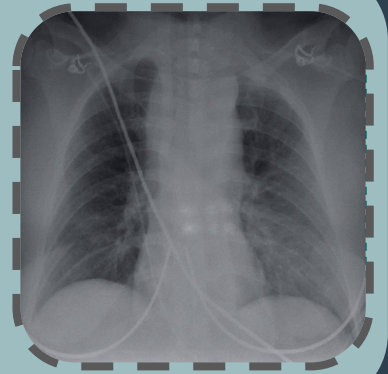


# Summary

Disease	Definition	Radiological finding	Picture
<b>Lobar Atelectasis</b>	Loss of volume of lobe, segment or sub segment of the lung. (Which leads to collapse)	1) Best sign is → Shift of a fissure. 2) Rapid development and clearance. 3) Air bronchograms if non-obstructive. 4) Secondary signs: Mediastinal shift, Elevated Diaphragm, Ribs closer together, Vague increase density.	
<b>Pneumonia</b>	Loss of air in lobe, segment or sub segment of the lung. The air is replaced by something else (Which leads to consolidation).	- Signs of pneumonia: signs of any air space process. Dx of pneumonia depends on appropriate clinical scenario. 1) Air bronchogram sign: It's either collapse or consolidation. 2) Silhouette: Positive or negative. 3) Dense Hilum. 4) Spine sign: Dorsal spine sign.	
<b>Pleural Effusion</b>	Accumulation of fluid in the pleural cavity outside the lung.	- blunted costophrenic angle. So we have bilateral costophrenic angle blunting.	
<b>Pneumothorax</b>	Accumulation of air in the pleural cavity outside the lung.	- Fig 1 There will be Pleural lines of the lungs, loss of lung markings (blood vessels) and it will appear as extremely black structure. - Fig. 2 Tension pneumothorax: Massive compression of lungs and shifting of mediastinum, left pneumothorax (no lung margin), flattening of the left hemidiaphragm, widening of intercostal spaces.	
<b>Hydropneumothorax:</b>	The presence of both air and fluid within the pleural space.	- Air fluid level appears flat. - 3 things in right side: air-fluid level, above it jet black air so we have fluid, air and the lung.	
<b>Emphysema</b>	Loss of elastic recoil of the lung with destruction of pulmonary capillary bed and alveolar septa. Most often by cigarette smoking and less commonly by alpha-1 antitrypsin deficiency.	1) Increased Lung Volume: Flattened Diaphragm, Increase in Retrosternal Airspace, Barrel chest. 2) Small Vessels. 3) Small, narrow cardiac shadow.	

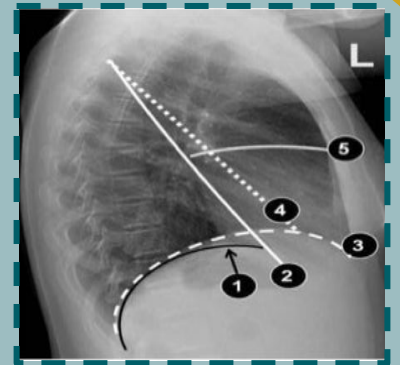
1-26 year -old pregnant female is imaged post motor vehicle collision (MVC). Which of the following is the next best step?

- CT angiogram of the chest
- non contrast CT of the chest
- MR angiogram of the chest
- direct angiography



2-What is the normal anatomical landmark shown in the picture?

- Left hemidiaphragm is completely shown
- The solid line represent the left oblique fissure
- The dotted line represent the azygos fissure
- The horizontal fissure is not present



3-Which one of the following is a sign of improper position ?

- Cardiomegaly
- Darker spine
- Bright muscles
- Patchy appearance in lung fields

4-Which one of the following is characteristic of pulmonary pneumonia?

- Volume loss
- Shifting of lung fissure
- Calcification
- Air bronchogram

5-Which of the following statements about taking a routine chest x-ray are true?

- It is normally taken in expiration
- It is normally taken as an anteroposterior view
- It is normally taken as a posteroanterior view
- It is hazy when the patient has taken a deep inspiration

6-On a normal chest x-ray, which of the following statements are true?

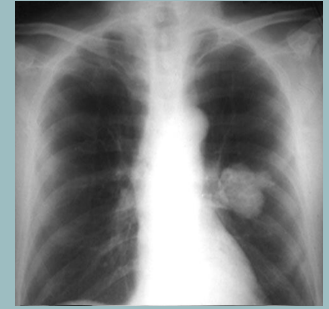- The dome of the right hemidiaphragm lies at the level of the anterior end of the sixth rib
- The trachea usually lies to the left of the midline
- The contours of the breast shadows are not seen
- Usually about two-thirds of the heart lies to the right of the midline

The doctor's questions from the lecture

Answers  
1)A  
2)B  
3)A  
4)D  
5)C  
6)A

1- What is the salient finding in the following chest X-ray?

- a. Consolidating
- b. Atelectasis
- c. Mass
- d. Pleural Effusion



2- In a patient with Atelectasis, what change is associated with the position of the trachea?

- a. Deviate away from the affected lung
- b. Deviate toward the affected lung
- c. No change

3- What does blunting of the costophrenic angles suggest?

- a. Pneumothorax
- b. Consolidation
- c. Collapse
- d. Pleural Effusion

4- “Presence of air inside the thoracic cavity but outside the lung” is a definition of:

- a. Pleural effusion
- b. Pneumothorax
- c. Hydropneumothorax
- d. Emphysema

5- In which of the following the air fluid level appears flat?

- a. Pneumonia
- b. Pleural effusion
- c. Pneumothorax
- d. Hydropneumothorax

6- Increase lung volume in emphysema will lead to all the following, Except:

- a. Flattened diaphragm
- b. Shift of a fissure
- c. Barrel chest
- d. Increase in retrosternal air space

[Quiz containing images from this lecture](#)

Answers  
1)C  
2)B  
3)D  
4)B  
5)D  
6)B