



Radiology
Team 438

Radiology of Cardiac Diseases

Lecture 5

Objectives

Reviewed By



Noura Alturki
Jehad Alorainy

- ❖ There is only one way to happiness and that is to cease worrying about things which are beyond the power of our will
- ❖ Happiness is when what you think, what you say, and what you do are in harmony
- ❖ The successful warrior is the average man, with laser-like focus.
- ❖ No objectives, :)

Color Index:

♦ Important

♦ Doctor's Notes

♦ Extra

♦ Female slides

♦ male slides

Team Leaders



Omar Aldosari



Leena Alnassar



Shahd Alsalamh

Done by:

Zyad Aldosari

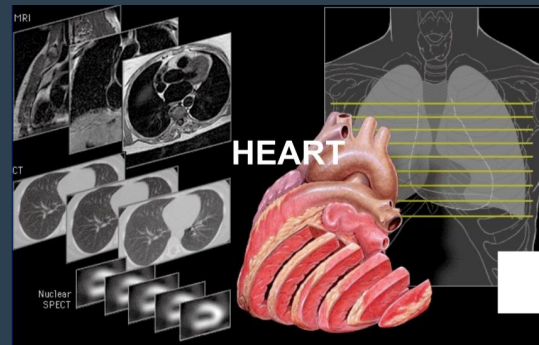
Revised by:



Shahd Alsalamh

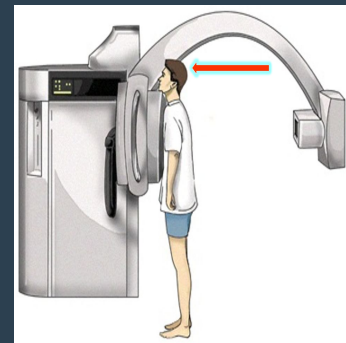
» BASIC CHEST EXAM FOR THE HEART AND GREAT VESSELS

- PLAIN FILM=CHEST X-RAY(CXR)
- CT FOR HEART AND MEDIASTINUM
- ANGIOGRAMS
- MRI
- ULTRASOUND (ECHOCARDIOGRAPHY)
- ISOTOPIC SCANNING



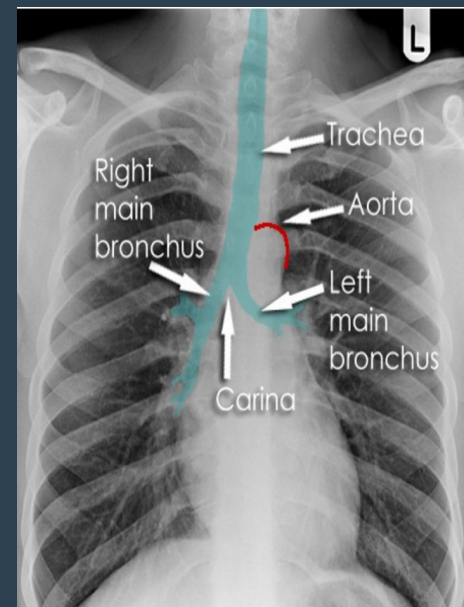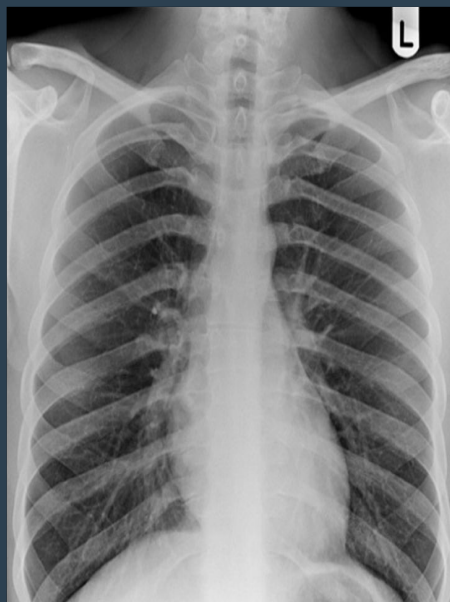
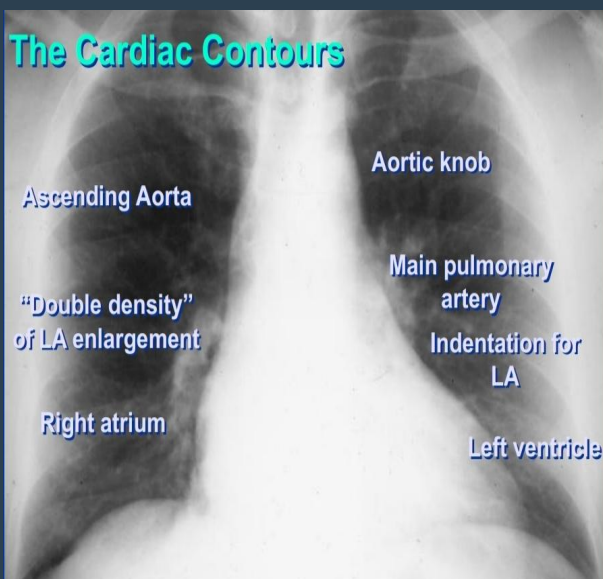
» The Chest X-RAY

- Plain film gives us basic information and it is limited. the findings are weak and sometimes not specific, but it should be the first step.
- Gold standard is erect PA chest X-ray, but it can be done in supine position if he can't stand up (Trauma, HF).
- Plain film is the basic examination for intrathoracic diseases "chest or cardiac".
- CXR helps you to exclude other diseases when a patient presents with chest symptoms so this can help you to avoid additional tests.



» The Cardiac contours + there is another important image regarding the anatomy of the heart [Click here](#)

The Cardiac Contours

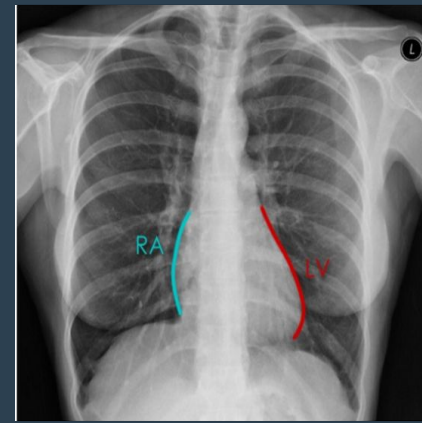
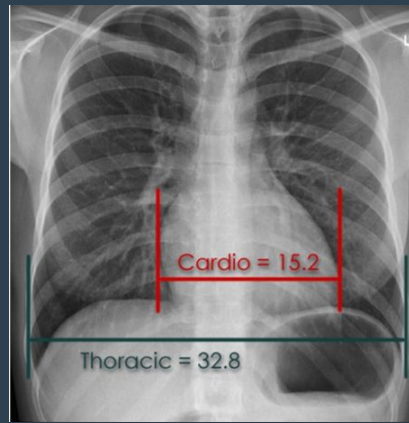


There are 7 contours to the heart in the frontal projection in this system. But only the top five are really important in making a diagnosis. (all except RA and LV)

We can see the air opacifying trachea and the bifurcation of trachea. sometimes when LA is enlarged it affect the acute angle of Carina to be nearly 90 degree angle. "Splaying of Carina" is one of the indirect signs for LA enlargement.

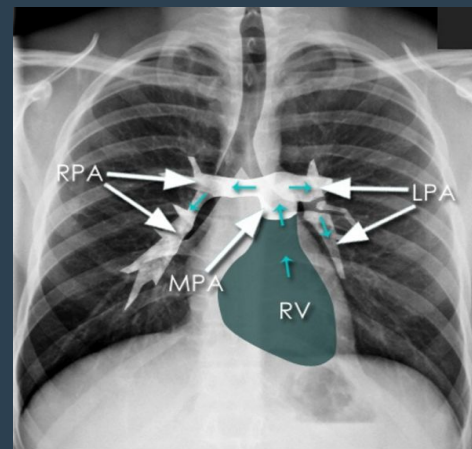
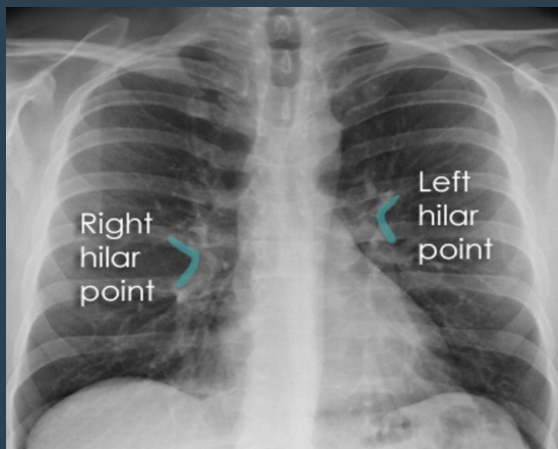
» Cardiac contours

- The cardiac transverse diameter should be less than $\frac{1}{2}$ of the thoracic transverse diameter.
- Normally, nearly $\frac{1}{3}$ of the heart is in the right hemithorax and $\frac{2}{3}$ of the heart is in the left hemithorax

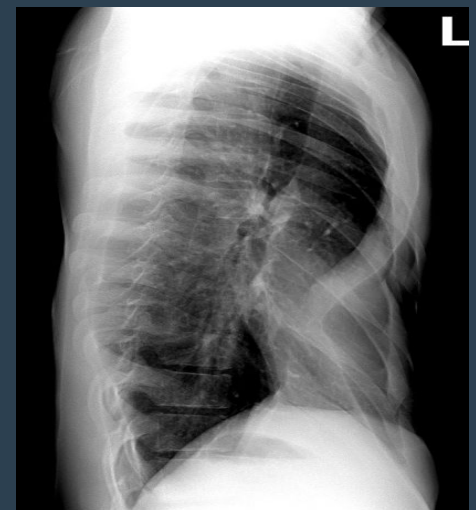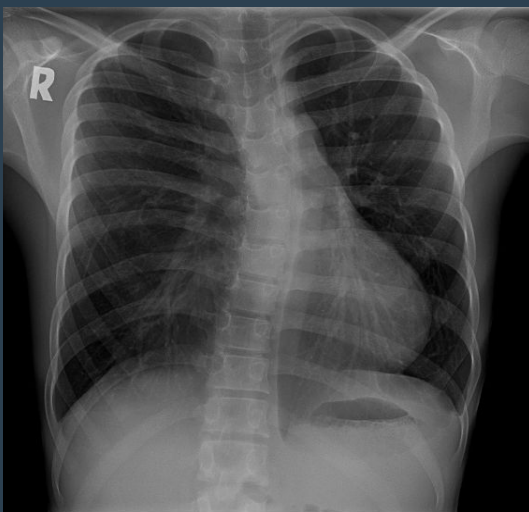


» Hilar levels

look for increase in density as well as size. If the hila are out of position, ask yourself if they are pushed or pulled, just as you would when assessing the trachea



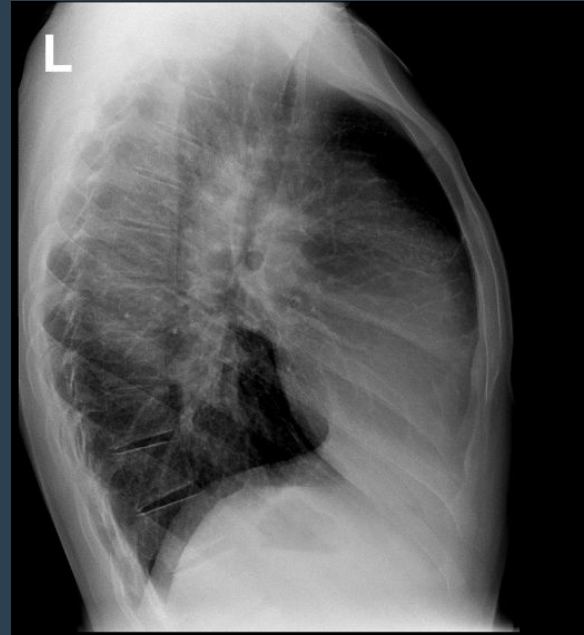
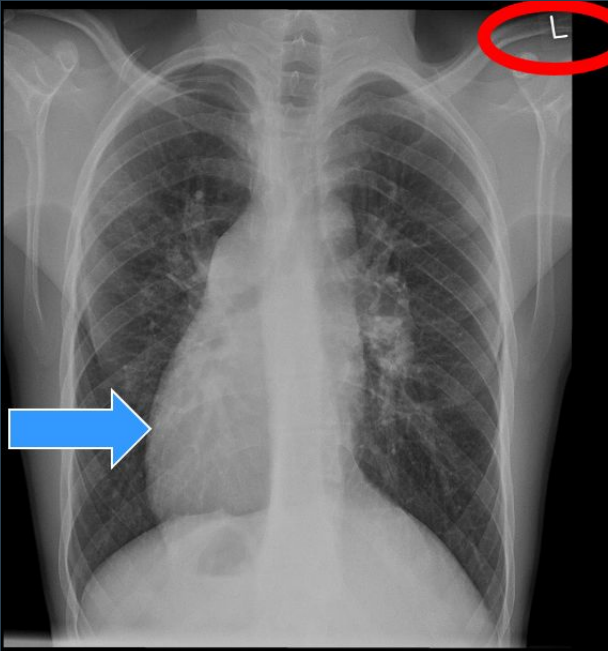
» Cardiac displacement



Pectus excavatum

This is the lateral view, shows **sternal depression** which causes the heart to be displaced

Cardiac displacement

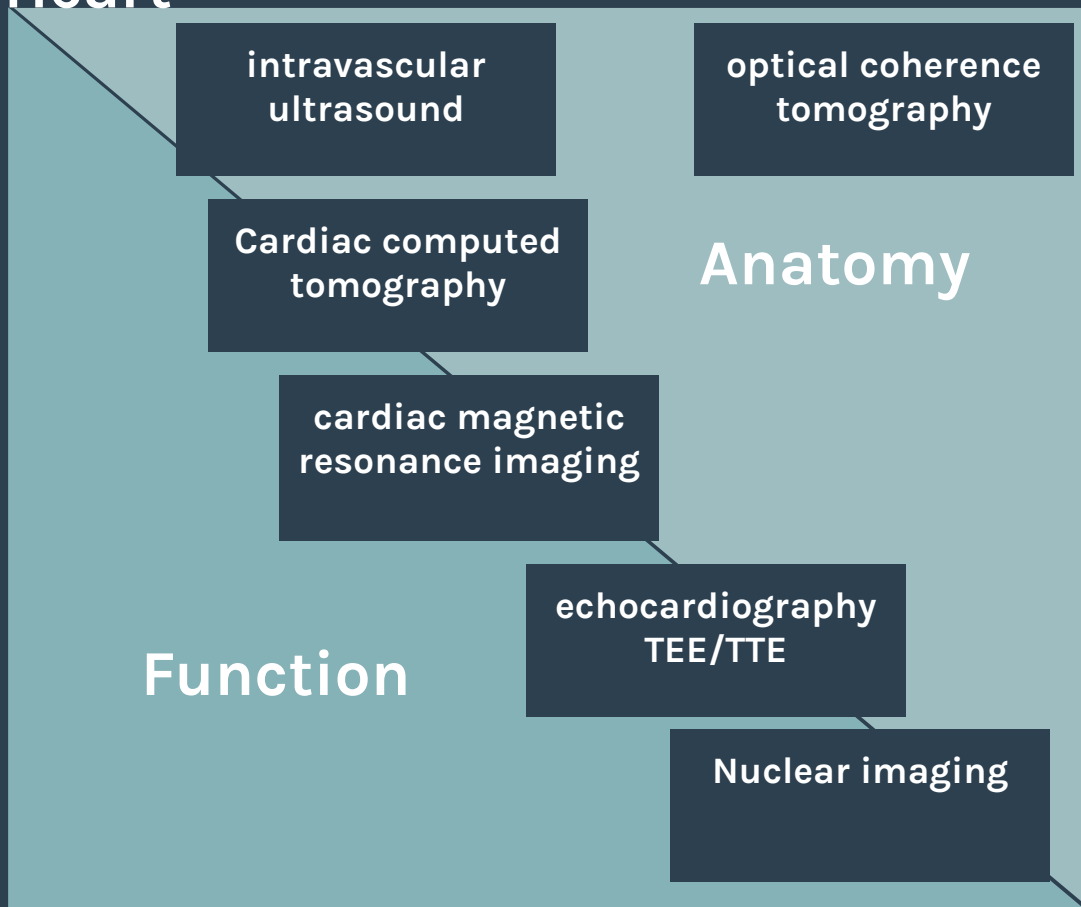


DEXTROCARDIA¹

That's why x-ray important, if patient have acute left iliac pain it might be appendicitis in this case.

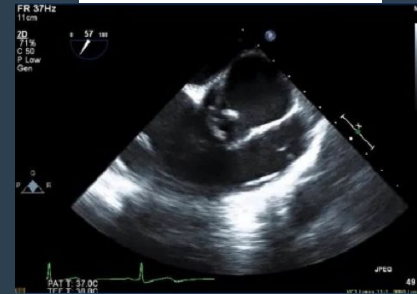
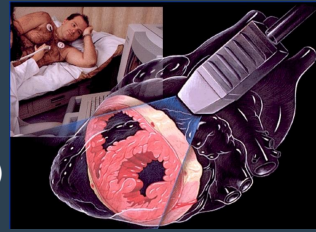¹ it's a rare heart condition in which one's heart points toward the right side of one's chest instead of the left side

Heart

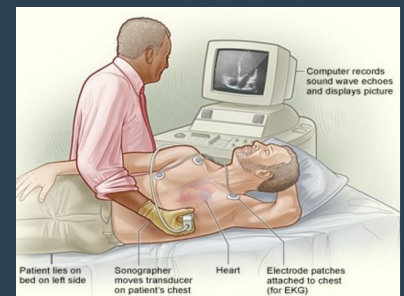
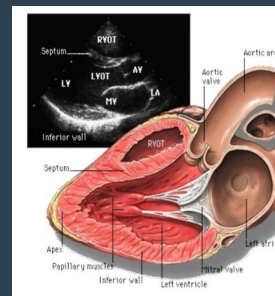


➤ Echocardiography

- Transthoracic echocardiography (routine)
- Transesophageal echocardiography
 - Evaluate for cardiac source of embolism (36%)
 - Endocarditis (14%)
 - Prosthetic Valve function (12%)
 - Valvular disease, aortic dissection or aneurysm, tumor, mass or thrombus. (6-8%)
 - Congenital Heart disease
 - Interventional cardiology guidance
 - Intraoperative evaluation cardiothoracic surgery
- Intracardiac echocardiography
- Intravascular echocardiography



Transthoracic echocardiography

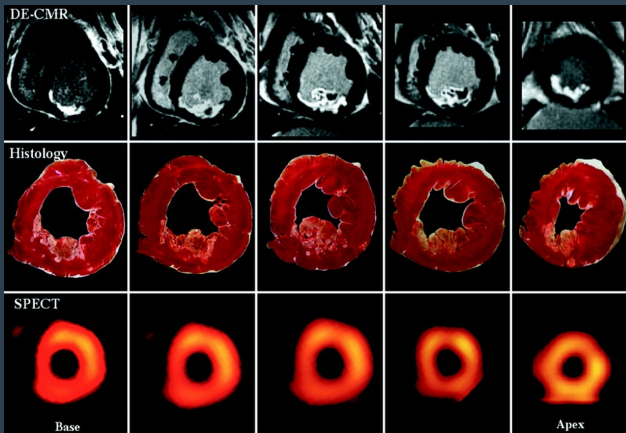


Transthoracic echocardiography

➤ MRI

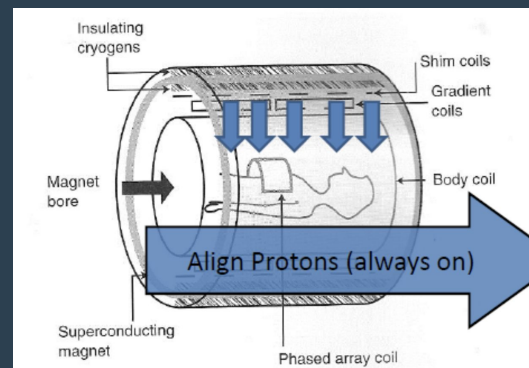
➤ Viability Assessment

CMR Delayed Hyperenhancement



Can get details of cardiac size, measure CO. You can compare it to SPECT, that shows muscle and blood supply and supply defect in case of MI or myocardial insufficiency, but not CO or contractility.

➤ Cardiac magnetic resonance

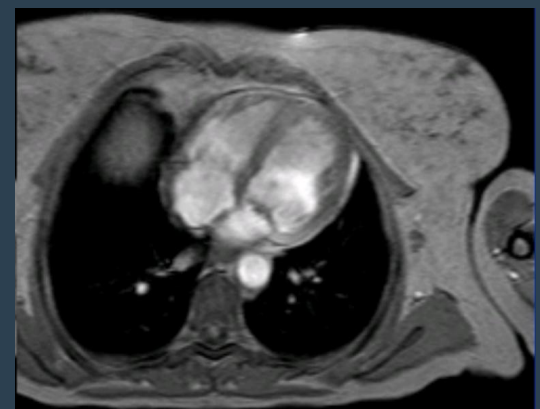

Disadvantages:

1. takes time (40-60 mins.)
2. Magnetic field -> Get rid of any metallic objects before entry.

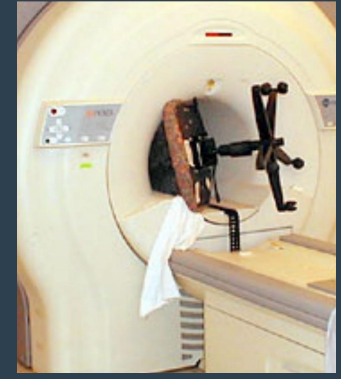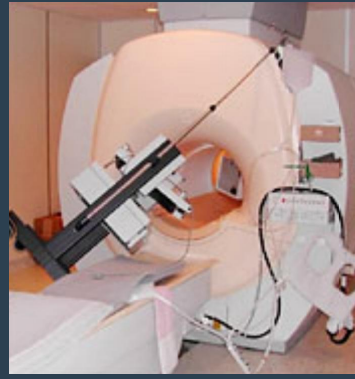
Advantages:

1. Can detect any abnormality,
2. No radiation



» Hazards of MRI

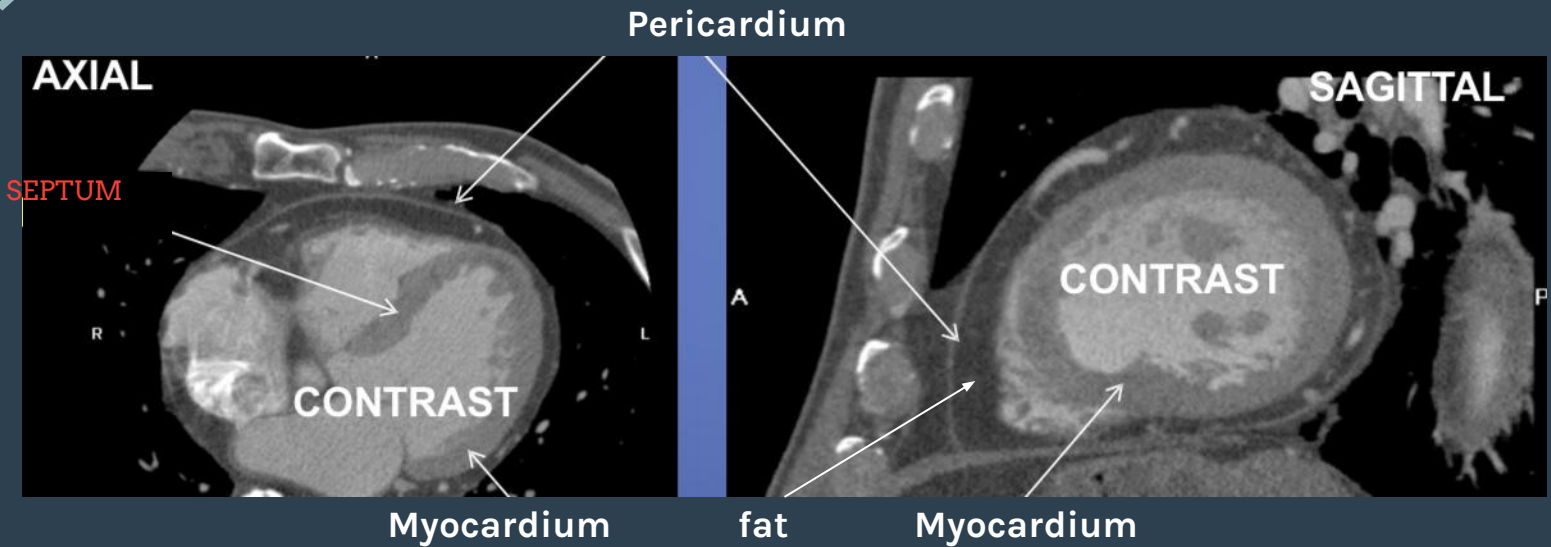
Magnet-Seeking Projectiles



» Cardiac CT

CT For the heart and coronary vessels

» Pericardium



Inside the cardiac cavities you can see the contrast, the lungs are black in appearance.

the heart is separated from surrounding by:

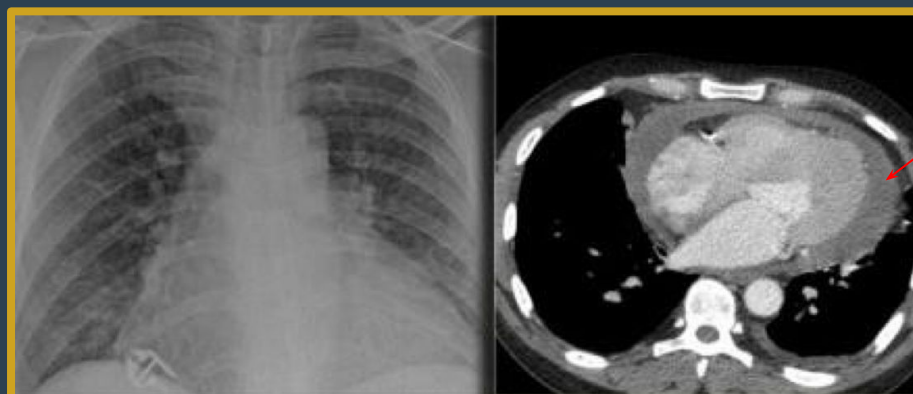
- fat (dark grey near black, gets thicker if the patient is obese or having cushing syndrome)
- Pericardium (grey)

» Pericardial Effusion

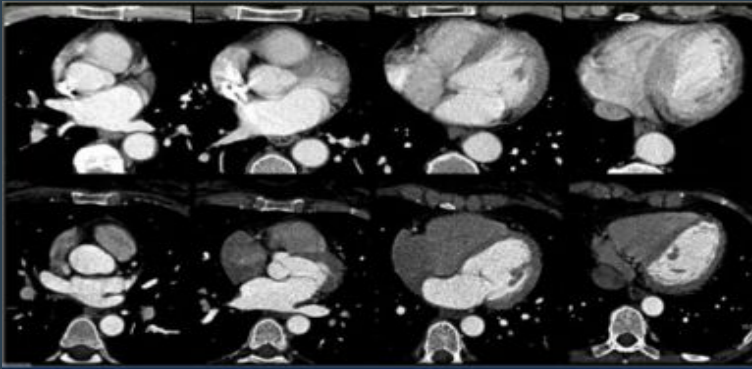
- ❖ whenever we encounter a large heart figure, we should always be aware of the possibility of pericardial effusion simulating a large heart.
- ❖ On the CXR it looks as if this patient has a dilated heart while on the CT it is clear, that it is the pericardial effusion that is responsible for the enlarged heart figure.

In the CT:

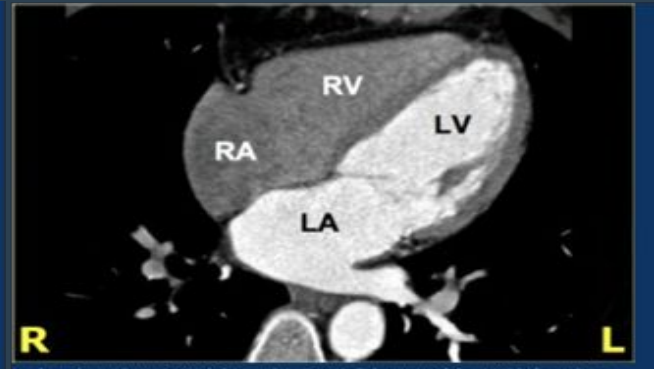The heart is surrounded by fluid (light grey) not fat. Pericardial effusion is diagnosed by CT or ultrasound



» Cardiac Chambers



Axial slices through the heart



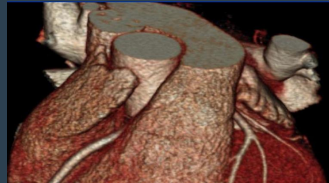
4-chamber view. RA=right atrium, RV=right ventricle, LA=left atrium, LV=left ventricle.

» 4 to 64 slice scans: five heartbeats

10mm detector pitch ~0.25
3cm in 5 sec

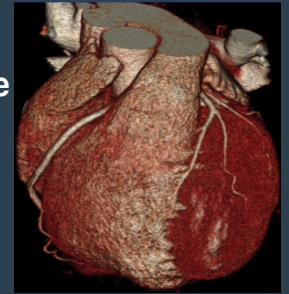


20mm detector pitch ~0.25
6.2cm in 5 sec



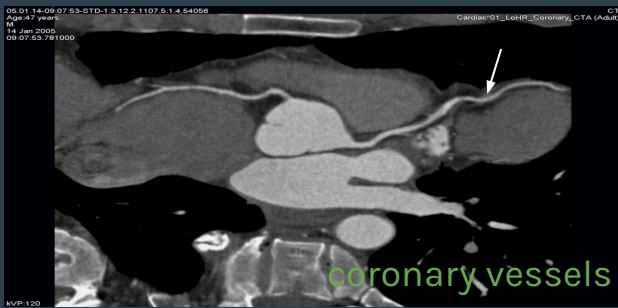40mm detector pitch ~0.25
12.5cm in 5 sec

3-D volume rendered:

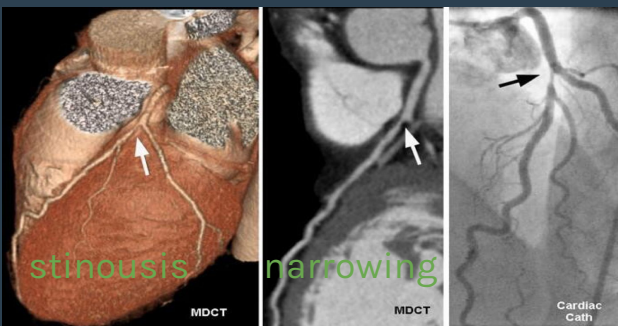


» Coronary Arteries Maximum Intensity Projection

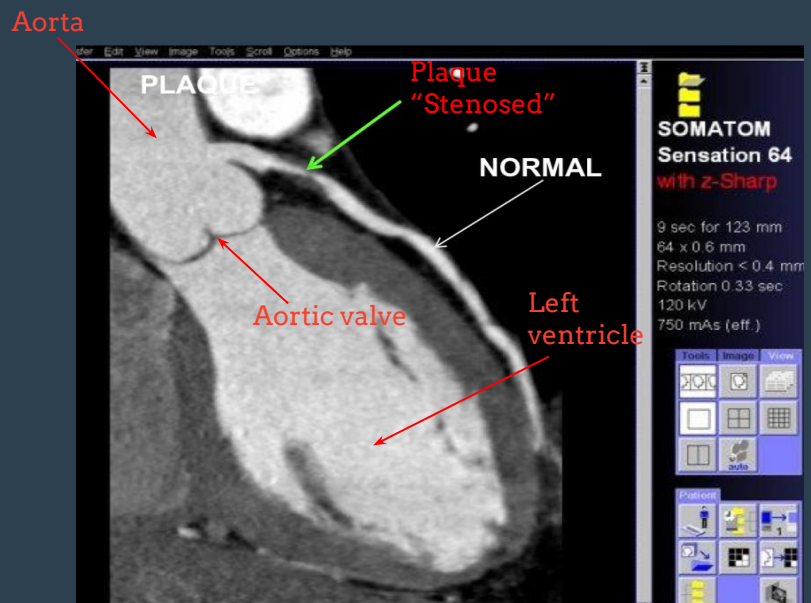
It is important to understand differences between CT angiography (CTA) and catheter.



Curved Planar Image



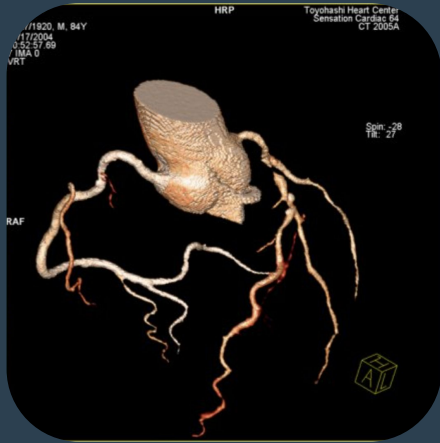Plaque = vascular narrowing



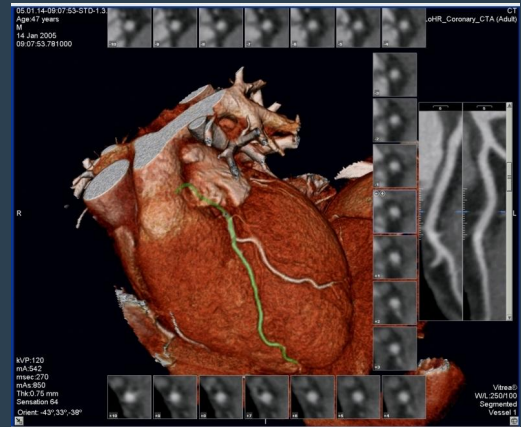
- Soft plaque in proximal LAD
- Narrowed lumen

- ❖ cardiac cath is an **invasive** technique and can be **interventional, time consuming**
- ❖ CTA or MRI of the heart Are **not invasive, not interventional=non therapeutic**
- ❖ High risk pts to ACS >> Do catheter
- ❖ Low risk pts such as young >> Do CT or MRI
- ❖ If the patient is already having stent and you want to check you can do CT angiography with Contrast.

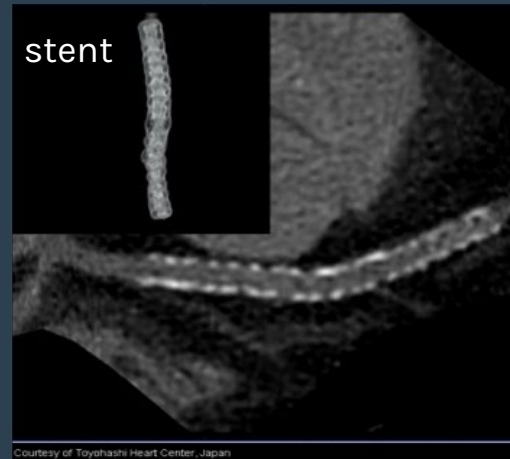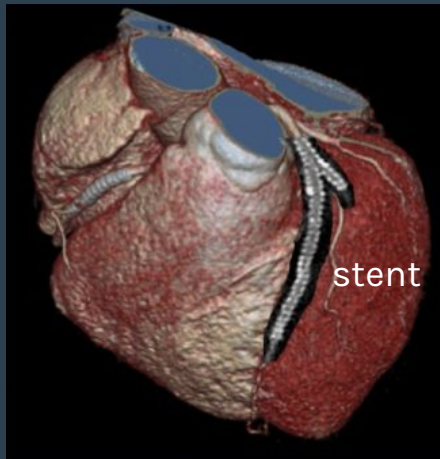
Cardiac CT



You can get 3D images and remove the cardiac shadow to see only the vessels.

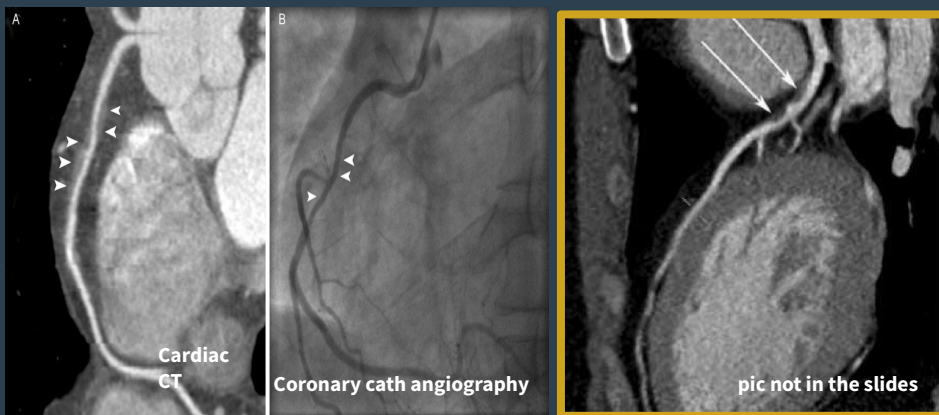


closing vessels



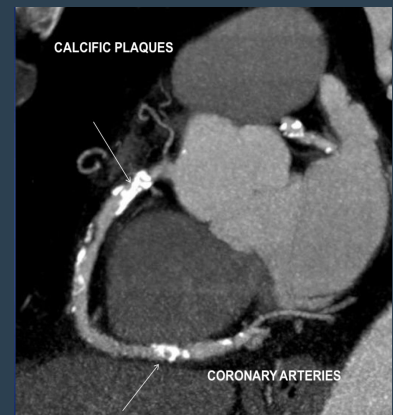
Types of Plaque

Soft Plaque visualization



- Plaque is black and not calcified which is area of stenosis is called soft plaque, it can be treated by balloon.
- In cardiac cath, they have advantage, when they see the area of narrowing, they put stent, the exam takes time.

Calcific Plaque

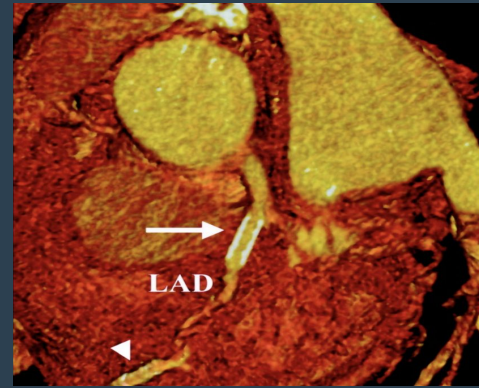
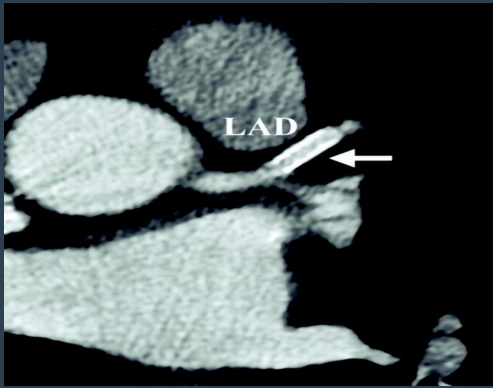


Plaque is **calcified** is called calcific plaque or hard plaque, it is hard to treat.

In cardiac CT you can differentiate between Calcifications and soft tissue
In coronary Cath angiography you can see narrowing but can't differentiate.

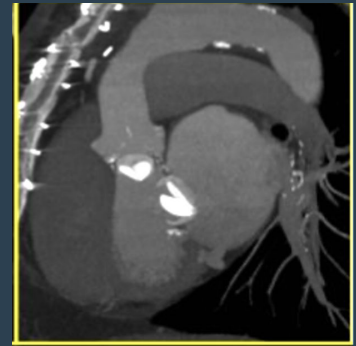
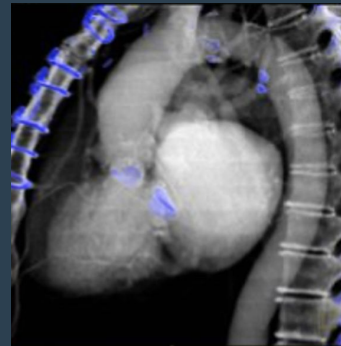
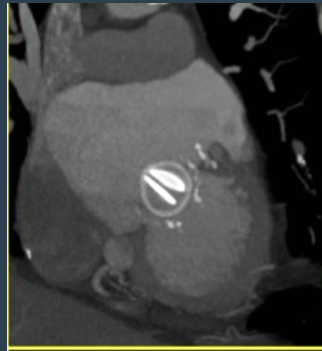
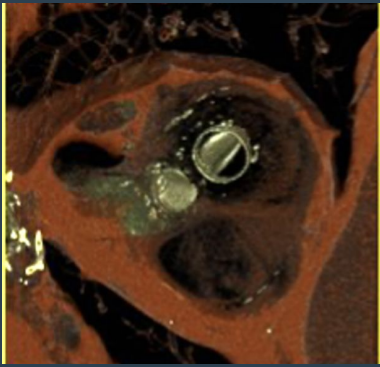
Plaques

» LAD (left anterior descending)

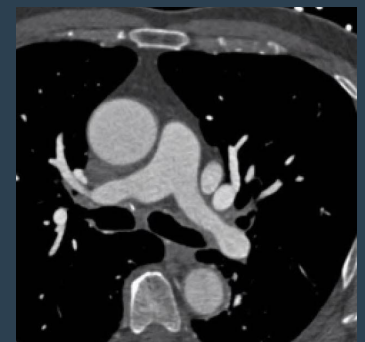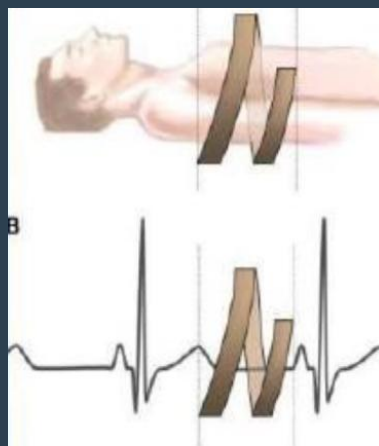
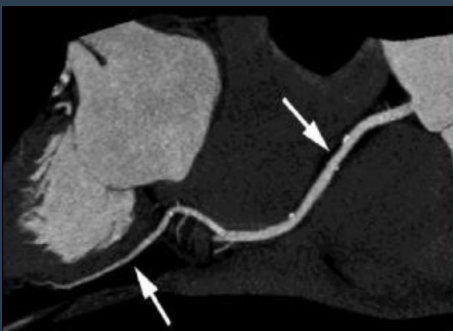
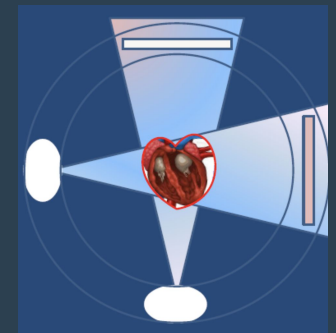
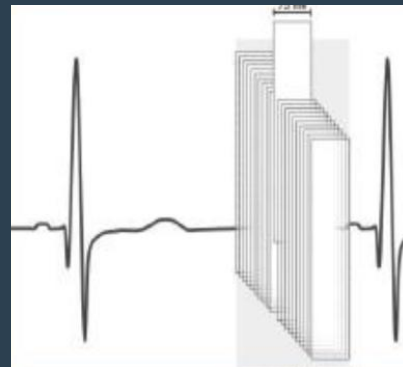
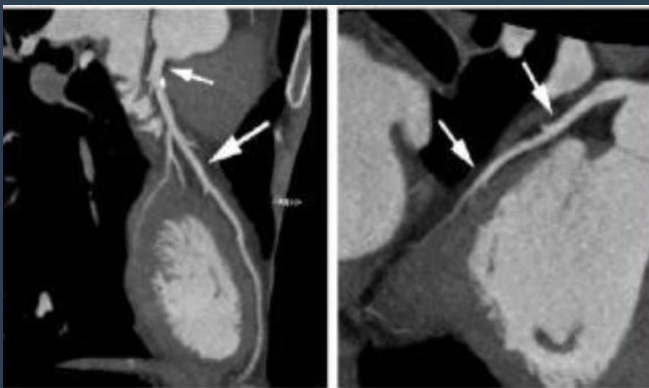


» Replaced Valve

You can see the replaced valve, status of sternum



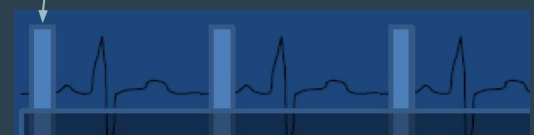
» High Pitch Coronary CT Scanning



Full course of the artery with tiny calcific foci

You can examine each segment of the vessel individually

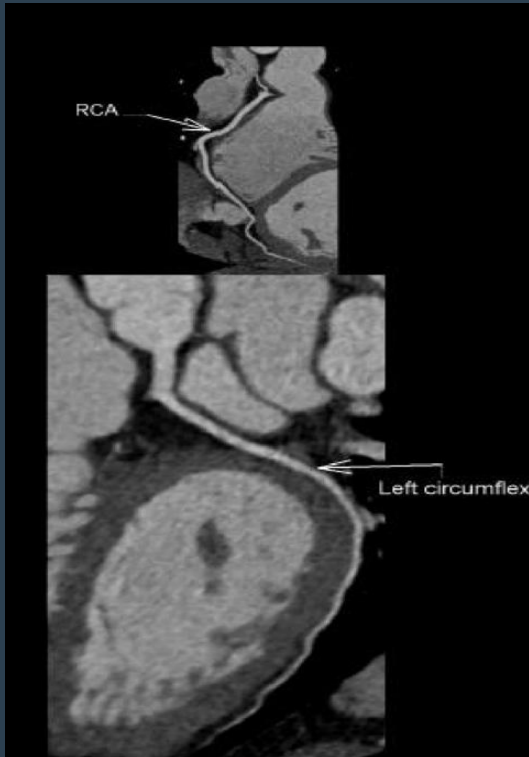it scans on each atrial diastole



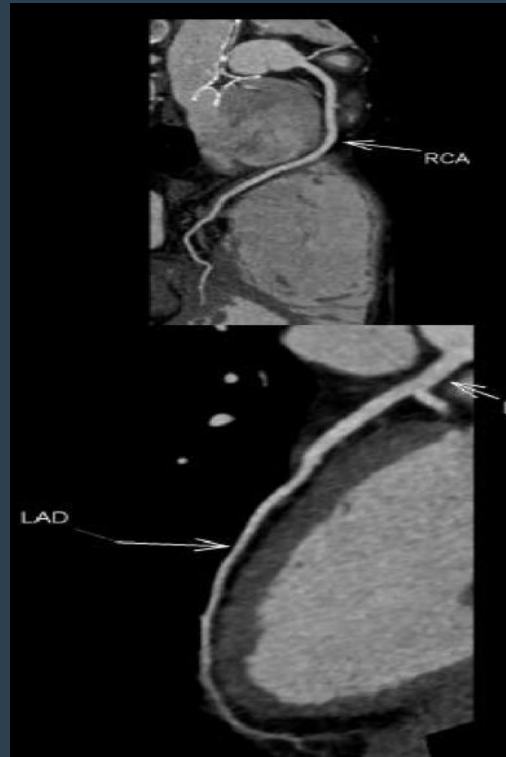Plaques

» Gated with contrast

Right coronary artery

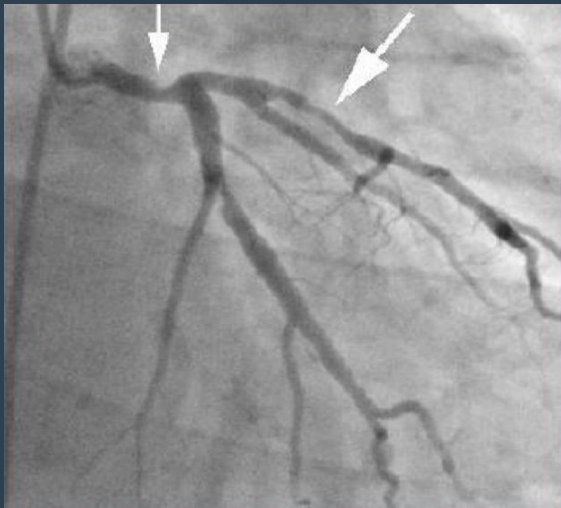


Right coronary artery

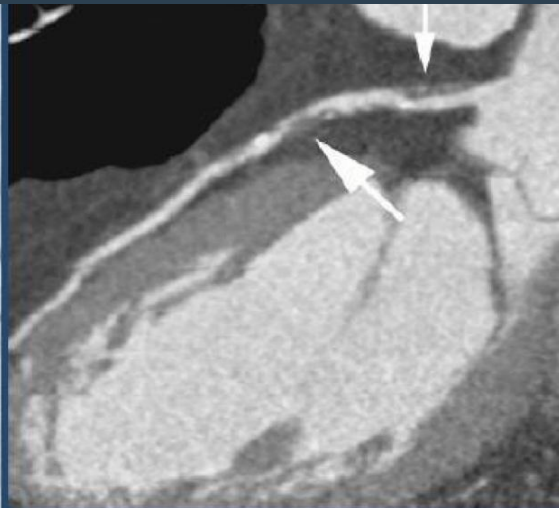


Left anterior descending

» Plaque visualization



Catheter Angiography

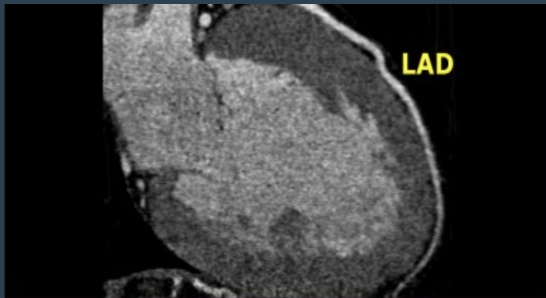


CT

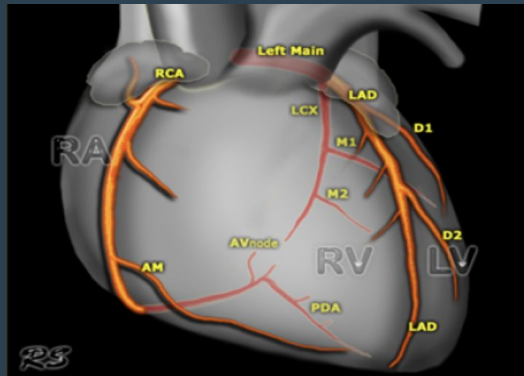
Notice the difference

» Anatomy of Coronary vessels

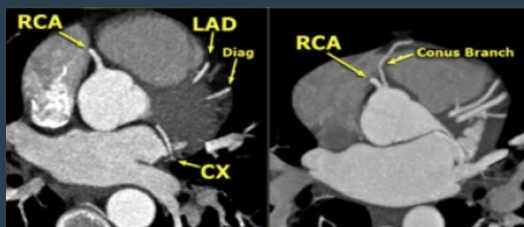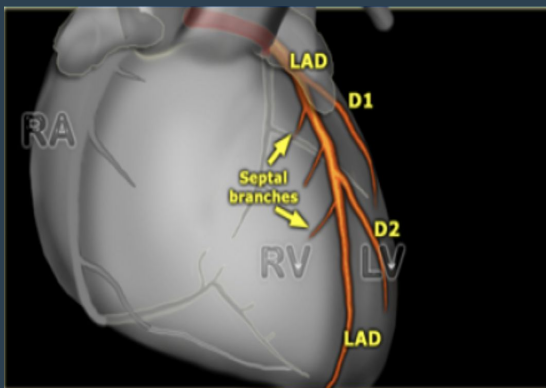
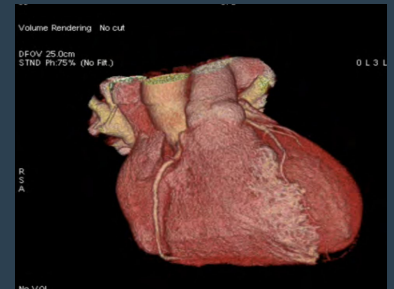- Knowledge of normal anatomy will allow for ideal imaging planes and sections.
- Knowledge of normal anatomy will allow for identification of pathology and proper CT scan interpretation.



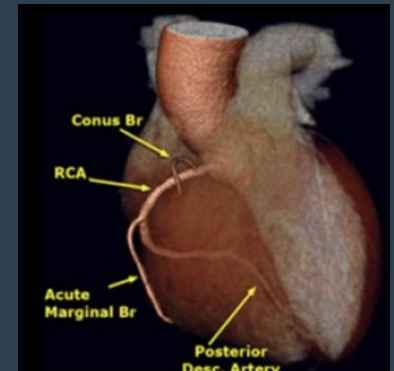
CT image of the LAD and RAD projection



RCA, LAD and LCx in anterior projection

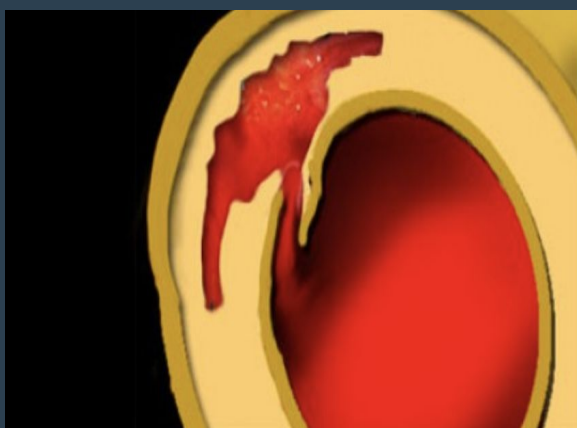


Left: RCA comes off the right sinus of valsalva
Right: Conus artery comes off directly from the aorta

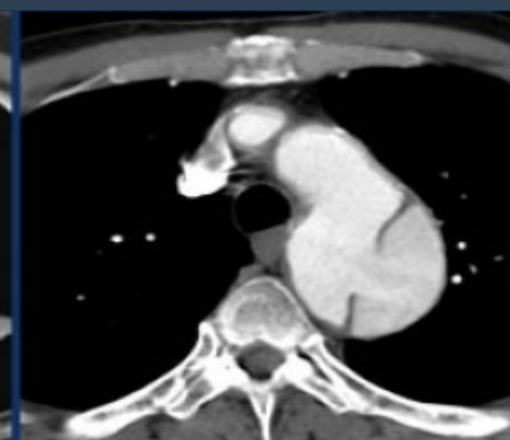
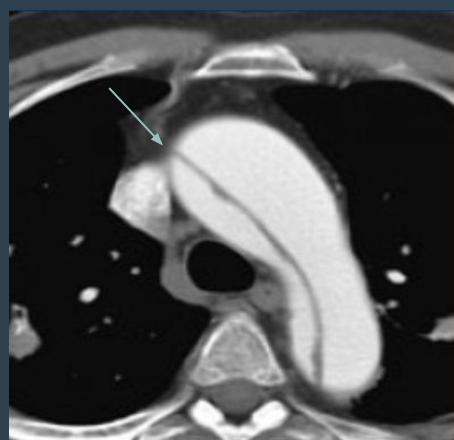
» Aortic Dissection

Aortic dissection (AD) occurs when an injury to the innermost layer (intima) of the aorta allows blood to flow between the layers of the aortic wall, forcing the layers apart. In most cases, this is associated with a **sudden onset of severe chest or back pain**, often described as "tearing" in character



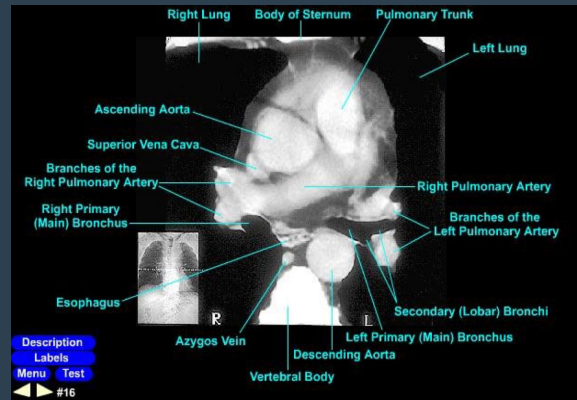
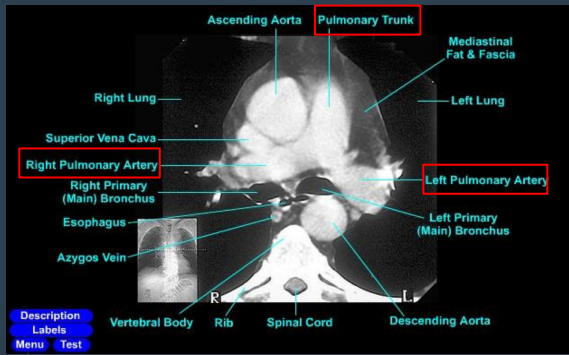
Classic aortic dissection



Left: Type A dissection with clear Intimaflap seen within the aortic arch
Right: Type B dissection. Entry point distal to left subclavian artery

Separating the two lumens of the Aorta

Vascular Anatomy of the Chest



The most important level (at level of hilum) you get what we call (Mercedes sign), if you see IV contrast is homogenous with blood in this area (no filling defect) that is mean the patient doesn't have major problem, if the patient has embolus here it is may be fatal

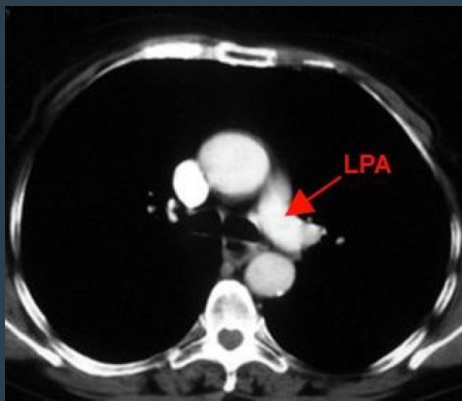
"This is another level. It is lower than the previous one - picture on left - and as you go down, the LPA will start to fade; just few parts are shown in this level"

Case:

Patient came to ER, he was bedridden for some time because of fracture for 4 months. After 4 months, he has chest pain and difficulty in respiration. He came to ER the most suspicious clinical diagnosis is acute pulmonary embolism because he is **bedridden** probably develop DVT in the lower limb.

The gold standard is CT Angiography.

Pulmonary Artery

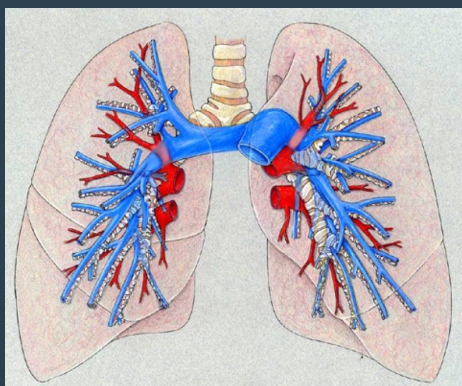
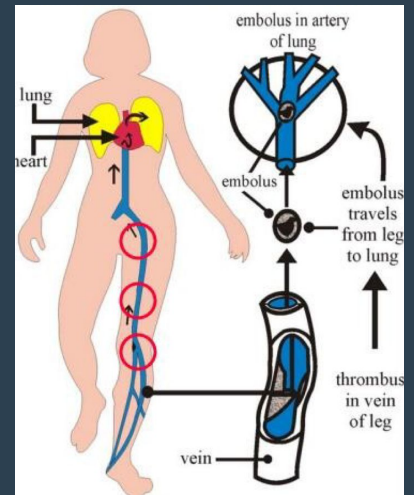


Left pulmonary artery

Development of pulmonary embolism

Usually the scenario includes:

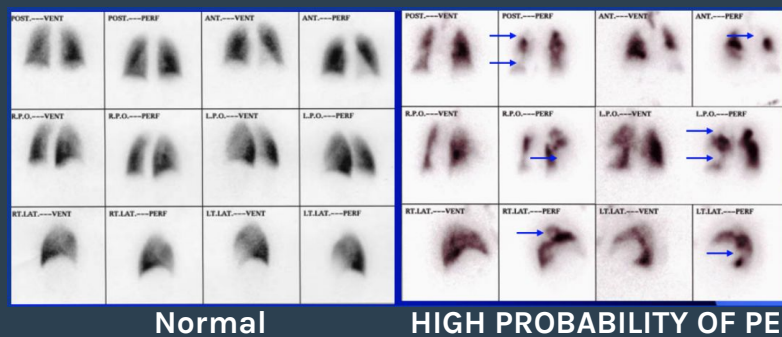
- bedridden patient
- Road traffic accident
- Post c-section



V/Q SCAN:

Will show the deficiency of blood flow. but will not show the cause and it does not correlate well with the severity

V/Q SCAN



Normal

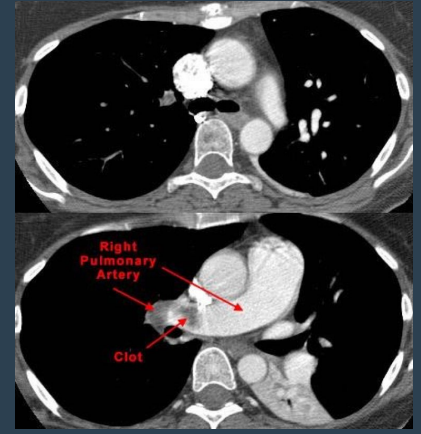
HIGH PROBABILITY OF PE

» Pulmonary Embolism

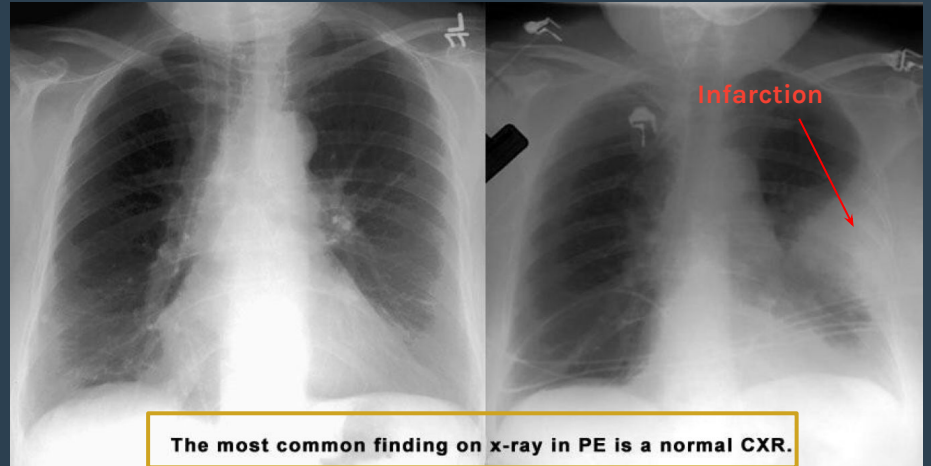
- The gold standard for diagnosis of PE is **CTA (CT Angiography)**.

Acute pulmonary embolism is one of the fatal diseases, so you have to investigate the patient very early.

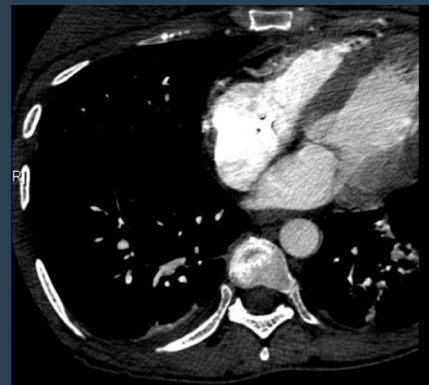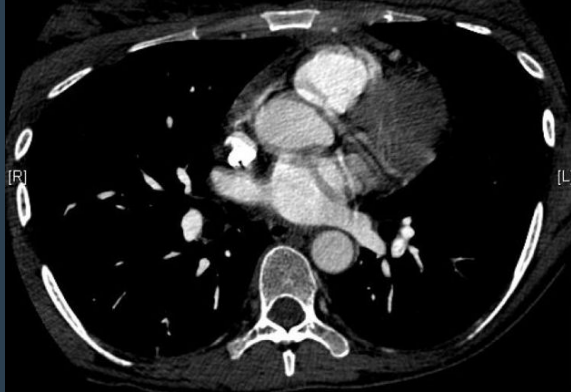When we do x-ray, there are many patients their result will be negative, but this does not mean they don't have PE. So, the gold standard today is CT angiography, we give IV contrast and do CT angiography for pulmonary vessels or for chest to check for PE.



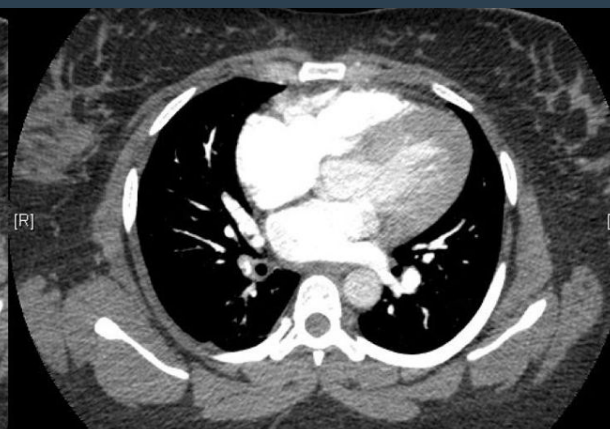
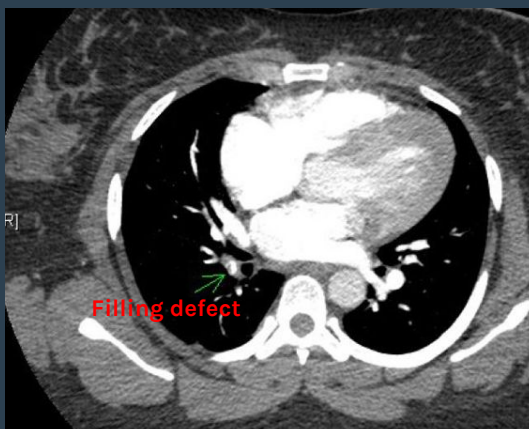
The picture on the left is normal but the patient actually have PE! his clinical symptoms were neglected because of the normal CXR. He was sent home but one day later, he came back to the ER with worsening symptoms. CXR was taken and showed pulmonary infarction in the left lung (right picture)



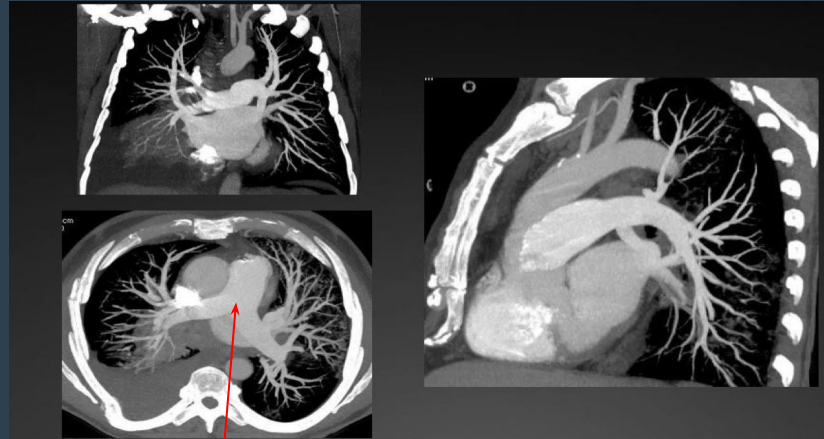
The most common finding on x-ray in PE is a normal CXR.



- The level in which we see all vessels together is the level of hilum.
- When the embolism is more to the peripheral its clinical significance decreases



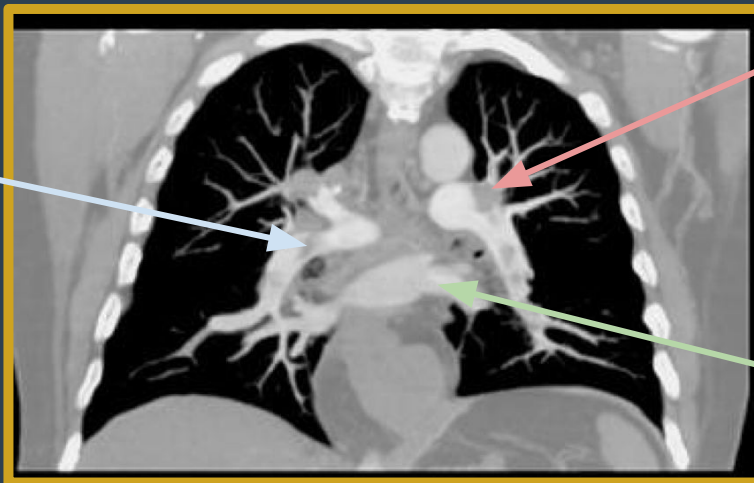
» CTA Pulmonary Vasculature



Mercedes Sign

» CTA (Coronal Reconstruction)

Embolus in descending right pulmonary artery



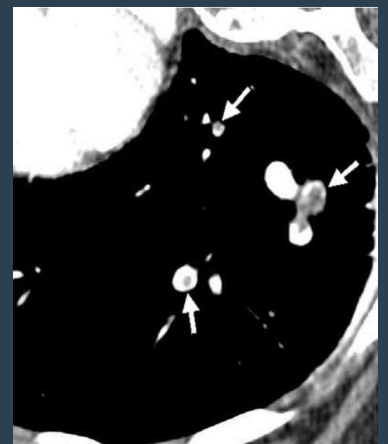
Embolus in left main pulmonary artery

Normal Homogenous filling of the filing of the vessels

This shows multiple embolisms which indicates Acute Massive PE

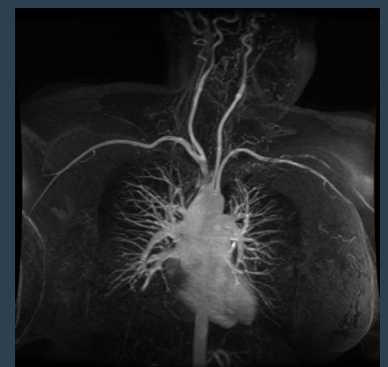» CT Angiogram

You can see even small peripheral vessels. The arrows here show filling defects which indicate the presence of clots within the vessel. They indicate that the patient is having acute peripheral PE



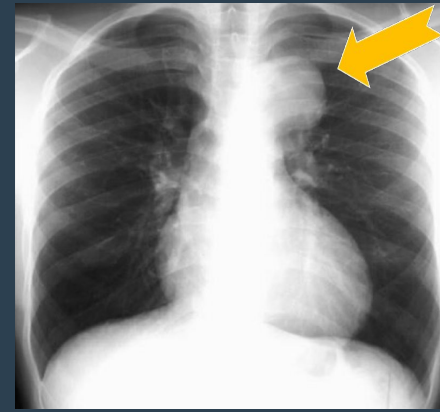
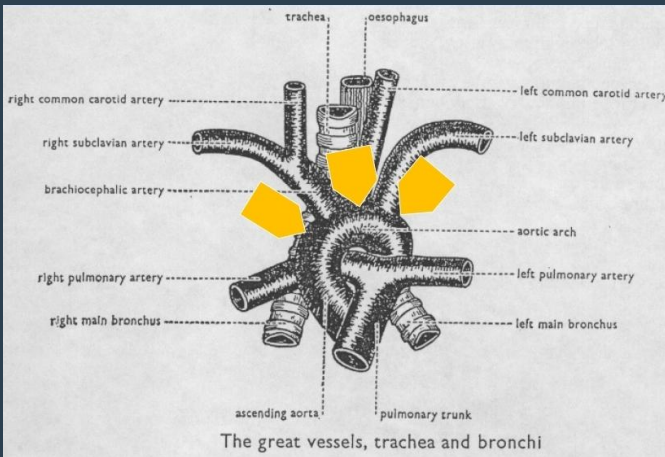
» Aortic Arch Anatomy

Another advancing revolution is MRI angiography. you can see the details of the heart and vessels, It can also show you the veins alone or arteries alone as well, but it takes around one hour while the CT takes less than 10 mins.



Heart and vessels

» Aortic arch/ great vessels » Aortic aneurysm



Aortic knob/knuckle

Large aortic knuckle, which means having aortic aneurysm which can be caused mainly by severe HTN, sometimes by dissection.

» Heart and vessels the slides were skipped by dr from here to page 18 (Star☆)

Cardiomegaly plus early Congestive Heart Failure (CHF)

Key:

1. Inferior vena cava (IVC)
2. Superior vena cava (SVC)
3. Azygos vein
4. Carina
5. Trachea
6. Right main stem bronchus
7. Prominent pulmonary vessels

Any and or all heart chambers may enlarge when the heart becomes diseased. Cardiomegaly = a big heart.

A patient's heart enlarges due to a number of diseases e.g. valve disease, high blood pressure, congestive heart failure.

If the heart fails, the lung often become congested. Early on the pulmonary vessels appear more prominent as in this case. More advanced failure can result in a condition of pulmonary edema which is fluid flooding into the alveoli of the lungs causing the patient marked shortness of breath.

» Cardiothoracic ratio

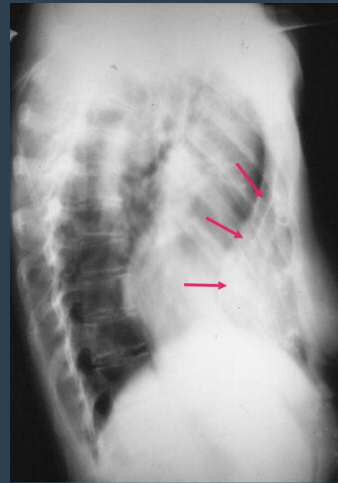
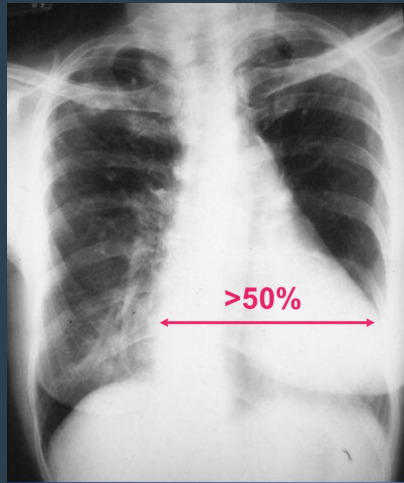
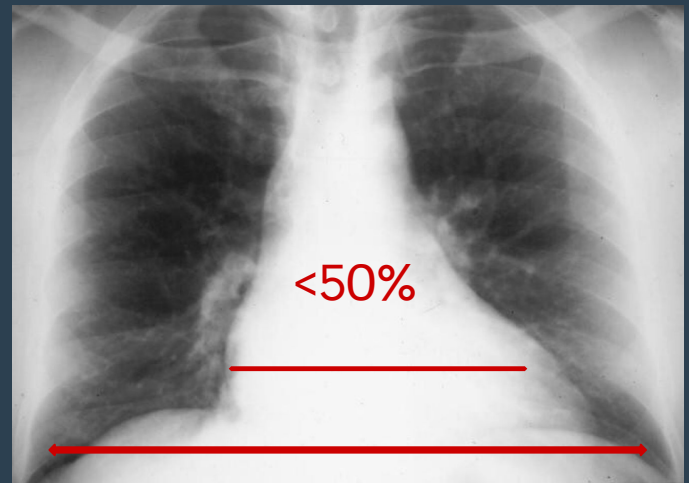
One of the easiest observations to make is something you already know:

- the cardiothoracic ratio which is the widest diameter of the heart compared to the widest internal diameter of the rib cage and it **must be <50%**.

(the X-ray must be posterior-anterior view)

It is not used anymore because sometimes you can get less than 50% but patient actually has cardiomegaly.

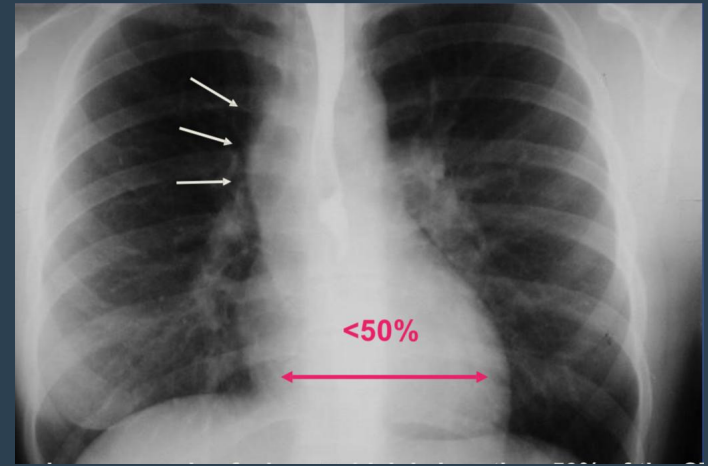
Sometimes, CTR is more than 50% But Heart is Normal



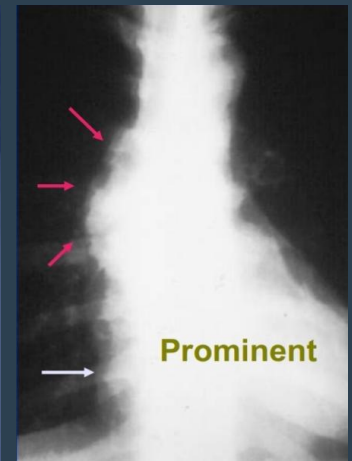
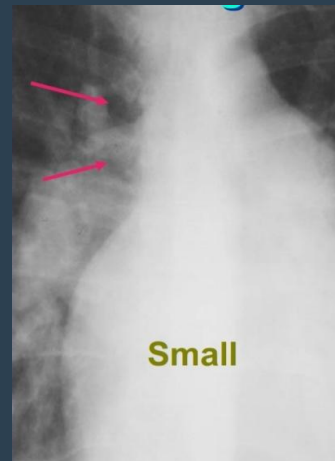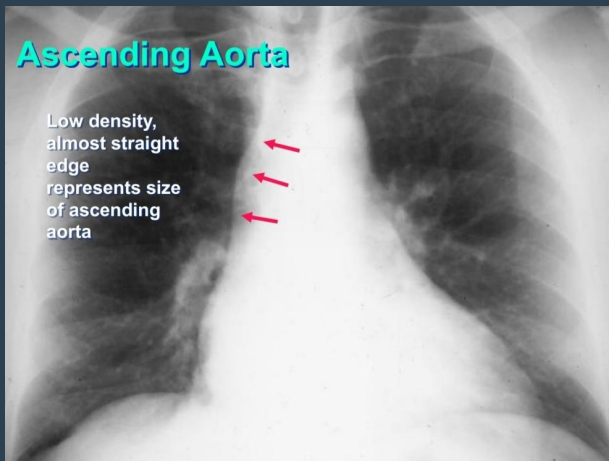
Here is a heart that is larger than 50% of the cardiothoracic ratio, but is still a normal heart. This is because there is an extracardiac cause for apparent cardiomegaly. On the lateral film, the arrows point to the inward displacement of the lower sternum in a pectus excavatum deformity

CTR is more than 50% but heart is <u>normal</u>	CTR is less than 50% But heart is <u>abnormal</u>
<p>Extracardiac causes of cardiac enlargement</p> <ul style="list-style-type: none"> - portable AP films - Obesity - Pregnant - Ascites - Straight back syndrome - Pectus excavatum 	<ul style="list-style-type: none"> - Outflow obstruction of ventricles , ventricle hypertrophy - Must look at cardiac contours

- Here is an example of a heart which is less than 50% of the CTR in which the heart is still abnormal.
- This is recognizable because there is an abnormal contour to the heart (arrows).



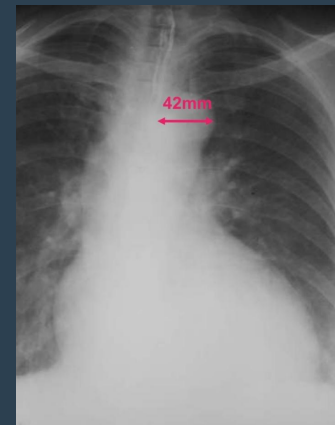» Ascending aorta



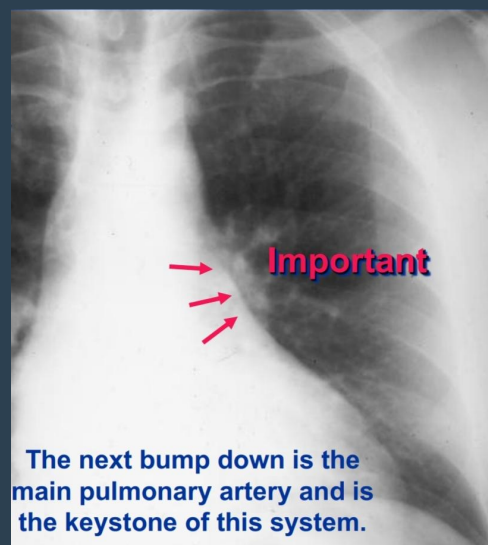
» Aortic knob (best characterized by CT with IV contrast)

Enlarged with:

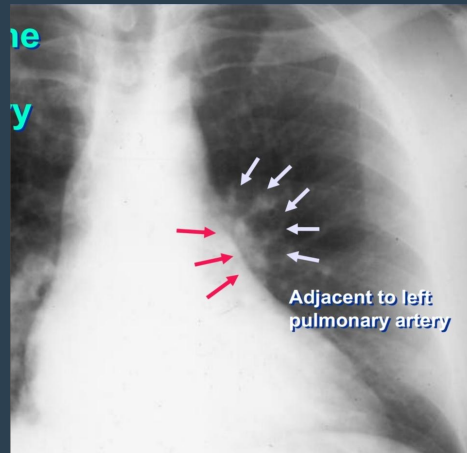
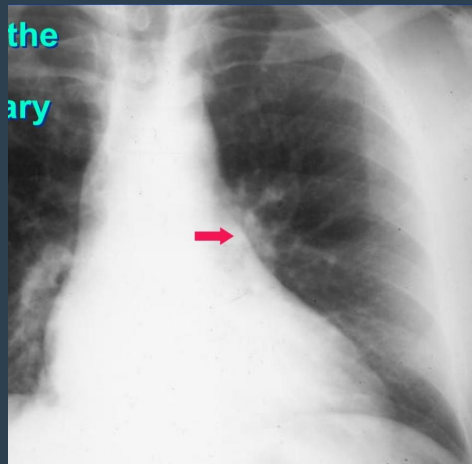
- Increased pressure
- Increased flow
- Changes in aortic wall



» Main pulmonary artery



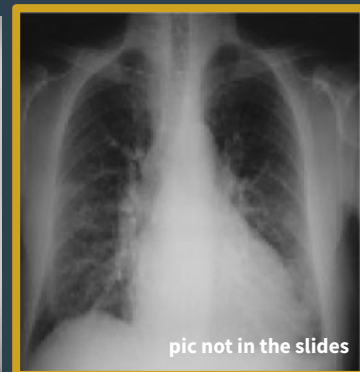
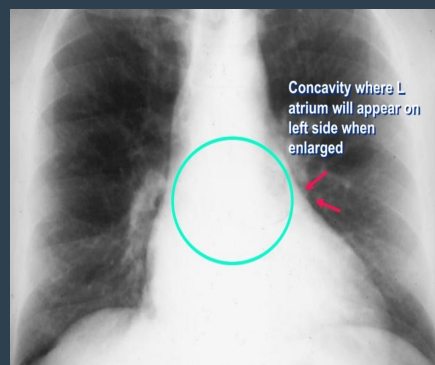
» Finding the main pulmonary artery



We can measure the main pulmonary artery

» Left atrial enlargement

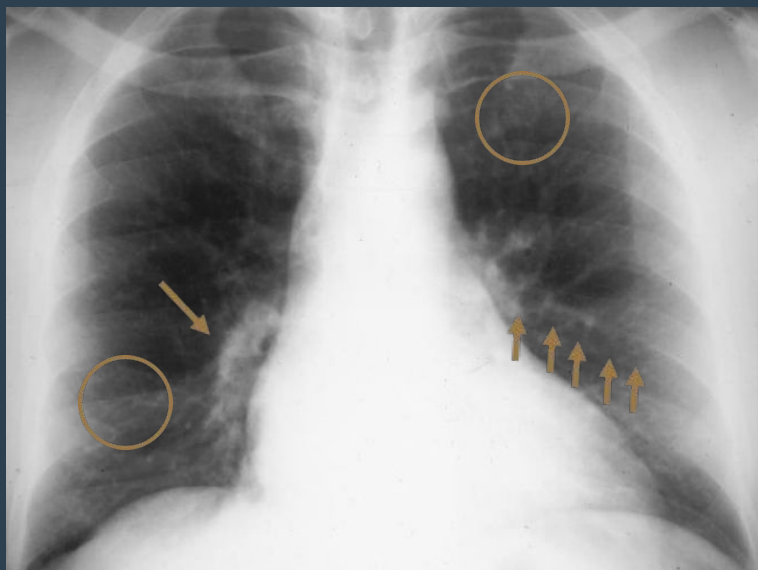
Concavity where L atrium will appear on left side when enlarged (circle)



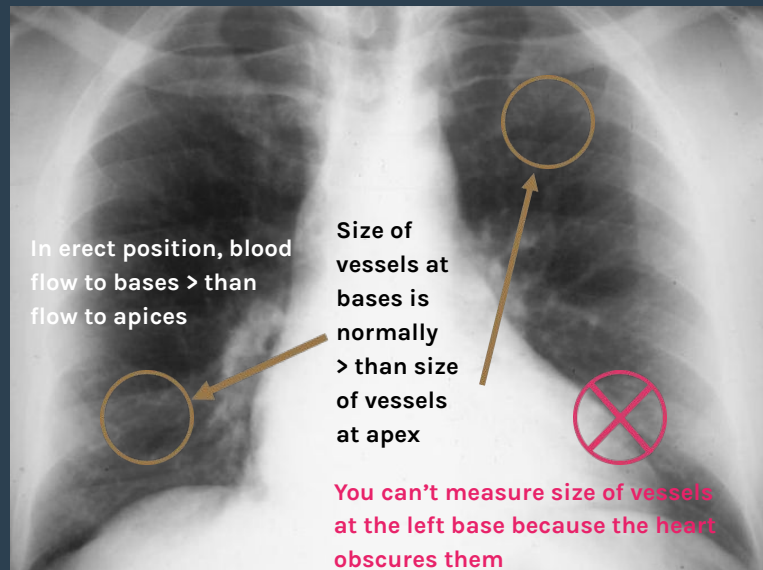
» The Pulmonary Vasculature

Five states of the pulmonary vasculature:

- Normal
- pulmonary venous hypertension
- Pulmonary arterial hypertension
- Increased flow
- Decreased flow

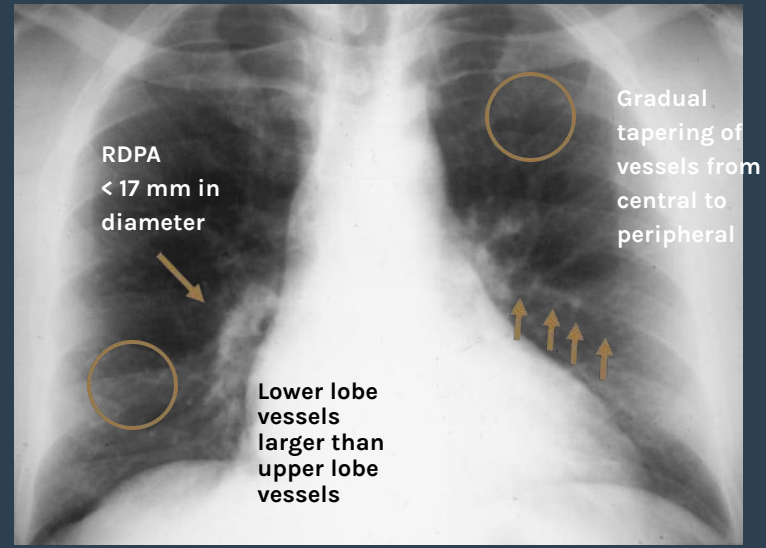
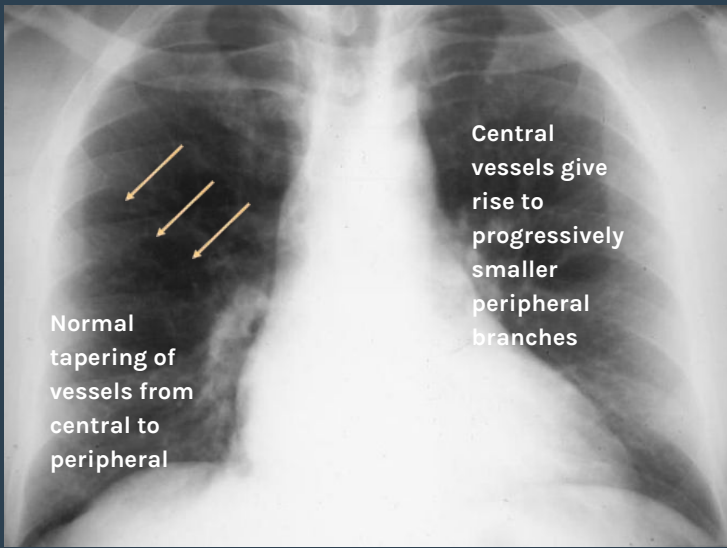


1) What to Evaluate



2) Normal Distribution of Flow
Upper vs Lower Lobes

The Pulmonary Vasculature

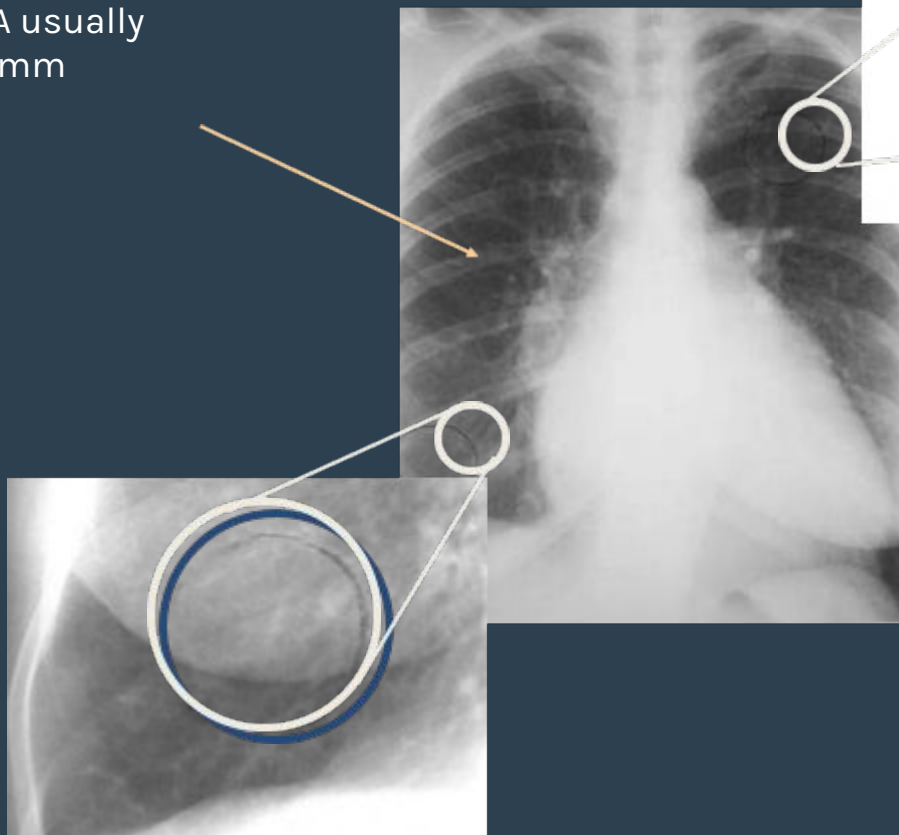


3) Normal Distribution of Flow
Central vs peripheral

Normal Vasculature - review

» Venous Hypertension

RDPA usually > 17 mm



Upper lobe vessels equal to or larger than size of lower lobe vessels = **Cephalization**

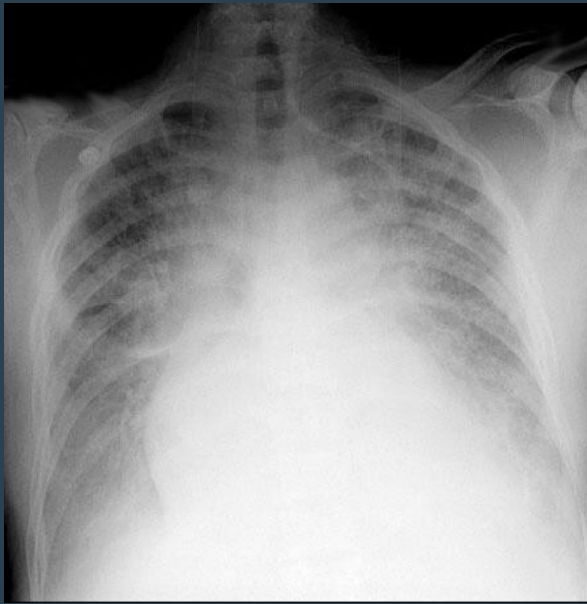
» The Pulmonary Vasculature Star☆ of happiness

- Normal
- Pulmonary venous hypertension
- Pulmonary arterial hypertension
- Increased flow
- Decreased flow - mostly unrecognizable even when it is present

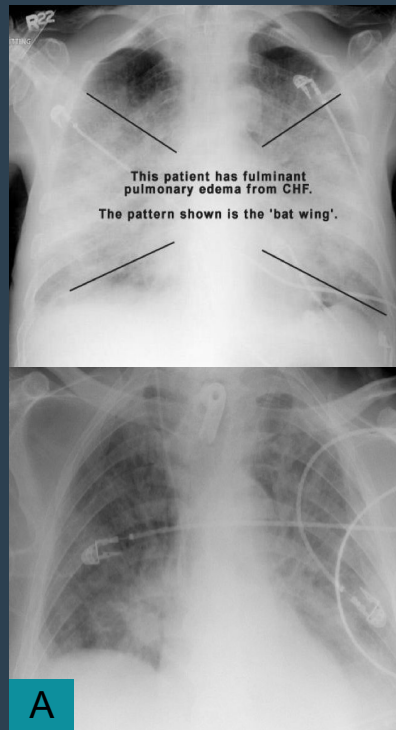
The Pulmonary Vasculature

» CHF VS APE Important

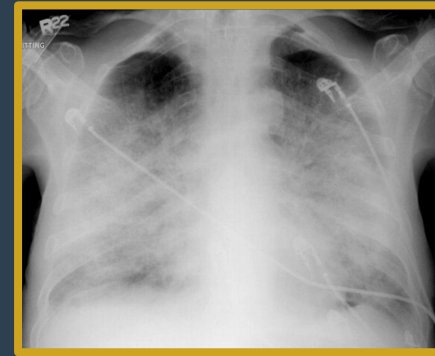
Congestive heart failure



Acute Pulmonary Edema



Cleared APE



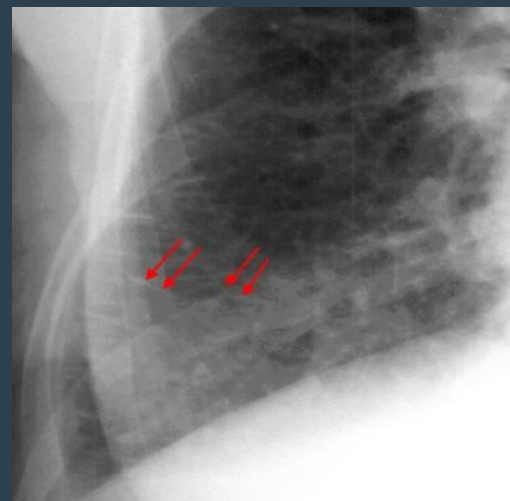
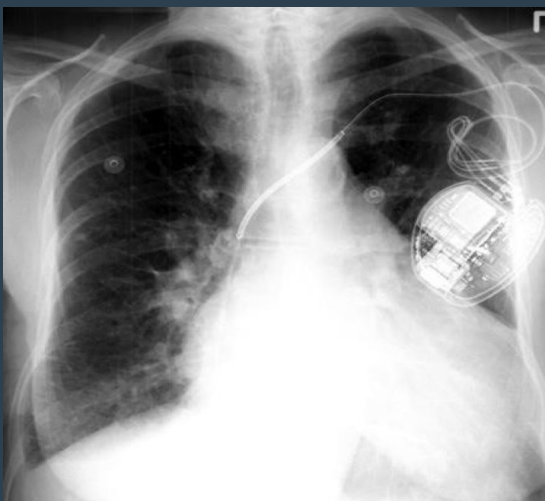
Congestive heart failure: Opacity in the lungs, ill defined cardiac contours, ill defined vessels, Increased cardiothoracic ratio.

- Heart failure can lead to pulmonary edema

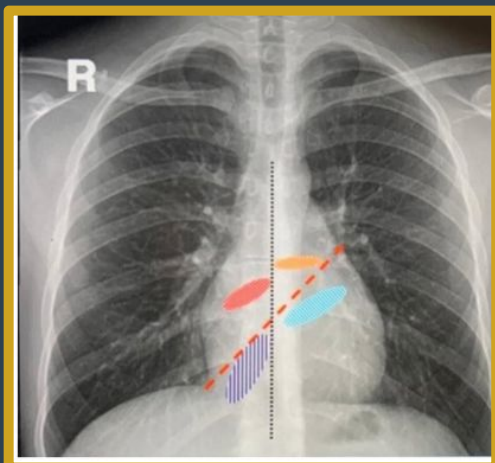
Acute pulmonary edema: One of supporting things is ill defined lung opacifications called **(Batwing/butterfly)**, indicative of acute pulmonary edema.

- Pneumonia is taking consolidation in the segment like middle lobe, right lower lobe but here is not taking segments **(butterfly or batwing)** so you have to suspect APE
- How to differentiate between pneumonia and heart failure? Pneumonia come with fever, heart failure maybe low-grade fever.
- We give the patient diuretics and redo the X ray. We will see improvement in the chest, the symptoms are improving and X-ray will be like in figure-A. This will not happen in case of pneumonia. So, this is **called diagnostic test**.

» Kerely's B-lines doctor said Not important, skipped by the doctor



	Advantages	Disadvantages
X-ray	Widely available, portable, cheap. Proper in assessing heart size & position. Lung assessment.	Use Ionizing radiation. Limited assessment of heart chambers and myocardium & valves & pericardium & mediastinum.
Angiogram	Minimal invasion. Proper in assessing and treating coronary diseases.	Use Ionizing radiation. Invasive procedure. Contrast complications.
Echocardiogram	Proper in assessing heart morphology & function by using doppler effect. Proper in assessing pericardial effusion.	Operator dependent. Not proper to assess coronary arteries.
CT scan	Gold standard for Pulmonary embolism. Proper in assessing heart anatomy, pulmonary artery, aorta & coronary arteries. Proper in assessing structure around the heart and mediastinal vessels.	Uses Ionizing radiation. Heart rate < 60 beat/min for an adequate cardiac exam. Intravenous contrast complications.
MRI	No Ionizing radiation. Better soft tissue Characterization. Proper in assessing myocardium, cardiac valves & aorta.	Not widely available. Contraindications (cardiac devices) Intravenous contrast complications.
Nuclear scan	Assess physiology/ pathophysiology. Proper in assessing myocardial perfusion & lung perfusion.	Use ionizing radiation. Not widely available. Poor in assessing anatomy.
V/Q scan	To diagnose PE. Includes ventilation phase and perfusion phase. Normal exam shows similar lungs uptake in ventilation and perfusion phases.	



Golden★

positions of heart valves on chest X-ray :

Light blue=mitral valve

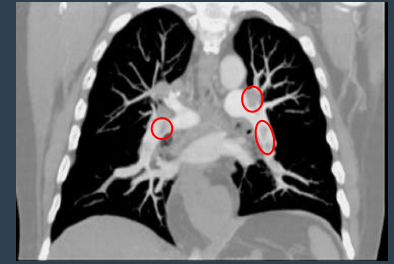
Purple=tricuspid valve

Orange=pulmonary valve

Red=aortic valve

» Pulmonary Embolism

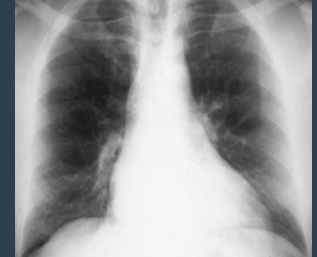- The most common findings on chest x-ray in case of PE is normal CXR
- The gold standard to diagnose PE is CT- angio



Normal	Homogeneous filling of the vessels	Indicate an Embolus	Filling defect
--------	------------------------------------	---------------------	----------------

» Cardiomegaly

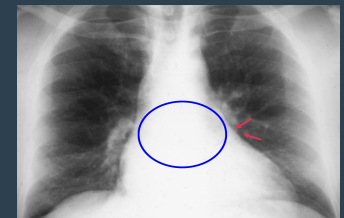
- When cardiothoracic ratio is more than 50%.
- But, it is not that accurate, there are some cases of abnormal heart with Cardio-thoracic Ratio less than 50% and cases of normal heart with cardiothoracic ratio more than 50%.



CTR>50% with normal heart	CTR< with abnormal heart
<ul style="list-style-type: none"> • portable AP films • Obesity • Pregnant • Ascites • Straight back syndrome • Pectus excavatum 	<ul style="list-style-type: none"> • Outflow obstructive of ventricles, ventricle hypertrophy • Must look at cardiac contours

» Left atrial enlargement

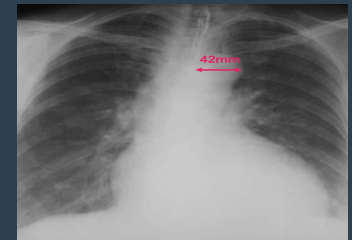- Concavity where Left atrium will appear on left side when enlarged



» Enlargement of the Aortic knob

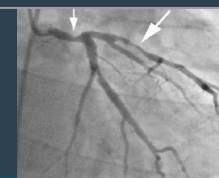
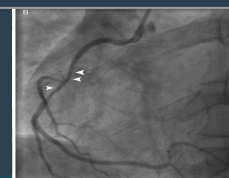
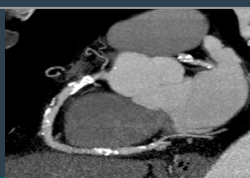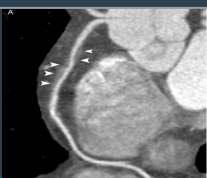
Occur due to:

- Increased pressure
- Changes in aortic wall
- Increased flow



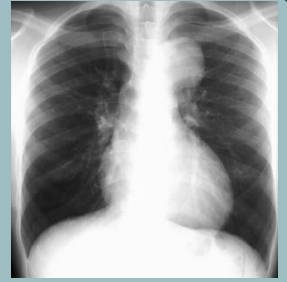» CT Angio vs Coronary catheter

CT- angio	Catheter Angiography
Less invasive,	invasive procedure
Immediate intervention is not applicable= non therapeutic	Immediate intervention is applicable=by stent
Usually we use it with young or low-risk of coronary artery disease patients	More time consuming
	We use it with high risk patients or patients with



1. 68 years old male, with BMI of 44.7. he started smoking before 40 years ago. CXR as shown, What is the diagnosis

- a. PE
- b. Heart Failure
- c. COPD
- d. Aortic Aneurysm



2-1. 36-year-old man who presents to your A&E department with shortness of breath, he has been immobile for 6 weeks because He has been in a plaster cast for a left sided lower limb injury which was removed last week. The oncall physician suspected PE. **What is the golden standard test to diagnose it?**

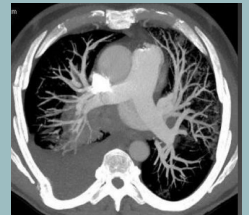
- a. Simple CXR
- b. CXR with contrast
- c. CT angiogram
- d. Spirometry

3- 22 years old man presented to ER with chest pain, he has very low probability of coronary artery disease, which modality is the best to use in this case?

- a. screening CT
- b. catheter angio
- c. CXR
- d. MRI

4- This is an CT Angiogram of 26 years old post c-section women, what is the diagnosis?

- a. coronary artery disease
- b. PE
- c. complicated parapneumonic effusion
- d. left heart failure



5- False positives high cardio thoracic ratio could be due to:

- a. sternal fracture
- b. sternal depression
- c. sternal elevation
- d. not related to sternum at all

6- What's the disadvantage of using CT angio (compared to catheter)?

- A) More time consuming
- B) Less accurate in localizing plaques
- C) Less information about heart and mediastinum
- D) We can't perform a therapeutic procedure.

Answers
1) D
2) C
3) A
4) B
5) B
6) D