



Radiology
Team 438


Radiology of urinary system diseases

Lecture 8

Objectives

- ❖ To know the principle disease entities of the urinary system organs and how they look in imaging.
- ❖ To correlate the clinical manifestations with radiological images

Reviewed By



Noura Alturki
Jehad Alorainy

Color Index:

♦ Important

♦ Doctor's Notes

♦ Extra

♦ Female slides

♦ male slides

Team Leaders



Omar Aldosari



Leena Alnassar



Shahd Alsalamh

Done by:

Fahad Alsultan

» Categories

1. Renal colic (KUB for ER then CT without contrast)
2. Infections (US then CT)
3. Urosepsis (CT with contrast)
4. Masses (US then CT with contrast)
5. Renal failure (different causes Have different imaging modalities)
6. Trauma (CT with contrast)

» Renal colic

- Caused by renal calculi **calcium oxalate stones**
- Most urinary calculi are calcified
- **Classic presentation:** (sudden onset of severe flank pain radiating inferiorly and anteriorly +/- nausea and vomiting **colicky type, radiates to the groin area and in men to the penis**)
- Diagnosis often made clinically
- **Imaging : to confirm and evaluate calculi**

Questions to ask

Are urinary stones present?
If so, what is the level and size?

Depending on the size the management will be different either conservative (medically) or interventional (surgery)

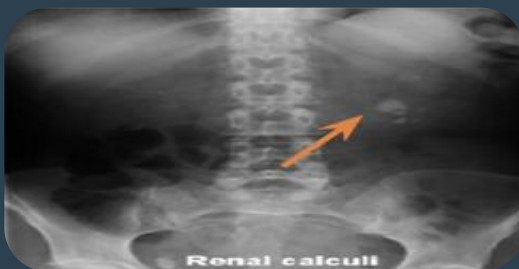Is obstructions present?
If so, what is the level and severity?

Severity: is it completely occluding the ureter and causing severe hydronephrosis? is their turbid urine? is their pyonephrosis? (we can see it on US and CT). If yes, it can cause severe sepsis which is fatal if it's ignored

Is urgent intervention required?

Think about intervention (percutaneous nephrostomy or ureteric stent) if the patient have the following symptoms

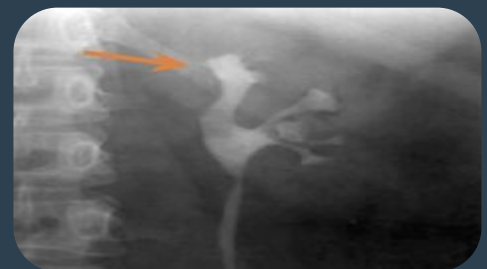- 1 Urosepsis
- 2 Solitary kidney
- 3 Severe pain



- **KUB:** to assess total stone burden, size, shape, location.
- Often US or CT is required in conjunction. **multiple renal stones on left pelviureteric junction**



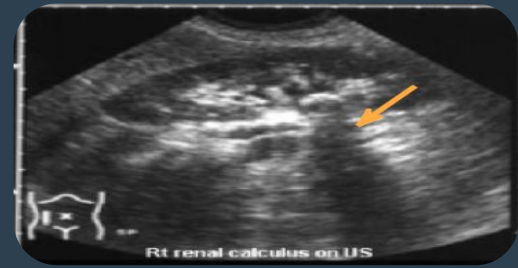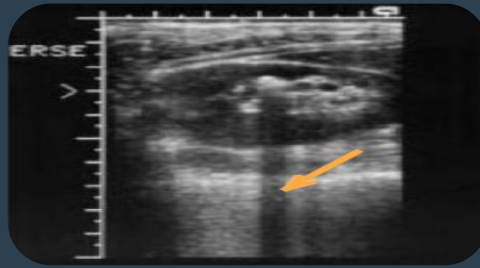
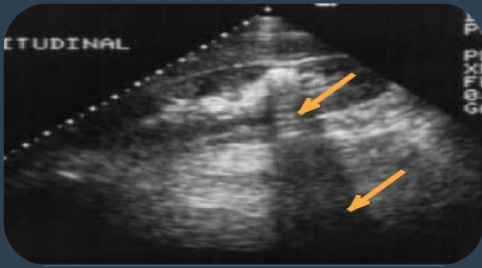
Radiolucent uric acid stones are not seen. Here you only see the bowel gas (air=black)



Radiolucent uric acid stones Here in the IVP we see filling defect due to mild obstruction and dilation of the superior calyces (arrow) causing mild hydronephrosis

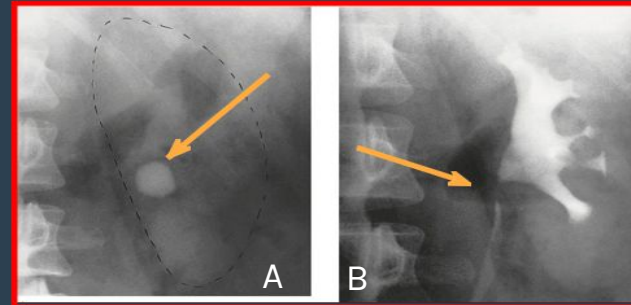
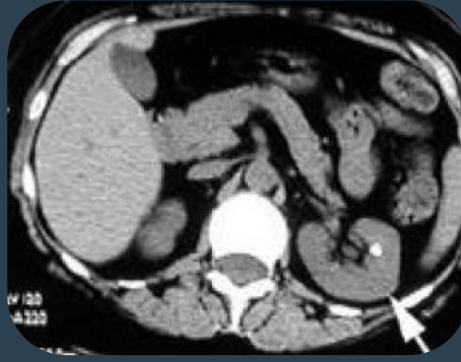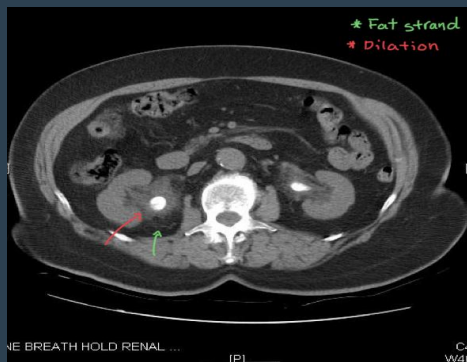Renal, Bladder Calculus

➤ Renal Calculus (US)



Renal stones in US (hyperechoic structure) with a **shadow behind**.
The shadow is important because we can't say its stone without the shadow.
NO signs of obstruction = No dilation

➤ Renal Calculus (CT), X-ray



Bilateral pelvic ureteral obstruction caused by hyperdense structure (stone) with dilatation of pelvicalyceal system and fat strands around caused by inflammation

Non obstructive renal stone with no dilation of renal calyceal system "pelvicalyceal"

A) rounded calcification is seen overlying the left kidney in the anteroposterior plain film.
B) Post contrast film in the same patient. As the contrast medium and the calculus have the same radiographic density, the calculus is hidden by the contrast medium
Calcification has the same density of contrast so it is **important** to start study with non contrast first

Causes of dilated calyces=**hydronephrosis**

VERY Important!

Due to obstruction, with dilatation down to a specific point of hold-up

Within the lumen
=**ducts**

Within the wall of the collecting system
=**attached to the wall**

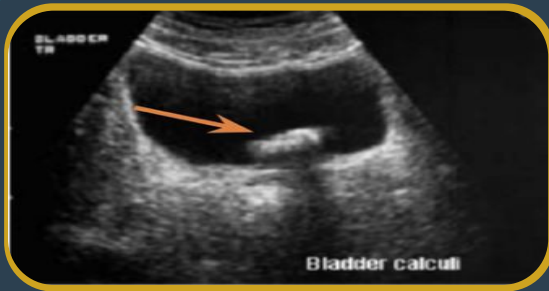
Extrinsic compression
=**from outside**

Due to papillary atrophy or destruction

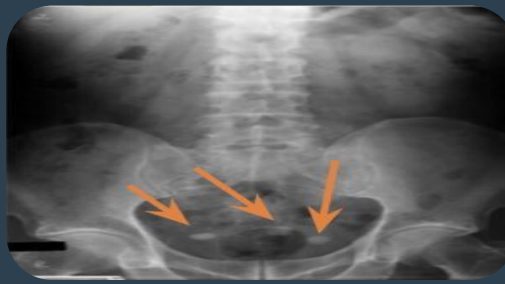- Calculus
- Blood clot
- Sloughed papilla
- Intrinsic pelviureteric junction obstruction
- Transitional cell tumour
- Infective stricture (e.g. tuberculosis or schistosomiasis)
- Retroperitoneal fibrosis
- Pelvic tumour (e.g. cervical, ovarian or rectal carcinoma)
- Aberrant renal artery or retrocaval ureter
- Reflux nephropathy
- Papillary necrosis
- Tuberculosis

Bladder Calculus

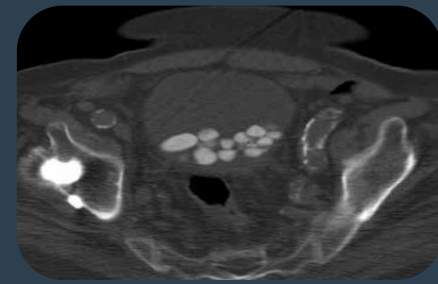Bladder Calculus



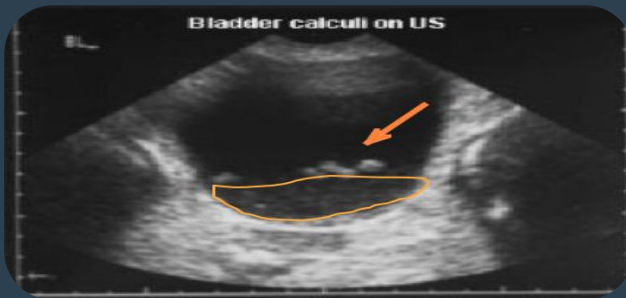
US: hyperechoic structure with shadow behind bladder stone



Multiple radiopaque opacities in the bladder. An example of bladder calculi in KUB



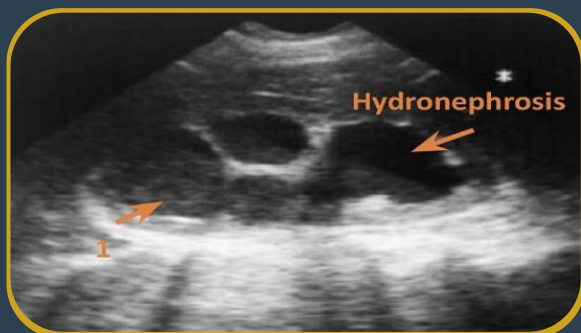
In CT: axial section; multiple bladder stones



- 1- Bladder stone with some **turbulent urine** that could be infected due to inflammation
- 2- Stones will appear white=hyperechoic. The reason of the absence of shadow is (the urine in the bladder is dark and the shadow is dark).
- 3- Fluid (urine) will appear black

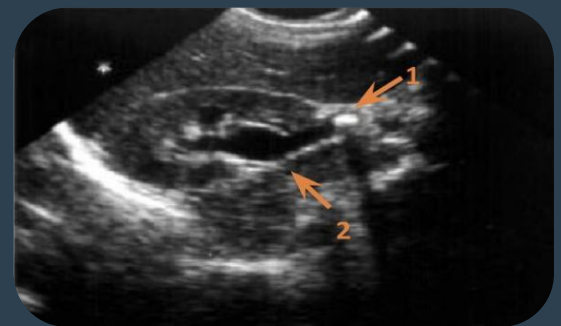
Urosepsis

- ❖ Risk factors: if the UTI (pyelonephritis, cystitis, prostatitis) left untreated and immunocompromised patients
- ❖ Establish a clinical diagnosis: Pyelonephritis, cystitis, prostatitis.
- ❖ Urosepsis and obstructed ureter is **urologic emergency**, so we have to relieve obstruction by treating the underlying cause and insert stent or perform nephrostomy
- ❖ Renal US is performed to rule out:
 - Renal obstruction
 - Renal or perirenal abscess which has to be evacuated or drained



Left pyonephrosis

We see severe **dilated** pelvic calyces with echogenic turbid content which should be black., but here the echogenicity (not completely black) means there is pus

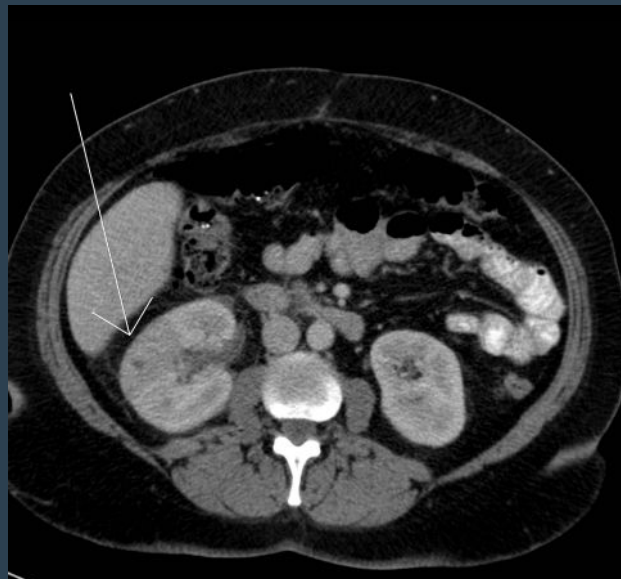


right UPJ stone

causing hydronephrosis
1=stone
2=showing dilated calyces

» Acute Pyelonephritis

- Life threatening infection & medical emergency, it cause urosepsis and septic shock.
- Ascent through lower urinary tract.
- Early diagnosis and management has significant impact on patient outcome.
- **Presentation:** (Fever, loin pain, nausea/vomiting), Diagnosed mainly clinically. Colicky pain in lumbar region
- **Predisposing factor:**
 - Stones
 - Reflux
 - obstruction=pregnancy
 - Diabetes
 - Obesity, female anatomy (short urethra).
- Pregnant women are more prone to acute pyelonephritis, why? because they have short urethra.
- the changes in the hormones slows the flow of the urine, as a result, bacteria have more time to grow in the urine before being flushed out. Also, as the uterus grows, the increased weight can block the flow of urine from the bladder, causing an infection.
- The diagnosis of pyelonephritis is based on clinical diagnosis but we do CT just to confirm the diagnosis and to exclude other diseases.
- In case of Acute Pyelonephritis, the functions of the kidney are decreased; that's why it doesn't take the contrast and we can confirm that the patient has pyelonephritis. The correlation always with clinical picture will rule out other infections.



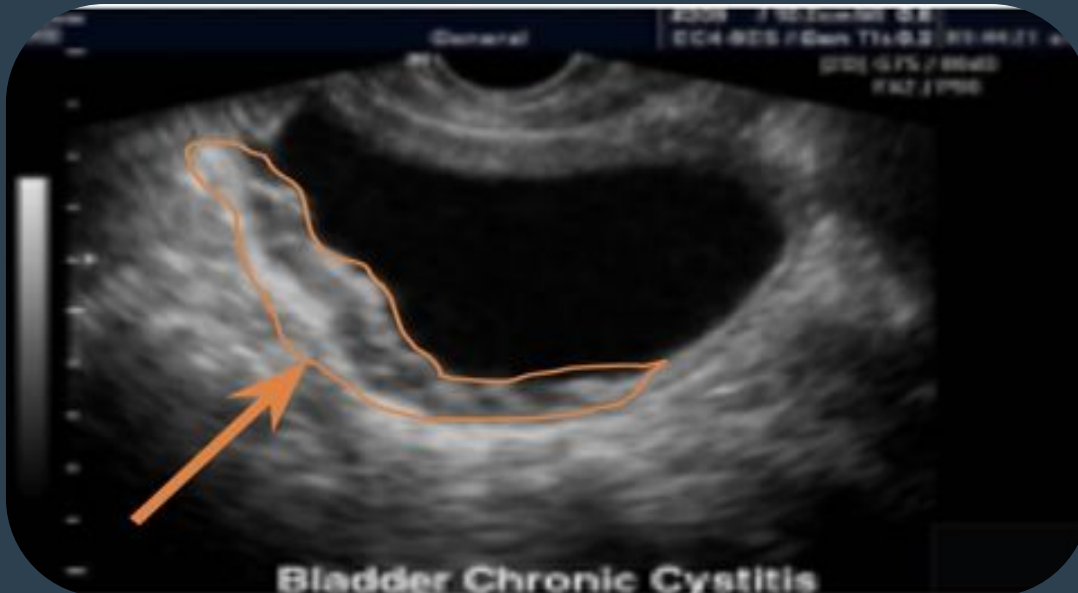CT with contrast injection pyelonephritis

Wedge shape hypoperfused lesion.

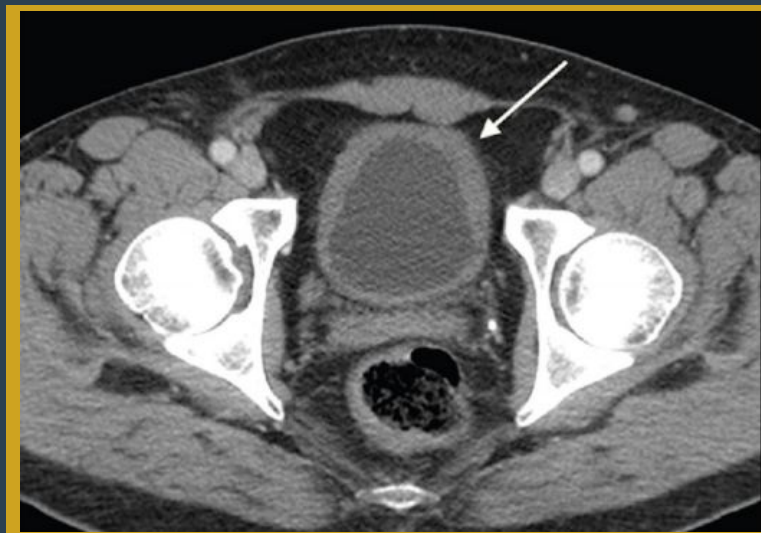
Congested right kidney with fat strands appearing grey in color (clear strands should be almost black), there is no differentiation between cortex and medulla cause the area is not taking the contrast as it is a hypofunctional hypoperfused lesion

» Cystitis

- Presentation: (Fever, suprapubic pain, frequent urination, In addition to lower urinary tract infection symptoms(frequency, burning, foul smell urine, turbid)
- As upper UTI, more common in females because of short urethra
- E-coli is the most common causative organism



US showing thick bladder wall with little turbid urine.(normally bladder is thin with anechogenic content and the urine should be black in both US and CT)



CT with contrast showing Thick urinary bladder wall
Normally it's 3mm here it's 5-6mm and fat strands

Renal Masses

Most solitary renal masses are either

malignant tumor

simple cyst

In adult: almost certain to be a renal cell carcinoma (RCC)

Young children: usually Wilm's tumor

Other causes of renal mass

- ❖ renal abscess
- ❖ benign tumor (Oncocytoma, angiomyolipoma)
- ❖ metastasis

Multiple renal masses include:

Metastases

Multiple simple cysts

Polycystic disease

Malignant lymphoma

Inflammatory masses

Approach to renal mass

Most renal masses are simple cysts

we find them by coincidence when we do the US for other reasons And we usually ignore them and dont follow up

Use US to characterize the mass:

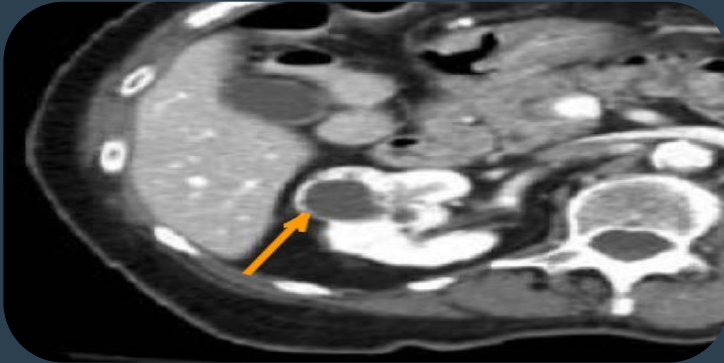
- Simple cyst: STOP.
- Solid mass or atypical cyst: CT with IV contrast.

-US and CT characterize > 90% of masses > 1.5 cm

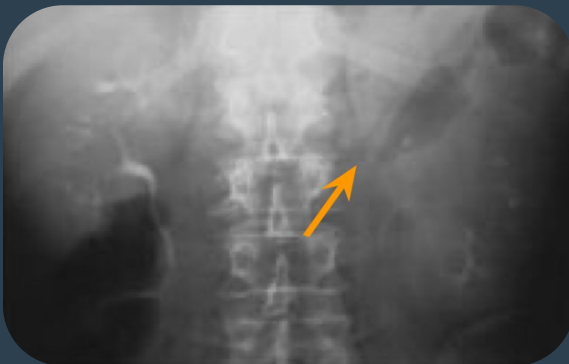-Biopsy is rarely warranted

» Renal Carcinoma

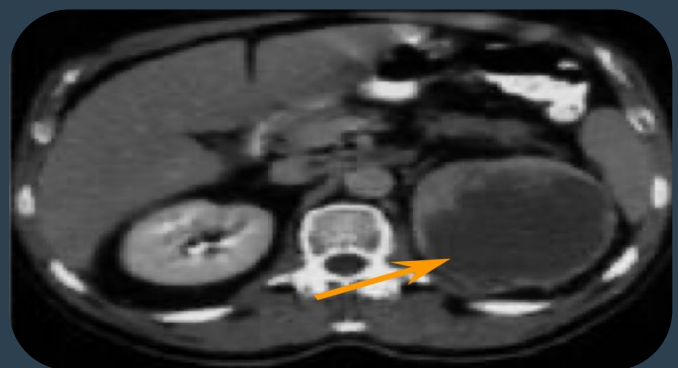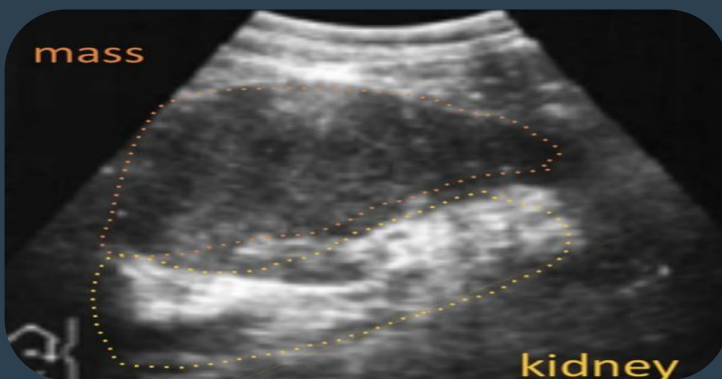- If US indicates that the mass is solid=**serious indication**, we must do CT with IV contrast can characterize the tumor in greater details.
- Delineate extent will show
 1. Degree of the vascularity.
 2. Presence/absence of the necrotic tissue center.
 3. Presence/absence of local invasion of adjacent structures



CT with IV contrast in the corticomedullary phase showing mass occupying the anterior part of right kidney with anterior thickened wall and necrotic center. malignant renal tumor



Distortion of left Pelvicalyceal System in IVP. Completely irregular, contrast filling some of the calyces, no smooth passage of contrast in proximal ureter



- Solid left renal mass in a patient with micro hematuria.
- US shows echogenic structure in the left kidney with hypoechoic on the center
- CT with contrast shows in left kidney a mass with cystic content, and thick irregular wall enhanced with contrast and necrotic center.

» Renal Cyst

US will determine if the lesion is cystic or solid

There are **two types of renal cysts**:

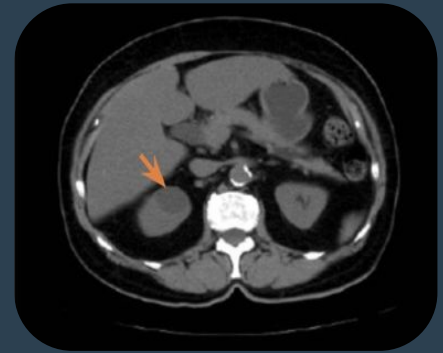
- **Simple cyst**

Spherical, **Echo-free** fluid collection within a thin surrounding wall and will show good sound wave transmission.

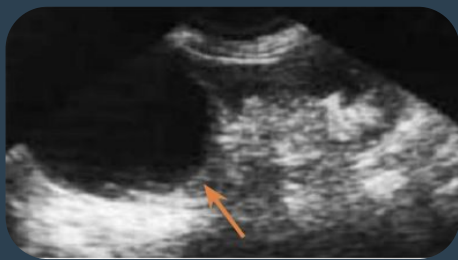regular in US= anechogenic structure inside = black
no thickening, no calcification, no septation

- **Complicated cyst**

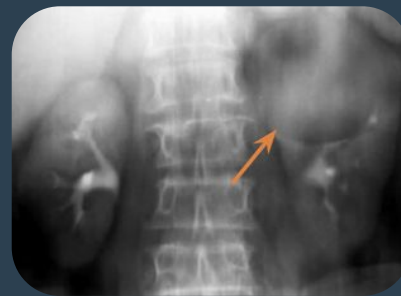Will show the presence of echoes within the cyst,
Will have a thick wall, And/or calcification in the wall.
it's not only a simple fluid.



CT showing round hypodense lesion Of anterior part of the right kidney, no calcification or thickening of the wall, density is about 0-15 Hf units. simple cyst



Simple Cyst on US
Anechoic content no thickening



Left renal mass on IVP
Regular round mass in upper pole of left kidney

» Renal adenocarcinoma

- 90% of all renal malignancies.
- 15-30% metastatic at diagnosis.
- Hematogenous and lymphatic spread.
- 10% have venous invasion so there is thrombosis either in renal vein or IVC

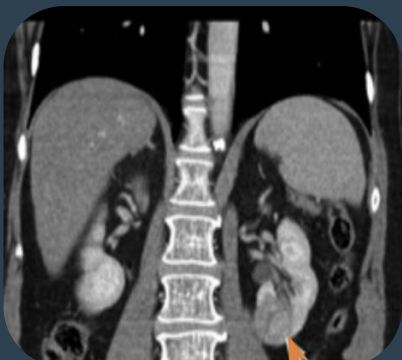
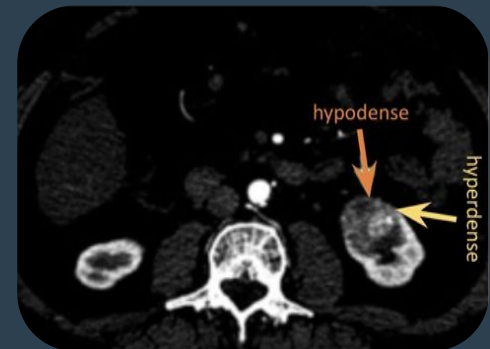
Treatment:

- Radical Nephrectomy.
 - Mostly it's the treatment of choice
- Partial Nephrectomy.

Case: 70 y/o female presented with painless hematuria:

CT with contrast showing Upper pole malignant mass lesion of the Left anterior part of the Kidney with heterogeneous enhancement.

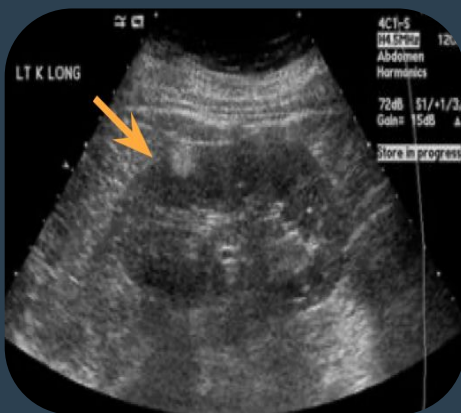
Right kidney is well differentiated, no fat strands and check lymph nodes for metastasis



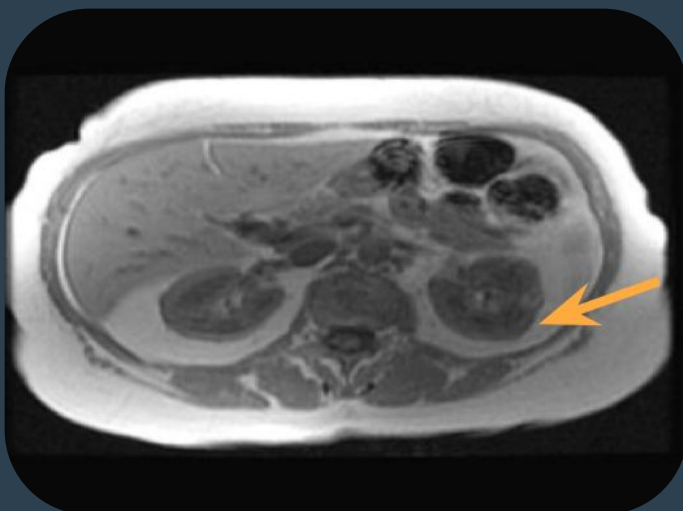
On the frontal section of CT we see the heterogenous mass with bulging and fat strands around

» Renal Angiomyolipoma

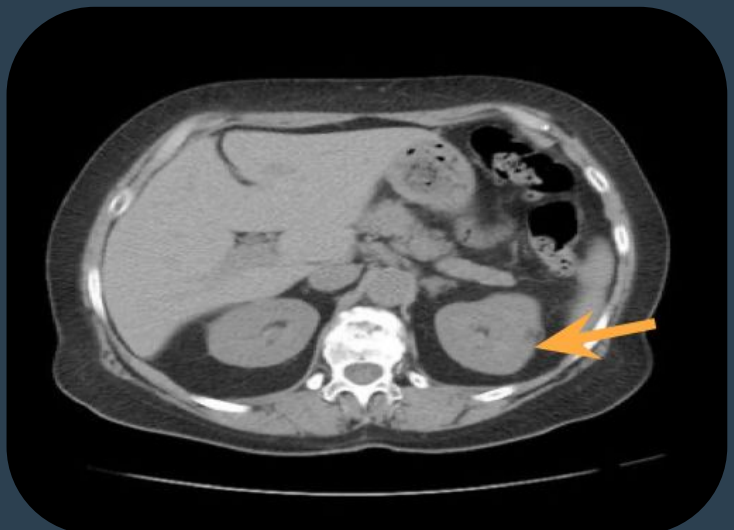
- Benign hamartomatous tumor composed of **fat**, smooth muscle and vessels.
- Usually asymptomatic.
- Occasionally present with hemorrhage when large or multiple **and we have to embolize it to control this hemorrhage.**
- **Fat detected in 96% by CT**
- Diagnostic key to angiomyolipoma is detection of fat surrounding the kidney.
- Angio= vessels, myo= muscle, lipo= fat & oma= benign tumor.
- Embolization is a minimally invasive treatment that occludes, or blocks, one or more blood vessels or vascular channels of malformations (abnormalities).



Example of angiomyolipoma in US showing sagittal section of kidney showing Round hyperechogenic mass in the upper pole of the cortex of the left kidney. (fat is hyperechoic)



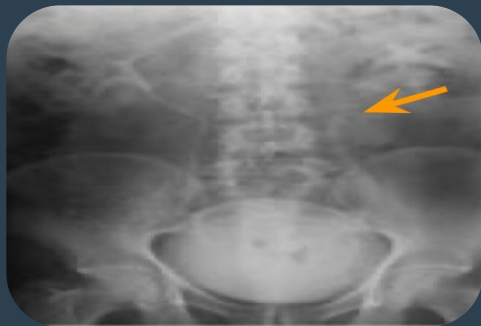MRI: hypersignal lesion



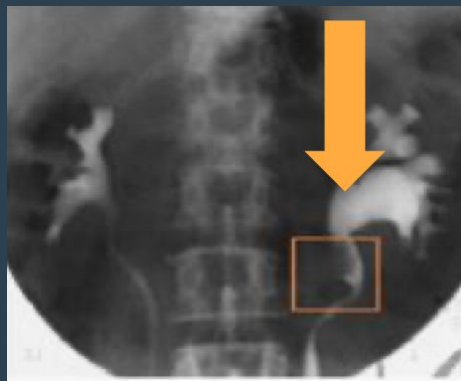
CT: Hypodense lesion (so contains fat) of the left kidney on the cortex

» Transitional Cells Carcinoma (TCC)

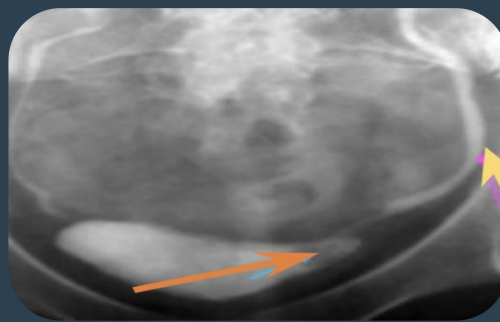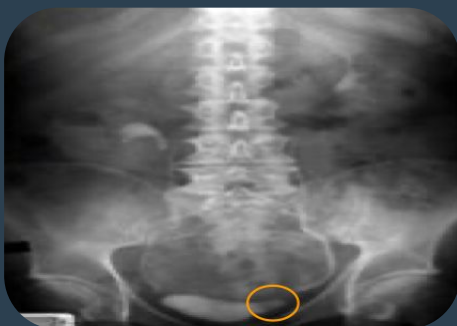- Most common malignancy of ureter and bladder.
- <10% of renal malignancies.
- Typically present with gross hematuria.
- CT for staging and surgical planning. **and diagnosis**
- Treatment: radical nephrectomy.



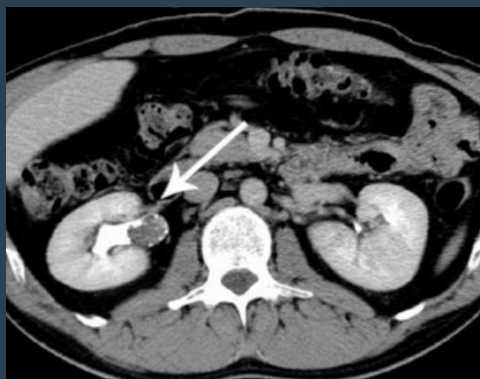
IVP (left radiograph) and retrograde pyelogram (right radiograph) TCC proximal left ureter.



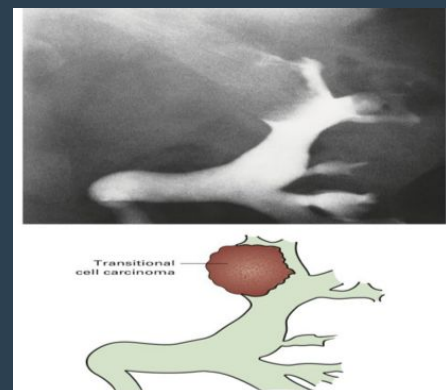
IVP shows distortion of part of the ureter with ureteropelvic junction obstruction and dilatation. TCC was discovered here in left proximal ureter as filling defect. We did IVP and we saw the right kidney is ok but on the left kidney we can see ureteropelvic junction obstruction and dilatation, so we inject the contrast retrograde pyelogram and we saw there is filling defect in left proximal ureter, so this is Transitional Cells Carcinoma.



Small TCC of bladder in patient with hematuria
Small bladder mass with dilation of the ureter



CT + contrast in the excretion phase Large TCC on the right renal pelvic seen as filling defect (the arrow) of proximal ureter caused by the tumor preventing the passage of the contrast. remember the phases (arterial 30-40s, venous 80s, corticomedullary 3m, excretory 8-10m)

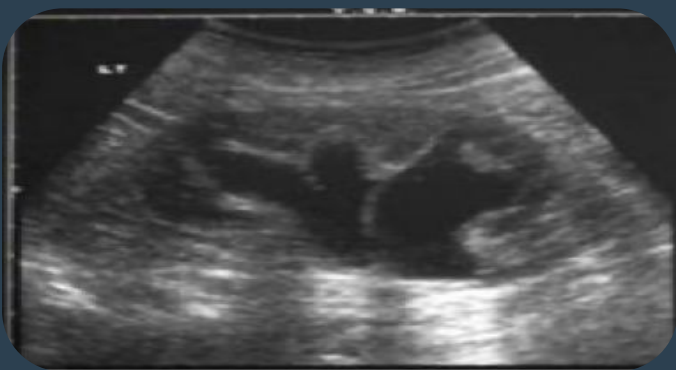

Filling defect in the margins and not obstruct the lumen so CT urography is done to see contrast in collecting system.
TTC

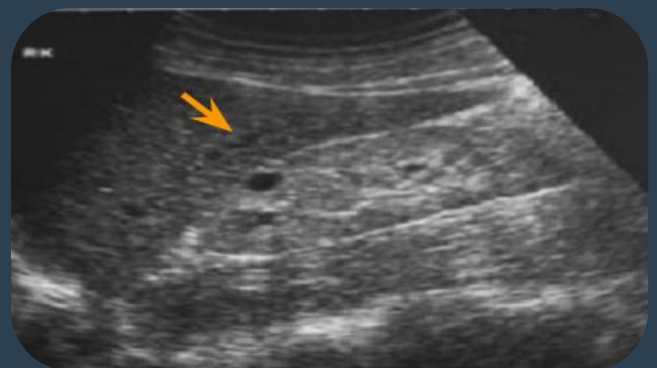» Renal Failure

Acute and Chronic Renal Failure

Clinical categories	Prerenal (dehydration, shock, cardiac failure)	Renal (parenchyma, diabetes, GN, drugs, renovascular e.g. chronic renal artery stenosis, renal vein thrombosis).	Postrenal (obstruction)
IV contrast	contraindicated if creatinine >200 mmol/dl (Patient will go into ARF so if needed dialysis is organized after the session)		
Use US to assess	Renal size (If kidney is less than 7 cm=atrophic kidney)	Parenchymal thickness Thickness should be more than 1.5-2 cm, if there is cortical thinning than suggests loss of renal function	US guided renal biopsy is important to establish diagnosis If patient comes with high creatinine and low creatinine renal clearance. by taking part of the kidney with biopsy needle percutaneously under ultrasound guidance.



Hydronephrosis post-renal
 Caused by long standing obstruction



Atrophic less than 7 cm, echogenic kidney

- No differentiation between the cortex and medulla (Undifferentiated kidney = non functioning kidney).
- The arrow is pointing at a simple cyst.

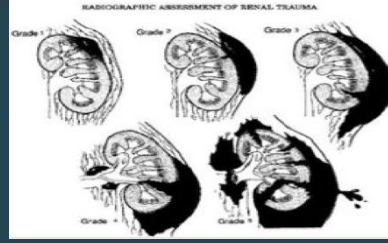
Penetrating Trauma (gunshot, stab)

Unstable

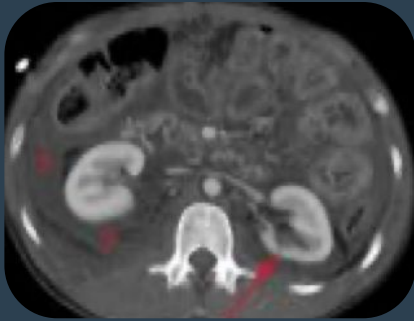



Do surgery or angiography
To stop the bleeding

Stable

Do CT with IV contrast
used to grade the trauma

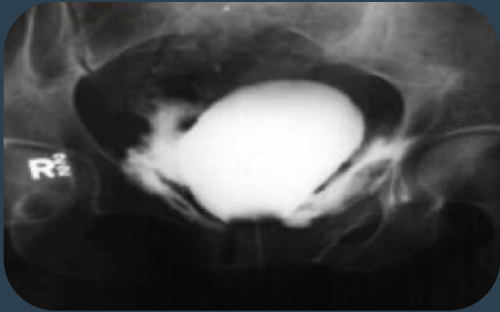


Radiographic assessment of renal trauma

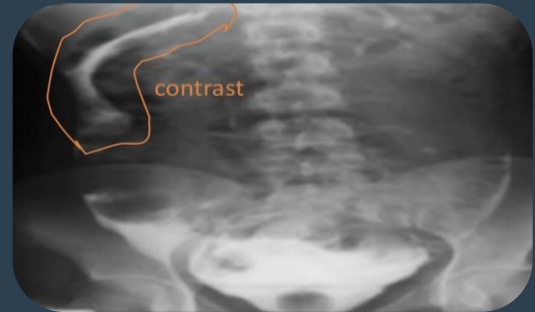Grade 1	Subcapsular Hematoma, only contusion (a bruise) of the kidney	 <p>Grade 1-2 injury CT showing some hematoma</p>
Grade 2	laceration in the cortex <1cm	
Grade 3	>1 cm but not extending into collecting system	 <p>Grade 3 injury Laceration Not extending to the collecting system, discontinuation of renal cortex</p>
Grade 4	Laceration with hematoma Extend to pelvicalyceal system the patient will have hematuria	 <p>Grade 4 injury Deep laceration with perirenal hemorrhage, hematoma around kidney</p>
Grade 5	Shattered kidney completely around the kidney	 <p>Grade 5 injury Thrombosed renal artery In CT scan, the kidney is non enhanced at all, there is thrombosis of the right renal artery which completely cut down. In angiography, we don't see the right kidney at all</p>

» Bladder Injury

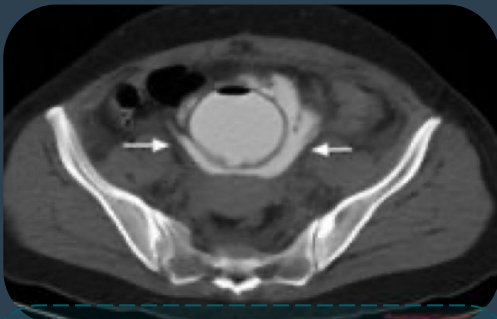
- Bladder injury is either extraperitoneal or intraperitoneal. In trauma patient we see blood at urethral meatus we should do retrograde cystography "Inject contrast by retrograde catheter" then can see whether the contrast extra or intra peritoneal.



Extraperitoneal bladder rupture
Contrast around urinary bladder



Intraperitoneal bladder rupture
contrast in peritoneum



CT showing extraperitoneal bladder rupture with contrast extravasation around the urinary bladder

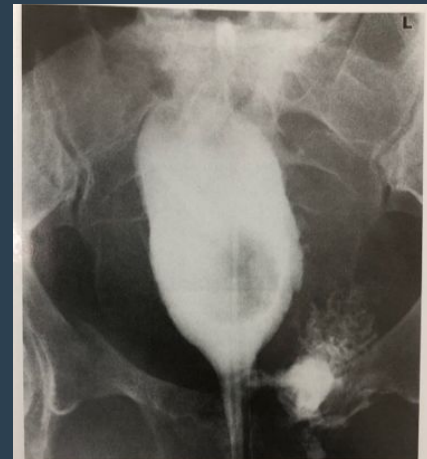
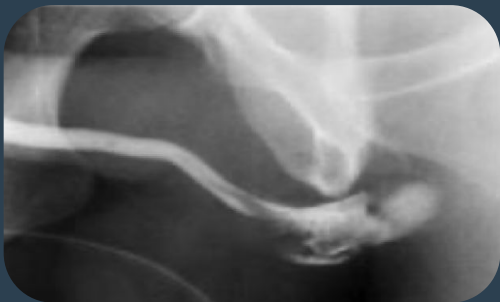
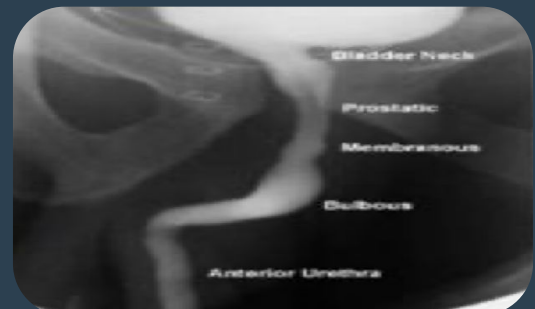Fig. 8.56 Rupture of the base of the bladder. Cystogram showing extravasation of contrast into the extraperitoneal space on the left, and deformity of the bladder due to surrounding haematoma and urine.



Traumatic rupture of bulbous urethra



Normal retrograde urethrogram

Summary

Renal calculi

- The diagnosis of renal calculi is often made clinically, common symptoms of renal calculi include: sudden onset of flank pain radiating to the ipsilateral groin and sometimes associated with hematuria, nausea and vomiting.
- The diagnosis of renal calculi is confirmed and evaluated using various imaging techniques (KUB, CT, US)
- Renal calculi can be radiopaque (visible on x-ray and CT) or radiolucent (invisible)

Infections

- Acute pyelonephritis: Mainly due to an ascending bacterial infection (eg. E.coli, enterococcus and proteus), Individuals are usually presented with fever, loin pain, nausea and vomiting, on CT with contrast a wedge shaped hypoperfused lesion is seen in acute pyelonephritis.
- Cystitis: Infection of the urinary bladder, symptoms include fever, suprapubic pain and polyuria, More common in females, The wall of urinary bladder is thick and regular on CT and US
- Urosepsis: sepsis due to UTI, Renal US is performed to rule out renal obstruction or renal/perirenal abscess.

Renal masses

Most solitary renal masses are either malignant tumor or simple cyst (benign), US and CT characterise >90% of renal masses >1.5cm (biopsy is rarely warranted), US will determine if the lesion is cystic or solid. If solid, CT with IV contrast can characterise the mass in greater detail.

- Renal cysts
- There are two types of renal cysts
 - Simple cyst: Spherical, anechogenic, no thickening wall, regular wall
 - Complicated cyst: Echogenic, thick wall +/- calcification in the wall
- Renal Adenocarcinoma
 - 90% of all renal malignancies, Exophytic renal mass with cystic content and irregular wall, Treatment: radical or partial nephrectomy
- Renal Angiomyolipoma
 - Benign hamartomatous tumor composed of fat, smooth muscle and vessels, Usually asymptomatic, Detected by CT.
- Transitional cell carcinoma
 - Most common malignancy of ureter and bladder, Usually seen as filling defect, CT for staging and surgical planning, Treatment: Radical nephrectomy.

Acute and chronic renal failure

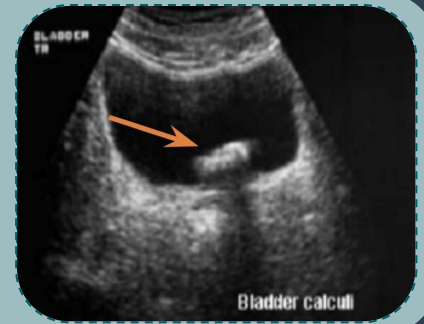
Acute	Kidney is enlarged in size	Oedematous	Obstruction	
Chronic	Kidney is small in size	No darkness in the cortex	Bright echo pattern	cysts can be seen

GU trauma

- Unstable: Surgery or angiography
- Stable: CT with contrast to grade the trauma

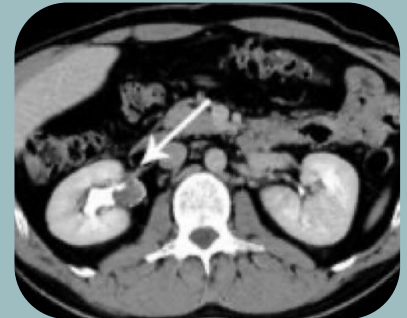1- Young adult presented with right flank pain and blood in urine . Ultrasound exam was performed. Which of the following is most likely the diagnosis:

- a. Bladder calculi
- b. normal US
- c. Hydronephrosis
- d. renal cyst



2- 60 years old male presented to the emergency with gross hematuria CT was done which of the following is correct:

- a. TTC
- b. Renal stone
- c. Pyelonephritis
- d. Normal CT



3-which level of creatinine is contraindicated to give IV contrast in renal failure patient?

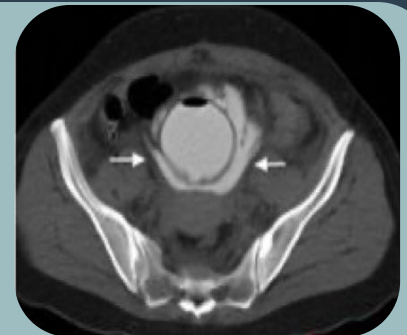- a. >200 mmol/dl
- b. 133 mmol/dl
- c. 150 mmol/dl
- d. 50 mmol/dl

4- Which of the following is a common site of urinary stone obstruction?

- a. Junction of mid-distal ureter
- b. Vesicoureteric junction
- c. Proximal ureter
- d. Mid ureter

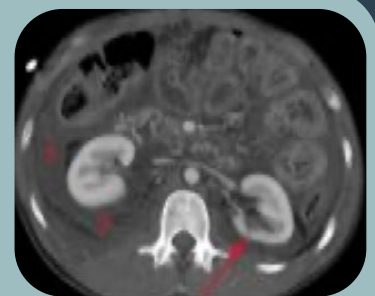5- A CT was done to a patient after transurethral resection of bladder tumor and the CT shows:

- a. Renal injury
- b. Bladder injury
- c. TCC
- d. Renal mass



6- A 43 years old Pakistani gentleman came to the ER with a stab wound to the right kidney. A CT was performed. What's most likely the diagnosis

- a. Grade 1-2 injury
- b. Renal calculi
- c. Grade 4 injury
- d. Normal CT



Answers
1) A
2) A
3) A
4) B
5) B
6) A