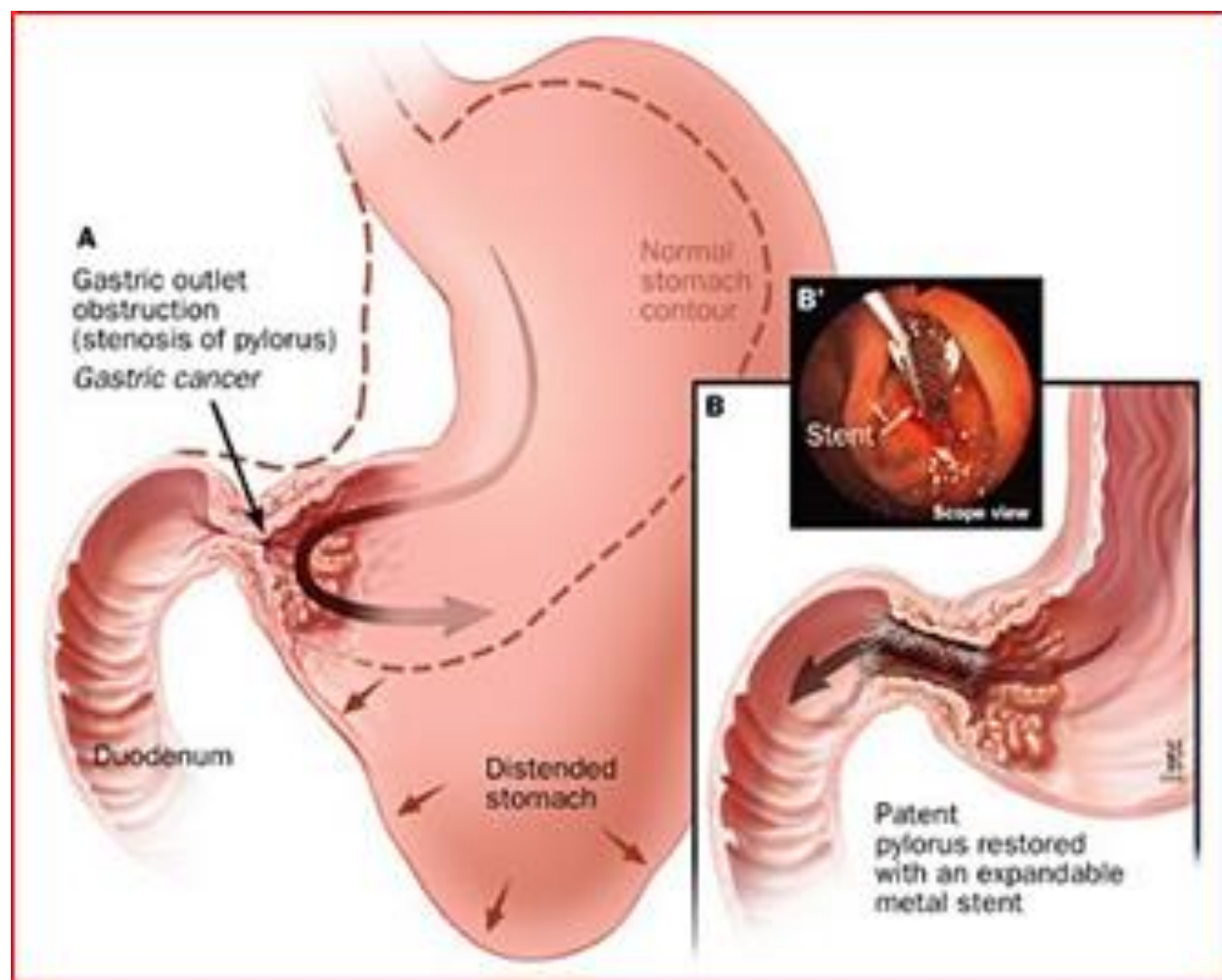


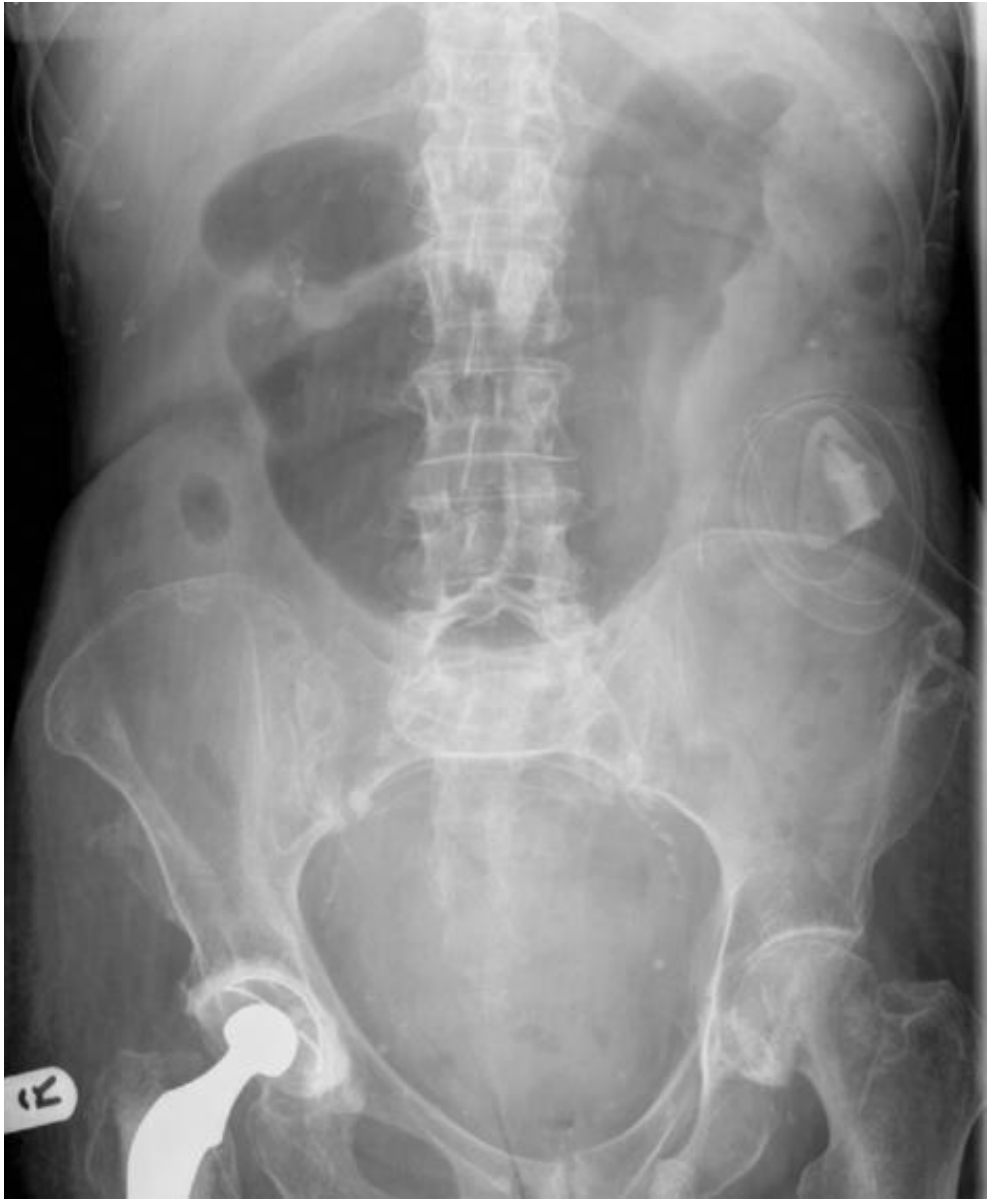Gastric outlet obstruction

Khayal AlKhayal FRCSC, FASCRS

Professor of Surgery, KSU

GOO is the clinical and pathophysiological consequences of any impediment to gastric emptying mechanism





symptoms

Abdominal pain.

Upper abdominal distension.

Nausea.

Vomiting(copious, projectile, non bilious, food taken several hours to days ago).

Anorexia.

Early satiety.

Examination

Chronically ill looking.

Dehydrated.

Pallor

Epigastric ,left or right hypochondrium tenderness.

Distension.

Visible gastric peristalsis.

Succussion splash.

Signs of gastric cancer (supraclav LN,sister marry joseph)

Investigation

Stabilization, acute vs chronic.

Blood work.

Axr

Barium meal

Ct scan

Gastroscopy

gastric emptying studies.

DDX

PUD

Gastric,duodenal polyps.

Caustic ingestion.

Pyloric stenosis.

Congenital duodenal webs.

Gallstone(Bouveret syndrom)
pseudocysts.

Pancreatic

Bezoars.

SMA syndrom.

Cancers

(gastric,duodenal,ampullary,pancreatic,cholangiocarcinoma)

Mets.

