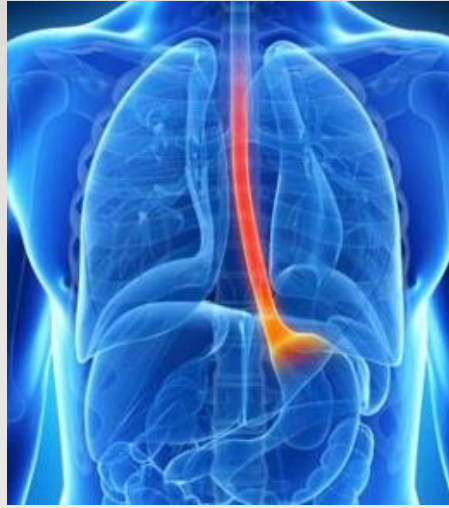

# ESOPHAGEAL DISEASES

---

**NUHA ALAMMAR, MD**

**ASSISTANT PROFESSOR IN INTERNAL MEDICINE  
CONSULTANT OF GASTROENTEROLOGY AND HEPATOLOGY  
SPECIALIZED IN NEUROGASTROENETROLOGY AND MOTILITY  
KING KHALID UNIVERSITY HOSPITAL**

# INTENDED LEARNING OUTCOMES

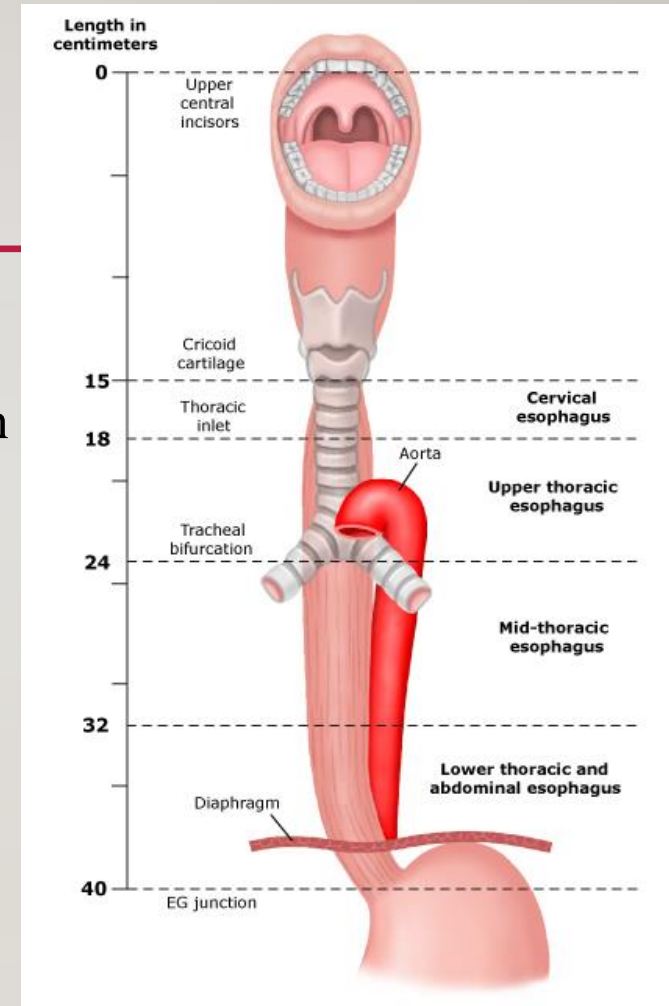
## BY THE END OF THIS LECTURE YOU SHOULD BE ABLE TO:

---

1. Describe the major components in the anatomy of the esophagus and physiology of swallowing.
2. Name the common presenting symptoms and complications of reflux disease (GERD).
3. List the main points in the management of GERD.
4. Differentiate between oropharyngeal and esophageal dysphagia.
5. Explain the differences between anatomical and functional esophageal disorders.
6. Explain the pathophysiology of common causes of dysphagia.
7. List the common presenting symptoms, appropriate investigations and treatment options in different causes of dysphagia.

# ANATOMY OF THE ESOPHAGUS

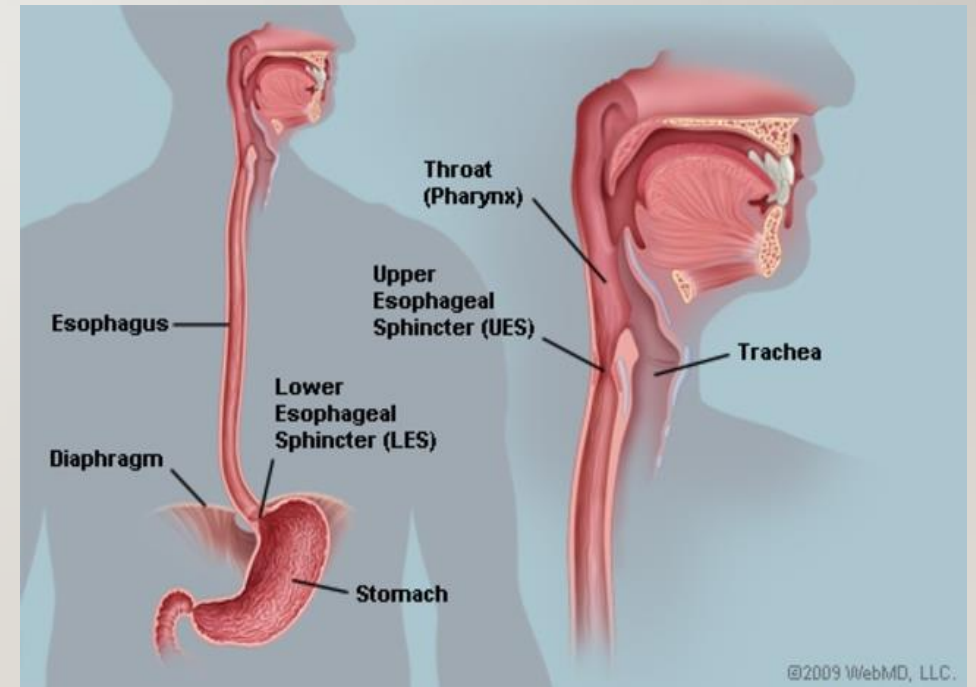
- Located between the pharynx and the stomach.
- Muscular tube 20-25 cm long with UES & LES that help empty food between swallows while preventing regurgitation of stomach contents.
- Striated muscles make up the proximal 1/3.
- Smooth muscles make up the distal 2/3 .
- **How long does it take for a bolus to pass the entire esophagus?**  
About 7-10 seconds.



# UPPER ESOPHAGEAL SPHINCTER

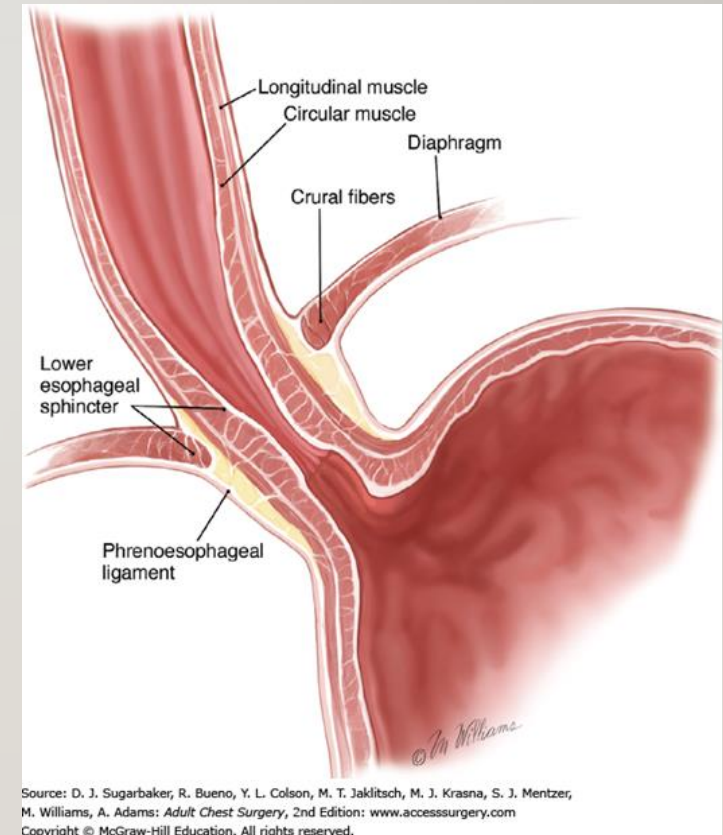
---

- Functions to prevent regurgitation into oral cavity and larynx and restricts airflow into the esophagus during inspiration.
- Composed of striated muscles



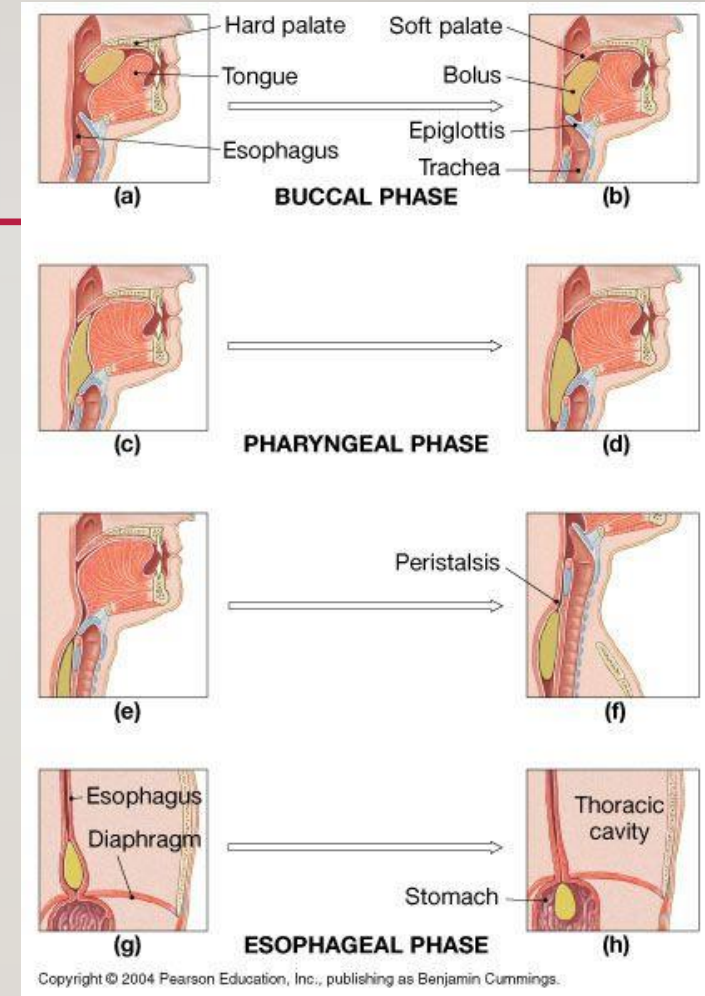
# LOWER ESOPHAGEAL SPHINCTER

- Maintains a high pressure zone between stomach and esophagus (barrier to reflux).
- Physiological sphincter.
- Composed of smooth muscles.
- Normally located within the diaphragmatic hiatus with 2/3 in the abdominal cavity and 1/3 in the thoracic cavity. Can be displaced proximally by hiatal hernia.



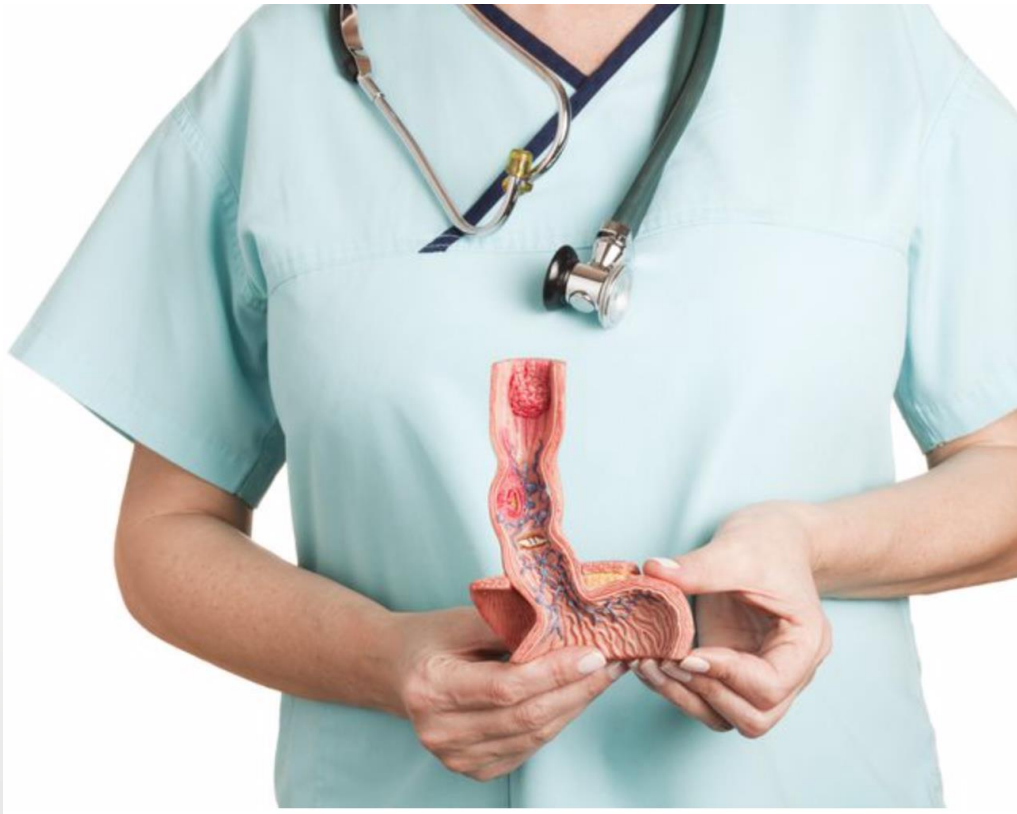# PHYSIOLOGY OF SWALLOWING

- UES opens.
- Bolus is introduced into the esophagus.
- Esophagus distends, causing a contraction proximal to distal. Propagating sequence
- Two types of peristalsis in the esophagus (primary and secondary)
  - Primary peristalsis: initiated in the pharynx by a swallow. These waves are slow moving and sweep the entire length of the esophagus.
  - Secondary peristalsis: initiated by esophageal distension by food. These waves are important to remove all the food from the esophagus if it has not been totally cleared by primary peristalsis.
- LES opens at the end of swallow to allow the food to pass to the stomach.



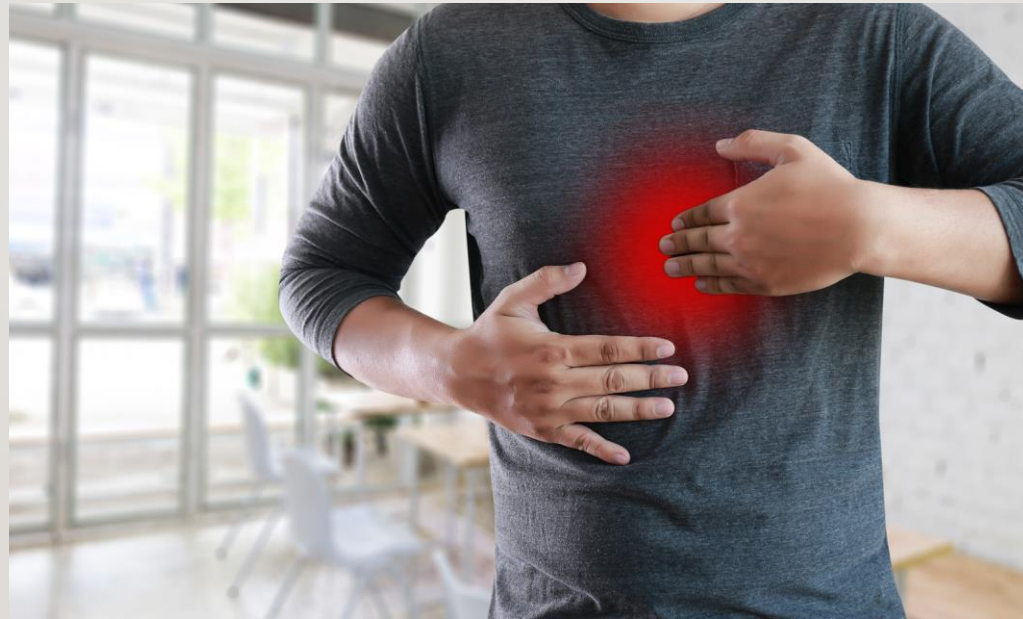# ESOPHAGEAL DISEASES

---



# GASTROESOPHAGEAL REFLUX DISEASE (GERD)

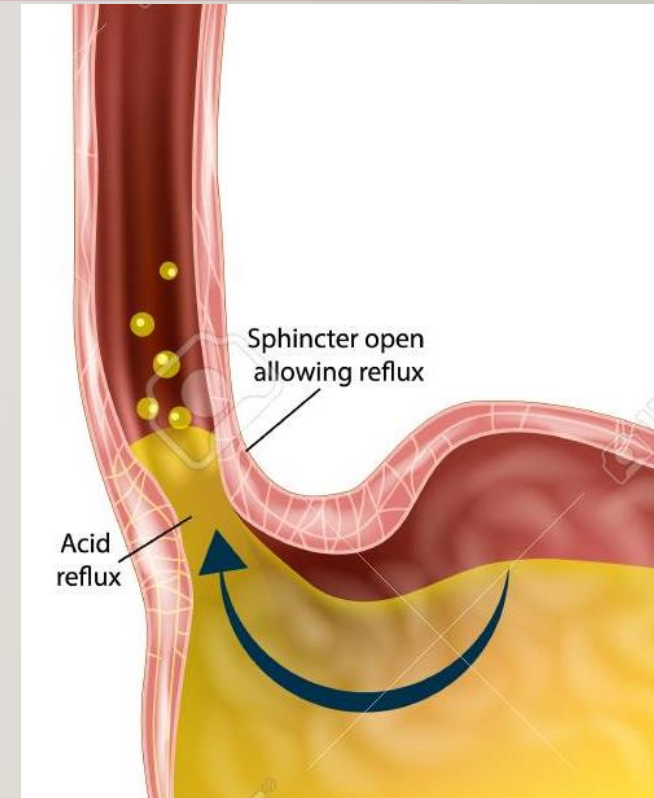
---





# GASTROESOPHAGEAL REFLUX DISEASE (GERD)

- Symptoms or complications resulting from the reflux of gastric contents into esophagus or beyond, into the oral cavity (including larynx) or lung
- Transient lower esophageal sphincter relaxations (TLESRs).
- Prevalence in Saudi Arabia?
- What causes GERD?



# SYMPTOMS OF GERD

---

Typical	Atypical	Extra-esophageal

# SYMPTOMS OF GERD

---

Typical	Atypical	Extra-esophageal
Heartburn		
Regurgitation		

# SYMPTOMS OF GERD

---

<b>Typical</b>	<b>Atypical</b>	<b>Extra-esophageal</b>
<b>Heartburn</b>	Chest pain	
<b>Regurgitation</b>	Early satiety	
	Nausea	
	Bloating and belching	
	Globus sensation	

# SYMPTOMS OF GERD

---

Typical	Atypical	Extra-esophageal
Heartburn	Chest pain	Cough
Regurgitation	Early satiety	Asthma
	Nausea	Laryngitis
	Bloating and belching	Sinusitis/recurrent otitis media
	Globus sensation	Dental erosions

\*\* A cardiac cause should be excluded in patients with chest pain before starting GI evaluation.

# HOW TO DIAGNOSE GERD?

---

- **The diagnosis is often made using mainly:**
  1. Typical symptom presentation.
  2. Antisecretory responsiveness.
  
- **In some cases you will need to go further with:**
  1. Endoscopy
  2. Ambulatory reflux monitoring (PH study).

# INDICATIONS FOR ENDOSCOPY IN SUSPECTED GERD

---

1. Alarm symptoms, like?
2. Non-Cardiac chest pain.
3. Screening high risk patients for Barrett's: overweight, white males, older than 50, chronic GERD, smokers.
4. Patients that are unresponsive to PPI

# INDICATIONS FOR AMBULATORY PH MONITORING

---

1. Suspected GERD with normal Endoscopy (to confirm GERD)
2. Persistent symptoms even with PPI (To R/o other causes)



# MANAGEMENT OF GERD

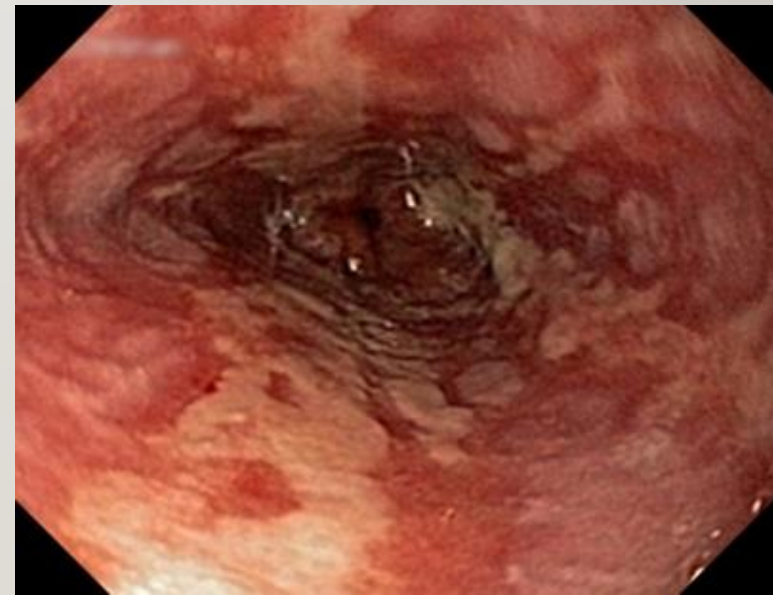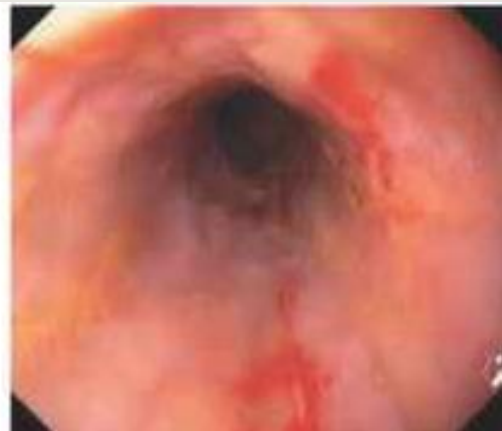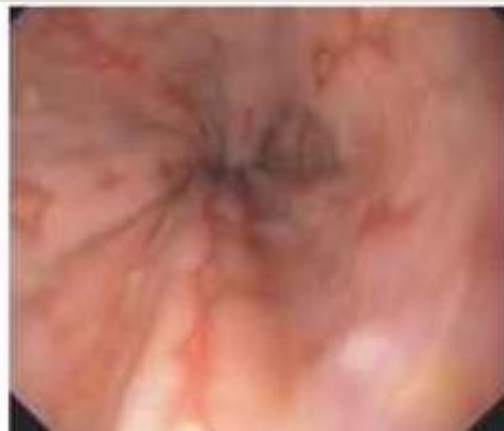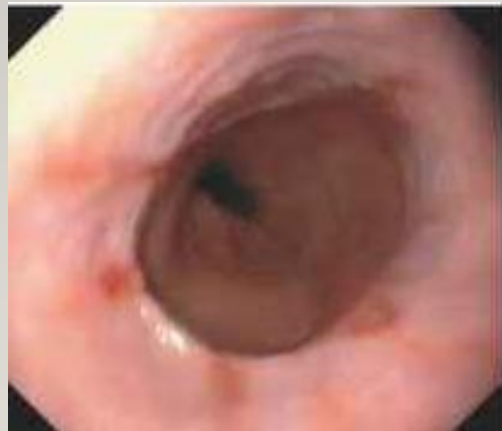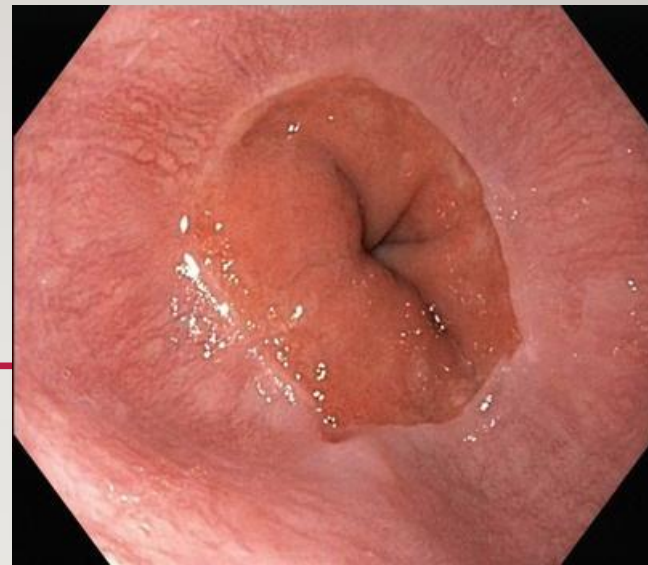
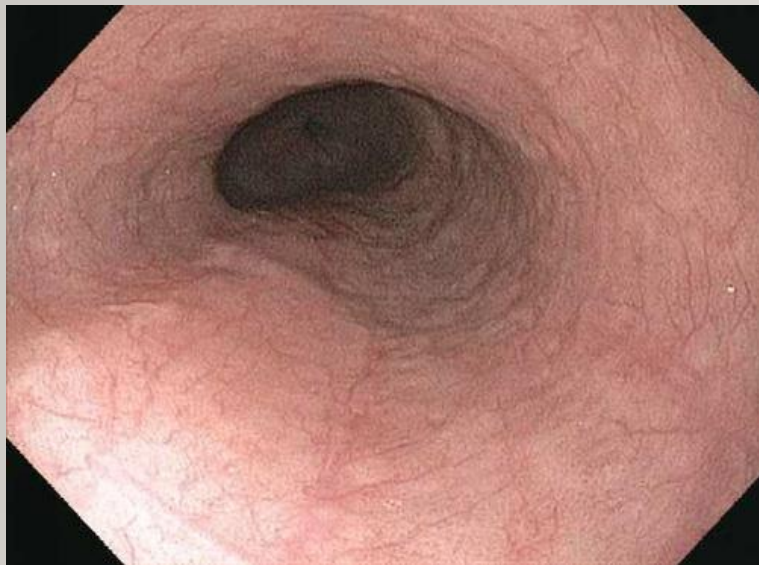---

- Lifestyle changes:
  1. Weight loss
  2. Head of bed elevation at night.
  3. Avoidance of meals 2-3 hours before bedtime for patients with nocturnal GERD.
  4. Smoking Cessation
  5. Culprits: fatty foods, caffeine, chocolate, ETOH, spicy foods, carbonated beverages, peppermints
- Medical Therapy
- Surgical Therapy

# COMPLICATIONS OF GERD

---

- 1. Erosive esophagitis.**



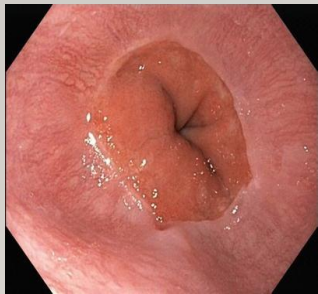
# COMPLICATIONS OF GERD

---

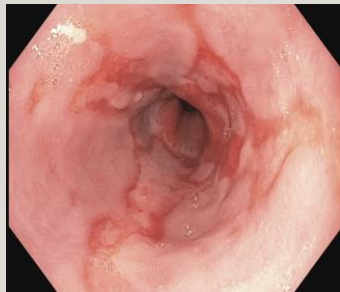1. Erosive esophagitis.
2. **Barrett's esophagus**

# BARRETT'S ESOPHAGUS

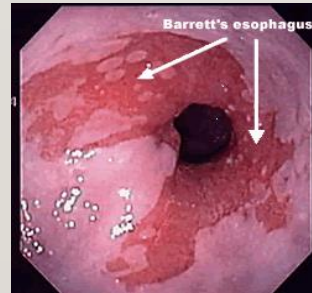
- Metaplastic columnar epithelium (gastric and intestinal) replaces the stratified squamous epithelium in the distal esophagus.



GERD



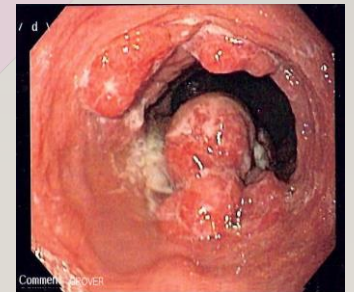
Metaplasia  
(Barrett's)



Low Grade  
dysplasia  
(LGD)

High Grade  
dysplasia  
(HGD)

Adenocarcinoma



# BARRETT'S ESOPHAGUS

---

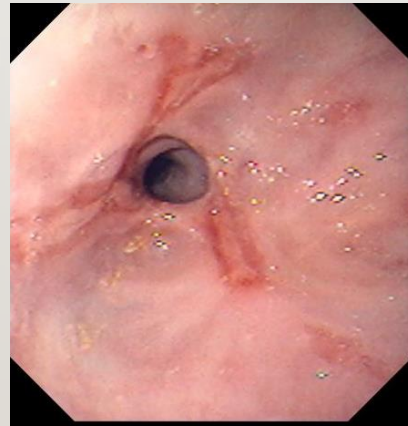
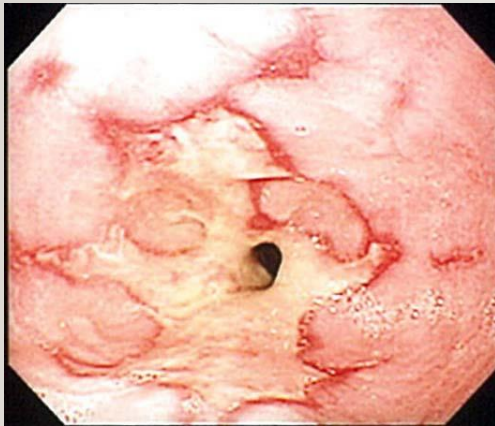
- More common in Men
- Risk Factors for Barrett's :
  1. Chronic (>5 years) GERD symptoms
  2. Advancing age (>50 years)
  3. Male gender
  4. Tobacco usage
  5. Central obesity
  6. Caucasian race
  7. Family history

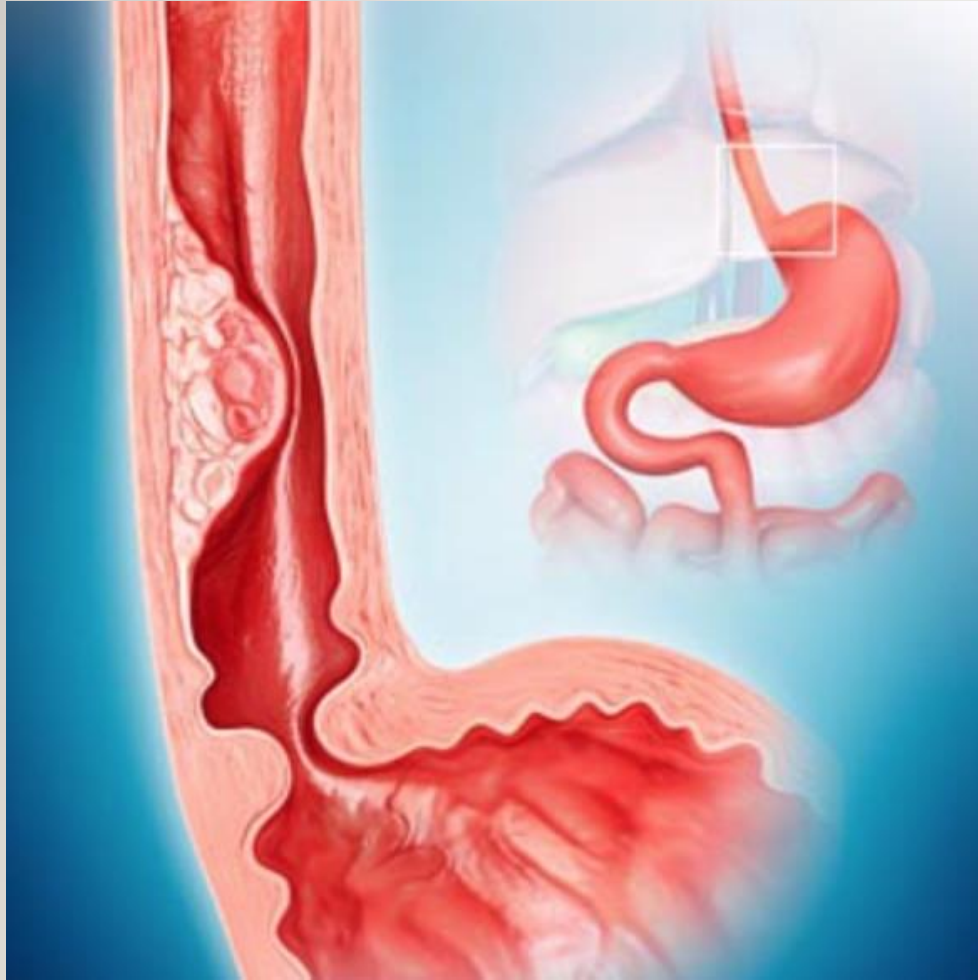**\*\*Alcohol doesn't increase risk of Barrett's**

# COMPLICATIONS OF GERD

---

1. Erosive esophagitis.
2. Barrett's esophagus
3. **Peptic stricture**





**OTHER ESOPHAGEAL PROBLEMS?**



# DYSPHAGIA

---

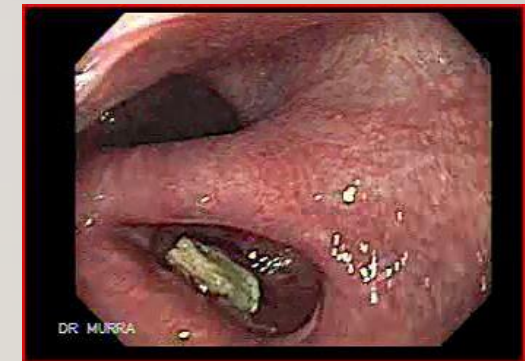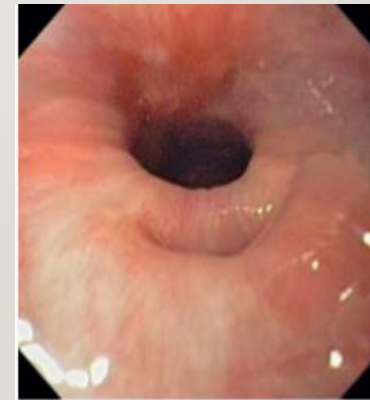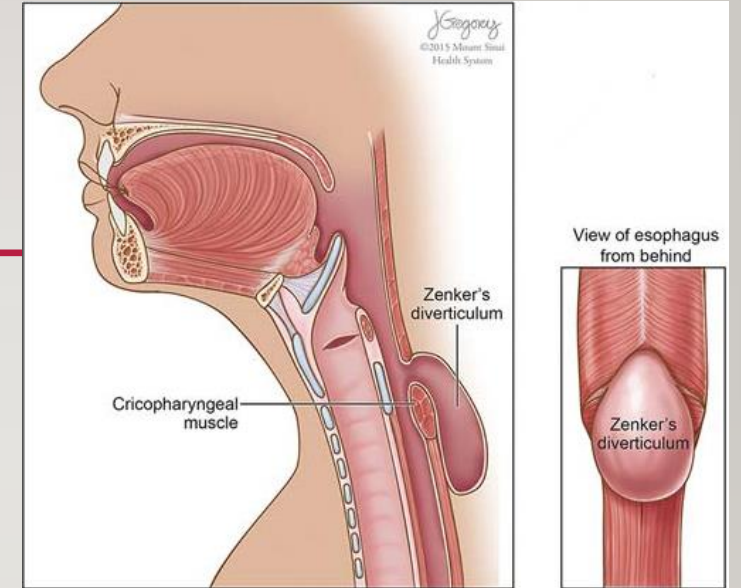
- Subjective sensation of difficulty or abnormality of swallowing.
- Oropharyngeal vs Esophageal dysphagia.

# OROPHARYNGEAL VS ESOPHAGEAL DYSPHAGIA

Oropharyngeal dysphagia	Esophageal dysphagia
Coughing or choking with swallowing	Usually no problems with initiation of swallowing
Difficulty initiation swallowing	Sensation of food getting stuck in chest
Change in voice or speech	Can have pain in the chest from food bolus
Nasal Regurgitation	Oral or pharyngeal regurgitation
Often result from systemic neurologic or myopathic syndromes	Related to intrinsic <b>functional</b> or <b>anatomical</b> abnormalities in the esophagus
Recurrent Pneumonia (Aspiration)	
Weight loss	

# ZENKER'S DIVERTICULUM (CRICOPHARYNGEAL DIVERTICULUM)

- Sac like, outpouching of the mucosa and submucosa in the area of muscular weakness in the hypopharynx between the inferior constrictor and cricopharyngeus muscle, above the upper esophageal sphincter.
- **Cause?** Hypertensive / noncompliance of upper esophageal sphincter.



# ZENKER'S DIVERTICULUM

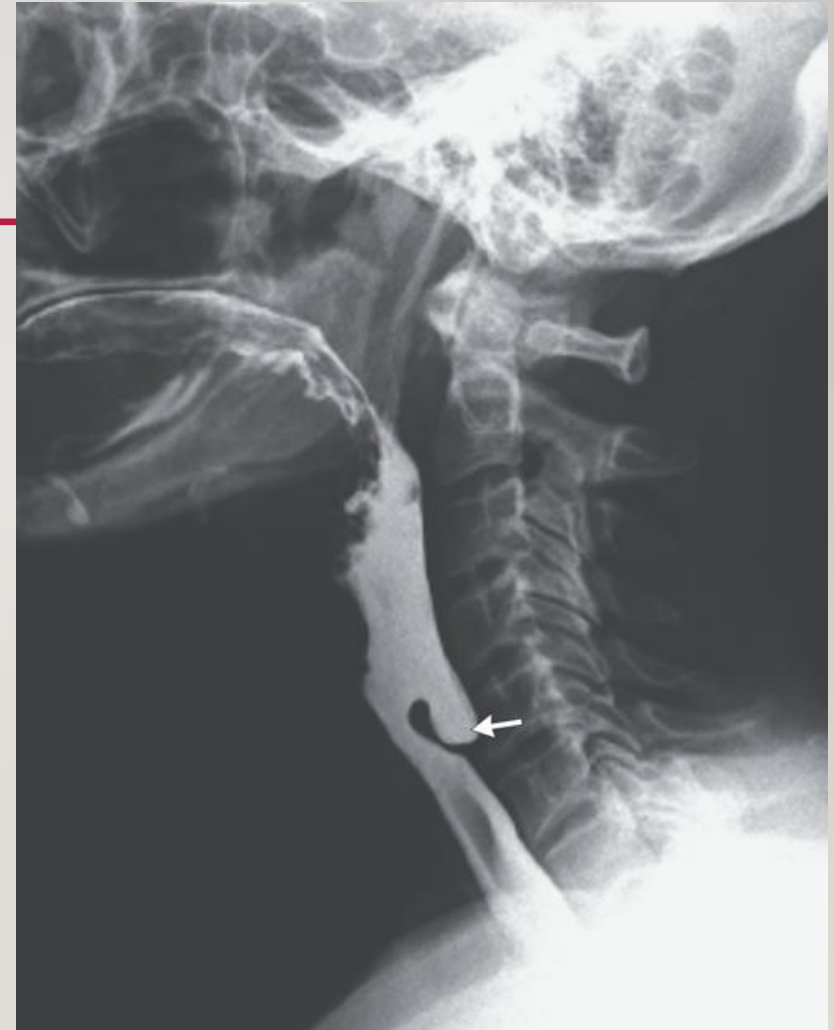---

## Symptoms:

- Oropharyngeal dysphagia symptoms
- Halitosis
- Food undigested on the pillow at night or after meals
- Weight loss happens in late stages (the diverticulum becomes big and obstructs the esophagus).

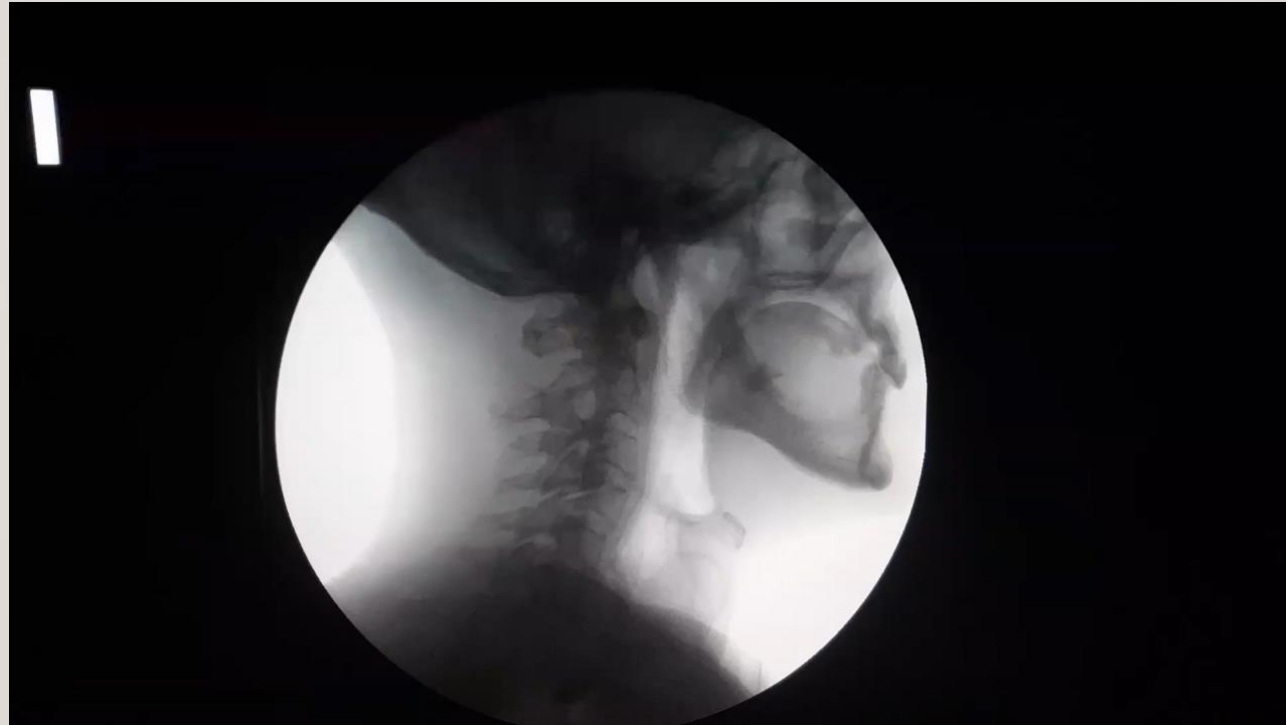## Diagnosis:

- Video swallow testing or modified Barium swallow.



# ZENKER'S DIVERTICULUM

---



# ZENKER'S DIVERTICULUM

---

## **Symptoms:**

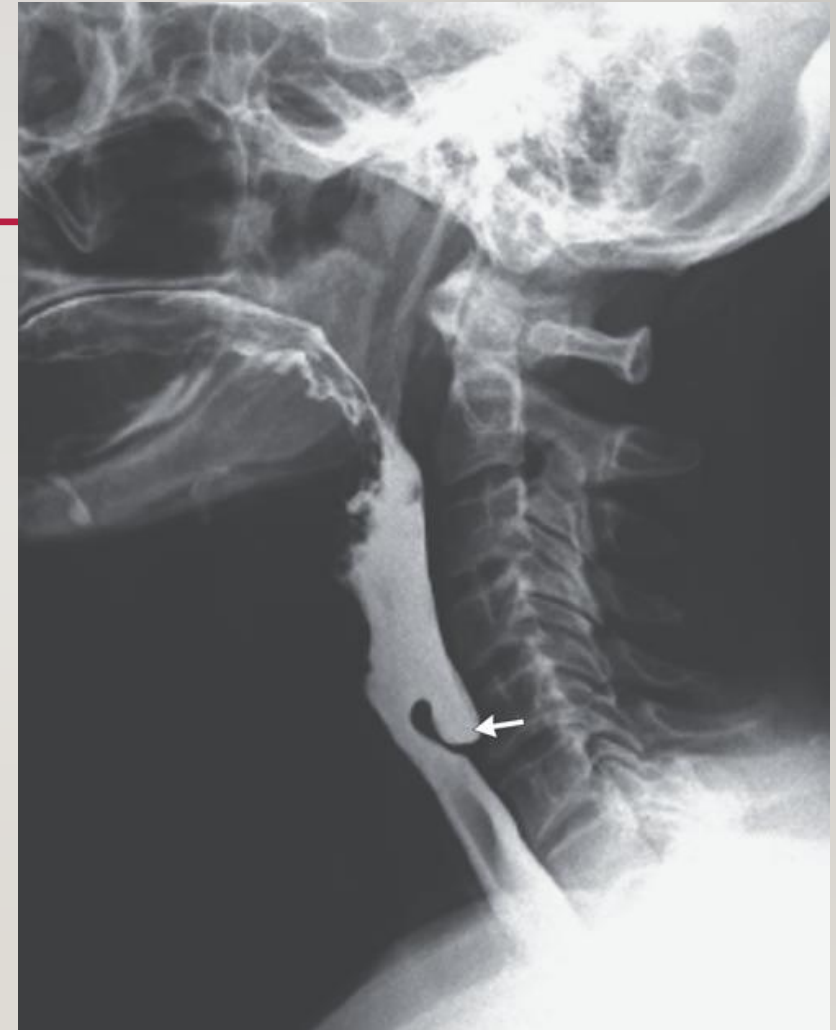- Oropharyngeal dysphagia symptoms
- Halitosis
- Food undigested on the pillow at night or after meals
- Weight loss happens in late stages (the diverticulum becomes big and obstructs the esophagus).

## **Diagnosis:**

- Video swallow testing or modified Barium swallow.

## **Treatment:**

- Surgical



# CAUSES OF ESOPHAGEAL DYSPHAGIA

---

<b>Anatomical causes</b>	<b>Functional causes</b>
Esophageal stricture (types?)	Achalasia
Esophageal Ring	Secondary dysphagia
Esophageal Web	Esophageal spasm
Malignancy	?Eosinophilic esophagitis

# HISTORY TAKING IN DYSPHAGIA

---

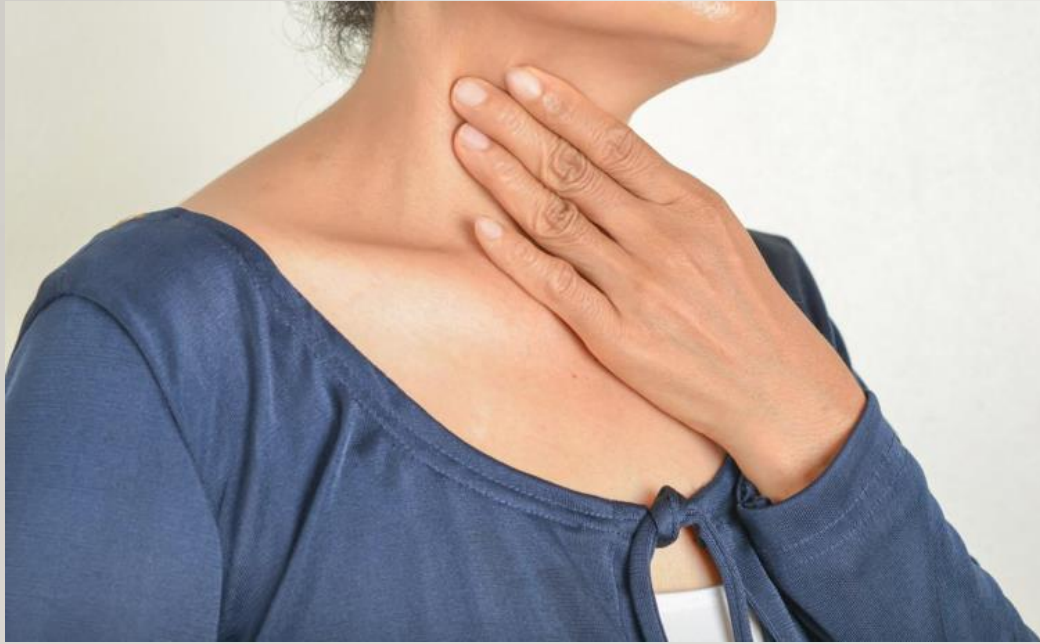1. Onset
2. Duration (weeks/months vs years)
3. Intermittent vs persistent
4. Solids vs solid +liquids
5. Stable vs progressive
6. Regurgitation
7. Associated symptoms (weight loss, anemia/blood in stool ... )



# CARDINAL SIGNS FOR DYSPHAGIA?

---

- Oropharyngeal or esophageal dysphagia.
- Solid vs both solid and liquid.
- Persistent vs intermittent.
- Important associated symptoms.



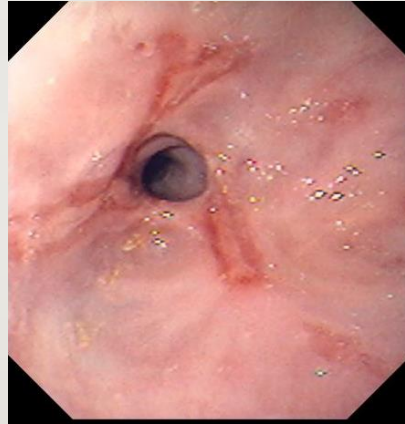
## CAUSES OF ESOPHAGEAL DYSPHAGIA

# 1. ESOPHAGEAL STRICTURE

---

- Causes:

1. Benign peptic stricture
2. Malignant stricture
3. Iatrogenic?

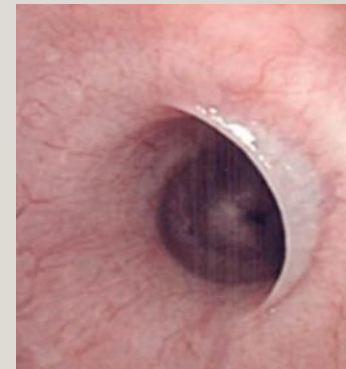
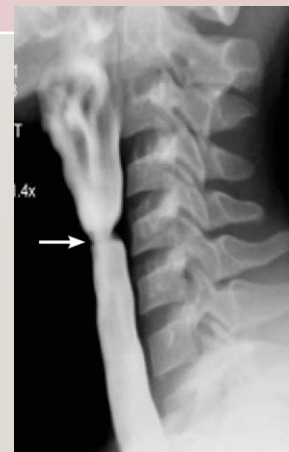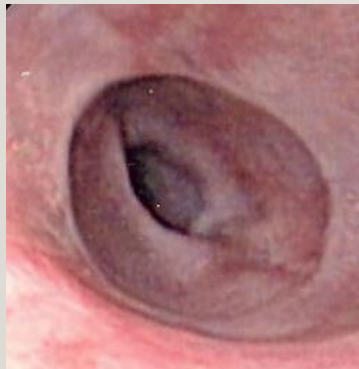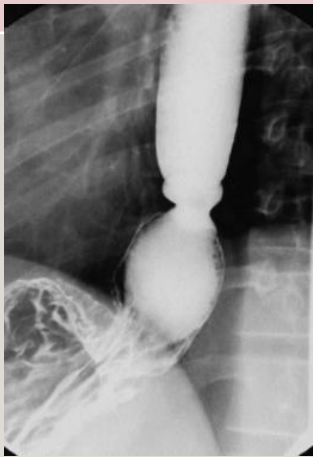


- Diagnosis?

- Treatment?

## 2. ESOPHAGEAL RINGS AND WEBS

Esophageal ring	Esophageal Web
Common in lower esophagus (above the LES)	Usually in upper esophagus (cervical)
Connective tissue + muscularis mucosa	Thin membrane
Caused by ?GERD	Unknown cause ?genetic
Schatzki's ring	*Plummer Vinson syndrome (triad)
Diagnosis: barium, endoscopy	



## 2. ESOPHAGEAL RINGS AND WEBS

Esophageal ring	Esophageal Web
Common in lower esophagus (above the LES)	Usually in upper esophagus (cervical)
Connective tissue + muscularis mucosa	Thin membrane
Caused by ?GERD	Unknown cause ?genetic
Schatzki's ring	*Plummer Vinson syndrome (triad)
Diagnosis: barium, endoscopy	
Treatment: endoscopic dilation if needed (persistent symptoms)	
PPI daily for GERD	Iron replacement therapy if PVS
No cancer risk	PVS has increased risk for squamous cell cancer in the esophagus, hypopharynx and oral mucosa.

# 3. ESOPHAGEAL MOTILITY DISORDERS CAUSING DYSPHAGIA

---

- A) Esophageal spasms.
- B) Aperistalsis in esophagus (connective tissue disease)
- C) Achalasia

# PRIMARY ACHALASIA

---

## Pathophysiology

- Failure of lower esophageal sphincter to relax (lacking ganglion cells in the myenteric plexus in the distal esophagus).
- M=F

## Etiology

- Immune mediated
- Genetic predisposition.

# SECONDARY ACHALASIA

---

- Chagas disease.
- Parasitic Infection by *Trypanosoma cruzi* (*common in latin America*)
- Result in achalasia with features of diffuse enteric myenteric destruction, including megacolon, heart disease (cardiomyopathy), and neurologic disorders.
- Diagnosis: serology testing.
- Treatment: Anti trypanosoma like Benznidazole (GI symptoms managed symptomatically)



# SYMPTOMS OF ACHALASIA

---

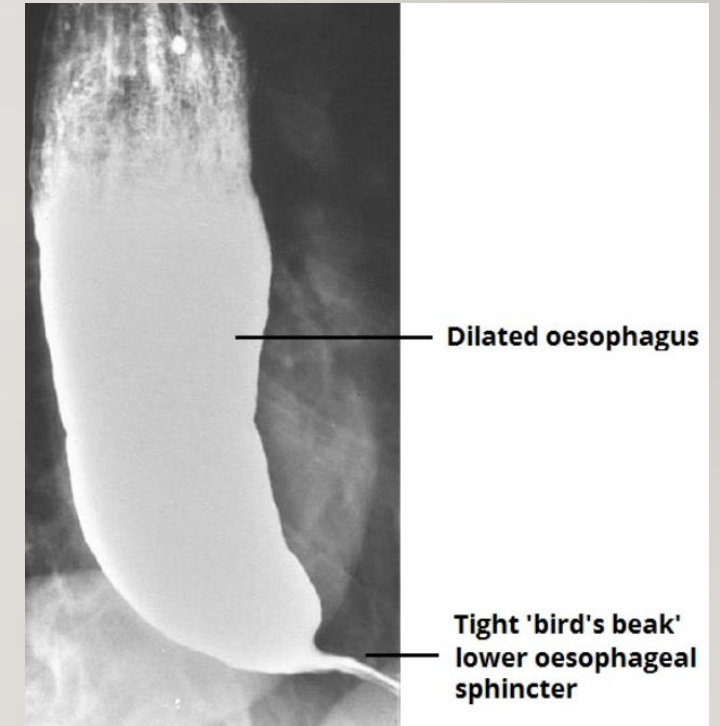
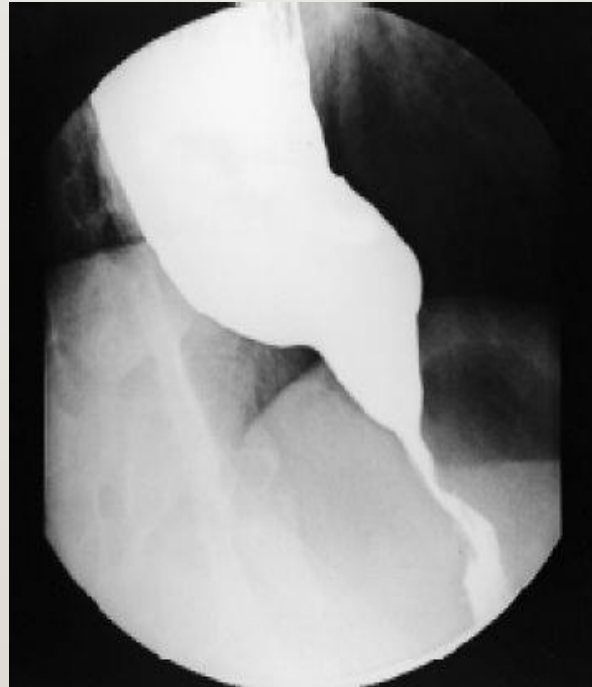- Dysphagia to solids and liquids
- Regurgitation of undigested food.
- Heartburn
- Chest pain
- Weight loss

# DIAGNOSIS OF ACHALASIA

---

## 1. Barium swallow:

- Dilated distal esophagus.
- Tight LES
- BIRD BEAK APPEARANCE

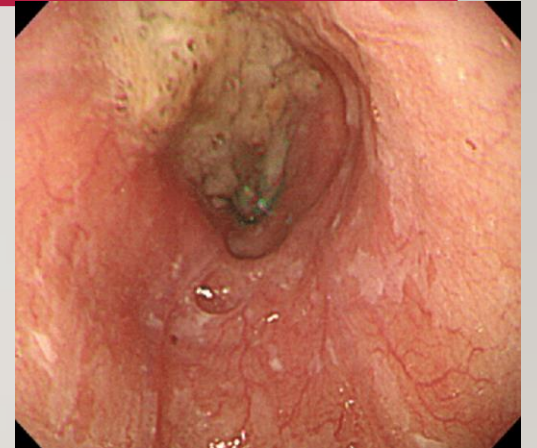
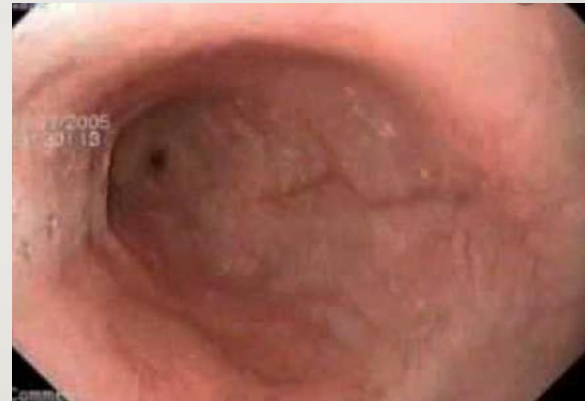

# DIAGNOSIS OF ACHALASIA

1. Barium swallow

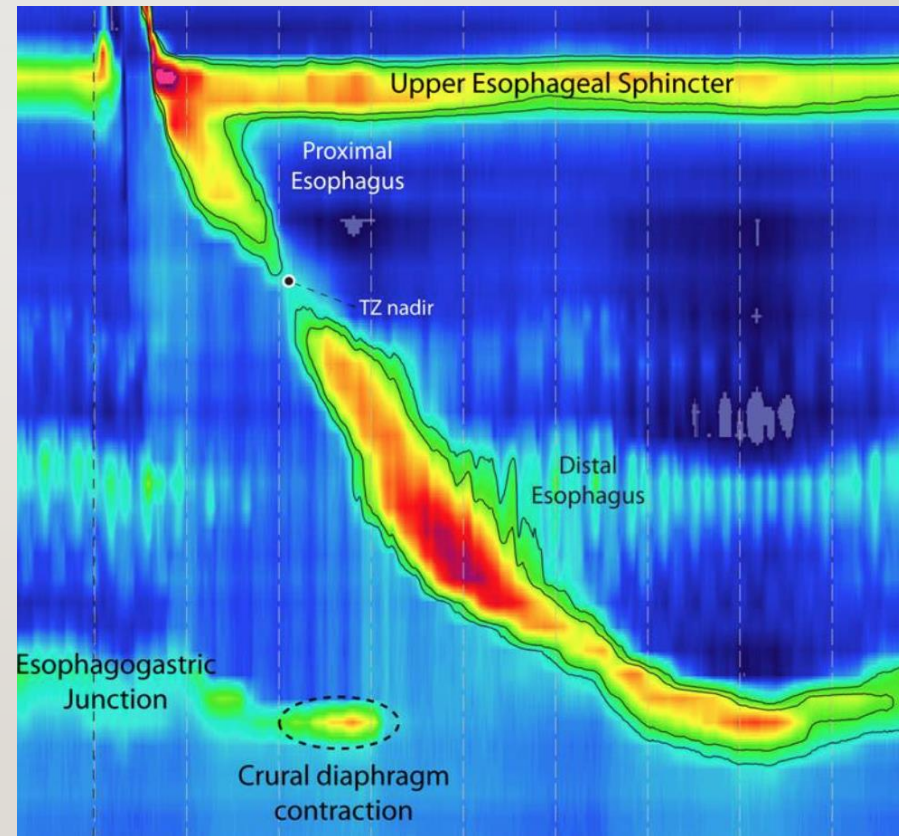
2. **Endoscopy**

- Normal with some resistance at the LES
- Dilated esophagus.
- Retained saliva, liquid, and food in the esophagus without mechanical obstruction from stricture or mass



# DIAGNOSIS OF ACHALASIA

1. Barium swallow:
2. Endoscopy
3. **Esophageal Manometry**



# PSEUDOACHALASIA

---

- Achalasia symptoms and similar diagnostic findings.
- Due to Malignancy (tumors in the gastric cardia or those infiltrating the myenteric plexus like adenocarcinoma of gastroesophageal junction, pancreatic, breast, lung, or hepatocellular cancers)
- When to suspect (rapid onset over weeks-months, elderly and risk factors for cancer)
- Need to get CT scan or endoscopic US for further workup.

# MANAGEMENT OF ACHALASIA

---

1. Medical therapy:

Calcium channel blockers, nitrate.

# MANAGEMENT OF ACHALASIA

---

1. Medical therapy:
2. Endoscopic therapy:
  - Pneumatic dilation. (effective/longer term/ more complications)
  - Botox injection at LES. (effective/ short term 3-6 months)
  - POEM

# MANAGEMENT OF ACHALASIA

---

1. Medical therapy:
  2. Endoscopic therapy:
  3. Surgical: Heller's Myotomy.
- \*\* Higher risk for Esophageal squamous cell cancer.



## 4. EOSINOPHILIC ESOPHAGITIS

---

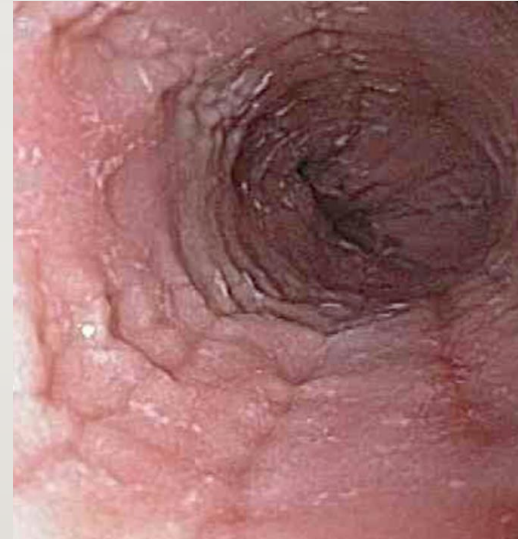- Chronic inflammation due to immune-mediated disease resulting in eosinophilic infiltration of esophagus
- No malignancy Potential.
- Commonly present with food impaction. Main symptom is dysphagia.
- History of allergies is seen in >50% of these patients.

# DIAGNOSIS OF EOSINOPHILIC ESOPHAGITIS

---

## **Endoscopy:**

- Can be normal
- Strictures
- Linear furrows
- Trachealization of the esophagus.

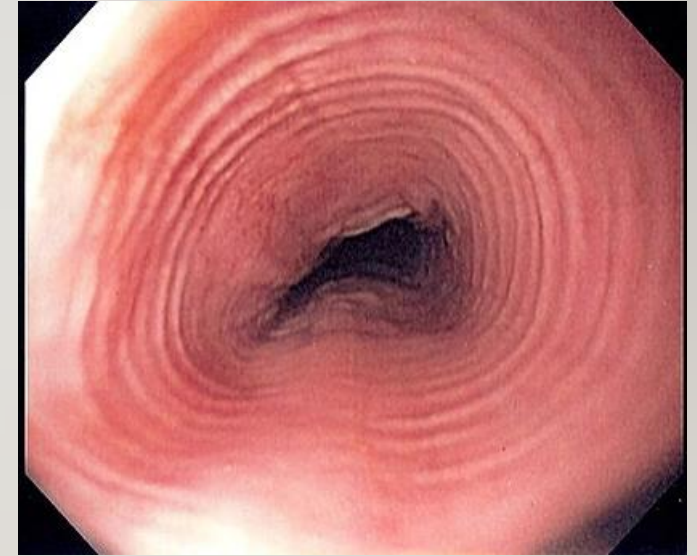
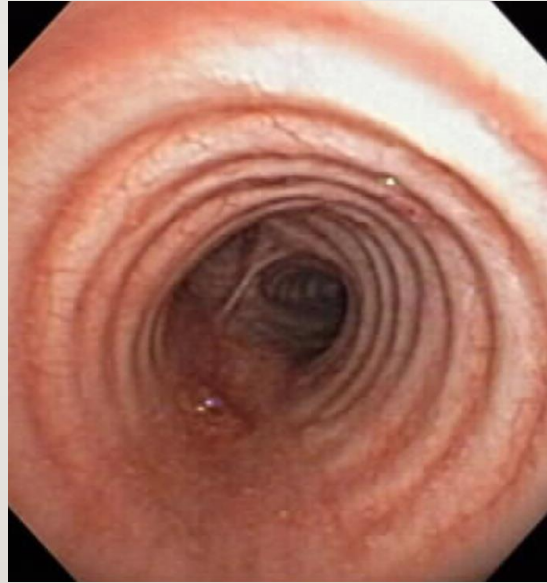
# DIAGNOSIS OF EOSINOPHILIC ESOPHAGITIS

---

## Endoscopy:

- Can be normal
- Strictures
- Linear furrows
- Trachealization of the esophagus.



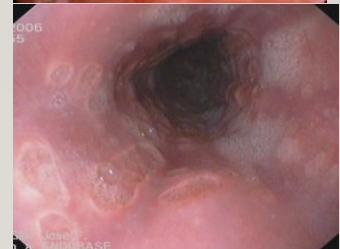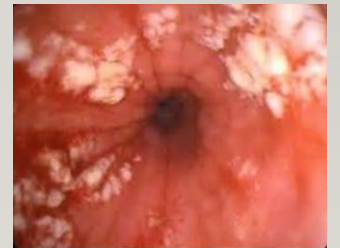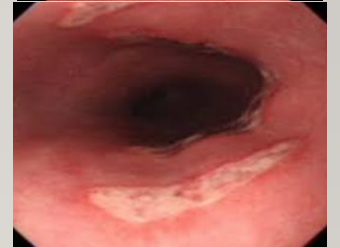
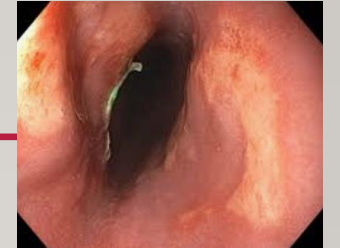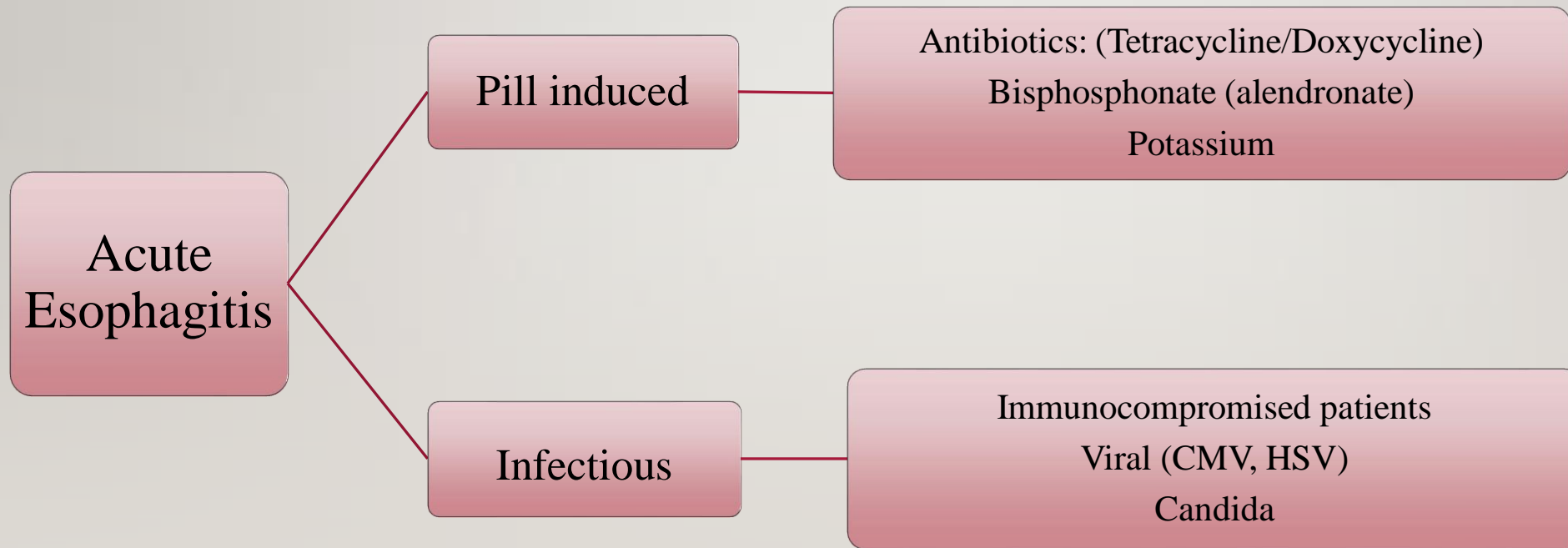
\*\*BIOPSY shows 15 or more eosinophils/hpf on microscopy (from proximal and distal esophagus)

# TREATMENT OF EOE

---

- PPI first for 8 weeks then repeat Endoscopy if Eosinophils is still 15 or more:
- Corticosteroids (swallowed fluticasone/ budesonide).
- If symptoms persist repeat endoscopy if there's a ring try dilation

# ODYNOPHAGIA+/- DYSPHAGIA



# QUESTION #1

---

A 42 y/o male presents for evaluation of heartburn. He denies any dysphagia or weight loss. He has no other medical conditions and is currently not taking any medications. You suspect that he may have GERD. Which of the following describes the role of upper endoscopy in the evaluation of this patient?

- A) He should undergo an Esophagogastroduodenoscopy with biopsy to ensure a more serious condition is not missed.
- B) He should undergo an Esophagogastroduodenoscopy only if he has no improvement in his symptoms after an empiric trial of twice daily PPI therapy.
- C) He should undergo ambulatory PH monitoring while on PPI therapy to ensure the medication is working.
- D) He should undergo both an Esophagogastroduodenoscopy and ambulatory PH monitoring prior to the initiation of any therapy.

# QUESTION #1

---

A 42 y/o male presents for evaluation of heartburn. He denies any dysphagia or weight loss. He has no other medical conditions and is currently not taking any medications. You suspect that he may have GERD. Which of the following describes the role of upper endoscopy in the evaluation of this patient?

- A) He should undergo an Esophagogastroduodenoscopy with biopsy to ensure a more serious condition is not missed.
- B) He should undergo an Esophagogastroduodenoscopy only if he has no improvement in his symptoms after an empiric trial of twice daily PPI therapy.**
- C) He should undergo ambulatory PH monitoring while on PPI therapy to ensure the medication is working.
- D) He should undergo both an Esophagogastroduodenoscopy and ambulatory PH monitoring prior to the initiation of any therapy.

# INDICATIONS FOR ENDOSCOPY IN SUSPECTED GERD

---

1. Alarm symptoms, like?
2. Screening high risk patients for Barrett's: overweight, white males, older than 50, chronic GERD
3. Patients that are unresponsive to PPI



## QUESTION #2

---

A 45-year-old man is evaluated for a 2-month history of a burning sensation starting in his stomach and radiating into his chest, usually occurring 4 to 5 times weekly. He says that he usually eats dinner late and then goes to sleep. He often wakes up with a sour taste in his mouth. He reports no dysphagia or unintentional weight loss. He takes no medication.

On physical examination, vital signs are normal; BMI is 34. The remainder of the examination, including abdominal examination, is unremarkable.

What would be the next step in his management?

- A) PH testing
- B) Barium esophagography
- C) Empiric trial of proton pump inhibitor
- D) Esophagogastroduodenoscopy

## QUESTION #2

---

A 45-year-old man is evaluated for a 2-month history of a burning sensation starting in his stomach and radiating into his chest, usually occurring 4 to 5 times weekly. He says that he usually eats dinner late and then goes to sleep. He often wakes up with a sour taste in his mouth. He reports no dysphagia or unintentional weight loss. He takes no medication.

On physical examination, vital signs are normal; BMI is 34. The remainder of the examination, including abdominal examination, is unremarkable.

What would be the next step in his management?

- A) PH testing
- B) Barium esophagography
- C) Empiric trial of proton pump inhibitor
- D) Esophagogastroduodenoscopy

## QUESTION #3

---

A 56-year-old woman is evaluated for chest discomfort after meals occurring intermittently over the preceding month. She describes a sensation of heaviness on her chest, and says that she also notices this pain sometimes while walking up stairs. She reports no nausea, dysphagia, or reflux. She has been taking ranitidine with minimal relief of symptoms. She also takes atorvastatin for hyperlipidemia. She smokes half a pack of cigarettes daily.

On physical examination, her blood pressure is 140/90 mm Hg and other vital signs are normal; BMI is 34. The remainder of the examination, including abdominal examination, is unremarkable.

What is your next step?

- A) Barium esophagography
- B) Electrocardiography
- C) Empiric trial of a proton pump inhibitor
- D) Esophagogastroduodenoscopy

## QUESTION #3

---

A 56-year-old woman is evaluated for chest discomfort after meals occurring intermittently over the preceding month. She describes a sensation of heaviness on her chest, and says that she also notices this pain sometimes while walking up stairs. She reports no nausea, dysphagia, or reflux. She has been taking ranitidine with minimal relief of symptoms. She also takes atorvastatin for hyperlipidemia. She smokes half a pack of cigarettes daily.

On physical examination, her blood pressure is 140/90 mm Hg and other vital signs are normal; BMI is 34. The remainder of the examination, including abdominal examination, is unremarkable.

What is your next step?

- A) Barium esophagography
- B) Electrocardiography**
- C) Empiric trial of a proton pump inhibitor
- D) Esophagogastroduodenoscopy

## QUESTION #4

---

A 75-year-old man is evaluated for progressive dysphagia of 8 months' duration for both solids and liquids and the necessity to induce vomiting several times each month to relieve his symptoms. He also has experienced chest pain and heartburn symptoms. He has lost approximately 6 kg (13 lb) of weight over the preceding 3 months and a total of 9 kg (20 lb) since his symptoms began. He has a long history of cigarette and alcohol use. His medical history and review of systems is otherwise negative. He has no travel history outside the northeastern United States. He takes no medication.

On physical examination, vital signs are normal; BMI is 23. He appears thin and tired. The remainder of the physical examination is unremarkable. Esophagogastroduodenoscopy findings reveal retained saliva, liquid, and food in the esophagus without mechanical obstruction. Manometry demonstrates incomplete lower esophageal relaxation and aperistalsis.

What is the most likely diagnosis?

- A) Achalasia
- B) Pseudoachalasia
- C) EOE
- D) Chagas disease

## QUESTION #4

---

A 75-year-old man is evaluated for progressive dysphagia of 8 months' duration for both solids and liquids and the necessity to induce vomiting several times each month to relieve his symptoms. He also has experienced chest pain and heartburn symptoms. He has lost approximately 6 kg (13 lb) of weight over the preceding 3 months and a total of 9 kg (20 lb) since his symptoms began. He has a long history of cigarette and alcohol use. His medical history and review of systems is otherwise negative. He has no travel history outside the northeastern United States. He takes no medication.

On physical examination, vital signs are normal; BMI is 23. He appears thin and tired. The remainder of the physical examination is unremarkable. Esophagogastroduodenoscopy findings reveal retained saliva, liquid, and food in the esophagus without mechanical obstruction. Manometry demonstrates incomplete lower esophageal relaxation and aperistalsis.

What is the most likely diagnosis?

- A) Achalasia
- B) Pseudoachalasia**
- C) EOE
- D) Chagas disease

# PSEUDOACHALASIA

---

- Achalasia symptoms and similar diagnostic findings.
- Due to Malignancy.
- When to suspect (rapid onset over weeks-months, elderly and risk factors for cancer)
- Need to get CT scan or endoscopic US for further workup.

## QUESTION #5

---

A 52-year-old man is evaluated for dysphagia of 3 months' duration. He reports regurgitating undigested food soon after eating solid food, occasional coughing and choking after swallowing, and chronic halitosis. He reports no weight loss or chest pain. He drinks two beers weekly and does not smoke.

On physical examination, vital signs are normal; BMI is 25. The remainder of the examination, including abdominal examination, is unremarkable.

What is your next step?

- A) Barium esophagram
- B) Esophagogastroduodenoscopy
- C) Manometry
- D) PH study



## QUESTION #5

---

A 52-year-old man is evaluated for dysphagia of 3 months' duration. He reports regurgitating undigested food soon after eating solid food, occasional coughing and choking after swallowing, and chronic halitosis. He reports no weight loss or chest pain. He drinks two beers weekly and does not smoke.

On physical examination, vital signs are normal; BMI is 25. The remainder of the examination, including abdominal examination, is unremarkable.

What is your next step?

- A) Barium esophagram
- B) Esophagogastroduodenoscopy
- C) Manometry
- D) PH study

## QUESTION #6

---

A 25-year-old man is evaluated for a sensation of solid food “sticking” several times per week. He reports that he sometimes forces himself to vomit when he feels food “stuck” in the esophagus, but he has never gone to the emergency department. He takes a multivitamin and is generally healthy.

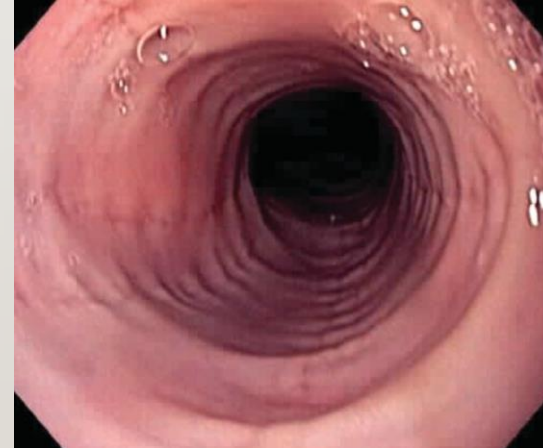On physical examination, vital signs and other findings, including those of an abdominal examination, are unremarkable.

Esophagogastroduodenoscopy findings are shown.

Biopsies of the esophagus show more than 18 eosinophils/hpf.

Which of the following is the most likely diagnosis?

- A) Achalasia
- B) Eosinophilic esophagitis
- C) Gastroesophageal disease
- D) Pill induced esophagitis.



## QUESTION #6

---

A 25-year-old man is evaluated for a sensation of solid food “sticking” several times per week. He reports that he sometimes forces himself to vomit when he feels food “stuck” in the esophagus, but he has never gone to the emergency department. He takes a multivitamin and is generally healthy.

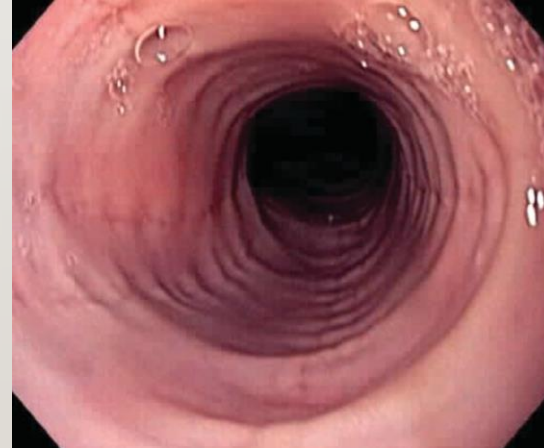
On physical examination, vital signs and other findings, including those of an abdominal examination, are unremarkable.

Esophagogastroduodenoscopy findings are shown.

Biopsies of the esophagus show more than 18 eosinophils/hpf.


Which of the following is the most likely diagnosis?

- A) Achalasia
- B) Eosinophilic esophagitis**
- C) Gastroesophageal disease
- D) Pill induced esophagitis.



# Thank you

---



# REFERENCES

---

- American College of Gastroenterology Guidelines.
- Prevalence of Gastroesophageal Reflux Disease in Saudi Arabia, Obaidallah Buraykan Alsuwat, et al. [J Clin Med Res](#). 2018 Mar; 10(3): 221–225.
- Herpes esophagitis in healthy adults and adolescents: report of 3 cases and review of the literature. [Eduardo Canalejo Castrillero](#), et al. *Medicine* 2010 DOI:[10.1097/MD.0b013e3181e949ed](#)
- Management of achalasia. [A. J. Moonen](#), et al. [Gastroenterol Clin North Am](#). 2013 Mar;42(1):45-55
- Netter's Gastroenterology, 2<sup>nd</sup> edition, Martin H.Floch
- MKSAP 18