



# Abnormal liver enzymes with selected common liver diseases

SAAD ALKHOWAITER, MD, DABIM, FRCP(C)

CONSULTANT OF GASTROENTEROLOGY, HEPATOLOGY AND MOTILITY

ASSISTANT PROFESSOR

DIVISION OF GASTROENTEROLOGY

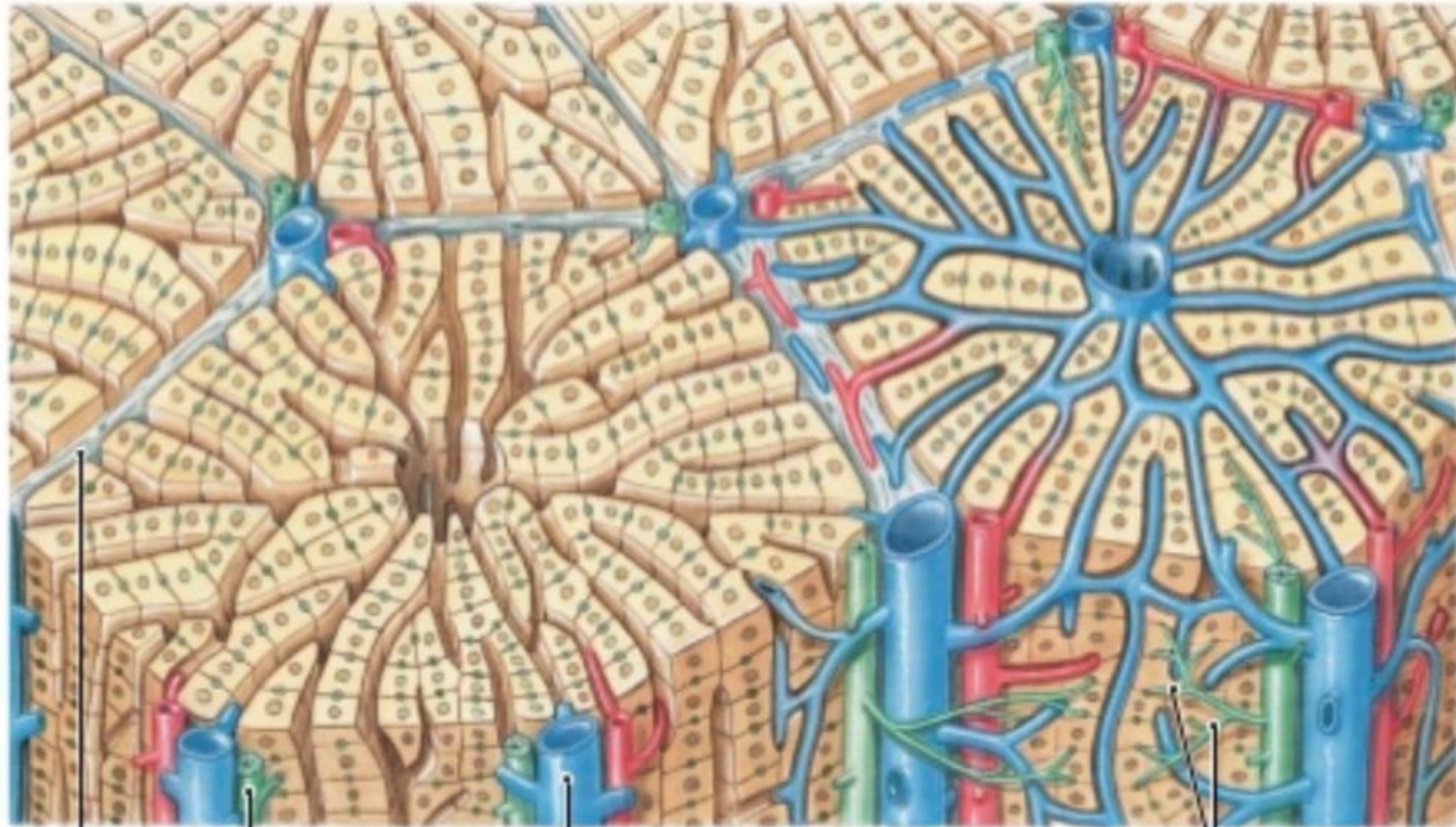
KING SAUD UNIVERSITY

▶ Story?

# Agenda

- ▶ Approach to liver enzymes
- ▶ Selected diseases
- ▶ Cases





N  
S

Interlobular  
septum

Bile  
duct

Branch of  
hepatic portal vein

Portal  
area

Bile  
ductules

# Approach to liver enzymes

- ▶ Hepatocellular causes

vs

- ▶ Cholestatic causes

Vs

- ▶ Mixed

# HOW TO IDENTIFY EACH

- ▶ **Hepatocellular causes**

vs

- ▶ **Cholestatic causes---** isolated ALP and role of GGT

vs

- ▶ **Mixed**

# Hepatocellular causes

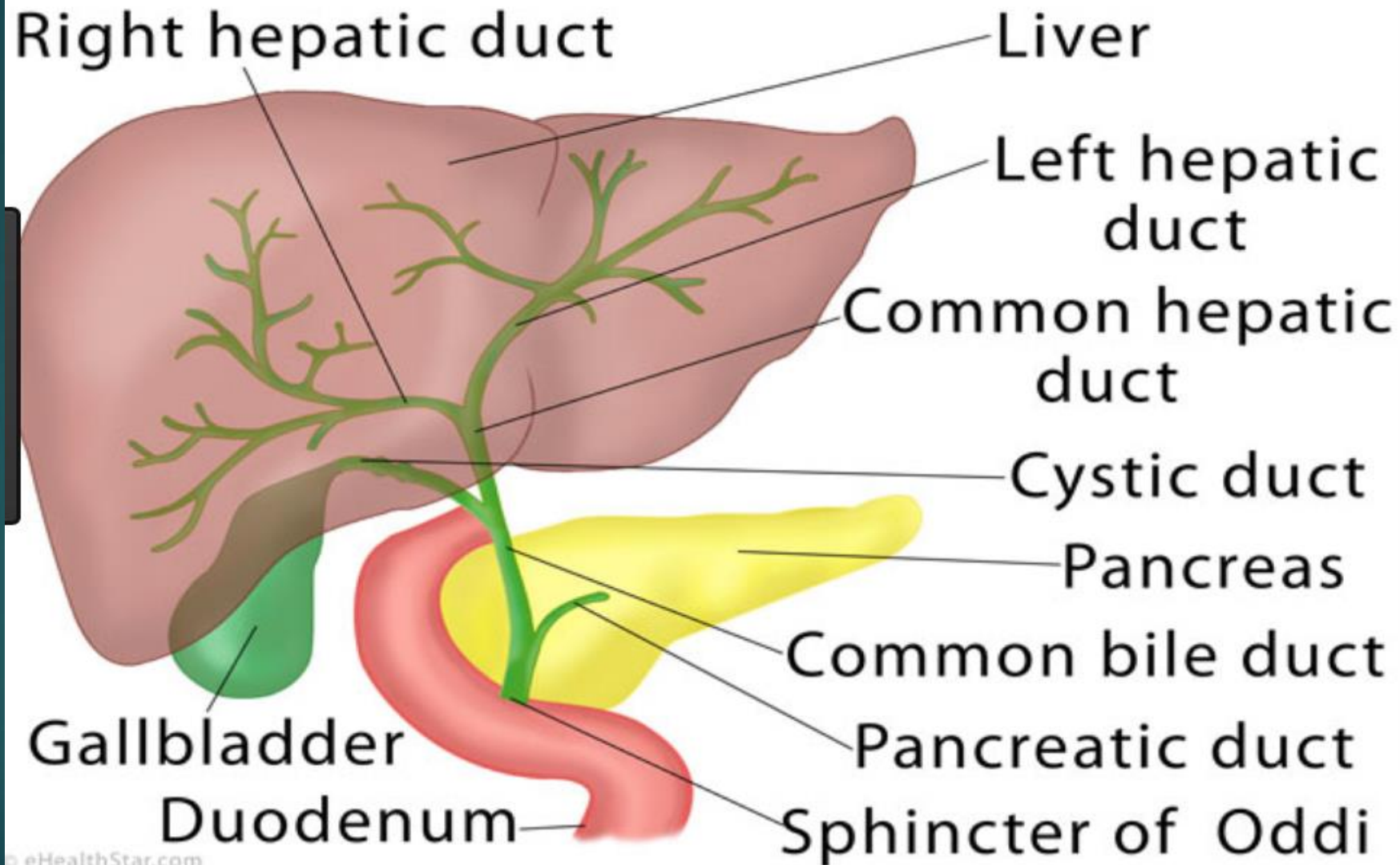
- ▶ **Viral hepatitis**
- ▶ Alcohol
- ▶ NASH/ASH
- ▶ **Drugs eg Tylenol OD, idiosyncratic reaction, NSAIDS, statins, Nitrofur.**
- ▶ **Toxins eg cocaine**
- ▶ **Vascular injury:** such as in hypotension, vascular outflow obstruction
- ▶ **AIH/ceeliac**
- ▶ **Metabolic diseases**
- ▶ Passed Stone
- ▶ Pregnancy related



# Thousand range elevated transaminases

▶ ddx

# Biliary Tree



# Cholestatic causes

## ▶ **Extra-hepatic = Obstructive**

### ▶ **Biliary stone**

### ▶ **Stricture:**

1. Malignant: Peri-ampullary tumors
2. PSC, AIDs cholangiopathy

## ▶ **Intra-hepatic = non-obstructive**

### ▶ PBC

### ▶ PSC: small duct

### ▶ Cystic fibrosis

### ▶ **Sepsis, TPN, Drugs**

### ▶ **Infiltrative:**

- ▶ **Granulomatous diseases** such as TB, sarcoidosis, lymphoma
- ▶ **Amyloidosis**

### ▶ intrahepatic cholestasis of pregnancy

# DDx of jaundice:

- ▶ **Direct Hyperbilirubinemia (Hepatic, Post-hepatic):** Hepatobiliary disease
- ▶ **Indirect Hyperbilirubinemia (pre-hepatic):** Hemolytic anemia, Hematoma, Massive t/f, rifampin
- ▶ **Indirect Hyperbilirubinemia:** Gilbert
- ▶ **Pseudo-Jaundice due to Carotenemia,** in which case the sclera is intact.

**If Hepatocellular pattern**



**Viral Hepatitis serologies**  
**Alcohol level**  
**US – for fatty liver or cirrhosis**  
**Drug level for Tylenol, pheytoin**  
**Urine toxins: cocaine**  
**Doppler US**  
**ANA, ASMA, IgG, AMA, celiac screen**  
**Serum ceruloplamin**  
**Liver Bx to be considered if needed**  
**Fibroscan**

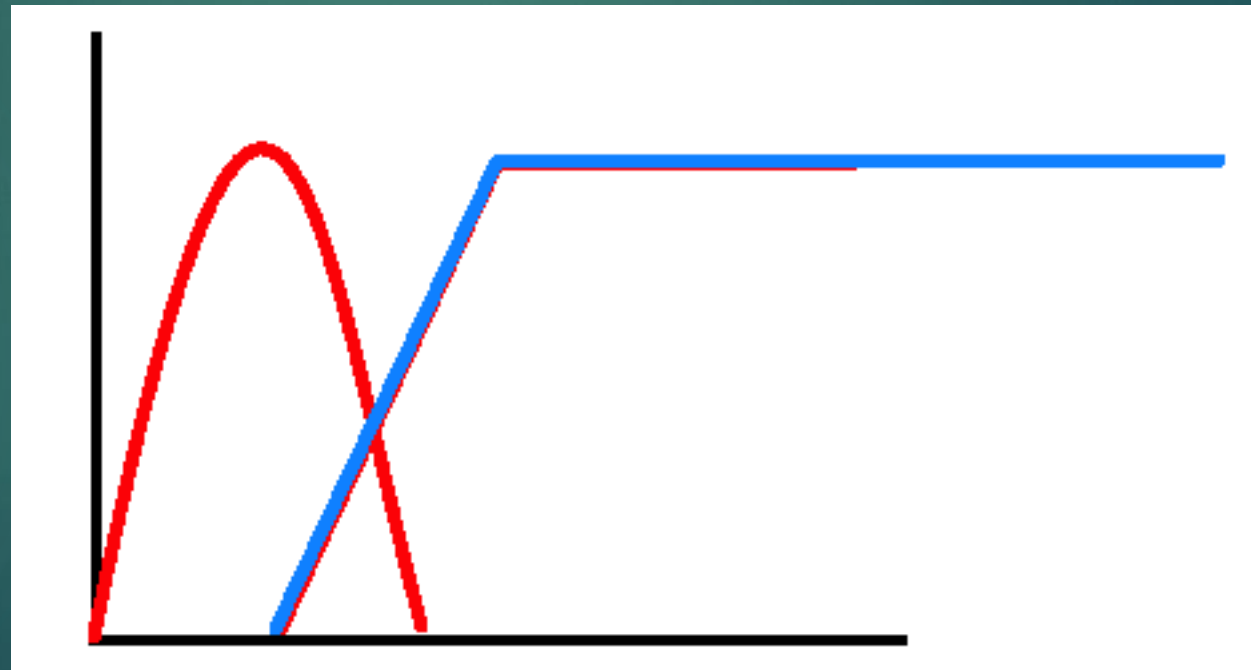
**6hr of severe RUQ pain with  
ALT 400 & AST 300 & ALP  
140**



**US abdo**

# Bile duct stone

- ▶ Expected liver enzymes pattern



**If Cholestatic pattern**

**US or CT**

**Dilated duct**

**Yes**

**No**

**Likelihood of obstruction**

- **High likelihood of obstruction:** ERCP (US: stone in CBD, cholangitis)
- **Intermediate likelihood:** MRCP/EUS (mild elevated ALT/AST or Bili)


**Low**

**Obstructive cause**  
**Likely Malig**  
• CT chest/abdo/pelvis  
• EUS/FNA  
• ERCP  
**Likely Stones → ?ERCP**

**If -ve**

**Intra-hepatic cause**  
Work up for hepatocellular & Intrahepatic choleststsis  
AMA  
MRCP  
Liver Bx

Isolated elevated ALP





# Alcohol

- ▶ How to ask?
- ▶ AST:ALT
- ▶ Bili?
- ▶ IgA, ACE, Anti-ttg

# HAV

- ▶ **The primary route of transmission** of HAV is the fecal-oral route, by either
  - ▶ Person-to-person contact or
  - ▶ Ingestion of contaminated food or water.
- ▶ Infection with HAV does not result in chronic infection, only in an acute self-limited episode of **hepatitis**.
- ▶ Complete clinical recovery is achieved in 2-6 months for almost everyone.

# HAV: Clinical presentation

- ▶ **Adults with HAV infection** usually present with one of the following five clinical patterns:
  - (1) Asymptomatic
  - (2) Symptomatic with jaundice and self-limited after approximately 8 weeks,
  - (3) Rarely -- Cholestatic, with jaundice lasting 10 weeks or more,
  - (4) 10% of symptomatic patients, relapsing, with two or more bouts of acute HAV infection occurring over a 6- to 10-week period,
  - (5) Rarely -- FHF.
- ▶ **Children**
  - ▶ If younger than 2 years are usually asymptomatic (80%).
  - ▶ If 5 years or older symptoms develop in most children (80%).

# HAV: Clinical presentation

## ▶ Hx:

- ▶ Prodromal symptoms in patients with acute hepatitis A include fatigue, weakness, anorexia, nausea, vomiting, and abdominal pain.
- ▶ Less common symptoms are fever, headache, arthralgias, myalgias, and diarrhea.
- ▶ Symptoms may last from a few days to 2 weeks
- ▶ and usually decrease with the onset of clinical jaundice.

## ▶ Px:

- ▶ Right upper quadrant tenderness and mild liver enlargement are found on physical examination in 85% of patients;
- ▶ splenomegaly and cervical lymphadenopathy are each present in 15%.

# HAV: Rx

- ▶ Treatment is symptomatic.
- ▶ Neither the cholestatic variant nor relapsing **hepatitis A** is associated with an increase in mortality.
- ▶ Acute **hepatitis A**, unlike **hepatitis E**, is not associated with a higher mortality rate in pregnant women.

# HBV prevalence

- ▶ The prevalence of **hepatitis B** varies markedly around the world.
- ▶ Highly endemic regions (**8% or more of the population are chronic HBV carriers**), such as
  - ▶ Southeast Asia (excluding Japan),
  - ▶ China, and
  - ▶ much of Africa,.

# HBV

## Transmission

- ▶ **Vertical Transmission:** Transmission of infection from an HBV carrier mother to her neonate accounts for the majority of new infections in the world today.
  - ▶ **If HbeAg +ve:** 80% of HBsAg-positive mothers who are HBeAg -positive transmit the disease to their offspring. whereas mothers who are positive for antibody to HBeAg (anti-HBe) transmit the disease less frequently (20%)
- ▶ **Other common sources of infection are**
  - ▶ High risk Sexual behavior
  - ▶ Receipt of blood products or organs.
  - ▶ IVDU
  - ▶ tattooing, body piercing
  - ▶ Household contact with an HBV carrier,
  - ▶ Hemodialysis
  - ▶ Needle stick injury

# HBV: Acute vs chronic

- ▶ **The age at which a person becomes infected with HBV is a principal determinant of the clinical outcome.**
  - ▶ In adults: only 1% to 5% of these persons become chronically infected when get HBV infection
  - ▶ By contrast, as many as 95% of infected neonates become chronic HBV carriers because of immunologic tolerance to the virus.
  - ▶ In adults, fulminant liver failure caused by acute hepatitis B occurs in less than 1% of cases .



# HBV: Natural history if chronic

## Natural history and assessment of patients with chronic HBV infection

### HBV markers

HBsAg  
HBeAg/anti-HBe  
HBV DNA

### Liver disease

Biochemical parameters: ALT  
Fibrosis markers: non-invasive markers of fibrosis (elastography or biomarkers) or liver biopsy in selected cases

	HBeAg positive		HBeAg negative	
	Chronic infection	Chronic hepatitis	Chronic infection	Chronic hepatitis
HBsAg	High	High/intermediate	Low	Intermediate
HBeAg	Positive	Positive	Negative	Negative
HBV DNA	>10 <sup>7</sup> IU/ml	10 <sup>4</sup> -10 <sup>7</sup> IU/ml	<2,000 IU/ml <sup>oo</sup>	>2,000 IU/ml
ALT	Normal	Elevated	Normal	Elevated*
Liver disease	None/minimal	Moderate/severe	None	Moderate/severe
Old terminology	Immune tolerant	Immune reactive HBeAg positive	Inactive carrier	HBeAg negative chronic hepatitis

**Fig. 1. Natural history and assessment of patients with chronic HBV infection based upon HBV and liver disease markers.** \*Persistently or intermittently. <sup>oo</sup>HBV DNA levels can be between 2,000 and 20,000 IU/ml in some patients without signs of chronic hepatitis.

# HBV: Natural history

- ▶ **Resolved CHB infection** is defined by clearance of HBsAg with acquisition of antibody to HBsAg.
  - ▶ **Approximately 0.5% of persons with inactive CHB** will clear HBsAg yearly; and most will develop antibody to HBsAg (anti-HBs).
  - ▶ **Low levels of HBV DNA** are transiently detected in the serum in the minority of persons achieving seroclearance.

# Clinical presentation: Acute Hepatitis B in adults


- ▶ Acute infections are heralded by a serum sickness–like prodrome of fever, arthralgia or arthritis, and rash, which is most commonly maculopapular or urticarial, in 15% of patients.
- ▶ These features generally **abate before the manifestations of liver disease which include jaundice and peak serum aminotransferase elevations are observed.**
- ▶ Clinical symptoms and jaundice generally disappear after one to three months. In general, elevated serum ALT levels and serum HBsAg titers decline and disappear together, and in approximately 80% of cases.

# Clinical presentation: Chronic Hepatitis B

- ▶ Asymptomatic
- ▶ Fatigue
- ▶ Symptoms and signs of CLD
- ▶ **Extrahepatic Manifestations:** arthritis, dermatitis, glomerulonephritis, polyarteritis nodosa, cryoglobulinemia, papular acrodermatitis, and polymyalgia rheumatica.
- ▶ **Acute Flares in Chronic Hepatitis B**
  - ▶ Spontaneous Flares
  - ▶ Immunosuppressive Therapy-Induced Flares

# HBV: Diagnosis

- ▶ HBsAg
- ▶ HbcAB IgG vs IgM
- ▶ HbsAb
- ▶ Tests for co-infection:
  - ▶ HCV
  - ▶ HDV
  - ▶ HIV

- 
- ▶ HBsAg +ve
  - ▶ HbcAb +ve
  - ▶ HBsAb -ve

- ▶ HBsAg -ve
- ▶ HbcAb +ve
- ▶ HBsAb +ve

- ▶ HBsAg -ve
- ▶ HbcAb -ve
- ▶ HBsAb +ve

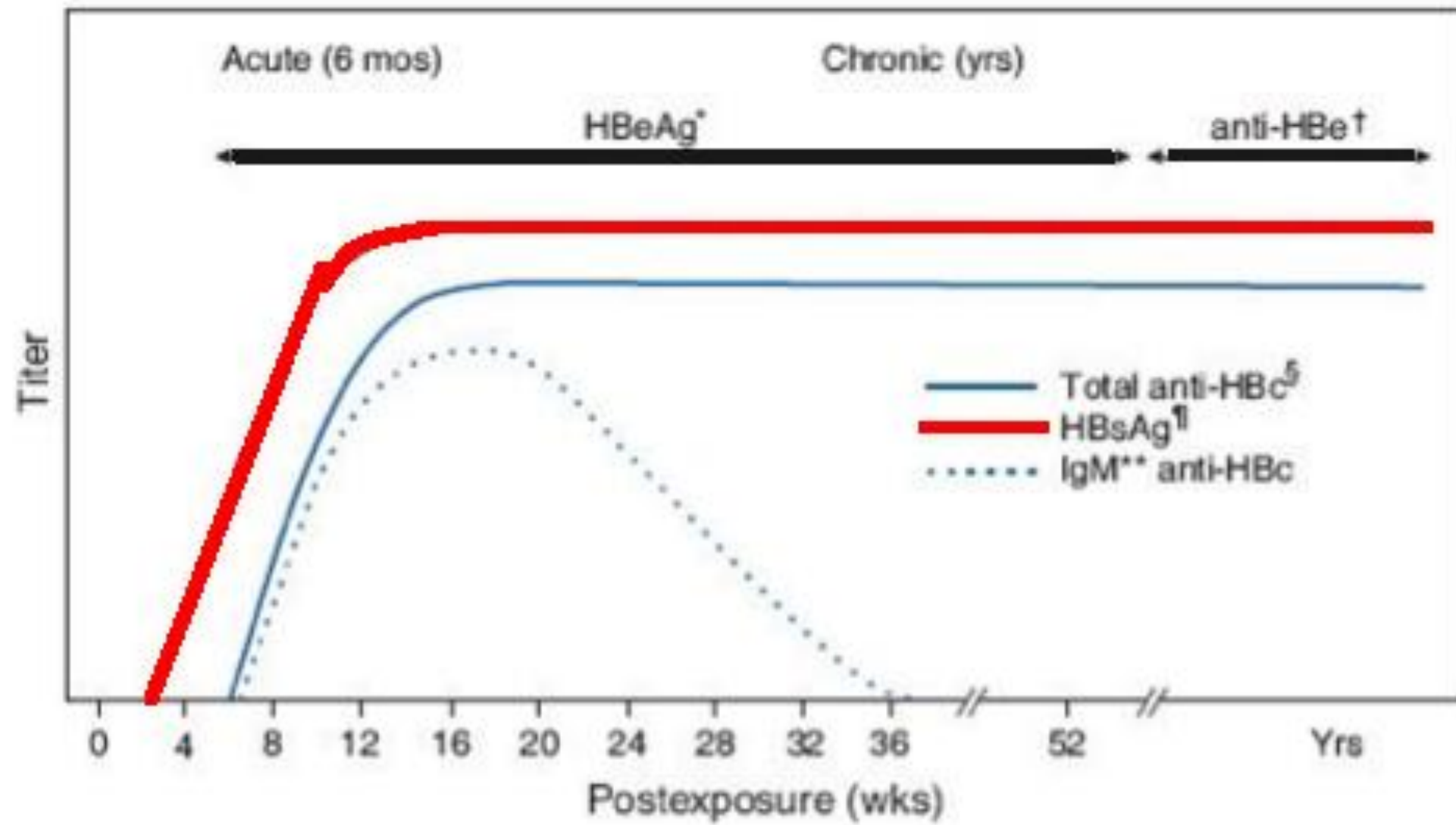
# HBV: Diagnosis of acute or CHB

## ▶ HBsAg

- ▶ Appears in serum 2 to 10 weeks.
- ▶ Persistence of HBsAg for >6 months implies progression to chronic HBV infection.
- ▶ In self-limited acute hepatitis, HBsAg usually becomes undetectable after 4-6 months.
  - ▶ The disappearance of HBsAg is followed several weeks later by the appearance of anti-HBs.
  - ▶ Anti-HBs may not be detectable during a window period of several weeks to months after the disappearance of HBsAg.

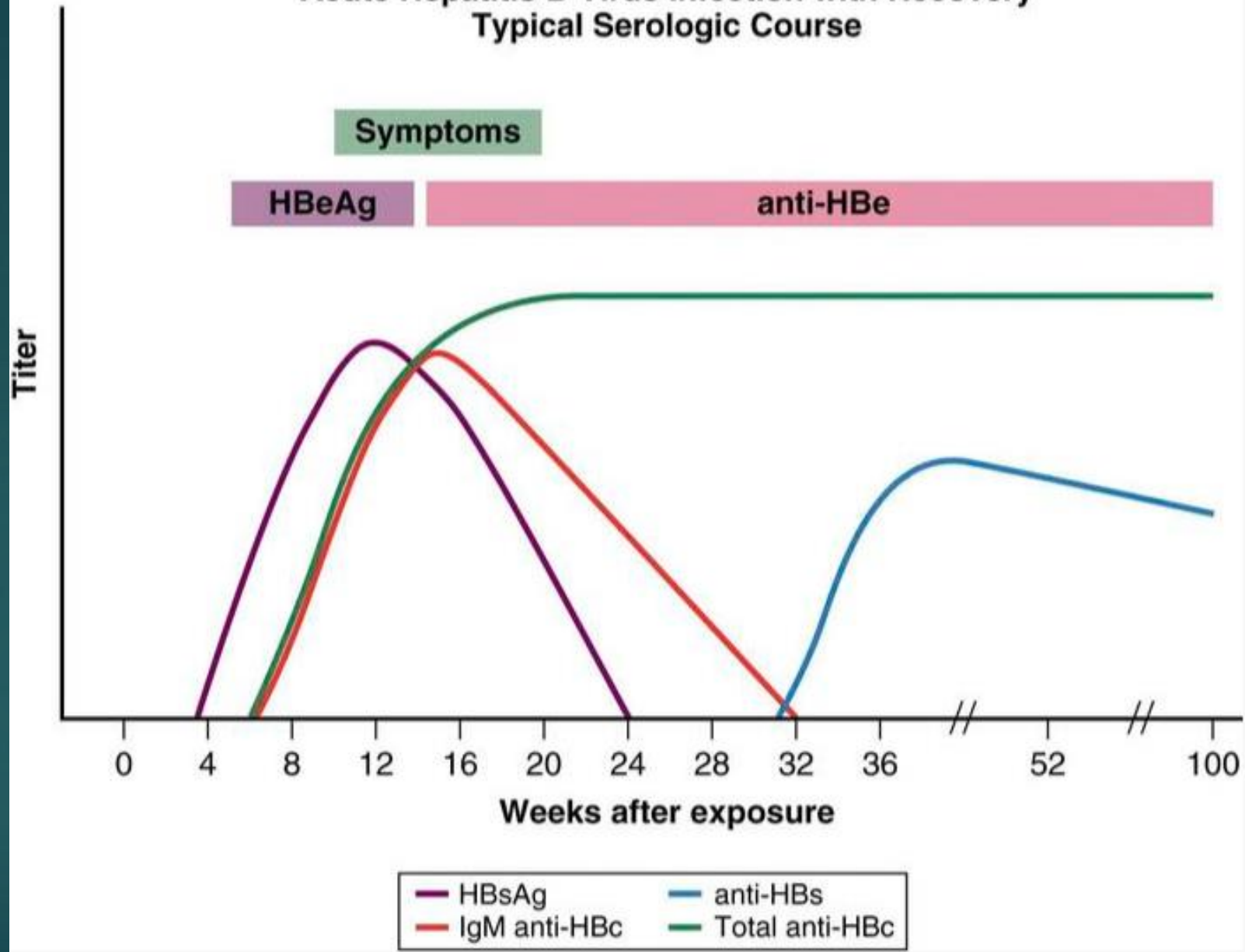
## ➤ HbcAB IgM vs IgG

- ▶ During the window period, the diagnosis of acute HBV infection is made by the detection of IgM anti-HBc in serum. IgM class is usually detectable for 4 to 6 months after an acute episode of hepatitis or during exacerbation of chronic hepatitis B and rarely for up to two years.
  - ▶ IgG Anti-HBc persists in persons who recover from acute hepatitis B and CHB.
- ▶ The accurate diagnosis of acute hepatitis B require testing with immunoglobulin (Ig) M antibody to hepatitis B core antigen (HBcAg) (IgM anti-HBc)





# Acute Hepatitis B Virus Infection with Recovery Typical Serologic Course



# HBV: Diagnosis of acute or CHB

- ▶ **Coexistence of HBsAg and anti-HBs** in serum has been reported in approximately 25% of HBsAg-positive persons and occurs more commonly in persons with chronic hepatitis B than in those with acute hepatitis B.
- ▶ **HbeAg**
  - ▶ Persistence of HBeAg three or more months after the onset of illness indicates a high likelihood of transition to chronic HBV infection.
  - ▶ The finding of HBeAg in the serum of an HBV carrier indicates greater infectivity, a high level of viral replication, and the need for antiviral therapy.

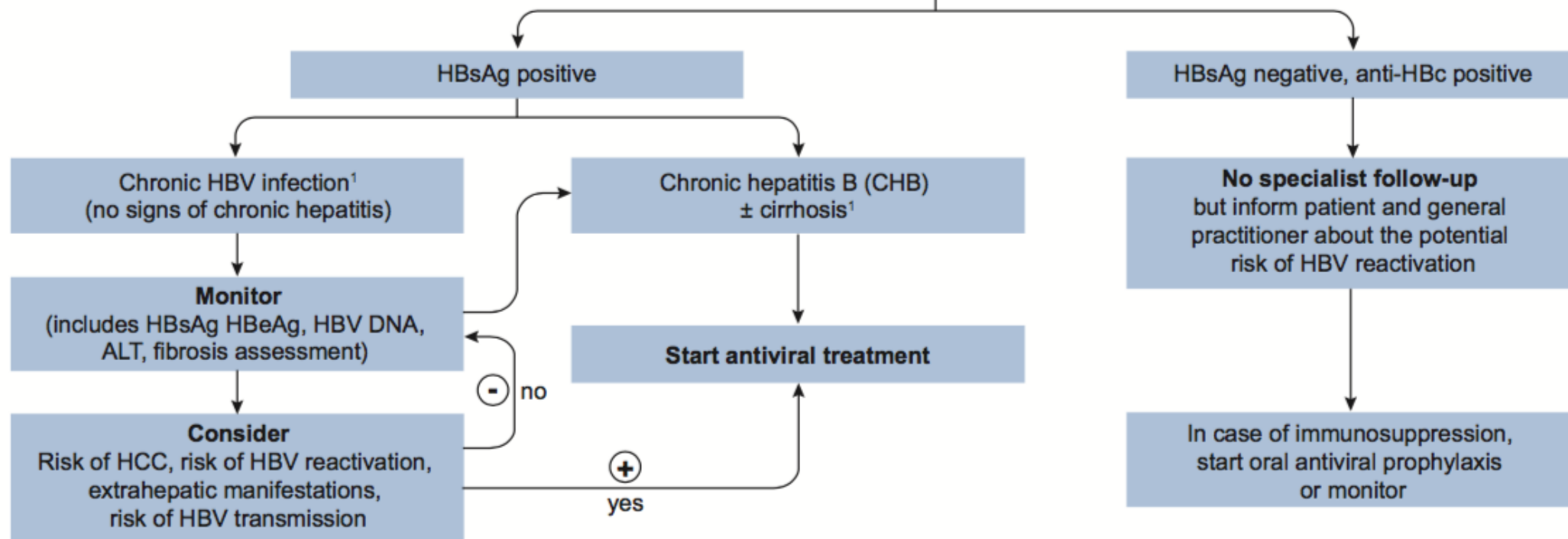
# Chronic HBV: Monitoring & Rx

- ▶ The measurement of **serum HBV DNA is** commonly used to evaluate a patient's candidacy for antiviral therapy and to monitor response during treatment.
- ▶ Owing to the fluctuating nature of CHB, the accuracy of one high HBV DNA level at a single time point in predicting prognosis is poor and regular monitoring of disease status is imperative to determine need for antiviral therapy.
- ▶ **ALT**
- ▶ **Fibroscan**: noninvasive methods to assess fibrosis severity.
- ▶ **Liver biopsy** provides an assessment of the severity of necroinflammation and fibrosis, and may be especially useful for persons who lack clear-cut indications for treatment. Whereas liver biopsy is regarded as the best method to assess the severity of inflammatory activity and fibrosis, noninvasive methods to assess fibrosis severity are also useful.
- ▶ **US**: HCC screening

# Chronic HBV: Monitoring & Rx

- ▶ Pegylated interferon (Peg-IFN).
  - ▶ Short duration of therapy
  - ▶ Before pregnancy
  - ▶ Side effects
- ▶ Nucleos(t)ide analogs (NAs) therapy.
  - ▶ Overall, all NAs have an excellent safety profile across a wide spectrum of persons with CHB, including those with decompensated cirrhosis.

## Suspected HBV infection



**Table 2. Main concepts and features of current treatment strategies of chronic hepatitis B.**

Features	PegIFN $\alpha$	ETV, TDF, TAF
Route of administration	Subcutaneous injections	Oral
Treatment duration	48 weeks	Long-term until HBsAg loss (stopping NA after some years might be considered in selected cases) <sup>1</sup>
Tolerability	Low	High
Long-term safety concerns	Very rarely persistence of on-treatment adverse events (psychiatric, neurological, endocrinological)	Probably not (uncertainties regarding kidney function, bone diseases for some NA)
Contraindications	Many ( <i>i.e.</i> , decompensated disease, co-morbidities etc.)	None (dose adjustment according to eGFR <sup>2</sup> )
Strategy	Induction of a long-term immune control by finite treatment	Stopping hepatitis and disease progression by inhibiting viral replication
Level of viral suppression	Moderate (variable response pattern)	Universally high
Effect on HBeAg loss	Moderate, depending on baseline characteristics	Low in the first year, increases to moderate during long-term treatment
Effect on HBsAg levels	Variable, depending on baseline characteristics (overall higher as compared to NA)	Low: slowly increases with treatment time in HBeAg-positive patients <sup>3</sup> ; usually very low in HBeAg-negative patients
Risk of relapse after treatment cessation	Low for those with sustained response 6–12 months after therapy	Moderate if consolidation treatment provided after HBeAg seroconversion. High for HBeAg-negative disease
Early stopping rules	Yes	No
Risk of viral resistance development	No	Minimal to none <sup>4</sup>

PegIFN $\alpha$ , pegylated interferon alfa; ETV, entecavir; TDF, tenofovir disoproxil fumarate; TAF, tenofovir alafenamide; NA, nucleoside/nucleotide analogues; eGFR, estimated glomerular filtration rate.

<sup>1</sup> See section on 'Treatment strategies'.

<sup>2</sup> Dose adjustments in patients with eGFR <50 ml/min are required for all NA, except for TAF (no dose recommendation for TAF in patients with CrCl <15 ml/min who are not receiving haemodialysis).

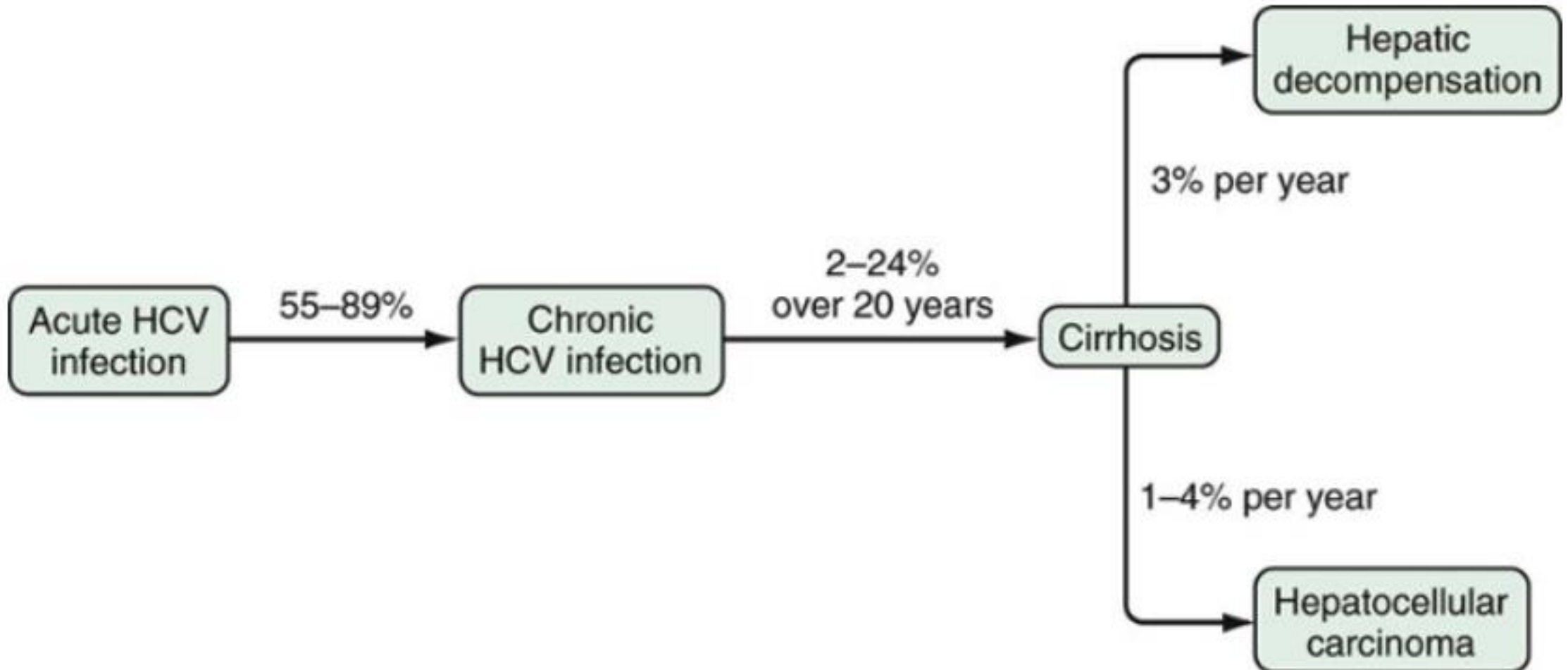
<sup>3</sup> A plateau in serologic responses has been observed beyond treatment year 4.

<sup>4</sup> So far no TDF or TAF resistance development has been detected.

# HCV

- ▶ Hepatitis C virus (HCV) infection is one of the main causes of chronic liver disease worldwide.
- ▶ The long-term impact of HCV infection is highly variable, ranging from minimal histological changes to extensive fibrosis and cirrhosis with or without hepatocellular carcinoma (HCC).

# HCV: Natural history





# HCV: Transmission

- ▶ Modes of transmission of HCV can be divided into
  - ▶ Percutaneous (blood transfusion and needle stick inoculation)
  - ▶ Non-percutaneous (sexual contact and perinatal exposure).
- ▶ The risk of **sexual transmission** is negligible in monogamous couples that do not engage in high-risk sexual practices. However, epidemiologic studies have shown that persons with multiple sex partners have a higher prevalence of HCV infection.
- ▶ the risk of **perinatal transmission of HCV infection is low**, averaging 5.1% to 6.7% for HCV-monoinfected patients.
- ▶ The Centers for Disease Control and Prevention have concluded that **breast feeding** by HCV-infected mothers is generally safe.

# HCV: genotypes

- ▶ Genotypes 1, 2, and 3 are most common in North America and Europe
- ▶ Genotype 4 is most common in the Middle East
- ▶ Genotypes 5 and 6 are most common in Southeast Asia

# HCV: clinical features

## ▶ Acute hepatitis C

- ▶ is rarely seen in clinical practice because nearly all cases are asymptomatic.
- ▶ The rate of viral persistence after acute infection varies, ranging from 45% to more than 90%.
- ▶ Younger and female patients having the lowest rates of chronicity. Other factors that may play a role include the source of infection and size of inoculum.

▶ **Anti-HCV** will be detected between Week 2 and month 3.

## ▶ HCV RNA

- ▶ is detectable within 2 to 3 weeks of exposure
- ▶ In patients whom the infection resolves spontaneously, loss of HCV RNA from serum usually occurs within 3 to 4 months of the onset of clinical disease

# Extrahepatic Manifestations

- ▶ Symptoms and signs include
  - ▶ Fatigue,
  - ▶ Arthralgias, arthritis,
  - ▶ Purpura,
  - ▶ Raynaud's phenomenon,
  - ▶ Vasculitis,
  - ▶ Peripheral neuropathy, and nephropathy.
- ▶ Among HCV-infected patients 19% to 50% have cryoglobulins in serum, but clinical manifestations of **cryoglobulinemia** are reported in only 5% to 10% of these patients and are more common in patients with cirrhosis.

# HCV: Diagnosis

- ▶ Anti-HCV antibodies are the first-line diagnostic test for HCV infection.
- ▶ If anti-HCV antibodies are detected, HCV RNA should be done.
- ▶ If detectable viral load, HCV Genotyping should be done.
- ▶ HCV RNA testing
  - ▶ should be part of the initial evaluation, in the case of suspected
    - ▶ acute hepatitis C or
    - ▶ in immunocompromised patients,
  - ▶ The diagnosis of acute and chronic HCV infection is based on the detection of HCV RNA by a sensitive molecular method limit of detection <15 international units [IU]/ml).
- ▶ In patients with acute Hepatitis C, HCV RNA should be retested 3 to 4 months after clinical presentation.

# HCV: Rx

- ▶ Researcher have recently made significant advances in treatment for hepatitis C using new, "direct-acting" anti-viral medications, sometimes in combination with existing ones. As a result, people experience
  - ▶ Better outcomes,
  - ▶ Fewer side effects and
  - ▶ Shorter treatment times.
- ▶ The choice of medications and length of treatment depend on
  - ▶ Presence of Cirrhosis,
  - ▶ The hepatitis C genotype,
  - ▶ Prior treatments
  - ▶ Renal function

# Autoimmune hepatitis

- ▶ AH is a chronic liver disease that affects mainly women
- ▶ is characterized by
  - ▶ Hypergammaglobulinaemia,
  - ▶ Circulating autoantibodies,
  - ▶ Interface hepatitis on liver histology, and
  - ▶ a favorable response to immunosuppression.
- ▶ The disease, if untreated, often leads to cirrhosis, liver failure and death.
- ▶ The disease can also affect males and may present at any age and in all ethnic groups.

# AIH: Sub-classification

- ▶ The clinical implications arising from this sub- classification are uncertain
- ▶ **Indirect immunofluorescence** is the test of choice for all auto-antibodies except **ASLA**. Immunoassays (ELISA/Western blotting) are the tests of choice for the detection of SLA/LP. Methods and cut- off values should be reported by the laboratory.
- ▶ AIH-1:
  - ▶ the more frequent type of AIH (accounts almost for 90% of AIH cases);
  - ▶ detection of **ANA, or ASMA**
  - ▶ association with HLA DR3, DR4 and DR13;
- ▶ AIH-2:
  - ▶ accounts for up to 10% of AIH cases;
  - ▶ detection of **anti-LKM1, anti-LC1** and rarely anti-LKM3;
  - ▶ association with HLA DR3 and DR7;
  - ▶ onset usually in childhood and young adulthood
- ▶ AIH-3:
  - ▶ **ASLA/LP positive**



# AIH: Clinical presentation

- Any age
- Both sexes (♀: ♂ 3:1)
- ▶ Broad range from asymptomatic to acute/severe or even fulminant
- ▶ Most common clinical phenotype of the disease (two thirds of patients) is characterized by an **insidious onset** either
  - ▶ without any apparent symptom or
  - ▶ with one or more of the following non-specific symptoms:
    - ▶ fatigue, general ill health,
    - ▶ right upper quadrant pain,
    - ▶ anorexia, weight loss, nausea,
    - ▶ fluctuating jaundice
    - ▶ and polyarthralgia involving the small joints without arthritis
    - ▶ Amenorrhea is also common .
- ▶ Acute onset of AIH does exist (about 25% of patients)

# AIH: Laboratory findings

- ▶ the typical biochemical profile of the disease is a predominantly hepatic pattern:
  - ▶ with bilirubin concentrations and aminotransferases ranging from just above the upper limits of normal to more than 50 times these levels,
  - ▶ with usually normal or only moderately elevated cholestatic enzymes,
  - ▶ Degree of ALT/AST elevations does not reliably reflect severity of AIH at the histological level.

# AIH: Laboratory findings

- ▶ Of note, in some patients with acute presentation of AIH, immunoglobulin G (IgG) levels may be within the normal range and antinuclear (ANA) and/or smooth muscle antibodies (SMA) as first screening may be negative.
- ▶ **The presence of high IgG levels is a very distinctive feature** (IgA and IgM levels are usually normal). Increased IgA or IgM levels suggest different diseases such as alcoholic steatohepatitis and PBC, respectively.
- ▶ It is important to underline that the range within which c- globulins and IgGs are considered normal is wide. This may explain why a proportion of patients may show apparently “normal” IgG levels at diagnosis. Many, if not most of these patients have IgG levels in the upper range of normal, and show a marked fall upon initiation of therapy, sometimes even to levels below the normal range . the level of immunoglobulins is an important and useful marker in monitoring the response to treatment and the achievement of remission.

# AIH: DIAGNOSIS

- ▶ The diagnosis of AIH relies particularly on the presence of
  - ▶ **Hypergammaglobulinemia** (A selectively elevated IgG in the absence of IgA and IgM elevation is particularly suggestive of AIH )
  - ▶ **Autoantibodies**, and
  - ▶ **Typical or compatible histology.**
- ▶ Adult patients with AIH and cholestatic lab changes should be considered for **MRCPC** to recognize sclerosing cholangitis
- ▶ When severe coagulopathy is present the transjugular approach can be used, in particular, in acute/fulminant onset of the disease.
- ▶ the simplified criteria for AIH are user-friendly and a good tool for daily clinical practice but without a diagnostic ‘‘gold standard’’ the clinicians must regard any diagnostic score only as an aid to diagnosis of AIH and the criteria should be used alongside clinical judgment.

# AIH: Histology

- ▶ There are no morphological features that are pathognomonic of AIH, but interface hepatitis, periportal necrosis, and rosetting of hepatocytes are suggestive of AIH.
- ▶ **Interface hepatitis with dense lymphoplasmocytic infiltrates** is the typical hallmarks of AIH .
  - ▶ Plasma cells are typically abundant at the interface and throughout the lobule, but their paucity in the inflammatory infiltrate does not preclude the diagnosis .
  - ▶ Interface hepatitis is not disease specific and patients with drug-related, viral or immune- mediated disease may show similar features.

# AIH: Rx

- ▶ Treatment of AIH should be aimed to obtain
  - ▶ complete biochemical (ALT/AST & IgG)
  - ▶ histological resolution of the disease

# AIH: Rx

- ▶ In mild asymptomatic older patients with mild necroinflammatory activity on liver biopsy:
  - is there any benefits of immunosuppressive therapy?
  - Treatment related side effects should be counterbalanced to the risk of sub-clinical disease.
- ▶ **Points to support observation:**
  - ▶ Ten-year survival in untreated patients with mild disease was reported to be 67–90% and in an uncontrolled study untreated asymptomatic patients had similar survival to those receiving immunosuppression. Thus, a decision not to treat might be justified, especially if there are relative contraindications to the use of steroids.
  - ▶ In addition, spontaneous resolution of AIH may occur.
- ▶ **Points to support treatment:**
  - ▶ As AIH is a lifelong disease, and progressive fibrosis may take many years to become clinically apparent, the observational studies published may have been too short and may have included too few patients in order to demonstrate the benefit of immunosuppressive therapy in milder disease.
  - ▶ AIH has a fluctuating, unpredictable disease behaviour and a substantial proportion of asymptomatic patients become symptomatic during the course of their disease follow-up, and progression towards end-stage liver disease with liver cirrhosis.

# Primary sclerosing cholangitis (PSC)

- ▶ It is **a chronic cholestatic liver and biliary tract disease**, defined as the presence of **beading and stricture formation of the intra and/or extrahepatic bile** ducts that cannot be ascribed to another cause, thus differentiating PSC from secondary sclerosing cholangitis.
- ▶ Many, if not most, cases of PSC are associated with IBD.
- ▶ The prevalence of PSC in UC has been estimated to be ~5%.
- ▶ PSC was also more common in men and those with pan-colitis.

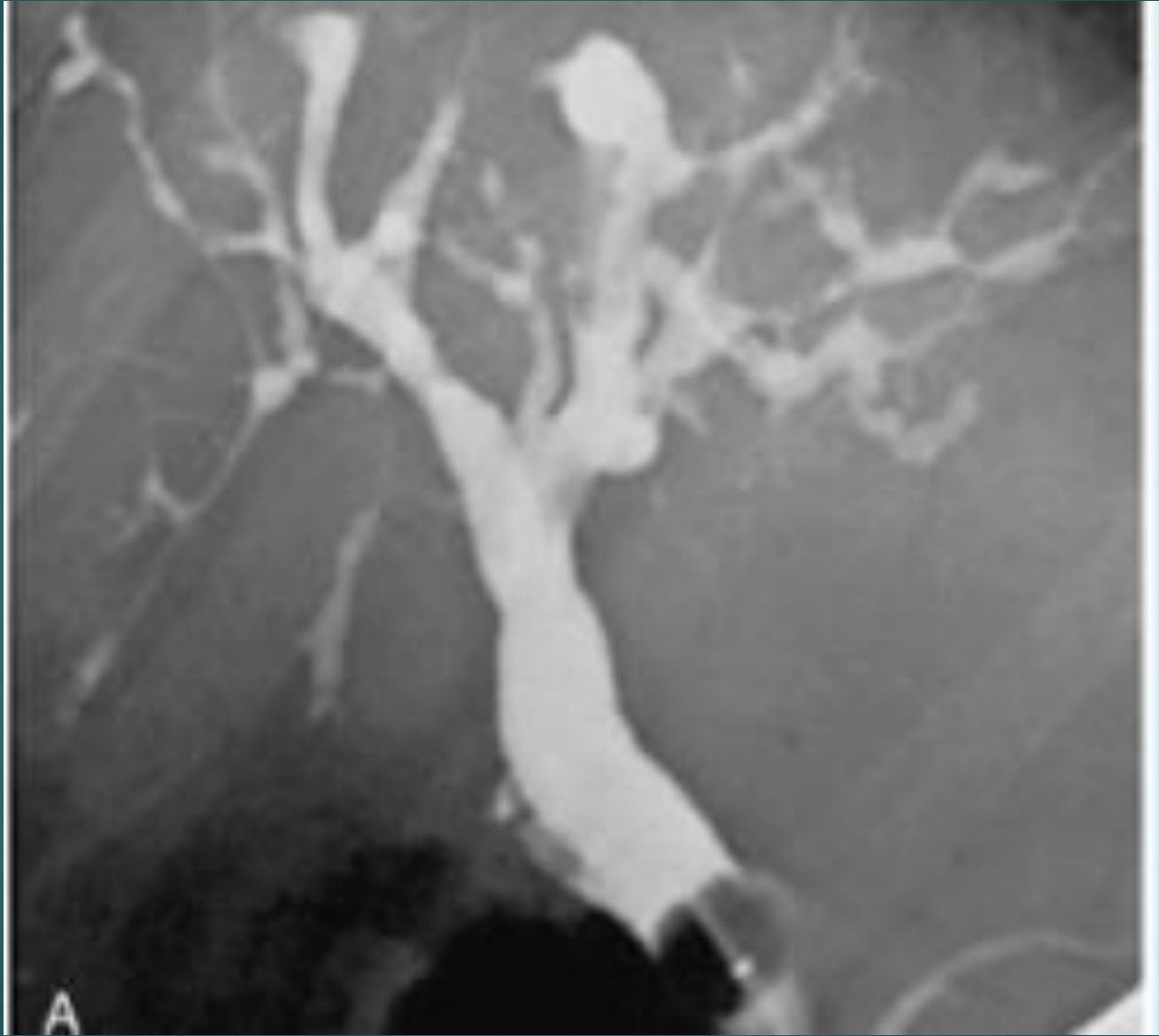


# PSC: Signs and symptoms

- ▶ PSC may be asymptomatic for long periods but may also have an aggressive course, leading to
  - ▶ **Recurrent biliary tract obstruction**
  - ▶ **Recurrent episodes of cholangitis, and**
  - ▶ **Cirrhosis/ESLD**
- ▶ A large number of patients present without symptoms and come to attention simply by **a finding of persistently abnormal liver tests.**
- ▶ When symptoms occur, **fatigue maybe the most commonly** noted finding.
- ▶ **Sudden onset of pruritus** should signal the possibility of obstruction of the biliary tree.
- ▶ other patients may experience **chronic right upper quadrant discomfort.**

# PSC: Diagnosis

- ▶ The diagnosis of PSC requires the following:
  - **Chronic cholestatic liver** test abnormalities, in particular elevations of serum ALP level.
  - **Cholangiographic (MRCP or ERCP) evidence**
    - of multifocal strictures and saccular dilatation of the intrahepatic and extrahepatic bile ducts, which may lead to a “beaded” appearance
  - **A liver biopsy, if performed:**
    - characteristic “onion skin” fibrosis, which is almost pathognomonic for the disease, is seen infrequently.
    - Small duct PSC makes up 5% of cases
- ❖ GGT will be elevated and the aminotransferases are often times only modestly elevated.
- ❖ Bilirubin and albumin levels are often normal at the time of diagnosis.



# PSC: Rx

- ▶ At this time, there is no established medical treatment for patients with PSC. However, we treat complications of the disease.
- ▶ MRCP & CA19-9 annually
- ▶ Annual colonoscopy if known to have UC

# Primary biliary cirrhosis

- ▶ is a chronic cholestatic disease with a progressive course.
- ▶ The etiology of PBC is thought to be due to a combination of genetic predisposition and environmental triggers.

# Clinical Manifestations of PBC

- ▶ **Fatigue:** is the most common symptom
- ▶ **Pruritus:** a more specific symptom of PBC

# PBC: *Liver Biochemical Tests*

- ▶ Most patients with PBC have abnormal liver tests including
  - ▶ elevations of ALP
  - ▶ mild elevations of aminotransferases activity, and
  - ▶ increased levels of immunoglobulins (mainly immunoglobulin M [IgM]).
- ▶ The degree of elevation in ALP is strongly related to the severity of ductopenia and inflammation;
- ▶ the increase in aminotransferase activity and IgG levels reflects mainly the degree of periportal and lobular necrosis and inflammation.

# PBC: *Autoantibodies*

- ▶ AMA is found in nearly 95% of patients with PBC.
- ▶ ANA and ASMA are found in nearly half of patients with PBC.
- ▶ In approximately 5%-10% of the patients, AMA antibodies are absent or present only in low titer (1/80), when immunofluorescent techniques are used.



# PBC: Histology

PBC is characterized by

- ▶ chronic, nonsuppurative cholangitis that mainly affects interlobular and septal bile ducts.
  - ▶ When focal lesions show intense inflammatory changes and necrosis around bile ducts, the term "florid duct lesion" is often used.
  - ▶ Bile duct paucity or ductopenia
- 
- ▶ The size of the liver biopsy specimen is important. The probability of observing cholangitis and bile duct destruction increases with the number of portal tracts because of the typical patchy distribution of the lesions. **At least 10-15 portal tracts should be present.**

# PBC: Diagnosis

- ▶ The diagnosis of PBC should be suspected in the setting of chronic cholestasis after exclusion of other causes of liver disease. The diagnosis is suspected based on
  - cholestatic serum liver tests and largely confirmed with tests for AMA.
  - A liver biopsy can be used to further substantiate the diagnosis if needed.
- ▶ *The diagnosis of PBC can be established when two of the following three criteria are met:*
  - ▶ *Biochemical evidence of cholestasis based mainly on alkaline phosphatase elevation.*
  - ▶ *Presence of AMA.*
  - ▶ *Histologic evidence of nonsuppurative destructive cholangitis and destruction of interlobular bile ducts .*


# PBC: Therapy

- ▶ UDCA in a dose of 13-15 mg/kg/day is the only therapy for PBC approved by the U.S. Food and Drug Administration. The drug is initiated gradually and generally given in two divided doses.


# Read about

- ▶ Alcoholic hepatitis
- ▶ Non-alcoholic steatohepatitis
- ▶ Paracetamol poisoning
- ▶ Vascular diseases that could cause liver injury
- ▶ Wilson's disease

# Take home messages



# Cases



# Case 1

- ▶ A 24-year-old woman presents with **acute onset of right upper quadrant pain, and increased abdominal girth**. She has no known past medical history. She has no risk factors for liver disease. Family history is unremarkable. **Her only medication is a birth control pill. Exam reveals tender hepatomegaly and obvious ascites.**
- ▶ Labs reveal mildly increased bilirubin and alkaline phosphatase only. Imaging studies reveal hepatomegaly (especially the caudate lobe) and ascites.
- ▶ What is the most likely diagnosis?
- ▶ **Acute Budd-Chiari syndrome**

# Case 2

- ▶ You see in consultation a 43-year-old man because of **jaundice**. **He has been drinking 1 pint a day (sometimes more) of whiskey for the past 4 months**. He denies other risk factors for liver disease. Examination reveals a blood pressure 110/80, pulse 110; respirations 16, temperature 37°C. He is jaundiced, has multiple spider telangiectasias, and parotid gland swelling, but no muscle wasting. Abdominal examination reveals a liver 4 finger breadths below right costal margin, a palpable spleen tip, but no shifting dullness. Laboratory studies:
  - ▶ **Bilirubin 150 mmol/l , mostly direct, AST 212 U/L , ALT 63 U/L (normal: 0-35 U/L), ALP 140 U/L (normal: 36-92 U/L), INR 1.5 , Ferritin 480 ng/mL**
  - ▶ **What is the pattern?** Direct hyperbili. with hepatocellular pattern
  - ▶ **Do you need to do work up?** Viral hepatitis , ?Fibroscan
  - ▶ **How to ask about alcohol?**



# Case 3

- ▶ A 35-year-old woman is referred to you for elevated liver enzymes. She was found to have:
  - ALT 255 U/L , AST 205 U/L , Alkaline phosphatase 121 U/L
  - Total bilirubin 18 mmol/l
- ▶ **Her ANA is positive at a 1:80 & IgG is elevated.** Her albumin and INR are at normal levels. She has mild tenderness over her right upper quadrant. **She is otherwise healthy, with the exception of being treated intermittently with nitrofurantoin for recurrent urinary tract infections.** Viral serologies against hepatitis A, B, C, and E are all negative. ultrasound revealed a heterogenous echotexture of a normal-sized liver.
- ▶ **What is the pattern?** Hepatocellular with normal bili.
- ▶ **What should you do next for the diagnosis or treatment of this patient?**
- ▶ **This pattern is consistent with an autoimmune hepatitis-like presentation induced by nitrofurantoin. Simply stopping the offending medication will usually result in normalization of her liver enzyme values.**
- ▶ **Of note, an ANA that is positive at 1:80 dilution is fairly non-specific, and may be seen in 30% of adults, especially women, without disease.**

# Case 4

- ▶ A 45-year-old woman presents for evaluation of elevated liver tests. She has a past medical history of diabetes, & hypertension. She does not drink alcohol or use tobacco. Her medical regimen consists of insulin, metformin, & lisinopril. On physical exam, BMI is 39, blood pressure is 160/98. Abdominal exam reveals an obese abdomen without hepatosplenomegaly, masses, hernias, or ascites. Her evaluation included:
  - **AST 330 U/L , ALT 380 U/L** , Alkaline phosphatase 80
  - Total bilirubin is normal
  - **ANA 1:640, ASMA 1:160, IgG is elevated**, AMA negative
  - Hepatitis A IgM negative, HbsAg negative, HCV antibody negative
  - Abdominal ultrasound shows mild echogenic liver of 14 cm with normal spleen size and no focal masses or ascites.
  - **A liver biopsy** shows 50% macrovesicular steatosis, interface hepatitis comprised of lymphocytes, prominent plasma cells, and periportal fibrosis Metavir stage 2.
- ▶ **What is the pattern?** Hepatocellular with normal bili
- ▶ **What is the diagnosis?**
- ▶ **AIH & NASH**

# Case 5

- ▶ A 53-year-old woman presents for evaluation of elevated liver tests. She has a past medical history of diabetes mellitus treated with insulin and hyperlipidemia treated with atorvastatin, 20 mg daily. She does not drink alcohol and does not use tobacco. On exam, her BMI is 32, weight is 90 kg, BP is 130/80, heart rate is 88. On abdominal exam, there is no hepatosplenomegaly, ascites, masses, or hernias. Blood work shows:
  - ALT 221 U/L, AST 90 U/L , Total bilirubin is normal
  - Alkaline phosphatase 220 U/L (normal: 36-92 U/L)
  - ANA 1:160 , ASMA is negative, IgG is mildly elevated
  - Hepatitis C antibody negative, Hepatitis B surface antigen negative, Hepatitis A IgM negative
  - Normal US
- ▶ **What is the pattern?** Hepatocellular or may be mixed with normal bili
- ▶ **What is the most appropriate next step in her management?**
- ▶ **Liver biopsy +/- MRCP**
- ▶ **Up to 20% of patients with nonalcoholic fatty liver disease may have positive autoantibodies, and autoantibodies alone should not be used to establish the diagnosis of autoimmune hepatitis.**

# Case 6

- ▶ An 66-year-old man is found collapsed at a home. He is found to be in asystole. After CPR and other emergency treatments, a pulse is restored and she is taken to the hospital. His only known medications are furosemide, and insulin. On admission, her LFTs are normal. Twenty-four hours later, her **AST is 12,500 U/L and ALT is 7,450 U/L.**
- ▶ **What is the pattern?**
- ▶ **What is the diagnosis?**
- ▶ Shocked liver
- ▶ **Treatment:**
- ▶ Supportive

# Case 7

- ▶ A 65-year-old woman presents with malaise of 2 weeks and is found to have elevated ALT/AST. Her past medical history is significant for hypertension, hypothyroidism, and osteoarthritis. Her medications include lisinopril 10 mg daily, levothyroxine 100 micrograms daily, diclofenac 75 mg daily, and acetaminophen 500 mg, twice a day. On physical exam, her **sclera are icteric**, abdomen is soft with mild right upper quadrant tenderness, no hepatosplenomegaly, masses, or ascites. Labs reveal:
  - **AST 350 U/L , ALT 480 U/L**
  - **Total bilirubin 45 mmol/L**, Alkaline phosphatase 180 U/L (normal: 36-92 U/L)
  - **ANA 1:640 (positive: titer of  $\geq 1:160$ ), ASMA -ve & IgG normal**
  - Hepatitis C antibody negative, Hepatitis B surface antigen negative, Hepatitis A IgM negative
- ▶ **What is the pattern?**
- ▶ **What is the diagnosis?**
- ▶ Drug induced liver injury. **Diclofenac** is the most common NSAID associated with DILI.
- ▶ The most immediate intervention is to stop the diclofenac and monitor the patient for resolution of the injury.
- ▶ Half the cases of **diclofenac hepatotoxicity present with an autoimmune phenotype** characterized by the presence of serum autoantibodies with or without typical histologic features on liver biopsy.
- ▶ **Liver biopsy and abdominal ultrasound** may be indicated and provide important information if stopping diclofenac does not normalize the LFTs. Steroids can also be considered if there is no improvement after discontinuation of the offending drug.

# Case 8

- ▶ A 33-year-old woman with acute liver failure. The patient has no prior history of liver disease and was well until 1 month ago. There is no family history of liver disease. Physical examination reveals jaundice and ascites; Grade 2 encephalopathy is present. Laboratory tests are as follows:
  - **ALT 500 U/L , AST 1,220 U/L , Total bilirubin 50 mmol/l that is mostly direct**
  - Alkaline phosphatase 40 U/L
  - **INR 1.7**
  - **Hb 9 with evidence of hemolysis but Coombs test negative**
  - Ceruloplasmin 24 mg/dL (normal: 20-40 mg/dL)
  - Ferritin 1,200 ng/mL (normal: 15-200 ng/mL)
- ▶ **What is the pattern?**
- ▶ **What is the diagnosis?**
- ▶ This is a classic presentation for acute fulminant Wilson disease. The constellation of a Coombs-negative hemolytic anemia, acute liver failure and the age of the patient all point to this diagnosis.
- ▶ A **positive slit lamp exam** would confirm the diagnosis of Wilson disease, however, if negative does not rule out the disease.
- ▶ **The ceruloplasmin is falsely elevated into the low normal range due to an acute phase response.**
- ▶ The **serum iron studies** are increased because of release of iron from the liver.
- ▶ Liver biopsy may demonstrate increased copper concentration because of the relatively high serum bilirubin level.

# Case 9

- ▶ A 53-year-old woman underwent hysterectomy and oophorectomy for stage 2 ovarian cancer which was complicated by a colonic perforation with intra-abdominal infection and abscess requiring drainage and broad-spectrum antibiotics. She was treated initially piperacillin-tazobactam and vancomycin for 2 weeks and then amoxicillin clavulante for an additional 2 weeks. She was discharged home following completion of the antibiotics and is readmitted for mild jaundice and pruritus 1 week later.
- ▶ A recent abdominal/pelvic CT scan shows normal appearing liver without biliary duct dilatation and improved intra-abdominal abscess.

Time	AST (U/L)	ALT (U/L)	ALKP (U/L)	Total bilirubin (mg/dl)
28 days	30	40	119	0.9
14 days	40	50	199	0.8
7 days	55	65	243	1.9
3 days	68	74	398	3.3
Today	70	83	488	3.9

# Case 9

- **What is the pattern?** Cholestatic with direct hyperbili.
- **What is the likely Diagnosis?**
- Amoxicillin/clavulanate may be associated with **hepatotoxicity, typically with a cholestatic** (ALP predominant increase in liver enzymes). A mixed hepatocellular and cholestatic pattern of liver injury may also be observed.
- The onset of drug-induced liver injury from amoxicillin/clavulanate may be **as little as a few days to as long as 8 weeks post-exposure.**
- Treatment for antibiotic associated drug-induced liver injury is withdrawal of the drug and supportive care.



# Case 10

- ▶ A 58 year-old overweight Hispanic man with diabetes has been referred to you for evaluation of persistently mildly elevated liver enzymes with his **ALT/AST ranging between 60 and 140 over the last year**. As part of the evaluation, you are able to rule out viral, autoimmune, and metabolic liver diseases. He drinks alcohol occasionally. He is not on medications. US showed evidence of fatty liver. Normal liver function tests & CBC
- ▶ **What is the likely Dx ?**
- ▶ NASH or ASH
- ▶ **What is the next step?**
- ▶ Fibroscan
- ▶ Liver biopsy reveals moderate steatosis, hepatocellular ballooning, Mallory bodies, and both lobular and portal-septal inflammation, consistent with steatohepatitis.

# Case 11

- ▶ You are asked to see a 14-year-old boy who suddenly developed itching and jaundice. He started taking minocycline for acne about 6 weeks ago. This is now stopped. Laboratory studies demonstrate
  - AST 13 , ALT 15 ,
  - **Alkaline phosphatase 620 ,**
  - **Total bilirubin 90 mmol/l**
  - Serum albumin and INR are normal.
- ▶ **What is the pattern?** Cholestatic with direct hyperbili.
- ▶ **What is the next step?**
- ▶ US: The liver and biliary tree appeared normal on ultrasound.
- ▶ **What should you tell the parents about their child?**
- ▶ Pure cholestatic drug reactions almost always resolve within 6 weeks of stopping the medication. We just need to monitor.

# CASE 12

- ▶ You are asked to see a 45-year-old woman who developed elevations in liver transaminases after initiating a statin. Over the past 3 months,
  - AST has been 65 U/L, 75 U/L, and 85 U/L (normal: 0-35 U/L).
  - ALT has been 86 U/L, 88 U/L, and 95 U/L (normal: 0-35 U/L).
  - Alkaline phosphatase and total bilirubin were normal.
  - The primary care physician was concerned that the liver transaminases were rising and so he stopped the statin.
  - The AST is now 45 U/L and ALT 50 U/L.
- ▶ **What is would you recommend?**
- ▶ **Adaptation phenomena vs True hepatotoxicity**
- ▶ **Adaptation phenomena** : In these patients the liver transaminases elevate to values **under 3 times the ULN** and then remain stable for variable periods of time before declining back to the normal range. This process is referred to as adaptation and **is commonly seen with many medications**.
- ▶ **True hepatotoxicity** is associated with progressive stepwise elevations in liver transaminases to values greater than 3 times the upper limit of normal. When this occurs, the risk of liver toxicity is significant, medications must be stopped and not restarted.
- ▶ Although statins can cause hepatotoxicity **this is relatively uncommon**. However, it is not unusual for statins to cause mild elevations in liver transaminases when first initiated.
- ▶ In this patient, the **mild fluctuations in AST and ALT are not significant stepwise elevations**.