



# Localization in Neurology

Salman Aljarallah

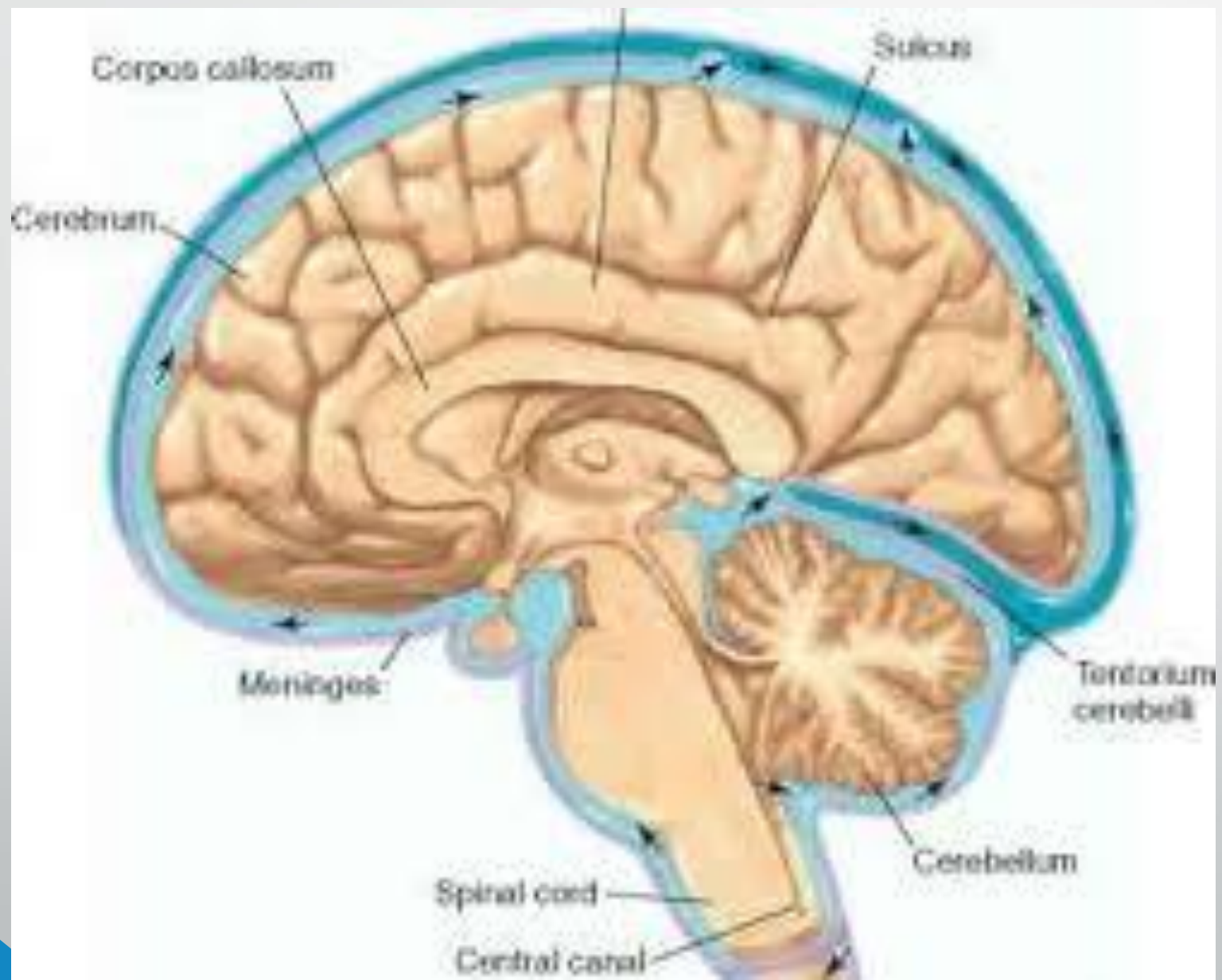
Slides modified from Dr. Hana Albulaihe

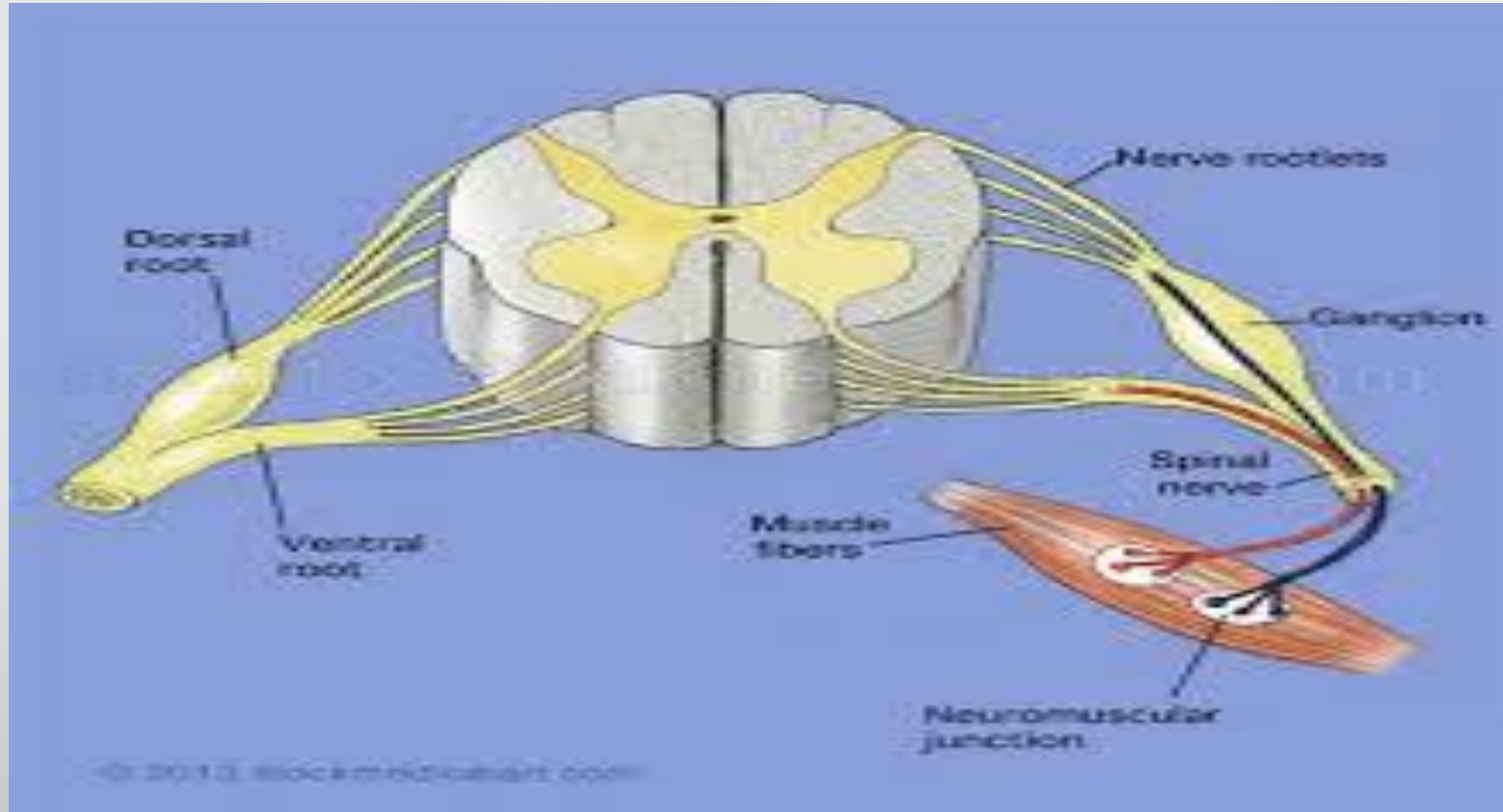
# Objectives

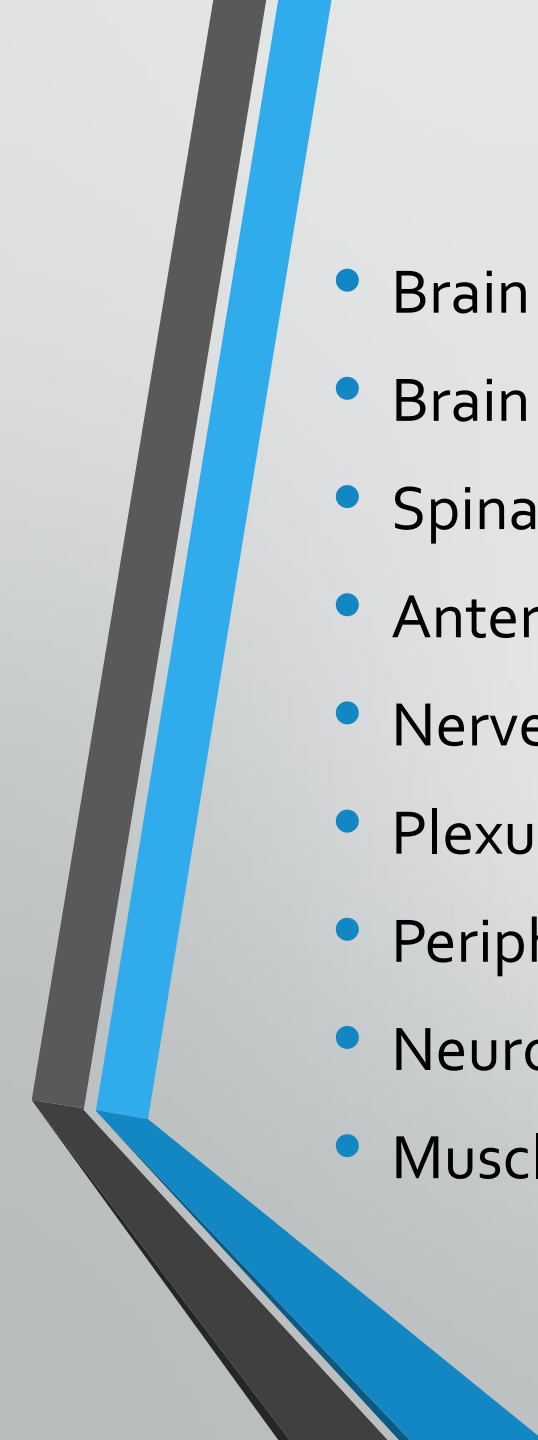
- Neuroaxis structures.
- Central vs. peripheral nervous system.
- UMN & LMN signs.
- Functions of the brain lobes.
- Brain stem and spinal cord anatomy and functions.
- Cases.

# Case 1

- A 72-year-old woman with a history of diabetes and hypertension suddenly awakens with deviation of her mouth angle to the left, weakness of the right arm and leg. On examination, she has upper motor neuron weakness of the right face, arm and leg associated with brisk reflexes on the right and a right extensor plantar response.





- 
- Brain
  - Brain stem.
  - Spinal cord.
  - Anterior horn cells.
  - Nerve root.
  - Plexus.
  - Peripheral nerve.
  - Neuromuscular junction.
  - Muscle.

## UPPER MOTOR NEURON SIGNS

- Indicate that the lesion is above the anterior horn cell (spinal cord, brain stem, brain).
- increased muscle tone (spasticity).
- weakness (flexors weaker than extensors in the legs and the reverse in the arms - pyramidal pattern of weakness).
- increased reflexes.
- up-going plantar response.
- sustained clonus.

## LOWER MOTOR NEURON SIGNS

- Indicate that the lesion is distal to the anterior horn cell (root, plexus, peripheral nerve, NMJ, muscle).
- decreased muscle tone.
- weakness and wasting.
- areflexia.





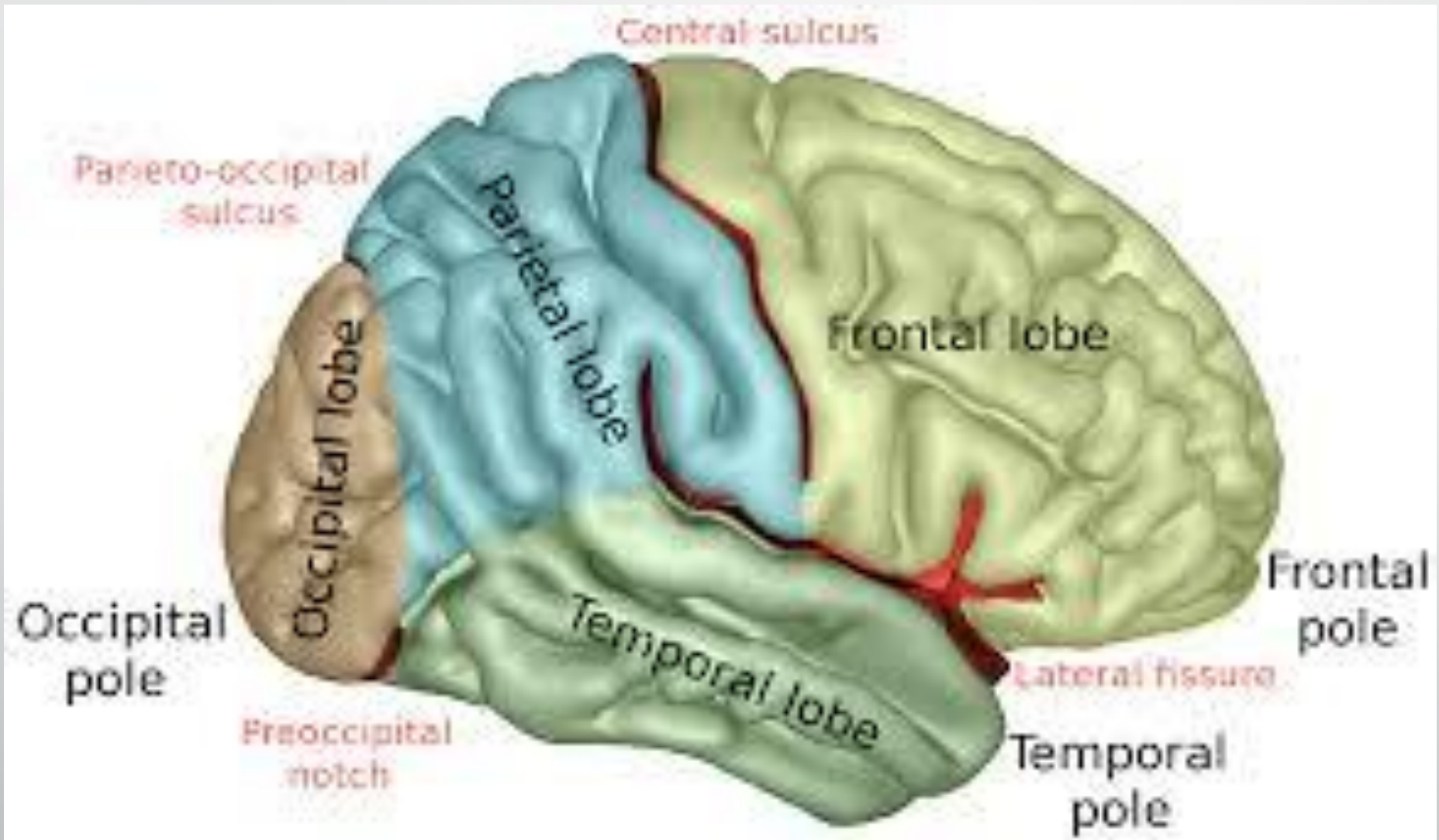
## Brain :

Frontal lobe.

Temporal lobe.

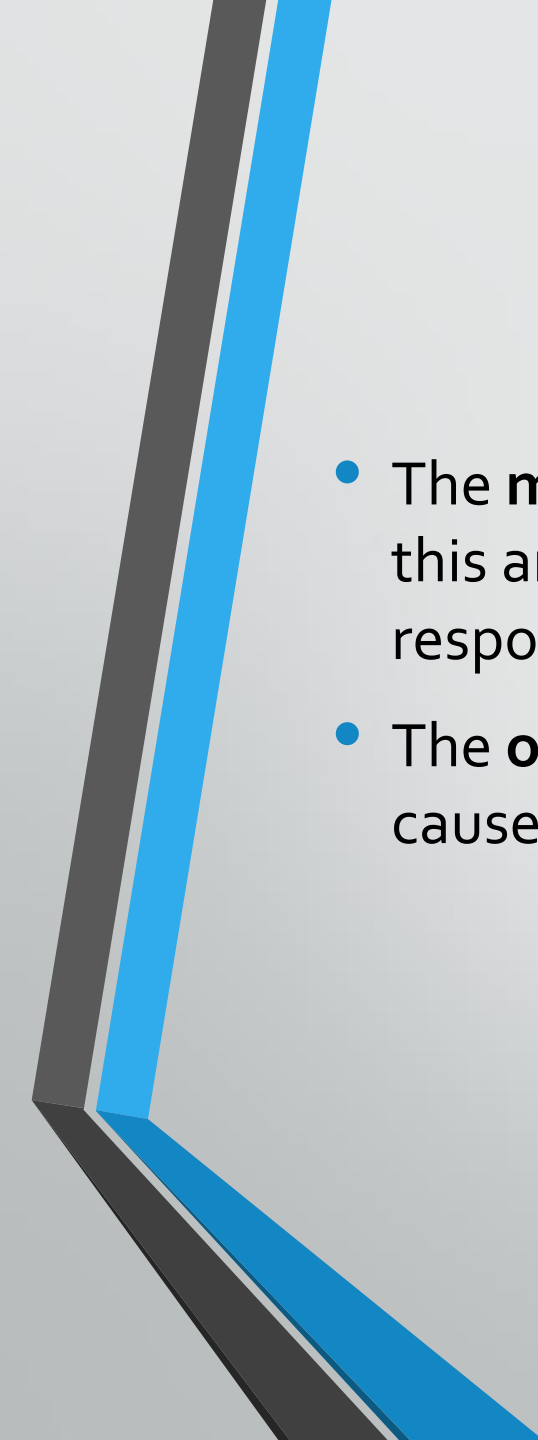
Parietal lobe.

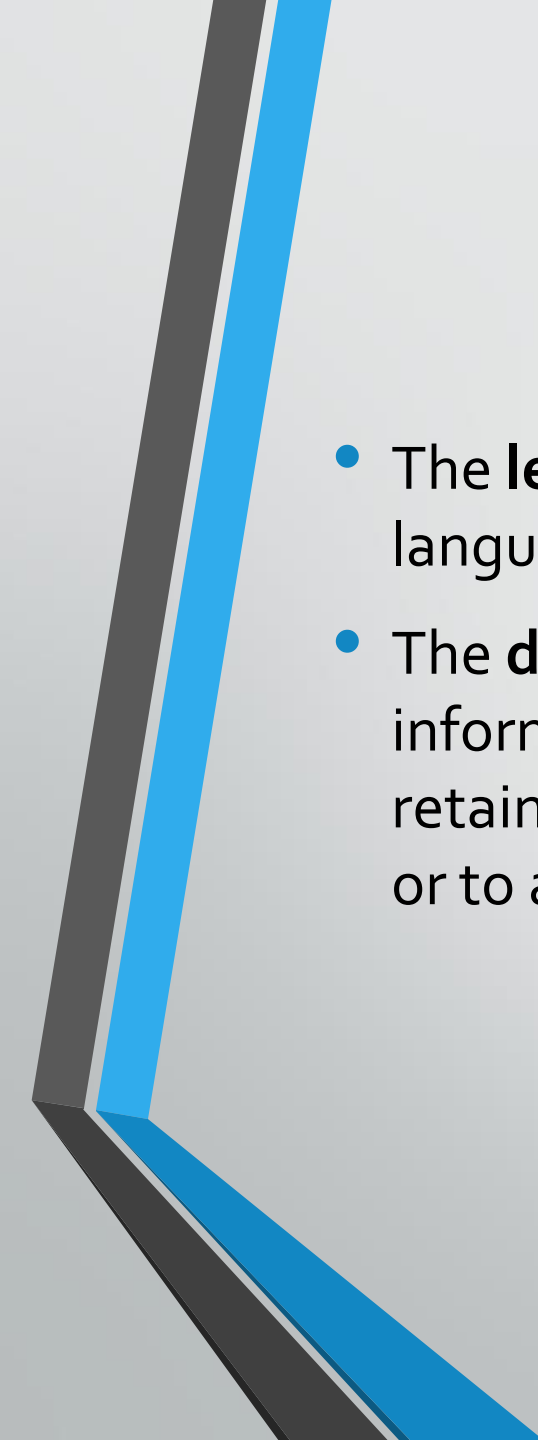
Occipital lobe.



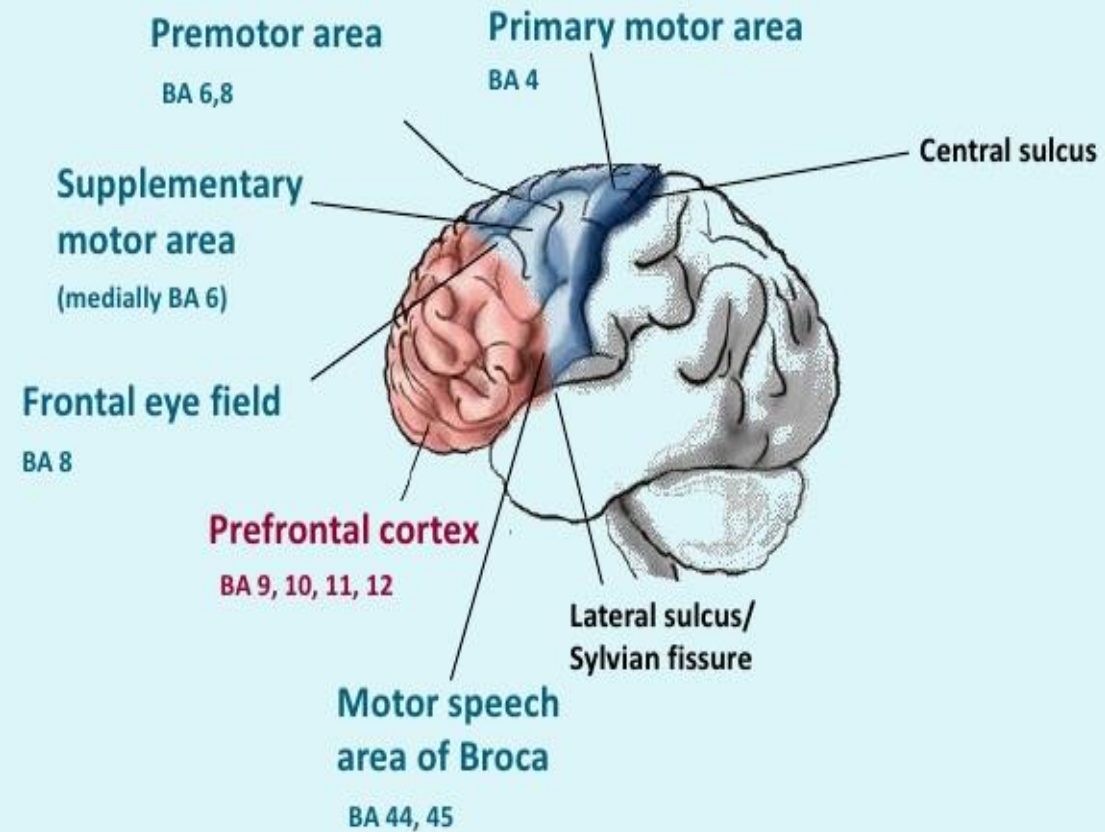
# Frontal lobe

- Essential for planning and executing learned and purposeful behaviors.
- Primary motor cortex controls all motor functions on the contralateral side of the body .
- 90 % of motor fibers from each hemisphere cross the midline in the lower medulla.

- 
- The **medial frontal cortex** is important in arousal and motivation. lesions in this area the patients become apathetic, inattentive, and markedly slow to respond. [L] [SEP]
  - The **orbital frontal cortex** modulates social behavior. lesions in this area cause emotional lability and disinhibition.

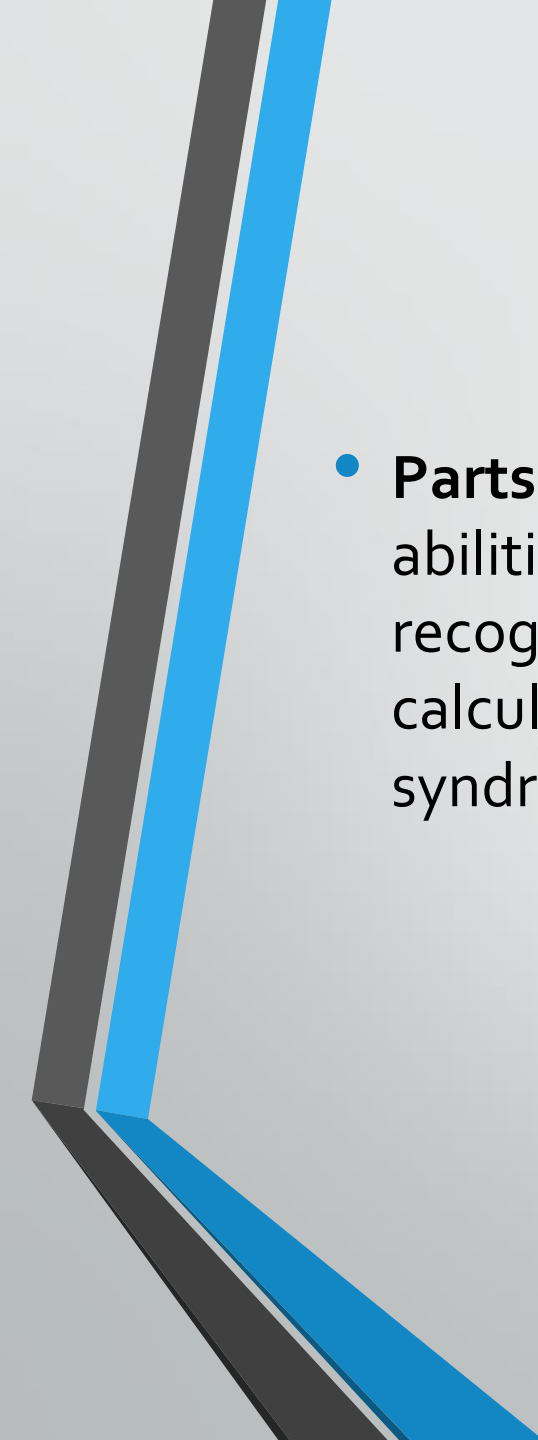
- 
- The **left posteroinferior frontal cortex** ( Broca area) controls expressive language function. Lesions in this area cause expressive aphasia.
  - The **dorsolateral frontal cortex** manipulates very recently acquired information ( working memory). Lesions in this area can impair the ability to retain information and process it in real time (eg, to spell words backwards or to alternate between letters and numbers).

# Functional Frontal Lobe Anatomy

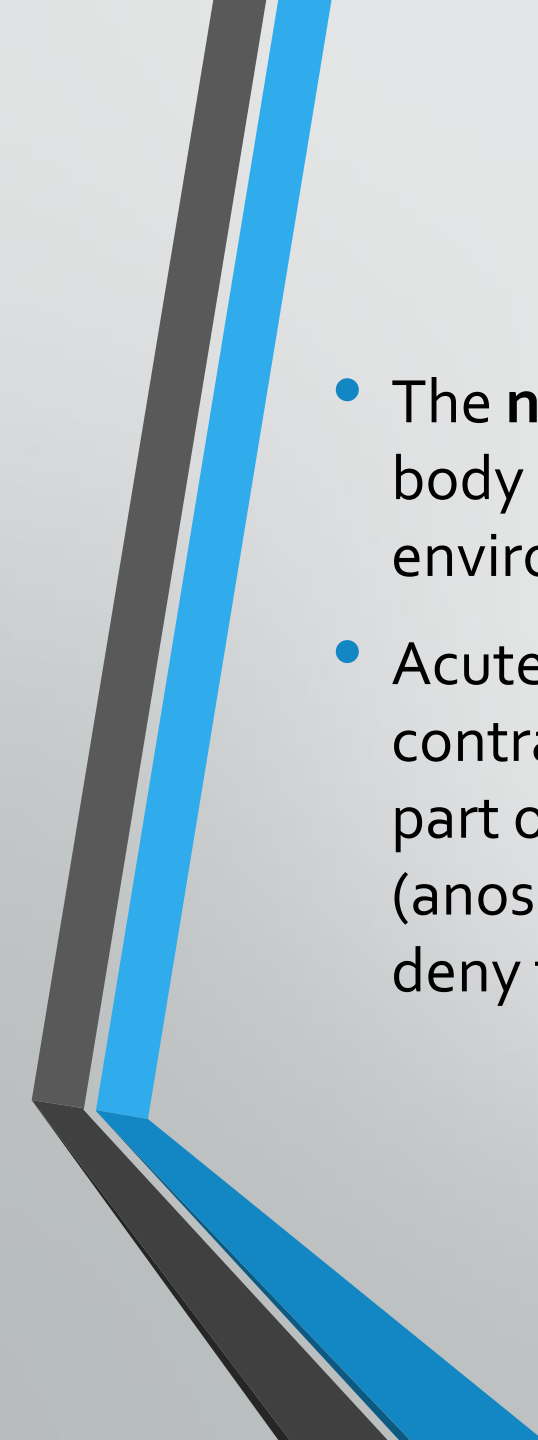


# Parietal lobe

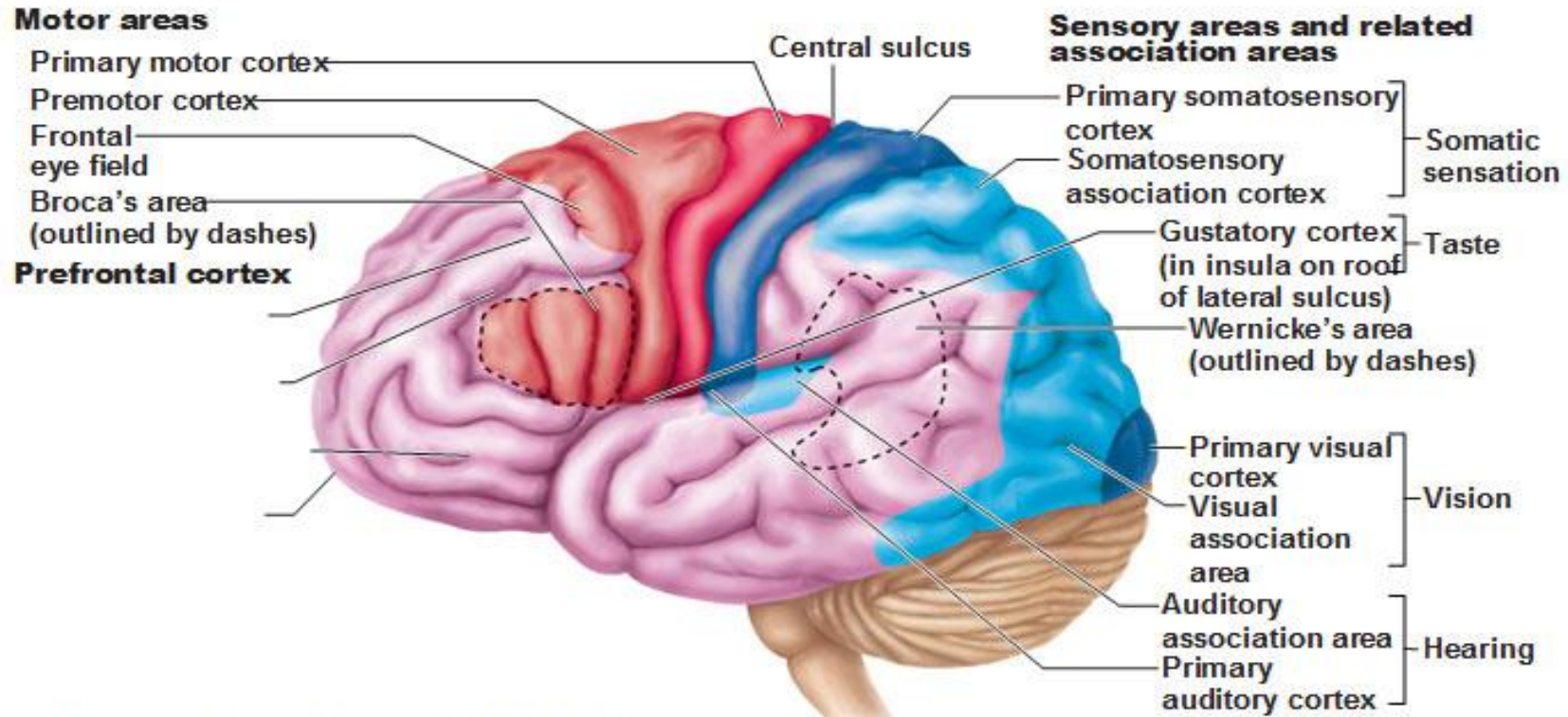
- The **primary somatosensory cortex** integrates sensory stimuli for recognition and recall of form, texture, and weight. The primary somatosensory cortex on one side receives all somatosensory input from the contralateral side of the body. Lesions in this area result in inability to recognize objects by touch (astereognosis).
- **Areas posterolateral to the postcentral gyrus** generate visual-spatial relationships and awareness of moving objects. [SEP]

- 
- **Parts of the parietal lobe of the dominant hemisphere** are involved in abilities such as calculation, writing, left-right orientation, and finger recognition. Lesions in the angular gyrus can cause deficits in writing, calculating, left-right disorientation, and finger-naming (Gerstmann syndrome).<sup>[L]  
[SEP]</sup>



- 
- The **nondominant parietal lobe** integrates the contralateral side of the body with its environment, enabling people to be aware of this environmental space.
  - Acute injury to the nondominant parietal lobe may cause neglect of the contralateral side (usually the left), resulting in decreased awareness of that part of the body, its environment, and any associated injury to that side (anosognosia). For example, patients with large right parietal lesions may deny the existence of left-sided paralysis.

# Functional Areas of the Cerebral Cortex



(a) Lateral view, left cerebral hemisphere


- |   |   |
|---|---|
| <span style="color: red;">■</span> Primary motor cortex           | <span style="color: orange;">■</span> Motor association cortex      |
| <span style="color: blue;">■</span> Primary sensory cortex        | <span style="color: lightblue;">■</span> Sensory association cortex |
| <span style="color: pink;">■</span> Multimodal association cortex |   |

# Temporal lobe

- The temporal lobes are integral to auditory perception, receptive components of language, memory and emotion.
- Lesions in the posterior third of the sup. Temporal gyrus result in wernicke aphasia.

# Occipital lobes

- The primary visual cortex<sup>[L]</sup><sub>[SEP]</sub>
- Visual association areas

- 
- Sub cortical areas.
  - Internal capsule.
  - Thalamus.

# Brain stem

- Lesions of the brain stem can result to abnormalities in the function of cranial nerves which may lead to visual disturbances, pupil abnormalities, changes in sensation, weakness, hearing problems, vertigo, swallowing and speech difficulty, voice change, and coordination problems.
- Crossed signs.

- **Cerebellum:**

**Hemispheric:**

Nystagmus.

Dysarthria with "scanning" speech.

Ipsilateral UE dysmetria.

Dysdiadochokinesia.

Ataxia.

Intention tremor.

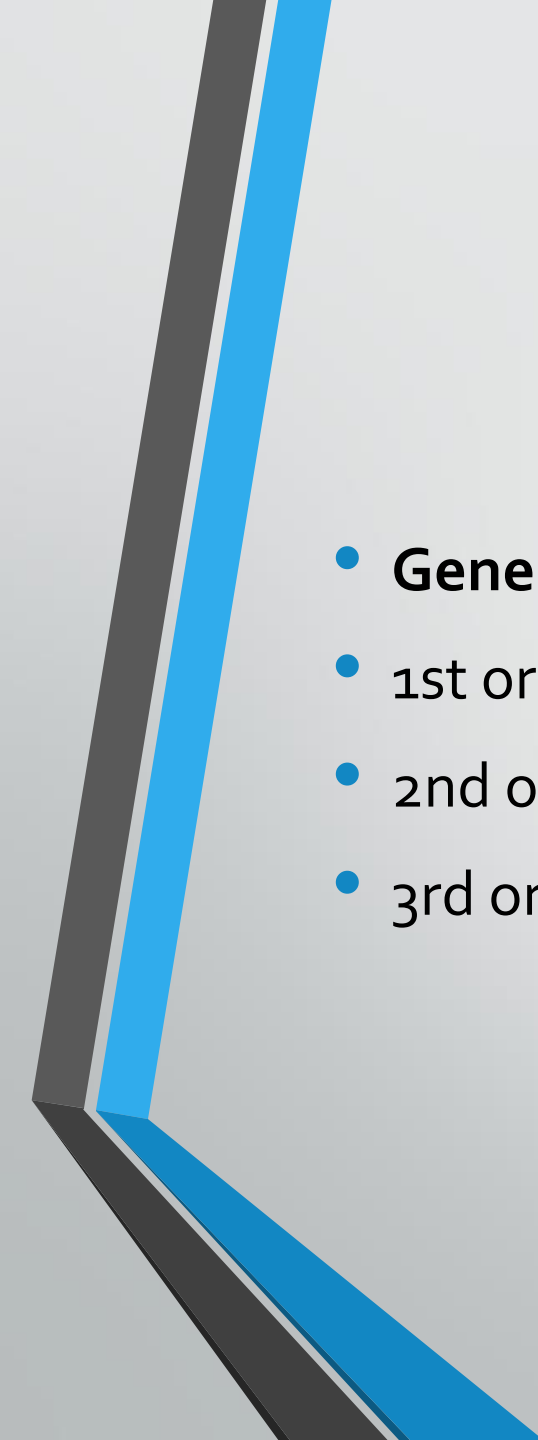
Impaired heel-to-shin test.


**Vermis** lesions cause truncal ataxia and unsteadiness.

# Spinal cord

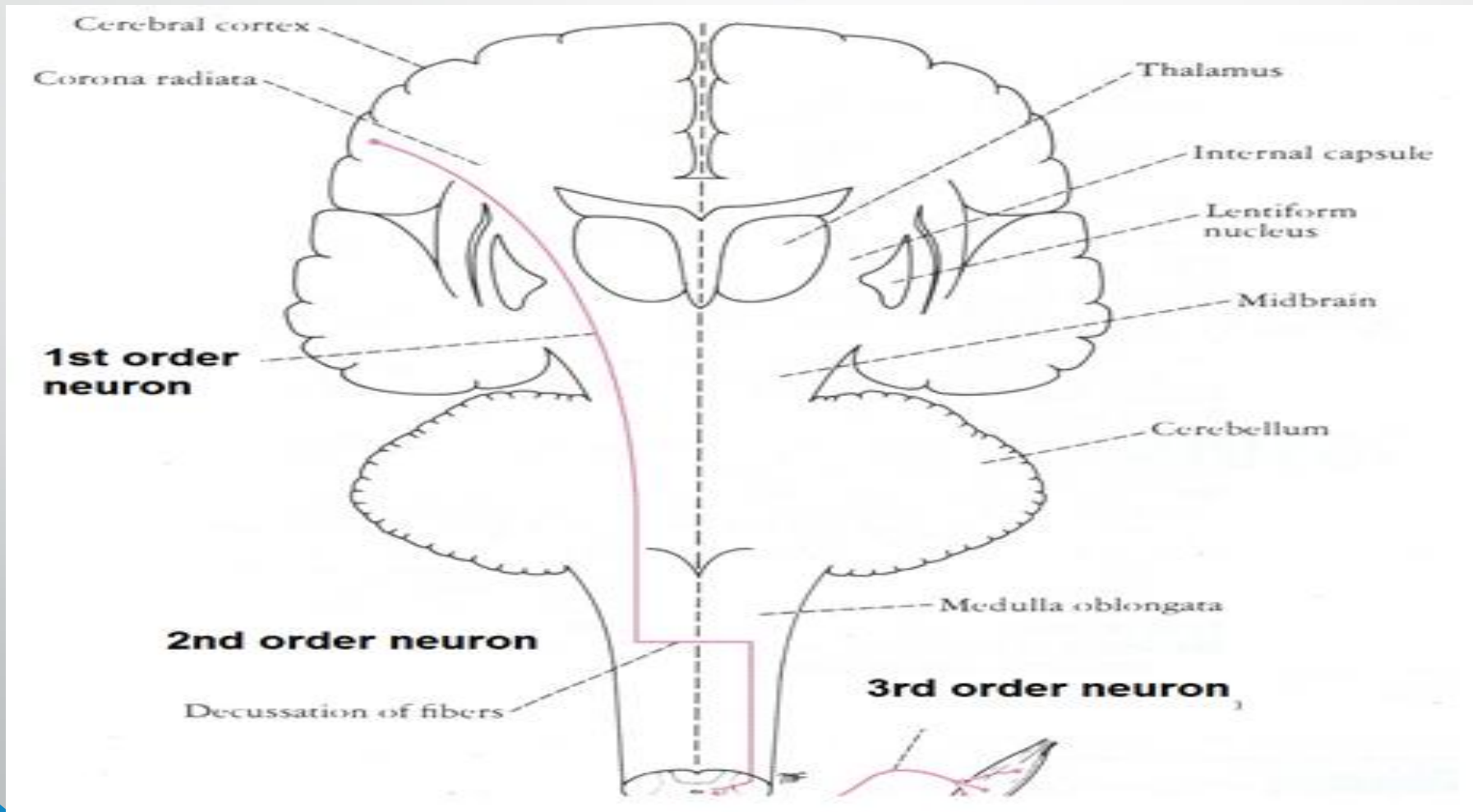
- Contains ascending and descending tracts.
- Ascending tracts are sensory.
- Descending tracts are motor.

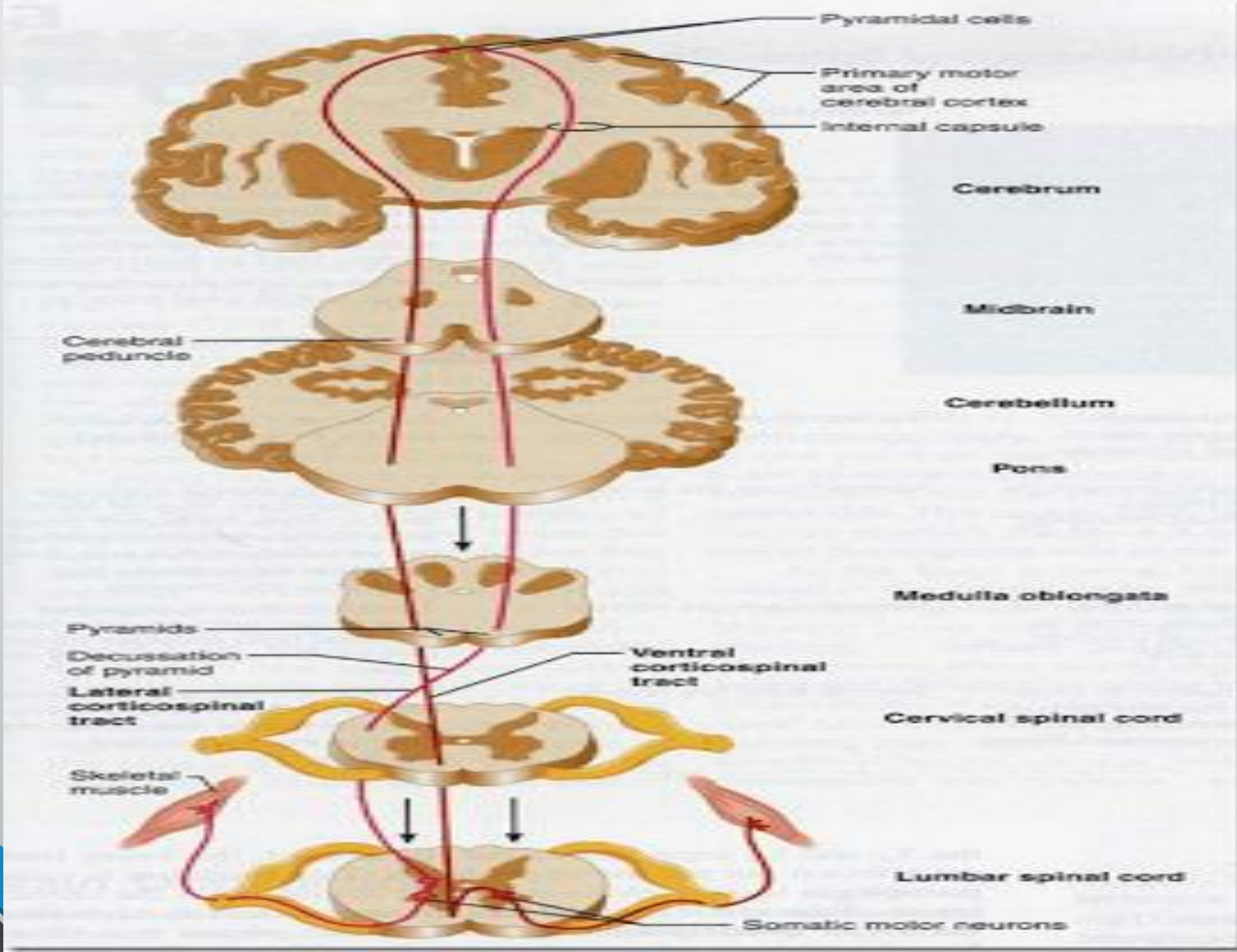


- 
- **General arrangement of both tracts**
  - 1st order neuron
  - 2nd order neuron
  - 3rd order neuron

- 
- Decussation is the cross-over of the tract from one side to the other.
  - Decussation occurs at different locations for each tracts.

# Descending tracts (Motor)





**SUPERO  
LATERA**



Neck  
Brow  
Eye  
Face  
Lips  
Jaw  
Tongue  
Swallowing

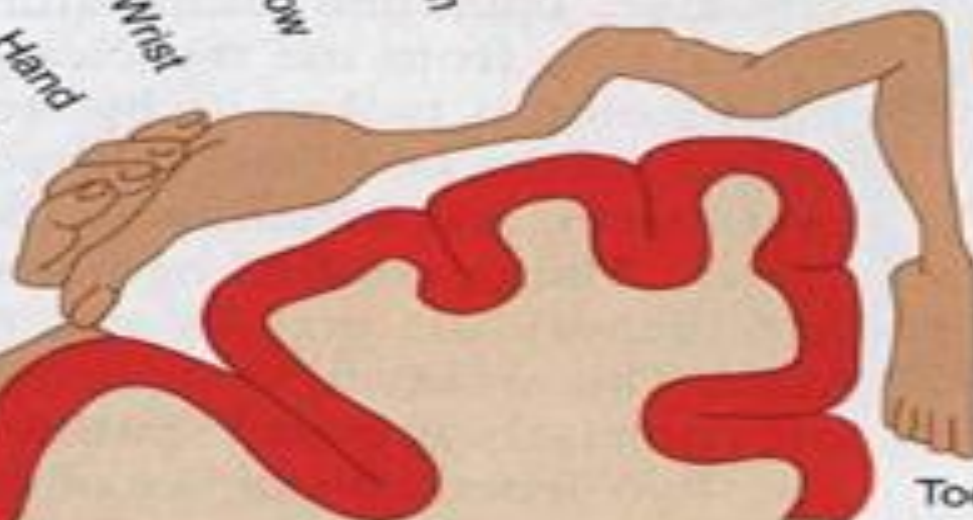

Thumb  
Fingers  
Hand



Wrist  
Elbow

Arm  
Shoulder



Trunk  
Hip  
Knee



Toe

**MEDIAL**

**Motor cortex  
(precentral gyrus)**





# Ascending tracts (sensory)

- **Types of ascending tracts:**

- Spinothalamic tracts

- Lateral

- pain & temperature

- Anterior

- light touch & pressure

- Dorsal column tract

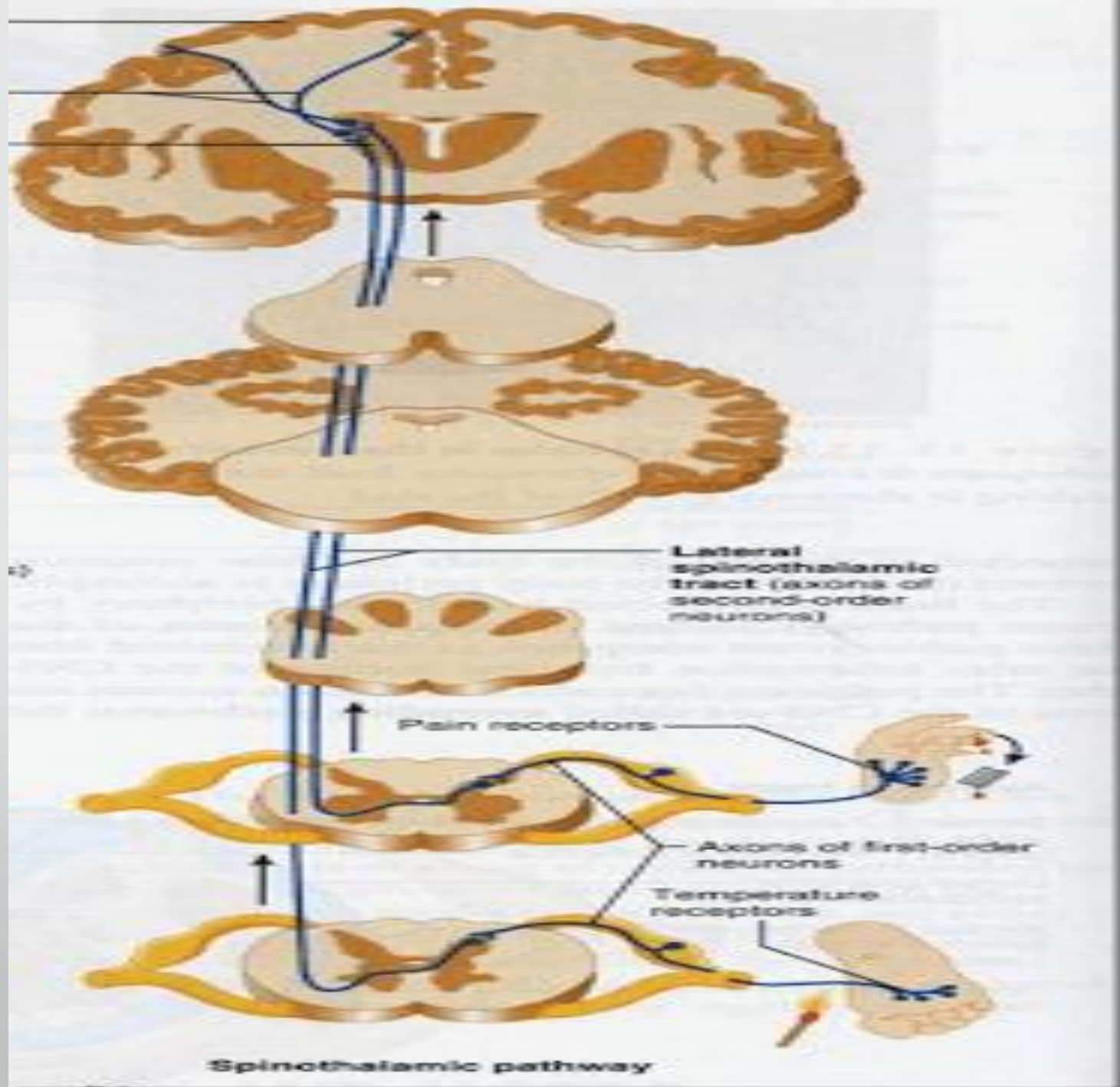
- deep touch & pressure

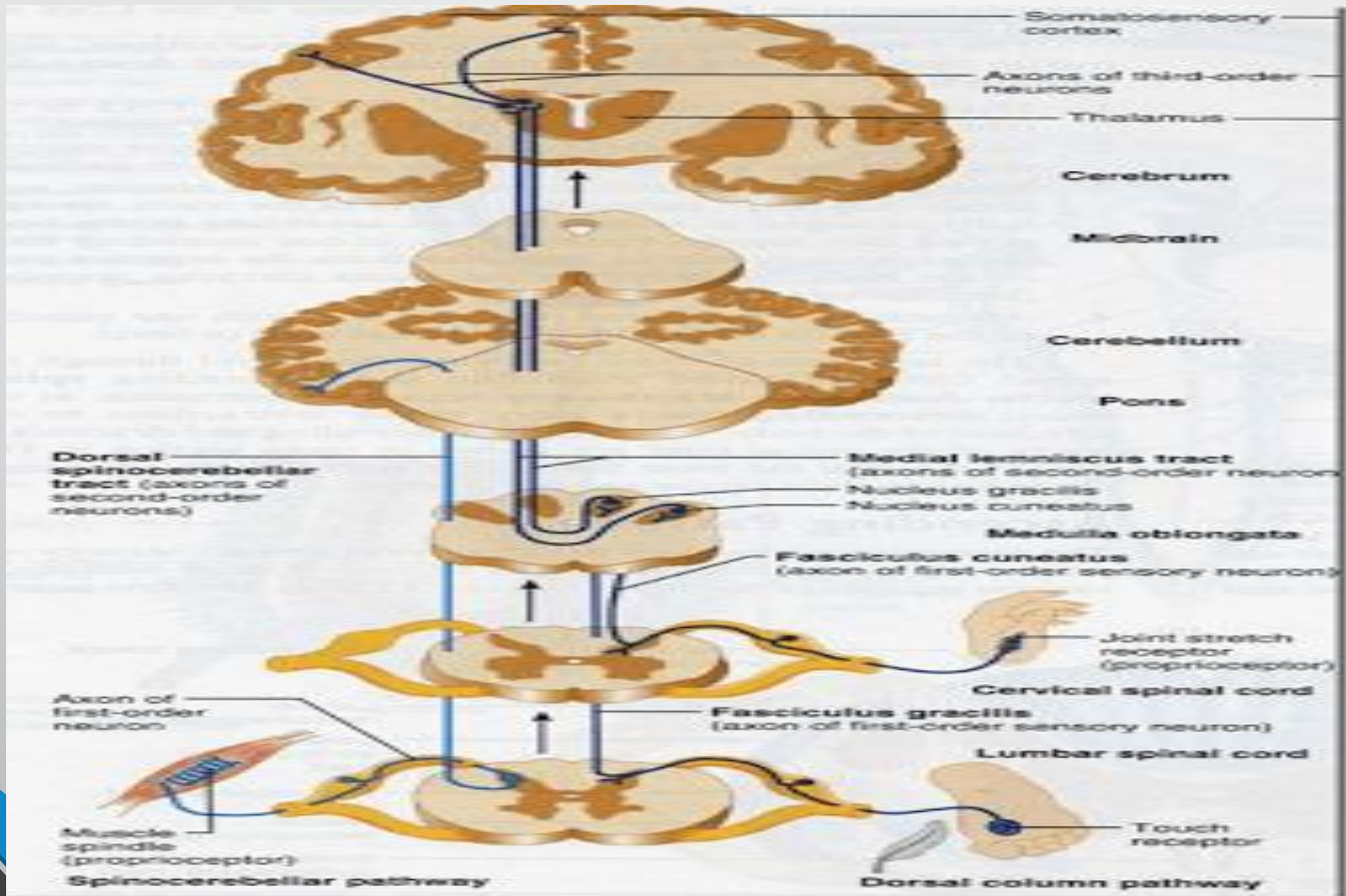
- proprioception

- vibration sensation

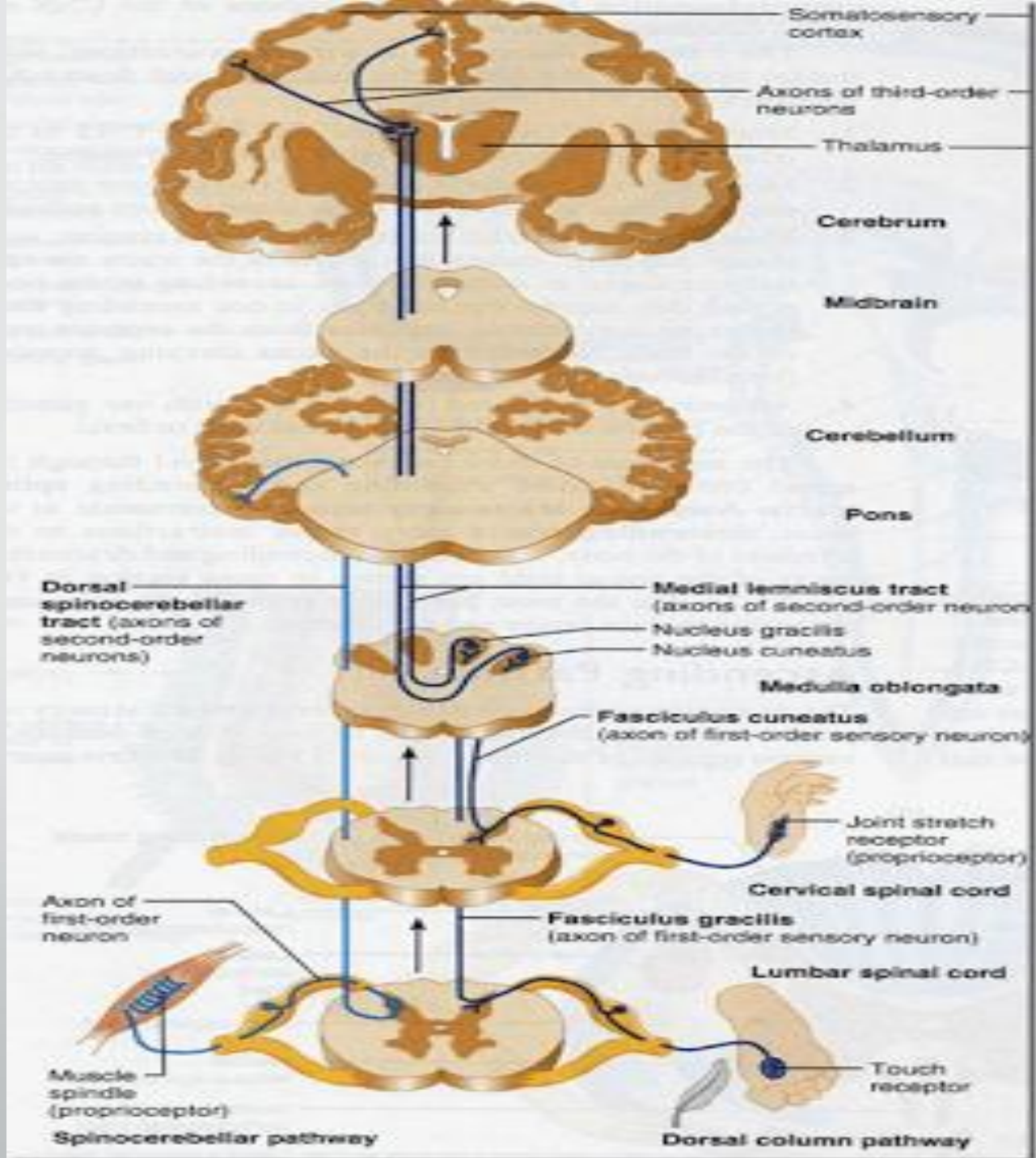
- Spinocerebellar tract

posture & coordination











## Spinal Cord:

### **Complete transection:**

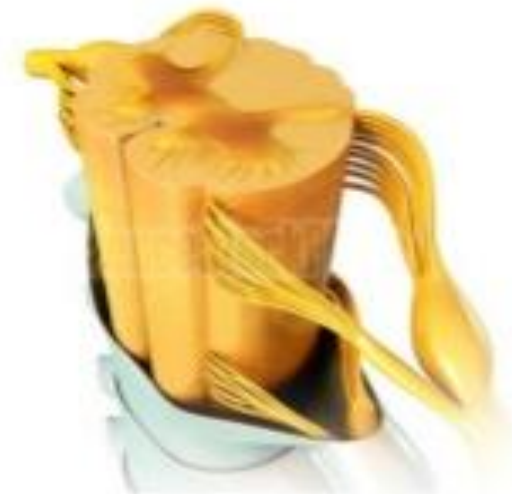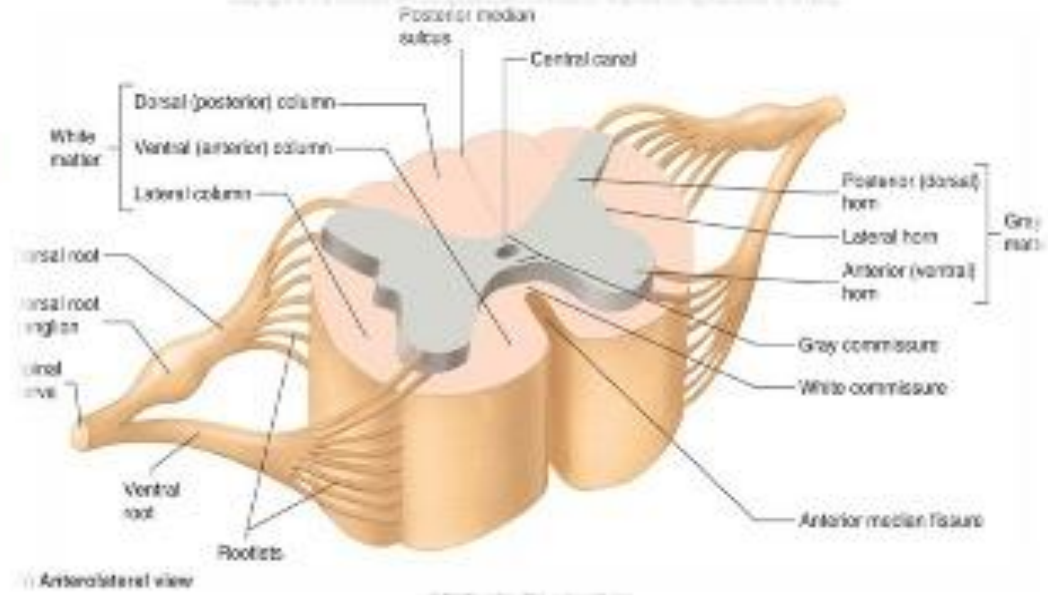
- sensory level.
- upper motor lower limbs weakness.
- spinal tenderness.
- bowel/bladder dysfunction.

## **Hemisection of the spinal cord:**

- Ipsilateral upper motor neuron weakness.
- Ipsilateral loss of vibration and proprioception.
- Contralateral loss of pain and temperature.

# Cross Section of Spinal Cord

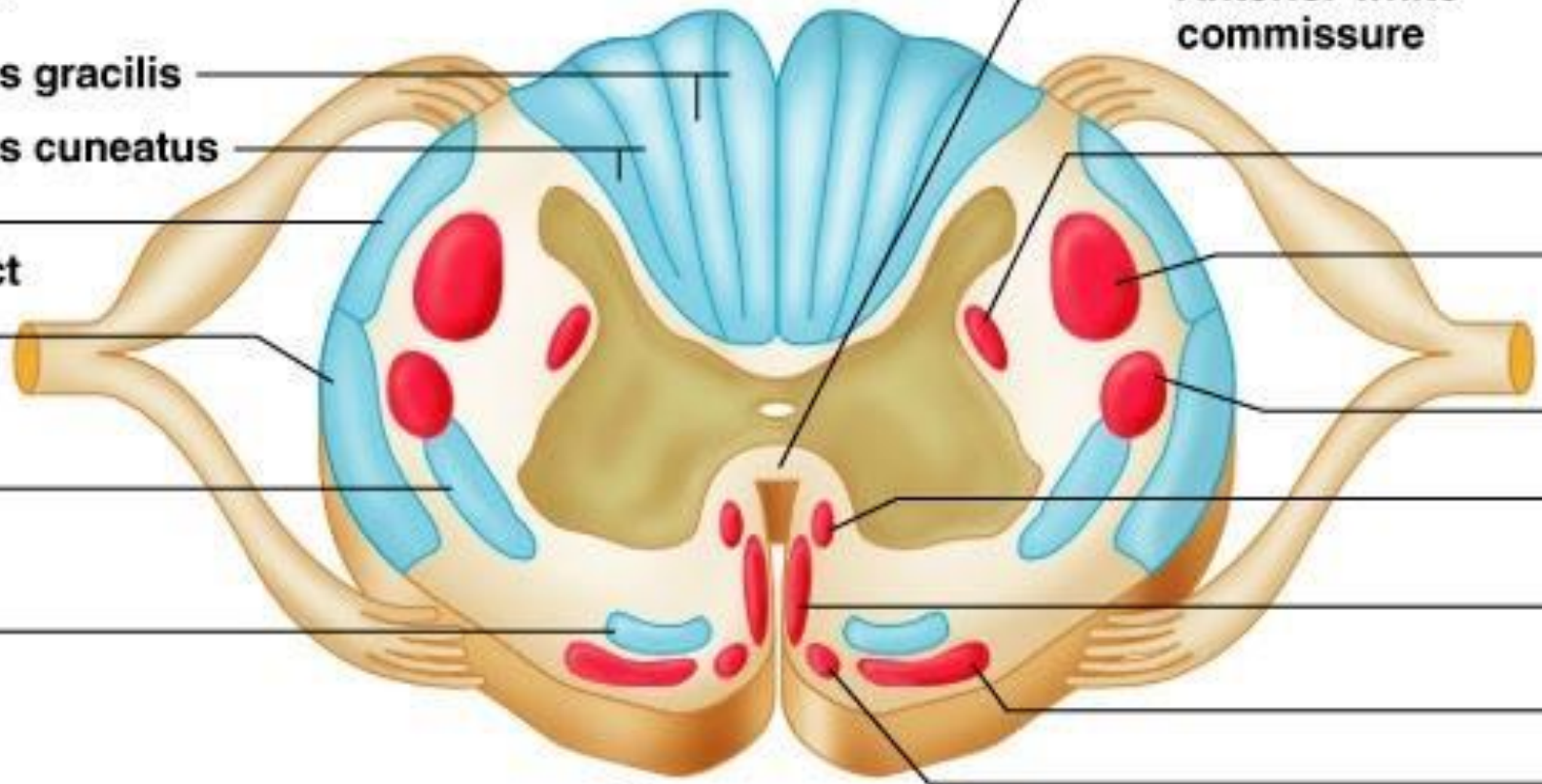
- ❖ The spinal cord is incompletely divided into two equal parts, anteriorly by a short, shallow **median fissure** and posteriorly by a deep narrow septum, the **posterior median sulcus**.
- ❖ Composed of **grey matter** in the center surrounded by **white matter** supported by neuroglia.
- ❖ **Commissures:** connections between left and right halves
  - Gray with central canal in the center
  - White
- ❖ **Roots:** spinal nerves arise as rootlets then combine to form roots
  - Dorsal (posterior) root has a ganglion
  - Ventral (anterior)
  - Two roots merge laterally and form the spinal nerve





**Ascending tracts**

- Dorsal white column
  - Fasciculus gracilis
  - Fasciculus cuneatus
- Posterior spinocerebellar tract
- Anterior spinocerebellar tract
- Lateral spinothalamic tract
- Anterior spinothalamic tract



**Anterior white commissure**

**Descending tracts**

- Lateral reticulospinal tract
- Lateral corticospinal tract
- Rubrospinal tract
- Medial reticulospinal tract
- Anterior corticospinal tract
- Vestibulospinal tract
- Tectospinal tract

**Key:**  
 ■ Descending tracts  
 ■ Ascending tracts



- **Anterior Horn Cells:**

Weakness.

Fasciculations.

Wasting.

No sensory loss.

## Peripheral nervous system:

- **Root (radiculopathy):**

Pain, focal weakness and wasting, sensory loss along a dermatomal distribution, history of back pain.

- **mononeuropathy:**

findings along a particular nerve distribution

- **Peripheral polyneuropathy:**

Glove and stocking" distribution, pain and paresthesias of toes, fingers, +/- loss of distal DTR'S, +/- loss of vibration and proprioception, +/- weakness

- **polyradiculoneuropathy:**

ascending weakness, +/- sensory loss and pain. Wasting in chronic form.





- **Neuromuscular junction:**

fluctuating weakness, wasting.

- **Myopathy:**

sensory usually not involved, although may have pain. Weakness .

# To localize a lesion:

- **Step 1:**

Is it UMN or LMN?



- Step 2:

If UMN:

1. Brain (including brainstem).
2. Spinal cord.



If LMN:

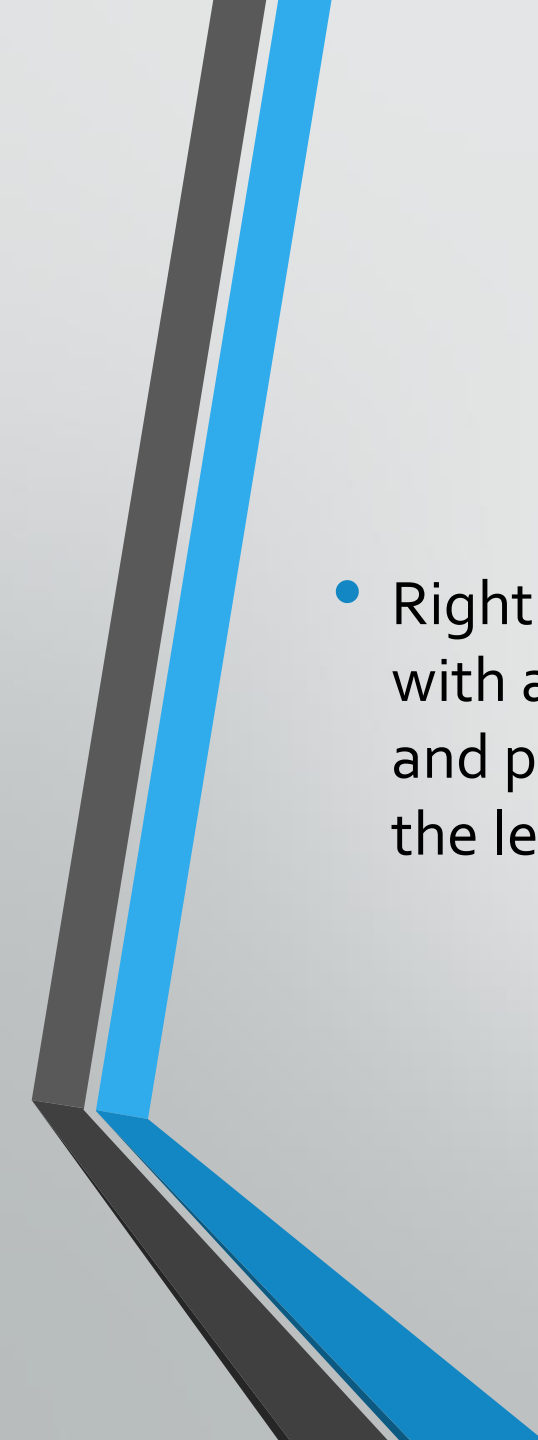
1. Nerve root.
2. Nerve.
3. Neuromuscular Junction (NMJ).
4. Muscle.

## Case 2

- A 35 year-old woman known to have breast cancer with metastasis to the liver presented with progressive weakness of both legs for 3 days. On exam she has bilateral lower extremity hyperreflexia and clonus.

## Case 3

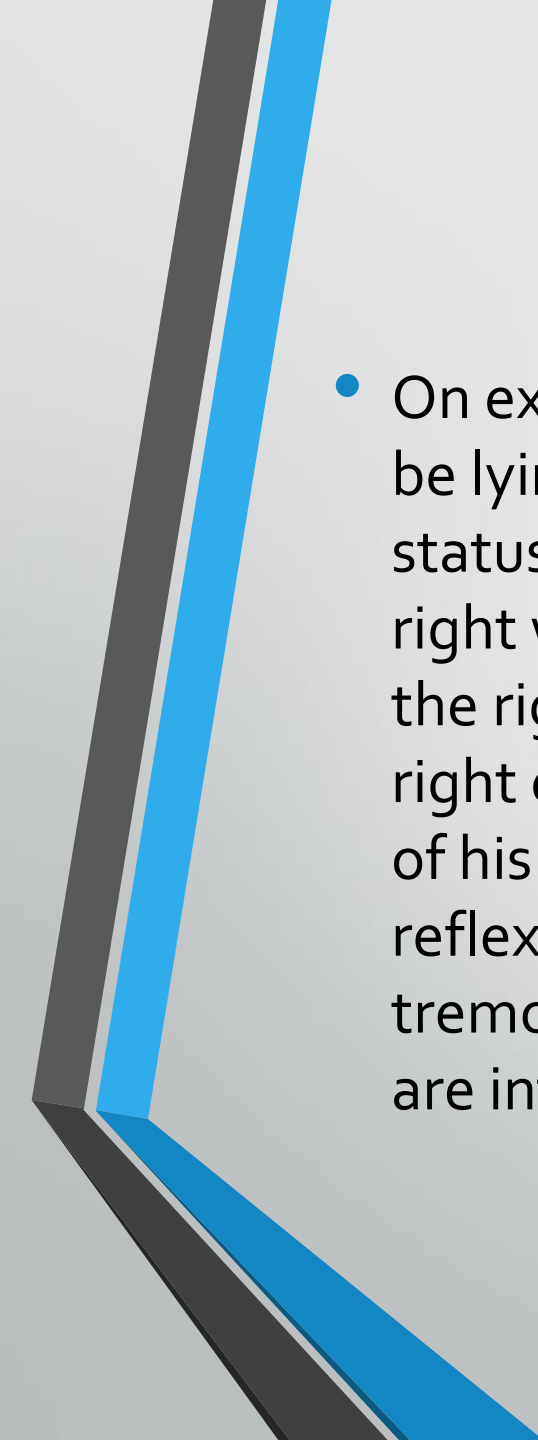
- 26 year old motorcyclist was received by the trauma team in the emergency department after being involved in MVA. Initial neurological examination found him alert and orientated with a Glasgow Coma Score of 15. Full neurological examination demonstrated reduced motor power on the left side. Shoulder abduction and elbow flexion was diminished but movement was absent or reduced to a flicker for elbow extension, wrist flexion and extension, finger extension and flexion, and all muscle groups in the lower limb.

- 
- Right sided motor function was normal. Sensation was abnormal below C6 with absent pinprick sensation on the right side and abnormal light touch and proprioception sensation on the left side. Reflexes were all reduced on the left side.

## Case 4

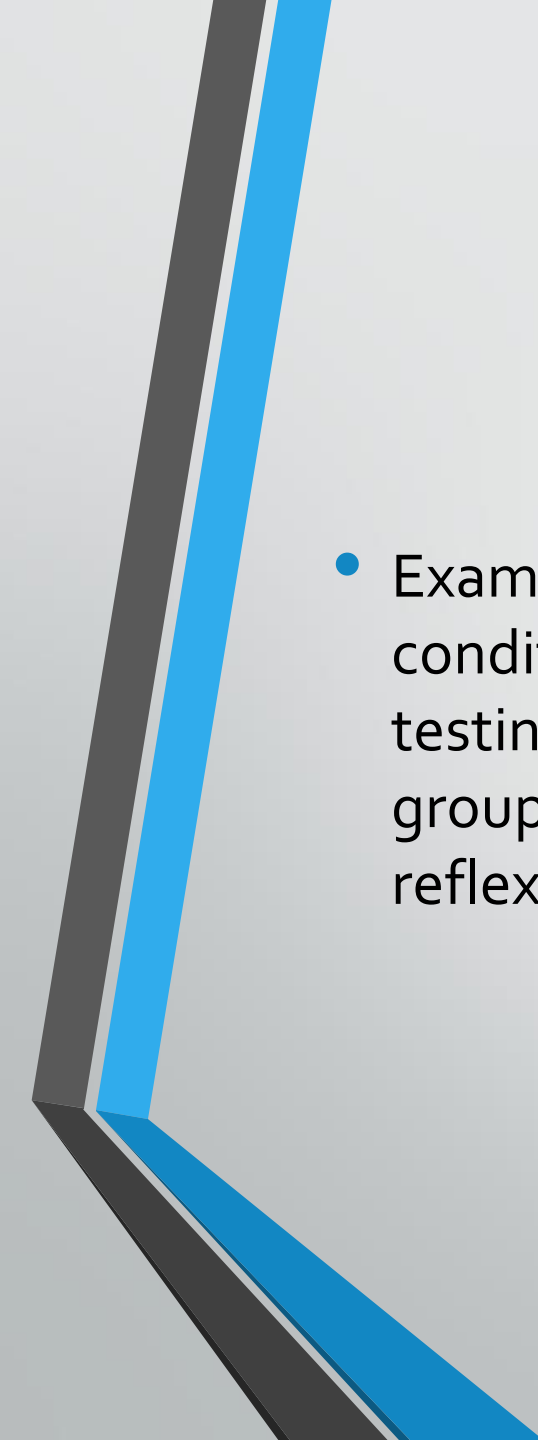
- A 60 year old man with hypertension wakes one morning with trouble walking. He is feeling dizzy. His wife gets him into the car and brings him to the emergency room where you are asked to evaluate him. On the way to the emergency room his wife noted that his face seemed to be drooping on the right.



- 
- On examination you find that the man is quite uncomfortable and prefers to be lying still rather than trying to cooperate with the exam. His mental status is appropriate. His pupillary exam is normal but he cannot look to the right with either the left or the right eye. The corneal reflex is abnormal on the right. Although he feels the cornea being touched he does not close his right eye. His left eye does close to right corneal stimulation. The right side of his face is weak and he has marked loss of right sided hearing. His gag reflex is intact. He is unable to walk and has right upper extremity intention tremor. When you sit him up he falls to the right. His reflexes and strength are intact in all limbs.

## Case 5

- A 37-year-old male presented to a chiropractic office complaining about recent onset of tingling and numbness in both hands. He also complained about his feet which he described as "feeling sleepy." His symptoms began slowly following an upper respiratory tract infection that he had about 14 days prior. No history of trauma was reported nor had he ever complained of the current symptoms.

- 
- Examination of this man revealed a healthy person in other- wise good condition. Generalized weakness of the lower ex tremities was noted when testing the quadriceps, hamstrings and the gastrocnemius-soleus muscle groups. Sensory loss was variable in both his hands and feet. Deep tendon reflexes are not obtainable.



Thank you