

**MEDCOURSE 341
Endocrine Block
February 2018**

Adrenal Disorders

MUHAMMAD MUJAMMAMI, MD, M.Sc, ECNU

Assistant Professor of Medicine.

Consultant in Medicine, Endocrinology, Diabetes & Thyroid & Endocrine Oncology.

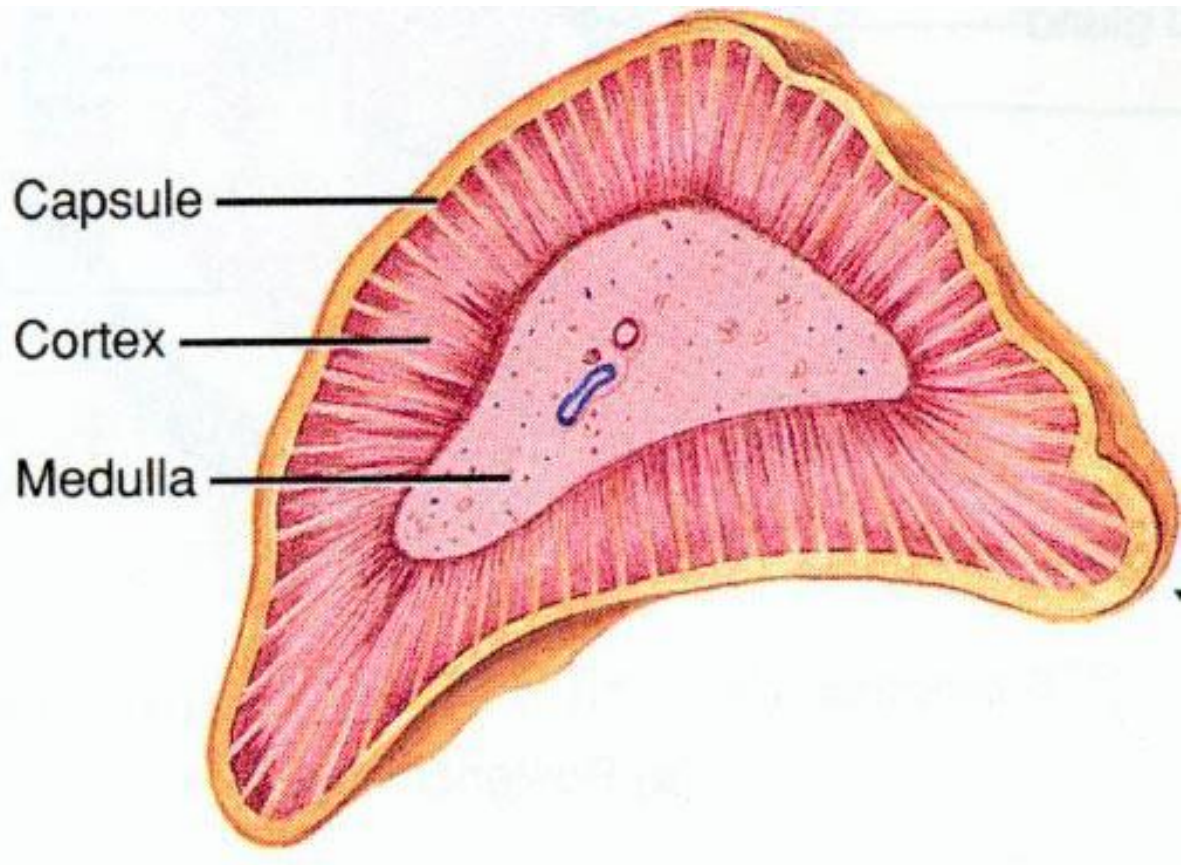
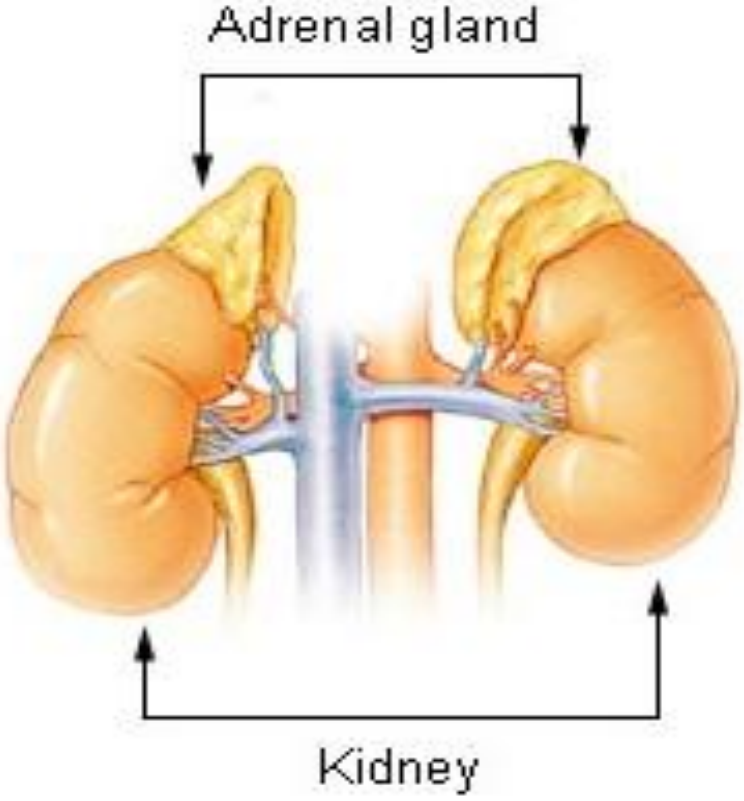
Endocrine & Metabolism Unit, Department of Medicine
King Saud University

Objectives

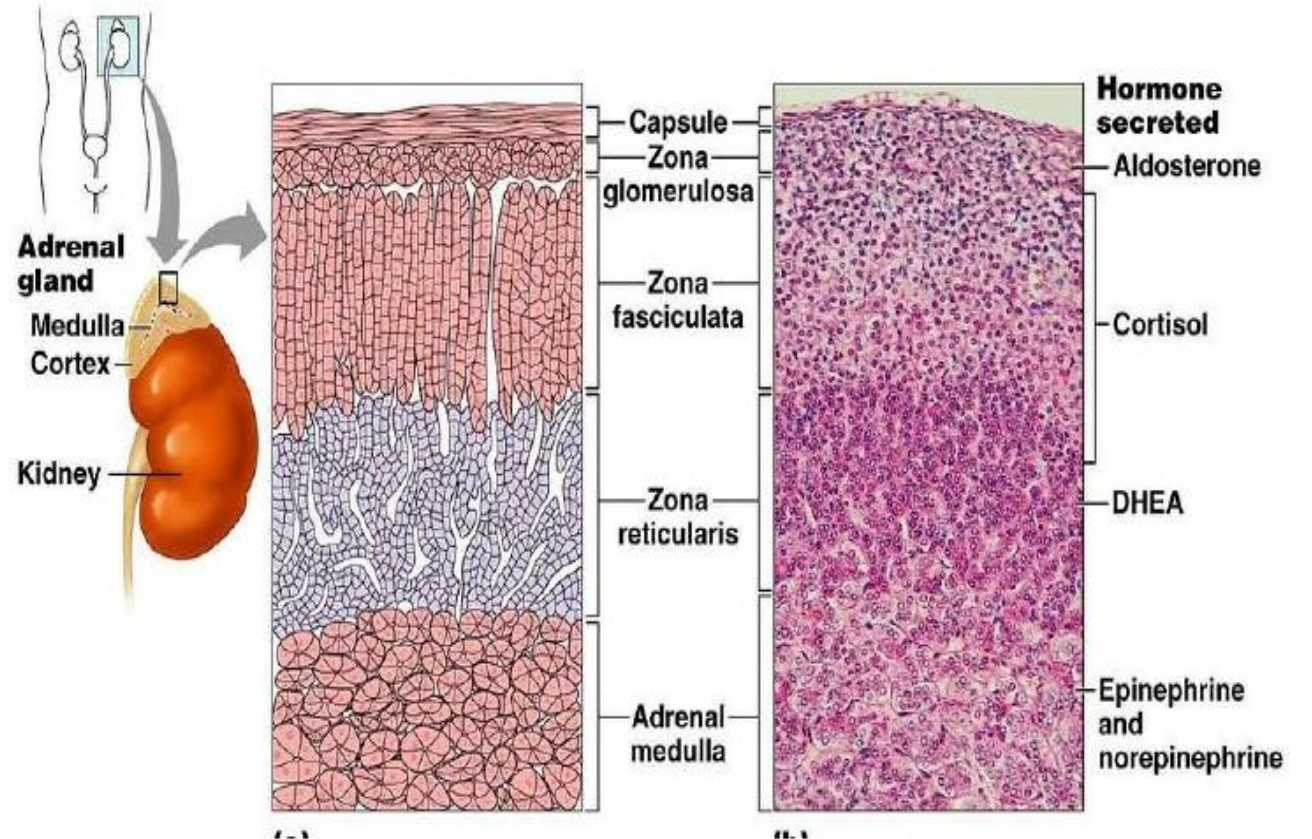
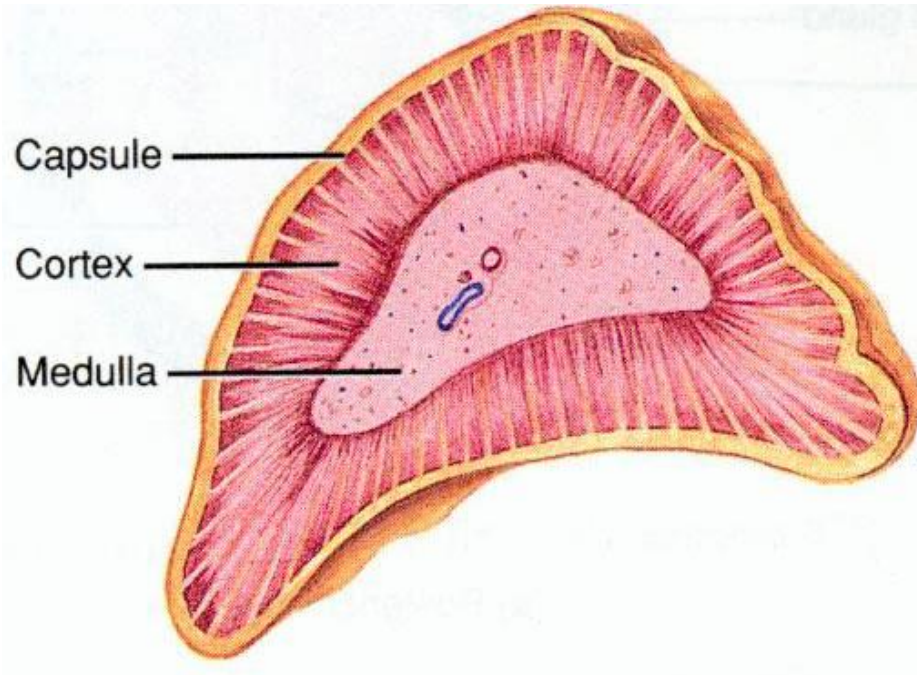
- **Understand anatomy, physiology and biochemistry of adrenal glands**

- **Understand clinical approach and management of adrenal disorders:**
 - Function: hyper and hypo-secretion
 - Structure

Anatomy



Anatomy



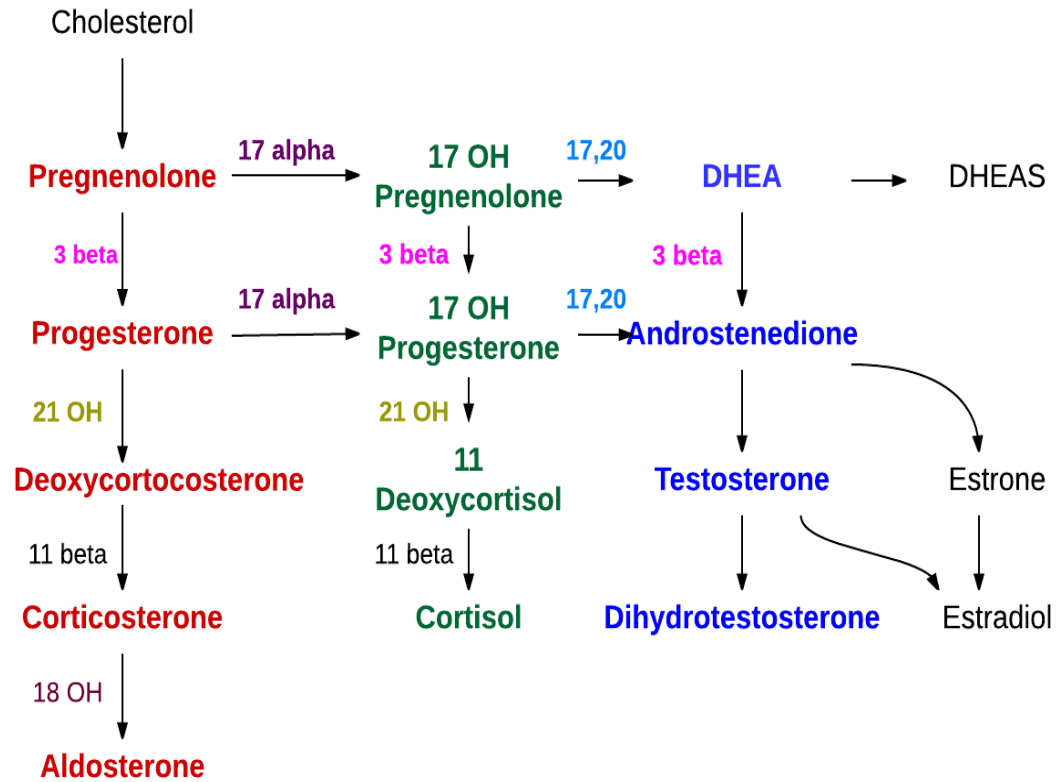
Zona	Hormones	Effects	Regulatory Control
<u>G</u>lomerulosa	<u>S</u>alt Mineralocorticoids (aldosterone)	Kidney: Maintain intravascular volume by : <ul style="list-style-type: none"> Increase reabsorption of Na⁺ and water 	angiotensin II, K ⁺ Na ⁺
<u>F</u>asciculata	<u>S</u>weet Glucocorticoids (cortisol)	Lipolysis Increase blood sugar	ACTH
<u>R</u>eticularis	<u>S</u>ex Androgens	It is the main source of androgen in human But it is important in the disorders	ACTH

Medulla	Catecholamines (Epinephrine, Norepinephrine, Dopamine)	Most of the time activate sympathetic fibers and increase (BP, HR, blood sugar) But could present with activations of parasympathetic as pathologic disorders	
----------------	---	---	--

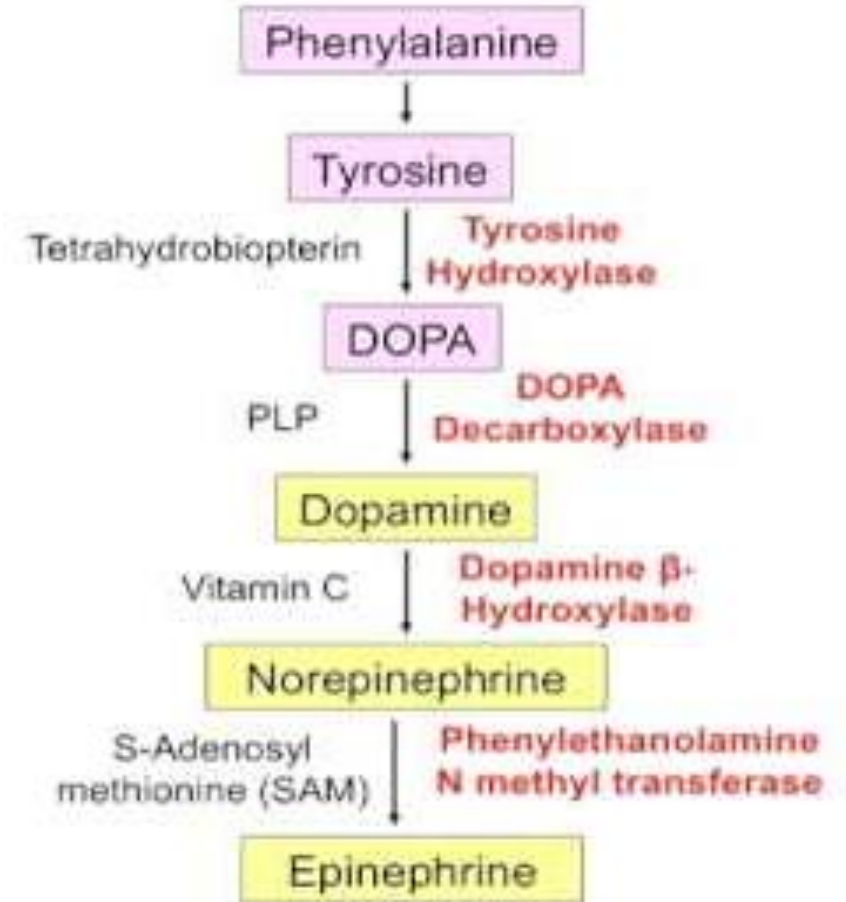
Biochemistry

- All adrenal cortex hormones are originating from Cholesterol
- All adrenal medulla hormones are originating from amino acid Tyrosine

Adrenal Cortex



Adrenal Medulla



Adrenal Disorders

```
graph TD; A[Adrenal Disorders] --> B[Function: Hypersecretion, Hyposecretion]; A --> C[Structural: Adenoma, Hyperplasia, Bilateral vs unilateral, Adrenal vs extra-adrenal];
```

Function:

- Hypersecretion
- Hyposecretion

Primary and **Secondary**

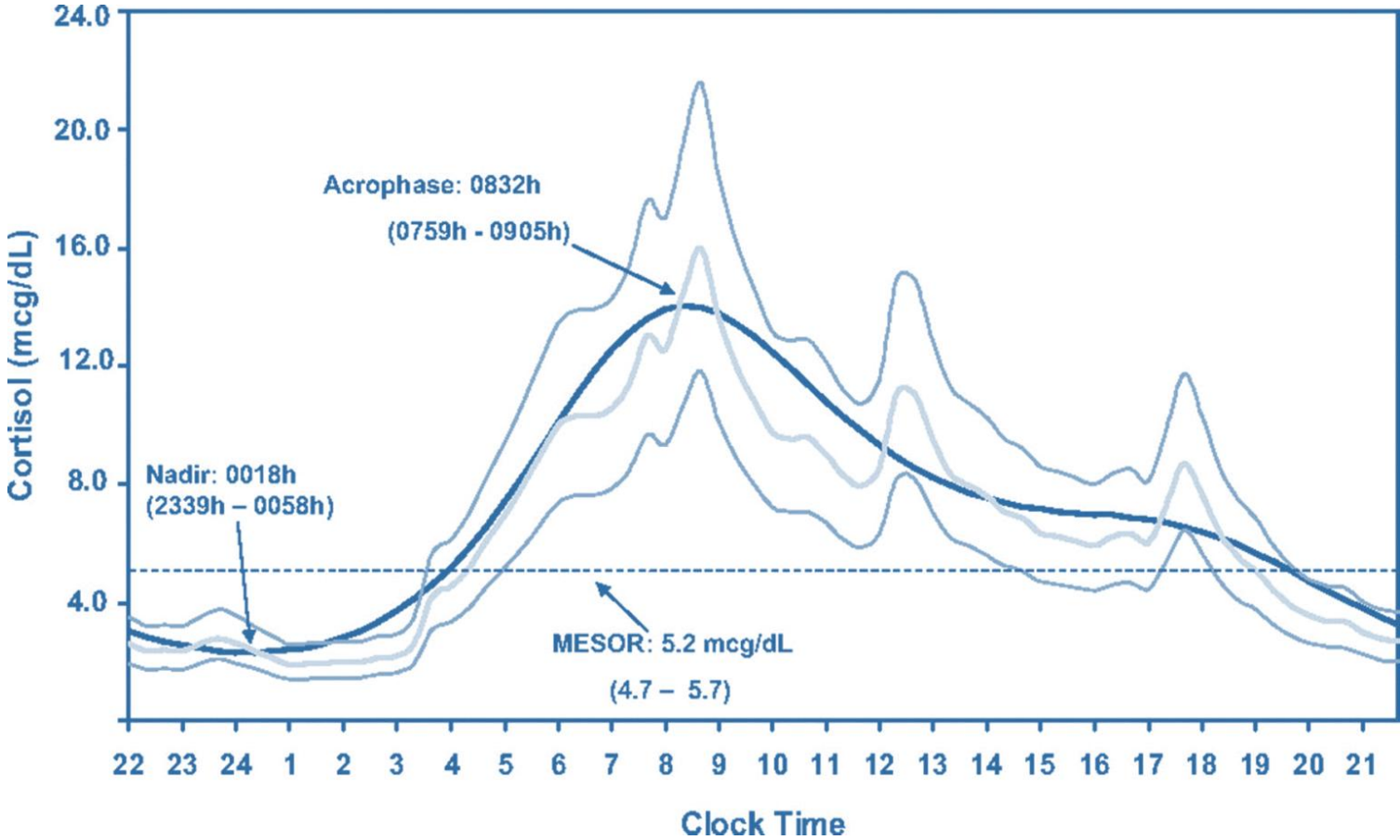
Structural

- Adenoma
- Hyperplasia
- Bilateral vs unilateral
- Adrenal vs extra-adrenal

Evaluation of Adrenal disorders

- **C: Clinical** (History and Examination)
 - function (oversecretion or hyposecretion)
 - Structural (headache, visual symptoms)
- **B: Biochemical**
 - Screen Test
 - Confirmatory Test
- **A: Anatomical**
 - CT or MRI adrenal
 - (adenoma, hyperplasia, uni or bilateral, adrenal , extradrenal, benign or malignant)
- Then treatment:

Physiological cortisol circadian rhythm



Adrenal hypofunction

- 1. Adrenal insufficiency**
- 2. Congenital Adrenal Hyperplasia**

1- Primary adrenal insufficiency

- **Idiopathic atrophy (autoimmune)**
 - isolated
 - or part of polyglandular disease (type 1 or type 2).
- **Infection** (TB, fungal: Histoplasmosis, CMV HIV, Syphilis, ..etc)
- **Infiltration** (lymphoma, Hemochromatosis, Amyloidosis, Sarcoidosis, malignancy)
- **Iatrogenic**
 - Surgical removal
 - Anticoagulation and hemorrhage
- **Medications** (ketoconazole, rifampin, phenytoin, Phenobarbital, Mitotane, Metyrapone, Aminoglutethimide)
- **Hereditary**
 - (Congenital adrenal hyperplasia, adrenal unresponsiveness to ACTH, adrenoleukodystrophy, adrenomyeloneuropathy, Refsum disease, Wolman disease)
- **Miscellaneous:**
 - Triple A syndrome= Allgrove syndrome
 - Adrenal hemorrhage

Secondary/Tertiary adrenal insufficiency

- **Pan hypopituitarism (congenital / acquired):**
 - Tumors, surgery, radiation therapy
 - Hypothalamic / pituitary disorders
- **Isolated ACTH deficiency**
- **Withdrawal from glucocorticoid therapy**
- **Inadequate glucocorticoid replacement**
- **Infant born to steroid-treated mother**
- **Surgical removal** of ACTH-producing adenoma of the pituitary gland (Cushing's disease)

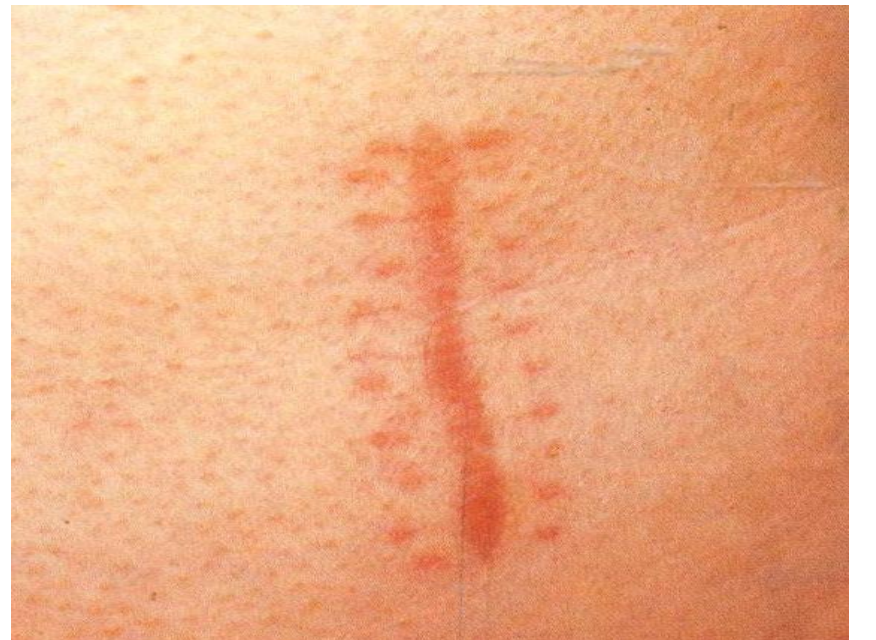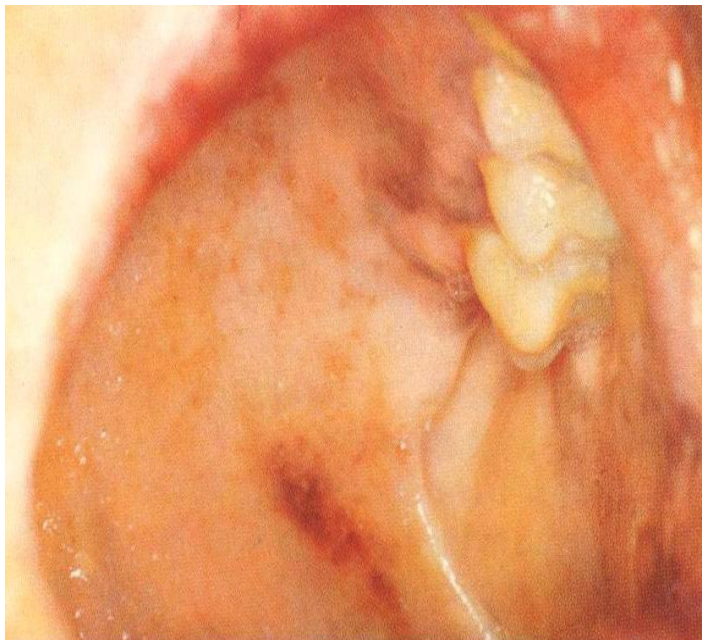
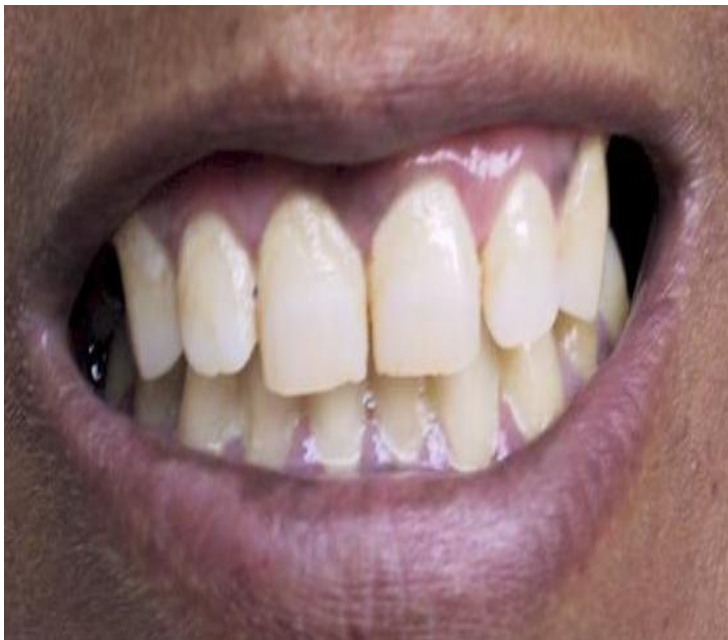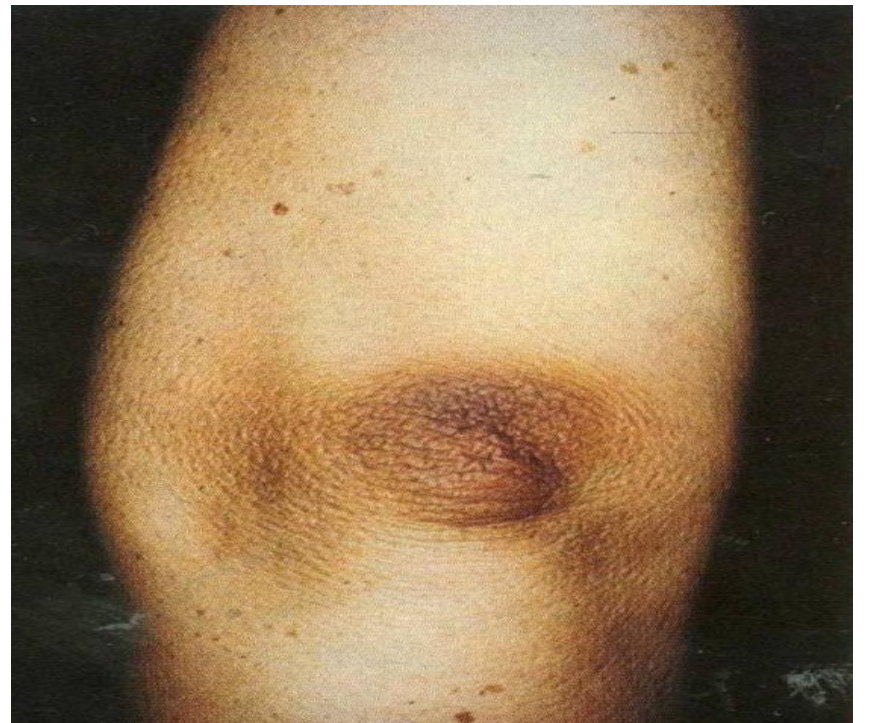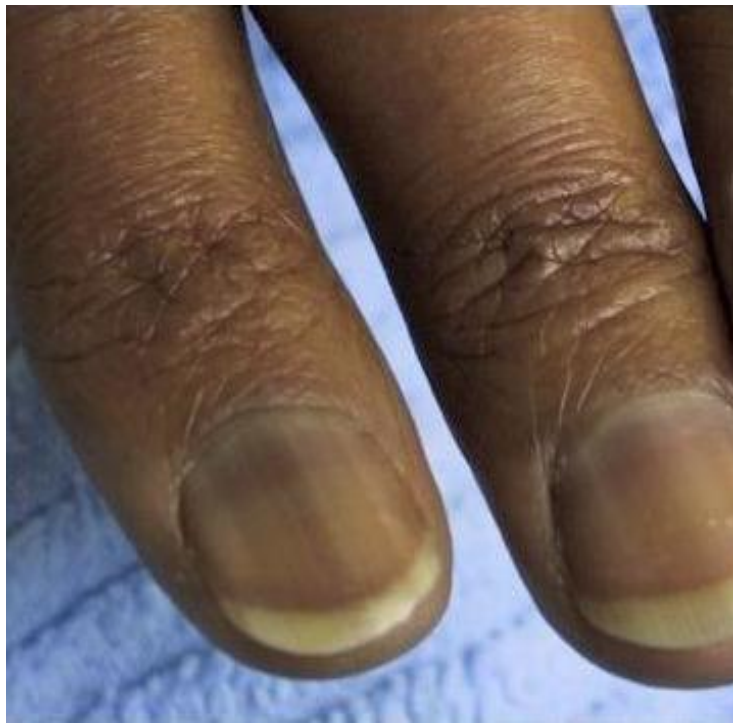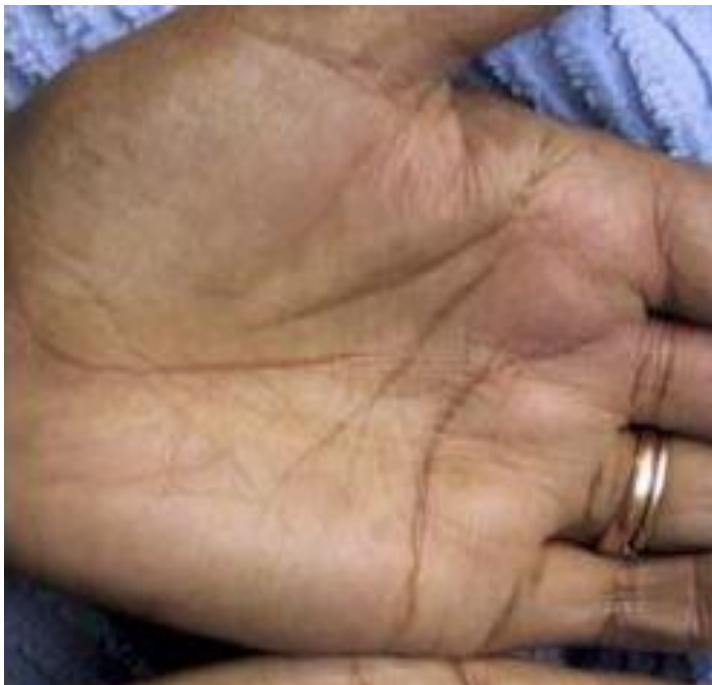Primary adrenal insufficiency (Addison disease)

- destruction of adrenal cortex (3 layers)
- Dr. Thomas Addison in 1849, TB was the commonest cause.
- Now, autoimmune: the most common cause.
- Often positive adrenal antibodies
- Could be:
 - an isolated problem
 - or associated with other autoimmune diseases:
 - Type I (APECED) : affects children: Adrenal insufficiency, hypoparathyroidism, pernicious anaemia, chronic candidiasis, chronic active hepatitis, and hair loss)
 - Type II “Schmidt's syndrome” usually affects young adults : hypothyroidism, adrenal insufficiency and diabetes mellitus, vitiligo

Clinical

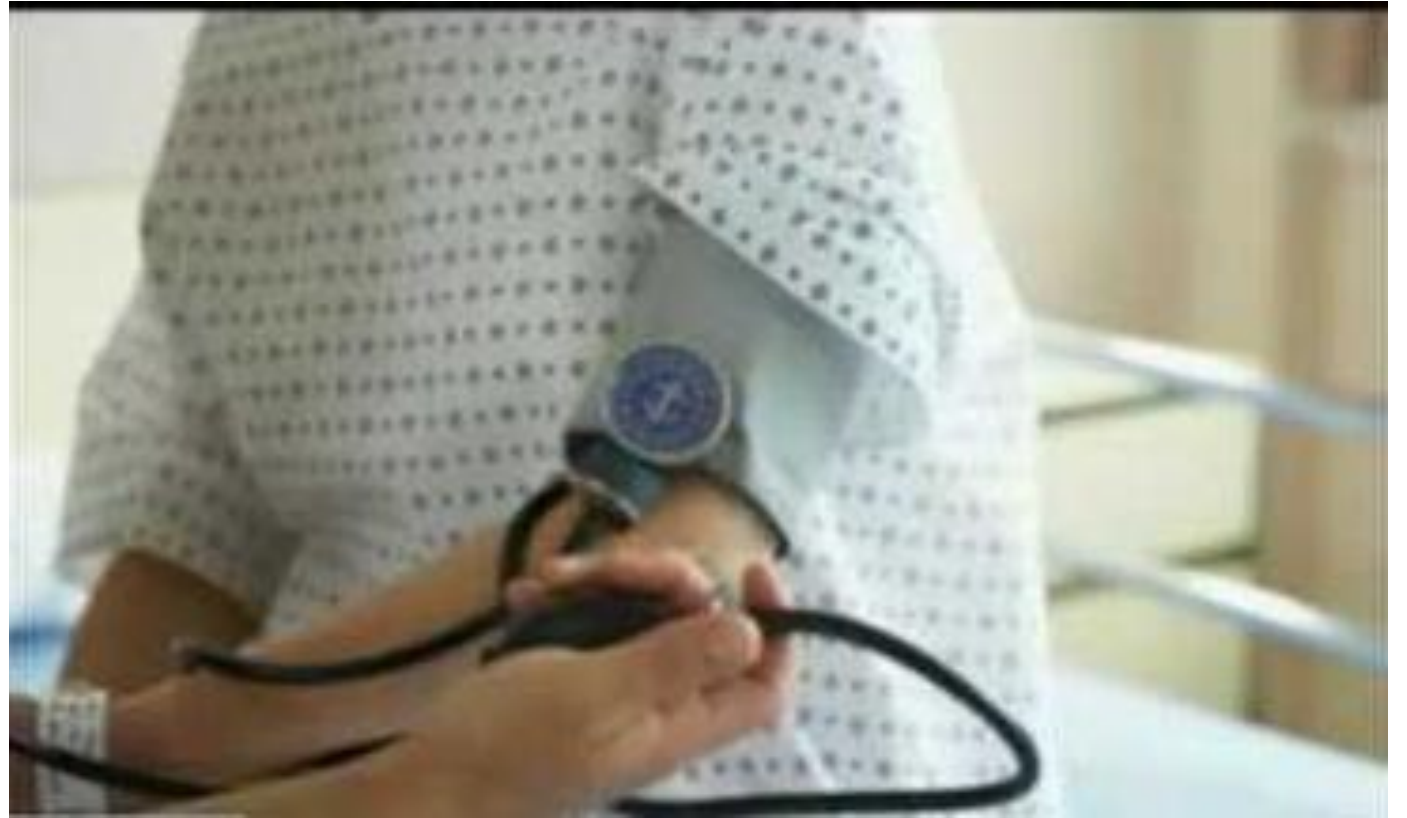- weakness, tiredness, fatigue, Nausea, Vomiting, Constipation, Abdominal pain, Diarrhea, weight loss, Hyperpigmentation, fasting hypoglycemia.
- **Hypotension**, Shock and death
- Decreased axillary and pubic hair (? Clinical significant)

- **NB:**
 - destruction of adrenal cortex (3 layers)
 - Hyperpigmentation: only in Primary adrenal insufficiency due to melanocyte stimulating hormone (MSH) from pro-opiomelanocortin (POMC) Not ACTH



Hypotension

- BP and HR
- Standing and supine
- Think about AI, if not respond to IVF and initial management



B: Biochemical

	Primary	Secondary
ACTH	high	low
cortisol	low	low
Androgen (adrenal)	Low High in CAH	low
Aldosterone	low	Normal N.B: RAS
K	high	Normal/high
Na	Low	Low/ normal
Glucose	low	low
Hb	Normal or low	low

B: Biochemical

- Measure am cortisol
 - If high : R/O
 - If very low : diagnosis
 - If borderline result : proceed for confirmatory test
 - ACTH stimulating test
- Measure ACTH
 - to differentiate primary or secondary

A: Anatomical

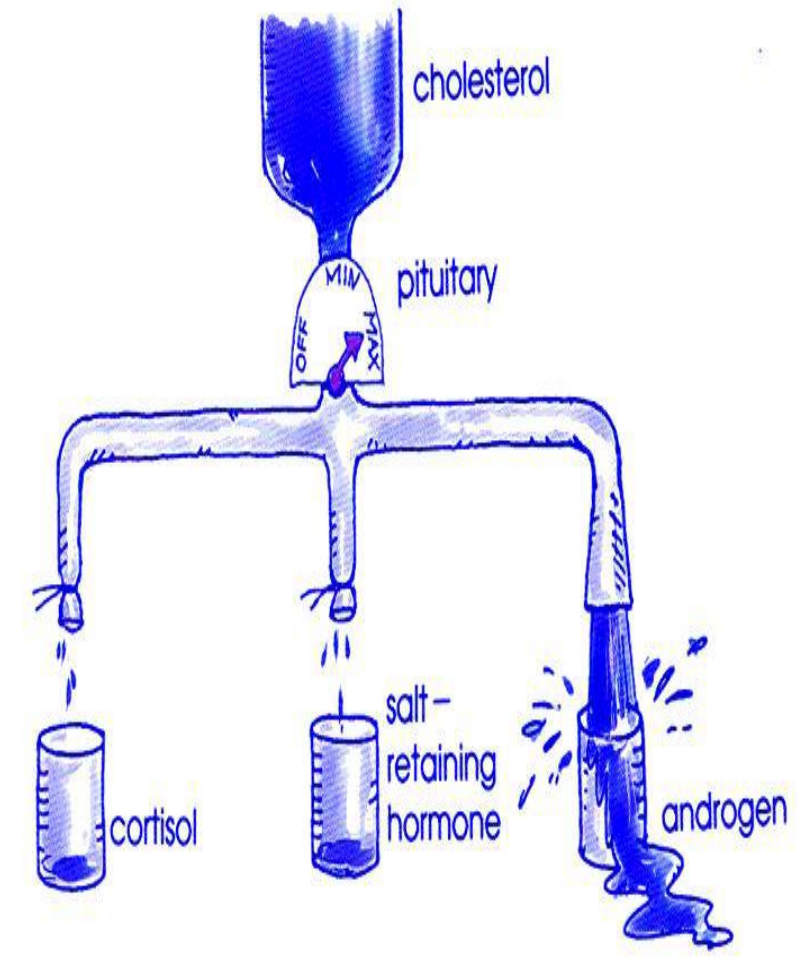
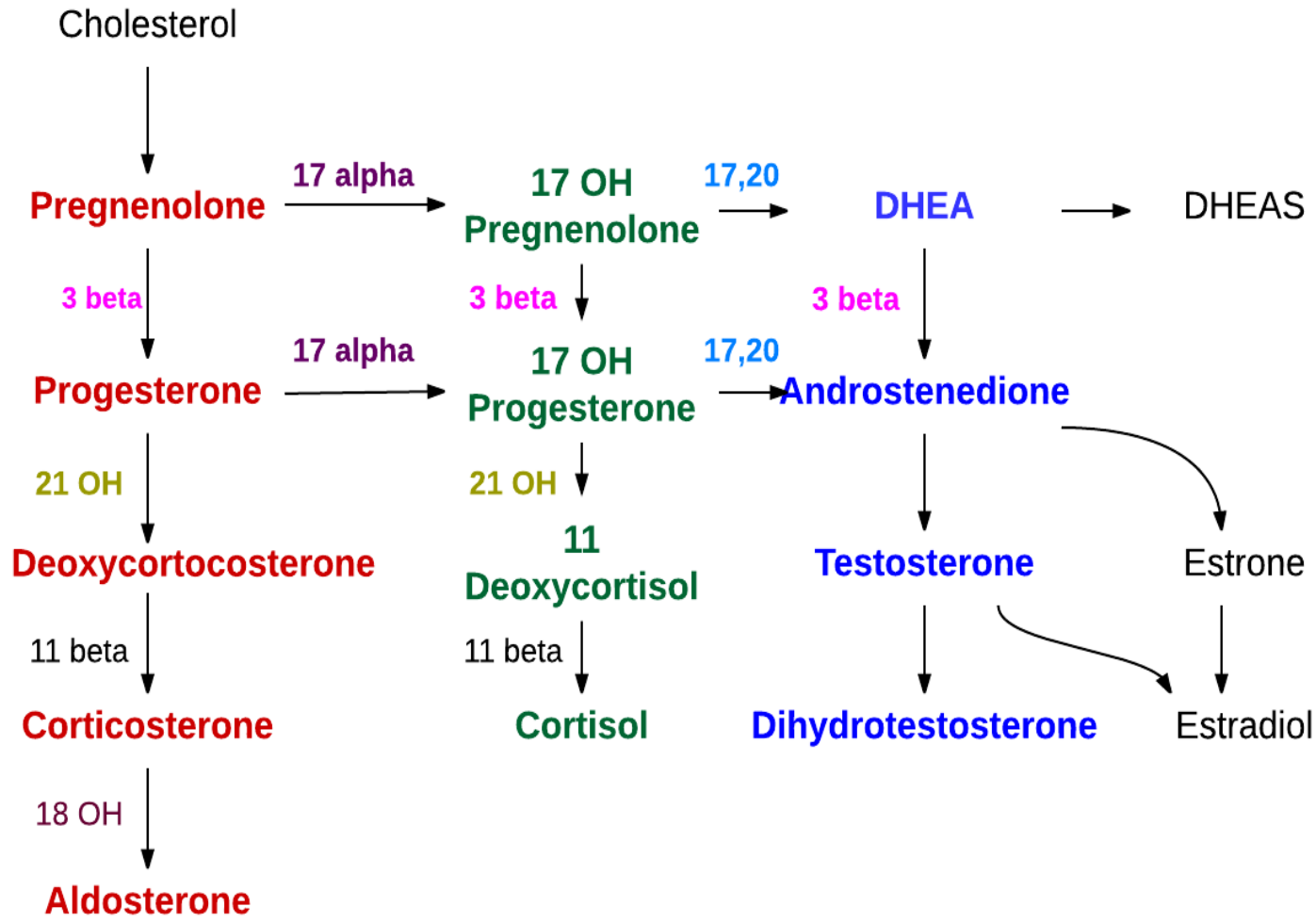
- Adrenal insufficiency is clinical and biochemical diagnosis
- No indications to do imaging unless clinically indicated such as:
 - Patient on anticoagulation
 - Malignancy with metastasis
 - Or other infiltrative disease

Treatment

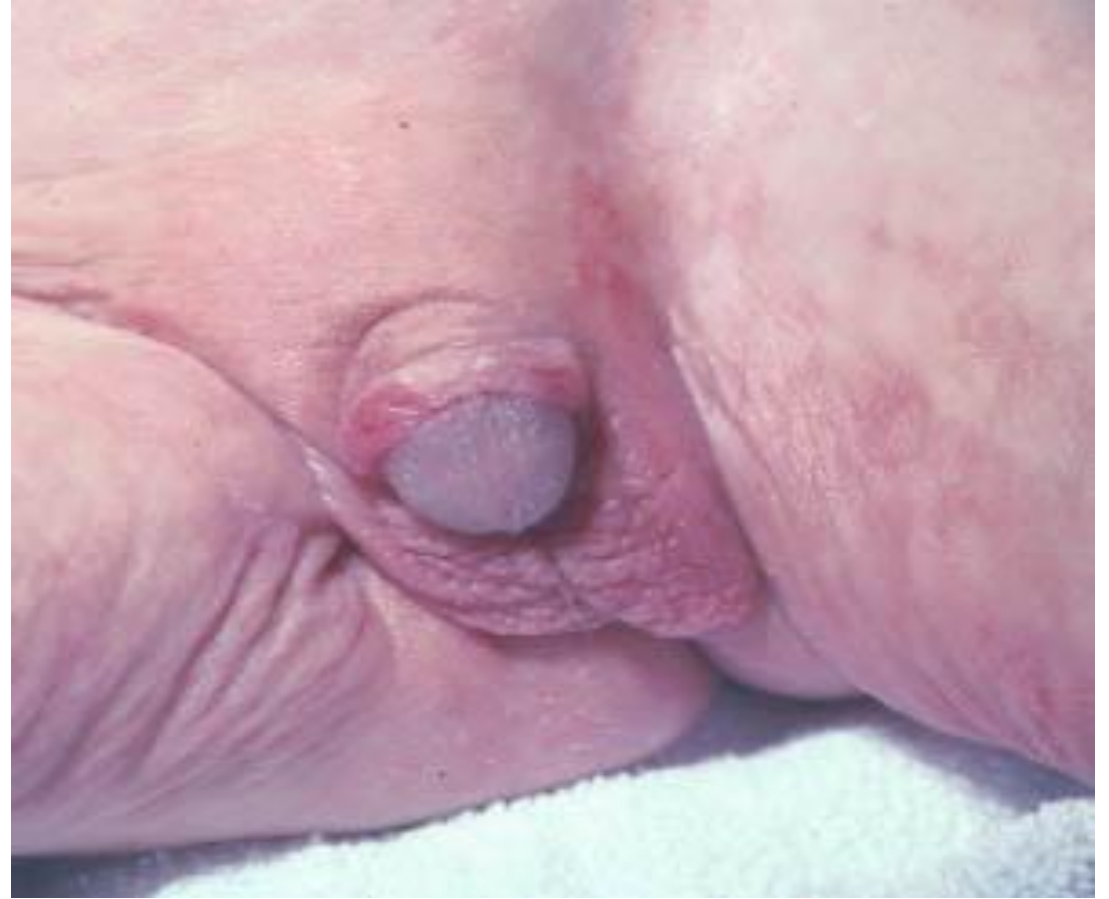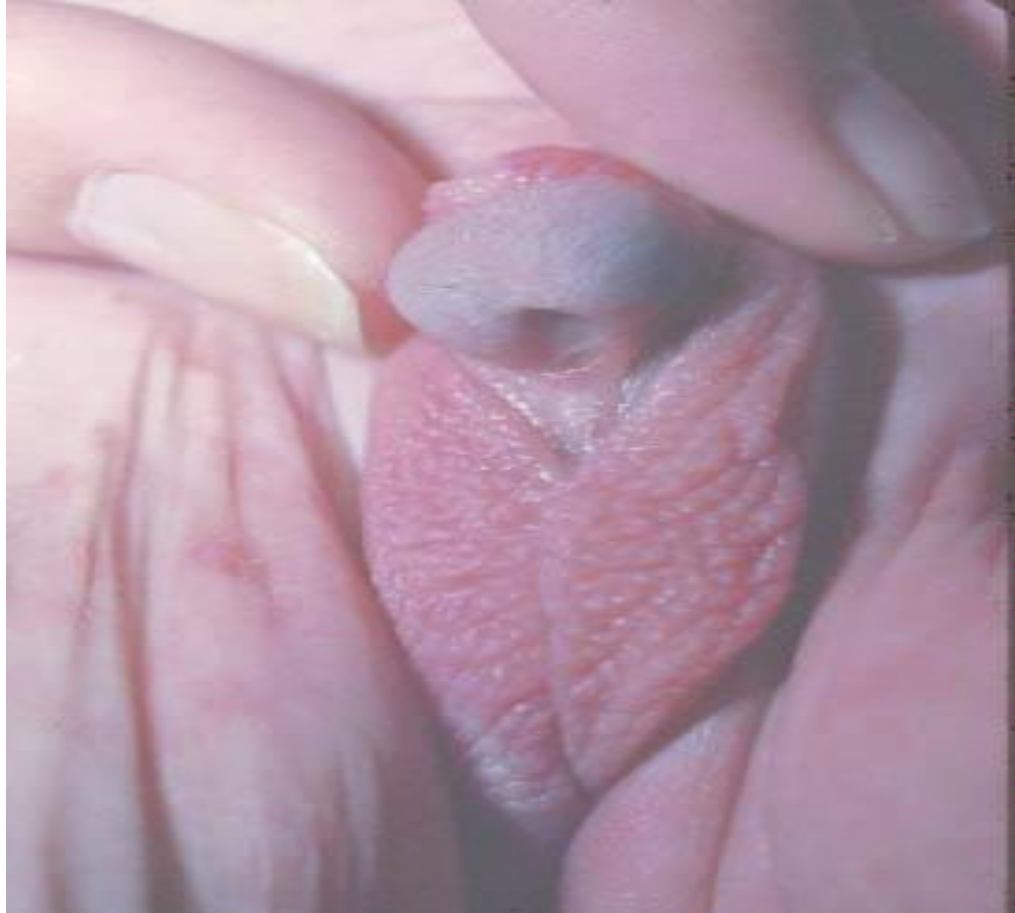- IVF: dextrose and salt for:
 - Rehydration and to restore intravascular volume
 - Electrolytes replacement
- Steroid replacement
 - If primary:
 - replace both Glucocorticoids (cortisol): hydrocortisone and Mineralocorticoids (aldosterone):
Fludrocortisone
 - if secondary: replace Glucocorticoids (cortisol): hydrocortisone only
- NB: hydrocortisone has some Mineralocorticoids activity, so if you use hydrocortisone in high IV dose , stop **Fludrocortisone**

2- Congenital Adrenal Hyperplasia

- 90–95% of CAH cases are caused by 21- OHD
- Ambiguous genitalia (Female)
- Failure to thrive
- Dehydration & Shock (usually male)
- Salt-loss presentations with electrolytes imbalance:
 - Hyponatremia
 - Hyperkalaemia
 - Hypoglycemia
- Hyperpigmentation



Is it a boy or a girl ?



Diagnosis

- Clinical: History and examination (B.P)
- Biochemical:
 - Serum electrolytes & glucose:
 - Low Na & high K
 - Fasting hypoglycemia
 - Elevated serum urea due to associated dehydration
- Elevated plasma Renin & ACTH levels
- Low Cortisol
- **High 17 – OHP**
- **High androgens** especially testosterone level
- Low Aldosterone (in salt losing types only)

Management

- Hydrocortisone:
 - 10-20 mg/m²/day divided into three doses
 - Adult usually 10-5-5 mg
 - Fludrocortisone 0.05 - 0.2 mg/day
- During adrenal crisis intravenous hydrocortisone 50-100 mg Q 6-8hrs
- IVF D5 0.9% saline
- During fever or sickness 2-3 fold increment in hydrocortisone dose
- In vomiting or diarrhea, parental therapy is indicated
- Medical Alert : bracelet

Adrenal Cortical Hyperfunction

Adrenal Cortical Hyperfunction

1- Hypercortisolism : Cushing syndrome

- First described by Cushing in 1932
- A constellation of clinical abnormalities due to chronic exposure to excesses of cortisol
- **ACTH dependent (pituitary or ectopic)**
- **ACTH independent (iatrogenic (most common), adrenal adenoma or carcinoma)**

2- Hyperaldosteronism

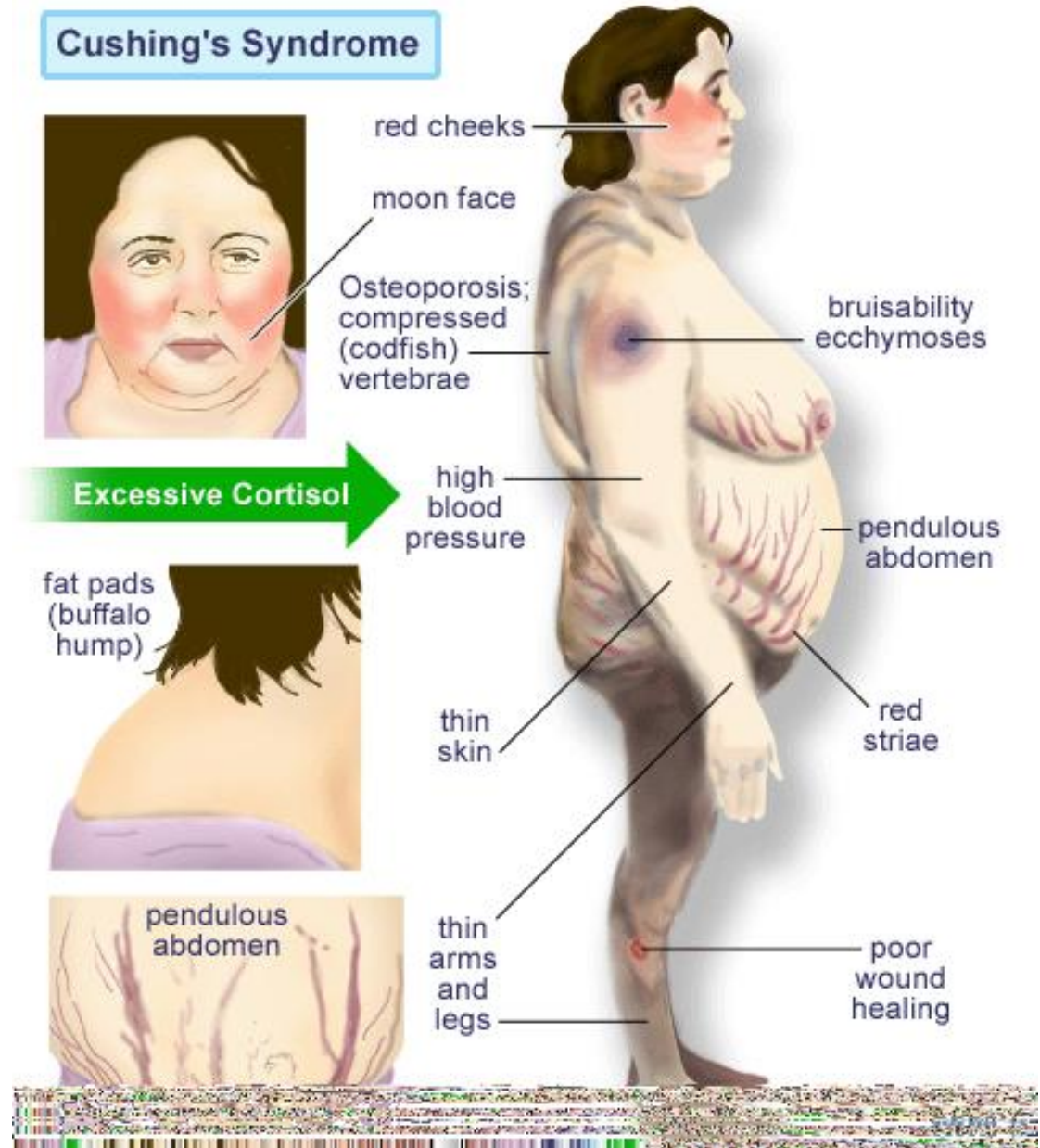
1- **Hypercortisolism**

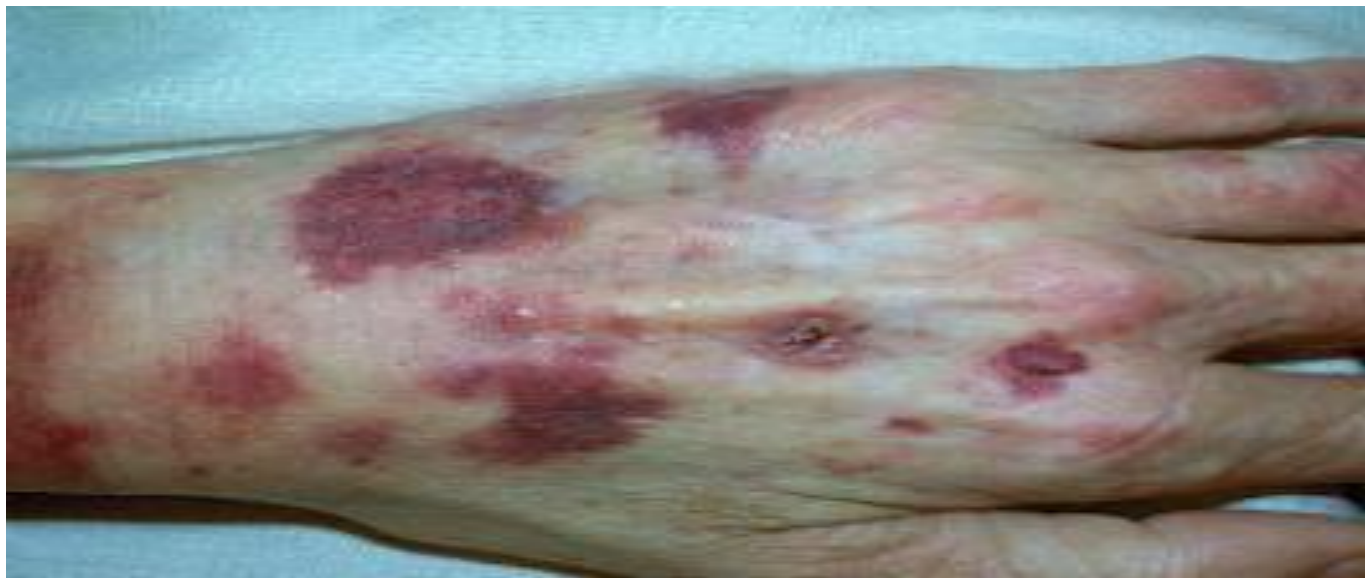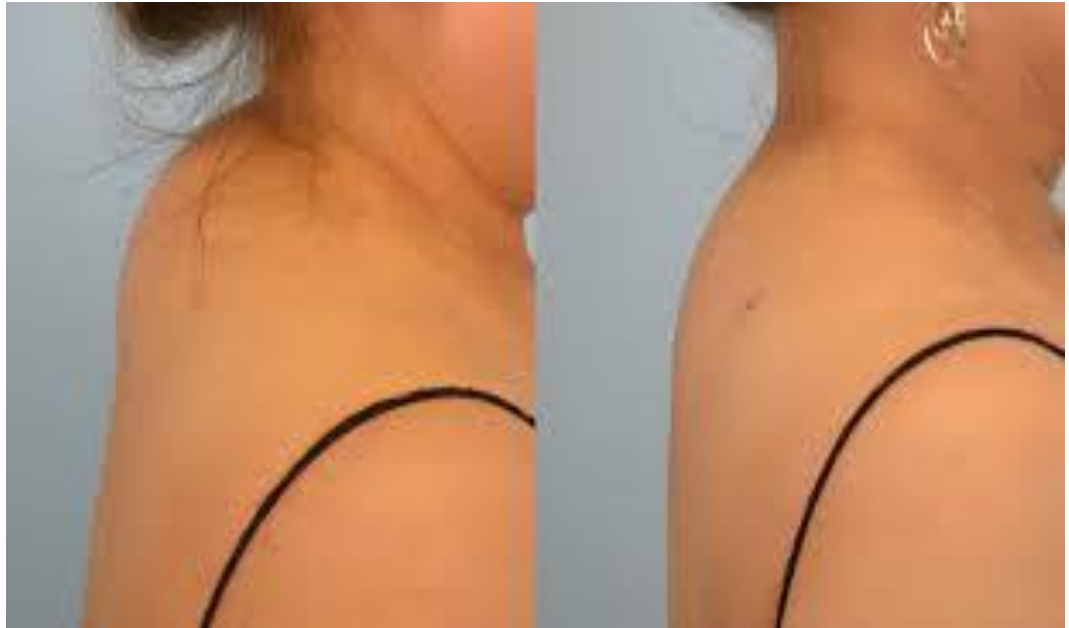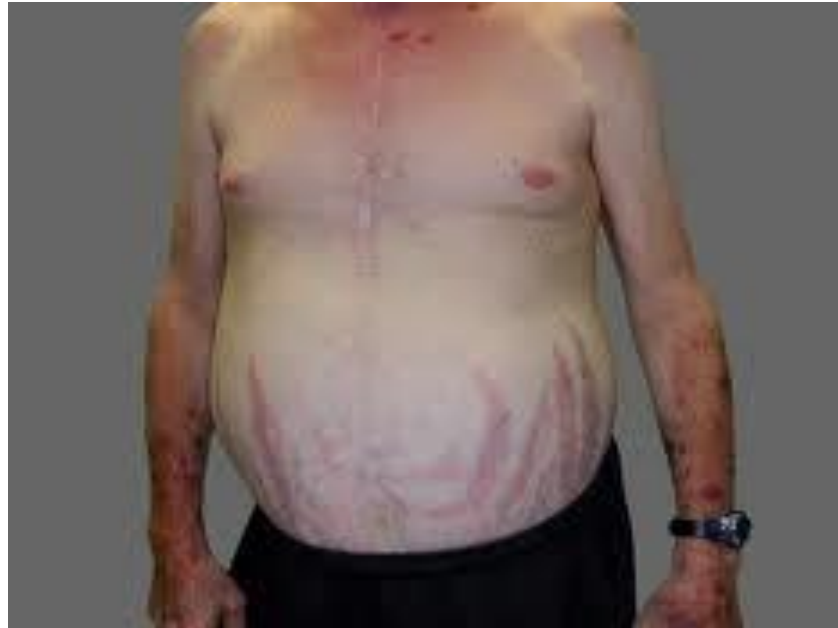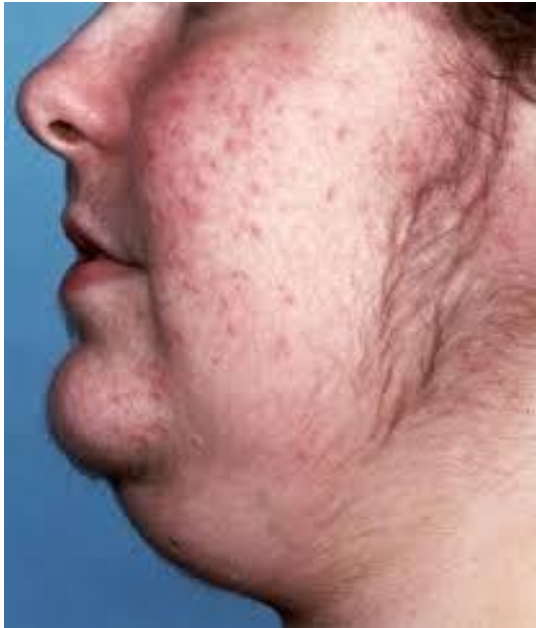- rounded "moon" facies with a plethoric appearance
- truncal obesity with prominent supraclavicular and dorsal cervical fat pads "buffalo hump"
- distal extremities and fingers are slender
- Muscle wasting and weakness
- The skin is thin and atrophic, with poor wound healing and easy bruising
- Purple striae may appear on the abdomen
- Hypertension
- renal calculi
- osteoporosis

Clinical

- DM, HTN, Obesity
- easy bruises, hirsutism
- Fractures
- Recurrent infections

- Clinical features





Cushing's (excessive cortisol)

C: Clinical	Function : Hirsutism, acne, easily bur DM,HTN, irregular period, proximal weakness, recurrent infections, depression O/E: hirsutism, acne, moon face, central obesity, stria, proximal weakness, supraclavicular fat pad,
B: Biochemical	High cortisol , high ACTH (ACTH dependent) and low if (non-ACTH dependent) 24hrs for UFC 1MG DST Midnight salivary cortisol
A: Anatomical	if ACTH: high: MRI pituitary If ACTH: low: history then CT adrenals
Treatment	Surgical or Medical

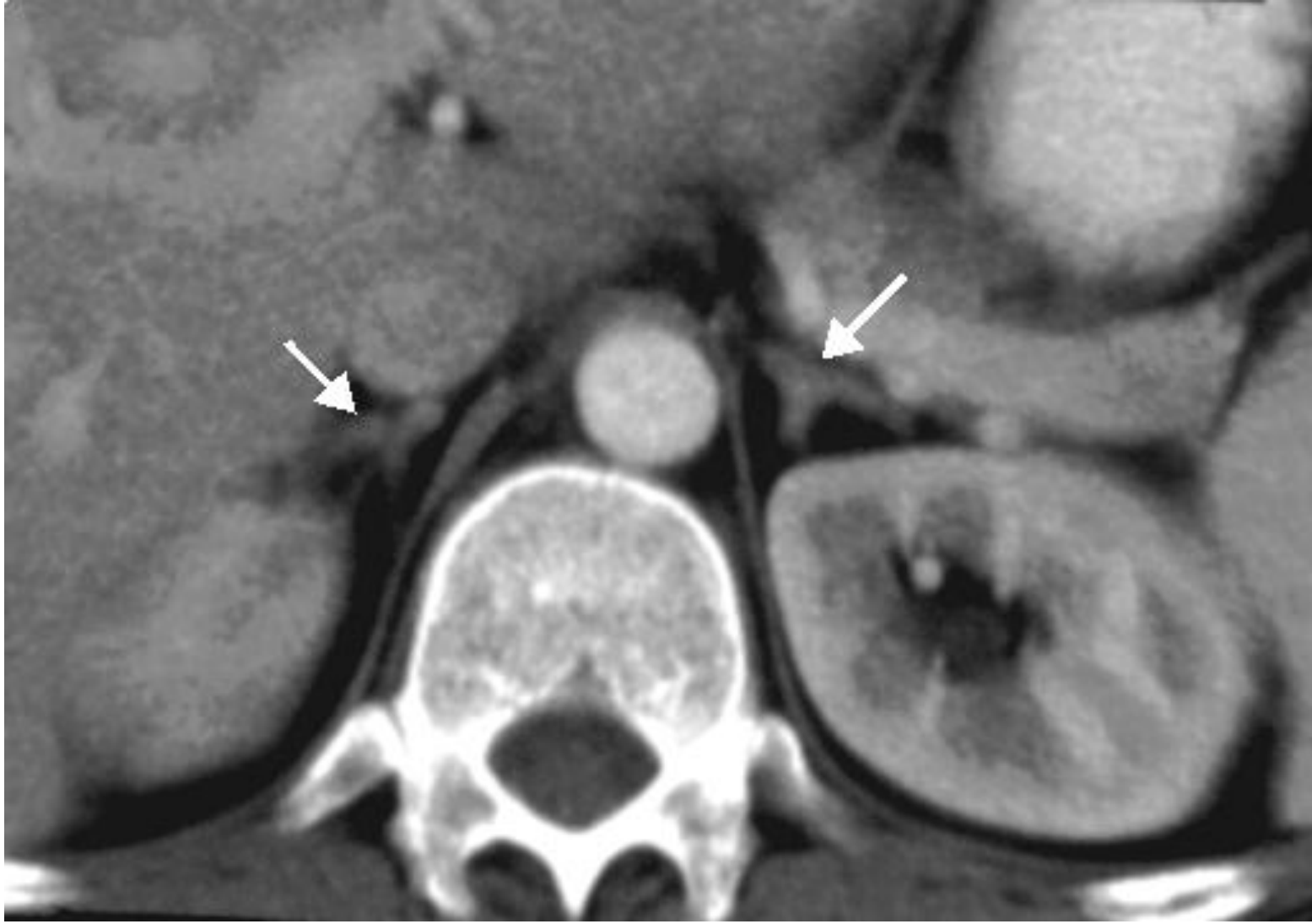2- Conn's Syndrome

- **Primary hyperaldosteronism**
 - Adenoma, usually unilateral, of the glomerulosa cells of the adrenal cortex
 - rarely, adrenal carcinoma
 - Hyperplasia
- The clinical picture may mimic CAH from of 11 α -hydroxylase deficiency

- Secondary HTN
- High Na, high Cl, high Aldosterone
- Alkalosis
- low K (episodic weakness, Paresthesias, transient paralysis, tetany, nephropathy with polyuria and polydipsia)

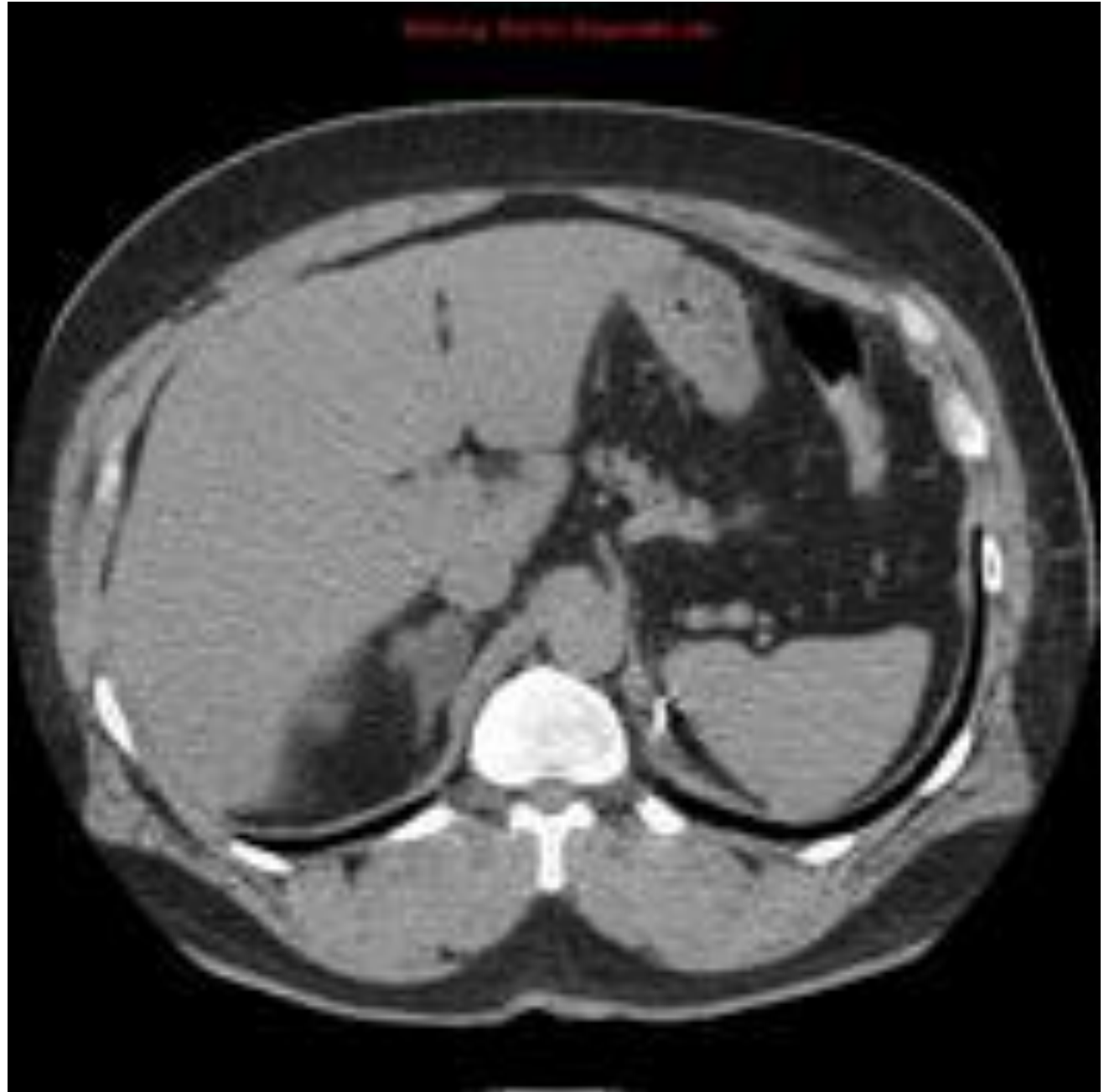Biochemical

- **Screening test:**
 - **aldosterone /renin ratio**
 - If high: do confirmatory test
 - If low: look for secondary causes
- **Confirmatory test:**
 - **Saline infusion test**
 - **Oral salt loading test**
 - **Captopril test**
 - **Fludrocortisone suppression test**



Anatomical

- CT adrenal



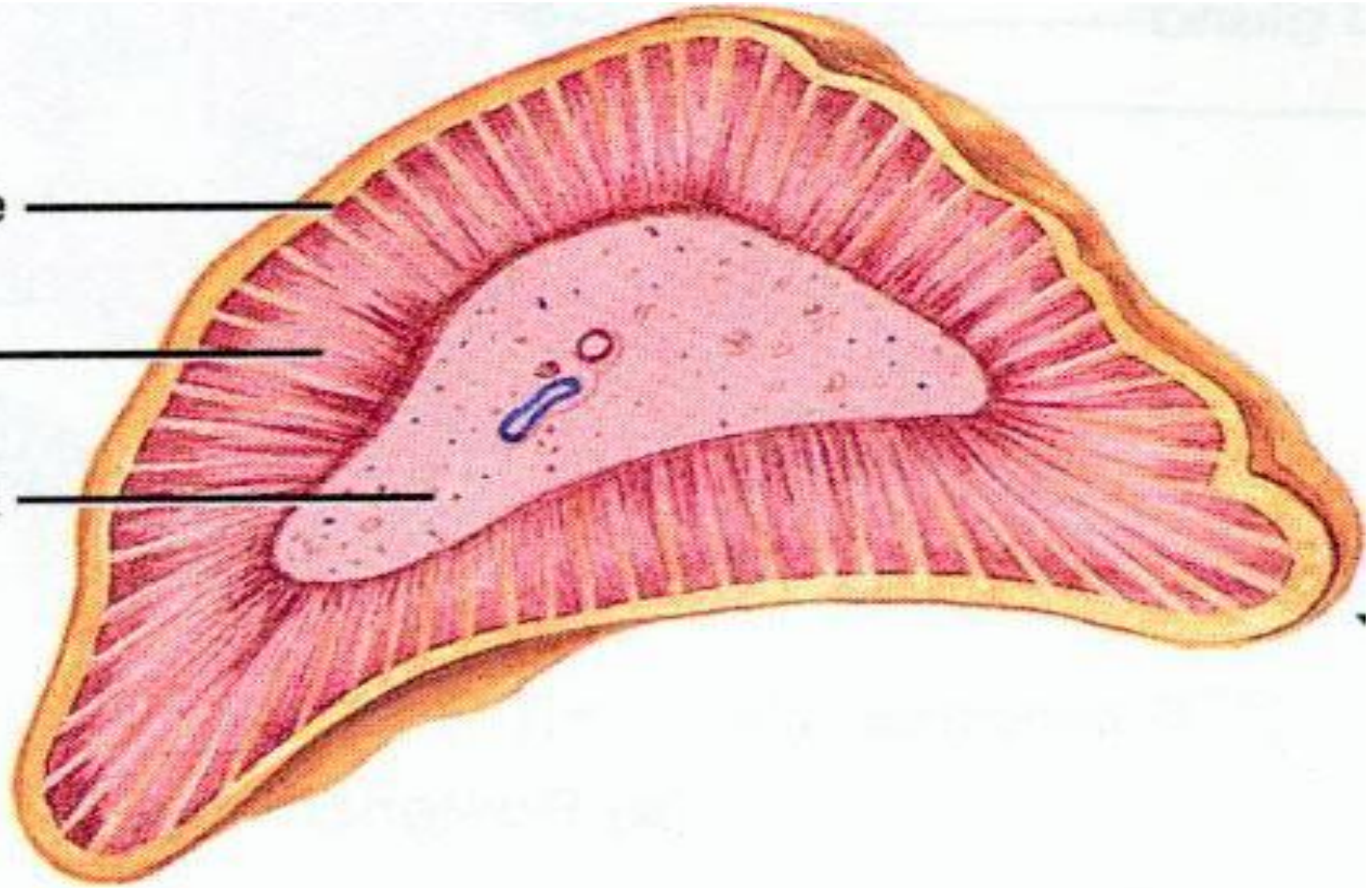
Treatment

- Adenoma → Surgical resection
- Adrenal hyperplasia:
 - Spironolactone.

Capsule

Cortex

Medulla



Pheochromocytoma

- Adrenal **medulla**: sympathetic nervous system
- **50%** are silent. (NO symptoms)
- **Pheochromocytoma**:
 - Isolated
 - or part of MEN type II A or MEN type II B
- **Secondary HTN**
- **Episodic (spells): sweating, palpitation, headache**

When you should think about Pheochromocytoma ?

- **Typical symptoms**
- **Secondary HTN**
 - Young age < 40
 - 3 anti-HTN medications
 - Resistant HTN
 - Accelerated HTN
- Any adrenal mass in image: **adrenal incidentaloma**
- You should R/O
 - pheochromocytoma
 - Cushing
 - and if there is HTN ,you should R/O hyperaldosteronism also

Biochemical

- 24 hr urine collection of **Metanephrines (2X)**
- **Plasma Metanephrines**

- **Make sure about medications that affect the result of the test (false positive)**

A: anatomical

CT scan = MRI

MIBG: if

- **Paraganglioma**
- **Young**
- **large size**
- **or malignant features**

Genetic Tests:

**N.B: 30-40% of Pheochromocytoma and Paraganglioma
Have positive genetic test. (not 10 %)**

Management

- **Control HTN**
 - α -blocker then B-Blocker (10-14 days before operation)
 - Ca-blockers: can be used
-
- **Salt loading**
 - Oral NaCl: 3 days
 - Or IVF 0.9% saline 1-2 days before surgery
- **Surgical removal**

?