

Dr Majid Al-Homiedan
Head Cardiothoracic Imaging division
ER/Trauma, Cardiothoracic and abdominal subspecialty consultant
King Saud University Medical City



Basic Chest X-ray Interpretation

Dr. Majid Al-Homiedan

Consultant and division head cardiothoracic imaging

ER/Trauma and abdominal Radiologist

King Saud University Medical City

Riyadh

Lecture outline

Chest X-ray interpretation skills

Common Chest X-ray findings

Objectives

I. Technique

Learn the difference between PA vs. AP CXR

Learn the utility of a lateral decubitus CXR

Understand the terms inspiration, penetration, and rotation as they apply to determining a technically adequate film

II. Anatomy

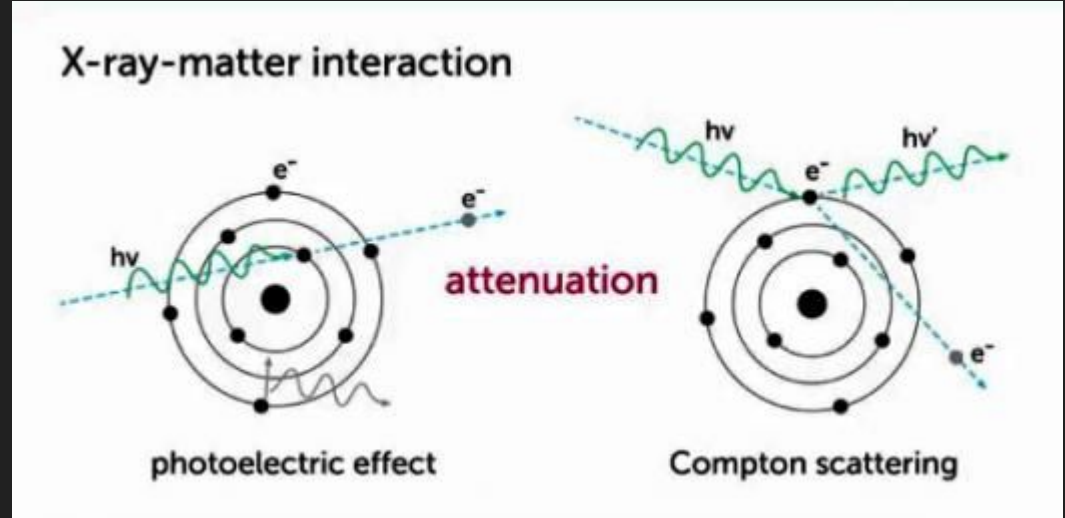
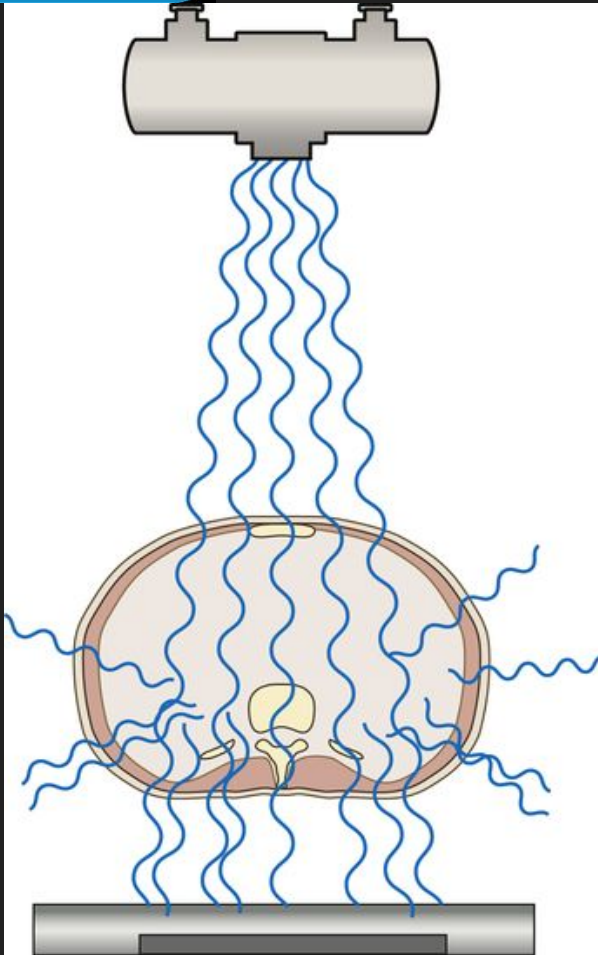
Learn the basic anatomy of the fissures of the lungs, heart borders, bronchi, and vasculature that can be seen on a chest x-ray

III. Interpretation

Develop a consistent and thorough technique for reading images

Learn how the silhouette sign can help localize pathology

IV. Pathology



Ionizing radiation



What determines BLACK □ GREY □ WHITE?

Atomic # n and path length

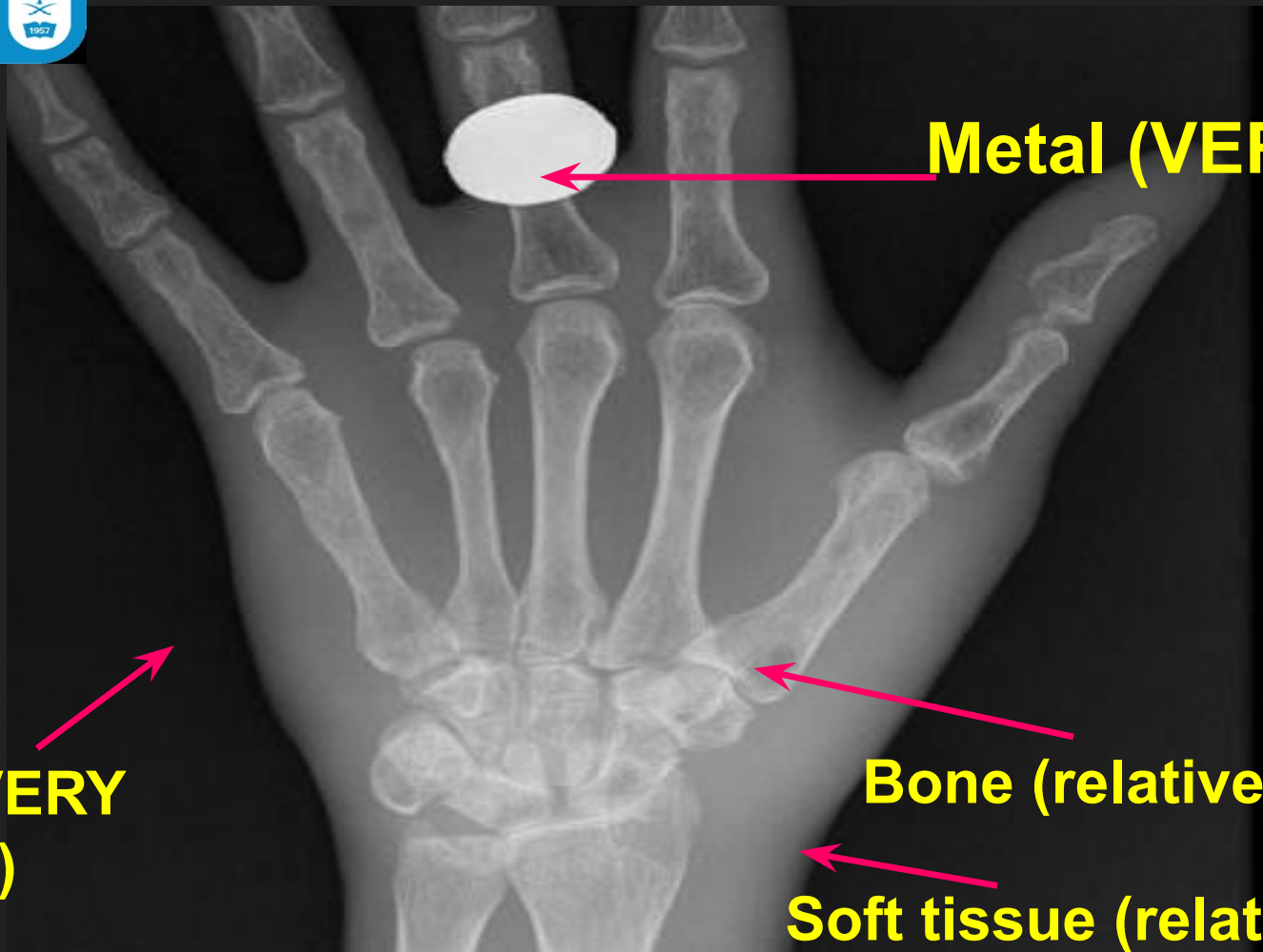
Lead Metals Bone Muscle Blood Liver Fat Air



WHITE:
Radioopaque;
“More”
Like Metal



BLACK :
Radiolucent;
“Less”
Like Air





Metal (VERY white)

Air (VERY black)

Bone (relatively white)

Soft tissue (relatively gray)

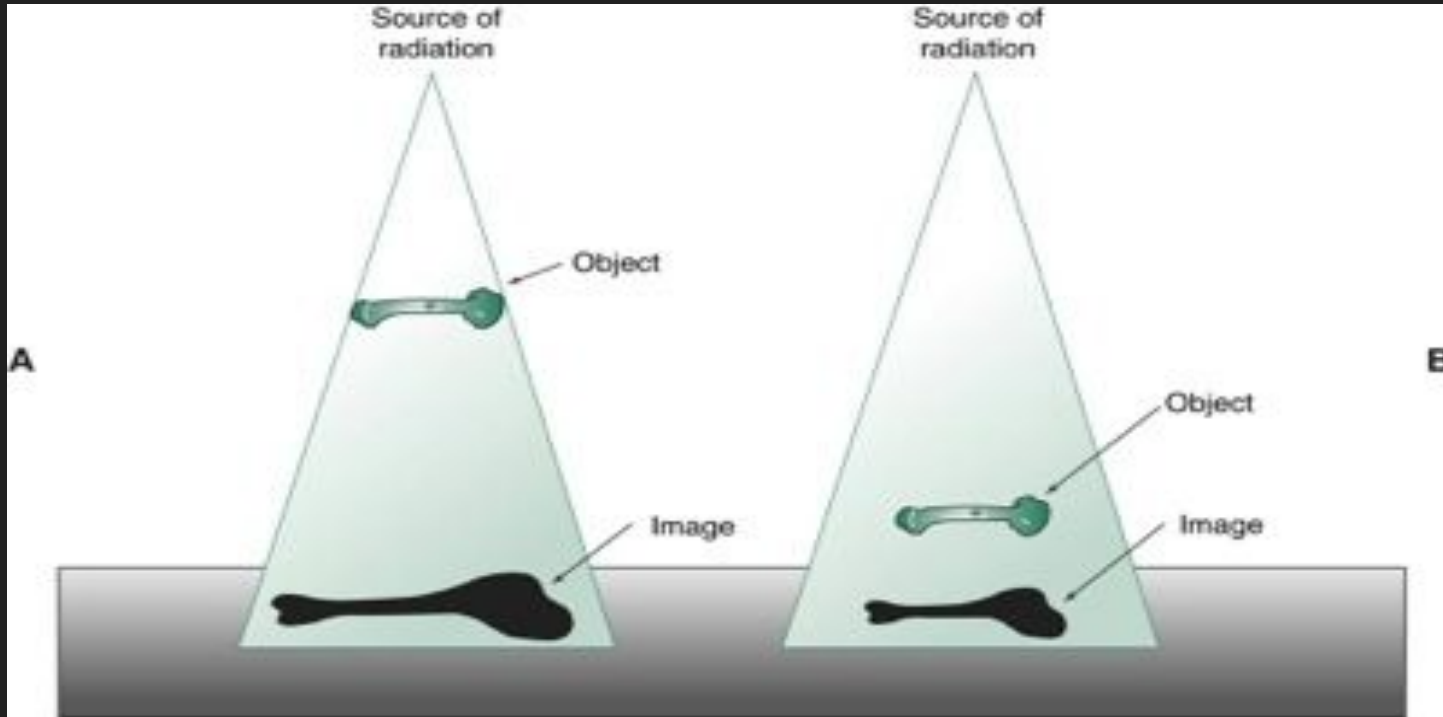
“ONE View is NO View”



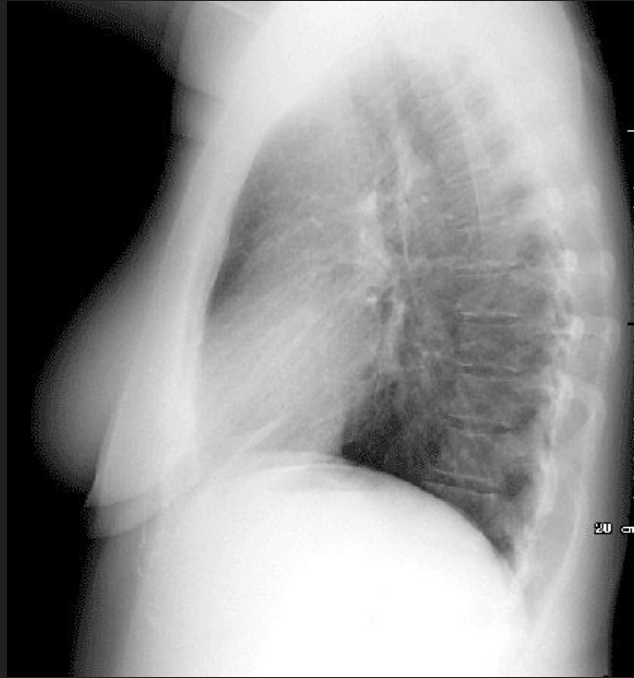
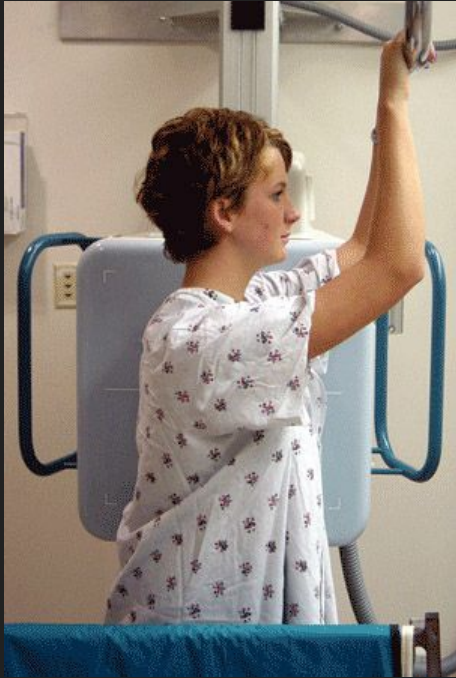Positioning PA



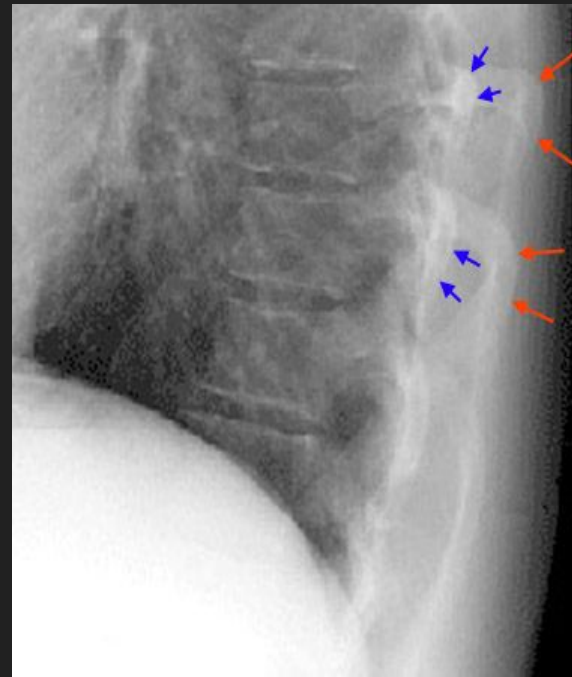
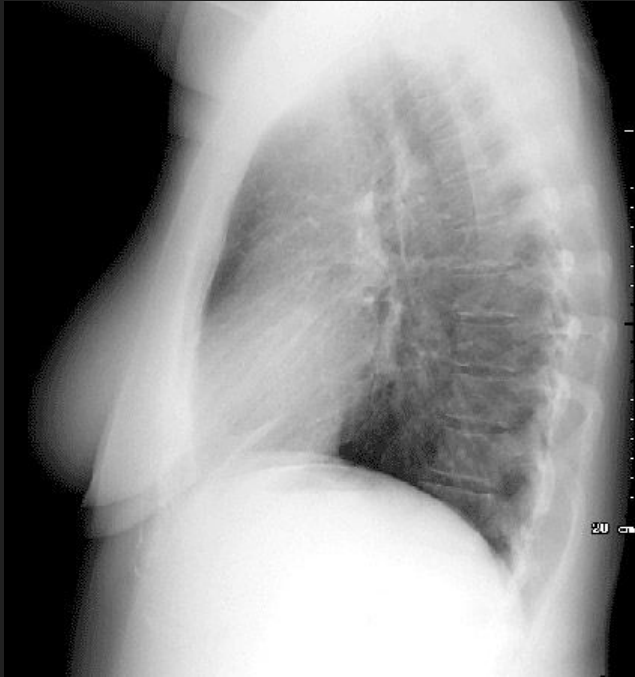
Positioning PA

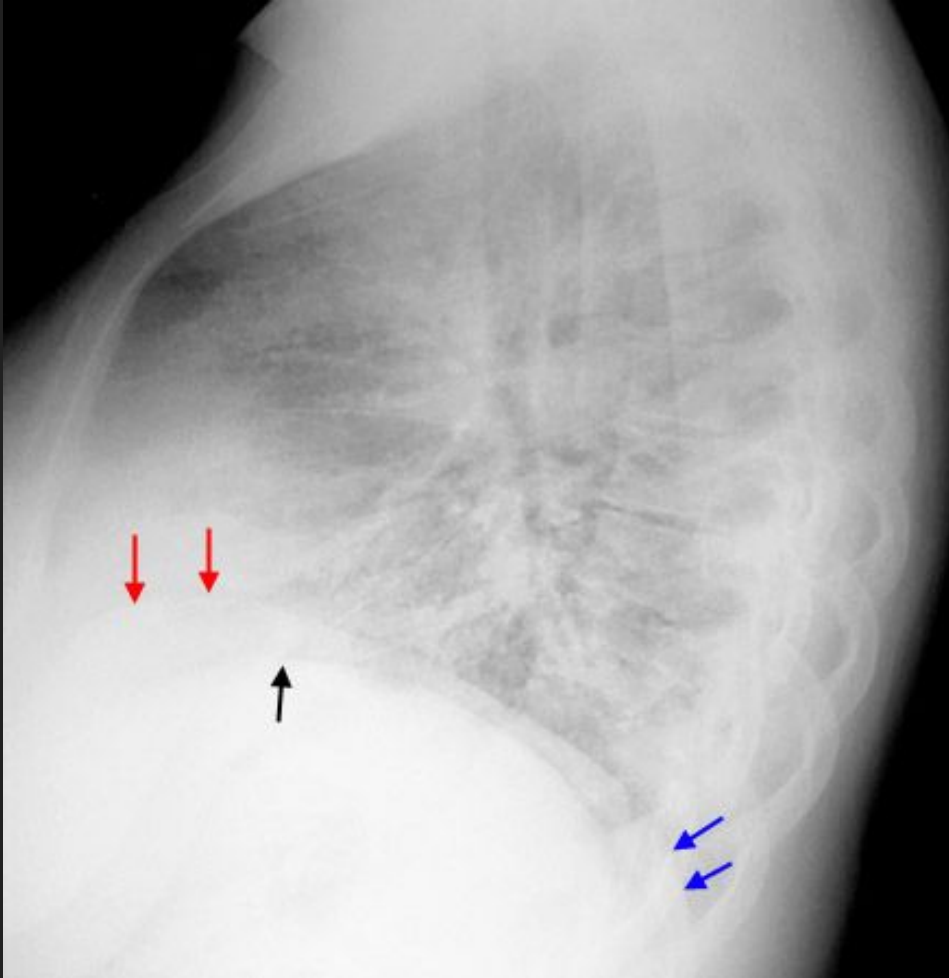


Positioning lateral

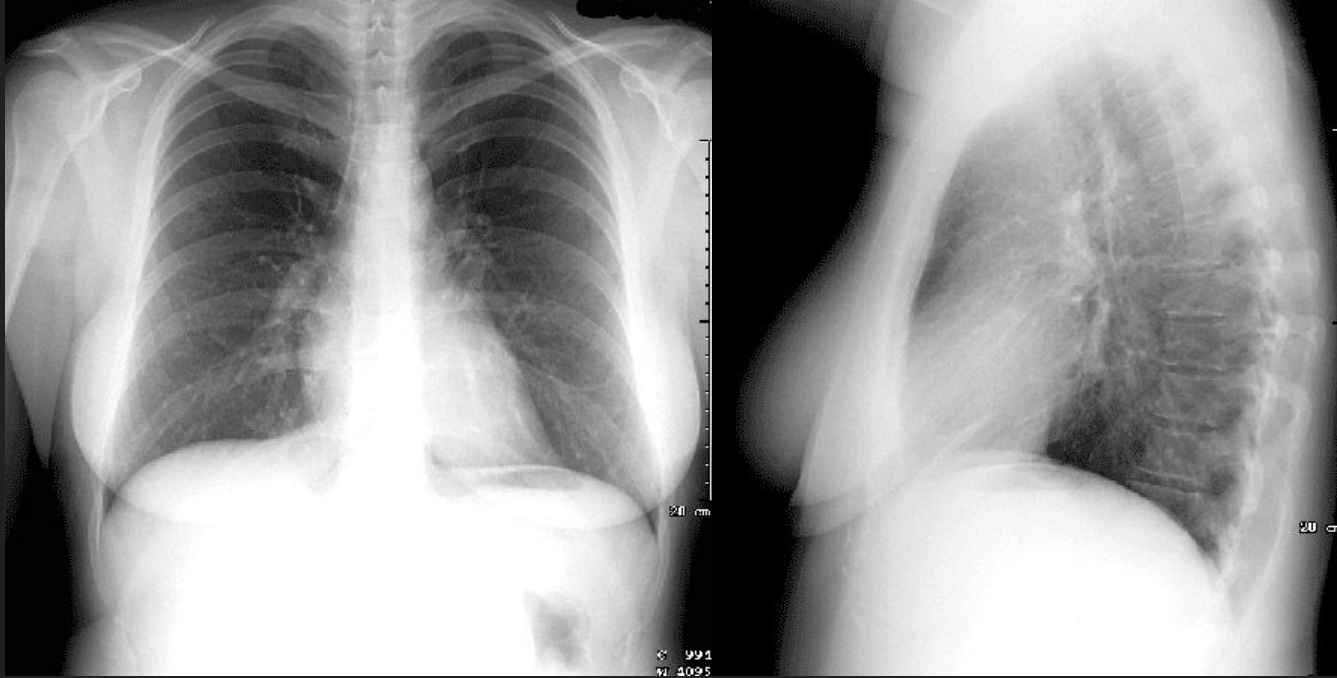


Positioning

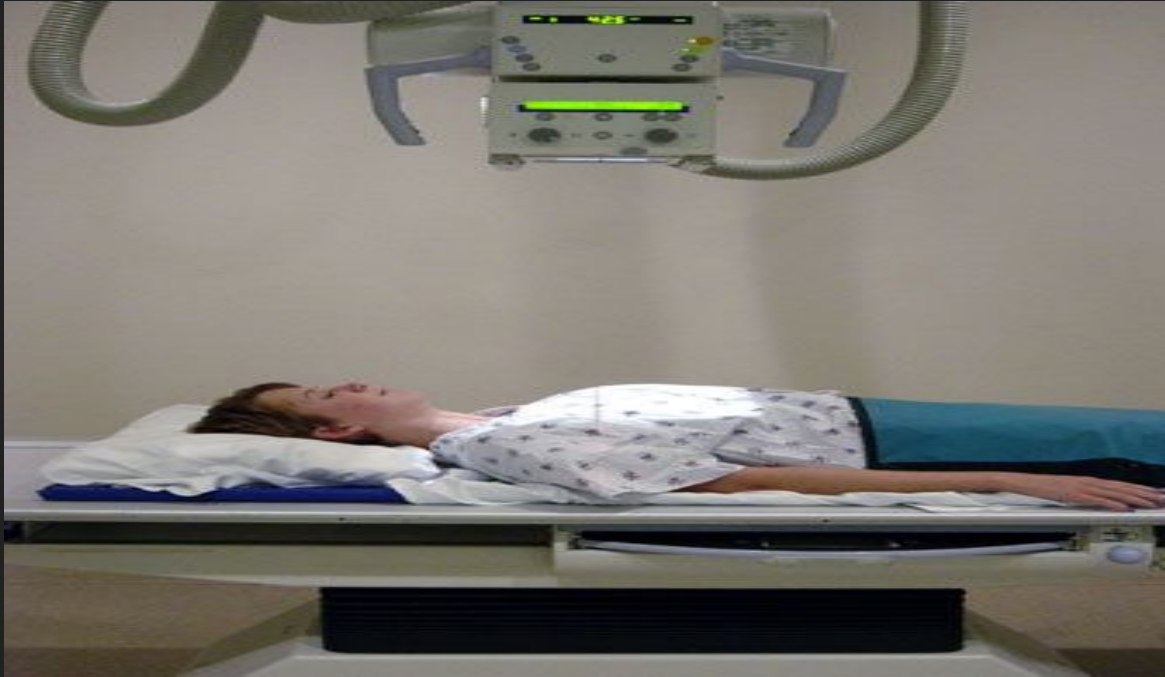



Always read together



Positioning AP

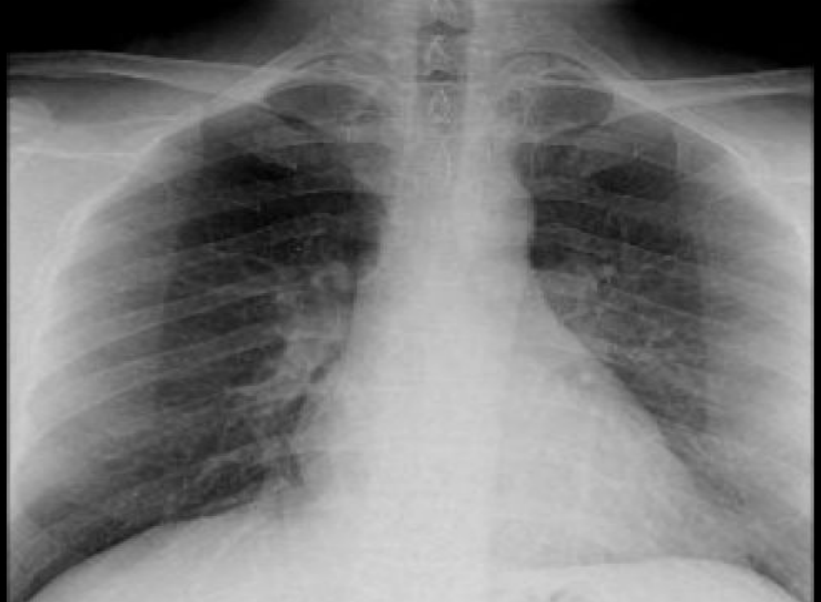
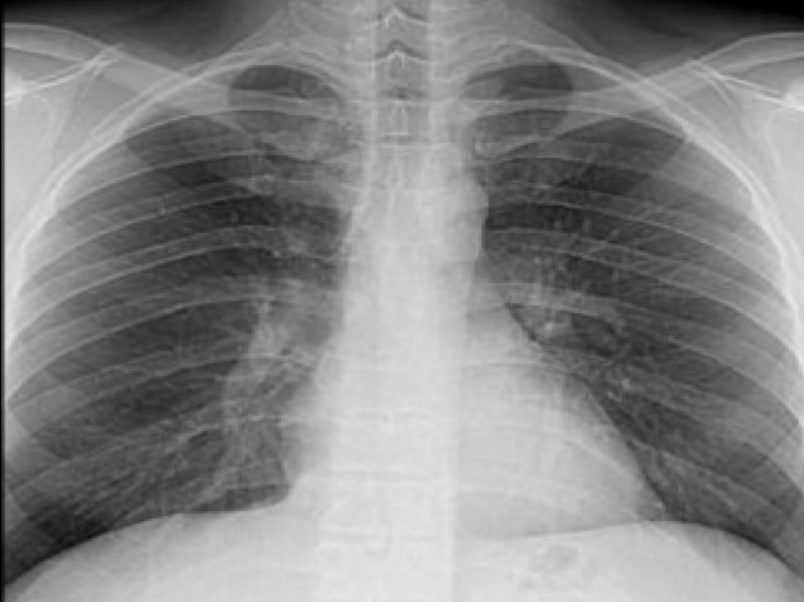
Positioning PA vs AP

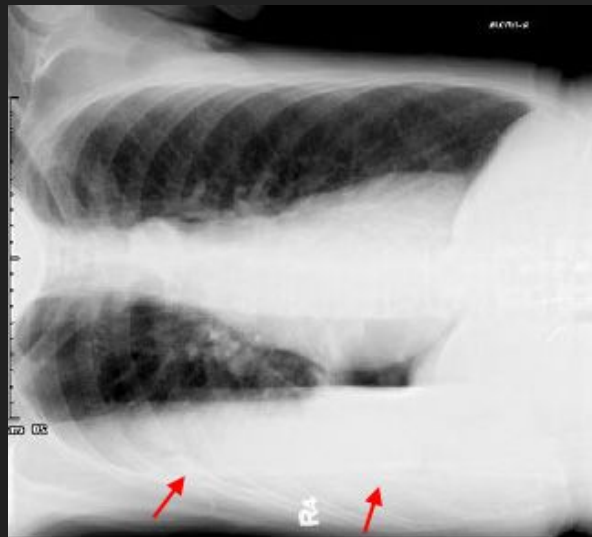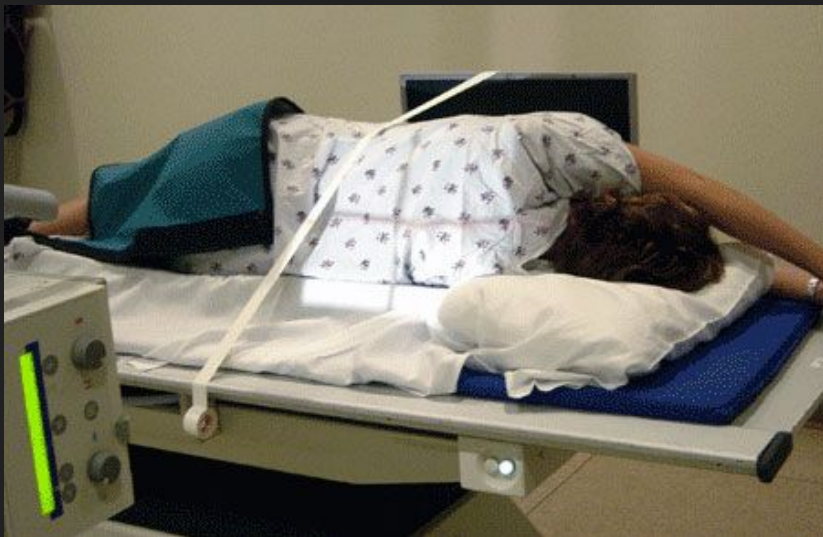PA

VS

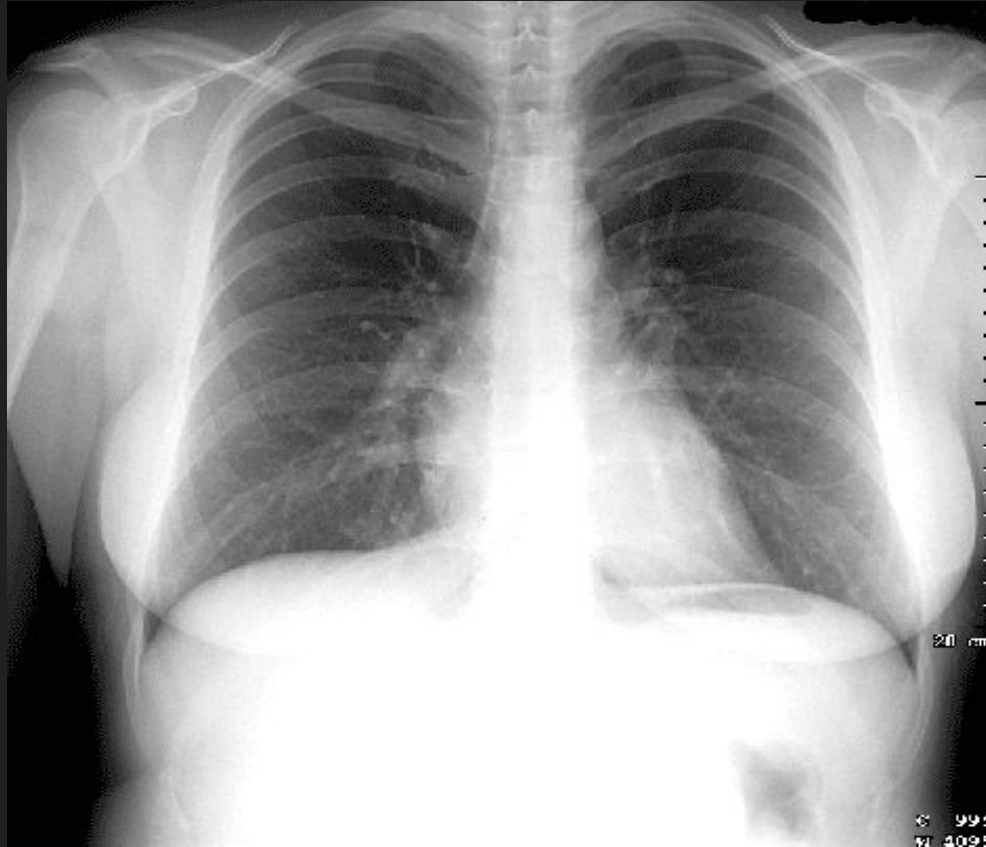
AP



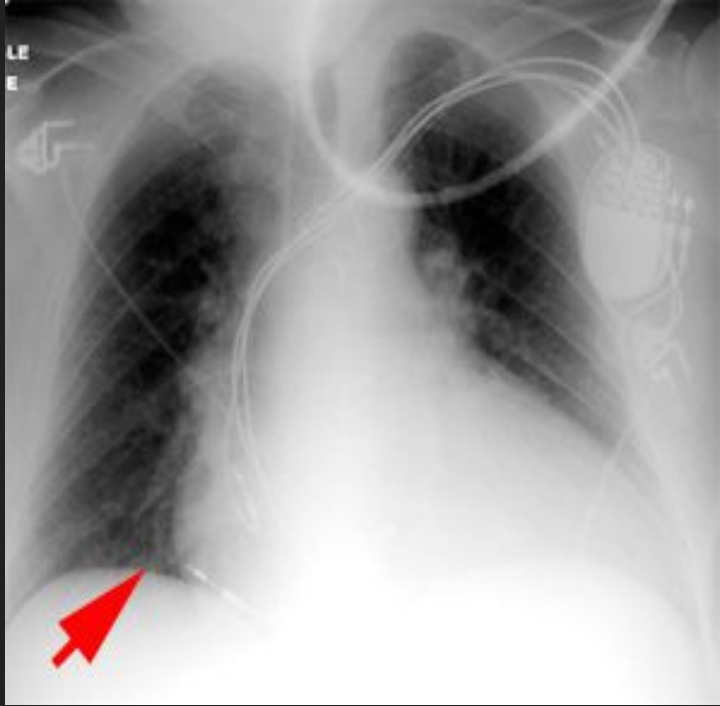
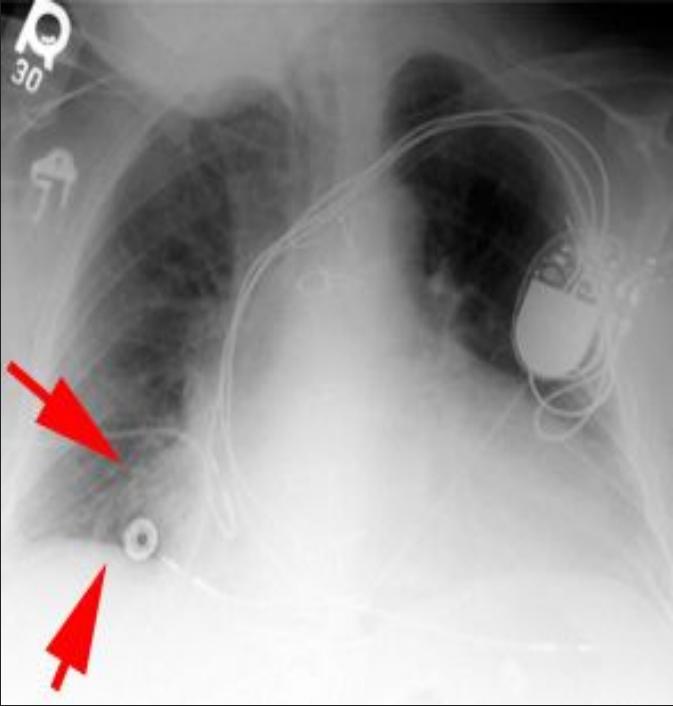
Positioning Lateral decubitus



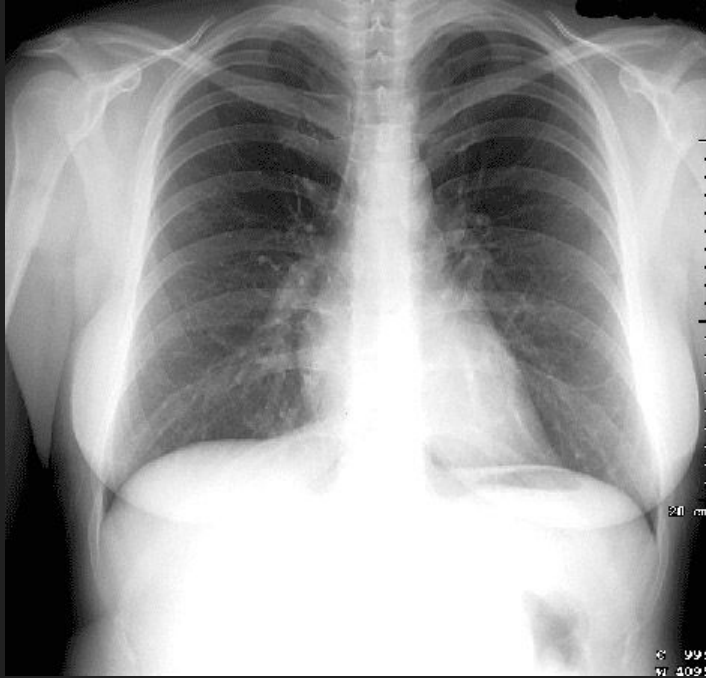
Technically adequate inspiration



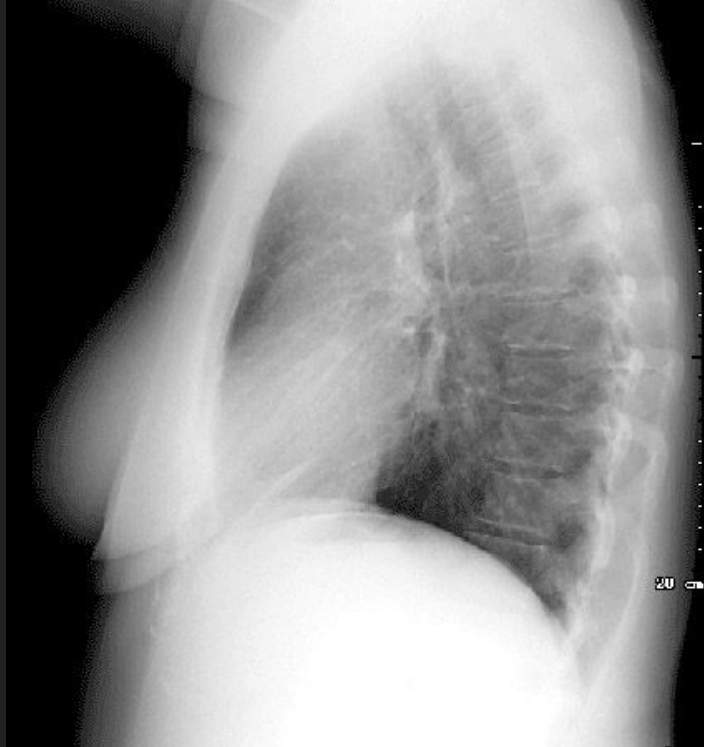Technically adequate inspiration

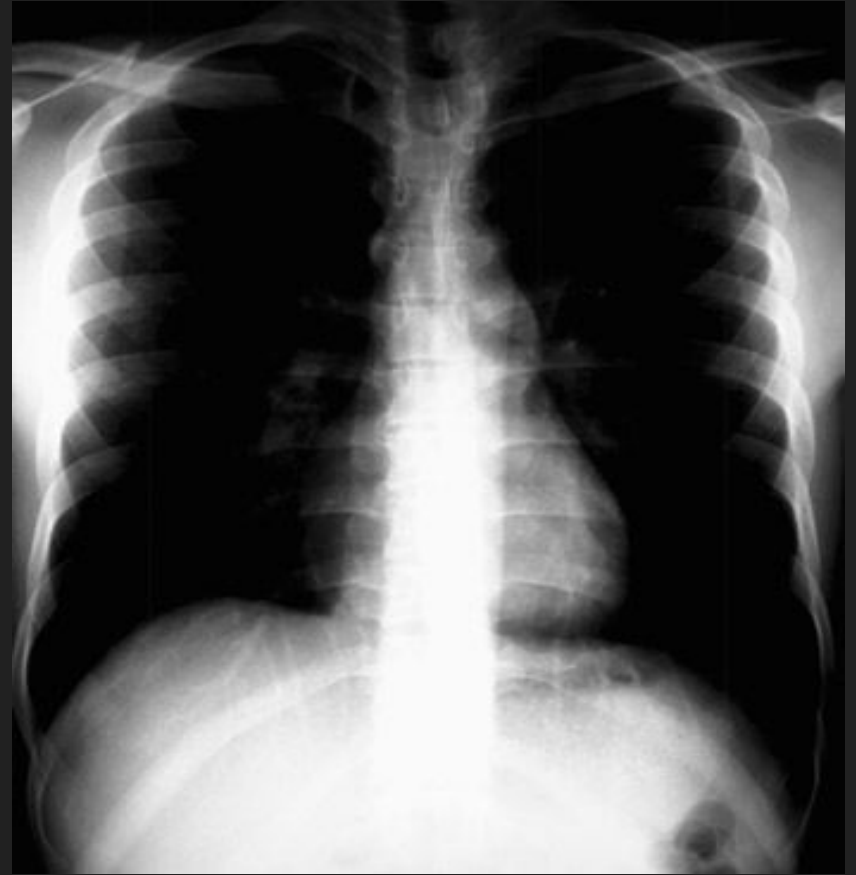
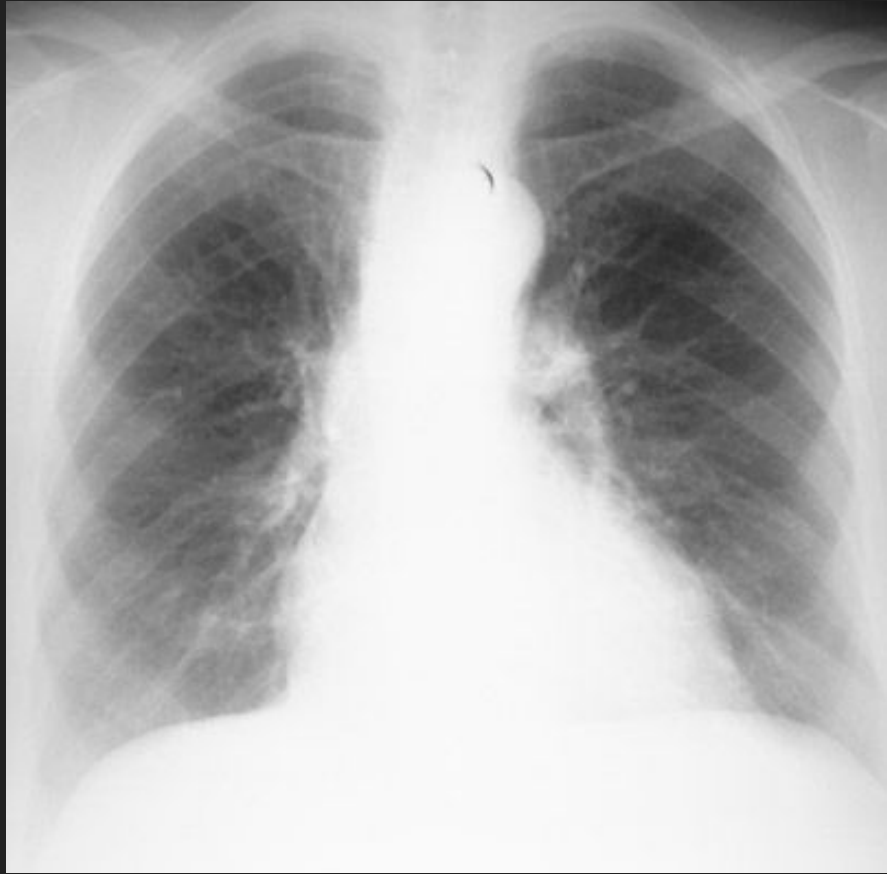


Technically adequate Penetration

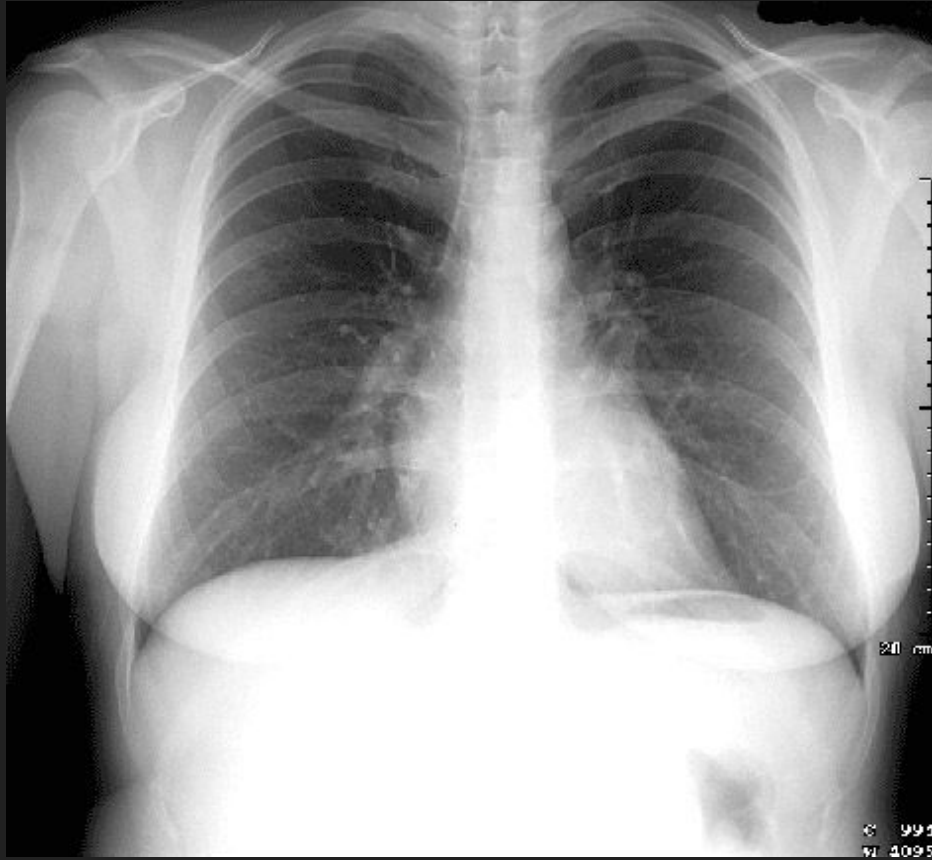


Technically adequate Penetration

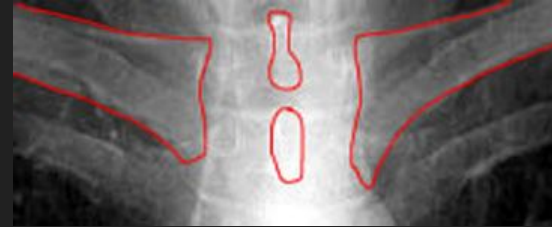
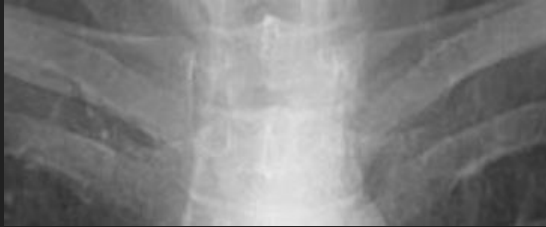


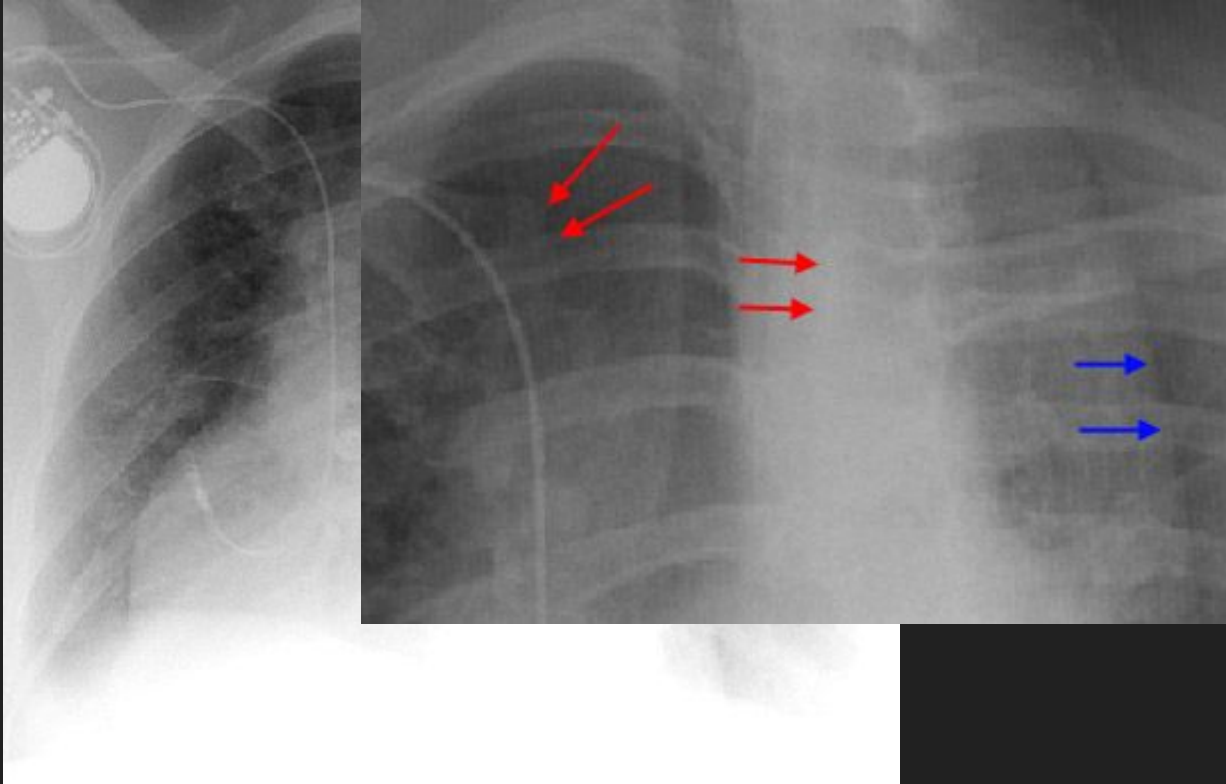
Technically adequate Rotation



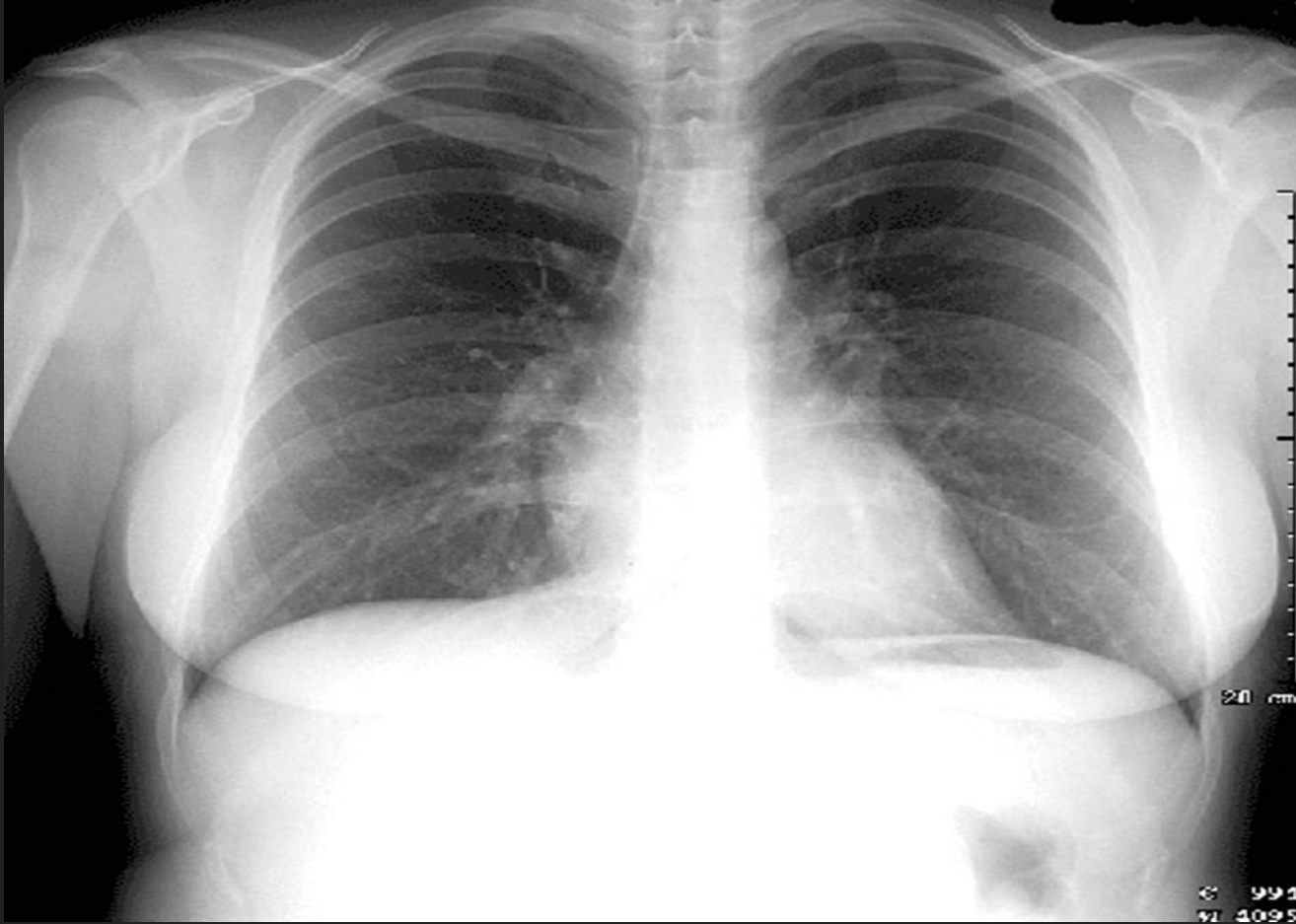
Technically adequate Rotation

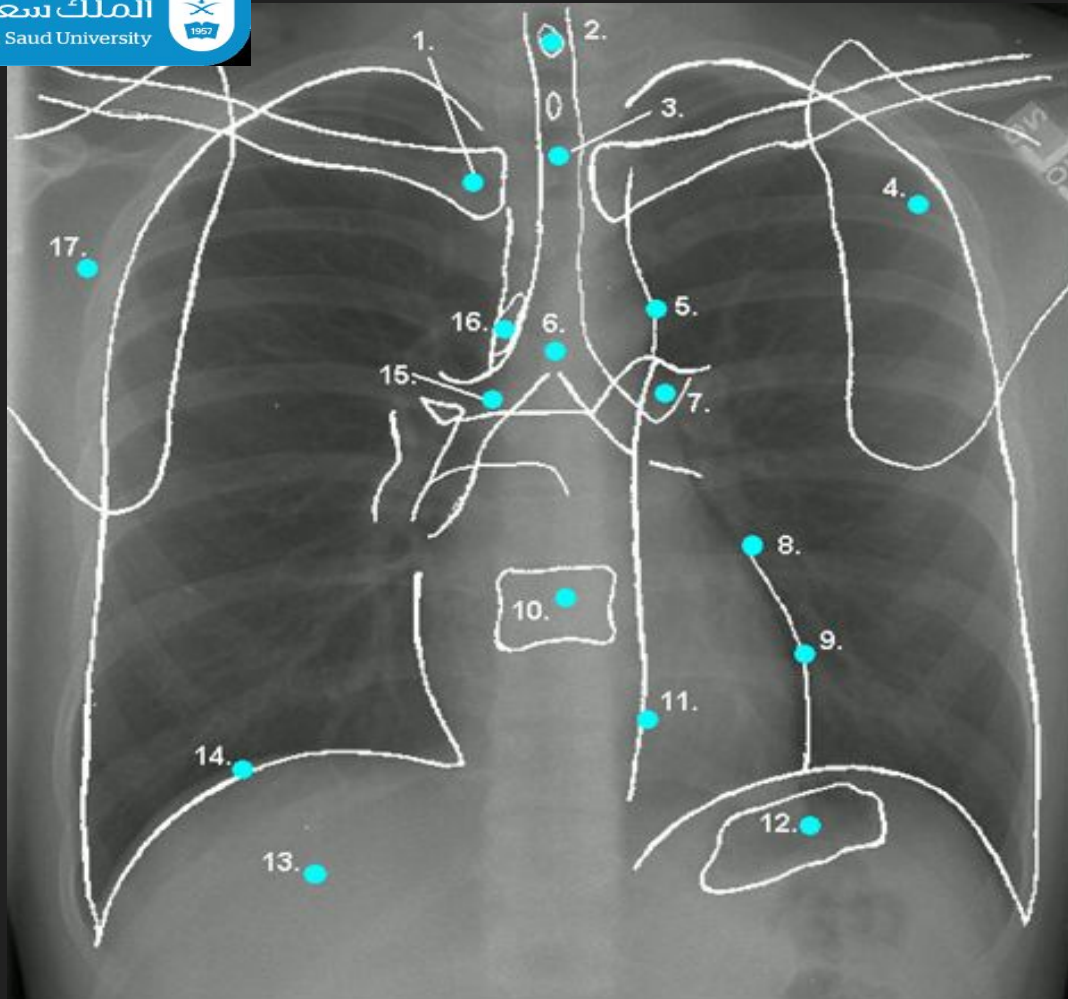


Technically adequate Rotation

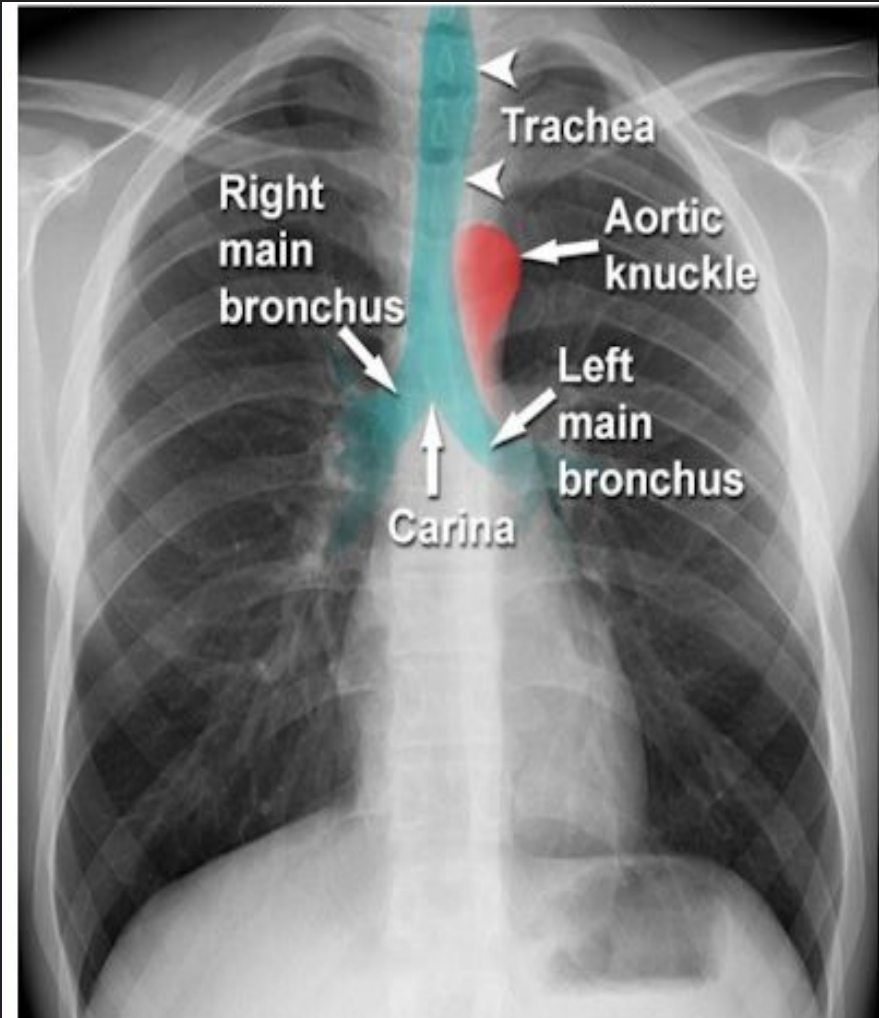
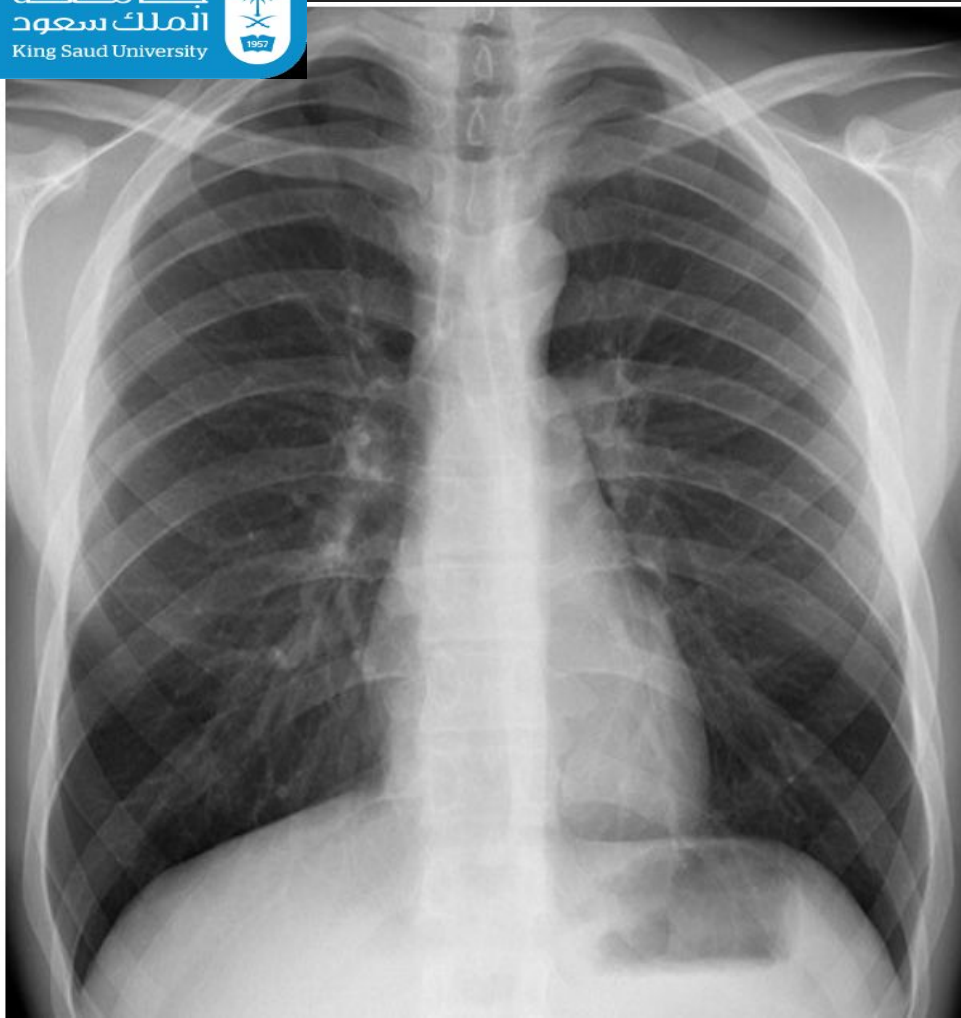


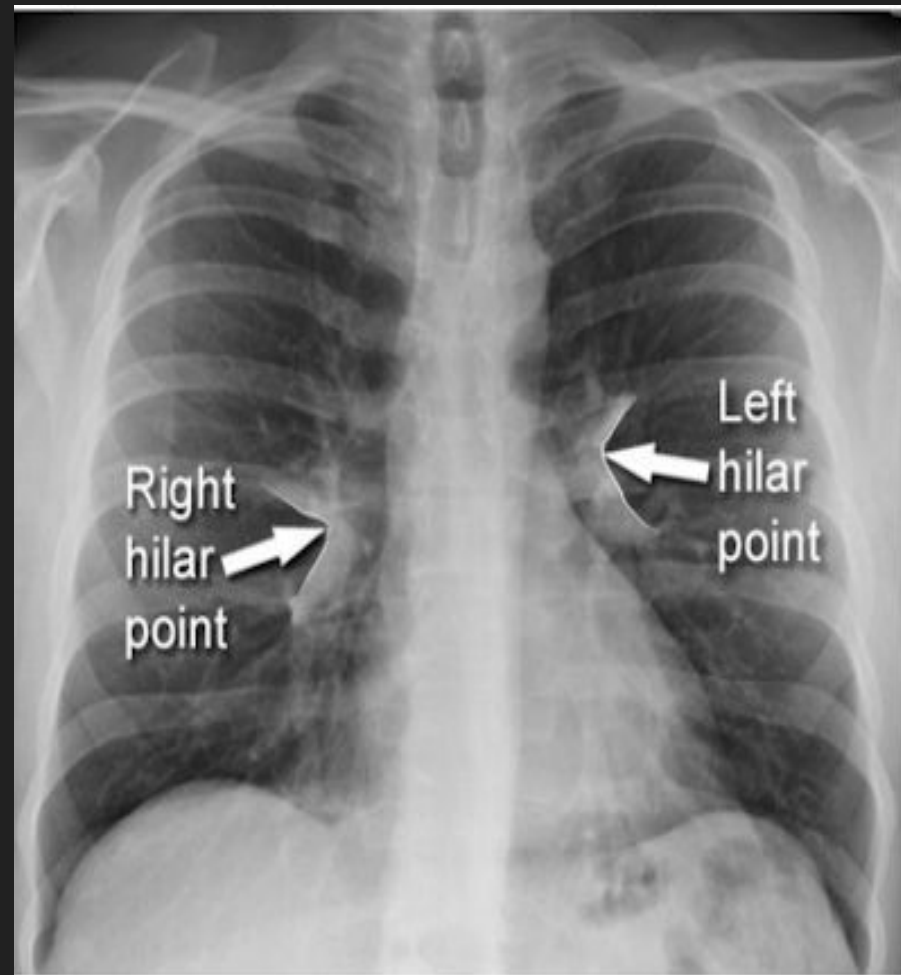
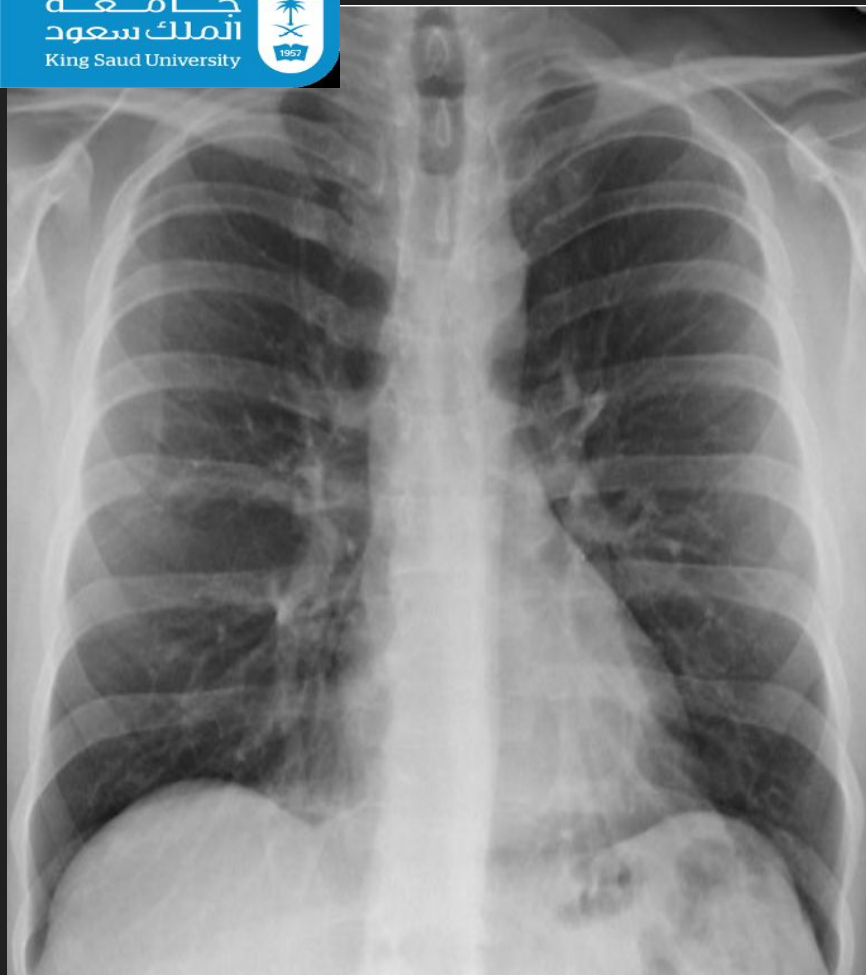
Anatomy

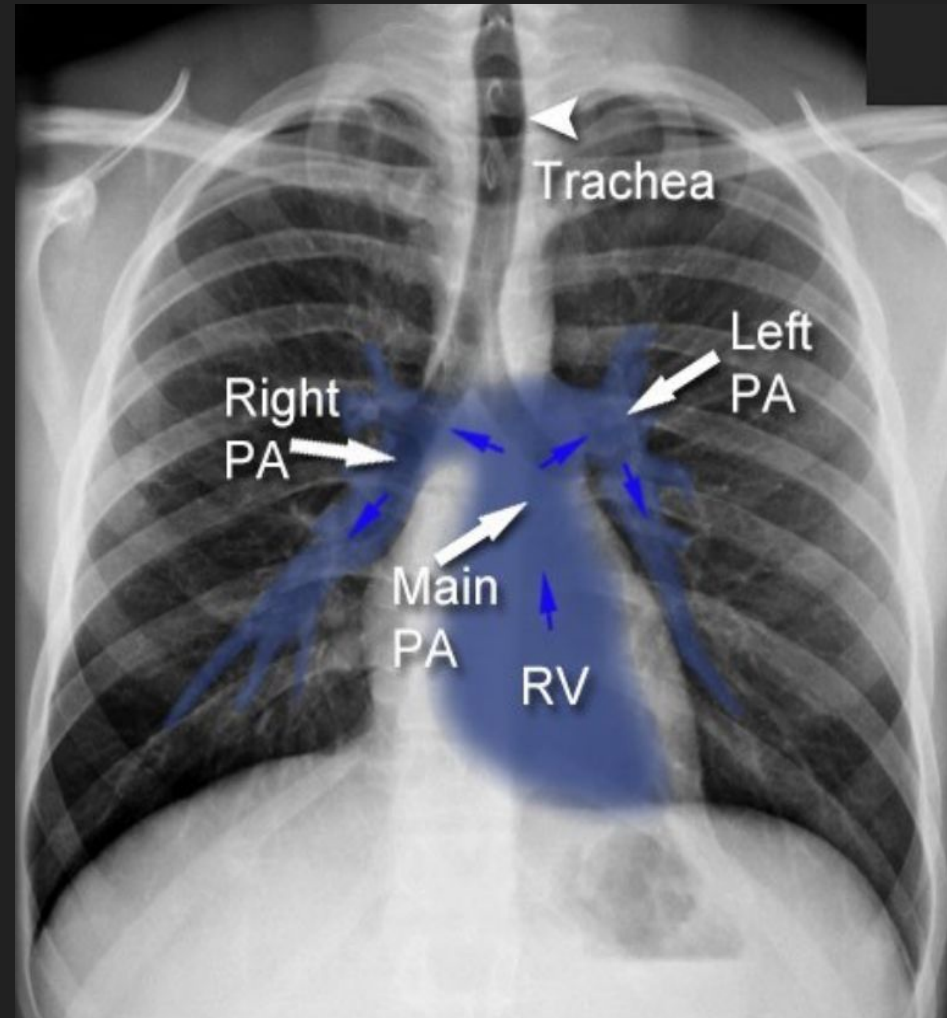
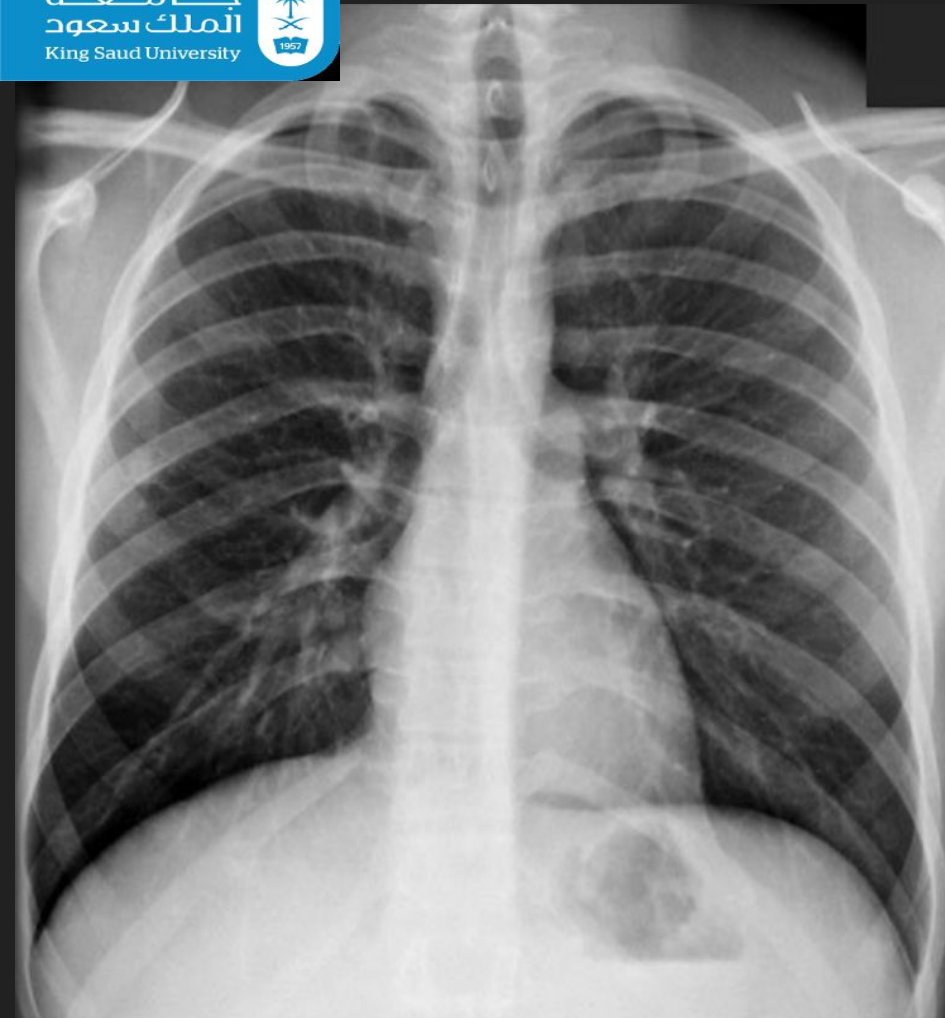


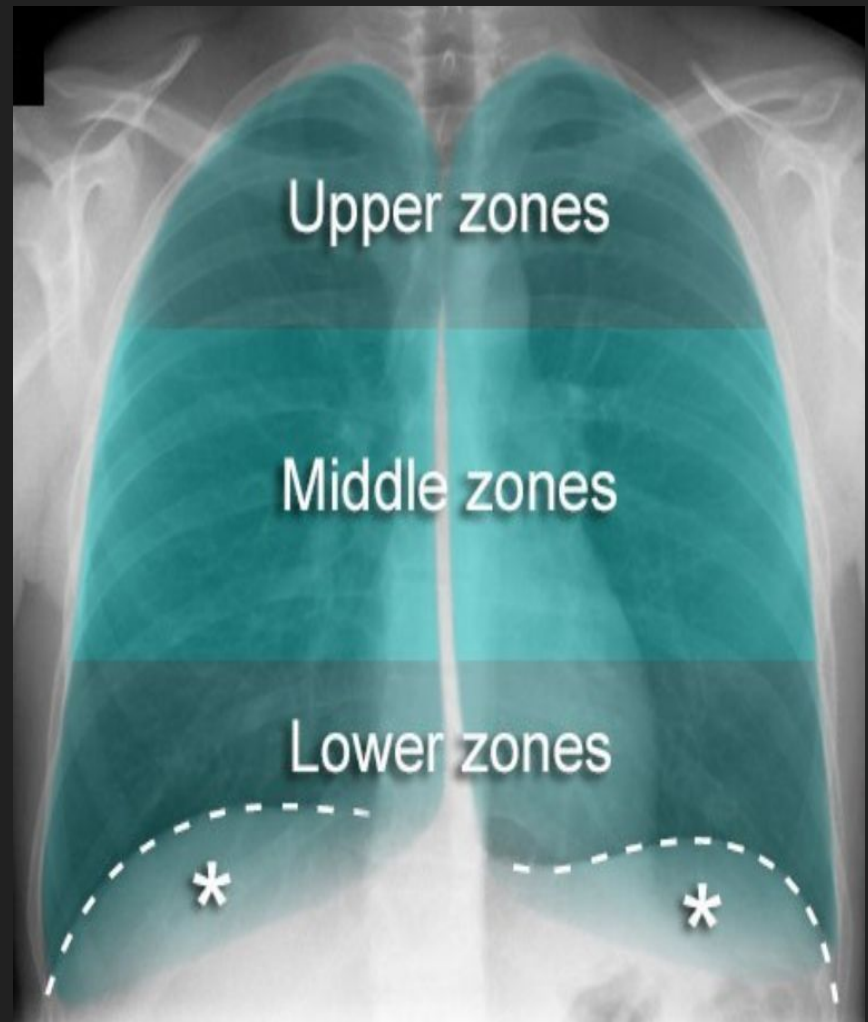
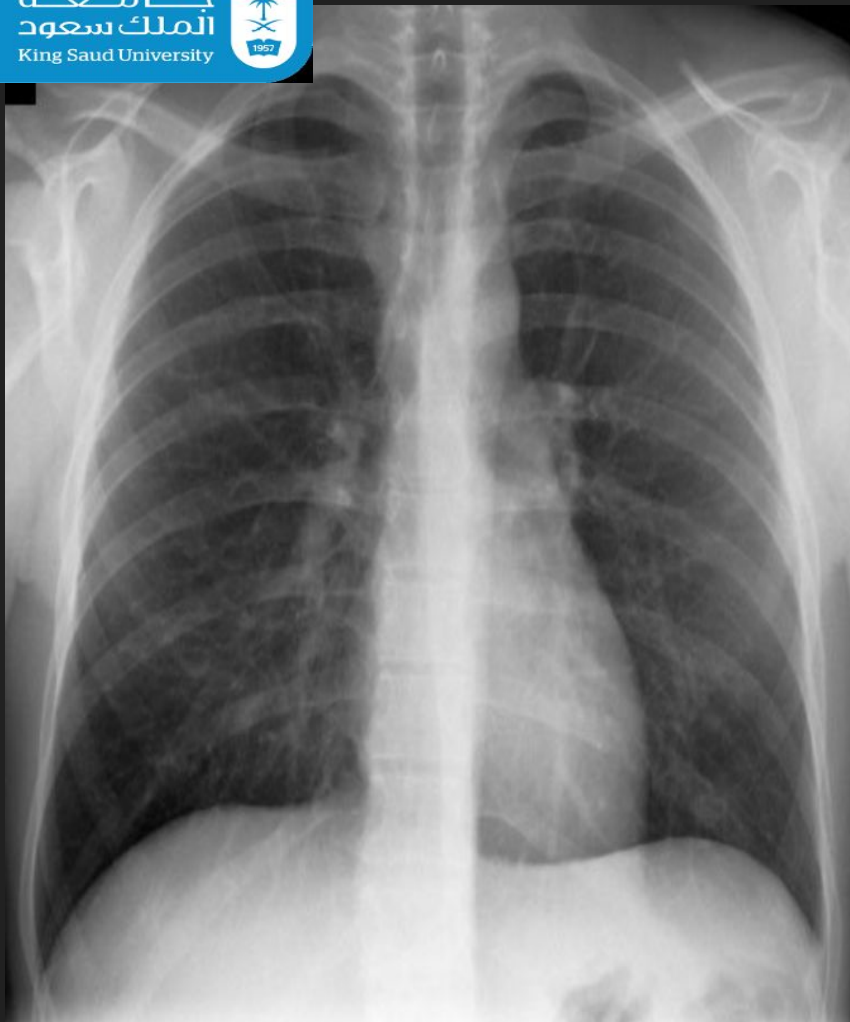

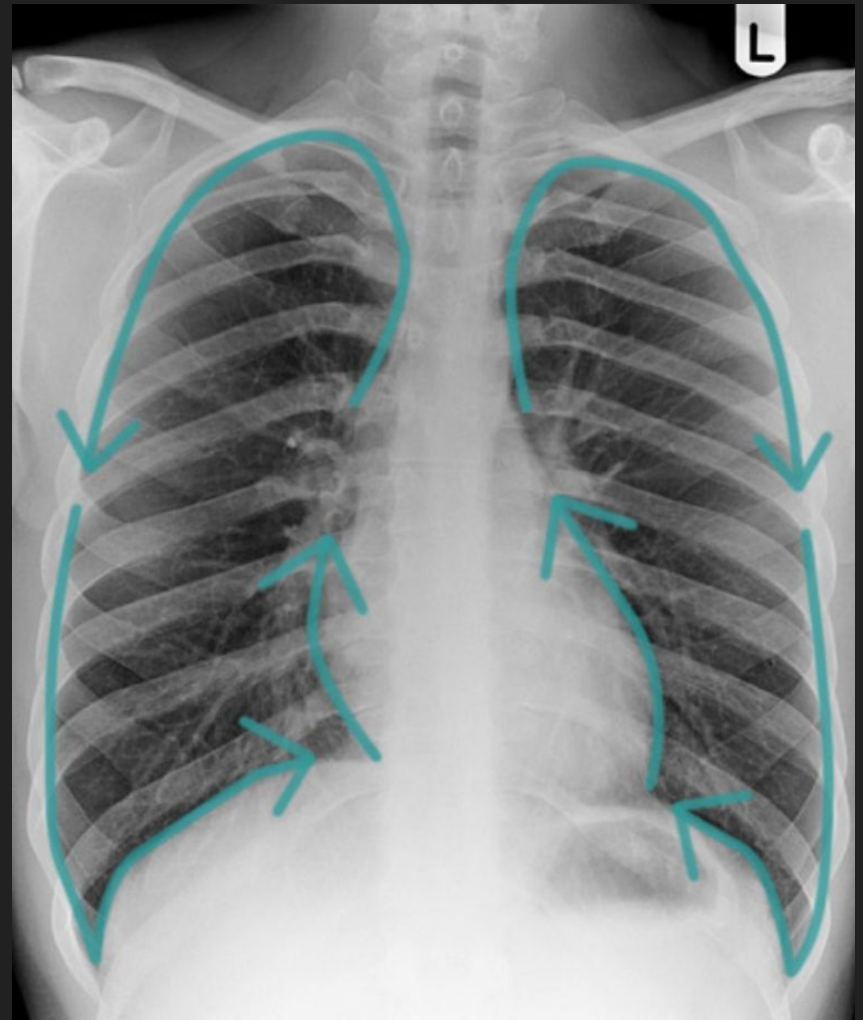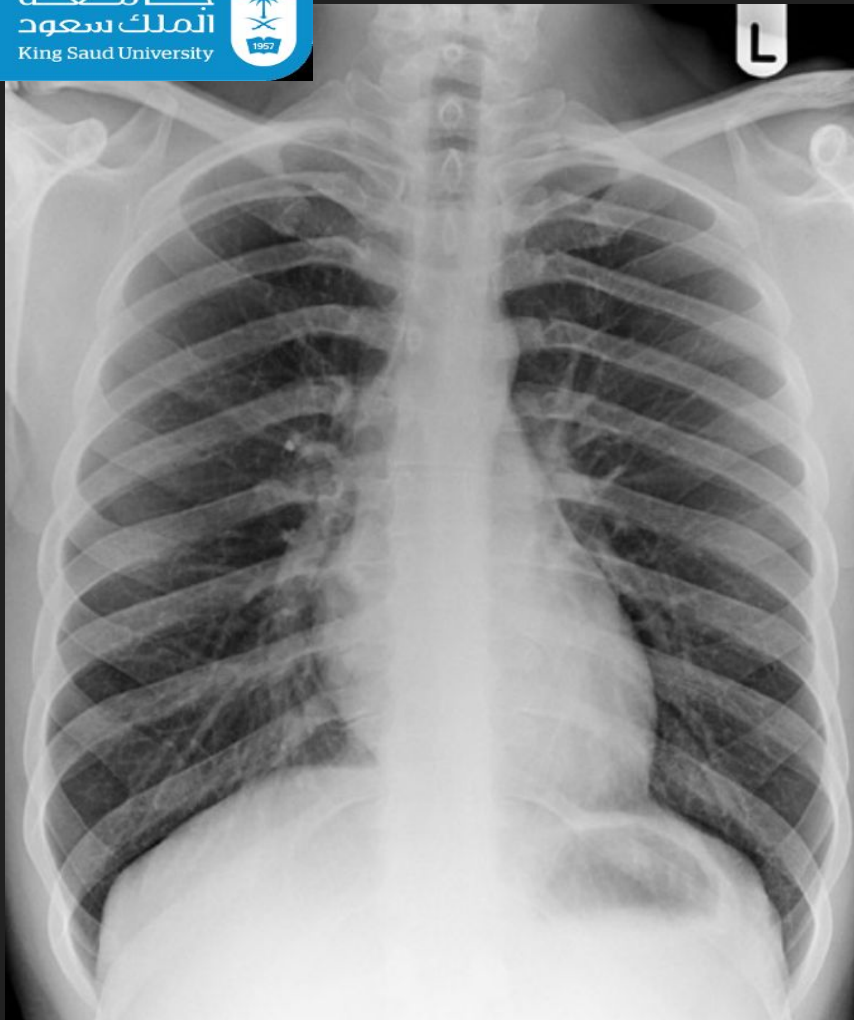- 1- Clavicle
- 2- Spinous process
- 3- Trachea
- 4- Scapula
- 5- Aortic arch
- 6- Carina (bifurcation)
- 7- Pulmonary trunk
- 8- Lt. cardiac border (atria)
- 9- Lt. cardiac border (ventricle)
- 10- Vertebral body
- 11- Descending Aorta
- 12- Gastric fundus
- 13- Liver
- 14- Rt. Hemi-diaphragm
- 15- Rt. Main bronchus
- 16- Azygos vein
- 17- Scapula



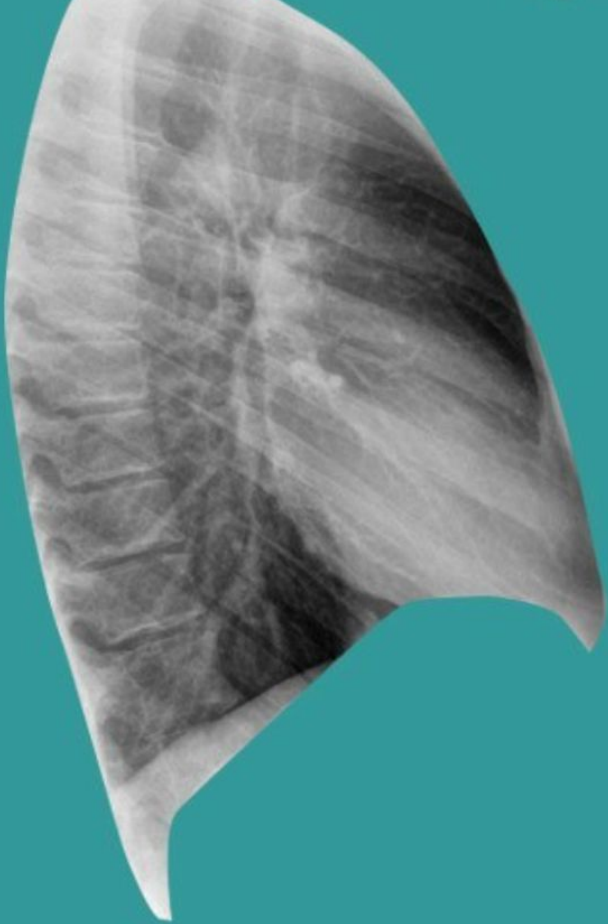



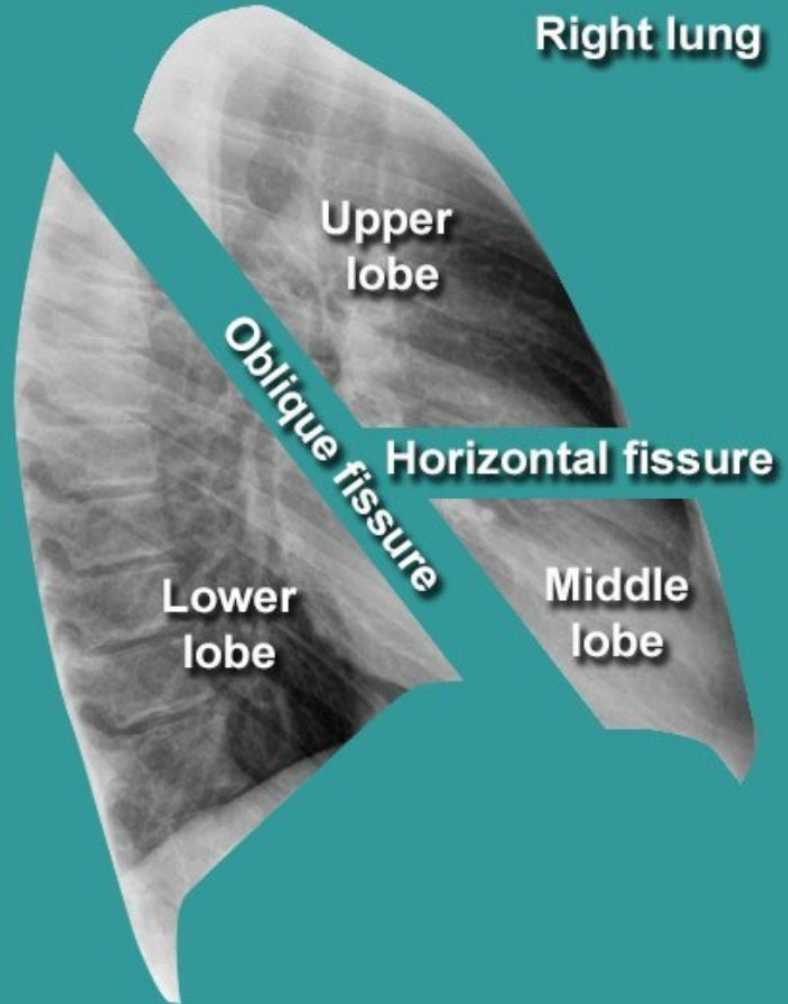




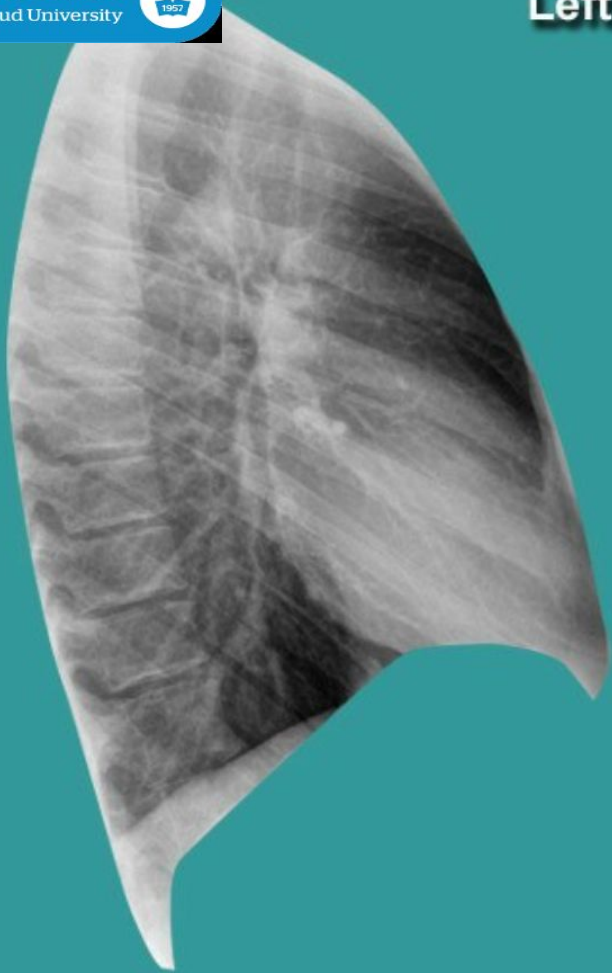
Right lung



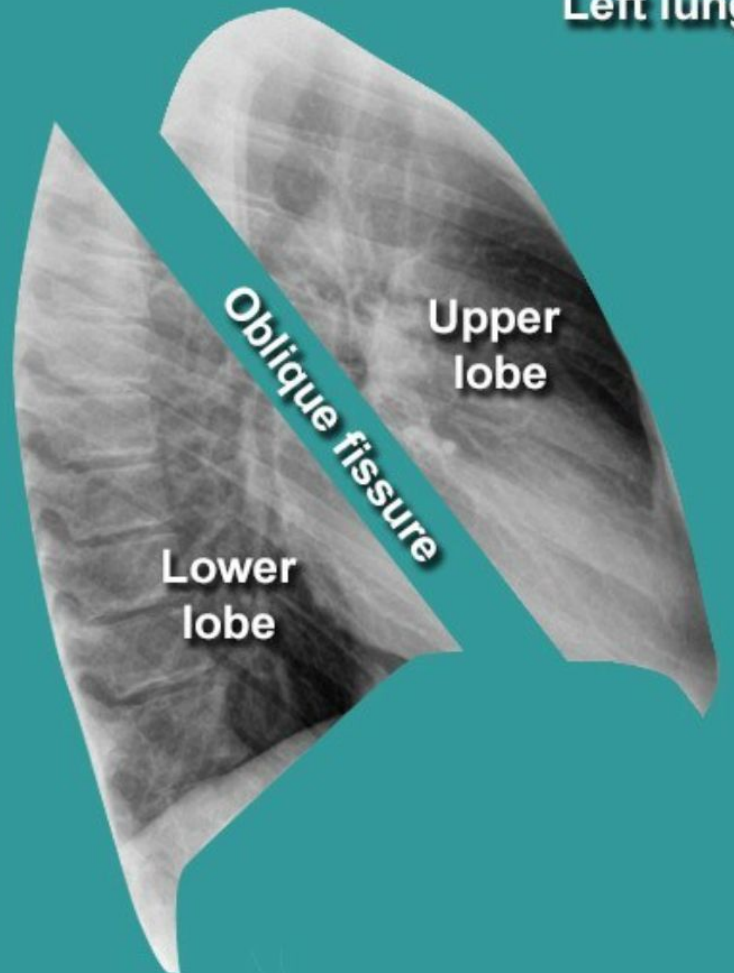
Right lung

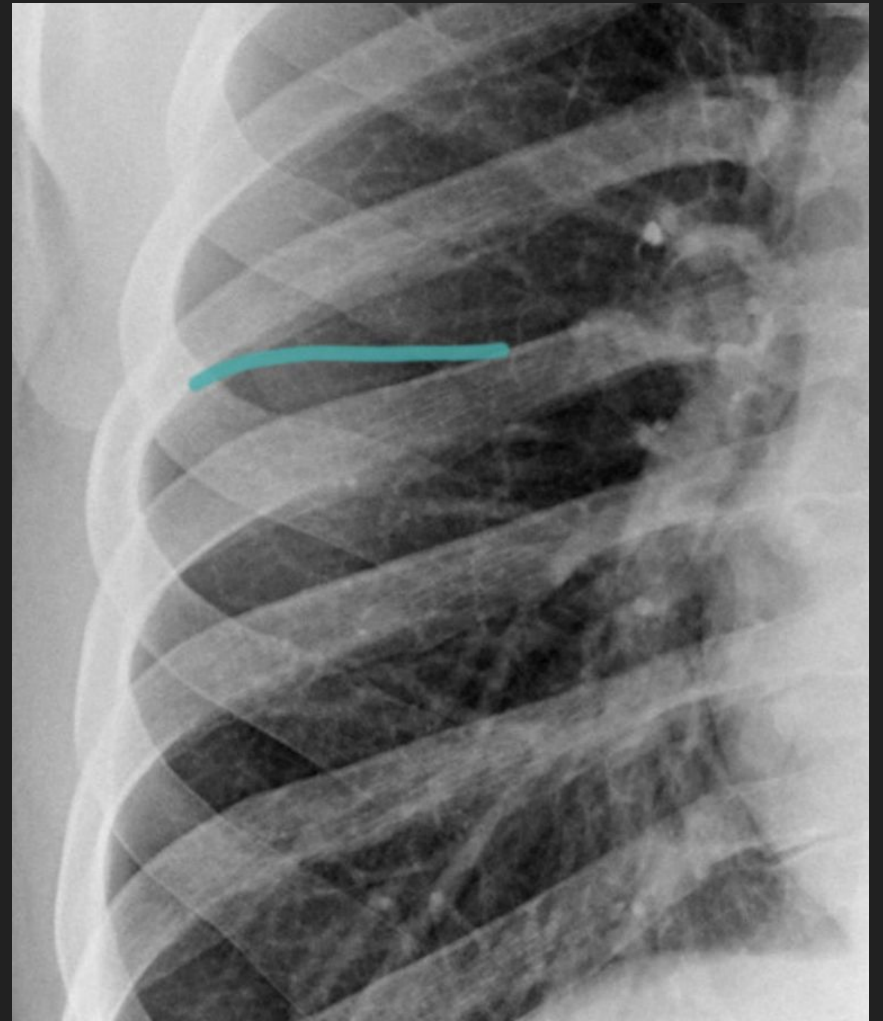
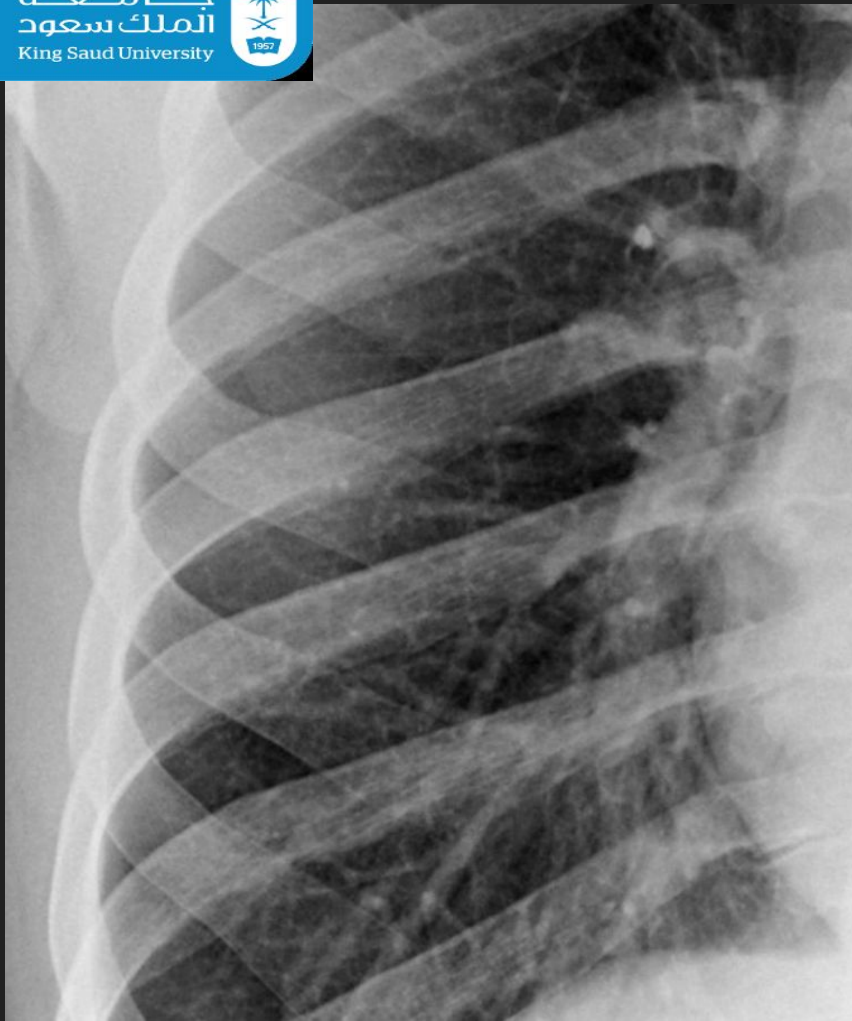

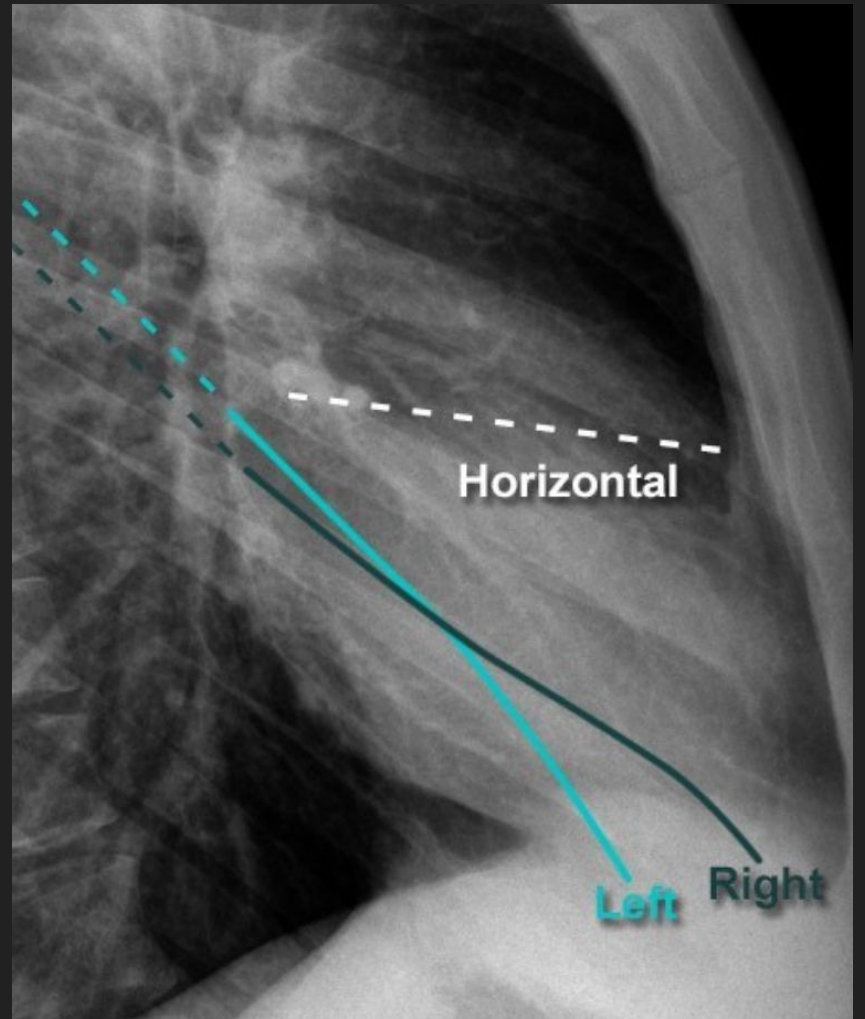
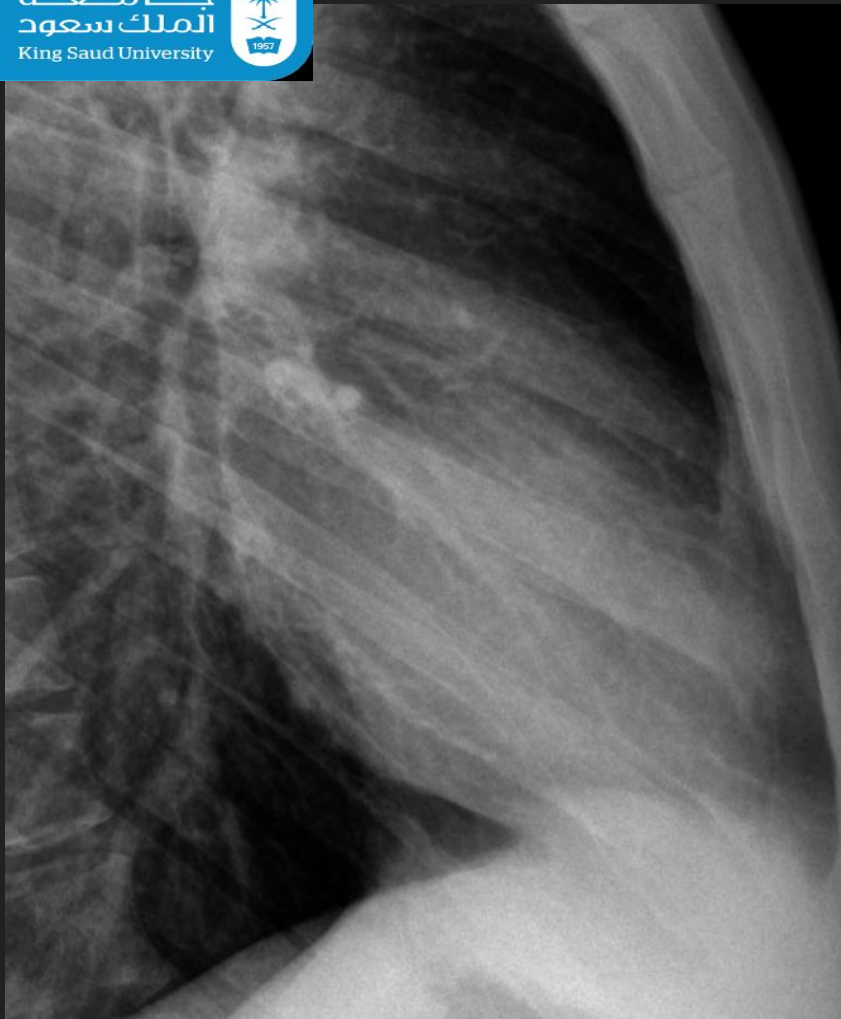
Left lung

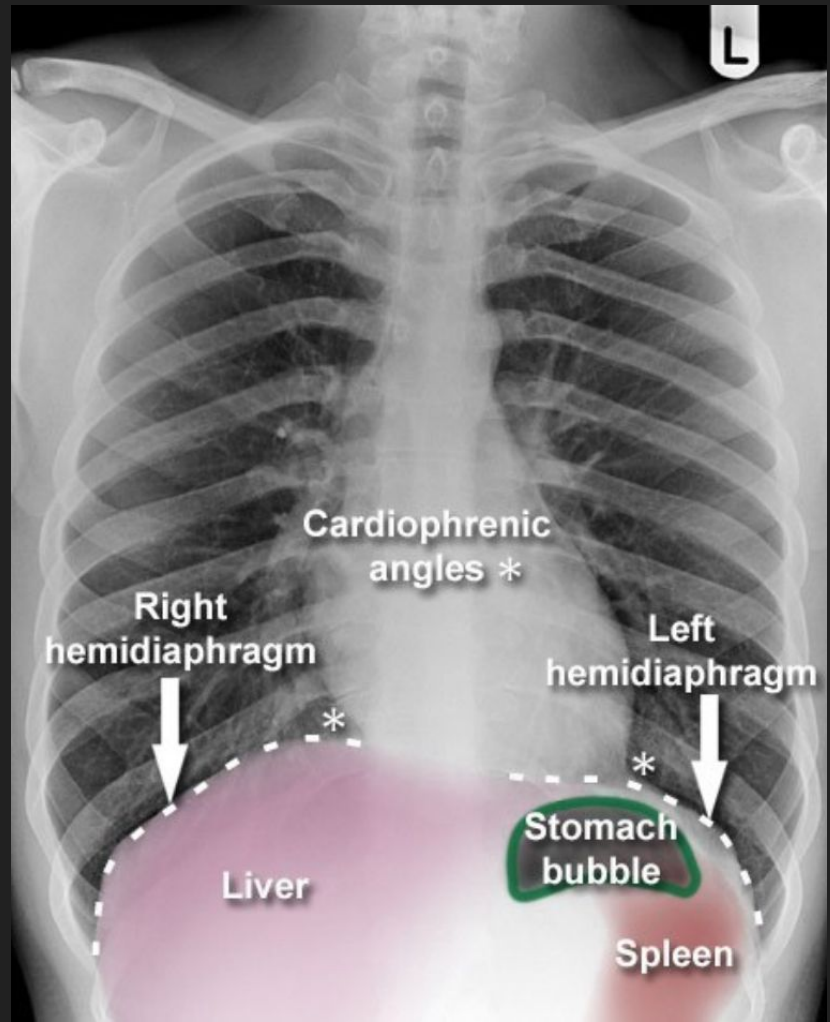
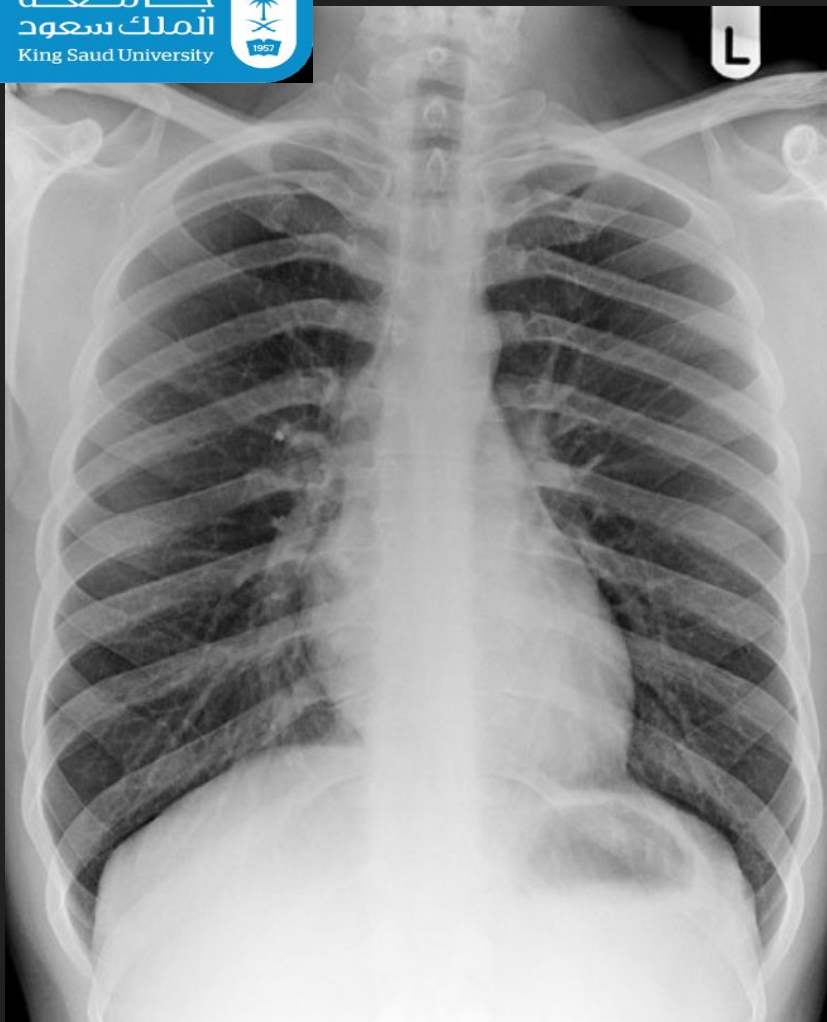

Left lung

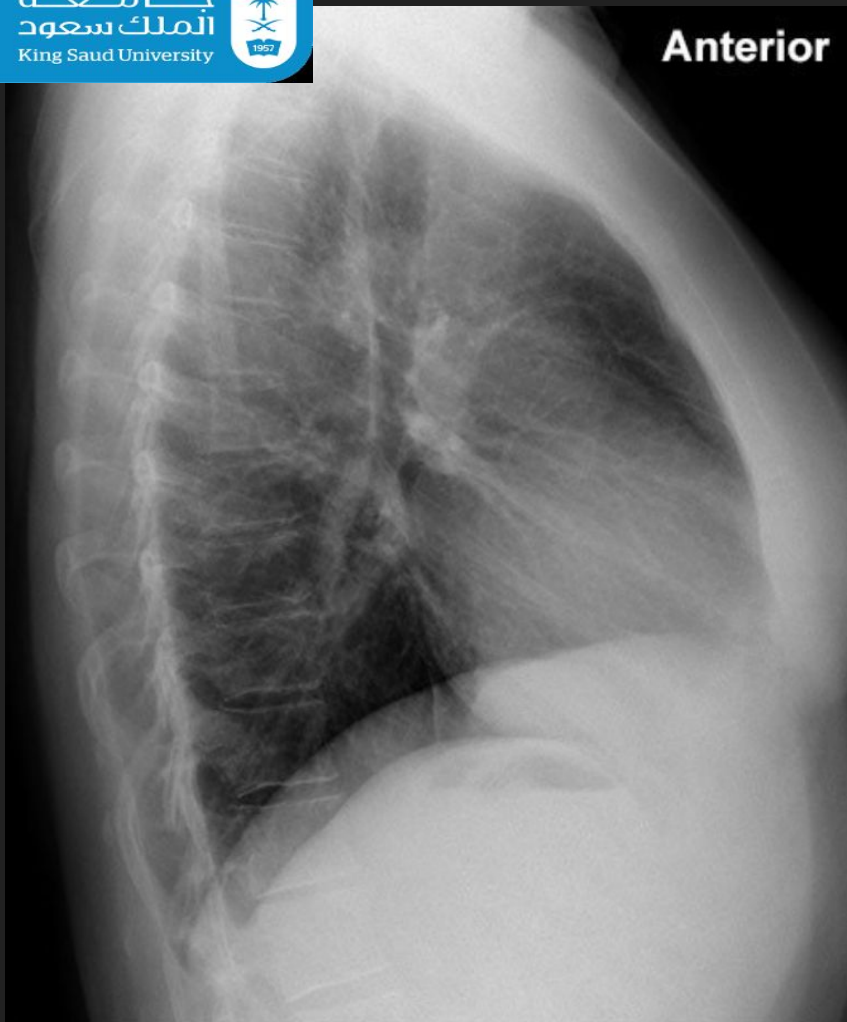




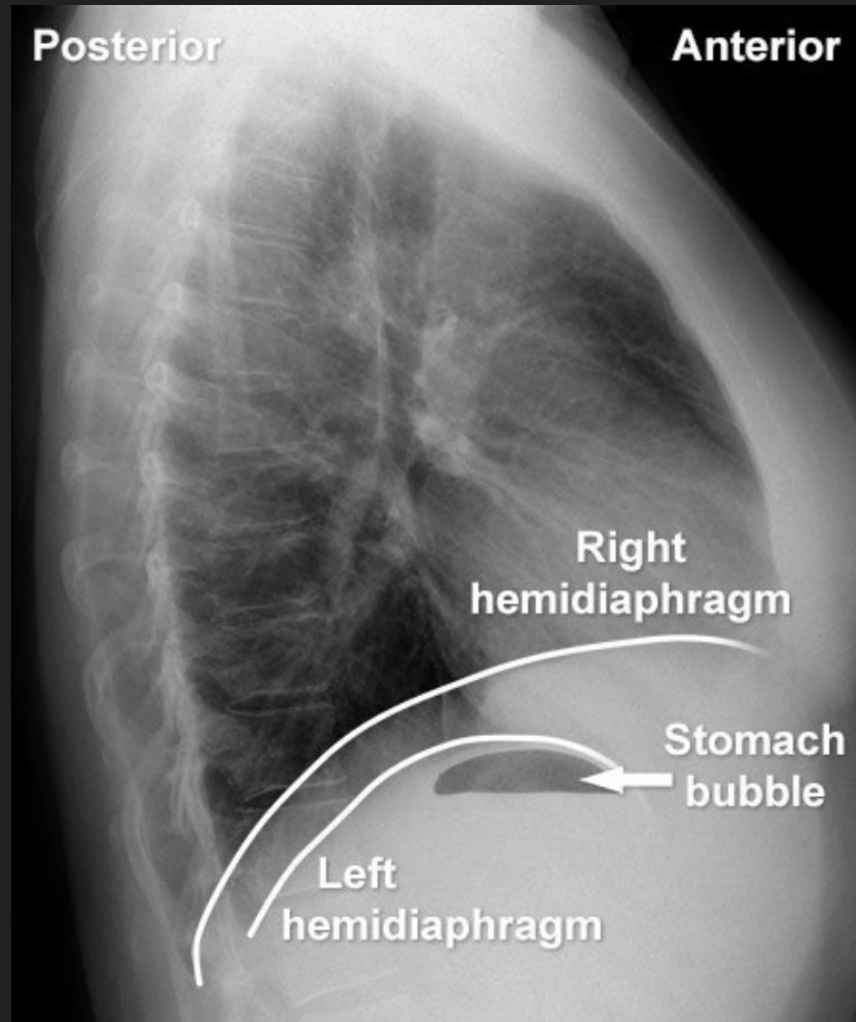




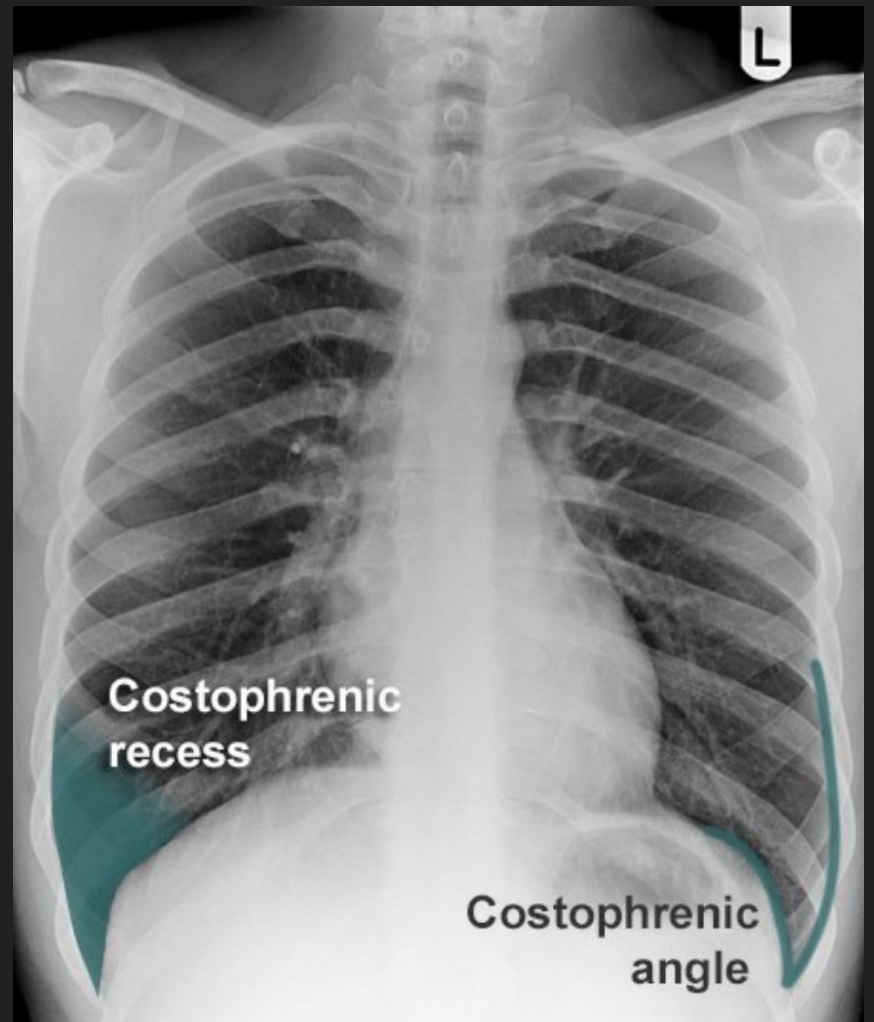
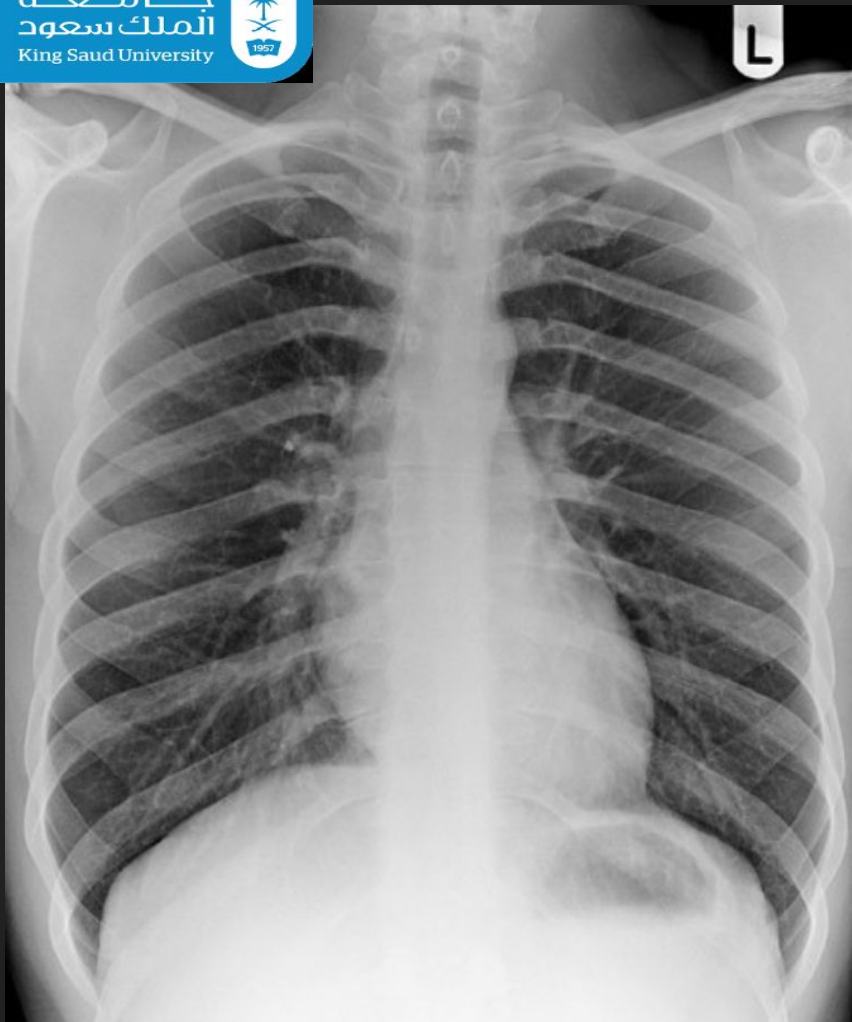Anterior

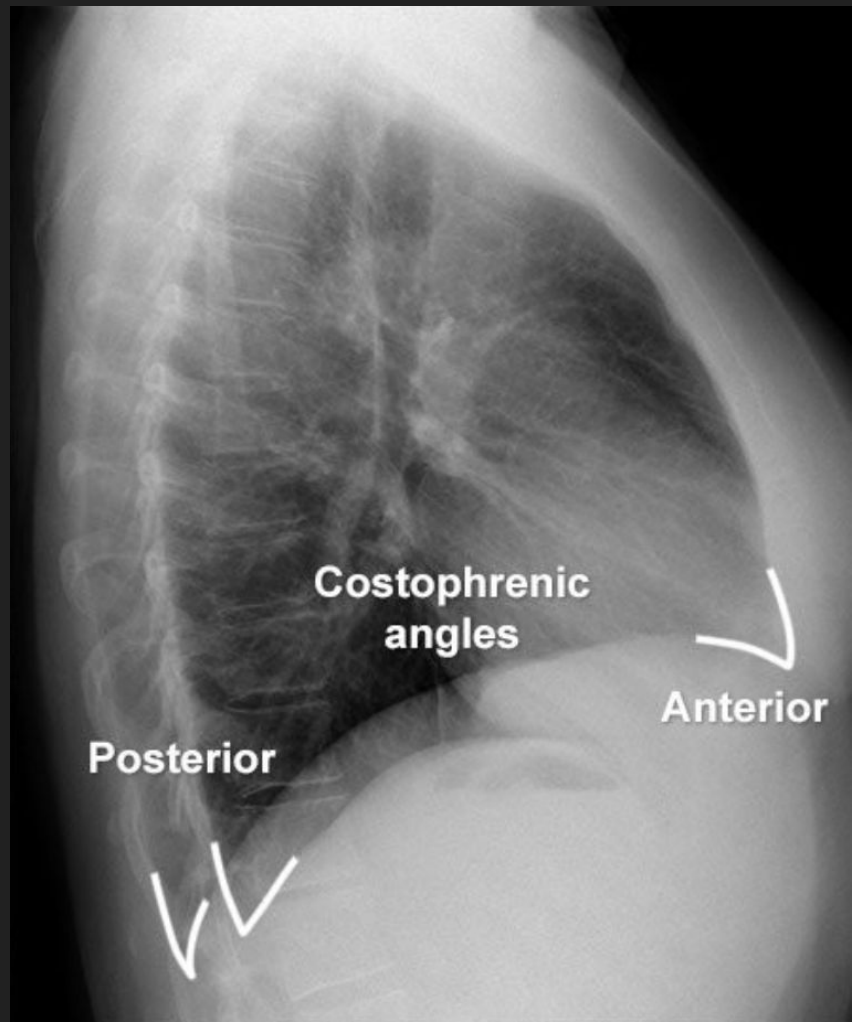
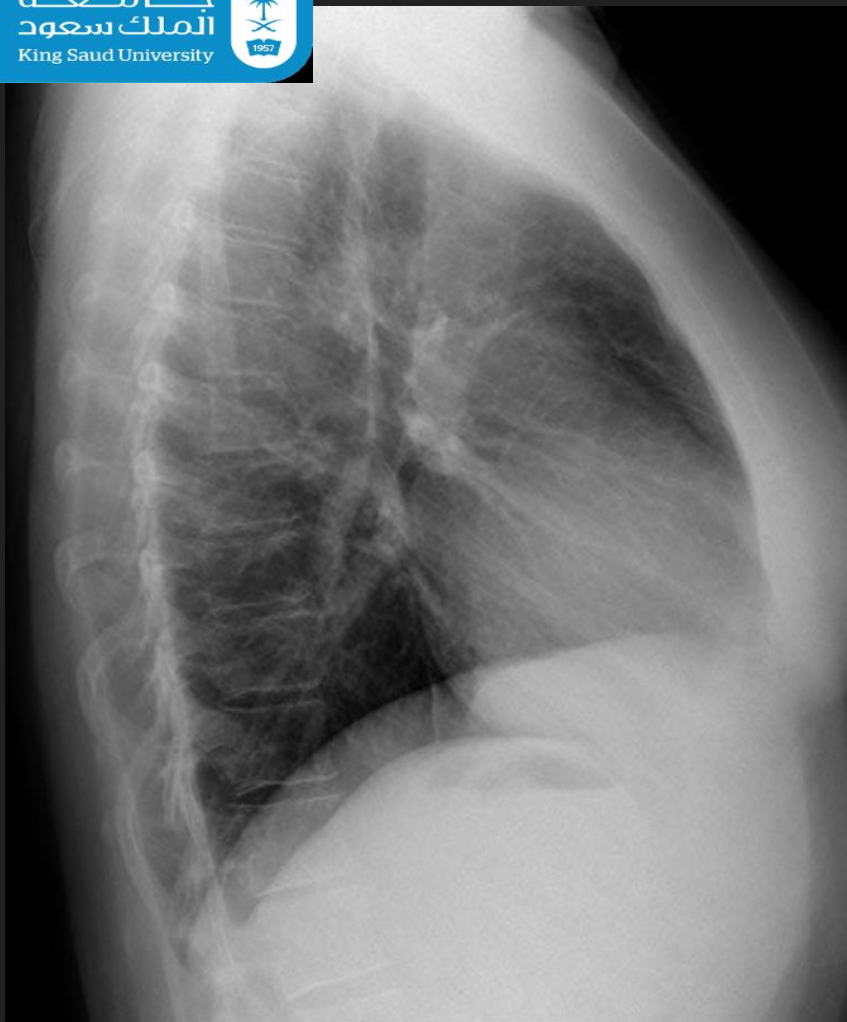


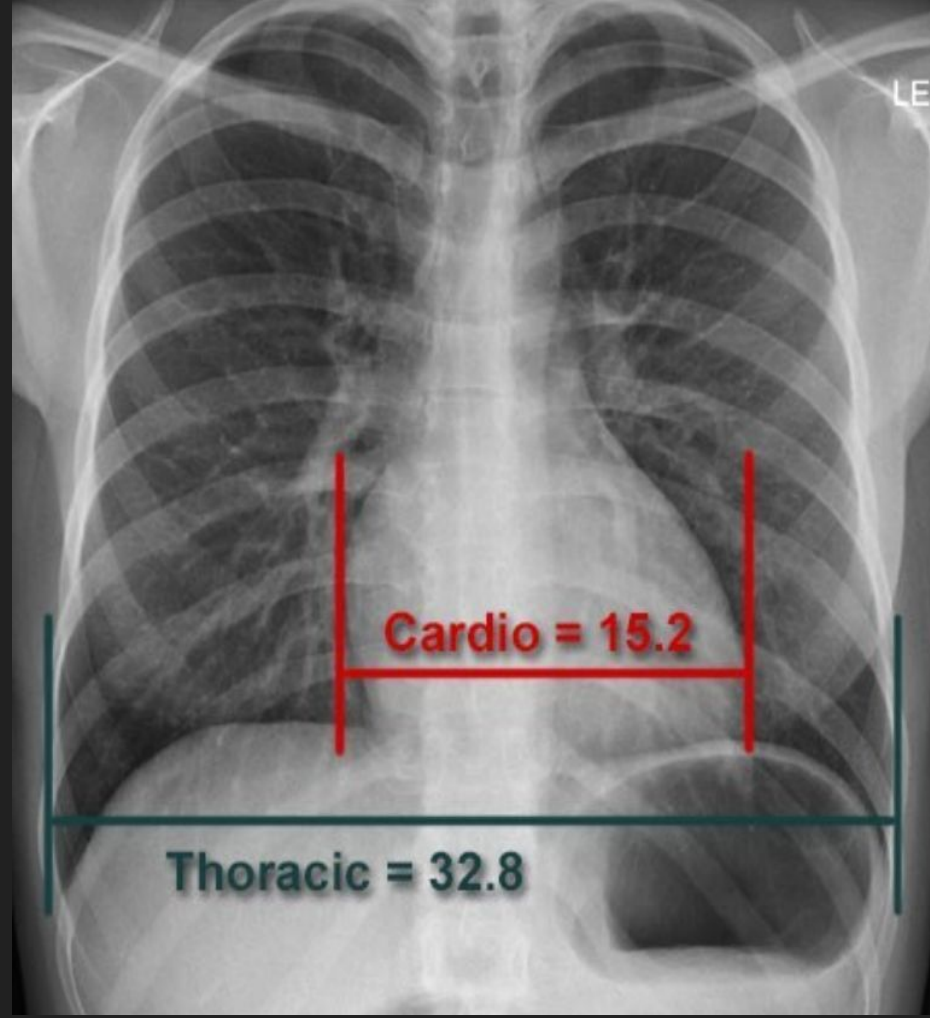
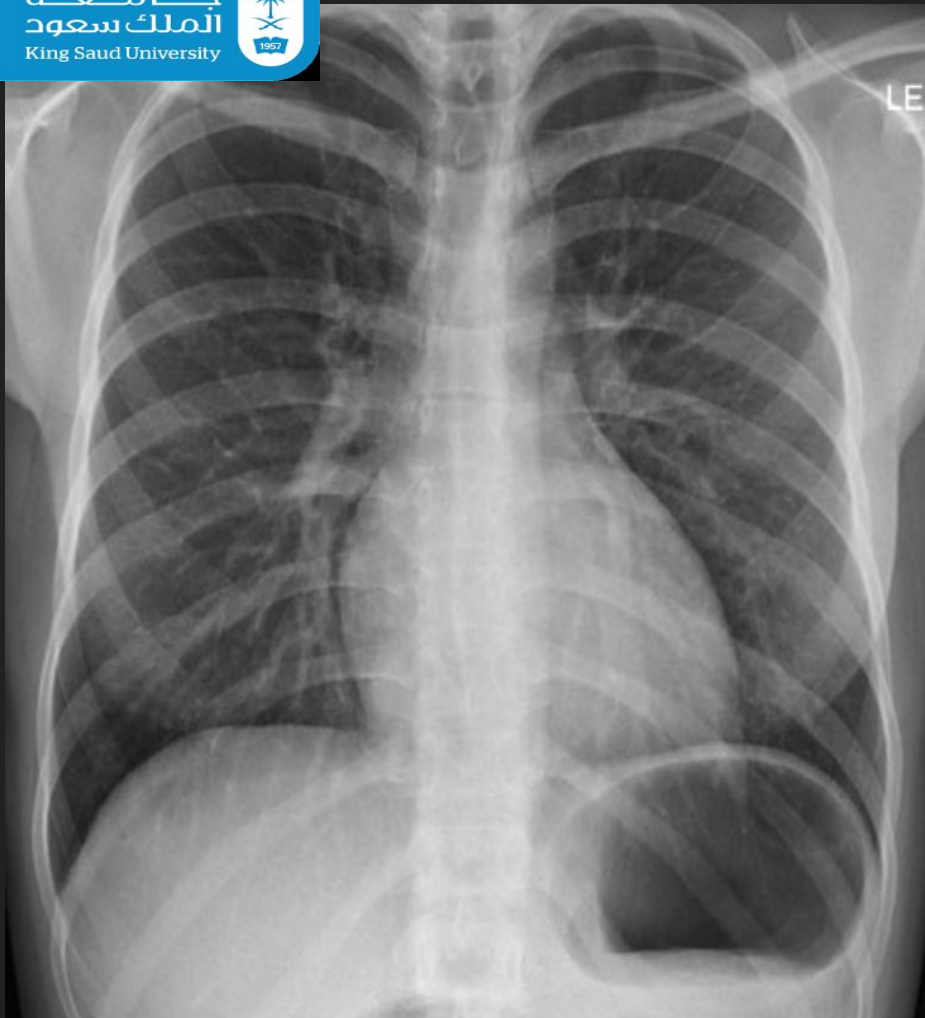
Posterior

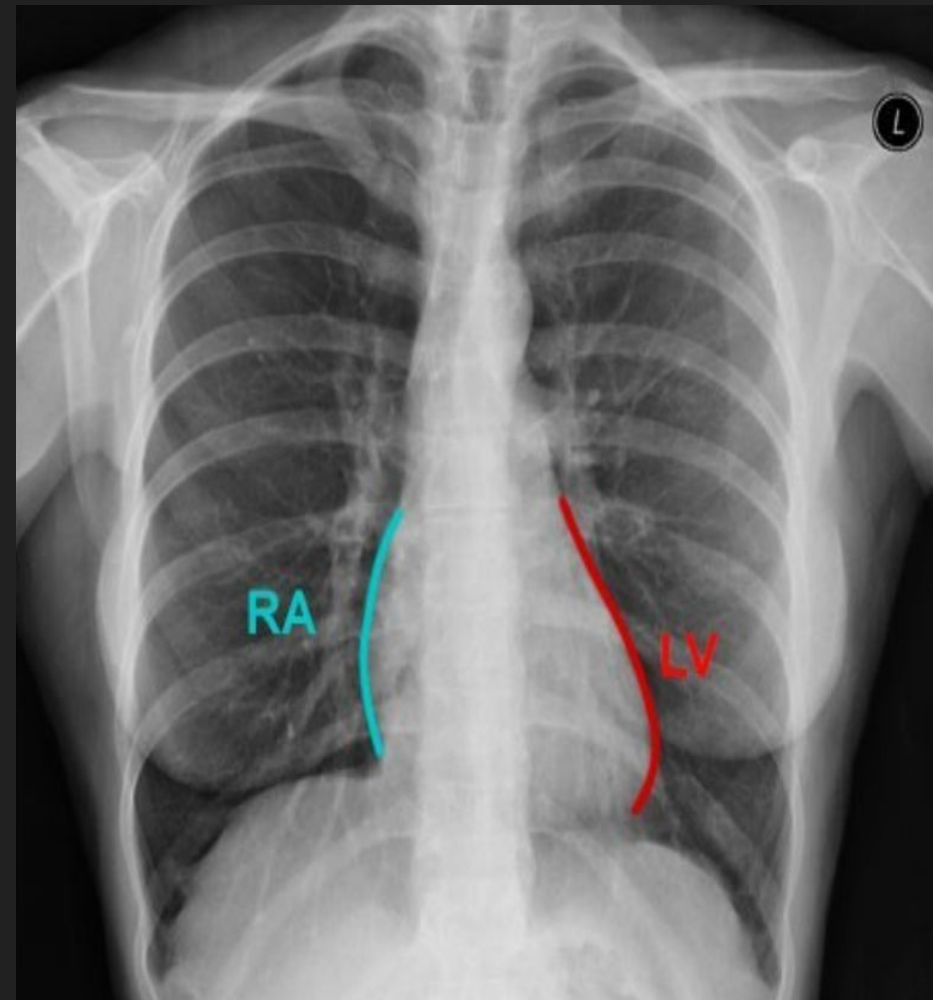
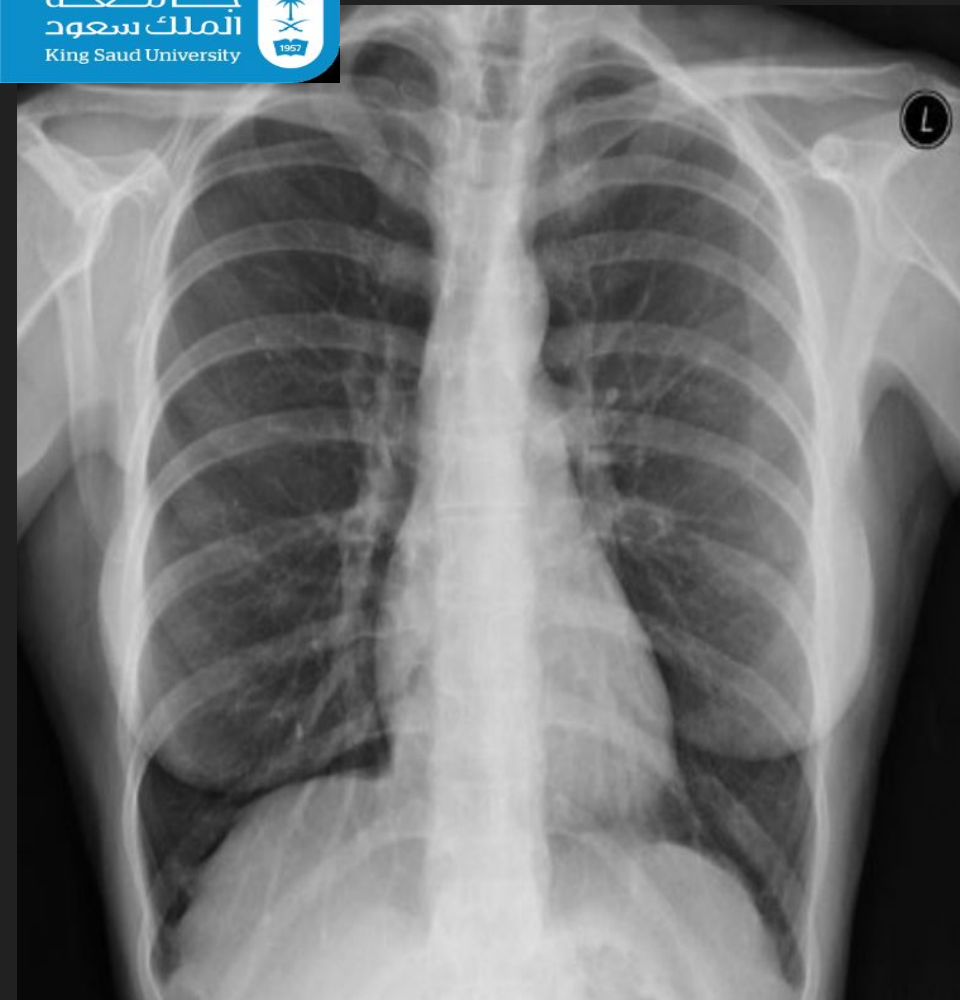


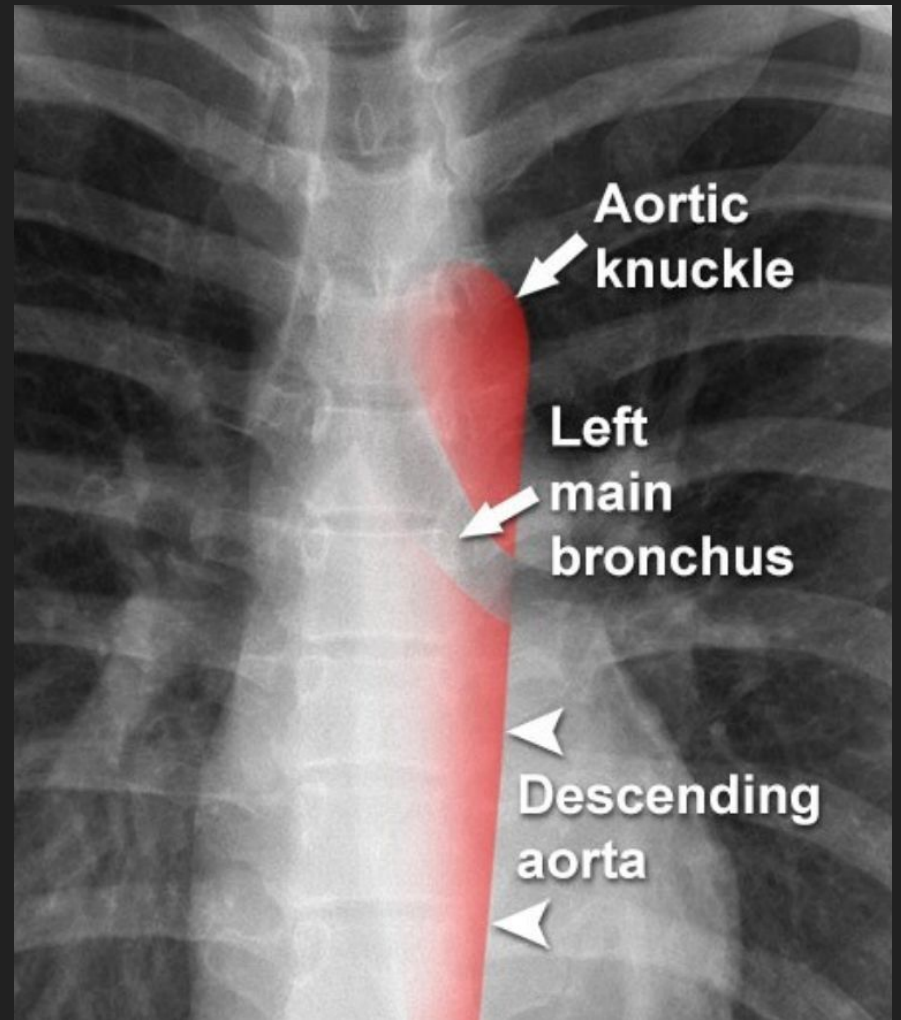
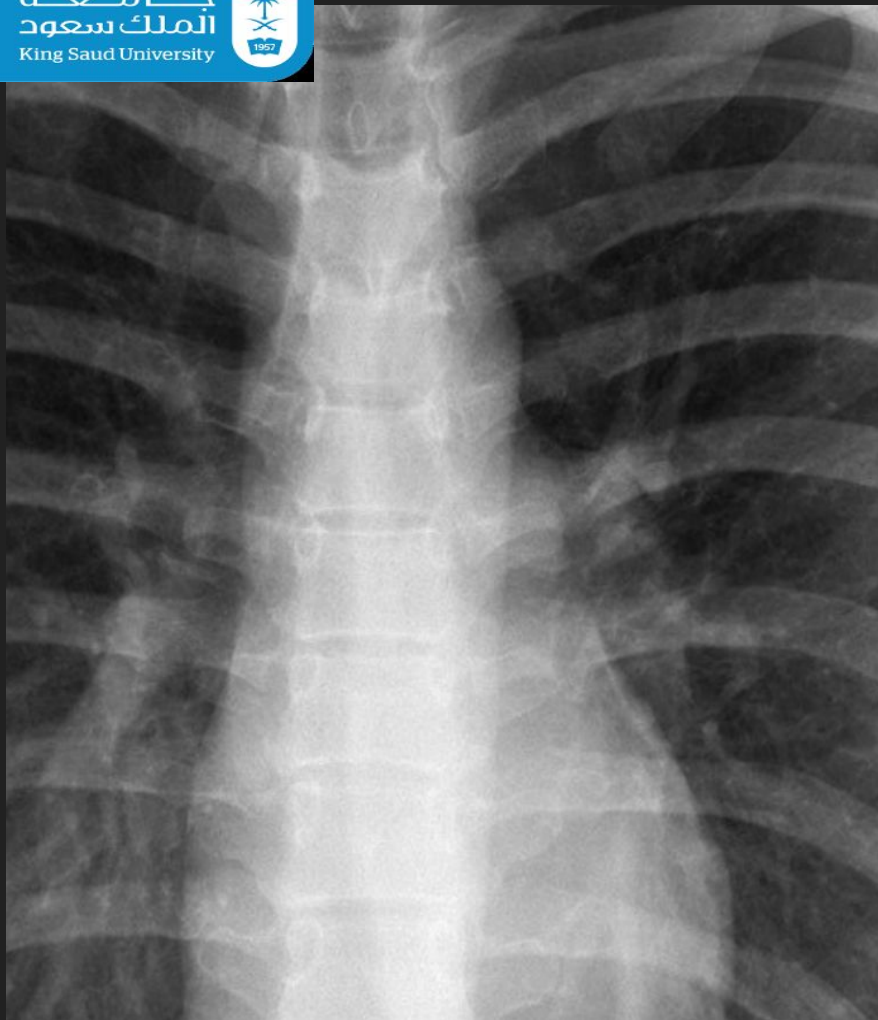
Anterior

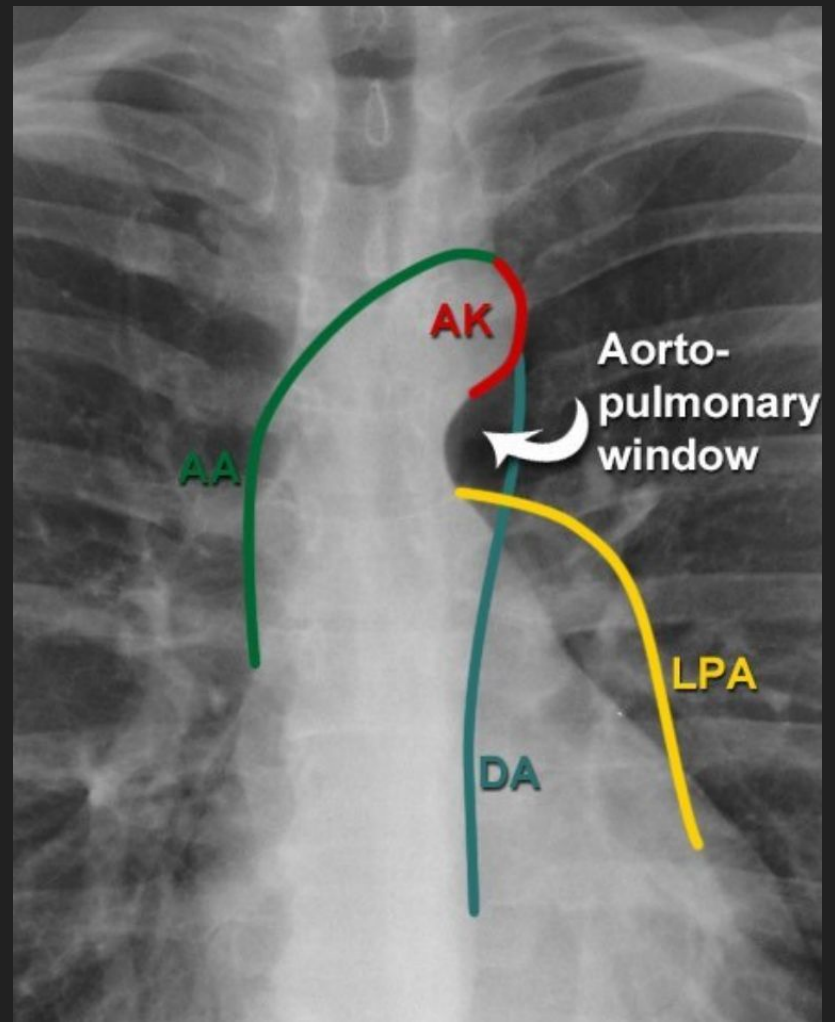
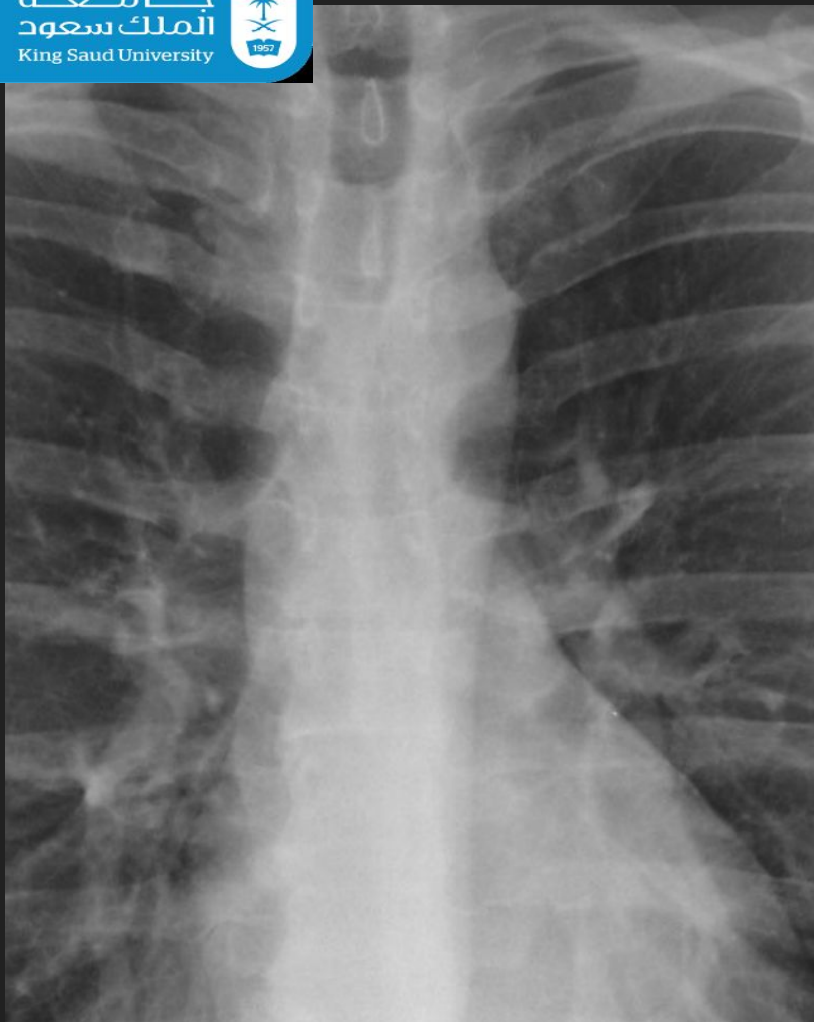

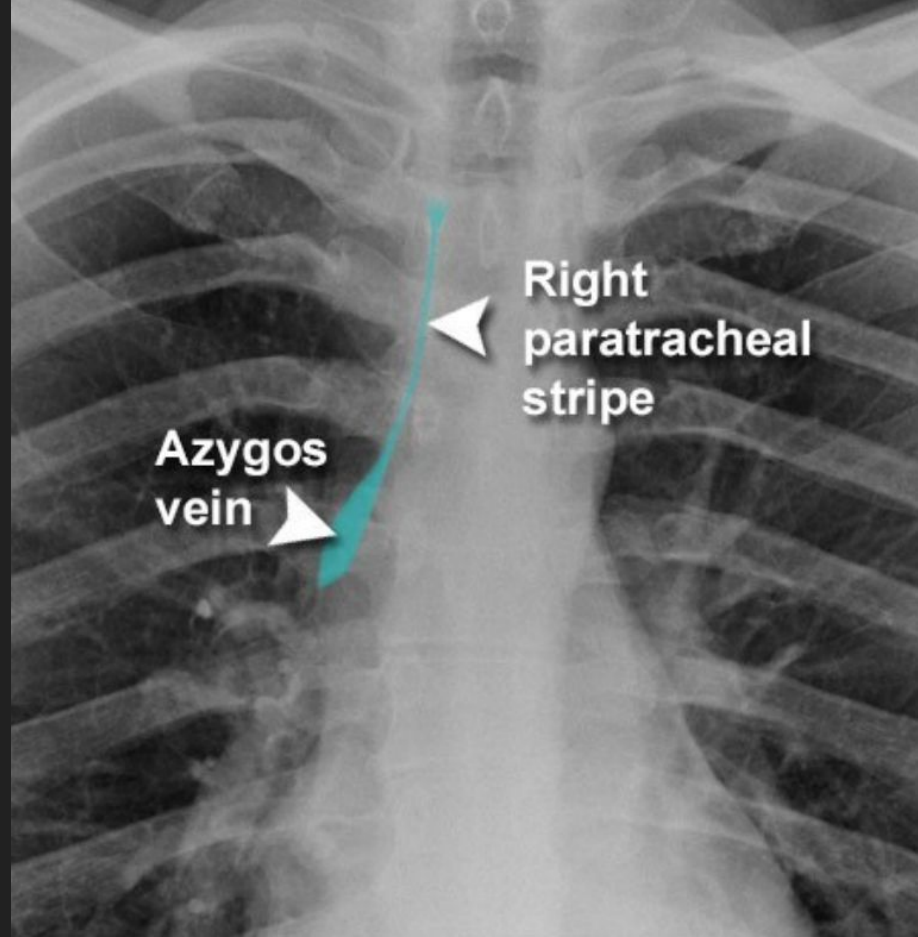

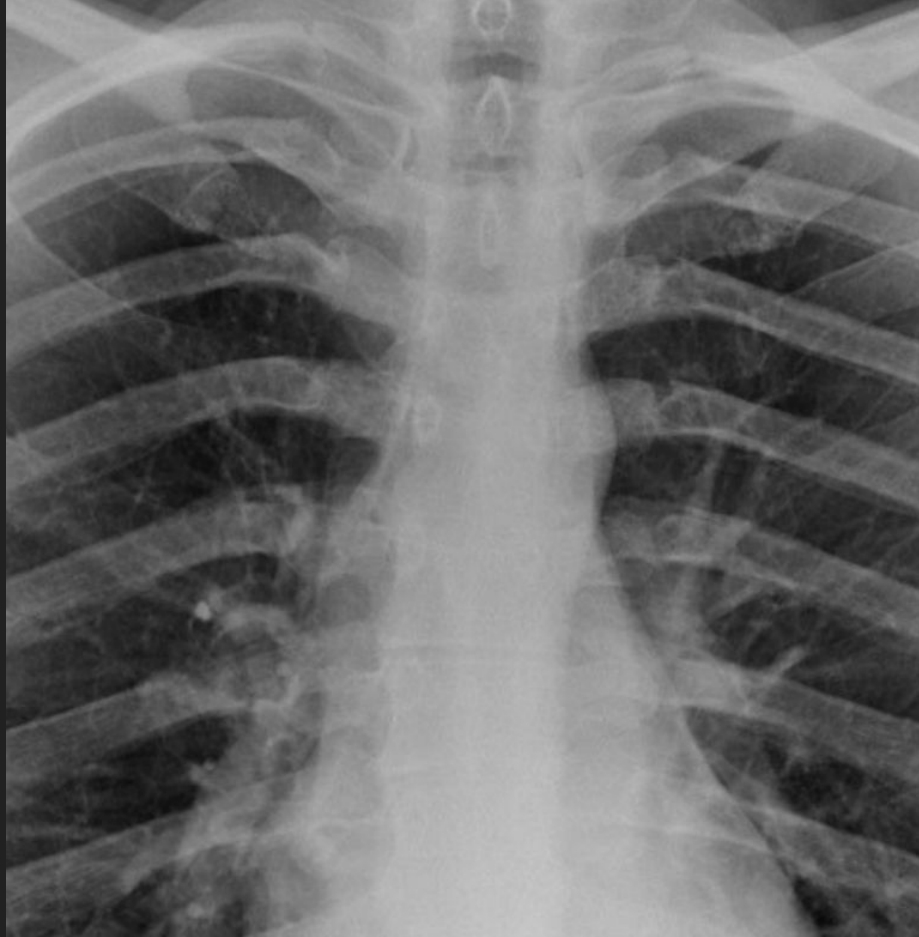
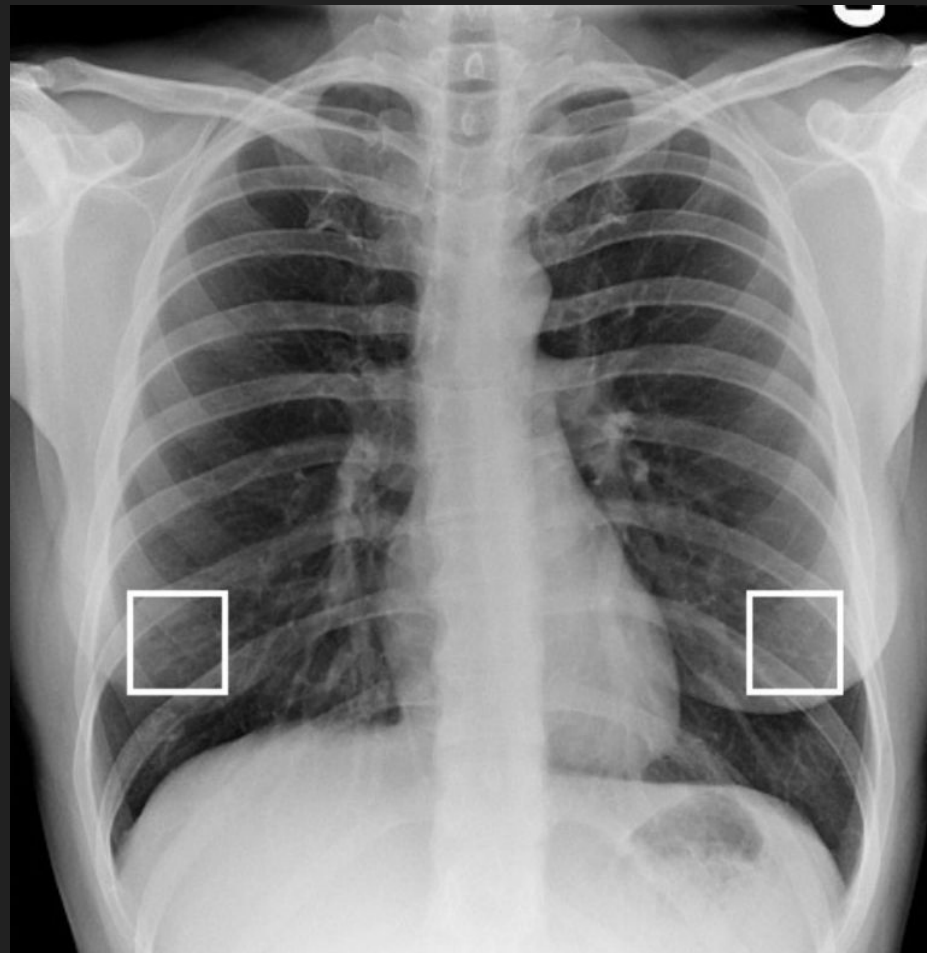
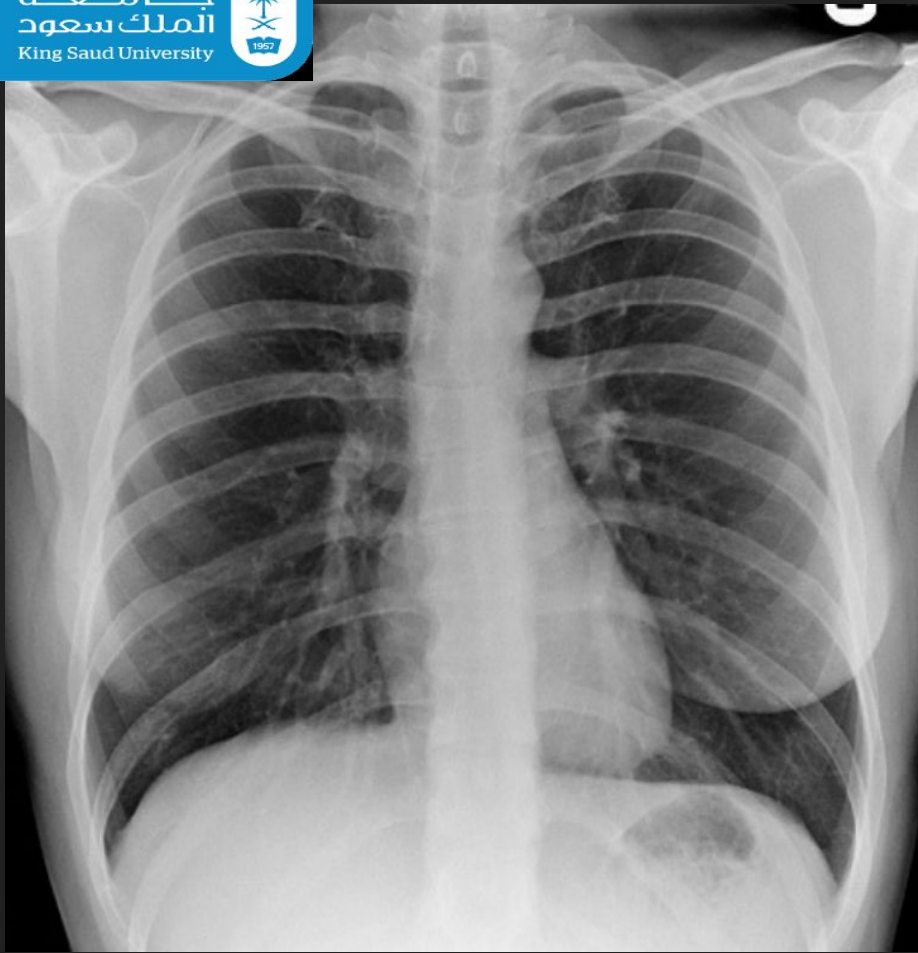


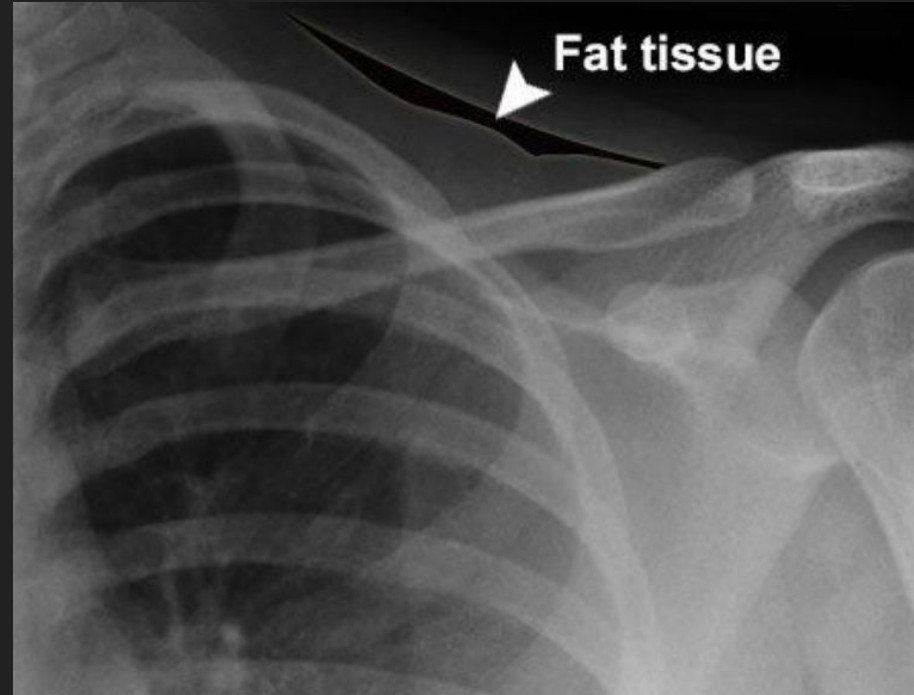
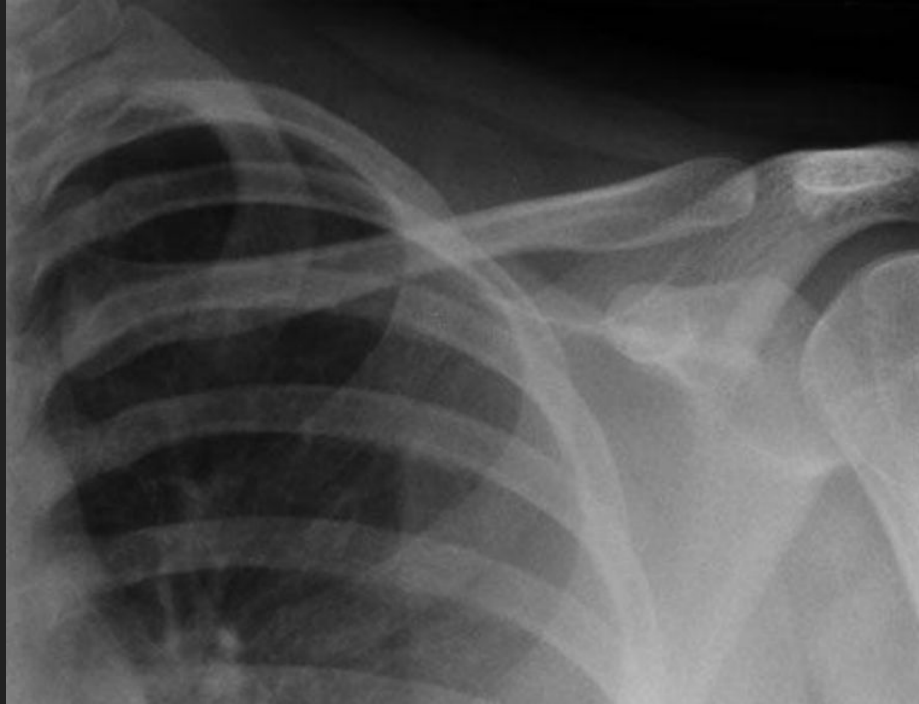


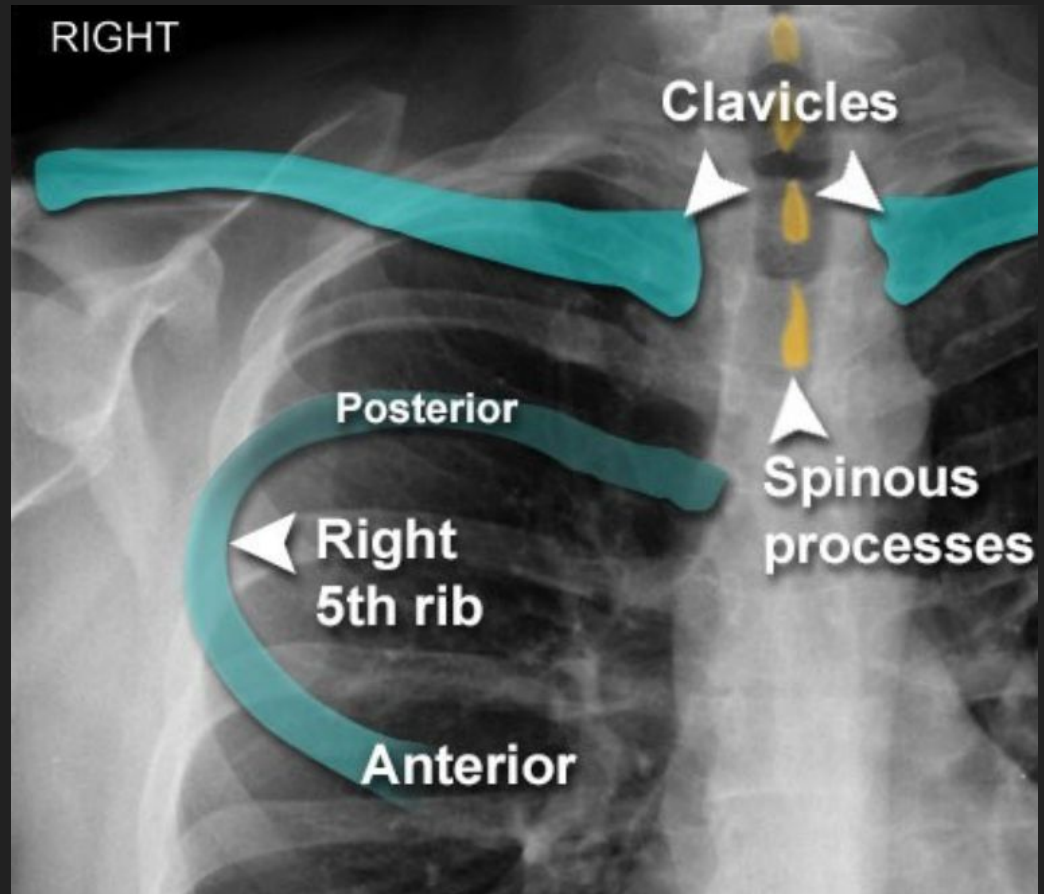
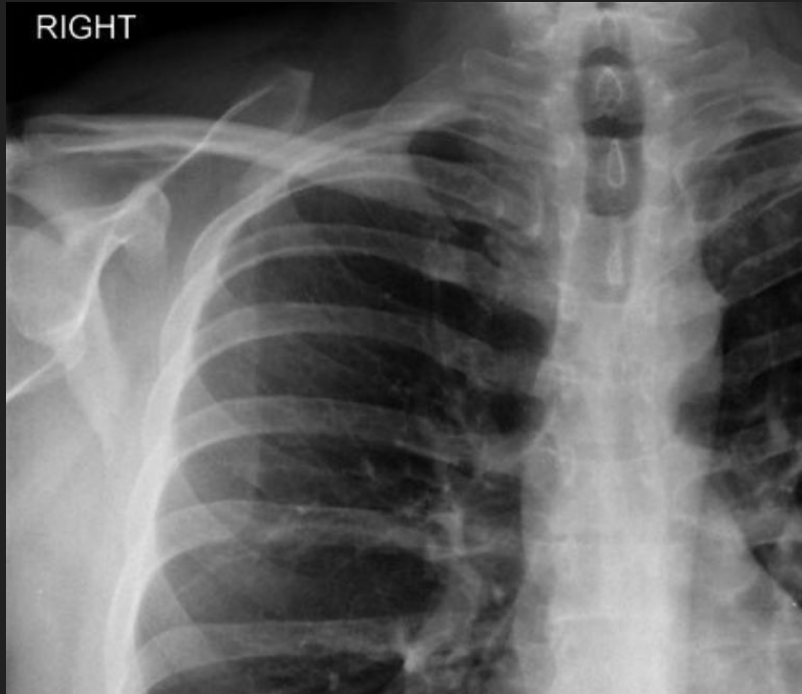


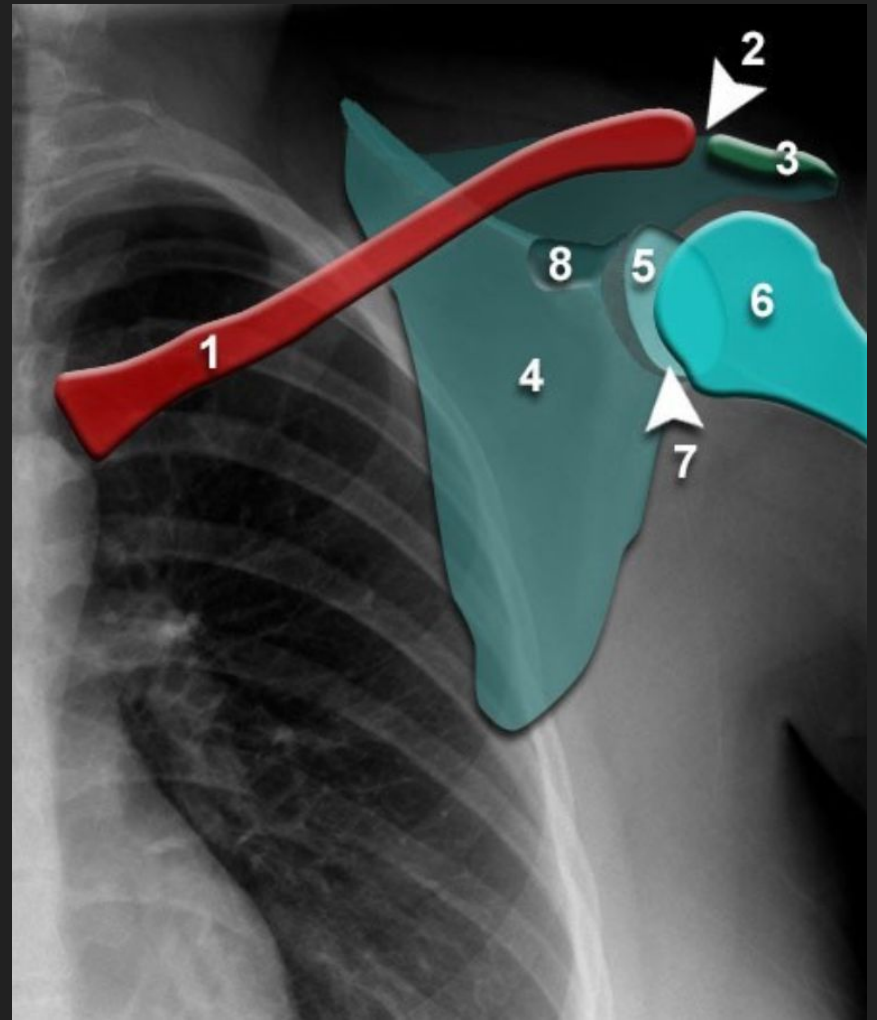


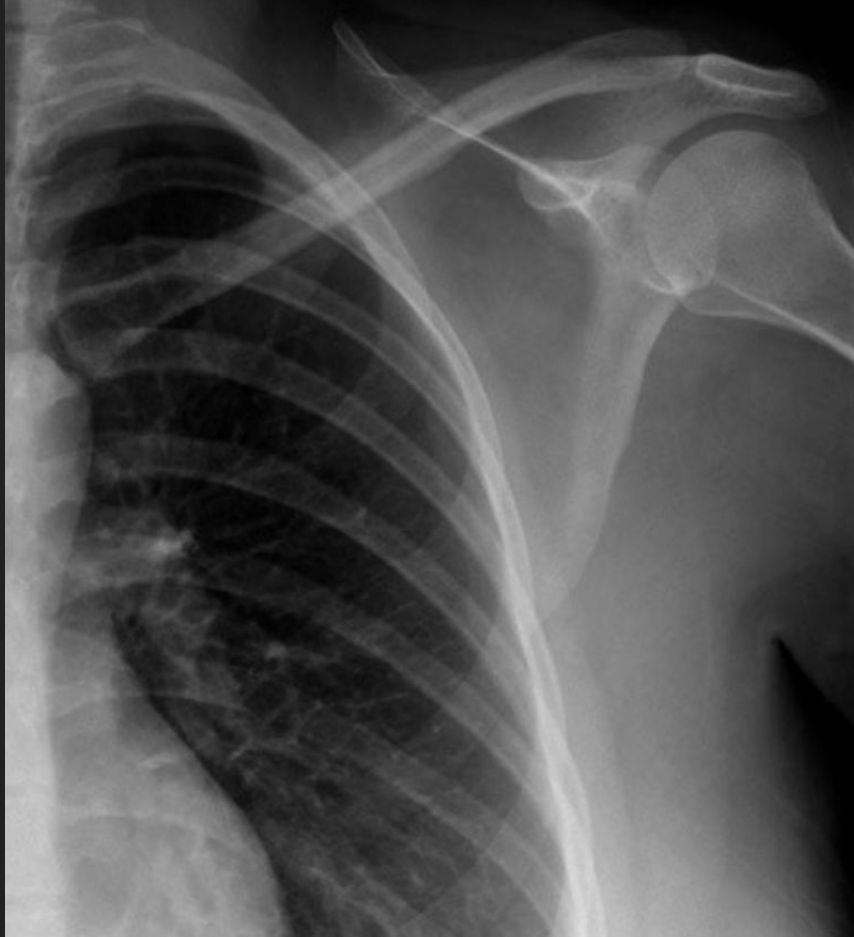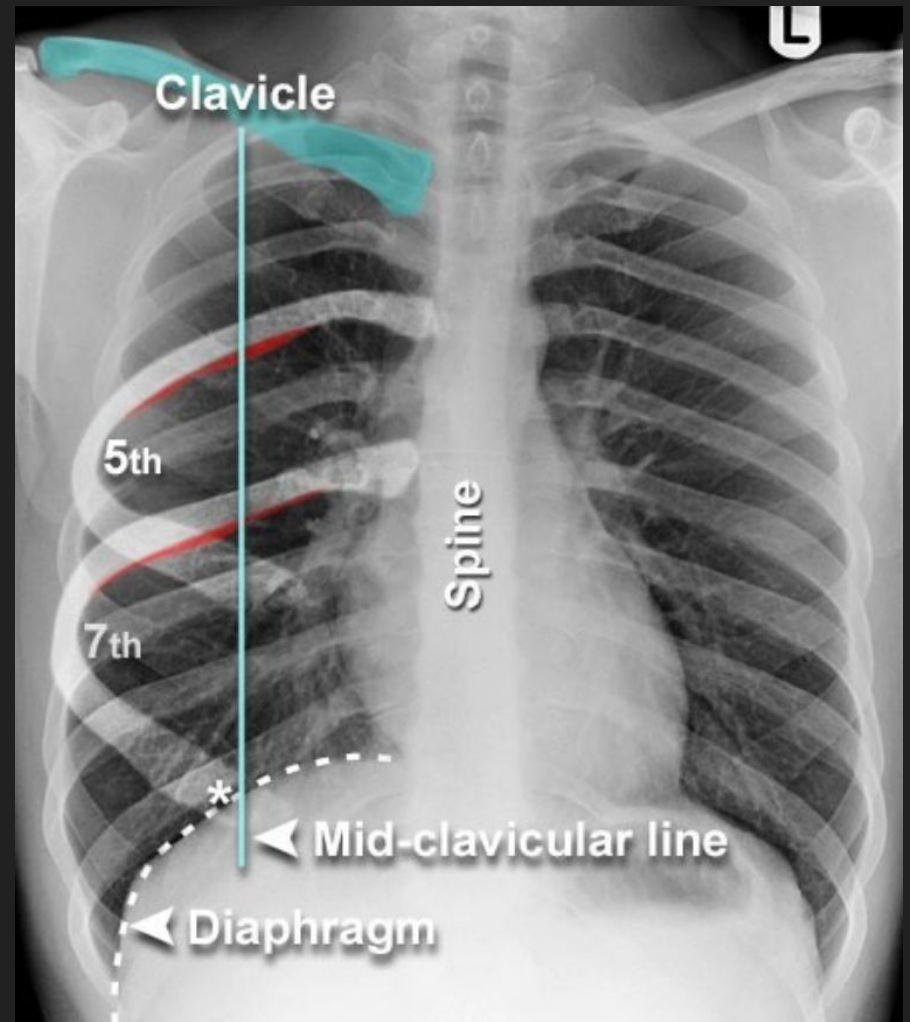
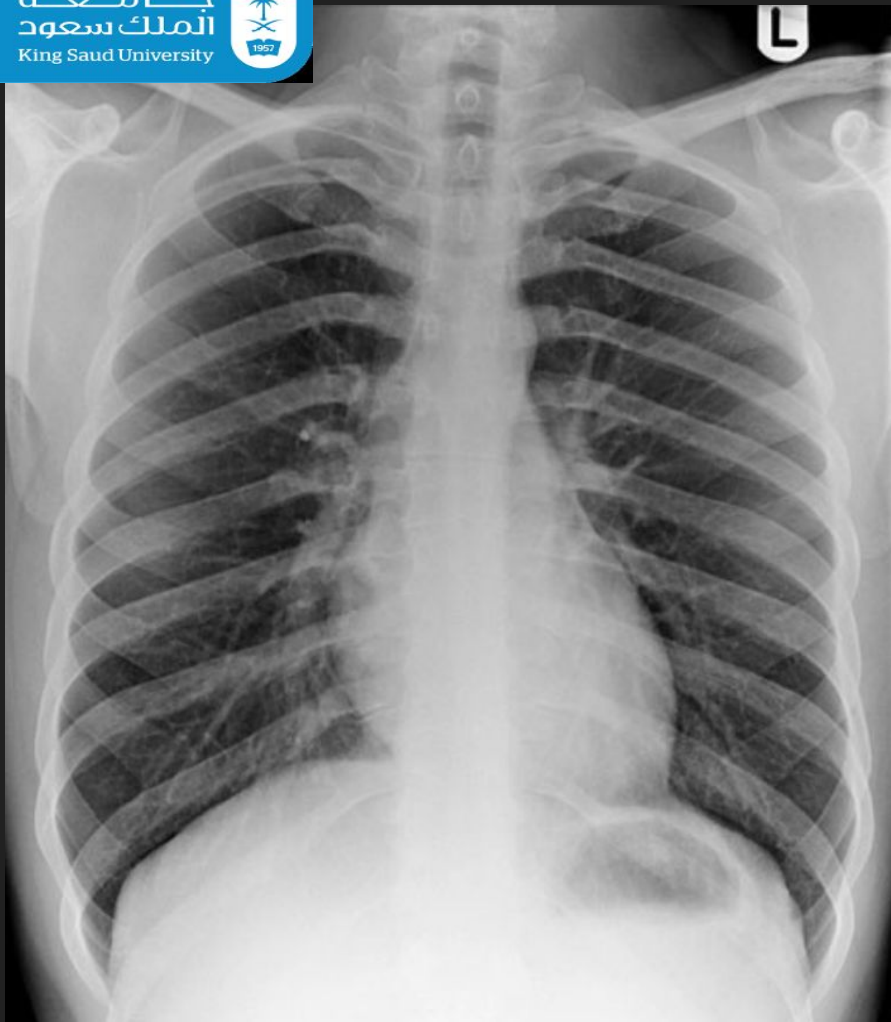






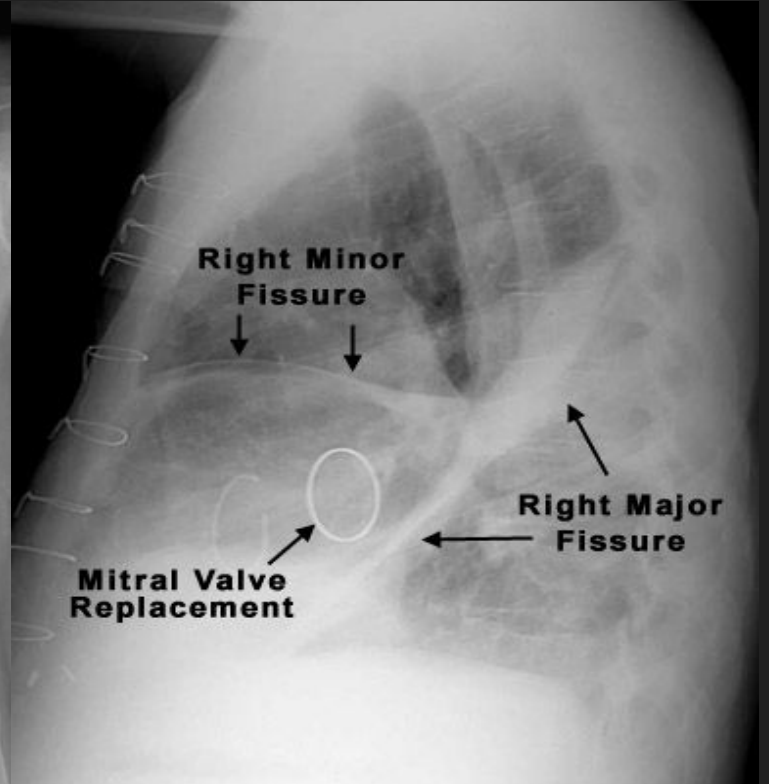
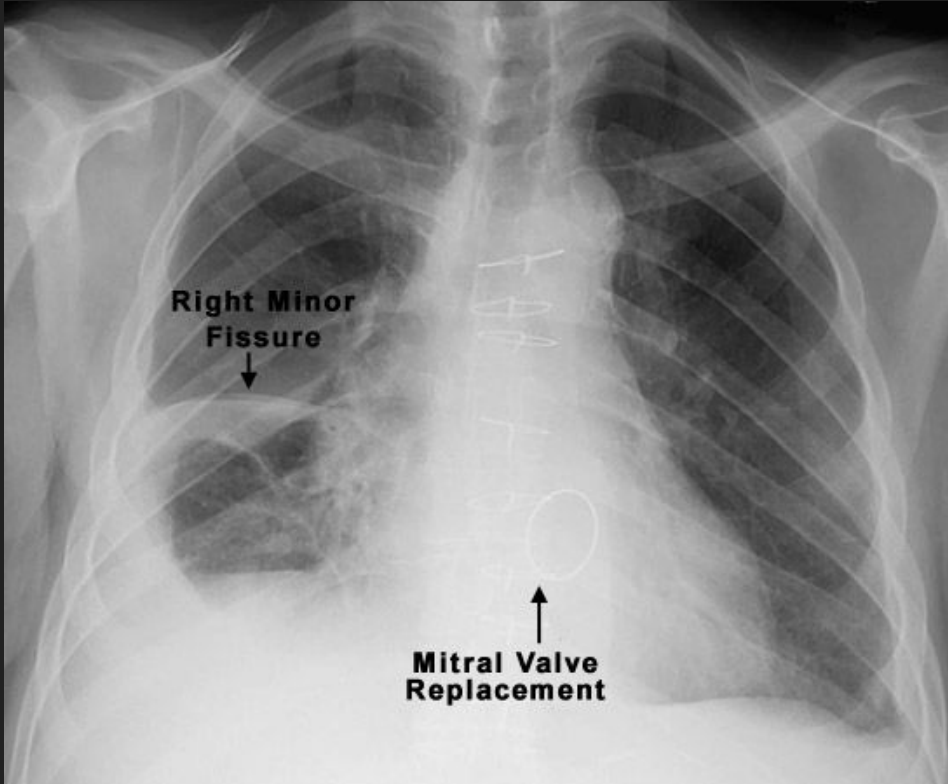




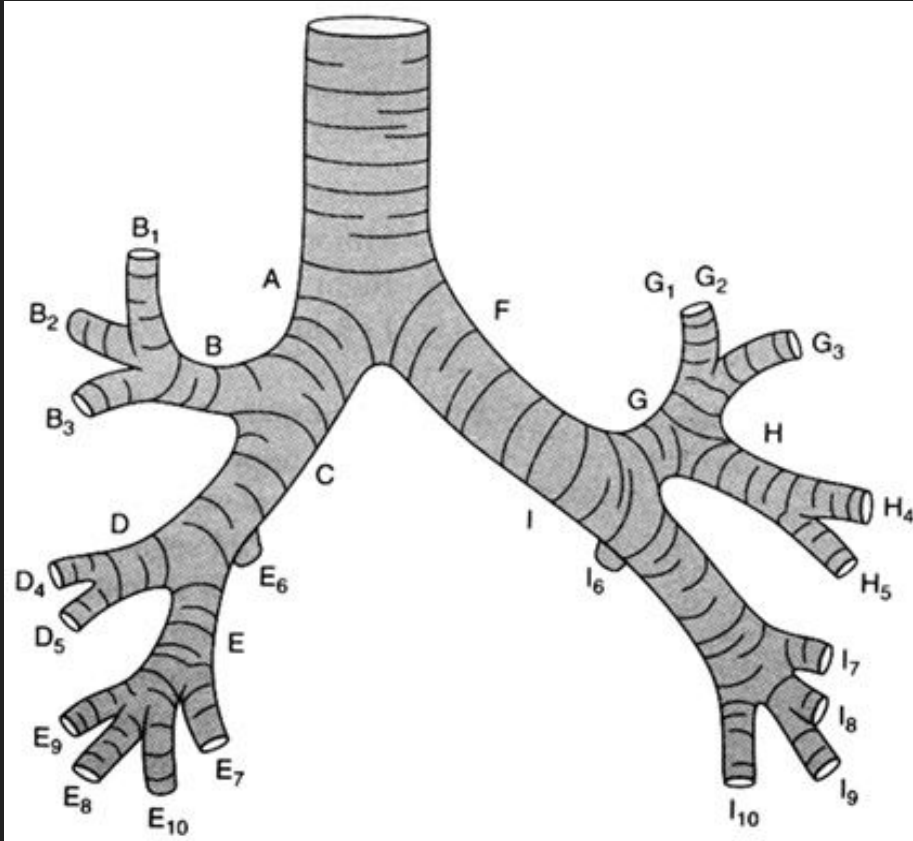


Anatomy

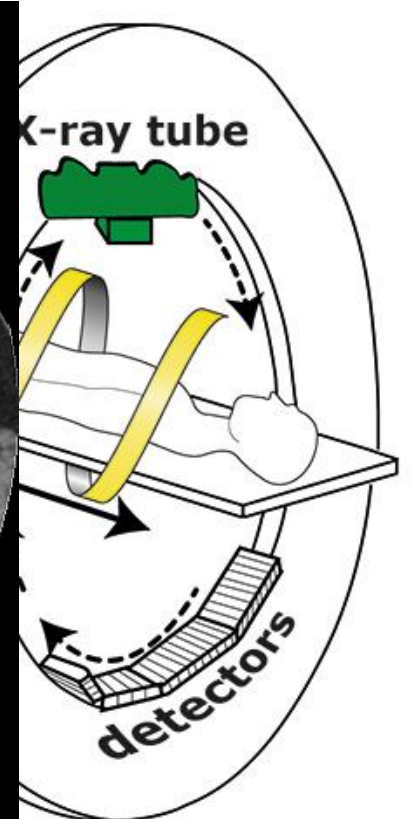
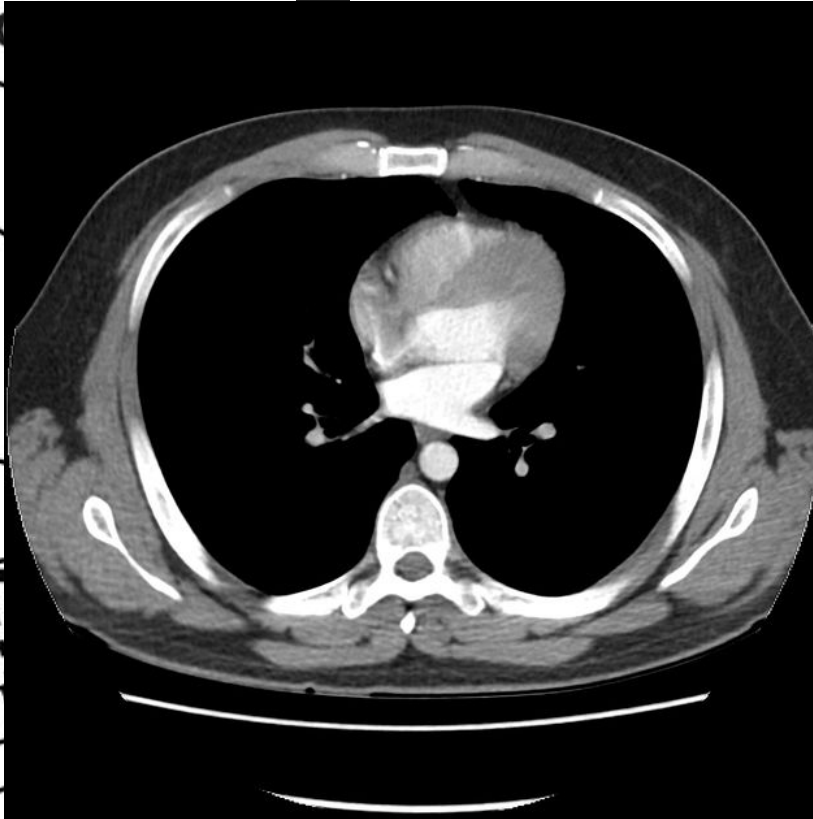
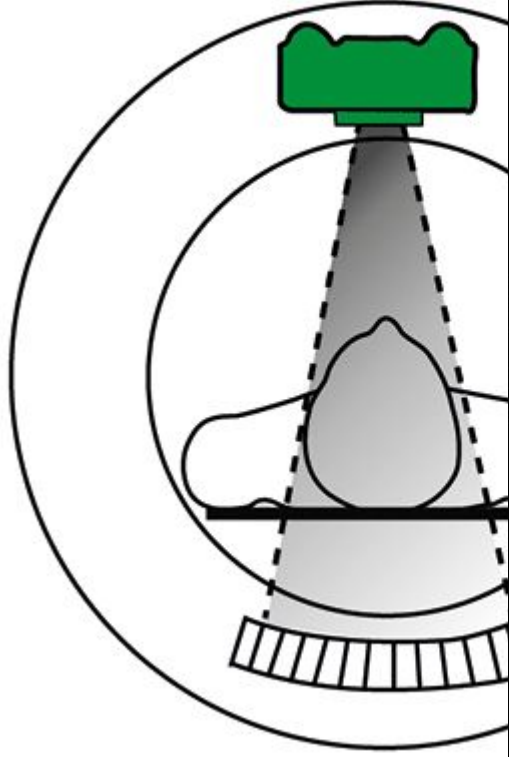
Lobes and Fissures

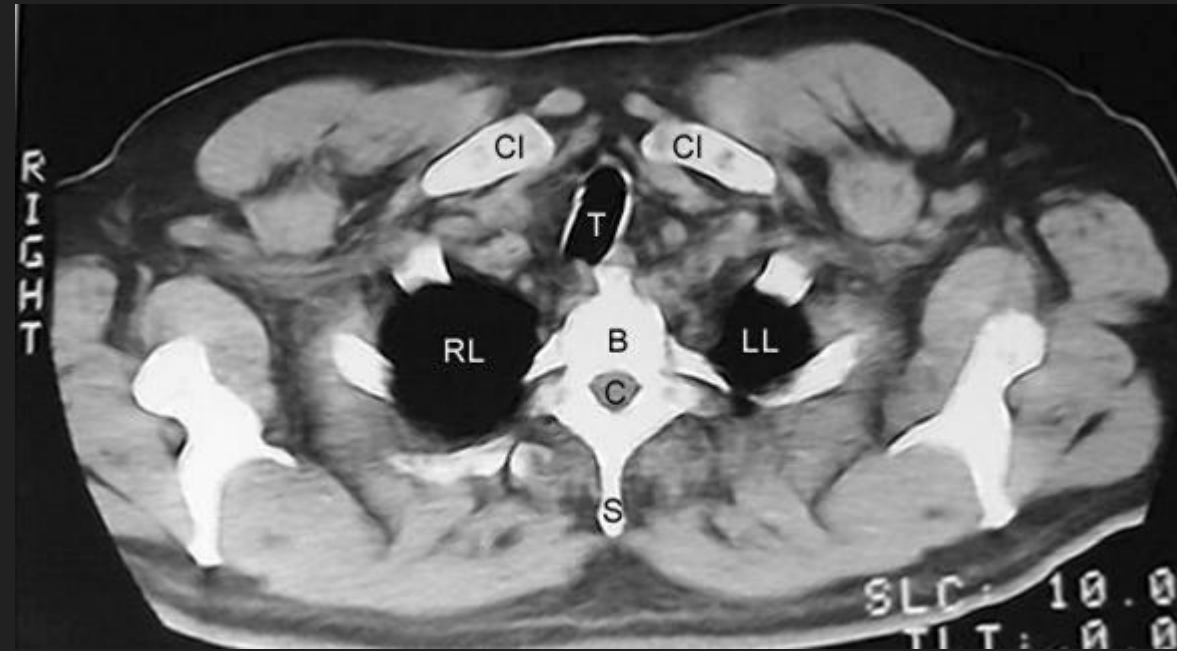


Anatomy Bronchi

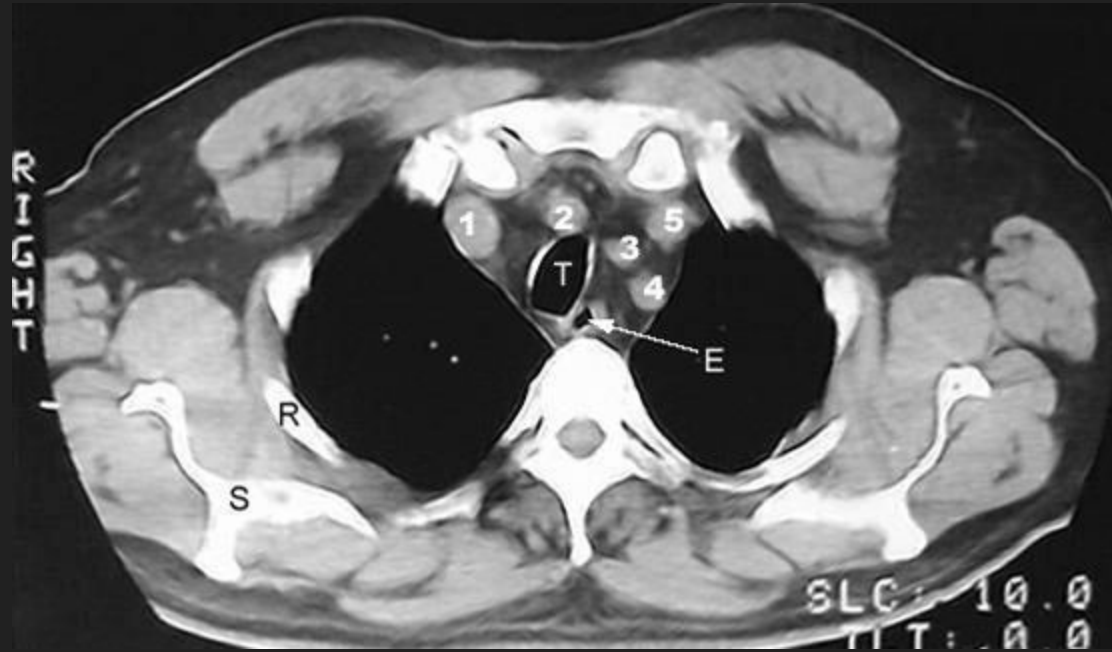


third generation





- B** BODY OF THORACIC VERTEBRA
- C** SPINAL CORD
- CL** CLAVICLES
- LL** APEX OF LEFT LUNG
- RL** APEX OF RIGHT LUNG
- S** SPINOUS PROCESS OF THE VERTEBRA
- T** TRACHEA



E ESOPHAGUS

R RIB

S SCAPULA

T TRACHEA

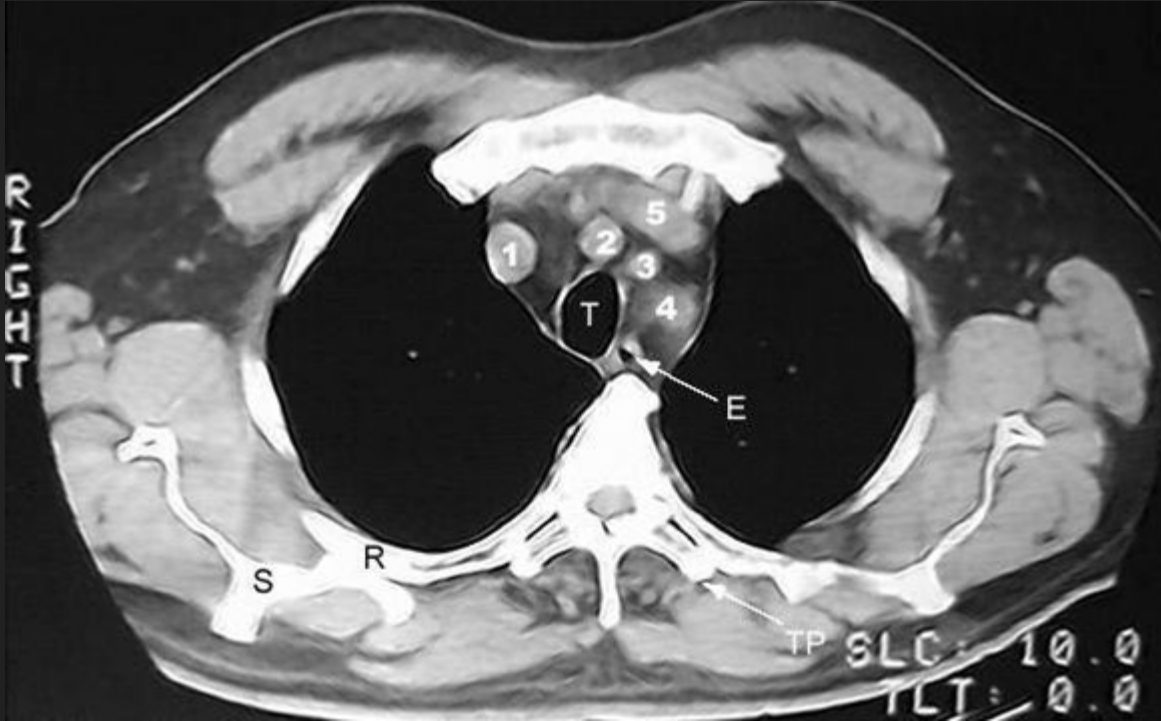Right Brachiocephalic vein

Brachiocephalic artery

Left common carotid artery

Left subclavian artery

Right Brachiocephalic vein



E ESOPHAGUS

R RIB

S SCAPULA

T TRACHEA

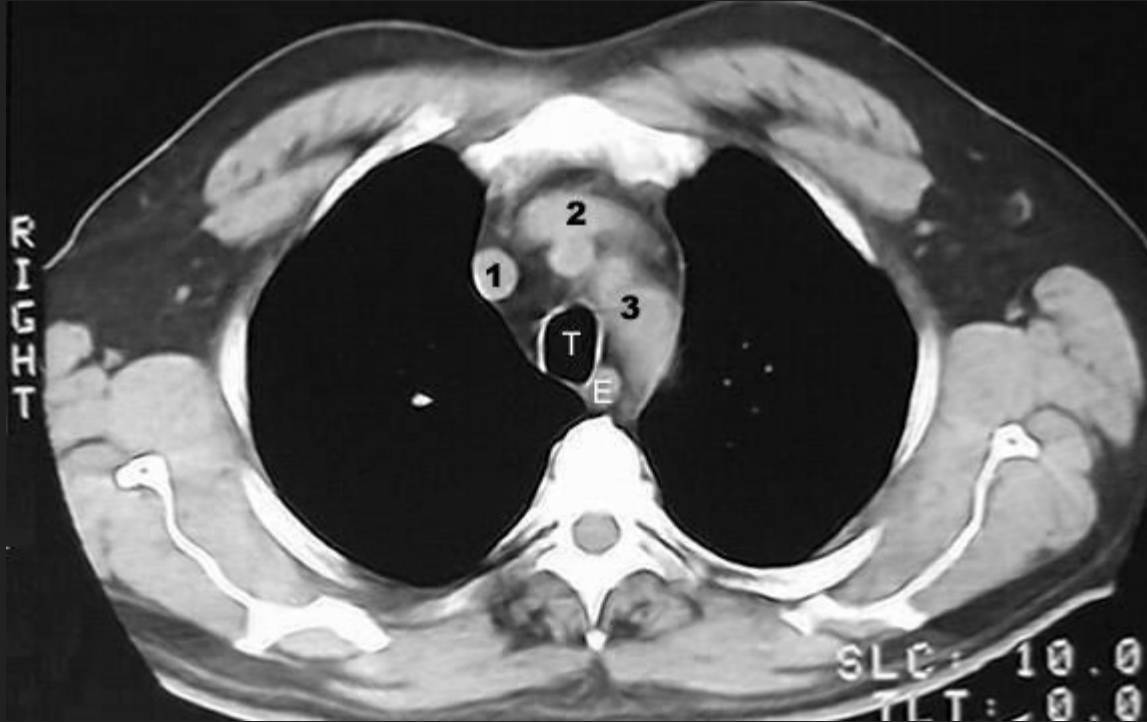1 Right Brachiocephalic vein

2 Brachiocephalic artery

3 Left common carotid artery

4 Left subclavian artery

5 Right Brachiocephalic vein



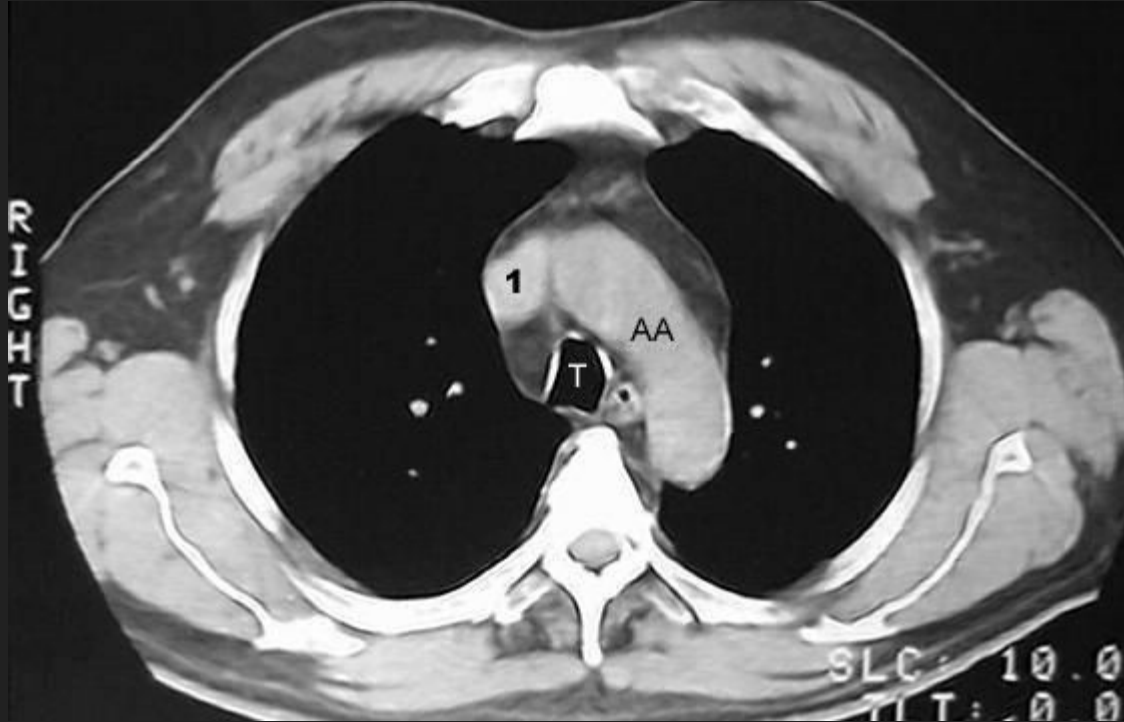
E ESOPHAGUS

T TRACHEA

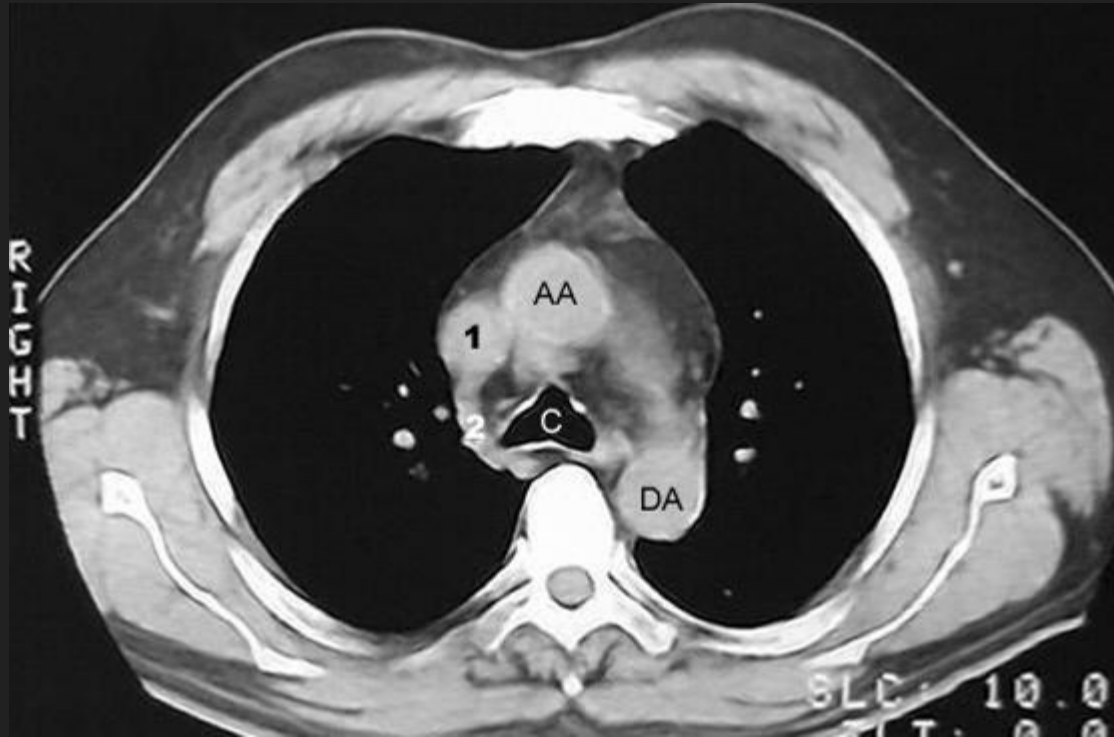
1 Right Brachiocephalic vein

2 Left Brachiocephalic vein

3 Aortic arch



- AA** Aortic Arch
- T** TRACHEA
- 1** Superior vena cava

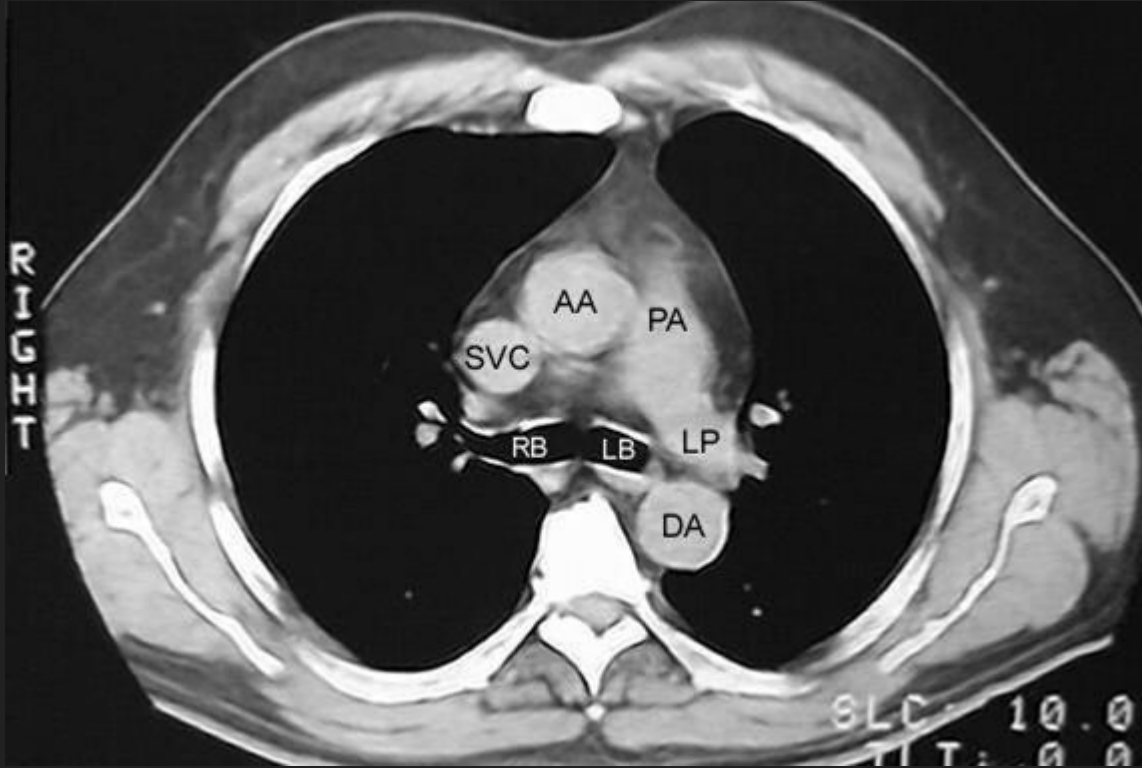


AA Ascending Aorta

DA Descending Aorta

1 Superior vena cava

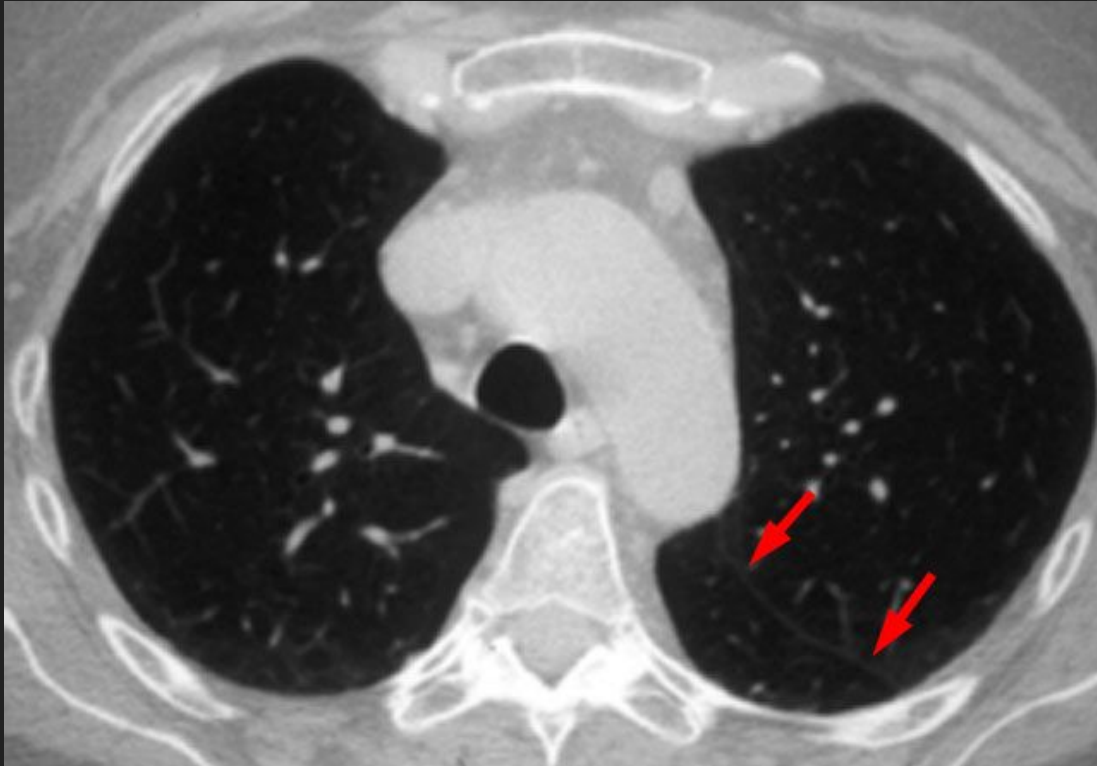
2 Azygous Arch

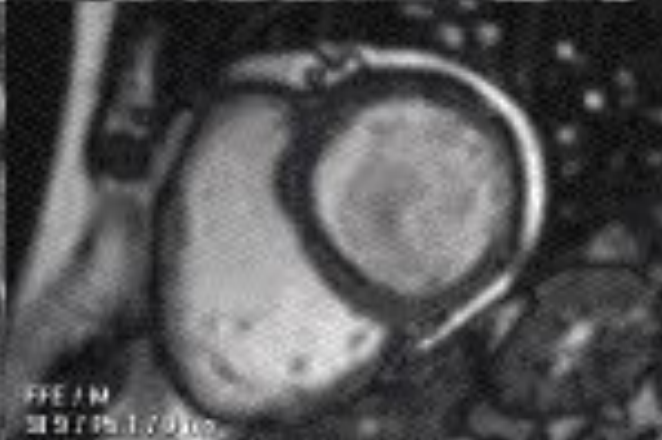
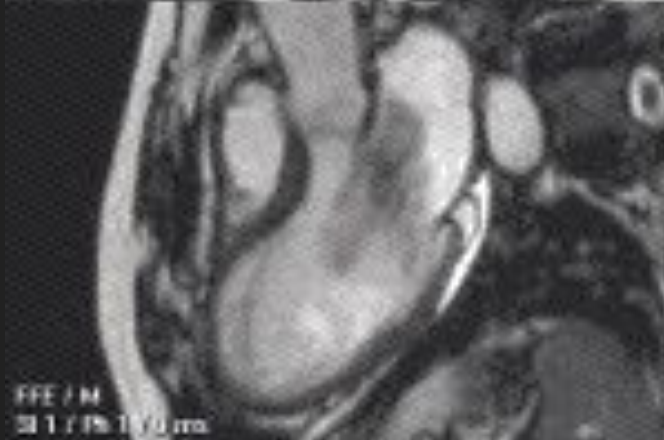
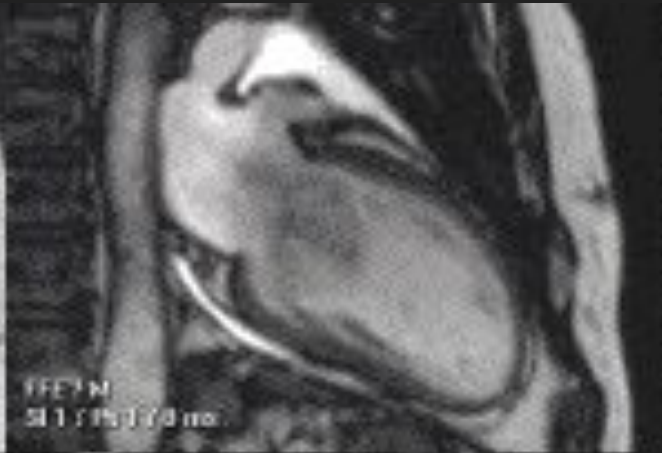
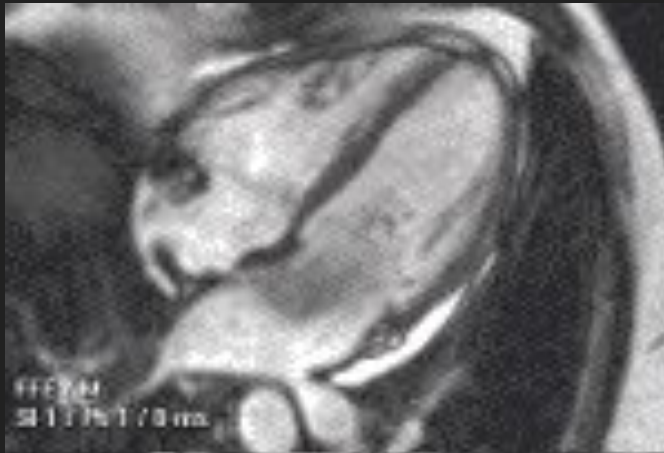
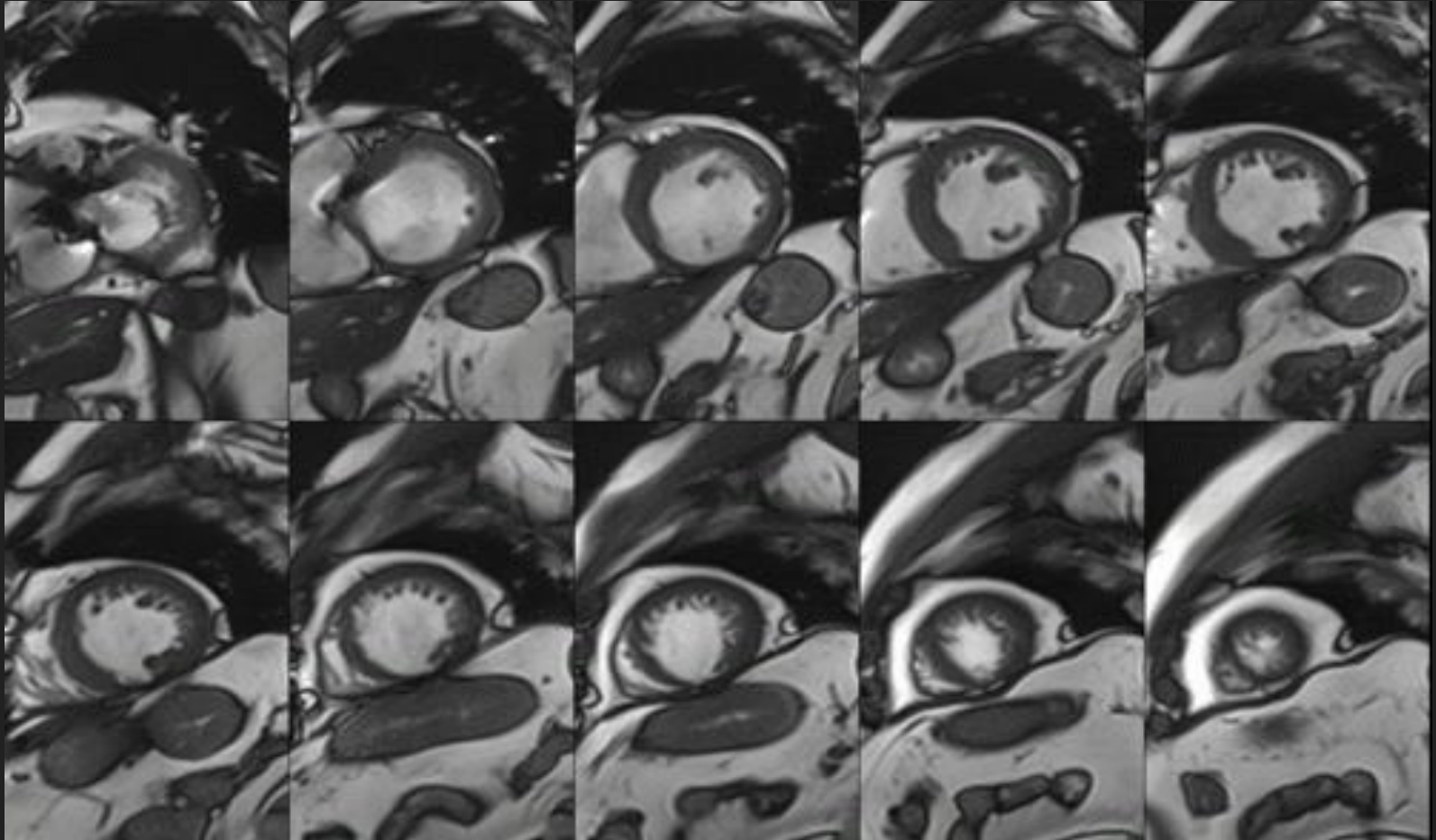
- AA** Ascending Aorta
- DA** Descending Aorta
- LB** Left main bronchus
- LP** Left pulmonary artery
- PA** Pulmonary trunk
- RB** Right main bronchus
- SVC** Superior vena cava

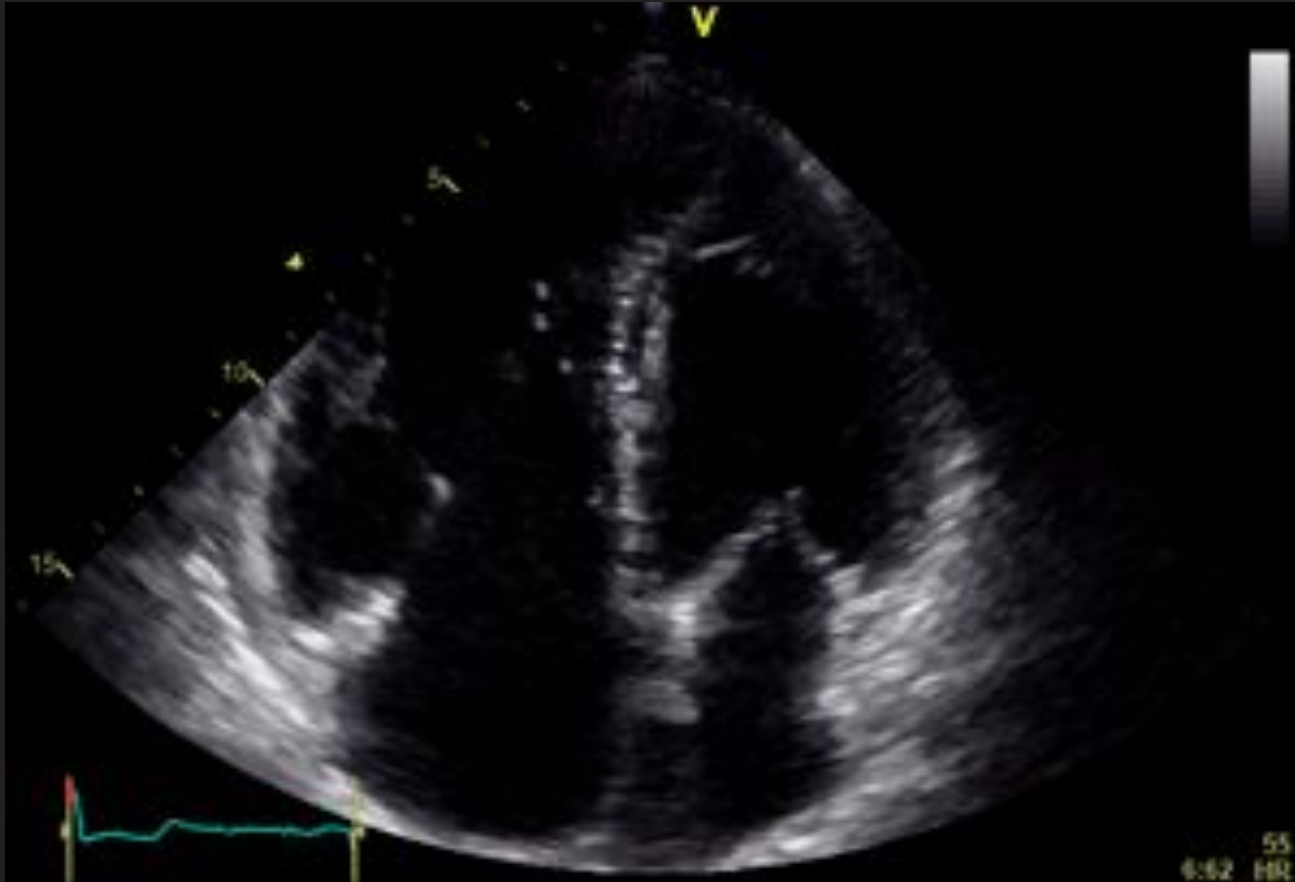
Anatomy

Lobes and Fissures



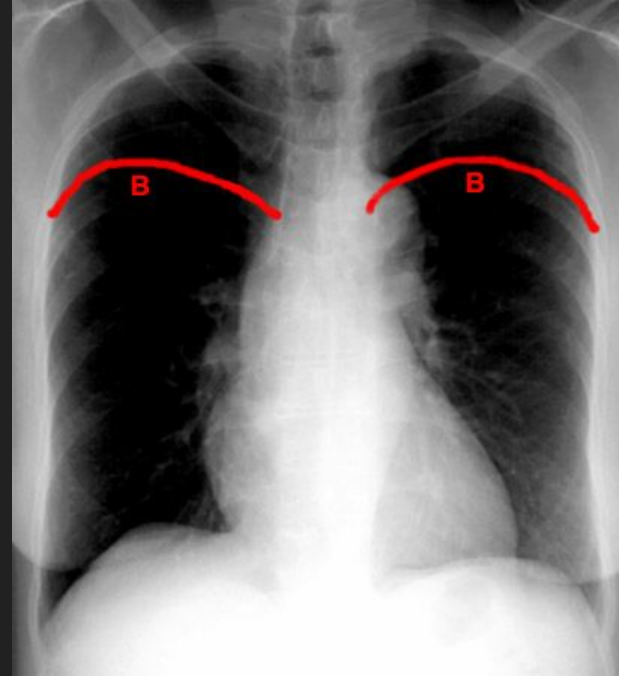
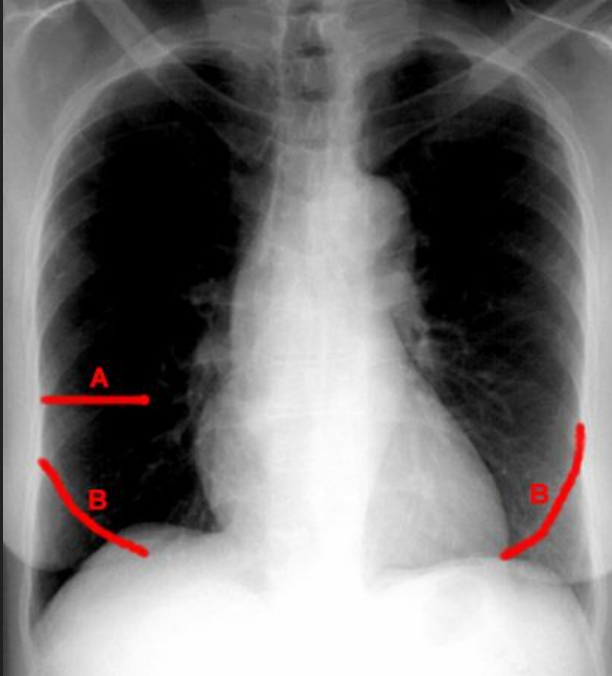






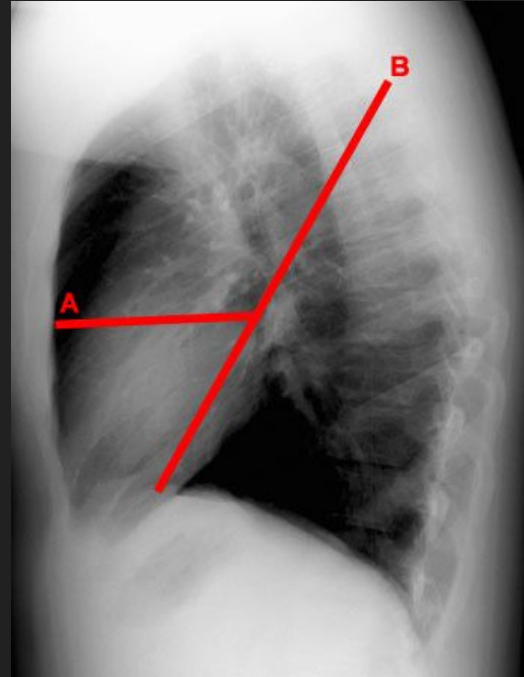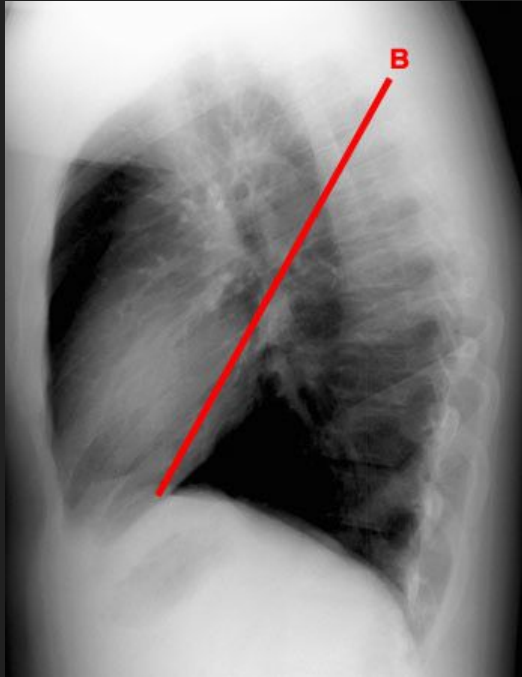Anatomy

Lobes and Fissures



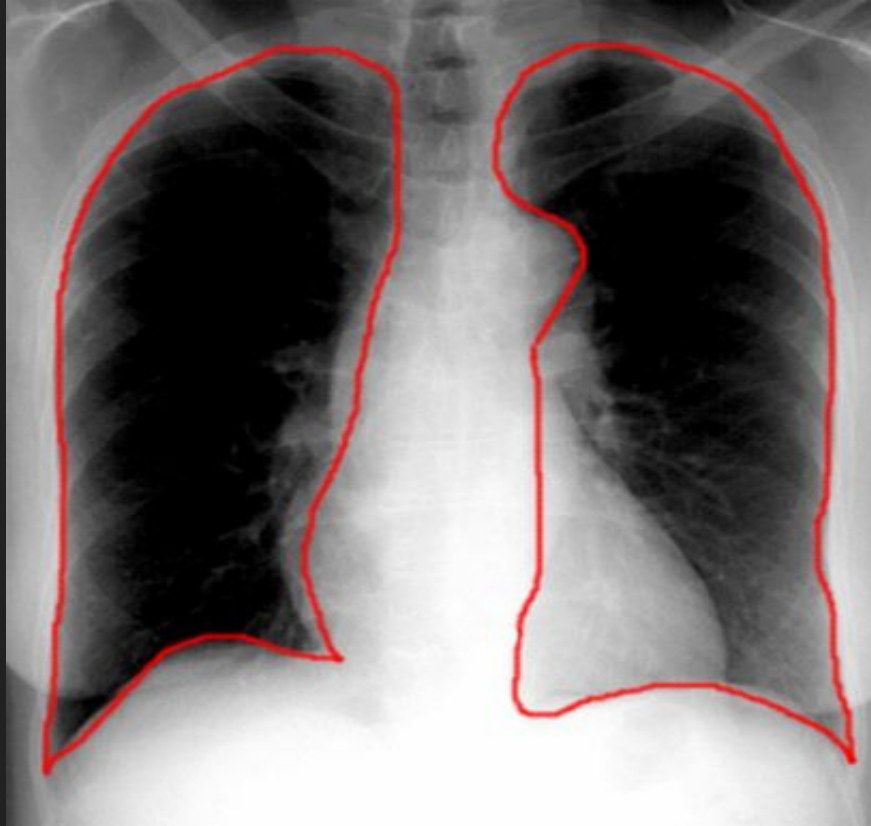
Anatomy

Lobes and Fissures



Anatomy

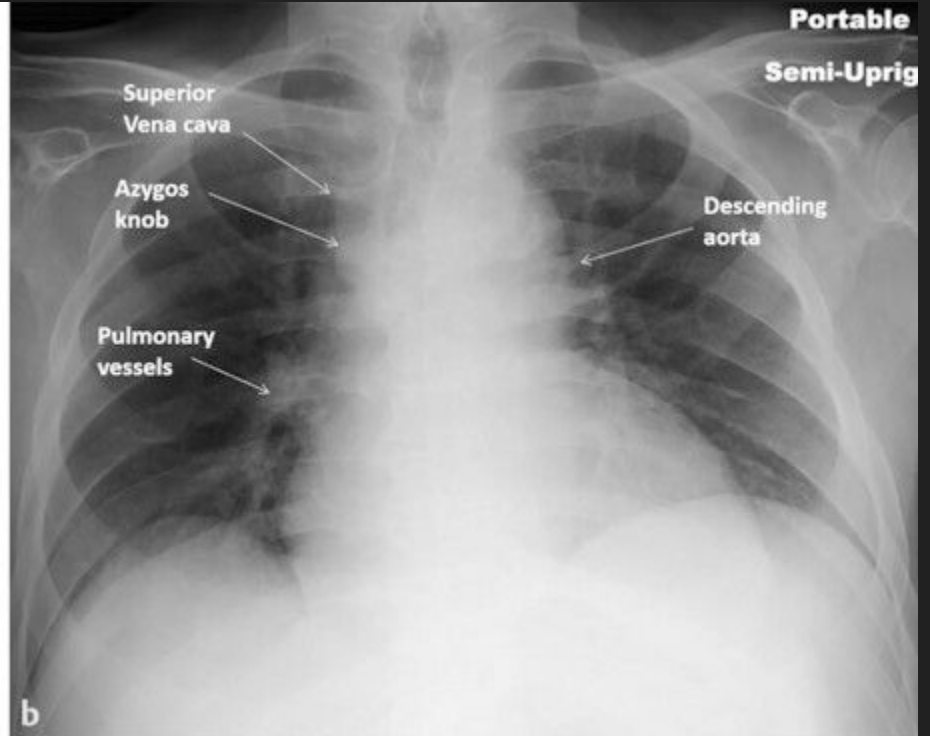
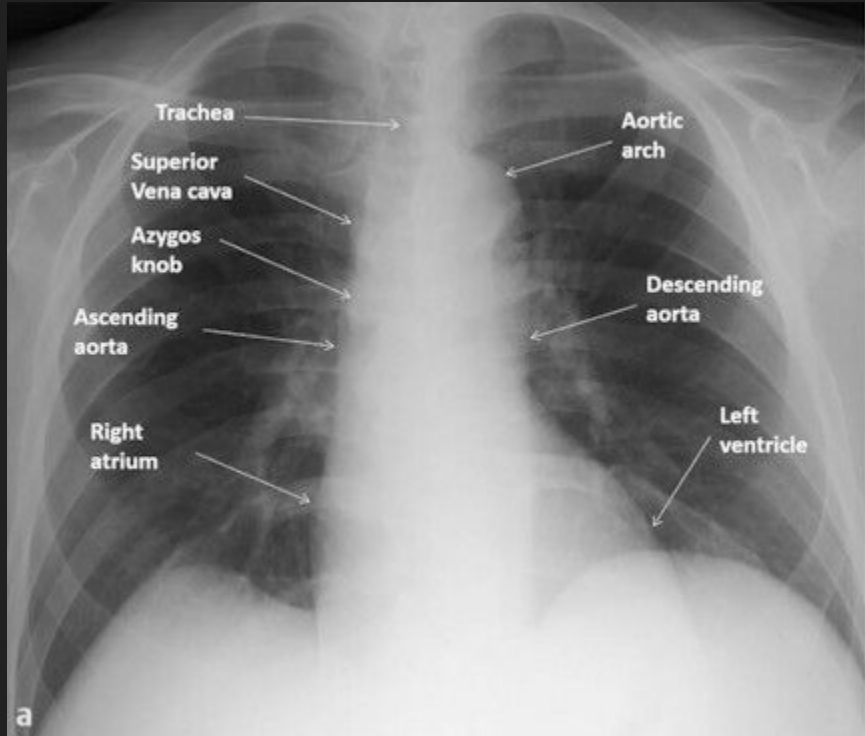
Mediastinum and Lungs

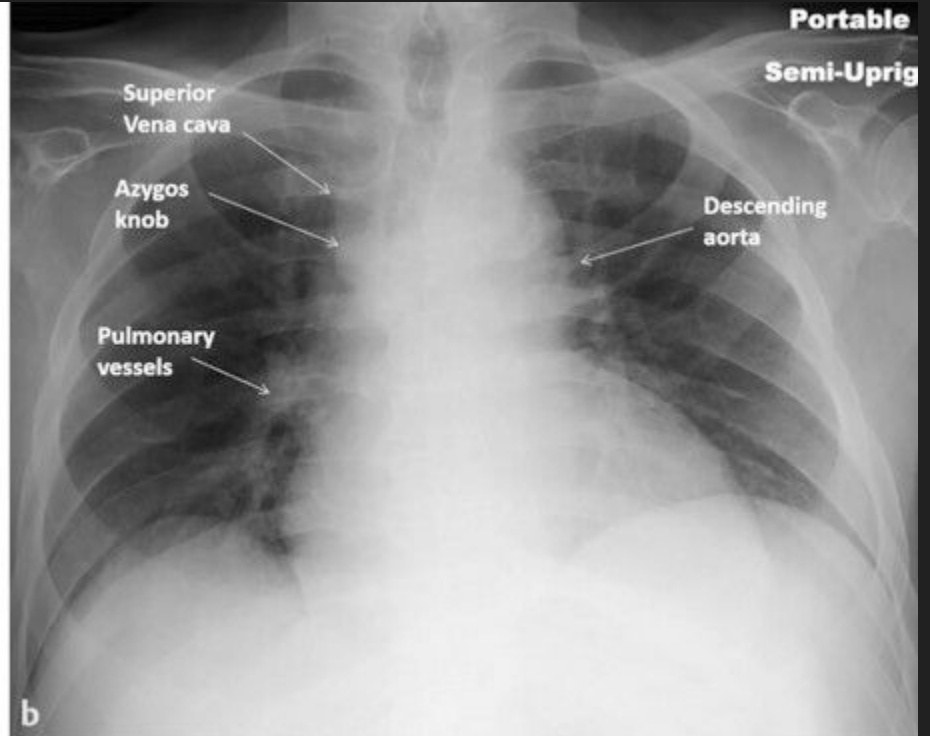
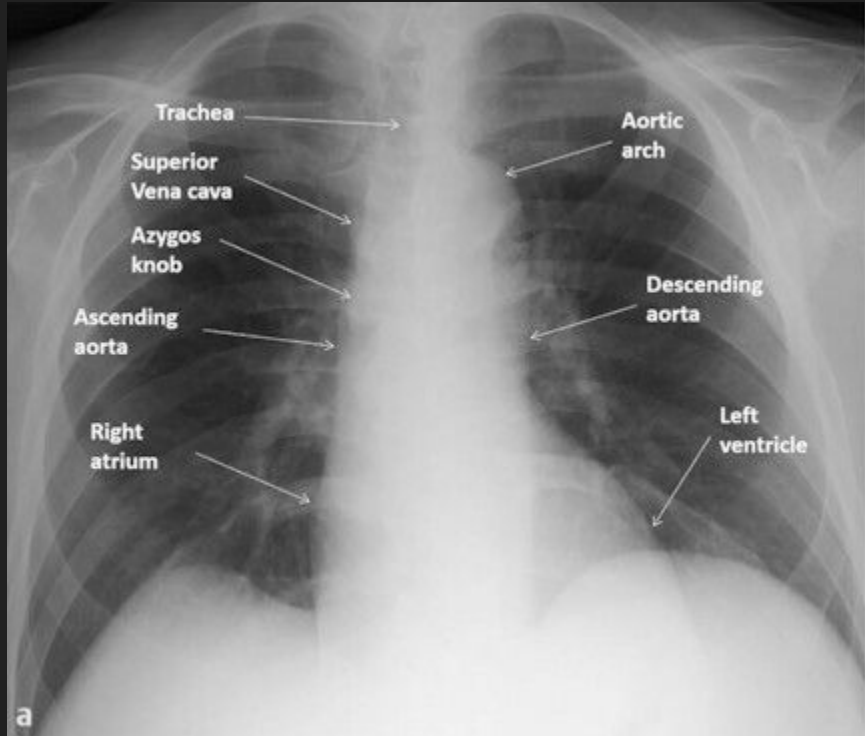


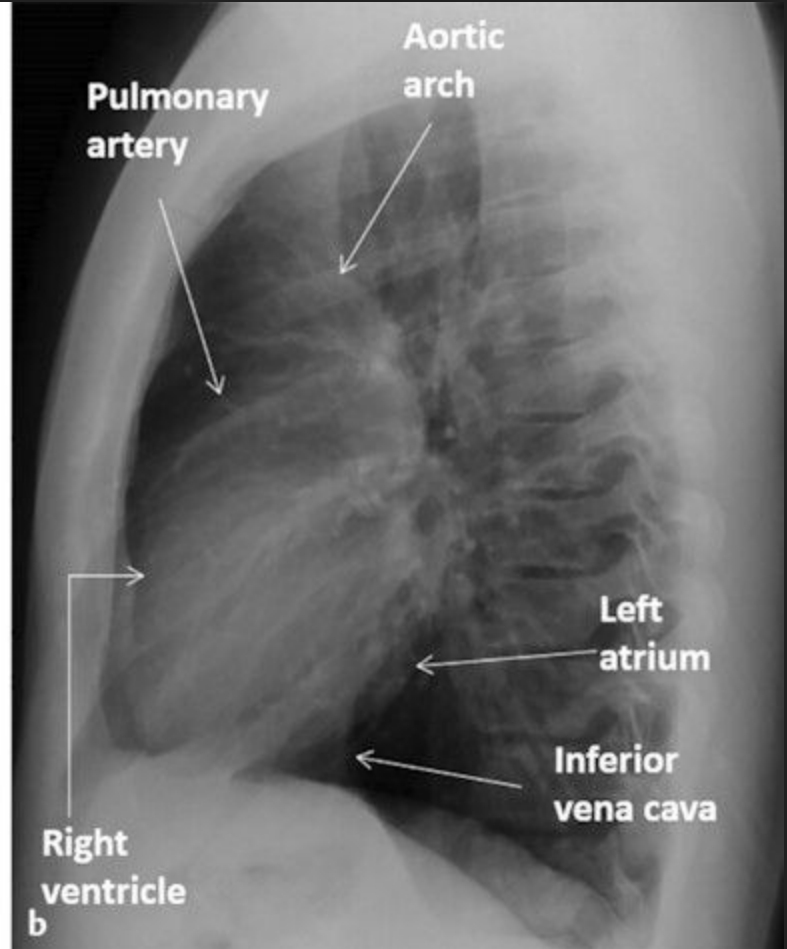
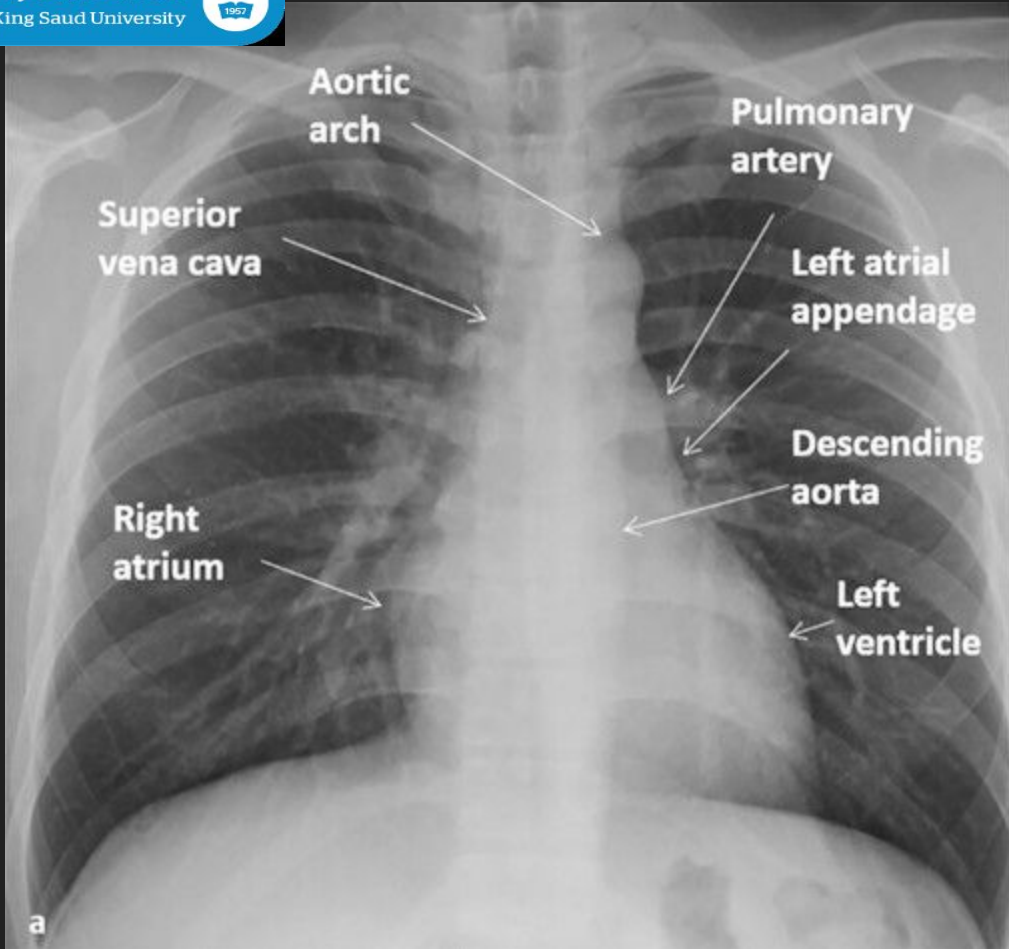


Cardiac Anatomy

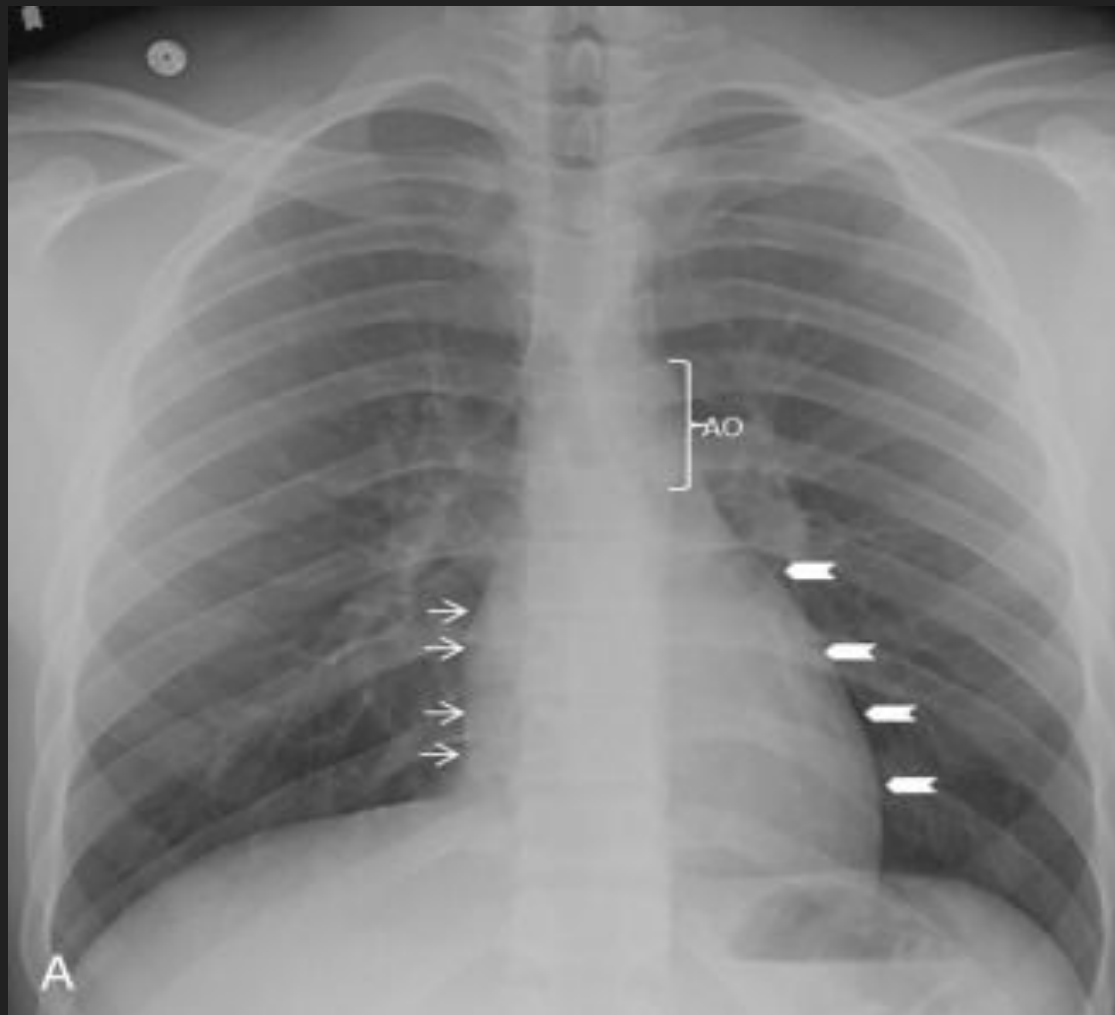
Dr Majid Homiedan



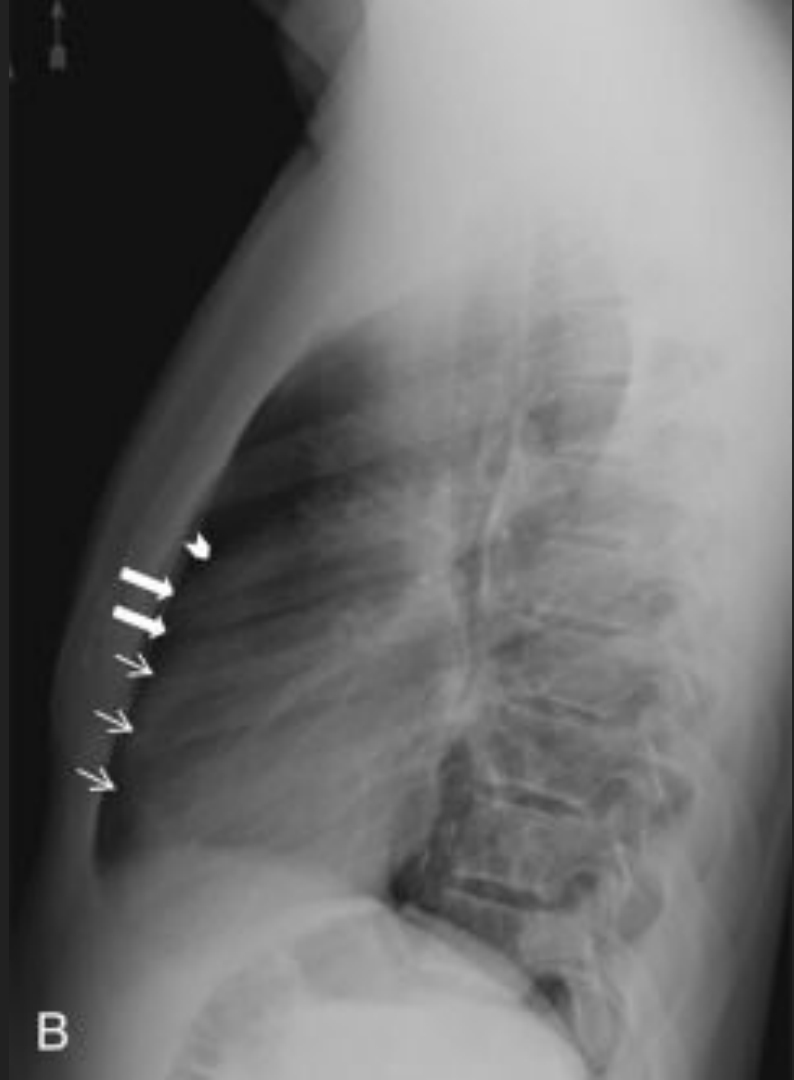




Cardiac Anatomy on Conventional Radiography

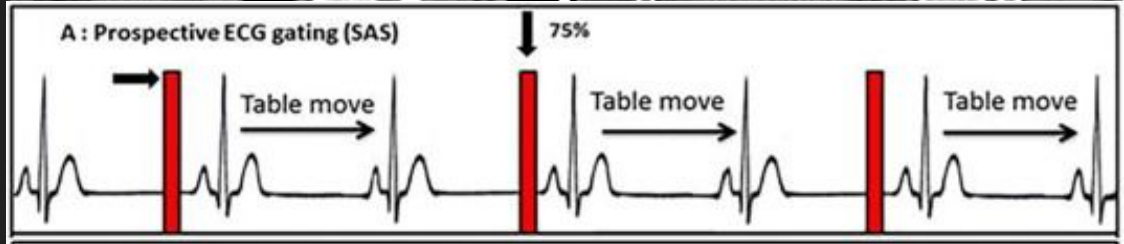
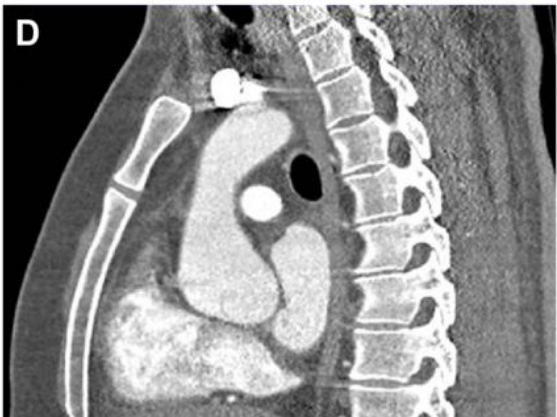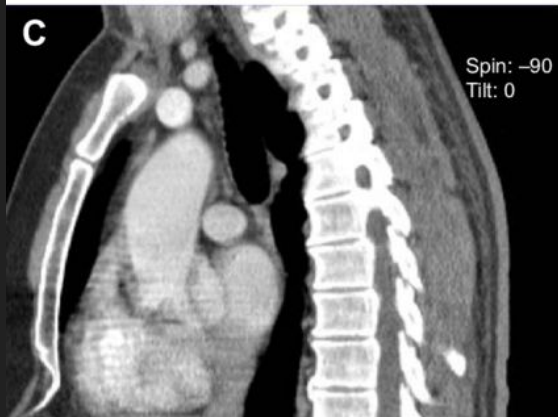
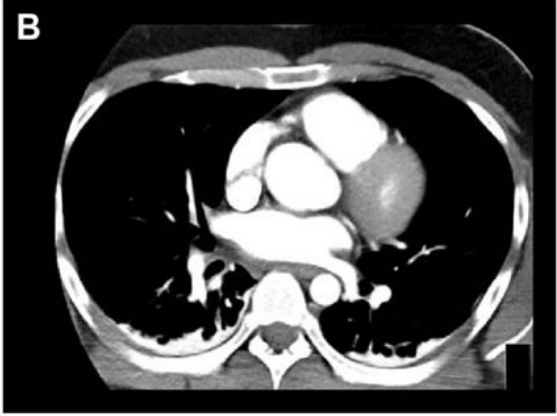

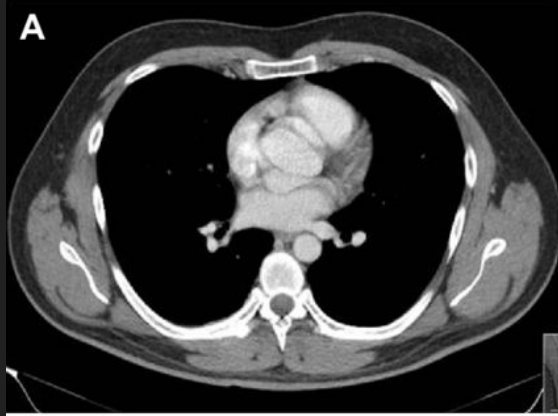
Cardiac Anatomy on Conventional Radiography



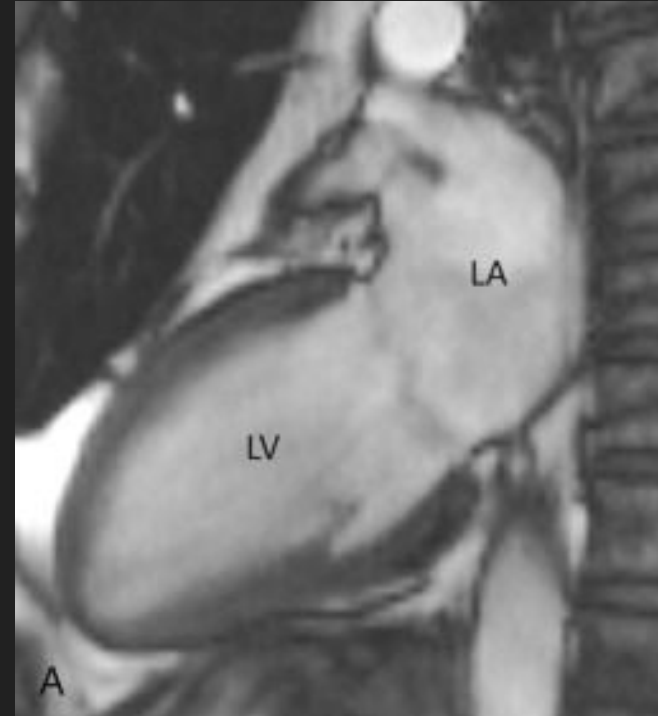
Technical Factors for Cardiac Imaging:

Electrocardiographic Gated Scan



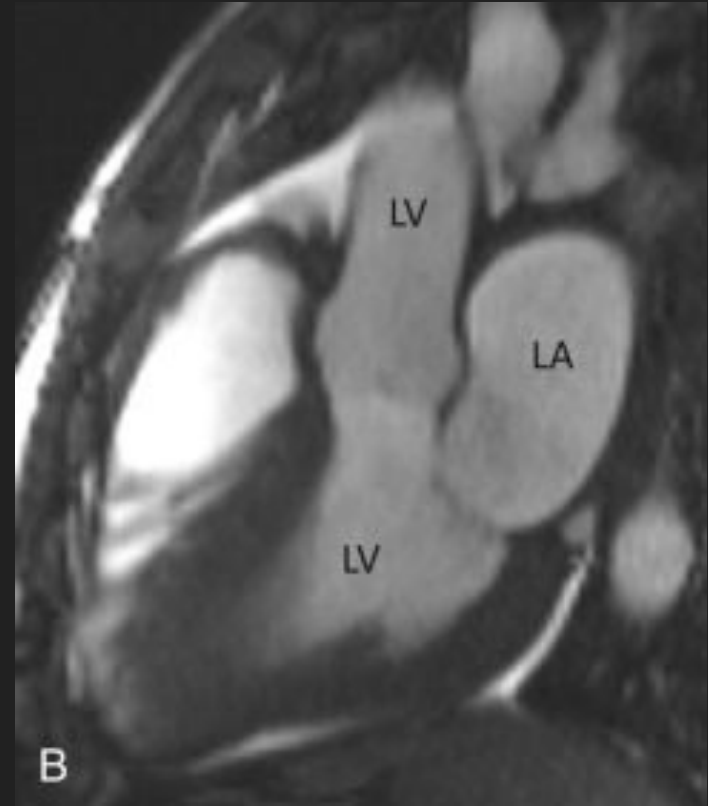Cardiac Imaging Planes

Two-Chamber View (Paraseptal View)



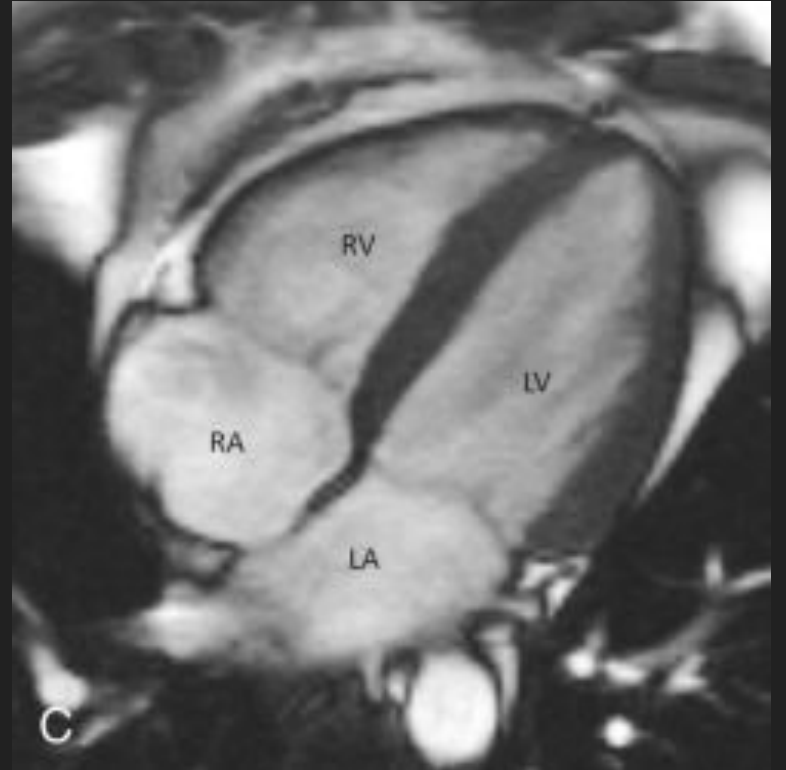
Cardiac Imaging Planes

Three-Chamber View



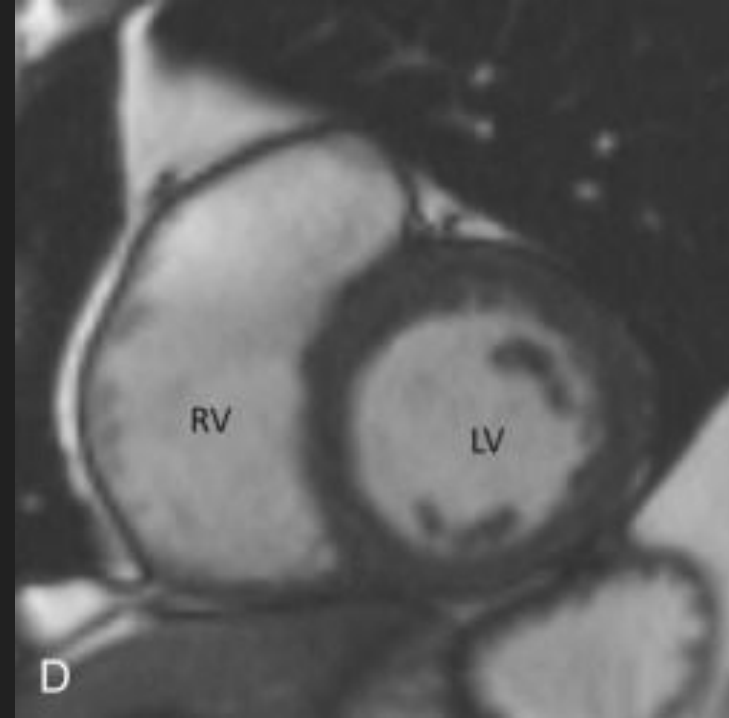
Cardiac Imaging Planes

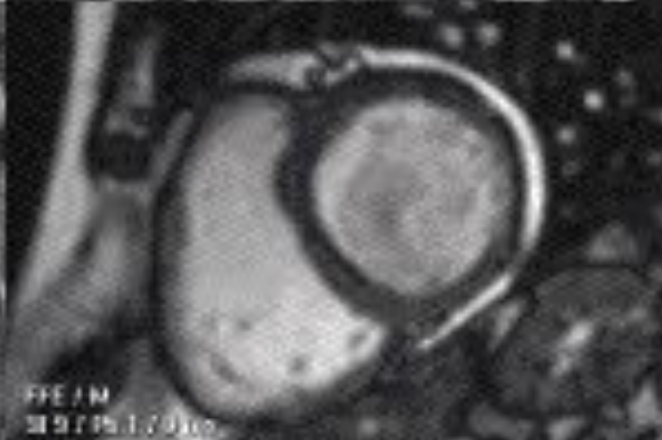
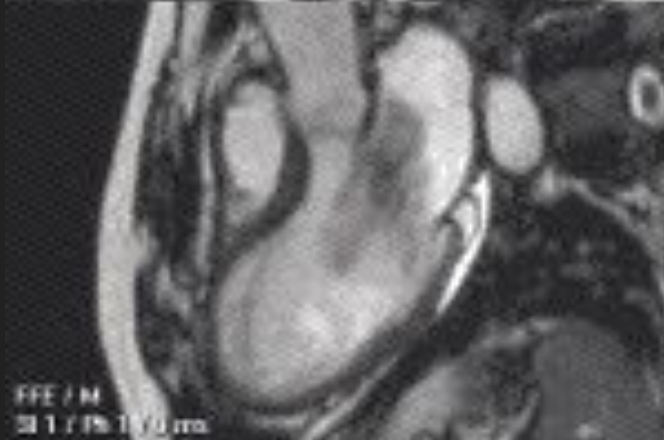
Four-Chamber View

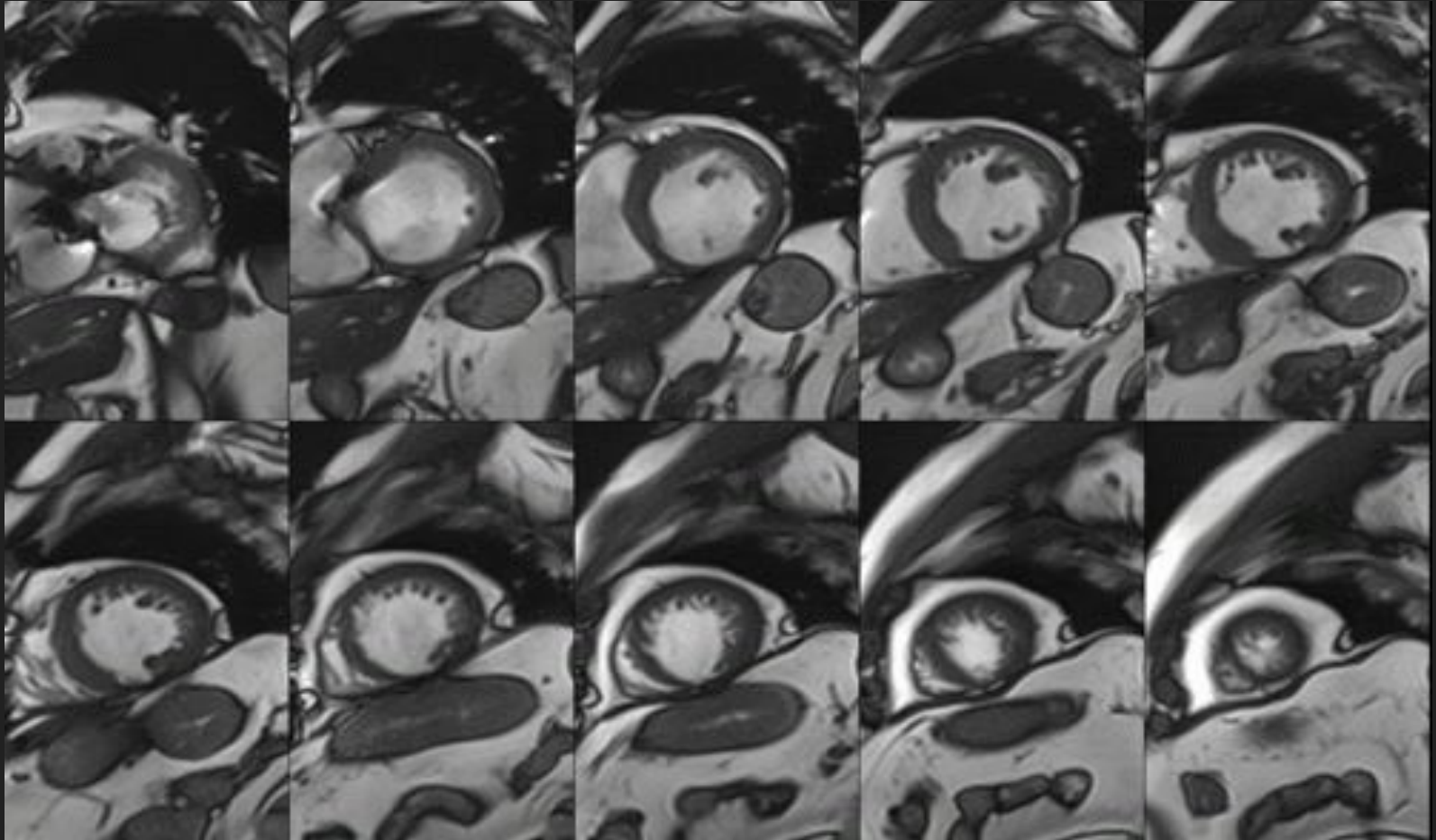


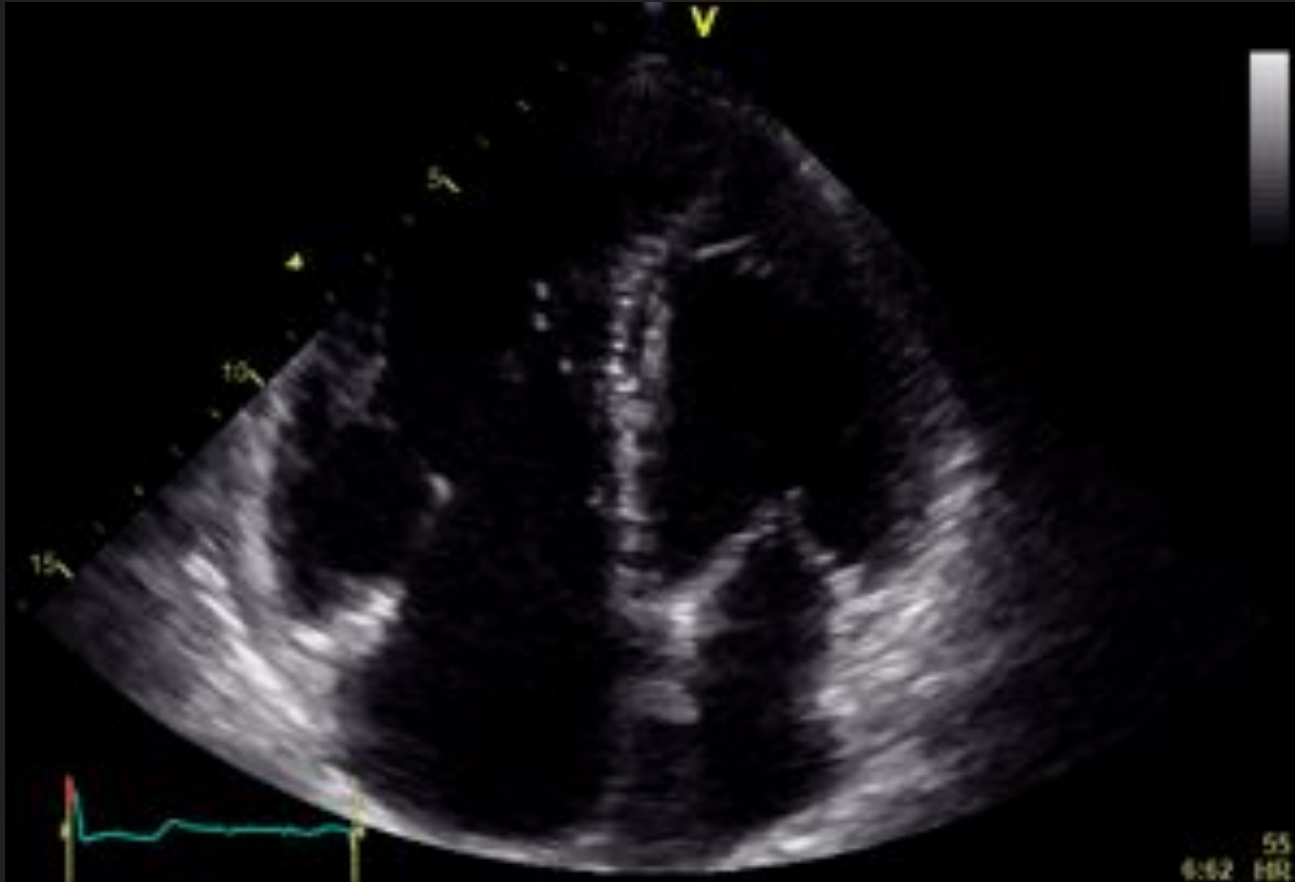
Cardiac Imaging Planes

Short-Axis Views









The 17-segment model

