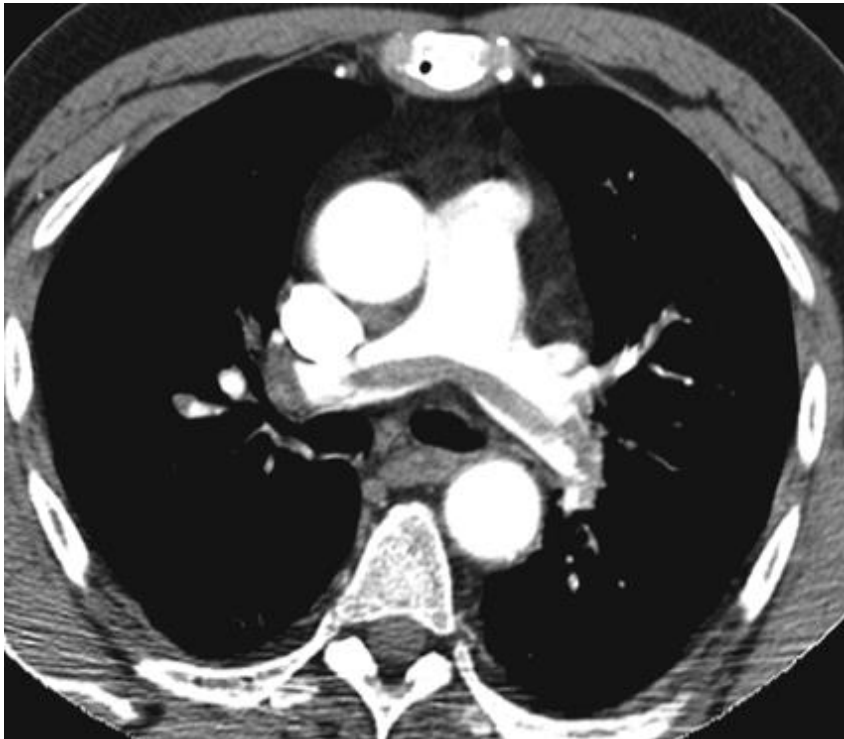


Interactive
CHEST IMAGING
lecture

366 COURSE

October 2021

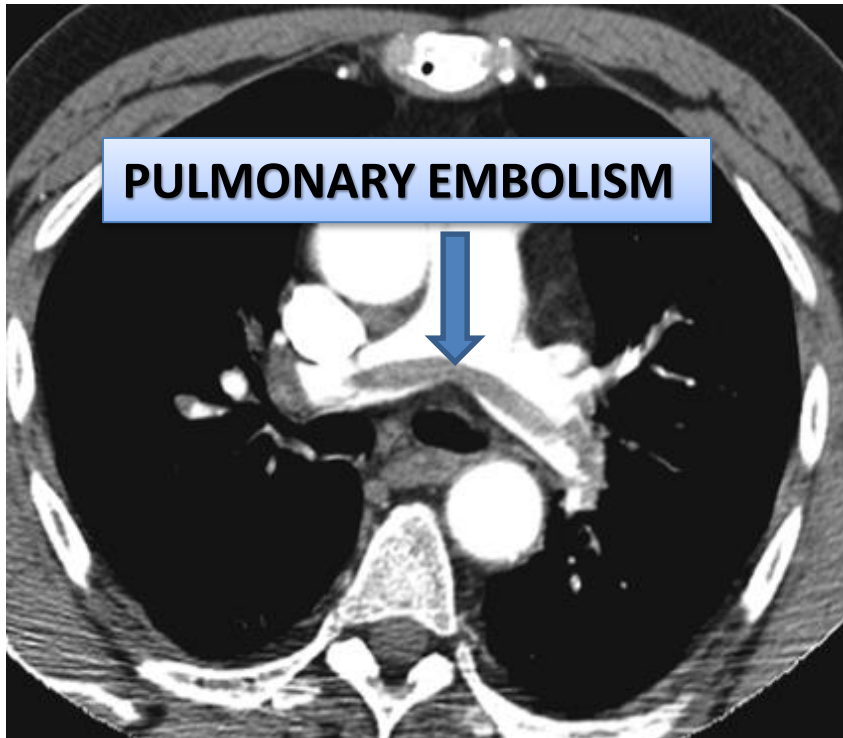
Question ?



- Patient presented to ER with acute chest pain and SOB
- Past history of pelvic fracture with hospital admission for 5 weeks.
- **Answer the following question by selecting the SINGLE BEST ANSWER**

1. -----
2. ----- **X**
3. -----
4. -----

Answer ?

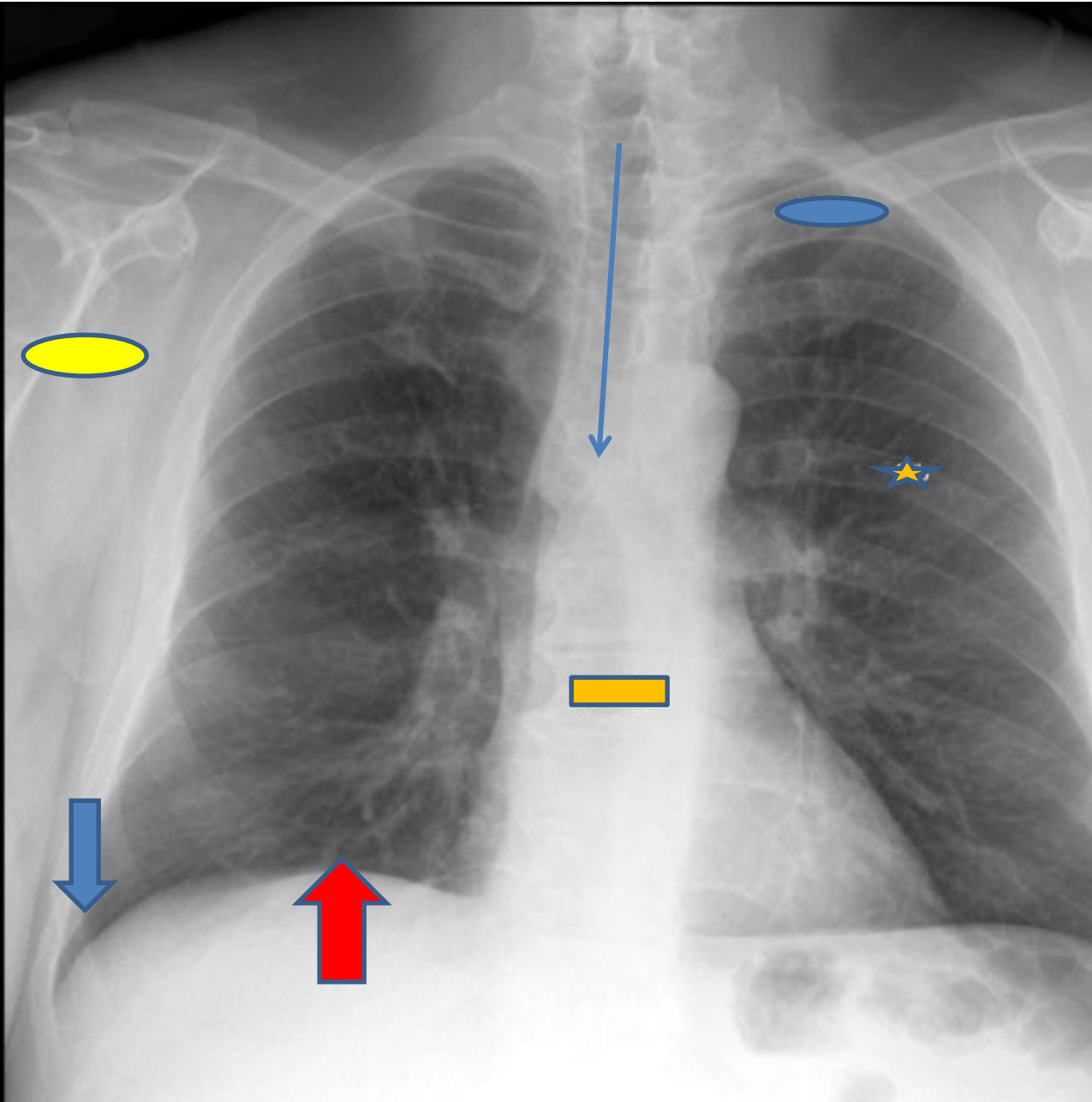


- Patient presented to ER with acute chest pain and SOB
- Past history of pelvic fracture with hospital admission for 5 weeks.

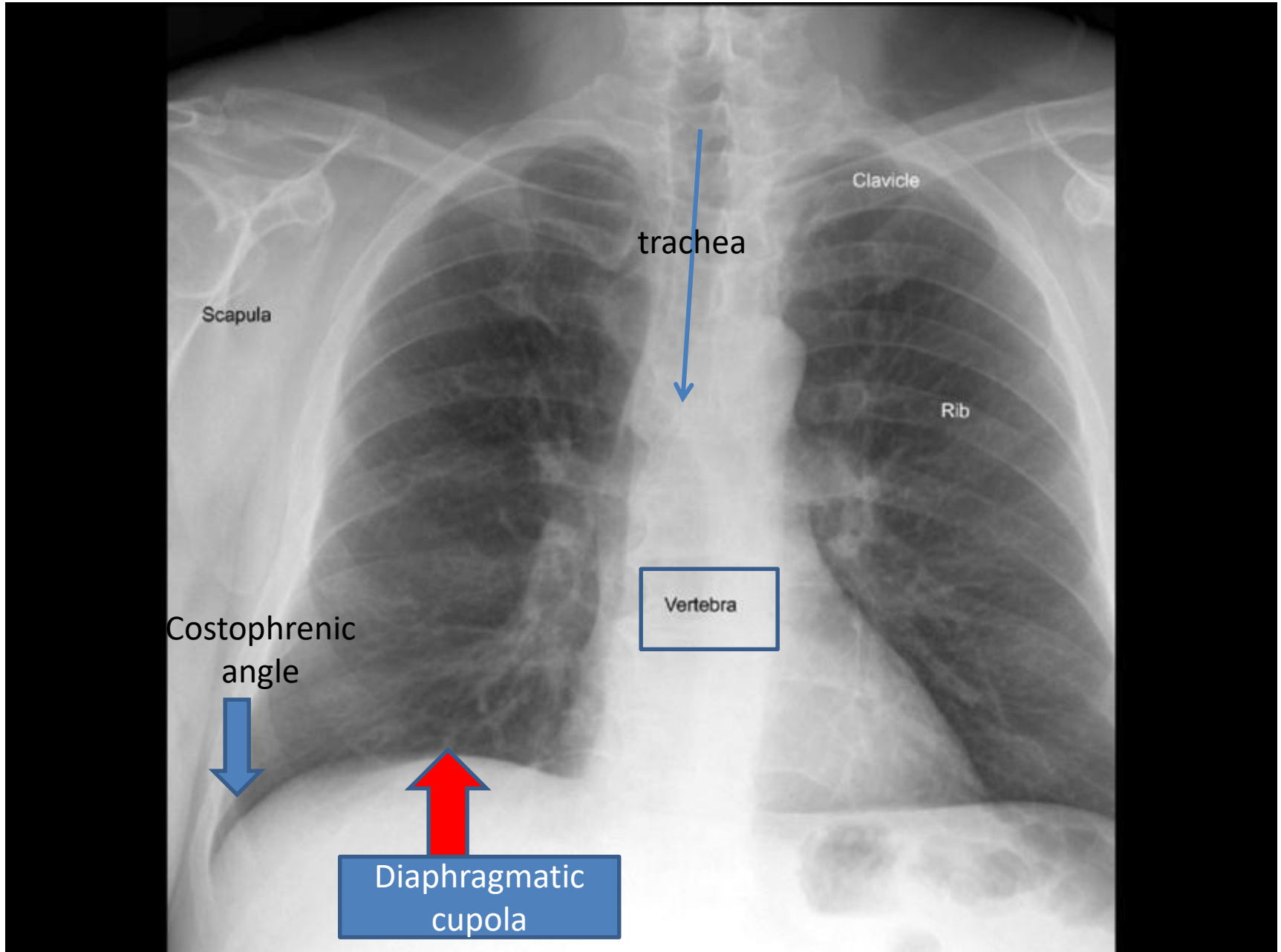
Q-SINGLE BEST ANSWER

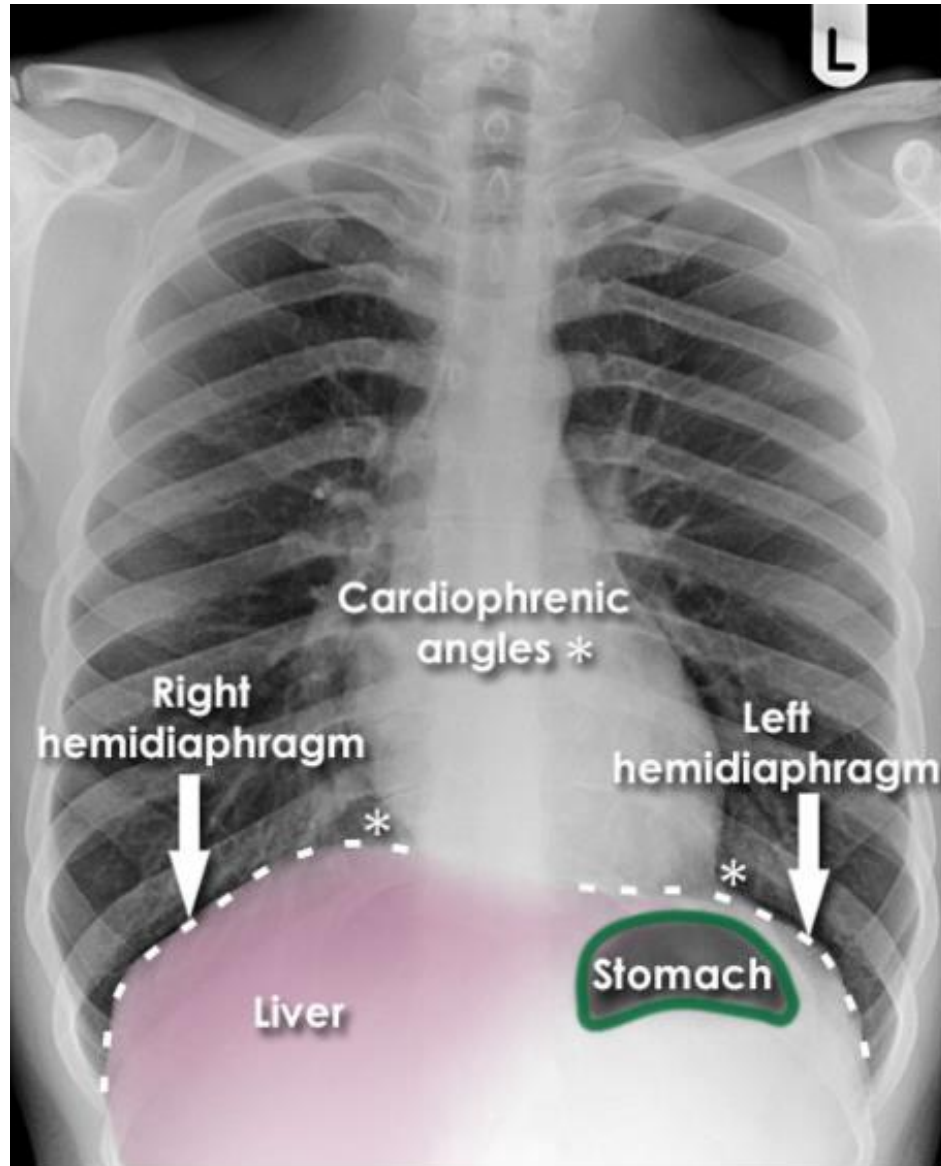
1. -----
2. CTA showing PULMONARY EMBOLISM **X**
3. -----
4. -----

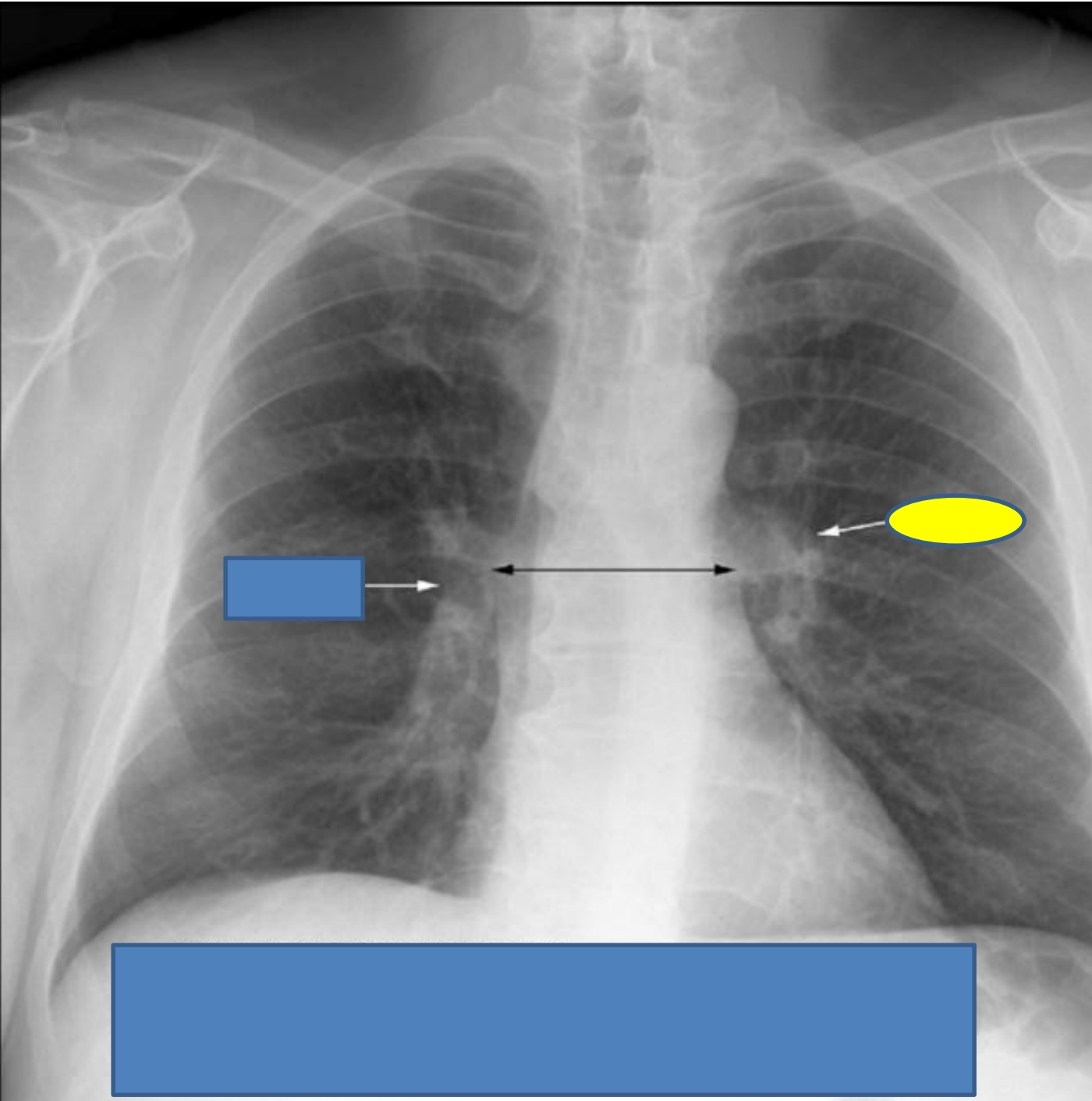
Anatomy



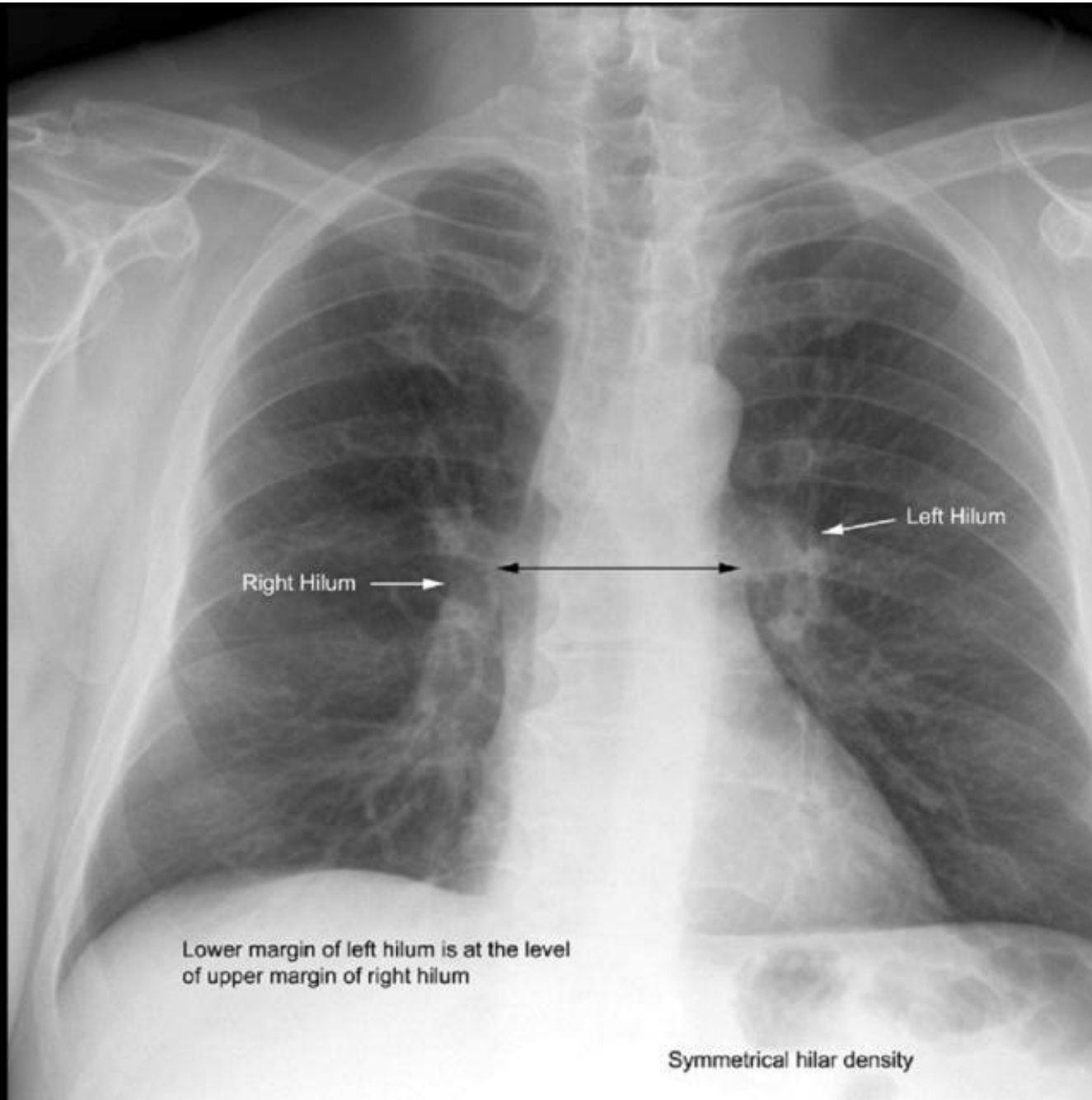
Anatomy



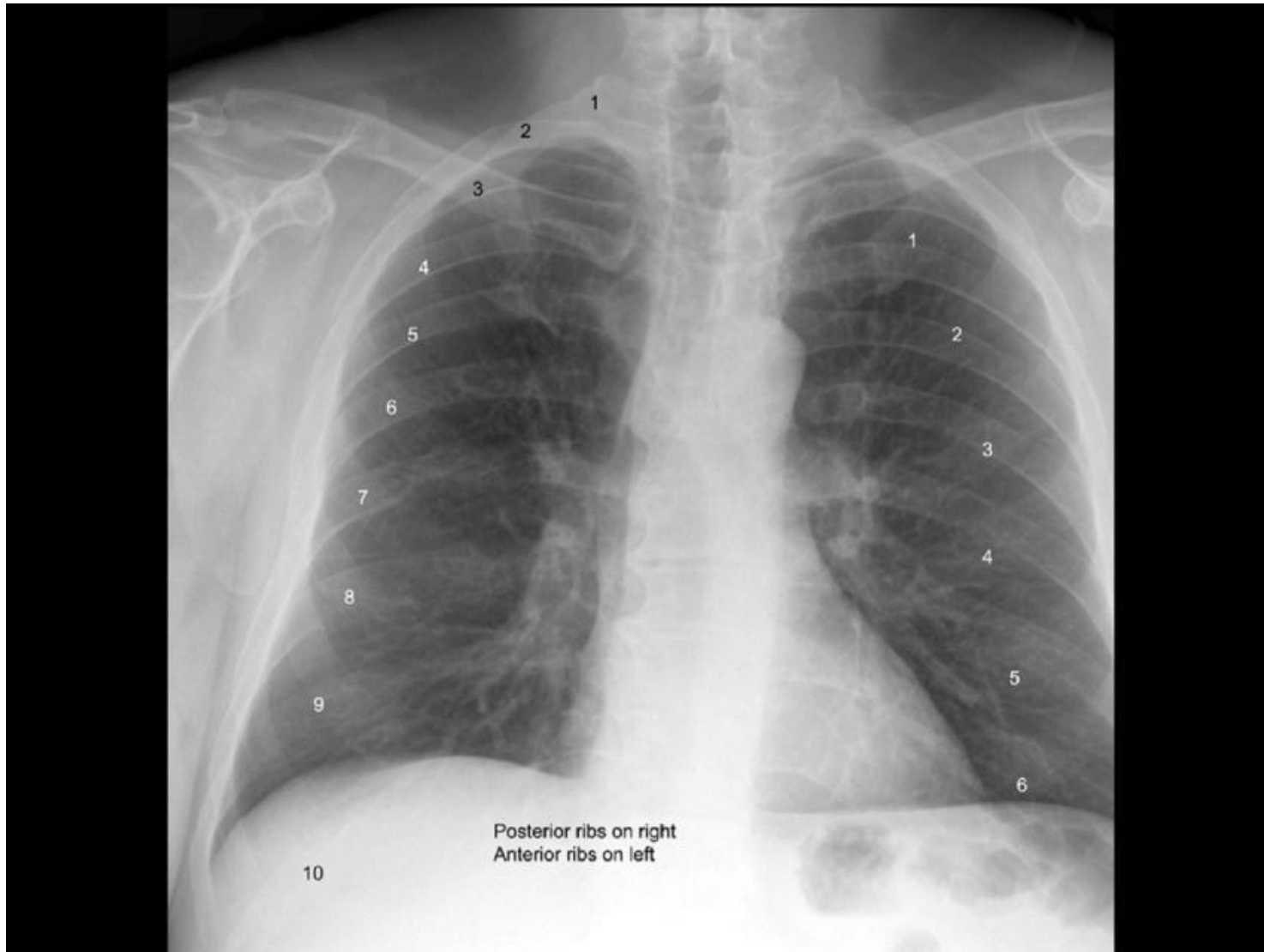




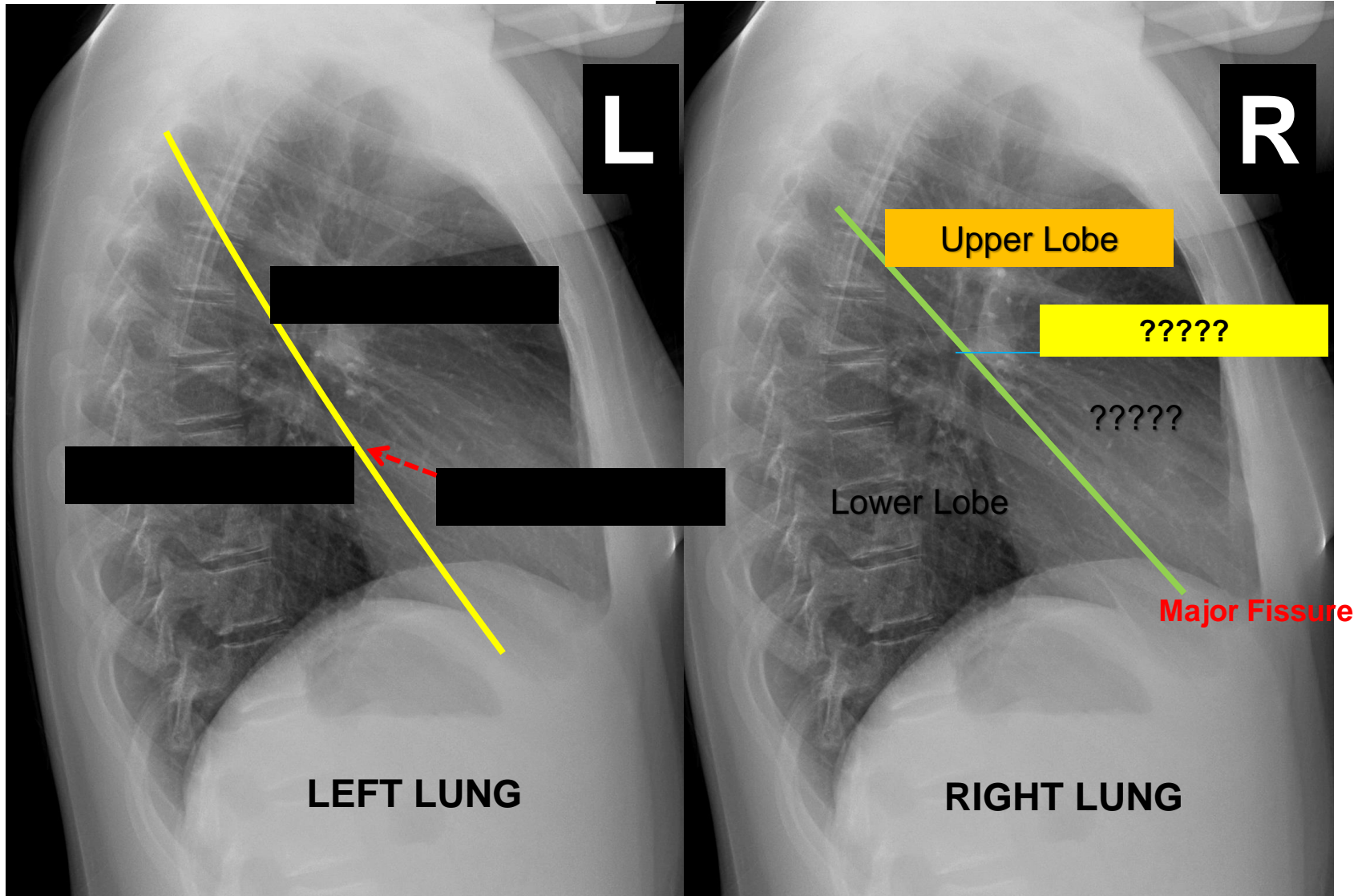
Hilum



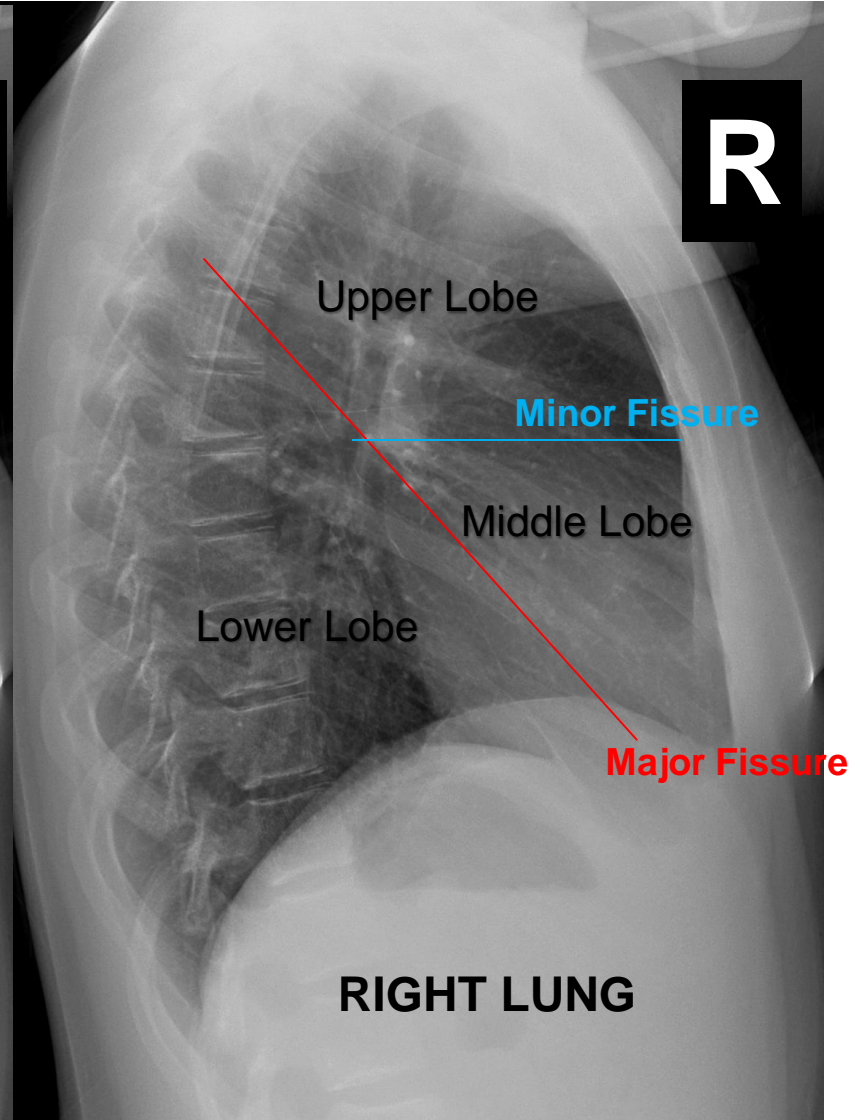
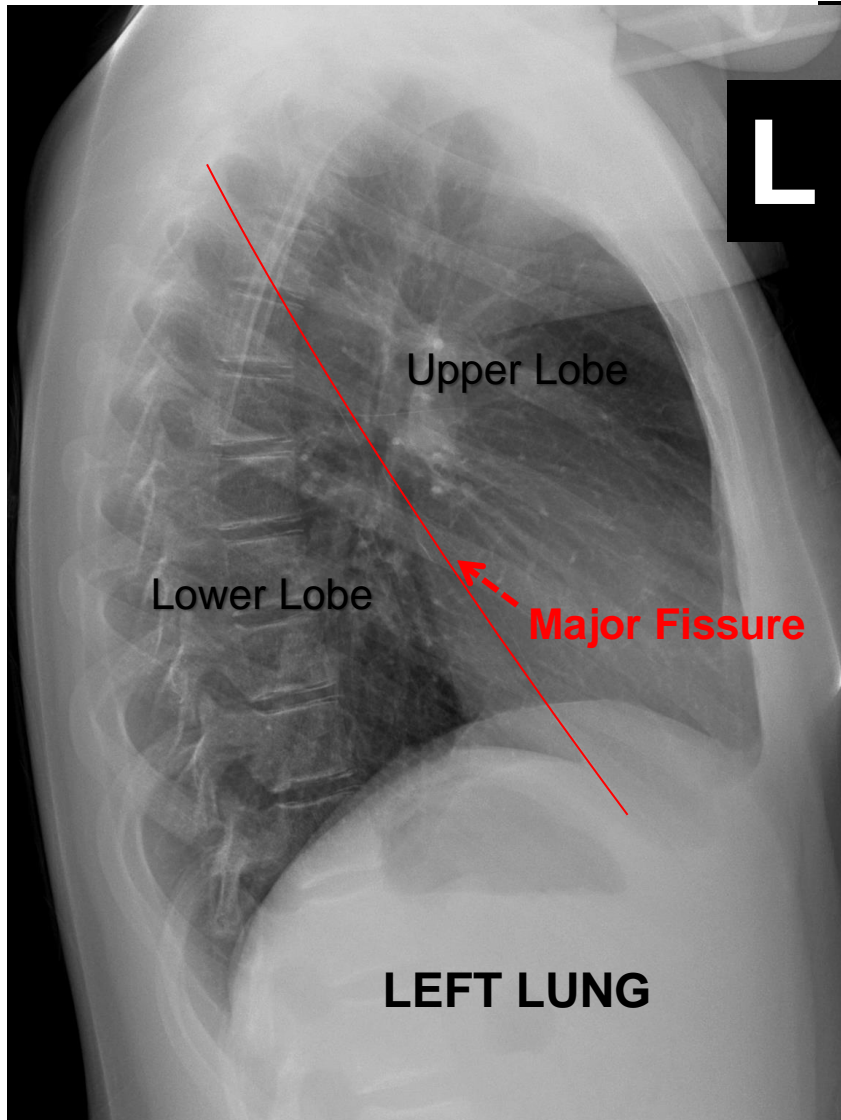
COUNTING RIBS



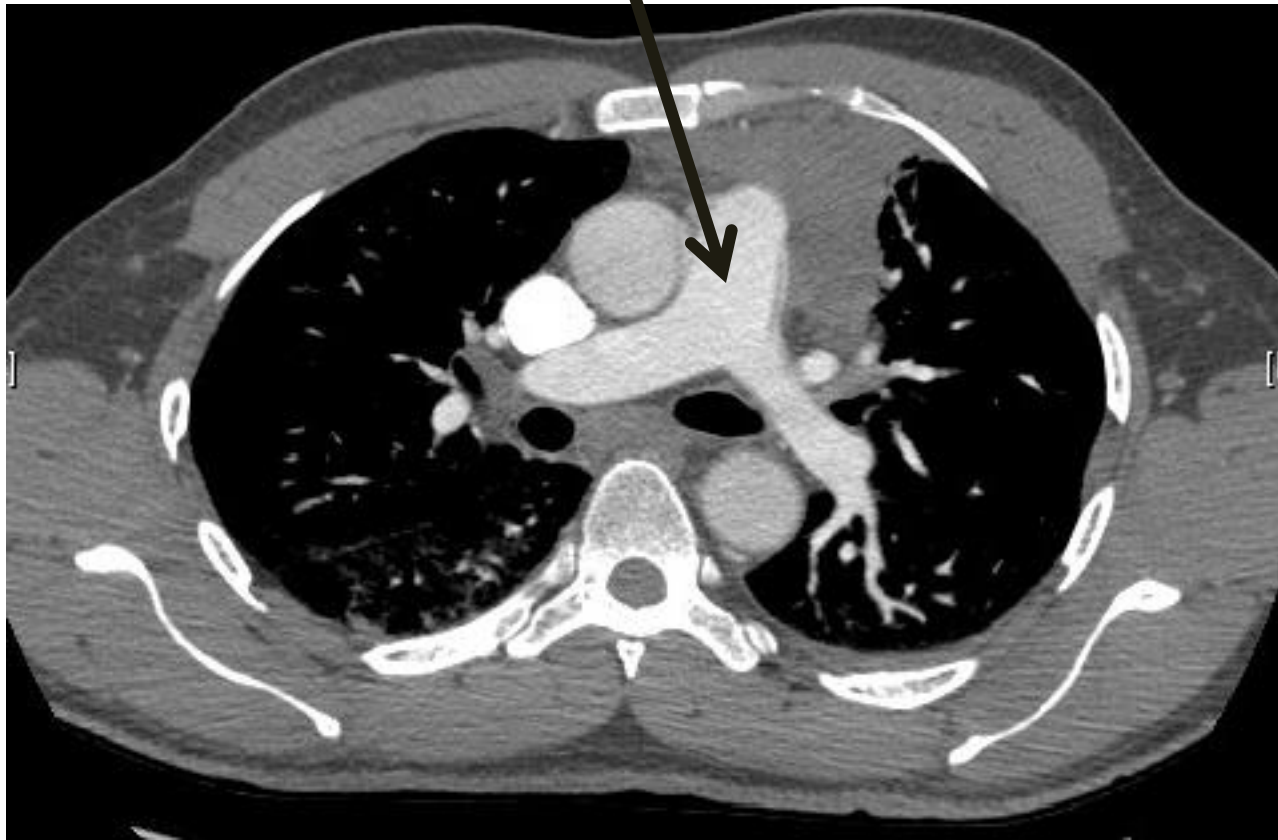
Radiological Anatomy of the Chest



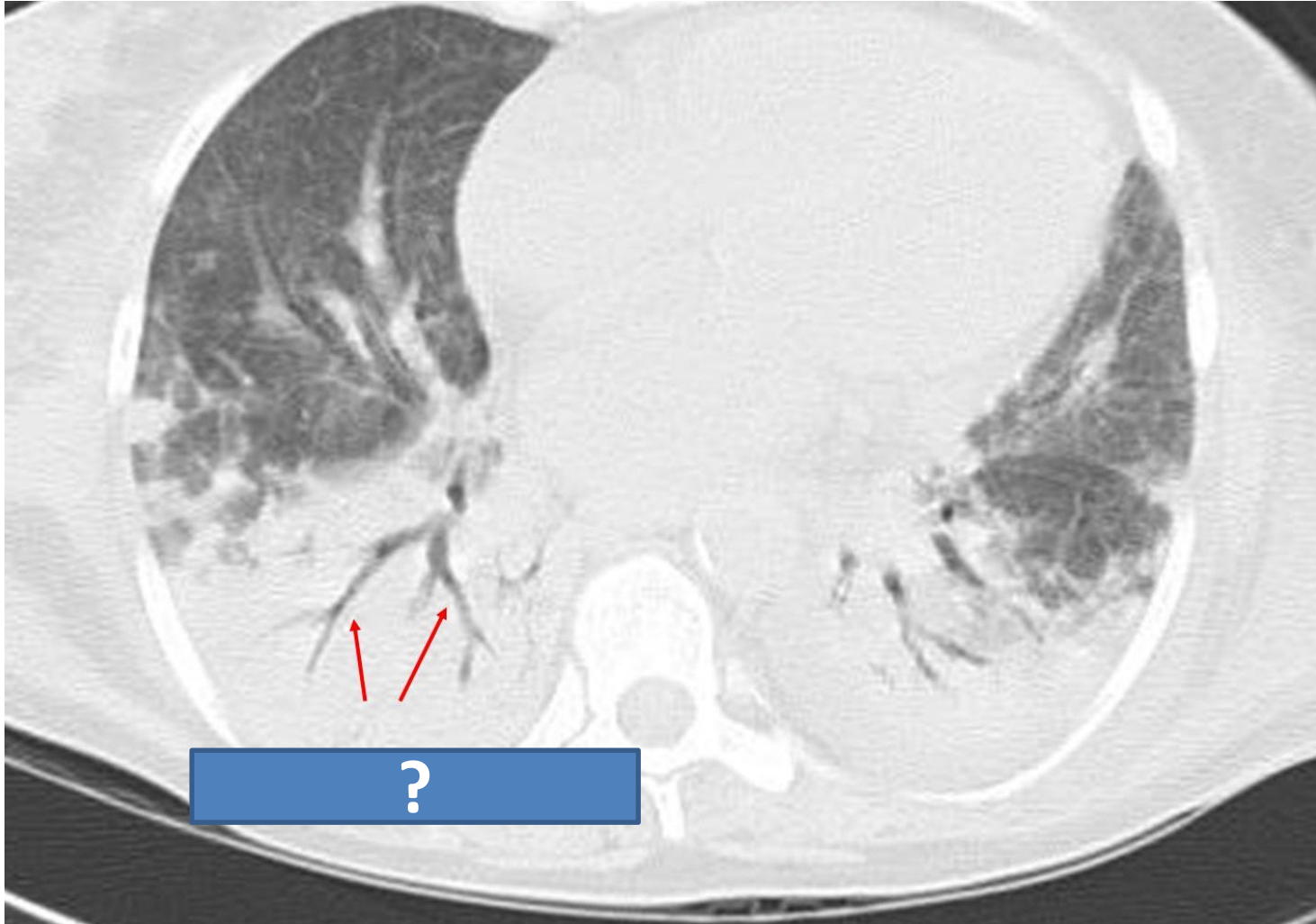
Radiological Anatomy of the Chest

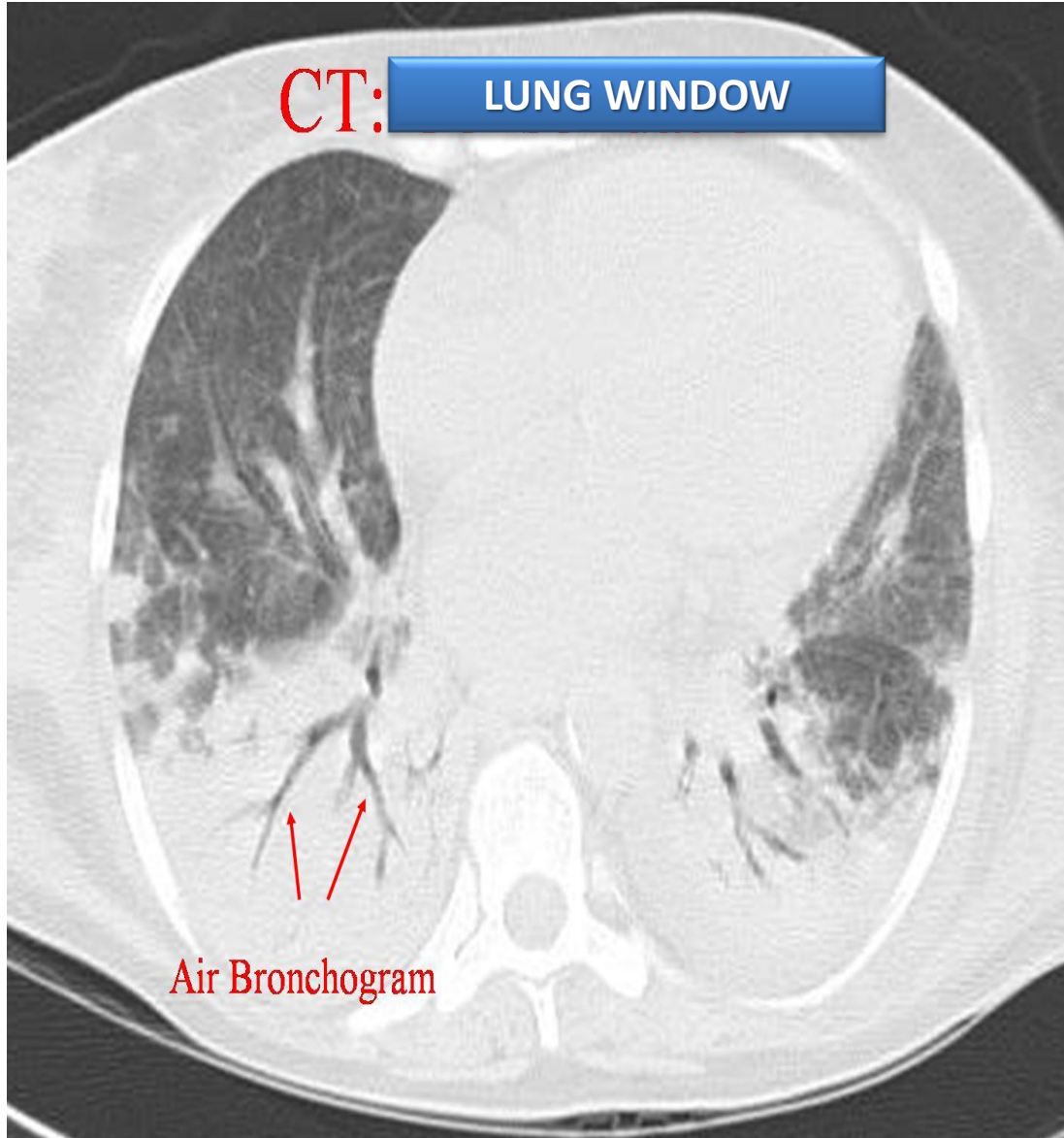


EXAM?
NORMAL/ABNORMAL?

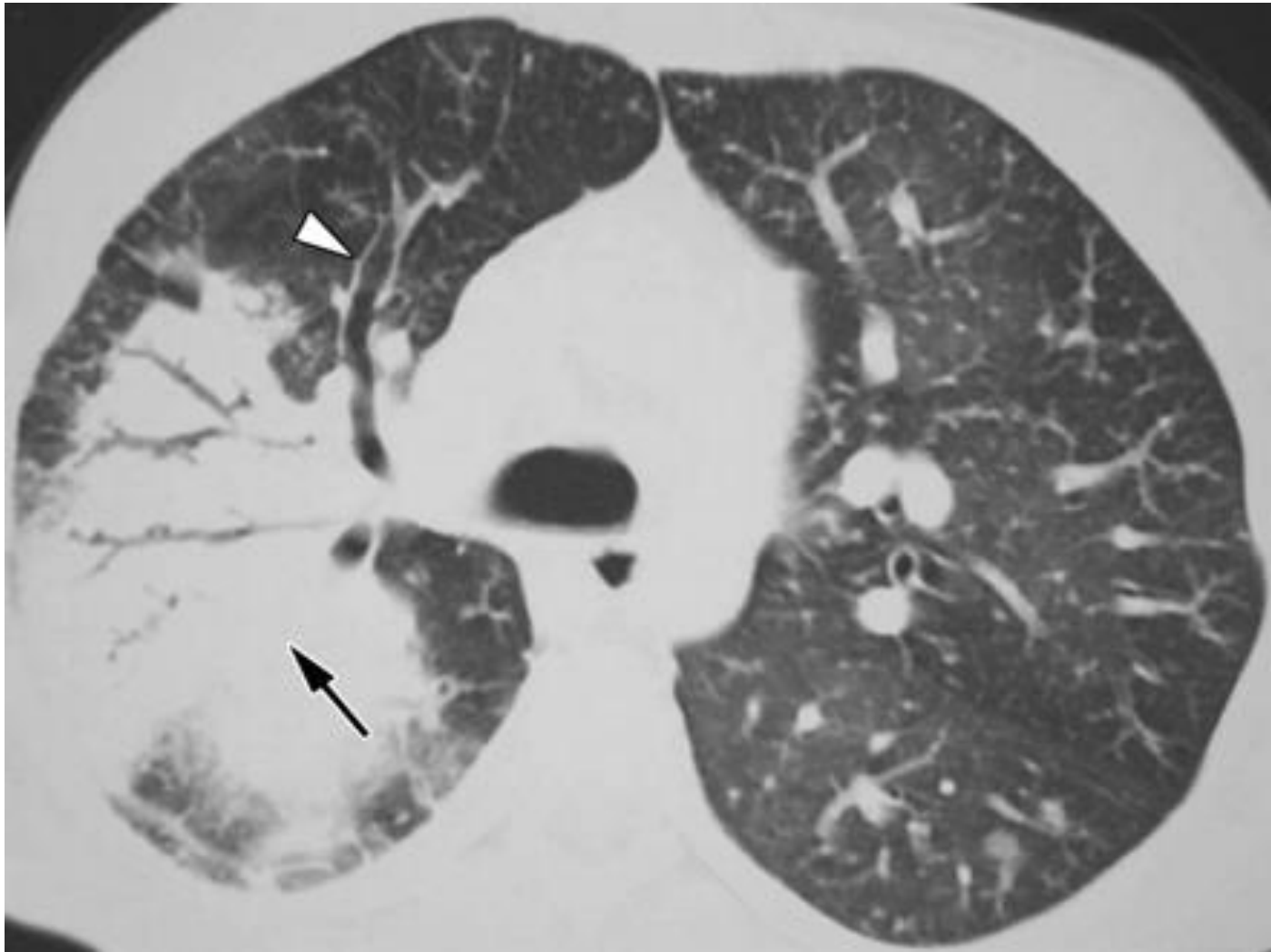


1-EXAM
2-SIGN?
3-DIAGNOSIS?



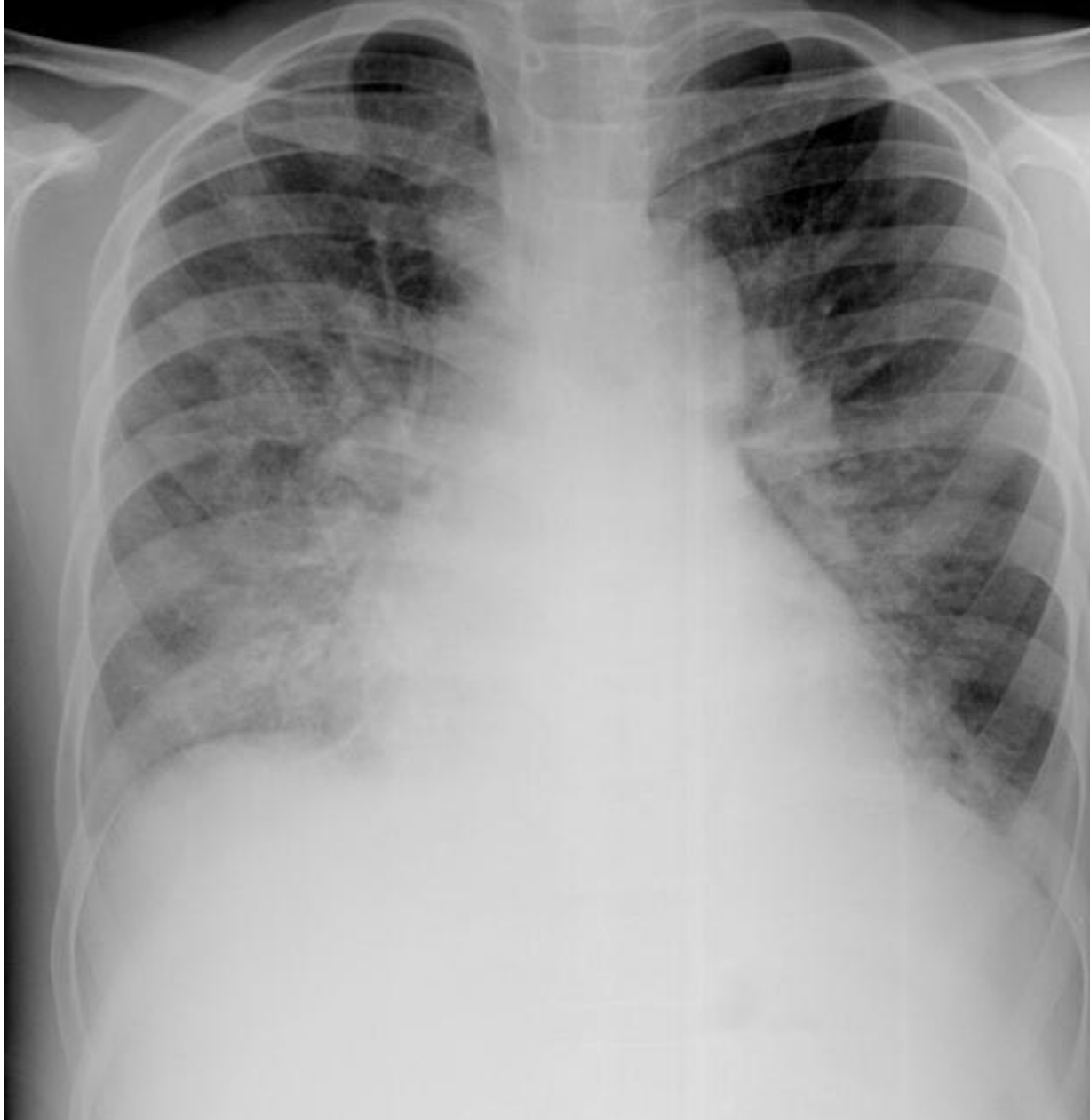

Consolidation

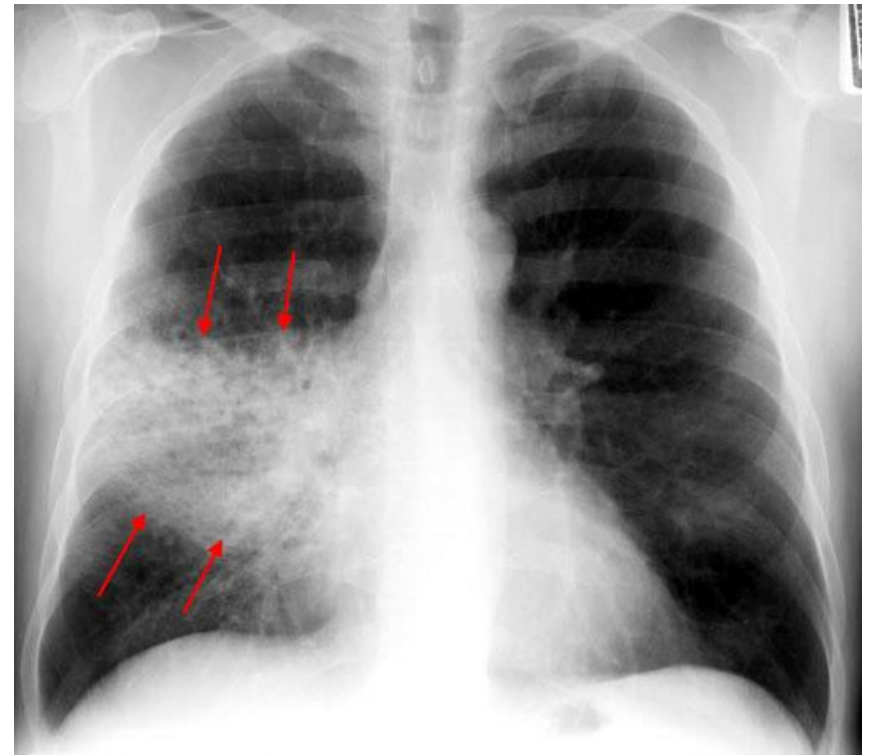
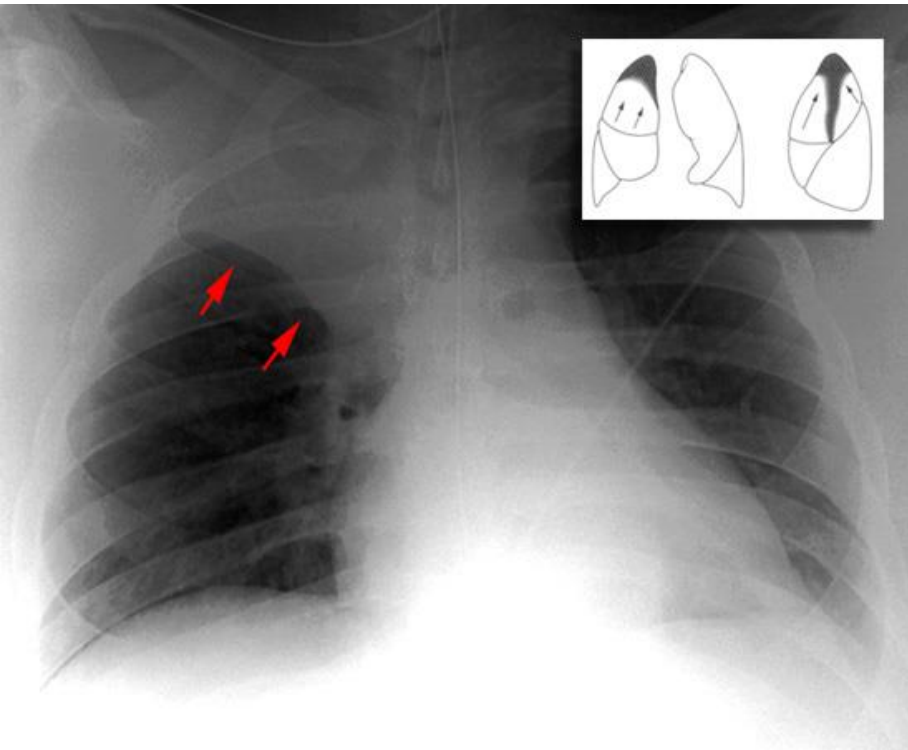


1-EXAM
2-SIGN?
3-DIAGNOSIS?

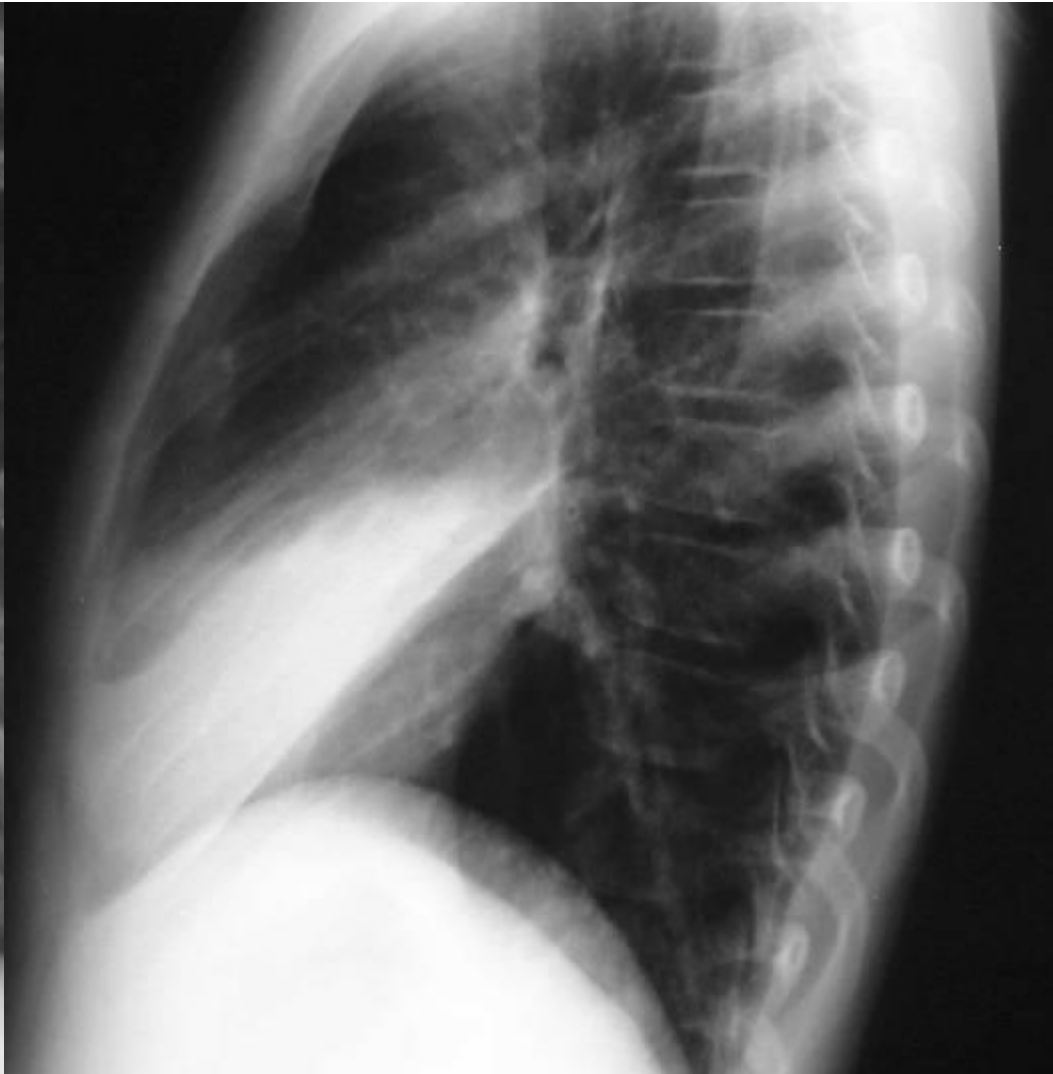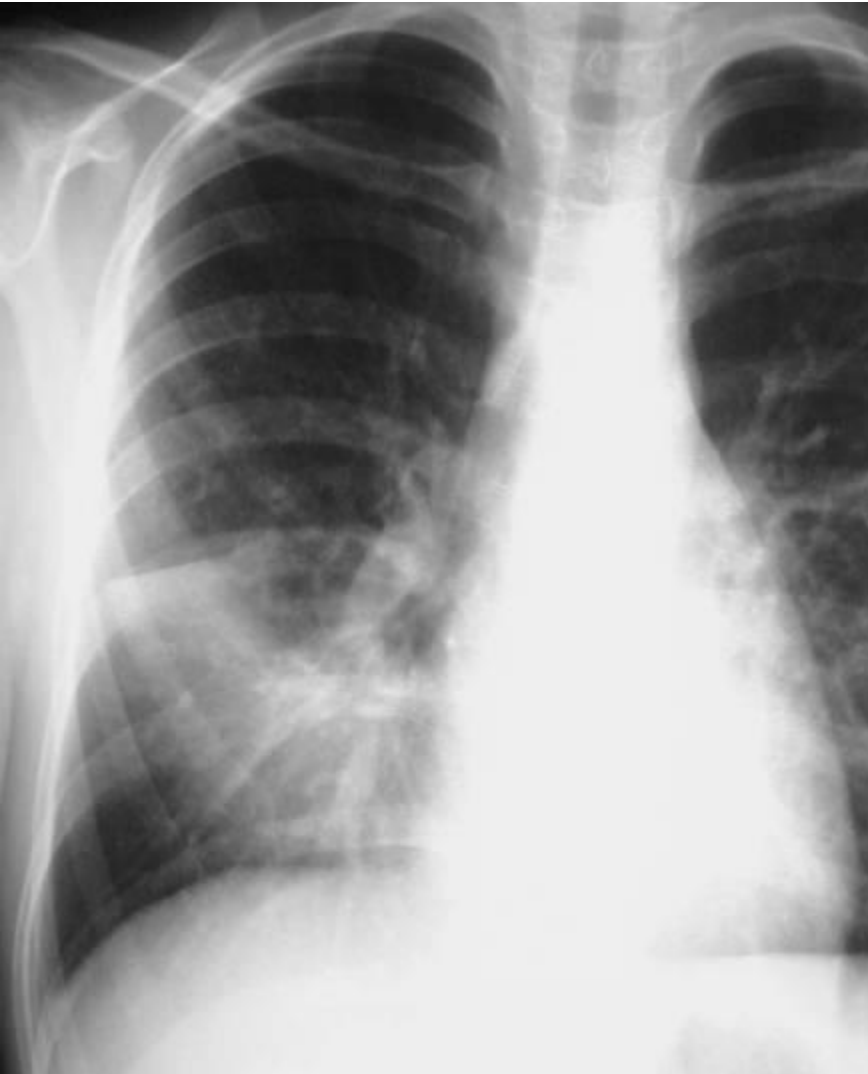MASS OR INFILTRATION



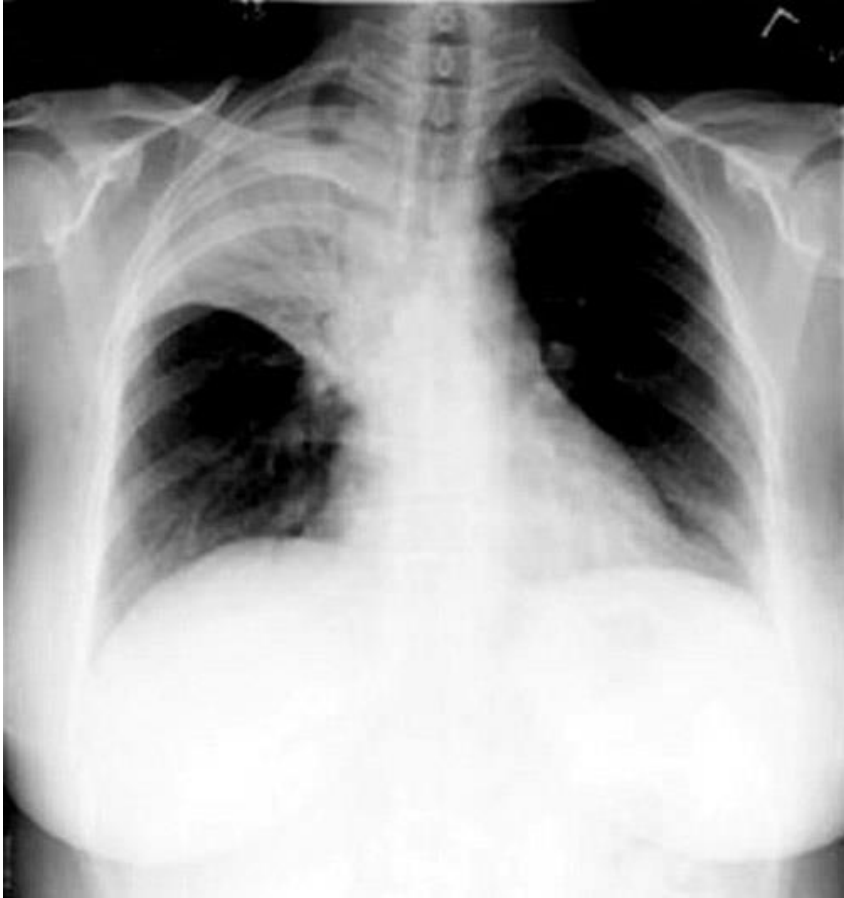ATELECTASIS Vs PNEUMONIA



Right ????? lobe ??????

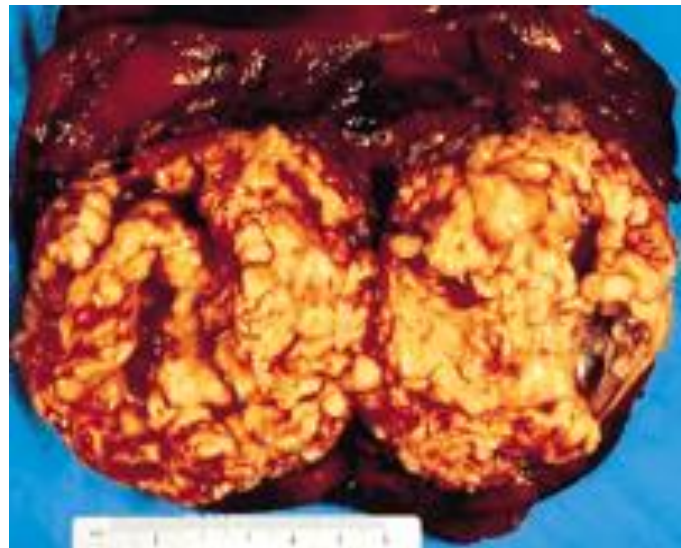
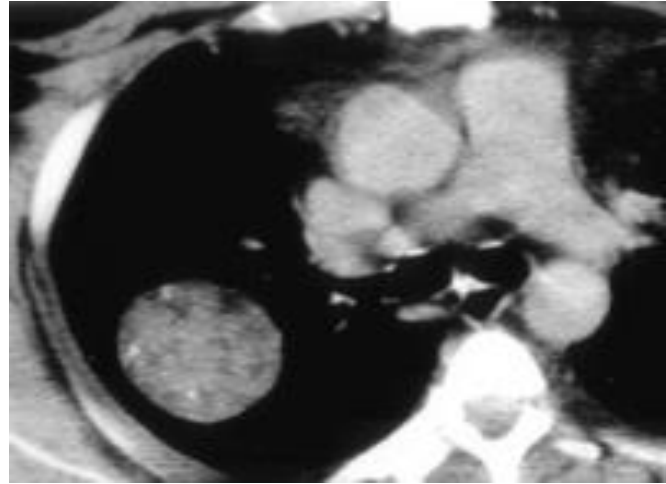
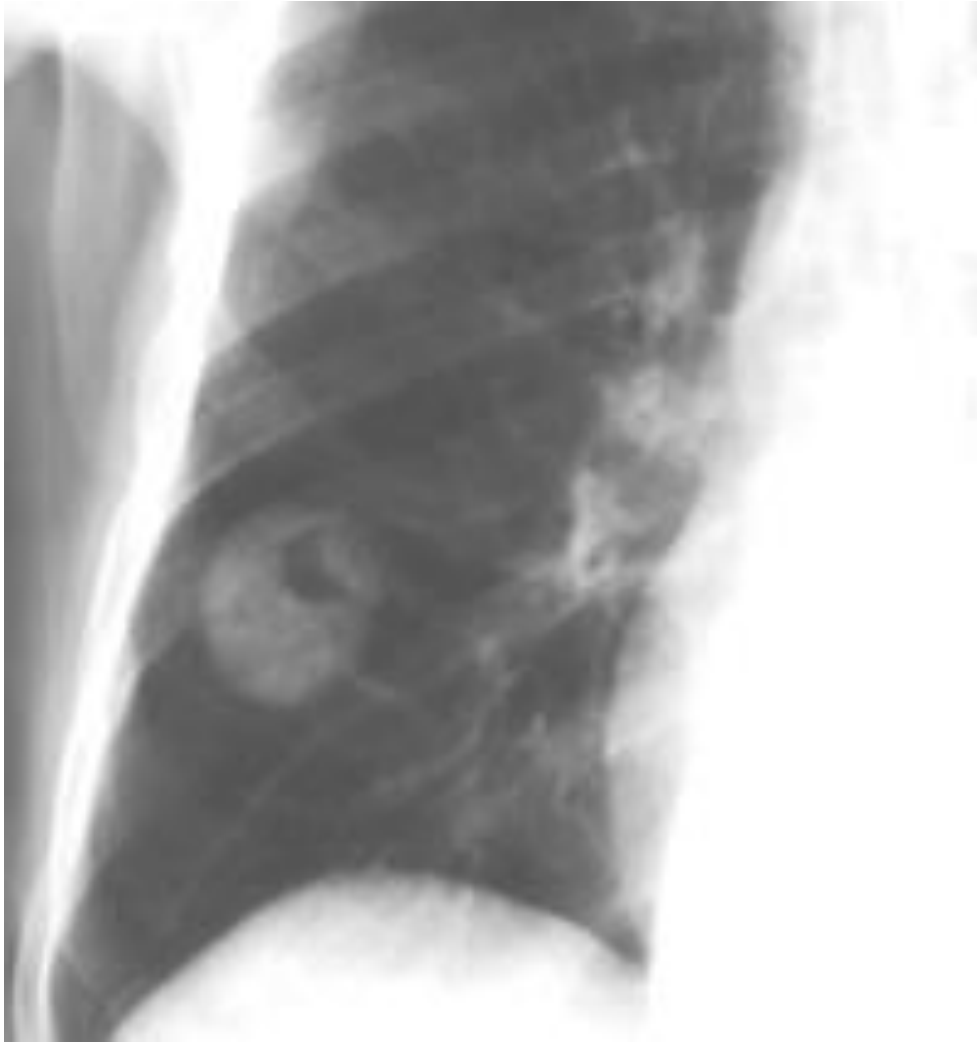

DIAGNOSIS

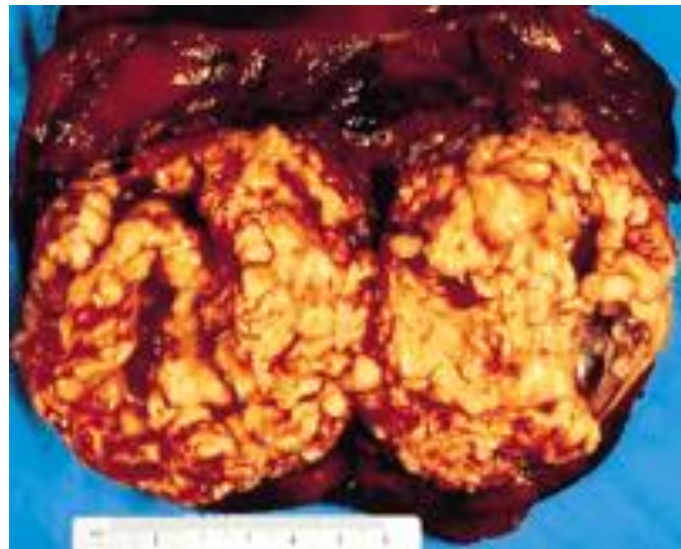
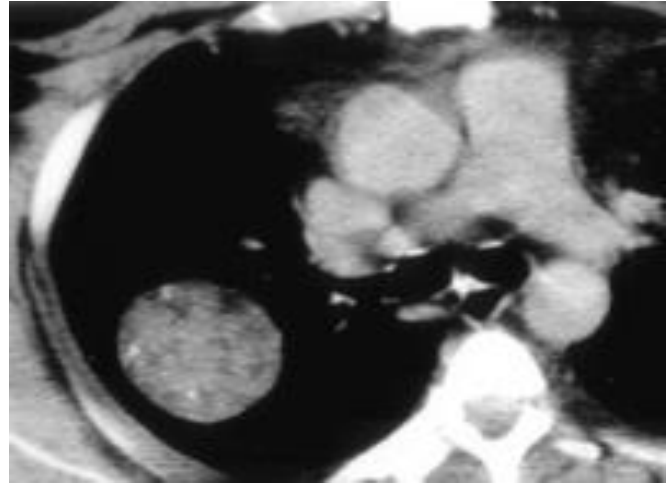


- 37 YEARS OLD PATIENT WITH SOB AND FEVER.

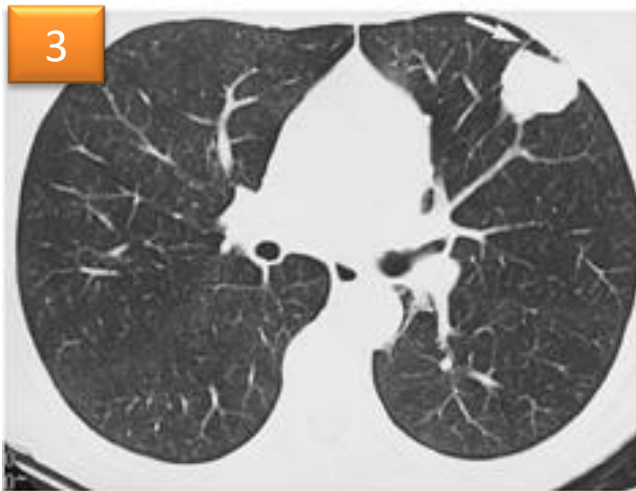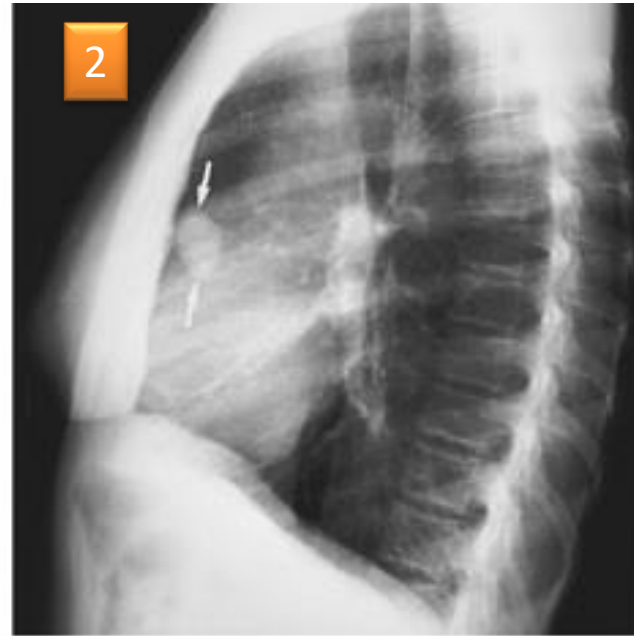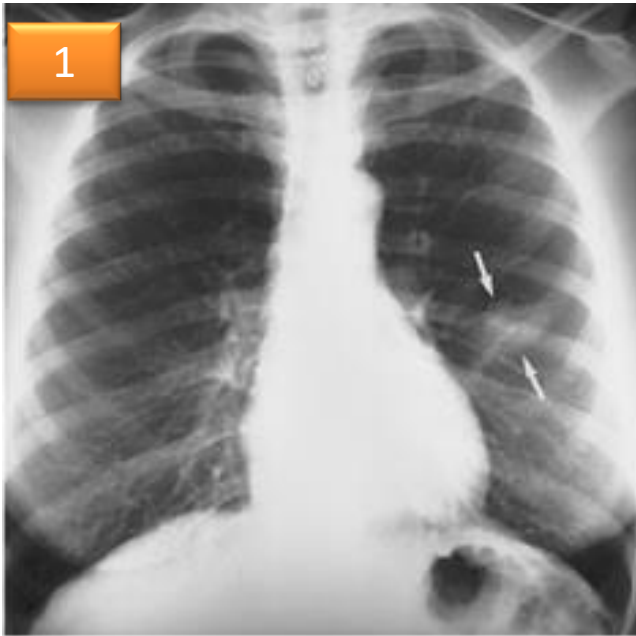
MASS OR INFILTRATION ?



Neoplastic: MASS

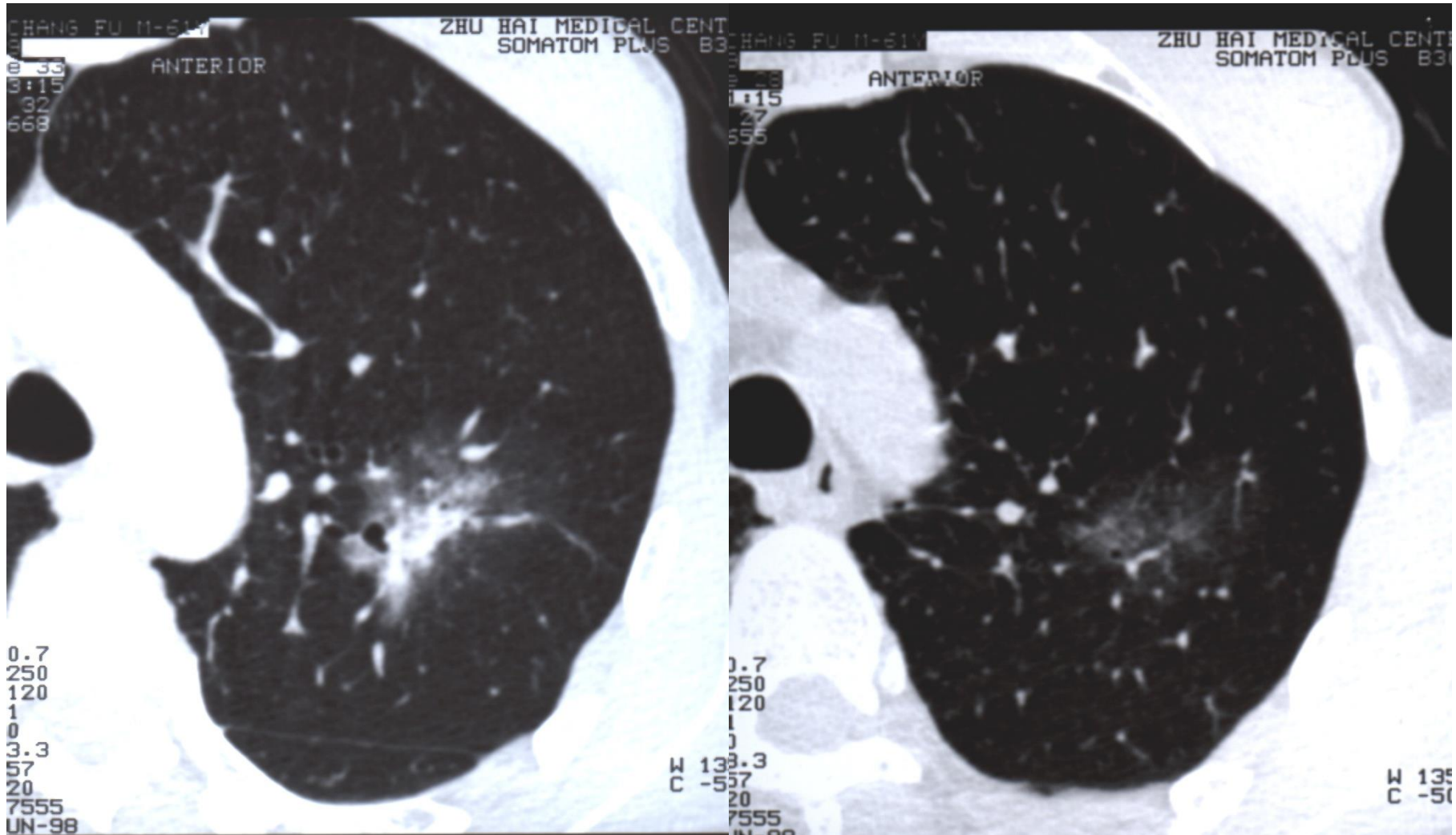


MASS OR INFILTRATION ? STEPS

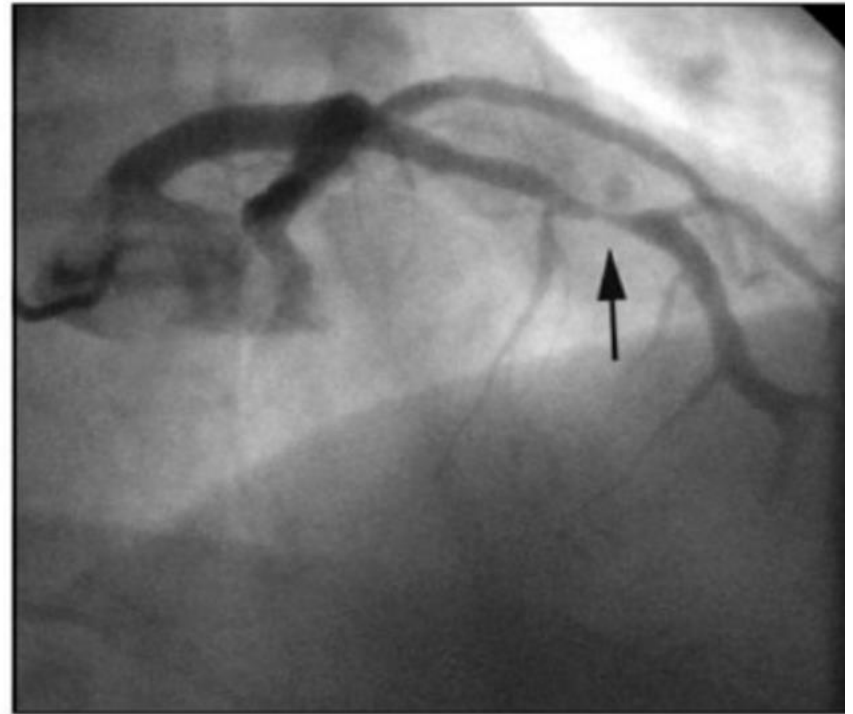
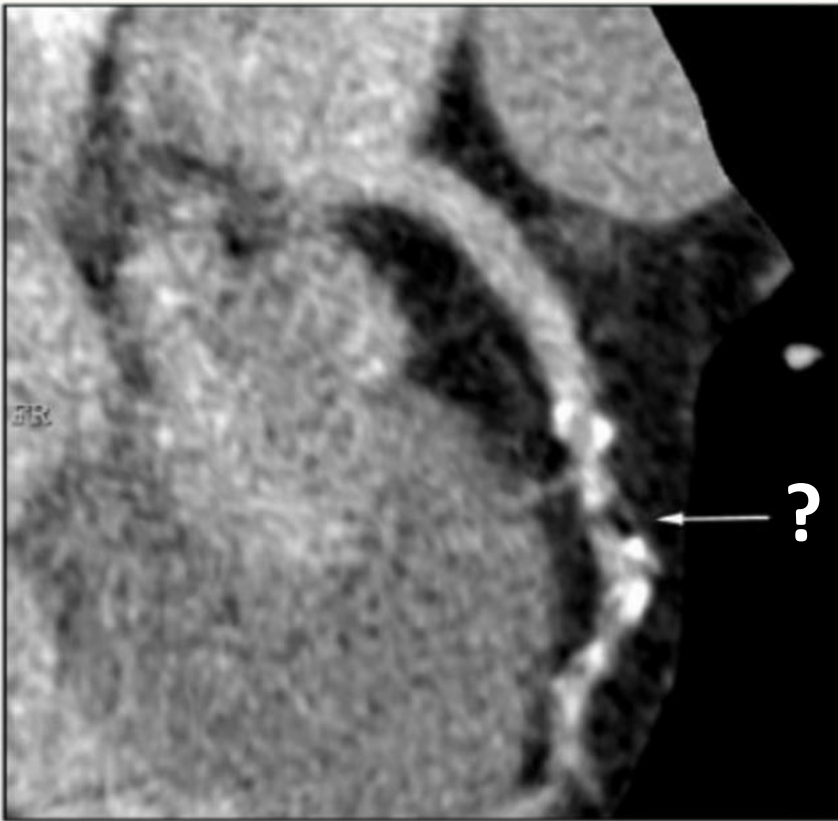


← ---?--- WINDOW

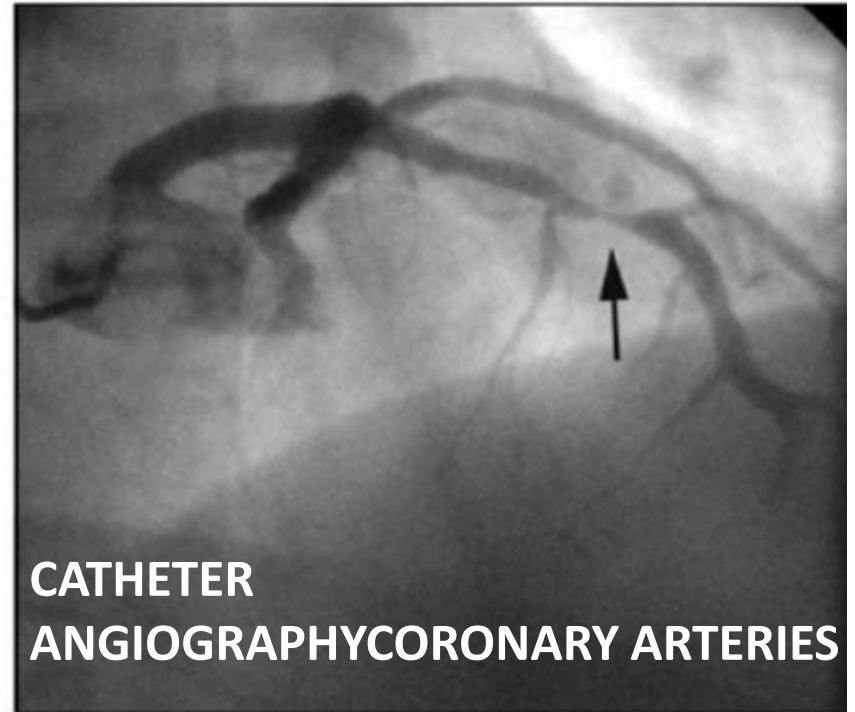
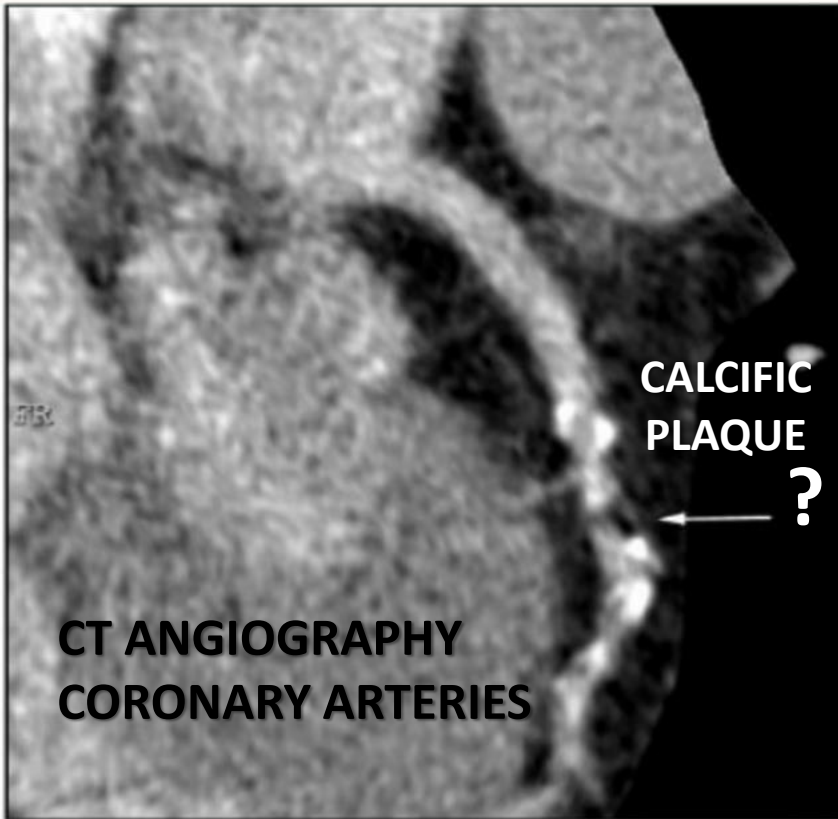
MASS OR INFILTRATION?

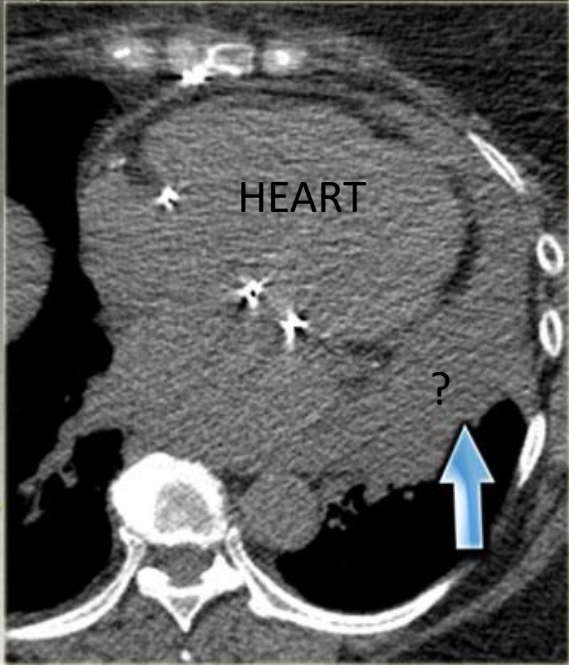
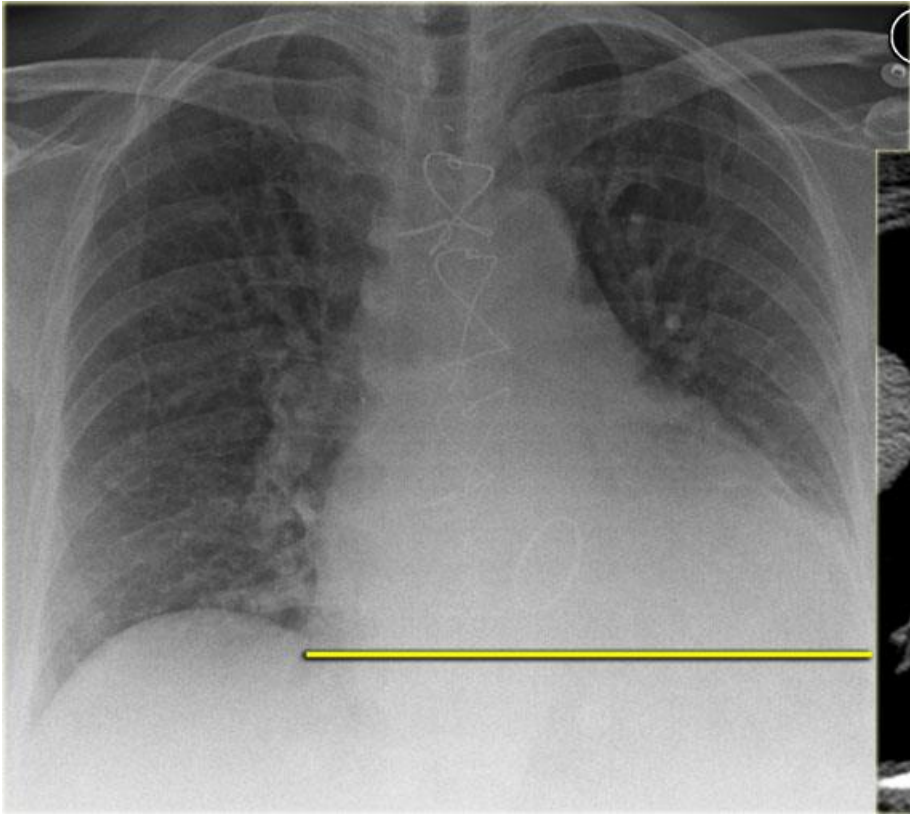


EXAM?

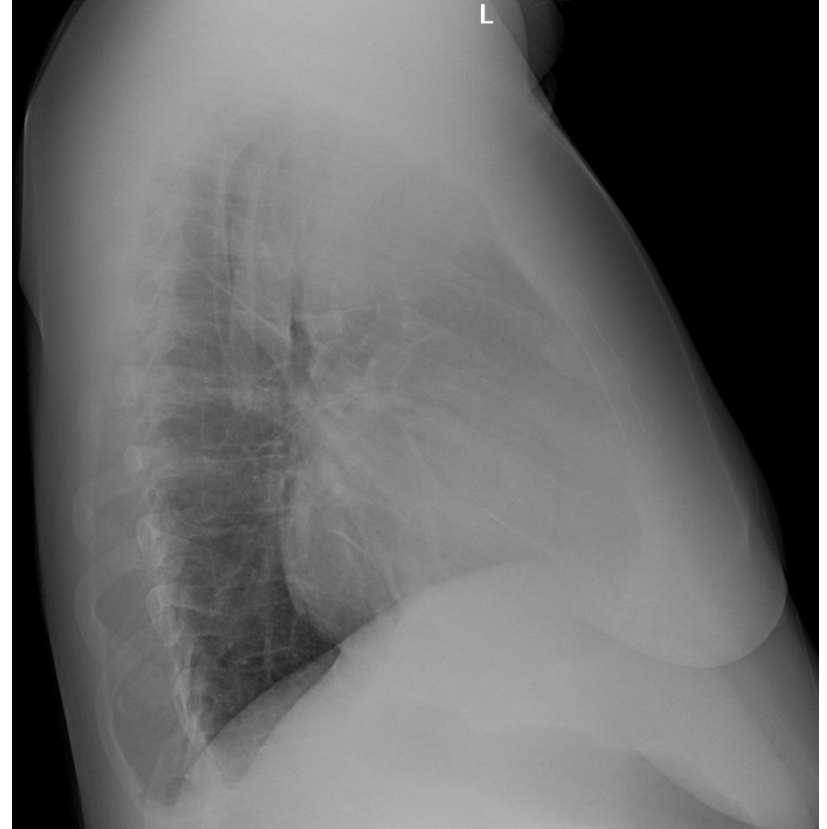
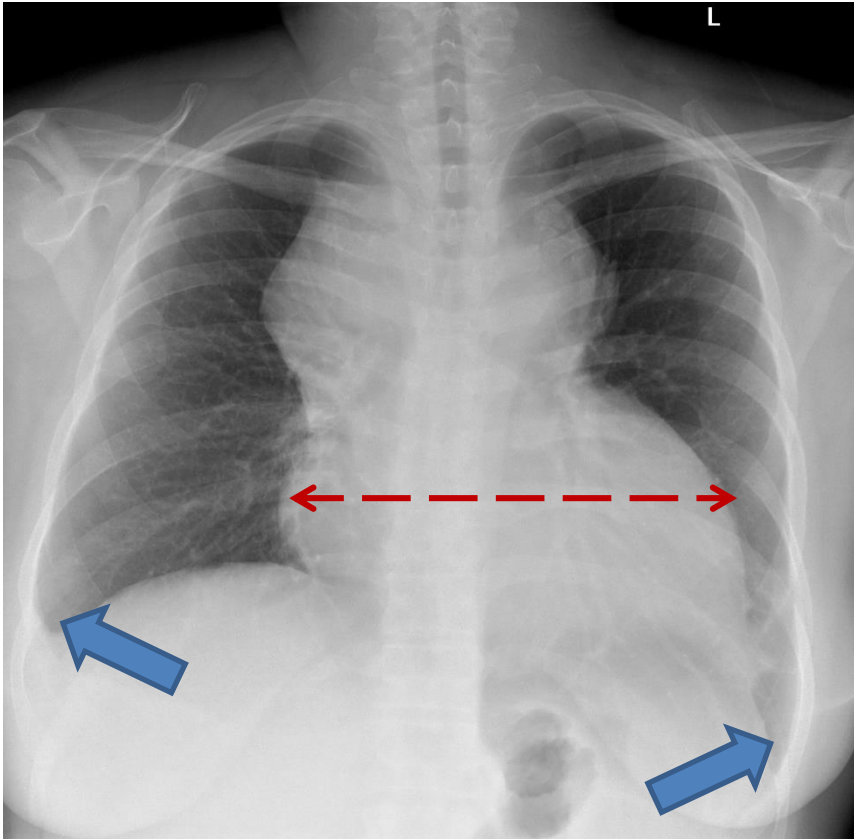


EXAM?

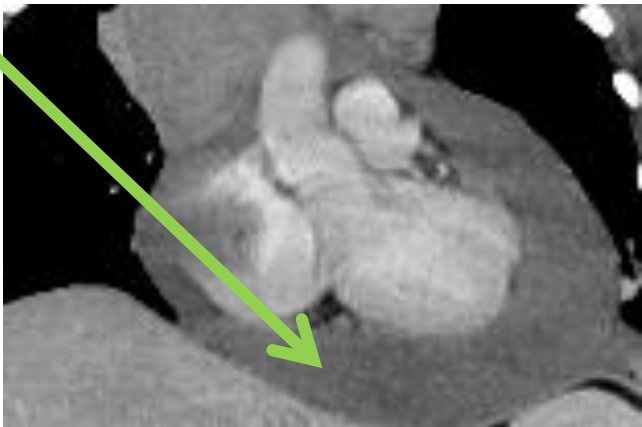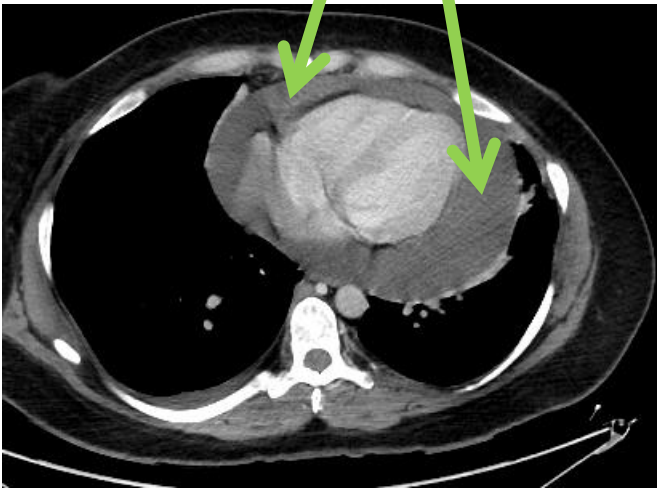
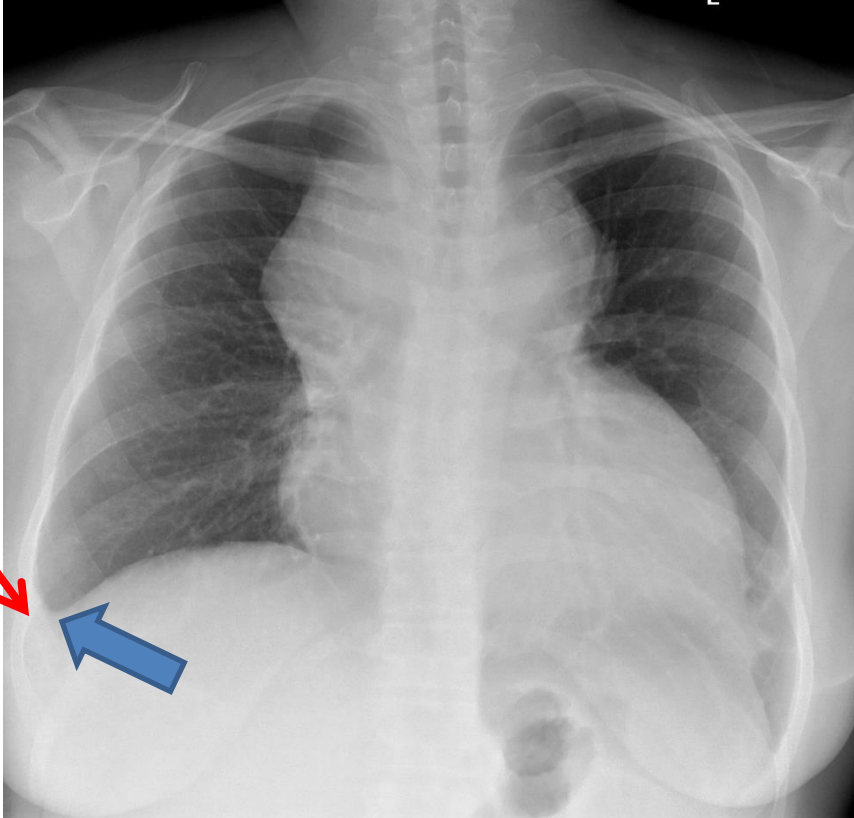




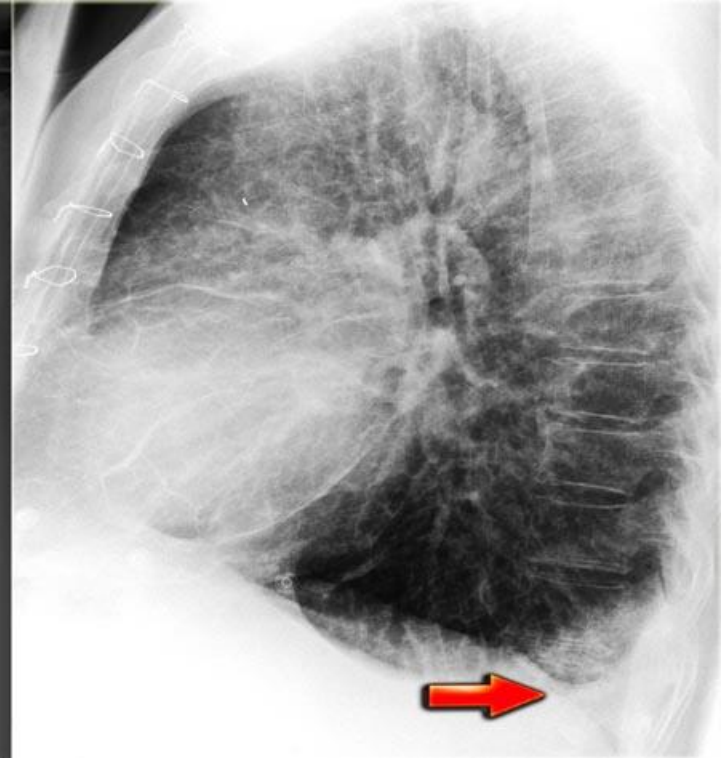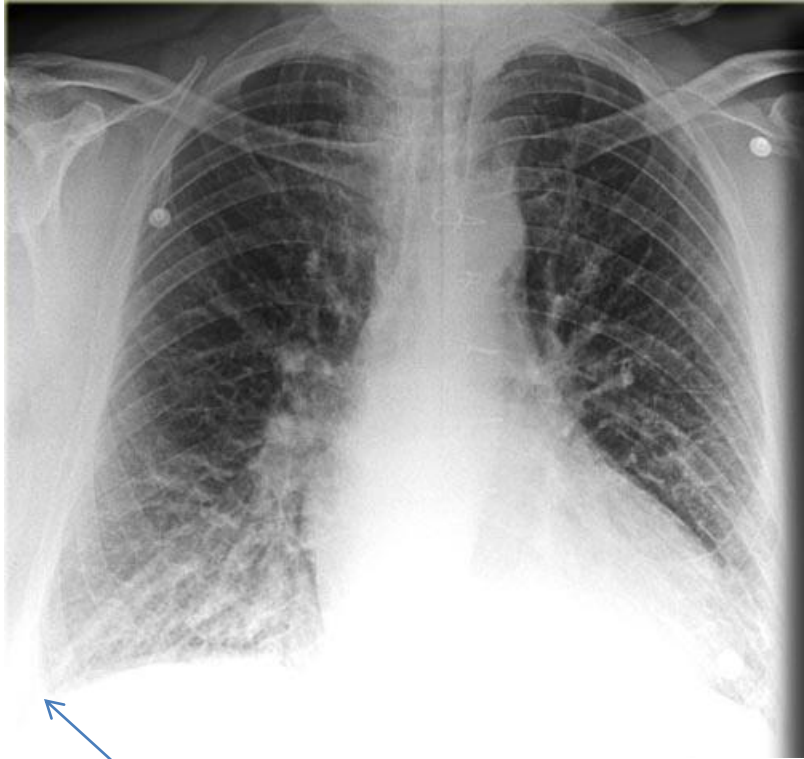
Heart ?



Pleural effusion and pericardial effusion

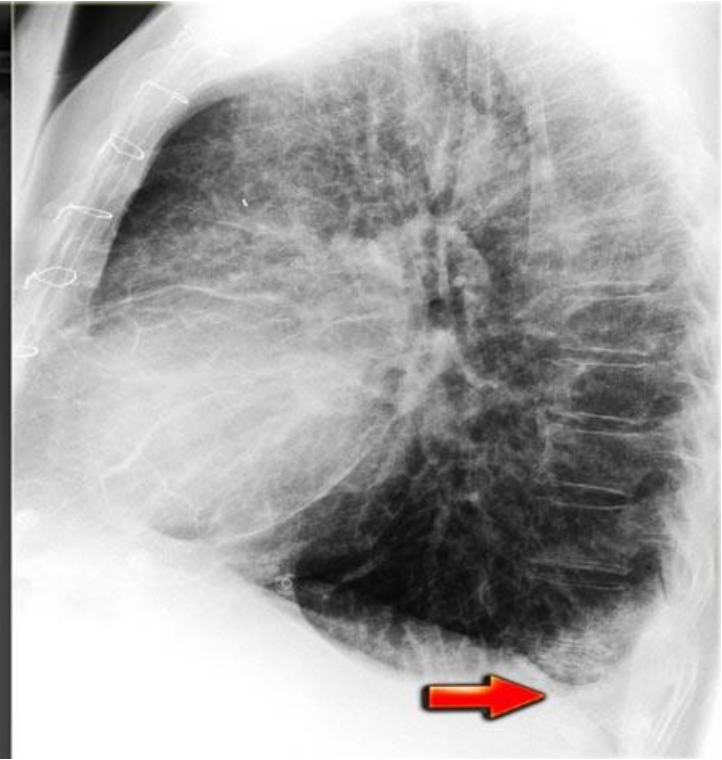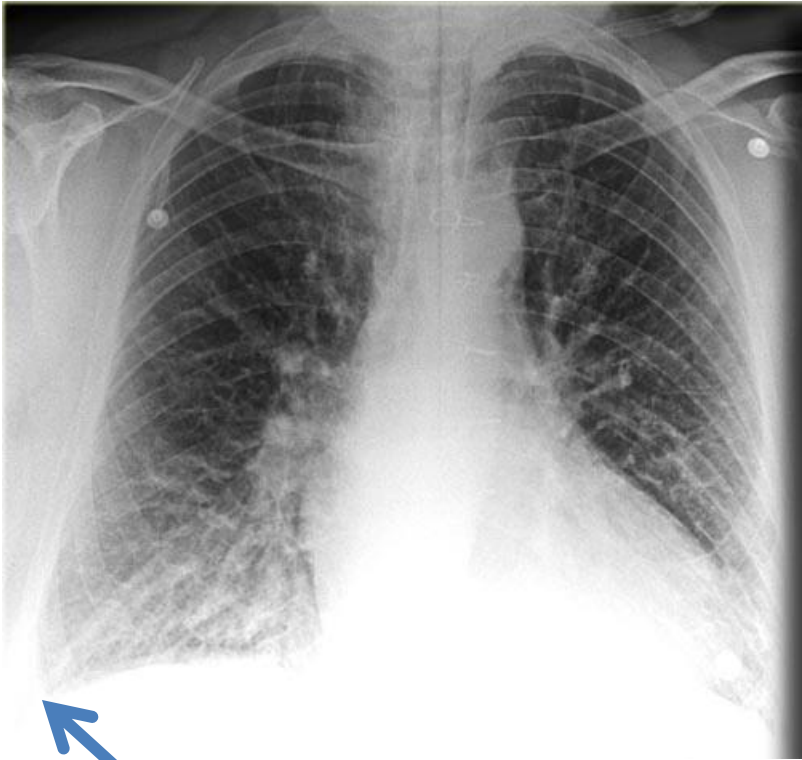


ABNORMAL? DIAGNOSIS?

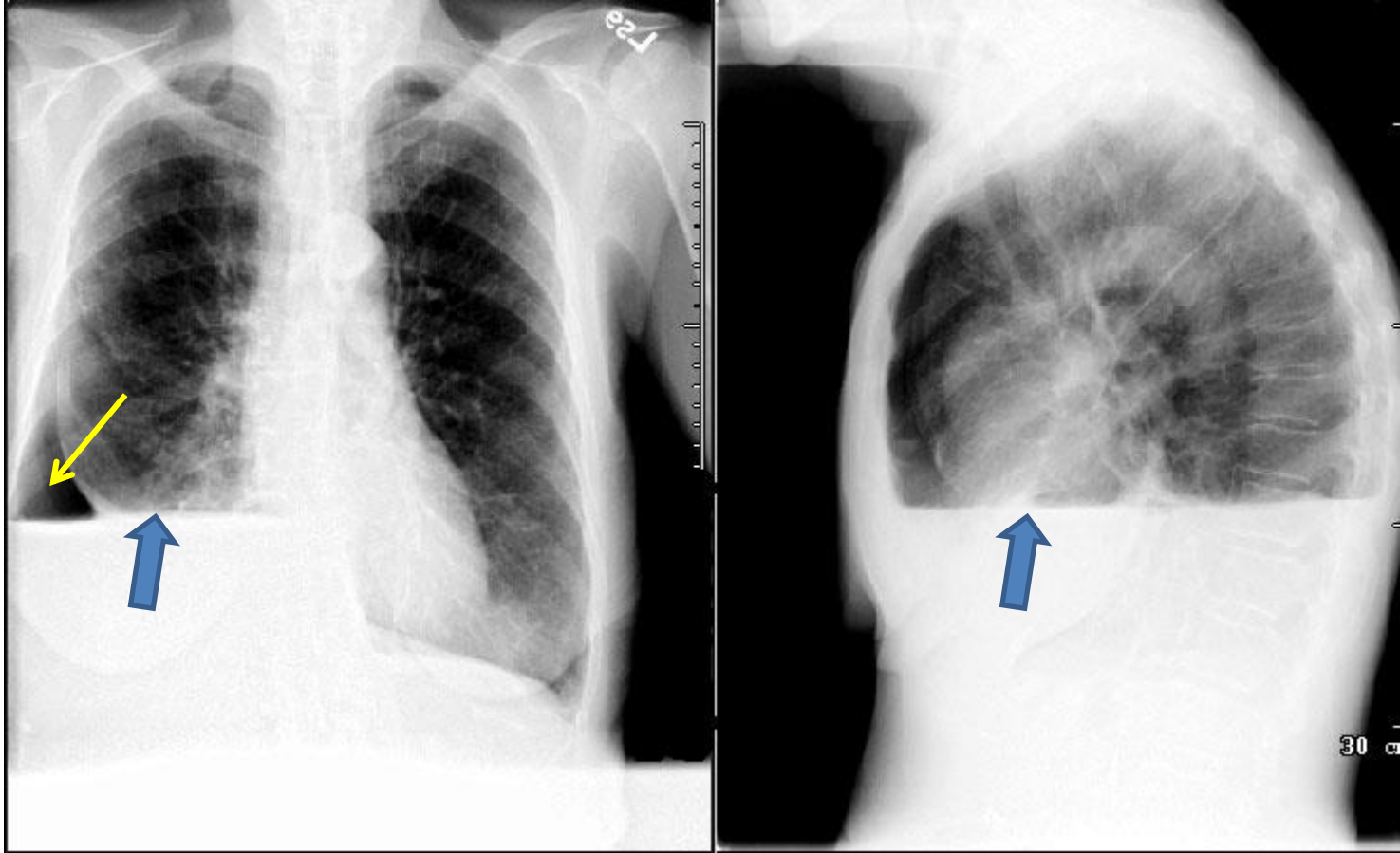


BLUNTED RIGHTCOSTOPHRENIC ANGLE

DIAGNOSIS: PLEURAL EFFUSION.



?????



HYDRO-PNEUMOTHORAX

