

Venous Diseases

Objectives

- Discuss the pathophysiology and epidemiology of varicose veins
- Discuss the classification and clinical features of varicose veins
- Discuss the diagnosis and managements of varicose veins
- Discuss the pathophysiology and clinical assessment of chronic venous insufficiency
- Discuss the managements of chronic venous insufficiency
- Discuss the pathophysiology and epidemiology of venous thromboembolism
- Discuss the classification and clinical features of venous thromboembolism
- Discuss the diagnosis and management of venous thromboembolism

Colour Index

- Main Text
- Males slides
- Females slides
- Doctor notes
- Textbook
- Important
- ★ Golden notes
- Extra

[Summary File](#)

[Editing File](#)

Anatomy Of Venous System

Anatomy of Venous System:

Superficial veins ¹ "Saphenous system":

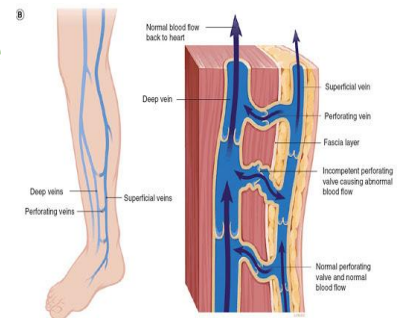
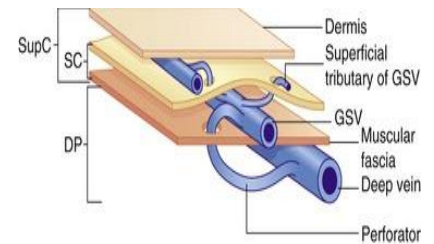
1- long (great) vein 2- Short (lesser) vein

• The saphenous veins and their tributaries lie outside the deep fascia and in healthy individuals carry about 10% of the venous return from the limb.

Deep veins ²:

Lie deeply within the muscles, Naming follows arterial system: femoral vein, popliteal vein, etc. 90% of venous return through the deep veins

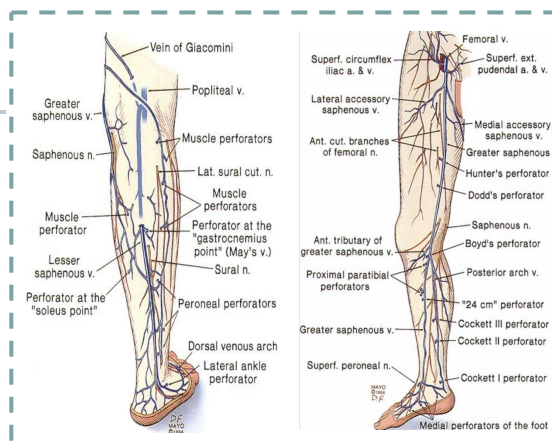
Perforators: perforate the deep fascia (muscular fascia) to connect the superficial and deep systems.



for exam purpose you don't have to know all the veins, just remember the superficial, deep and perforators

GSV

- Lies in front of the medial malleolus
- It penetrates the deep (cribriform) fascia (inguinal ligament) to enter the common femoral vein at the saphenofemoral junction (SFJ).
- (438) The most important system.
- (438) It begins at the medial end of the dorsal venous arch, crosses in front of the medial malleolus and ascends the medial side of the leg. 2.5 cm below and lateral to the pubic tubercle.



LSV

- Lies posterior to the lateral malleolus
- join the popliteal vein at the saphenopopliteal junction (SPJ)
- (438) It starts at the lateral end of the dorsal venous arch, passes posterior to the lateral malleolus, then ascends the median posterior line of the calf to join the popliteal vein at the saphenopopliteal junction (SPJ), usually just above the knee.
- Anatomical variations are very common.

Valves ³:

- Is a fold within the vein
- As Blood passes they open in a direction and close then in the other direction
- IVC has no valves, the venous valves starts at the external iliac vein, as you go more distally you have more valves
- **There are two types of valves:**
 - Vertical valves; prevent blood from going down (flow direction: down to up/distal to proximal)
 - Perforating veins valve; directing blood from superficial to deep veins (flow direction: out to in)

438 Notes:

- 1- Lie in the fatty layer just beneath the skin.
- 2- It has valves that allow the blood to flow upward towards the heart.
- 3- A valve is not a muscular structure, formed from a single layer of endothelial cells,

Physiology Of Venous System:

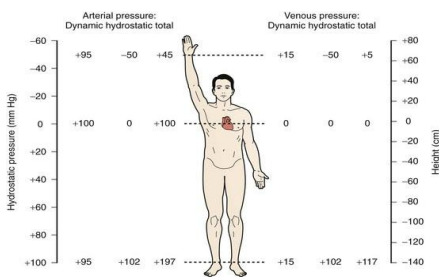
➤ Hydrostatic and Dynamic Pressure:

Dynamic

- The pressure generated by cardiac pumping is termed dynamic pressure.
- All the positive active pressures that pushes the fluid into that tube.
- Under normal conditions in the supine position, blood flow is determined by dynamic pressure gradients, with arterial pressure being higher than venous pressure. The majority of dynamic pressure is dissipated in the arterial system before it reaches the capillary bed. At the venous end of the capillary bed, it ranges from 12 to 18 mm Hg. Atrial pressure averages 4 to 7 mm Hg under normal conditions. Hence, blood flows along this gradient and is returned to the heart.

Hydrostatic

- Is the pressure that results from the weight of the fluid and it's fixed in arteries and veins.
- In the upright position, venous flow in the lower extremities is dominated by the effects of hydrostatic pressure.
- When a person is standing absolutely still, the pressure in the veins of the feet is about +90 mmHg simply because of the gravitational weight of the blood in the veins between the heart and the feet.



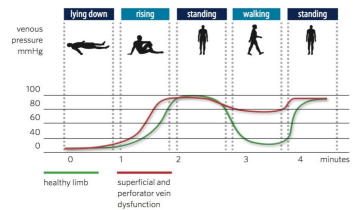
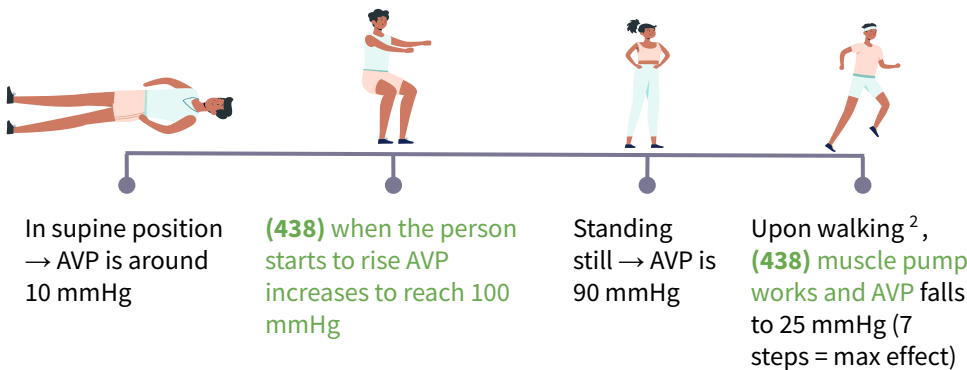
• Arterial blood pressure at the ankle in a standing position = Hydrostatic + Dynamic → $102 + 95 = 197 \text{ mmHg}$ (200 mmHg)

• Venous blood Pressure at the ankle in a standing position = Hydrostatic + dynamic → $102 + 15 = 117 \text{ mmHg}$ (120 mmHg) (117 mmHg is a high pressure that the physiological mechanisms need to push against.)

Once those mechanisms fail, we will have very high pressure in the foot. And the consequences of venous insufficiency are as high as a systolic failure in the upper limb (of the arterial system). The physiological mechanisms are explained in the next slide.

➤ Ambulatory Venous Pressure ¹:

- If you understand normal you will be able to advise and guide regarding therapy for the abnormal.



The green graph depicts the normal rise and fall of venous pressure according to body positioning and gravitational effect.

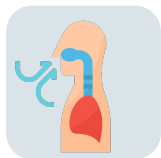
1-There will be some **MCQs** about it so you have to remember it's around 25 mmHg and when a patient has venous insufficiency it will be higher than 25 mmHg.

2-High walking ambulatory venous pressure will develop chronic venous insufficiency

Physiology Of Venous System:

How does the blood travel through veins?

- By many simple (e.g the venous plexus in soleus muscle) and complicated physiological mechanisms, which are:

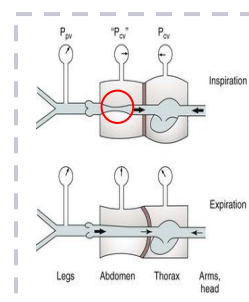


Abdominothoracic (Respiratory) Pump:

1 Upon inspiration there will be +ve pressure in abdomen, and -ve pressure in thorax (diaphragm will go down, creating a +ve pressure which will lead to closure of veins. That cycle will continue and form a valve like function).

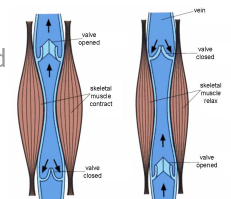
2 In expiration diaphragm will go up creating a -ve pressure, which will push the blood upward towards the heart from the legs.

3 As a result of pregnancy, large tumors, abdominal obesity, ascites, intra-abdominal pressure can rise to +15 or +30 mmHg (normally +6 mmHg), when it rises, the pressure in the **veins of the legs** must rise above the abdominal pressure before the abdominal veins will open and allow the blood to flow from the legs to the heart.



Venomuscular pump (Leg-Calf muscle pump):

- The strongest, most powerful system that can resist venous pressure in the lower limb.
- The contraction and relaxation of the skeletal muscles surrounding the veins impress volume and pressure variations to the venous blood, while the flow direction is conditioned by the valvular arrangements (flow can be only toward the heart, from down to up and from out to in).
- Weight-bearing compresses the veins in the sole of the foot, which propels blood into the calf ('foot pump').



Contraction

Relaxation

01

The vein is **squeezed** to push the blood **upward**. So when we move our legs, it moves up and empties.

03

On subsequent muscle relaxation, venous pressure falls below the pressure at rest. The fall is greater in the deep veins and less in the superficial veins.

05

Competent valves prevent backflow from the popliteal to the deep calf veins.

02

When the calf muscles contract, the pressure rises in all veins of the lower limb.

Venous pressure exceeds the intramuscular pressure in most of the step phases, but competent venous valves prevent retrograde flow.

04

(sponge effect) A suction effect will happen which will suck the fluid from the superficial veins (through the perforators) and from down (through the valves).

06

Physiology Of Venous System:

Varicose veins

01

Dilated elongated superficial veins

Venous insufficiency doesn't mean decrease blood supply
it means the function of the vein is insufficient

02

Chronic venous insufficiency

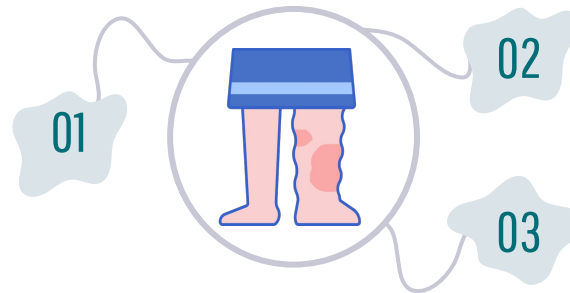Venous ulcer

03

- Most venous disease arises as a result of **incompetent valves**, either:
 - Primary valvular incompetence (floppy valve).
 - Secondary valvular incompetence.
- Incompetent valves lead to reflux of blood or increased ambulatory venous pressure (the hydrostatic pressure exerted by the column of venous blood stretching from the ankle to the right atrium). This leads to symptoms and signs such as:

01 Ulceration and hyperpigmentation.

- It's Yellow-brown or red-brown skin pigmentation
- RBC breakdown leads to hemosiderin release
→ accumulation in the dermis
→ skin pigmentation



02

02 Lipodermatosclerosis

Localized chronic inflammation and fibrosis of skin and subcutaneous tissues of lower leg.

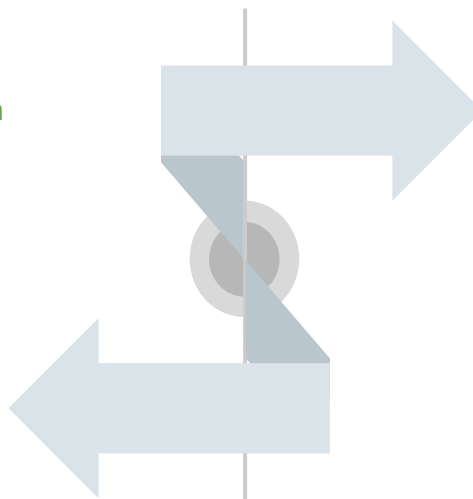
03

03 Swelling

> Causes of valvular failure:

Congenital

- A valvular venous system (rare).




Acquired valvular failure:

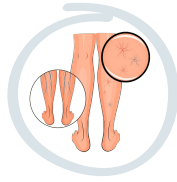
- occur with **obesity, pregnancy**, CHF, Ascites, and prolonged frequent standing, for the following reasons:
 1. Increased abdominal pressure, which will make the venous emptying from the legs to the chest much harder → the blood volume in veins increases which will increase the pressure within the vein leading to dilation and as a result of that the valve edges no longer touch each other.
- Issues above the abdomen (such as a tumor, surgery, radiation) and anything that obstructs flow leading to dilation.
- Issues inside the veins; such as **thrombosis (DVT)**.

Venous Diseases

➤ Varicose veins:



Their prevalence increases markedly with age and they are an almost universal finding in individuals over the age of 60 years.



A great majority of individuals with varicose veins are asymptomatic, and seek treatment for cosmetic purposes.

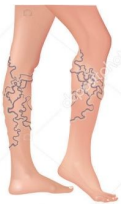

Only a portion of patients with varicose veins go on to develop the complications of chronic venous insufficiency: e.g., leg ulcers, haemorrhage and thrombophlebitis.

● Classification:

Trunk varices:

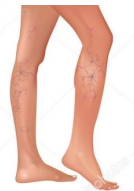- These involve the main stem and/or major tributaries of the GSV and LSV, are usually > 4 mm in diameter.



Varicose vein trunk

Reticular varices:

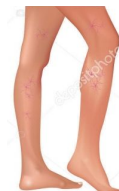- These lie deep in the dermis, are < 4 mm in diameter (present in 80% of adult population) render the overlying skin dark blue.



Reticular varices

Telangiectasia:

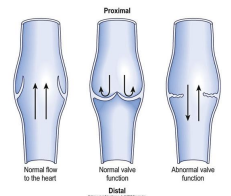
- These are also called spider and thread veins. They lie superficially in the dermis, are usually 1 mm or less (overlying skin purple or bright red).



Spider veins

➤ Chronic venous insufficiency:

- CVI is defined as the presence of (irreversible) skin damage (such as eczema, lipodermatosclerosis) in the lower leg as a result of sustained ambulatory venous hypertension.
- CVI collectively describes the manifestations of impaired venous return mainly due to failure of valves that leads to continued reflux of blood.
- This hypertension is due to failure of the mechanisms that normally lower venous pressure upon ambulation, namely:



90%

- **Venous reflux** due to valvular incompetence.
- This may affect the superficial veins, the deep veins or both, and may be due to primary valvular insufficiency (as in VV) or to postthrombotic damage.

10-20%

- **Venous obstruction.**
- This is usually postthrombotic in nature and coexists with reflux.

Venous Diseases

- So, What happens to the venous pressure?

1

With normal functioning valves:

When a person is lying down, the venous pressure of lower limb is distributed to be around 10 mmHg, but when the person starts to rise it increases to reach 100 mmHg, which stays like that if the person is standing still. Upon walking the muscle pump works to reduce the pressure (suction → push → suction → push).

2

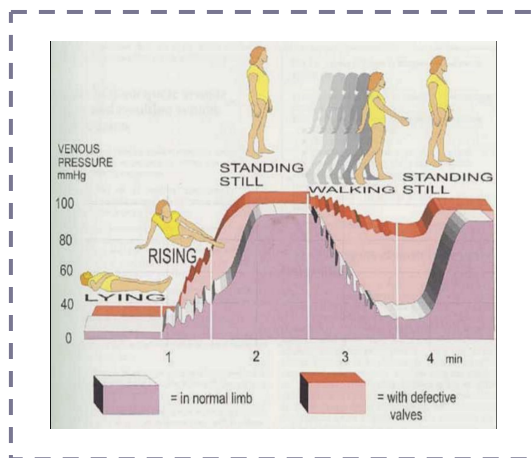
In someone with defective valves:

When the valves fail, the venomuscular pump and the respiratory pump function becomes harmful.

Venomusclar: When the muscle contracts, the blood is pushed below. And during the relaxation, blood is pulled from above due to the suction force.

Respiratory pump: During exhalation, the venous blood will be pushed below.

The rising phase is faster because the vein fills from up (backflow) and gravity. And walking won't reduce the venous pressure.



This graph depicts the pressures in a healthy limb, in mauve, while lying, rising, standing still and walking compared with the pressures present in a limb with defective valves. The mauve depicts the normal rise and fall of venous pressure according to body positioning and gravitational effect.

Purple: The pressure is building gradually because blood won't fall from superior parts.

Red: lying is the same, when they stand the blood drops from above which increases pressure rapidly. When they walk the blood keeps coming to the lower limb due to the harmful mechanism discussed above



Venous ulcer ¹

★ Venous leg ulcers are classically located in the “gaiter” region of the leg.



Why? Because the longest vein in the superficial venous system (GSV) starts at the medial malleolus. Once venous system failure occur, it will be the highest point of pressure in the venous system.

Which will lead to pain ² and increased: edema, protein rich fluid, lipodermatosclerosis and skin pigmentation and finally ulcers.

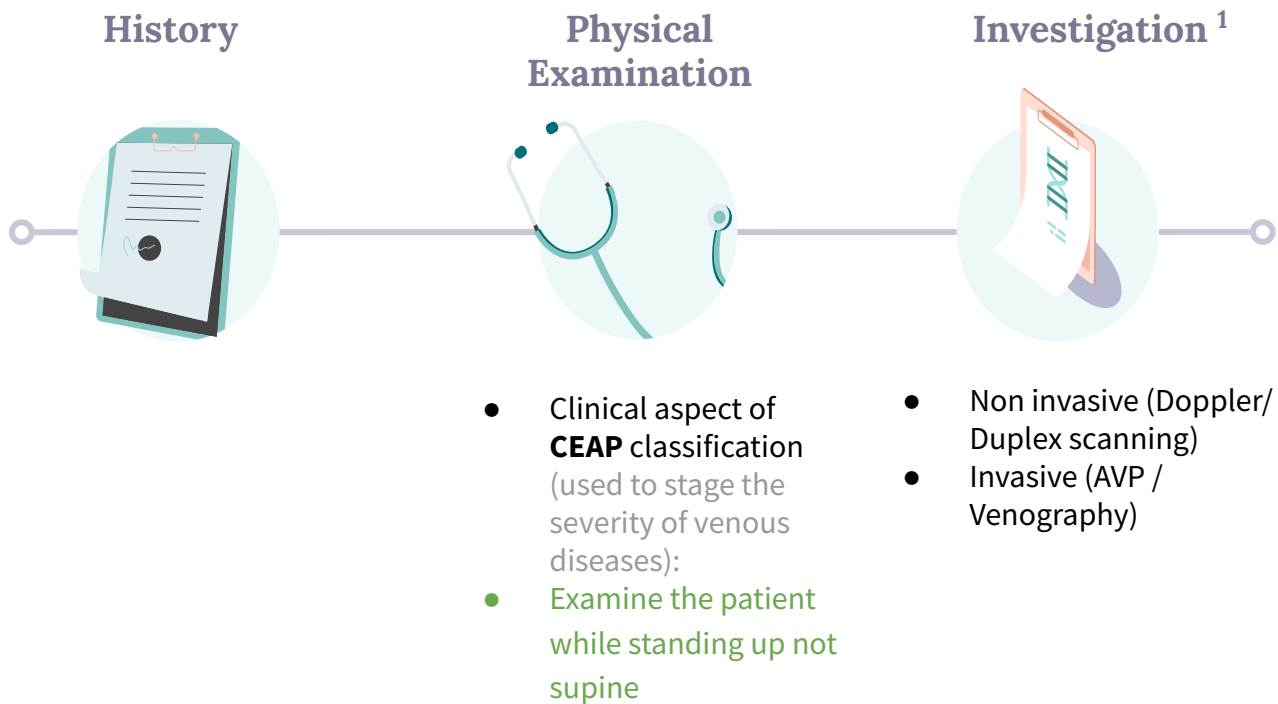
01

02

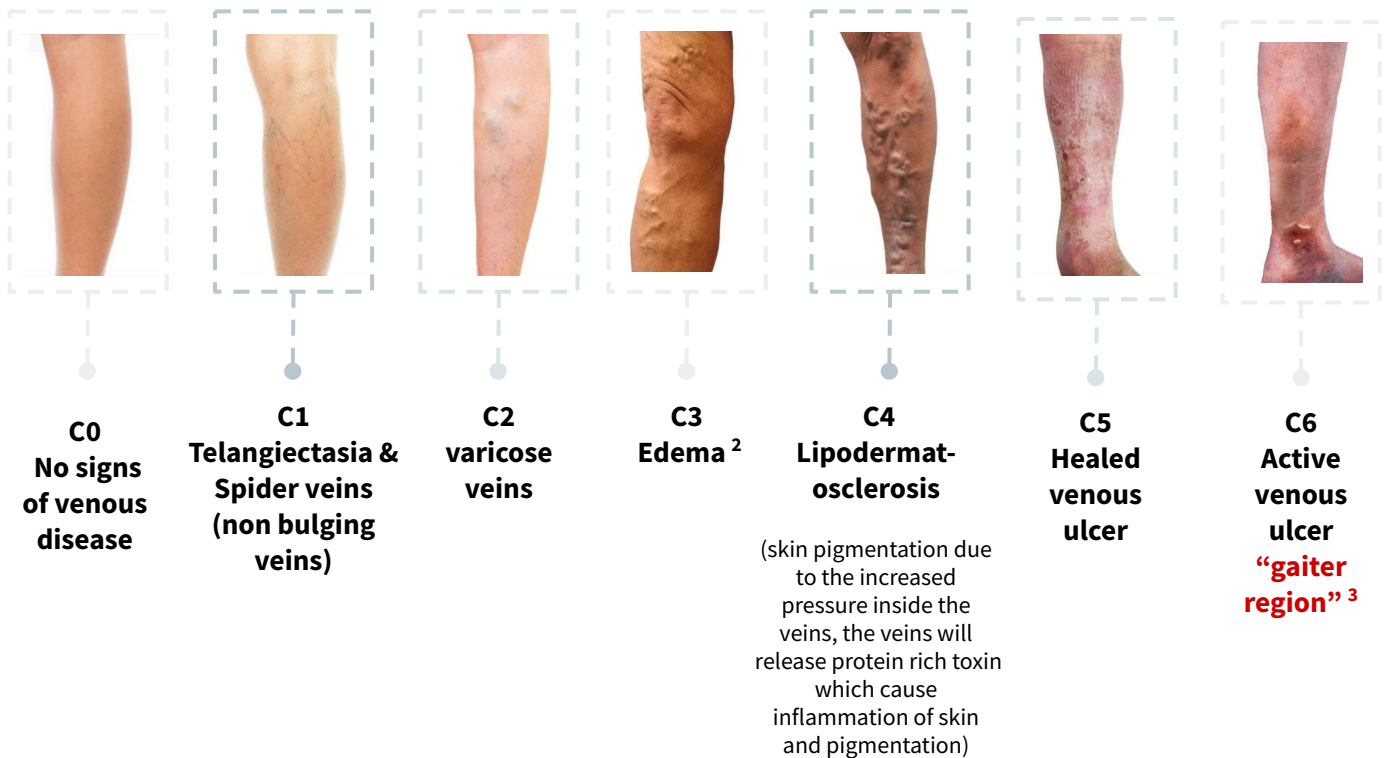
1. Varicose veins → extravasation of protein and leukocytes → release of free radicals → damage to capillary basement membrane → leakage of plasma proteins → edema formation → oxygen supply → tissue hypoperfusion and hypoxia → inflammation and atrophy → possibly ulcer formation.

2. Pain while standing relieved by walking is quite opposite to arterial diseases.

Evaluation



Clinical-Etiology-Anatomy-Pathophysiology (CEAP):



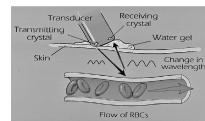
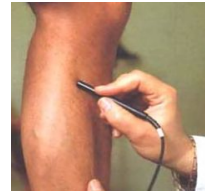
1. Venous insufficiency can be the first sign of a disaster. So whenever a patient presents with signs of venous disease, you should always look for the cause.
 2. When it exceeds just being a vascular problem it will affect the tissues around the vein in the form of fluid leak
 3. Ulcers and Lipodermatosclerosis happen above the malleus (gaiter area) only. Because it is the highest pressure point in the venous system, and in this place there are bone and skin only there is no fat.

Evaluation

> Non-Invasive:

01 Doppler

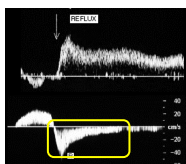
- Tells us that there is fluid & it's moving. You can also assess valve closure.
- Normal venous blood flow is spontaneous and phasic during respiration, yielding a **wind-like audible Doppler signal**. Manual compression of the limb below the probe should augment forward flow, with resultant increased amplitude of the audible Doppler signal. When the limb is compressed above the probe, the Doppler signal will normally cease, because competent valves restrict retrograde venous flow. When compression above the probe is released, an augmented, forward flow signal should be noted.



02 Duplex scanning

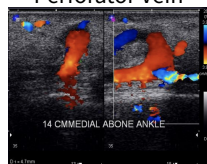
- ★ The best non-invasive diagnostic method for either venous or arterial diseases
- **Duplex ultrasound** involves using high frequency sound waves to look at the speed of blood flow, and structure of the leg veins.
- The term "duplex" refers to the fact that two modes of ultrasound are used, **Doppler and B-mode**:
 - **The B-mode transducer** (like a microphone) obtains an image of the vessel being studied.
 - **The Doppler probe** within the transducer evaluates the **velocity and direction of blood flow in the vessel**.
- The probe also has a receiver to receive the sound waves back and analyze it. Sound waves passing through fluid rapidly and easily will make the fluid appear black. While those passing through thick tissue will reflect the sound waves back. The receiver on the probe can also inform us if the sound waves are increasing (which indicates movement of fluid. This movement is either away from the probe or towards it)
- ★ **Duplex scanning is the most commonly used investigation tool.**
- All patients must undergo duplex ultrasound to define the nature and distribution of superficial and deep venous disease, as this has an important bearing on both treatment and prognosis.

▶ Incompetent Valves

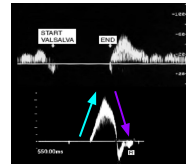
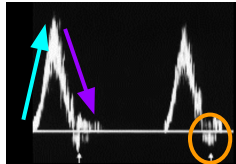


- Reversed flow

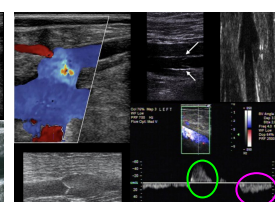
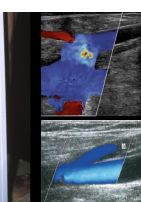
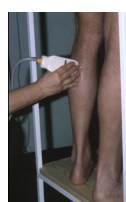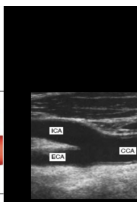
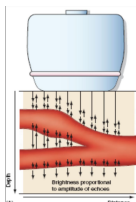
Incompetent Perforator Vein



▶ Normal



- The **arrows** in this picture indicate **speed** and not direction! (in this picture the wave is up which means that the direction of the flow is towards the probe).
 - The **blue arrow**: speed is **fast**
 - The **purple arrow**: speed is **low**
AND BOTH ARE GOING IN THE SAME DIRECTION BECAUSE THE VALVE IS FUNCTIONING WELL.
 How do we know that the valve is functioning normally? Because when the direction of the flow (the wave) was about to get reversed, the flow stopped = valve is working (**orange circle**).



- Wave is **up (green circle)**: blood is moving **towards** the probe.
 - Wave is **down (pink circle)**: blood is moving **away** from the probe.

Evaluation

> Invasive:

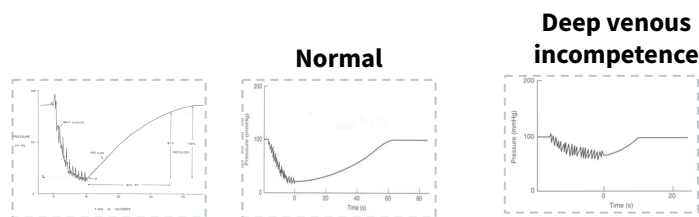
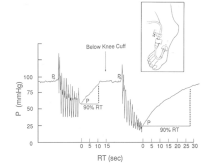
03 AVP

- **AVP** (ambulatory venous pressure)

Reflux - 20-21 gauge Butterfly Needle
 Superficial Dorsal Vein (Foot) or Ankle Vein
 Standing, Heal Raised, Measurements.

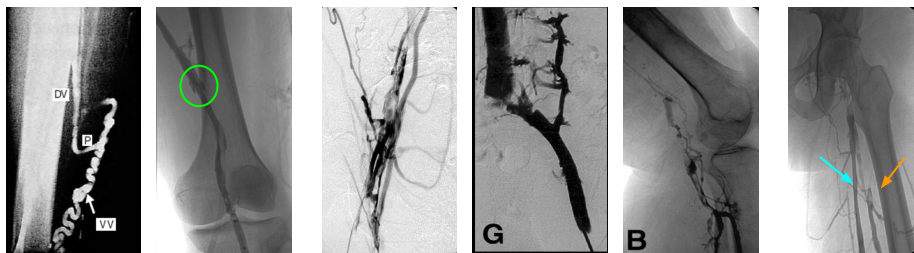
Normal: Pressure drop from 80-90 to 20-30 mmHg / or > 50% drop, Venous Refill Time (VRT) \geq 20 sec

Abnormal: Lack of sufficient drop in pressure with ambulation \rightarrow P < 50%, Short Venous Refill Time (VRT) < 20 sec



04 Phlebography (Venography)

- Injecting dye + x-ray to see inside the veins.
- It has many complications due to the contrast and the procedure itself
 - The vein in the picture is the popliteal and it's blocked in the picture 'B'.



popliteal vein.
 Green circle:
 valve.

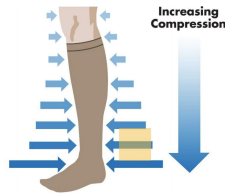
popliteal vein
 with filling
 defect (blocked
 vein).

Blue arrow:
 Saphenous vein

Orange arrow:
 Femoral vein
 with filling
 defect due to
 DVT.

Treatment (Types Of Ablation)¹:

Mechanical



Chemical

Side effect	Frequency	Mean value	Score	Pain
Color changes	++	1.5	1.5	1.5
Edema	++	1.5	1.5	1.5
Itching	++	1.5	1.5	1.5
Redness	++	1.5	1.5	1.5
Swelling	++	1.5	1.5	1.5
Tenderness	++	1.5	1.5	1.5
Warmth	++	1.5	1.5	1.5
Wound	++	1.5	1.5	1.5
Yellowish color	++	1.5	1.5	1.5
Other	++	1.5	1.5	1.5

Thermal

Surgical

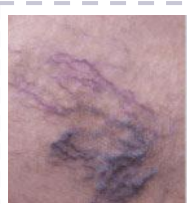- **Compression stocking:** a **temporary** solution that provides high compression below and low compression up for 2 reasons:
 - To close veins that aren't working properly which will shift blood to deep veins
 - Make valve leaflets close to each other
- **Disadvantage** patients usually have compliance issues with it especially elderly patients because it's hard to put on (high pressure) & may reduce arterial perfusion (contraindicated in arterial insufficiency; leads to ischemia)

- **Sclerotherapy:** Sclerotherapy is the injection of a sclerosing agent into a vein (**small veins only!**), causing an inflammatory reaction in the endothelium of the vein wall. The vein walls adhere together under compression and form a scar (fibrotic tissue) that is absorbed by the body. And the blood will be shifted to other working veins. **Usually it is a cosmetic procedure.**
 - **Contraindicated with large veins.**
- Complications : pigmentation, allergic reaction, necrosis, pain.

- ★ **EndoVenous Ablation Techniques²:** Denaturation of vein wall collagen → contraction → fibrous obliteration
 - EndoVenous Laser Therapy (EVLT)

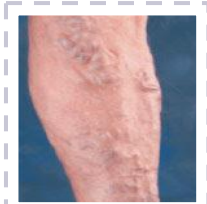- **Surgery** (stripping the saphenous vein)
 - **We don't do it anymore**, big wound, very painful, very challenging to the patient.
 - **An absolute contraindication** is if the rest of the veins are diseased (e.g. DVT)

Telangiectasia Reticular veins



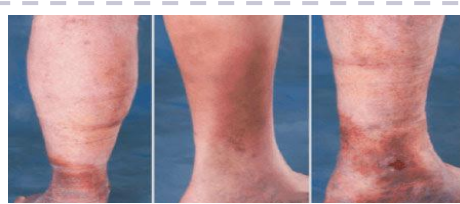
Stocking and/or
Sclero-Rx

varicose veins



Stocking
USG-Sclero-Rx
(less used in large ones to avoid chemical toxicity)
EVLT/Surgery

Edem - Cutaneous ulcer - Local wound



Stocking
USG-Sclero
ELVT/Surgery

1. before any form of ablation is planned for any insufficient vein we have to roll out DVT or any other cause of flow obstruction (e.g. Tumor because it could be the only functional vein)

Say you have a C2 (varicose veins), before initiating therapy, one needs to consider the following;

- Is the rest of the veins working? The rest could be thrombosed and you'd be ablating the only functioning one! So you need to check the deep veins. For example, see if the patient has DVT, by **duplex-scanning** (standard protocol).
- This could be the tip of the iceberg with an underlying cause (proximal occlusion), such as; tumor in proximal areas like groin lymph nodes or sarcoma in abdomen. Or could be a trauma or post-op fibrosis.

★2. Laser or radio ablation can be used where a laser fiber is inserted in the GSV to reach the saphenofemoral junction, then the thermal beam is turned on and pulled slowly out closing the vein entirely.

Venous Thromboembolism (VTE)

> Epidemiology:

- DVT is a common condition in medical and surgical patients.



- pulmonary embolism (PE) is consistently cited as the most common cause of potentially preventable death in the surgical patient.

> Pathophysiology:

01

DVT probably begins in the calf in most cases.

02

Clot may extend into the popliteal, femoral or iliac veins, and even the inferior vena cava.

03

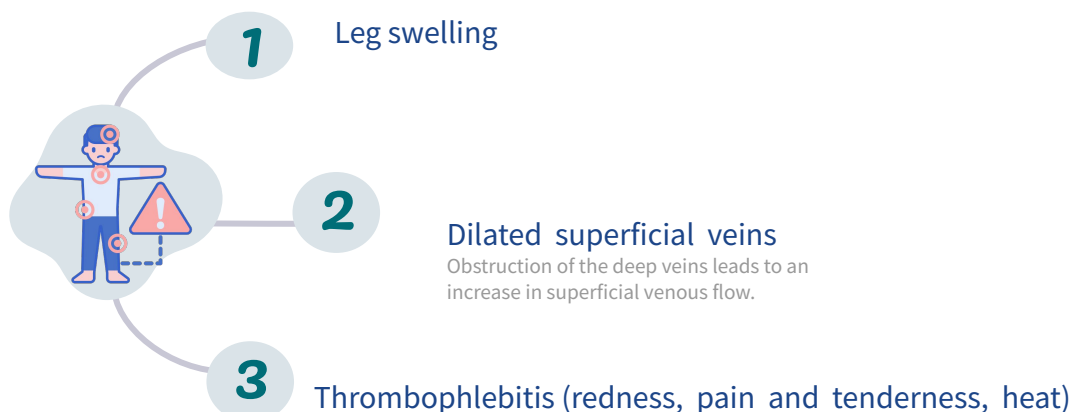At first, the clot is free-floating within a column of flowing blood.

04

The risk of PE is highest at this point. Later, when thrombus has completely occluded the vein and incited an inflammatory reaction in the vein wall, the clot becomes densely adherent and is unlikely to embolize.

> Aetiology and Clinical Features:

- **Virchow's triad:** namely, venous **S**tasis, intimal **E**ndothelial damage and **H**ypercoagulability of the blood (These include antithrombin, protein C and protein S deficiency, as well as factor V Leiden.) mnemonic: **HE'S** Virchow
- Clinical risk factors for DVT are related to venous stasis: for example, immobility, obesity, pregnancy, paralysis, operation and trauma.
- **Clinical features:**



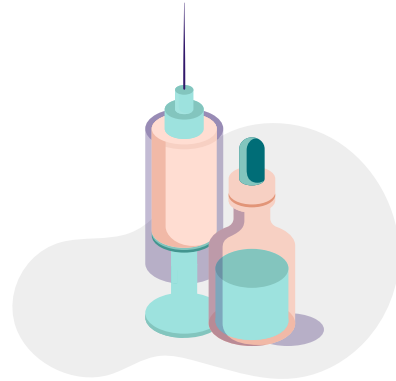
Venous Thromboembolism (VTE)

➤ Diagnosis and Management:



Diagnosis:

- Colour duplex ultrasound imaging has largely replaced conventional venography in the diagnosis of DVT.
- At times of doubt, MR or CT venography may be useful.



Management:

- Before treatment is instituted, the diagnosis of DVT should normally have been established by means of ultrasound or MR (CT) venography.
- However, where the clinical suspicion of DVT and/or PE is high and there is no contraindication to heparin, the potential benefits of 'blind' treatment until the diagnosis is confirmed often outweigh the risks of withholding anticoagulation.

➤ Uncomplicated DVT vs. Complicated DVT:

Uncomplicated DVT	Complicated DVT
<ul style="list-style-type: none">• If thrombus is confined to the calf, the patient is fully mobile and other risk factors are reversible, then an elastic stocking and physical exercise may be all that is required.• For most uncomplicated DVT, it is now clear that:<ul style="list-style-type: none">○ Bed rest is unnecessary and the patient can be mobilized immediately, wearing an appropriately fitted compression stocking.○ LMWH given by intermittent subcutaneous injection is more effective than unfractionated heparin given by infusion.	<ul style="list-style-type: none">• The DVT is more extensive (iliofemoral, vena cava, phlegmasia).• The DVT is recurrent.• The patient has had a PE.• The patient has one or more major irreversible congenital and/or acquired thrombophilia.• Heparinization is contraindicated (heparin-induced thrombocytopenia, trauma – especially intracranial, recent haemorrhage).

Summary

Lower Extremity Veins

Superficial

Deep

Perforating

Factors Affecting Venous Blood Flow

Hydrostatic pressure

- Upon standing about 90 mmHg
- Upon walking less than 20 mmHg

Intra-abdominal pressure

- Expiration → -ve pressure → blood moves from the legs to the heart
- Inspiration → +ve pressure → closure of the valves

Ambulatory venous pressure

- In supine position = 10 mmHg
- Standing still = 90 mmHg
- Upon walking = 25 mmHg

Venous pump

- Calf muscles relax → deep veins expand → pressure collapse → blood sucked from superficial veins
- Calf muscles contract → blood forced up → opening of the valves → blood pumped towards the heart

Venous Disorders

01

Chronic venous insufficiency

presence of (usually irreversible) skin damage (such as eczema, lipodermatosclerosis) in the lower leg as a result of sustained ambulatory venous hypertension.

02

Varicose veins

03

Venous ulcer

usually located in the “*gaiter*” region of the leg



Evaluation:

Non invasive:

- Doppler
- Duplex scanning

Invasive:

- Ambulatory venous pressure



Management:

- Compression stocking
- Sclerotherapy
- EndoVenous Ablation Techniques
- Surgery

439's Quiz

Q1: A question the Dr. mentioned: TRUE or FALSE, varicose veins treatment is sclerotherapy (chemical ablation) ?

- A) True
- B) False
- C) IDK :)

Q2: A 53 year old gentlemen who works as a security guard, came to your clinic complaining of leg pain, you examined the leg and found edema (C3), what's your next step?

- A) Send him home until he notices skin changes
- B) Confirm diagnosis by Duplex scanning
- C) Treat him by thermal ablation

Q3: Which of the following areas is venous ulcers seen the most?

- A) Medial malleolus
- B) Lateral malleolus
- C) The heel of the foot

Q4: What is the most commonly used investigation modality for venous diseases?

- A) Doppler
- B) Ultrasound
- C) Duplex

Answers

Q1	B
Q2	B
Q3	A
Q4	C

[Extra Questions](#)

438's Quiz

Q1: A 41-year-old woman, diagnosed with varicose veins in the left leg, presents to your clinic with a 2-month history of severe pain in the left leg on prolonged standing. The patient is obese and the pain has affected her working and social lifestyle and she asks you about the most effective treatment option. From the list below, choose the most effective treatment option that you would discuss with this patient.

- A) Use of compression stockings
- B) Injection sclerotherapy
- C) Surgery

Q2: Lipodermatosclerosis is commonly associated with which one of the following conditions?

- A) Deep vein thrombosis
- B) Varicose veins
- C) Intermittent claudication

Q3: A 65-year-old man presents for the first time to your clinic with a painless wound in his right leg, which has been present for over 2 months. On examination you notice a 3 cm × 4 cm leg ulcer in the gaiter area of the right leg, covering the medial malleolus. The shallow bed of the ulcer is covered with granulation tissue, which is surrounded by sloping edges. There is no history of trauma. From the list below, choose the most likely diagnosis.

- A) Arterial leg ulcer
- B) Neuropathic ulcer
- C) Venous ulcer

Q4: Which of the following statements regarding venous leg ulcers are true?

- A) Less than 10 percent of patients will get a recurrence within 5 years after healing.
- B) Venous ulcers are best managed by 'two layer' bandaging.
- C) Greater than 60 percent of all leg ulcers are venous in origin.

Q5: A 48-year-old man has a body mass index (BMI) of 37 and is a heavy smoker. He has primary symptomatic varicose veins with skin changes and duplex scan demonstrates an isolated saphenopopliteal junction incompetence and short saphenous reflux.

- A) Endovascular laser treatment (EVLV)
- B) Foam sclerotherapy
- C) Valve surgery

Answers

Q1	C	Q4	C
Q2	B	Q5	A
Q3	C	Q6	

Good
Luck!



Team leaders:




Reem Alqahtani

Shayma Alghanoum

Sarah AlQuwayz

Mona Alomirainy

This lecture was done by:

- Alia Ali Zawawi
-  Omar Alsuliman
-  Homoud Algadheb
-  Wesam Alhuways



Note taker



Reviser

[Feedback](#)