



Introduction to Dermatology

Dr. Sami N. Alsuwaidan

ASSOCIATE PROFESSOR
CONSULTANT IN DERMATOLOGY & LASER SURGERY
DIRECTOR, PSORIASIS RESEARCH CHAIR
DEPARTMENT OF DERMATOLOGY
KING SAUD UNIVERSITY

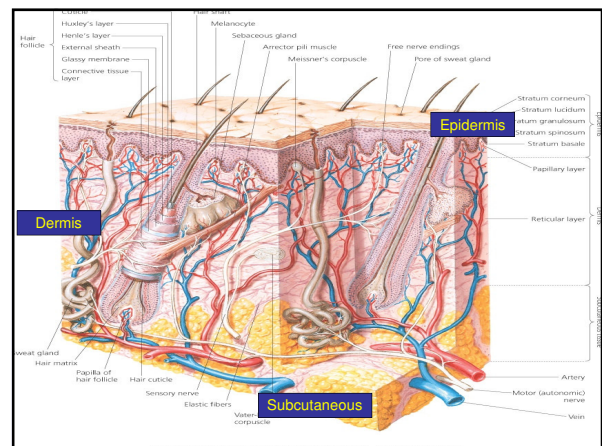
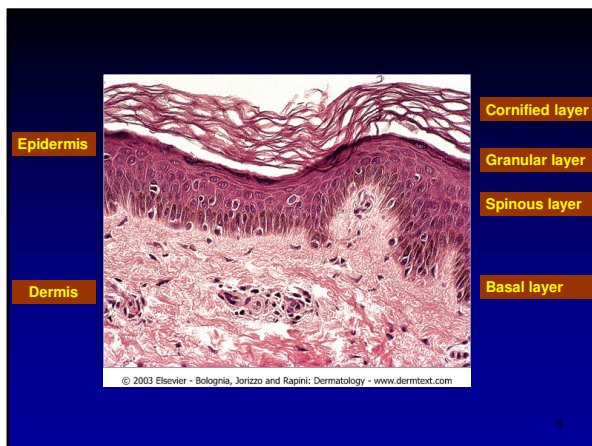
Dermatology

Skin, hair, nails, and mucous membranes (mouth and genitalia).

Important functions of the skin

- Protection against external injury
- Fluid balance
- Temperature buffering
- Synthesis of Vit. D
- Immune system
- Cosmetic function

Why Dermatology?



Skin Anatomy

- 1 Epidermis
- 2 Basement membrane (dermoepidermal junction)
- 3 Dermis
- 4 Subcutaneous fat

❖ **Epidermis: Four layers (from outside – inside)**

1. Cornified layer
2. Granular layer
3. Spinous layer
4. Basal layer

❖ **Dermis contains:**

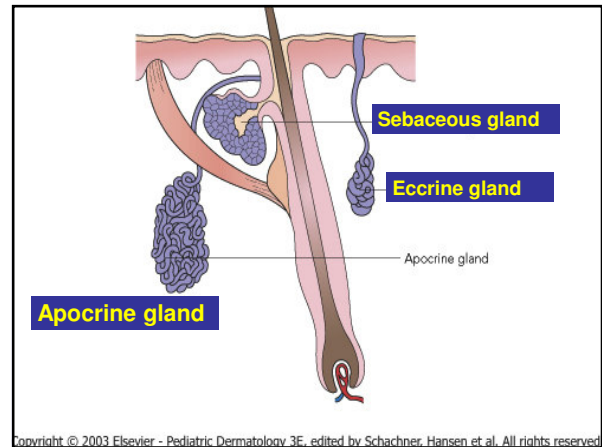
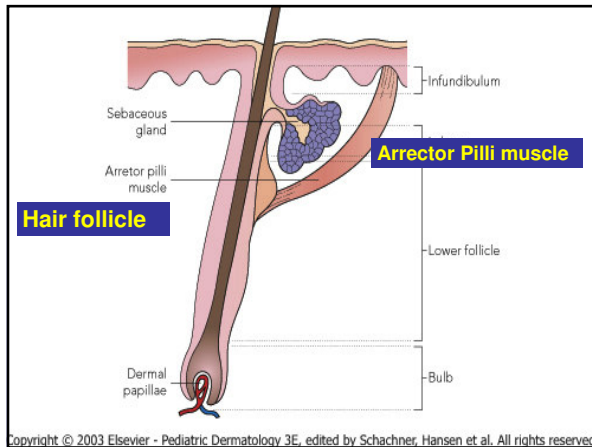
- Collagen fibers
- Elastic fibers
- Ground substances
- Blood vessels
- Nerves.

7

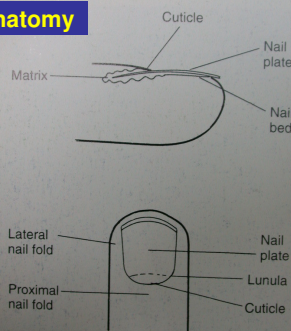
Skin Appendages

- **Hair follicle**
- **Sebaceous gland**
- **Arrector pili muscle**
- **Eccrine sweat gland**
- **Apocrine sweat glands**

8



Nail Anatomy



11

Examination

1. **Morphology**
2. **Configuration**
3. **Distribution**

12

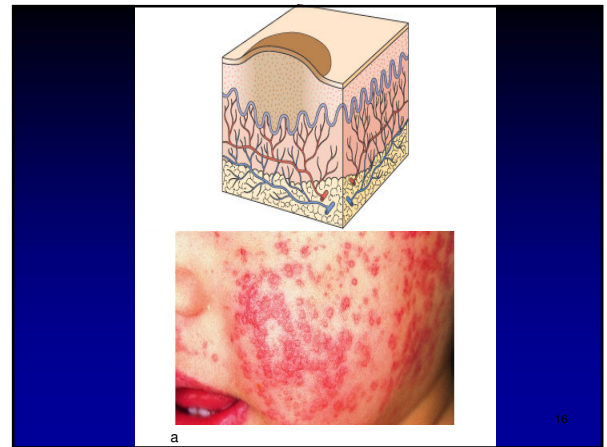
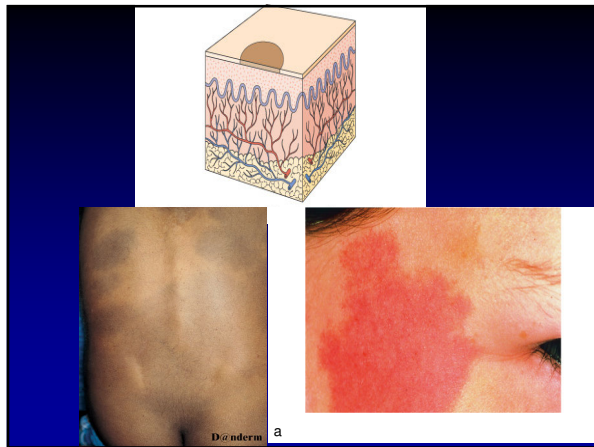
Primary Lesions
Secondary lesions

13

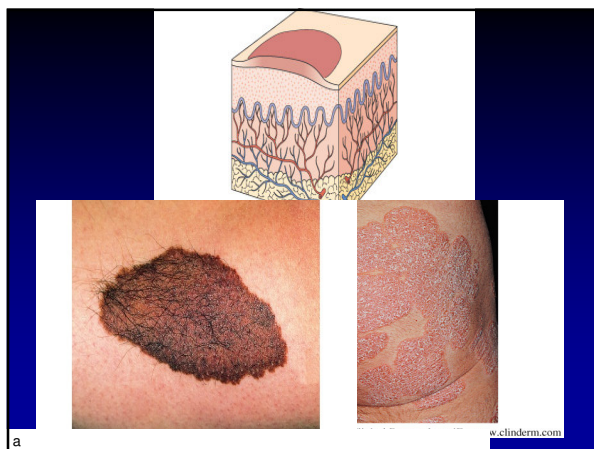Primary Lesions

- Macule
- Papule
- Plaque
- Nodule
- Wheal
- Vesicle
- Bulla
- Pustule

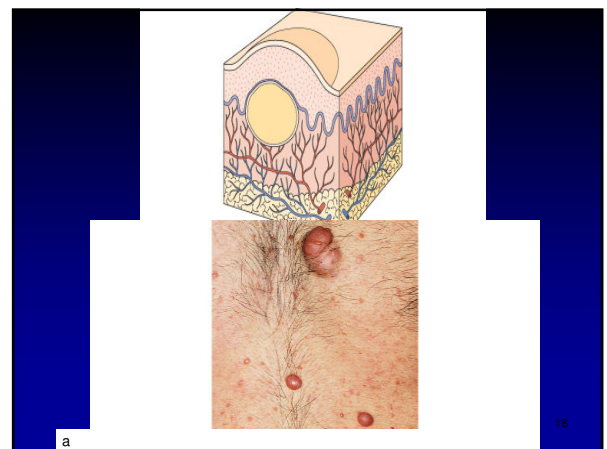
14



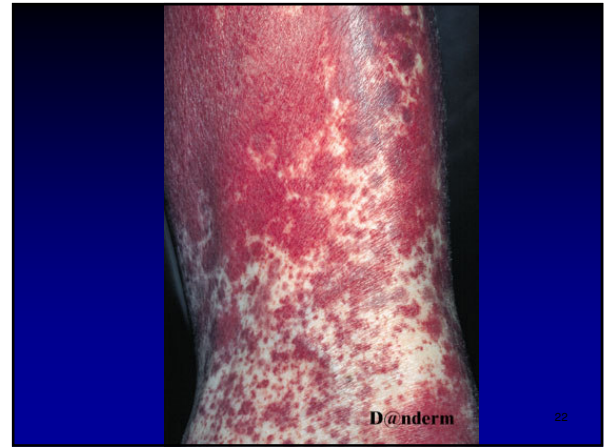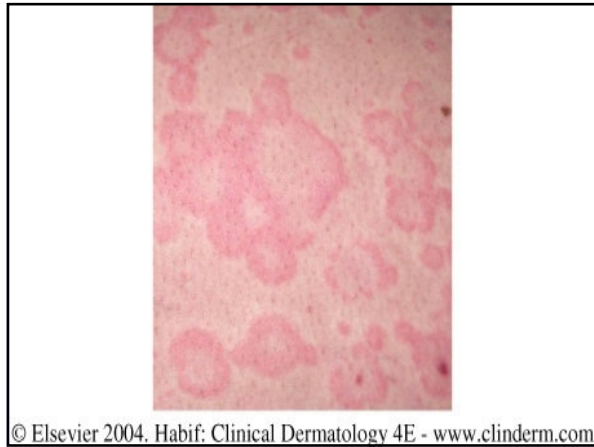
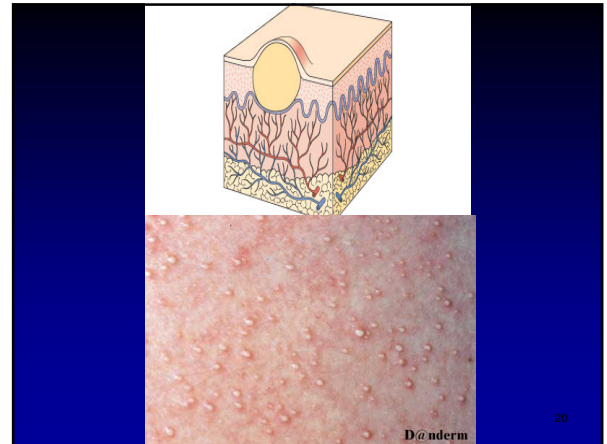
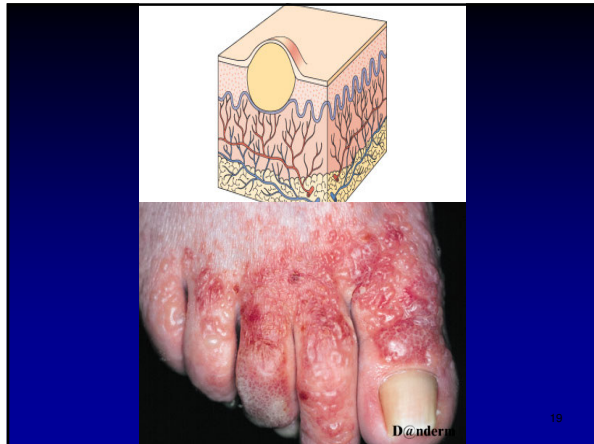
16



w.clinderm.com



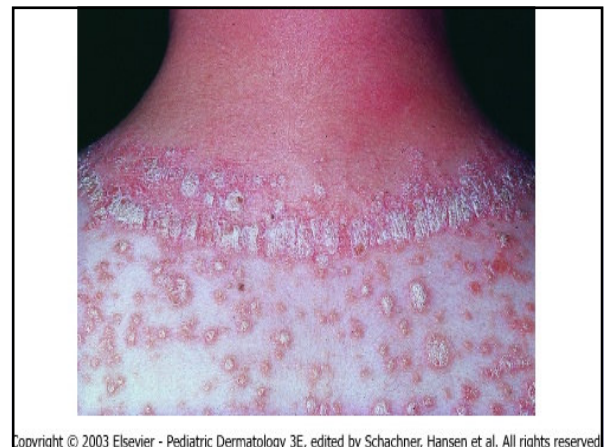18

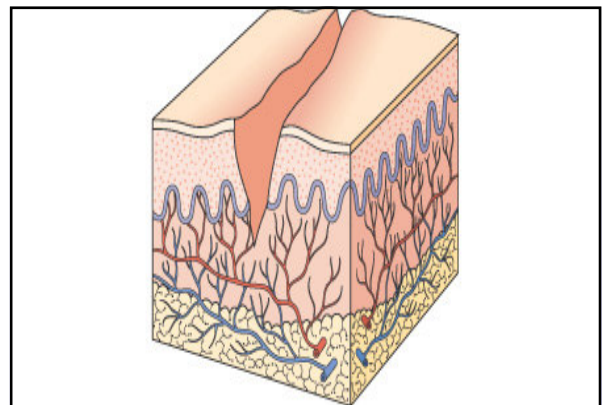
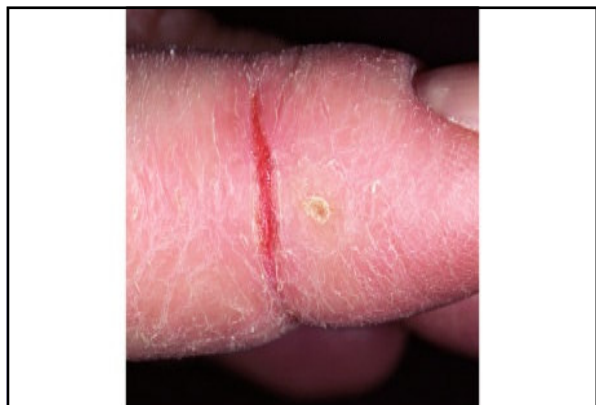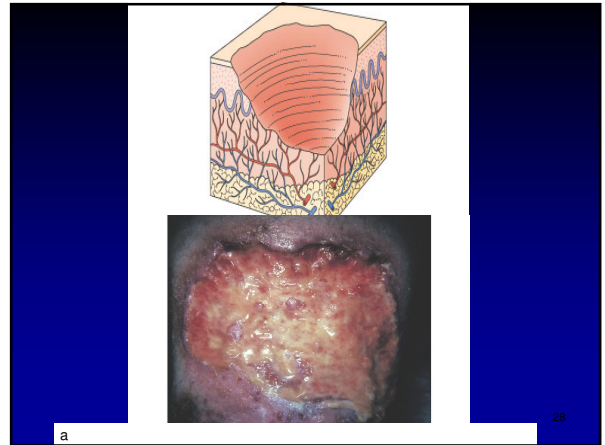
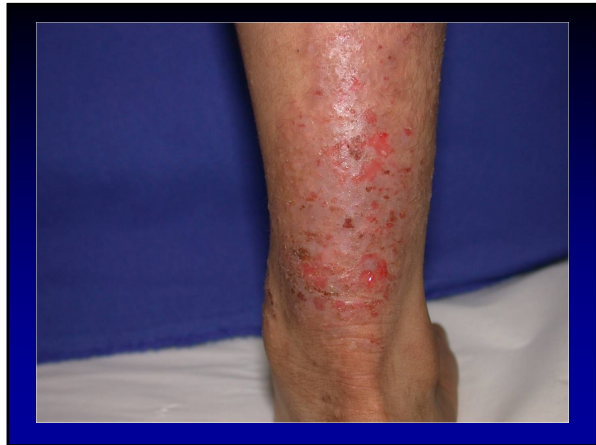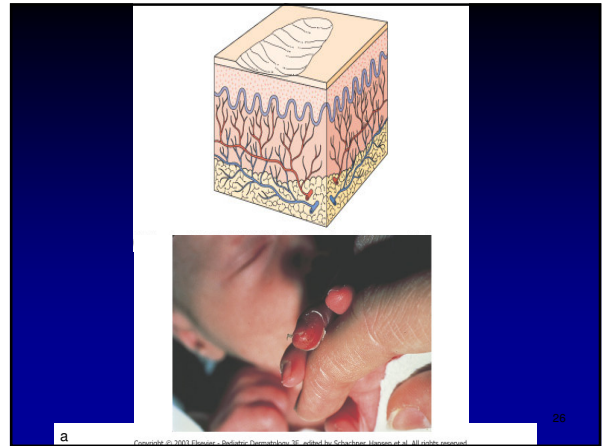


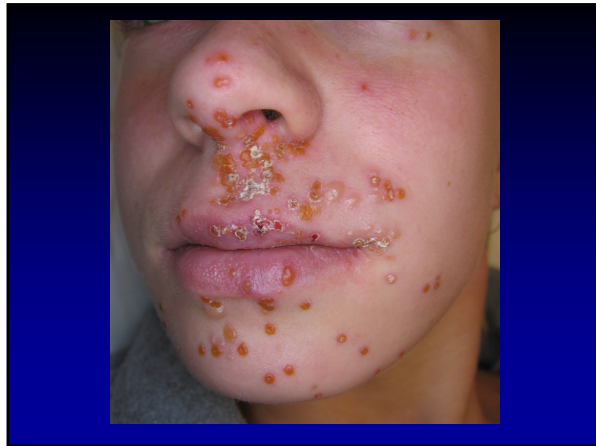Secondary lesions

- Crust
- Scale
- Ulceration
- Excoriation
- Scar
- Fissure
- Lichenification

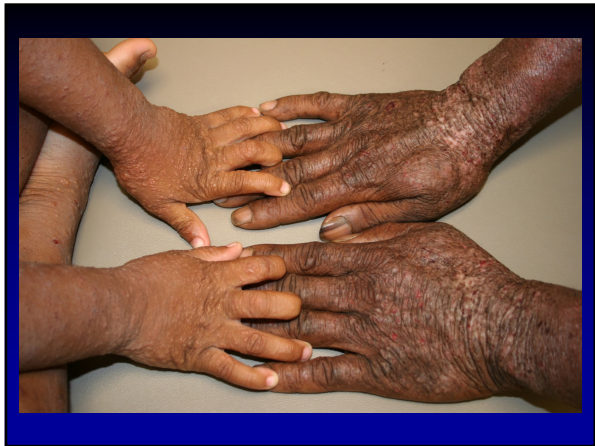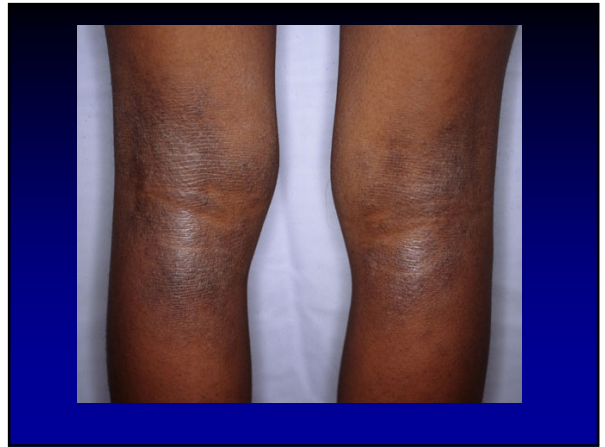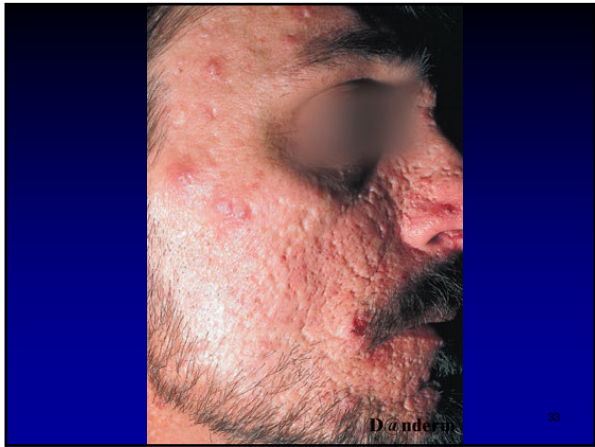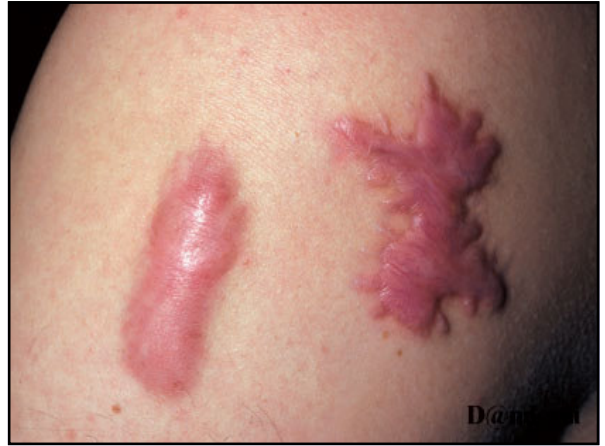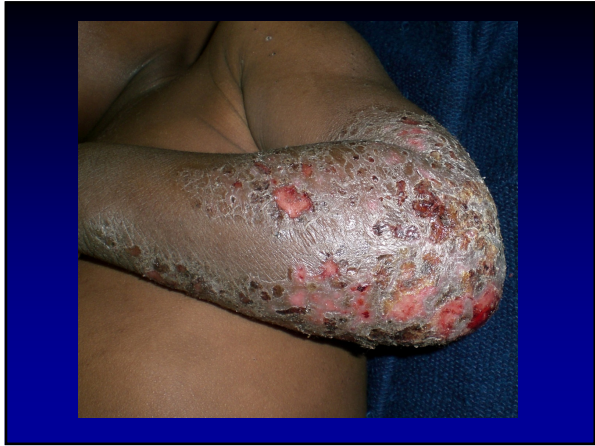23





© Elsevier 2004, Habif: Clinical Dermatology 4E - www.clinderm.com

© Elsevier 2004, Habif: Clinical Dermatology 4E - www.clinderm.com

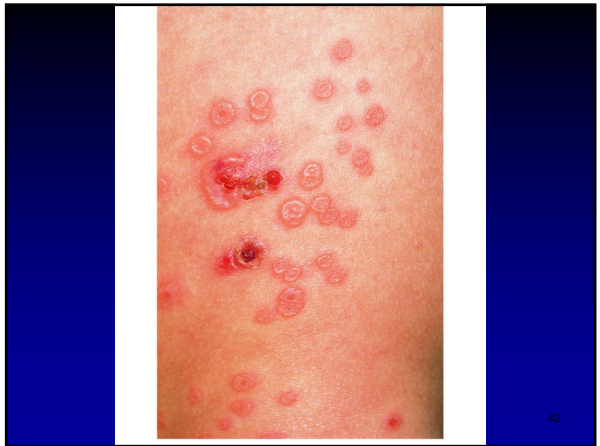
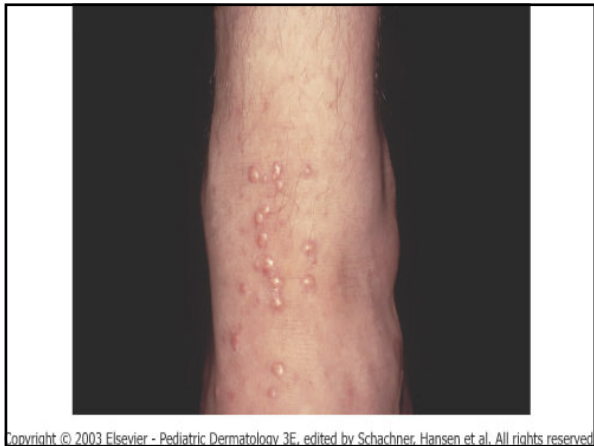
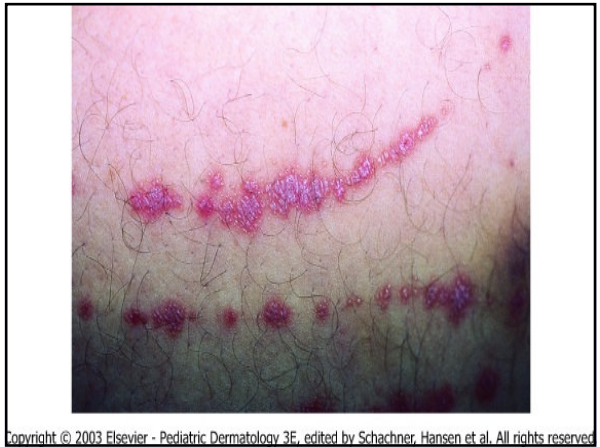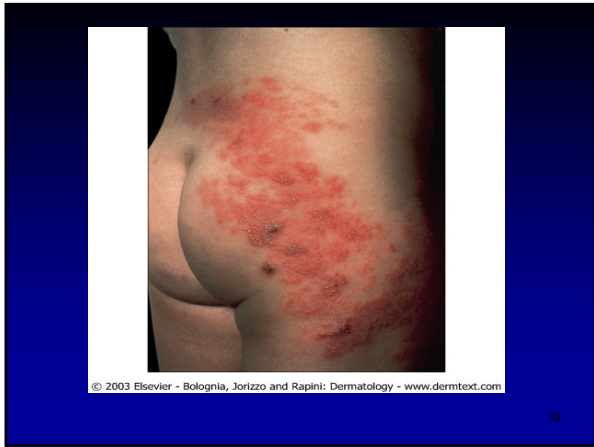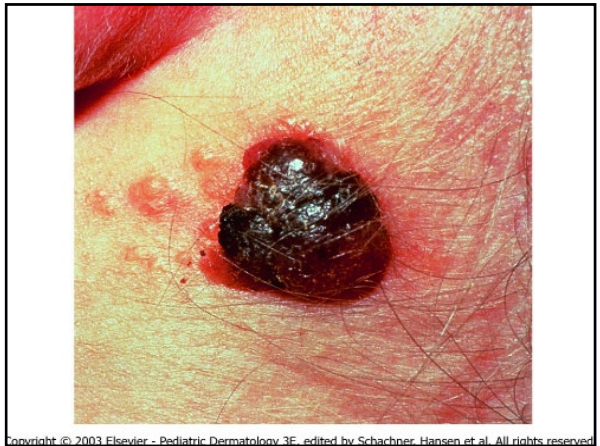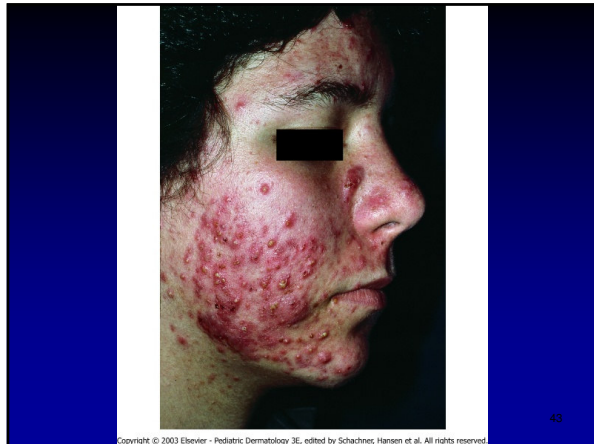Color and Shape

Distribution

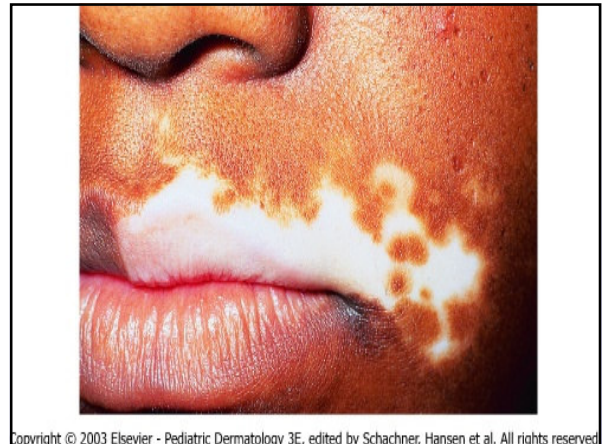Configuration

37





Copyright © 2003 Elsevier - Pediatric Dermatology 3E, edited by Schachner, Hansen et al. All rights reserved

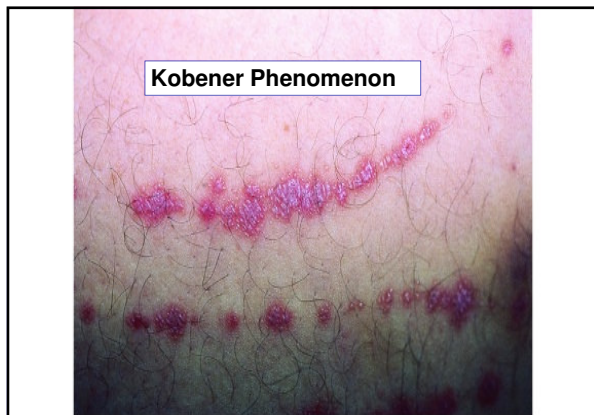


Copyright © 2003 Elsevier - Pediatric Dermatology 3E, edited by Schachner, Hansen et al. All rights reserved

Some specific signs in Dermatology

❖ **Dermatographism:** When you stroke the normal skin → edema and erythema (you can write on skin!) .Seen in physical urticaria

❖ **Kobener Phenomenon:** Induction of new skin lesions on previously normal appearing skin by trauma e.g. in psoriasis, wart, lichen planus



Copyright © 2003 Elsevier - Pediatric Dermatology 3E, edited by Schachner, Hansen et al. All rights reserved



Copyright © 2003 Elsevier - Pediatric Dermatology 3E, edited by Schachner, Hansen et al. All rights reserved

INVESTIGATIVE TOOLS

49

Additional skin examination

~**Wood's Lamp**: Produces long wave ultraviolet light(UVA). e.g.
Vitiligo → milky white
Tinea Versicolor → golden
Tinea Capitis (caused by microsporum) → yellow green
Erythrasma → coral red

~**Dermatoscopy**: Helpful to differentiate benign from malignant pigmented lesions.

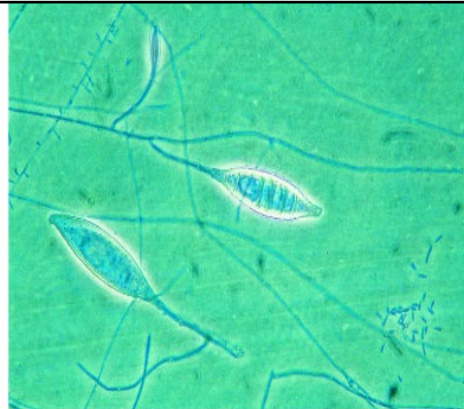50

Investigations

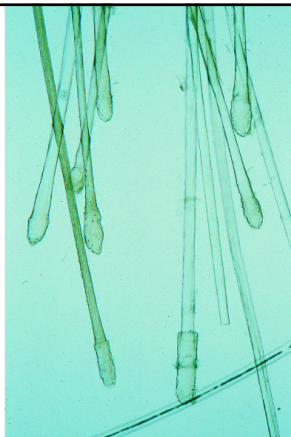*KOH and fungal culture

- Scrap skin scales → put over glass slide
- Add KOH 10% -- warm gently
- See under microscope
- You may see hyphae and/ or spores

51

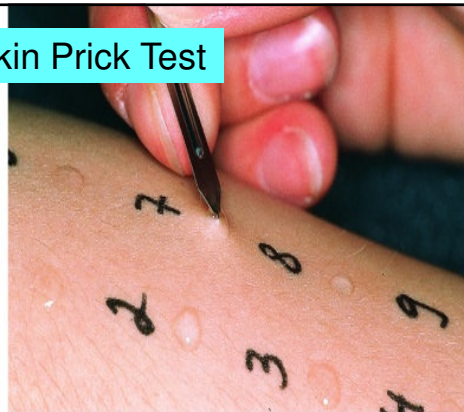

Copyright © 2003 Elsevier - Pediatric Dermatology 3E, edited by Schachner, Hansen et al. All rights reserved



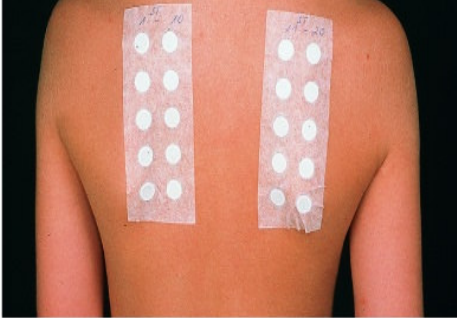53

Skin Prick Test



Copyright © 2003 Elsevier - Pediatric Dermatology 3E, edited by Schachner, Hansen et al. All rights reserved

Patch Test



Copyright © 2003 Elsevier - Pediatric Dermatology 3E, edited by Schachner, Hansen et al. All rights reserved

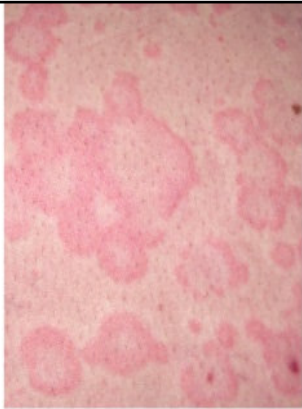
Investigations:

Skin biopsy

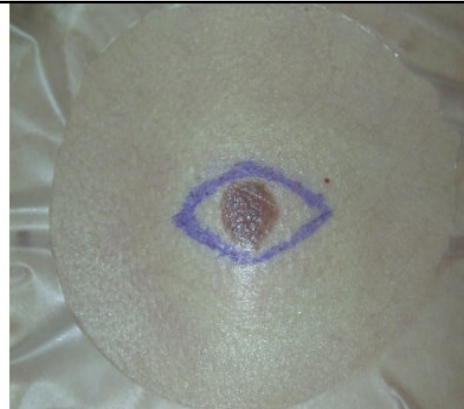local anesthesia,
different types:

- Punch
- Shave
- Excisional
- Incisional

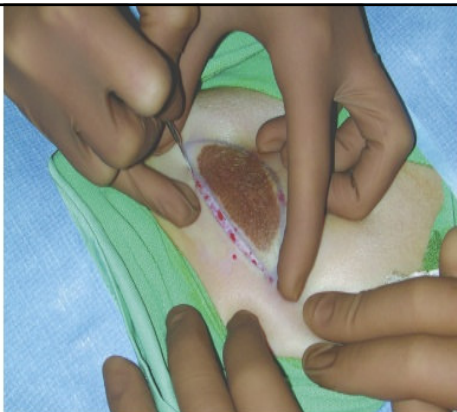66



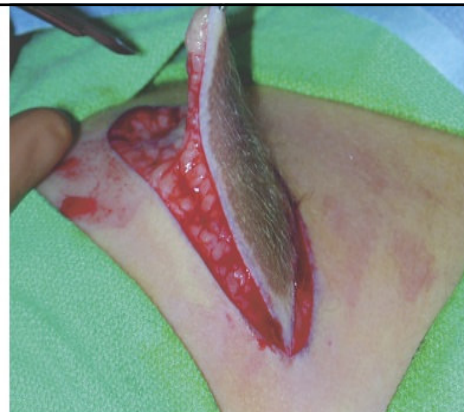© Elsevier 2004. Habif: Clinical Dermatology 4E - www.clinderm.com



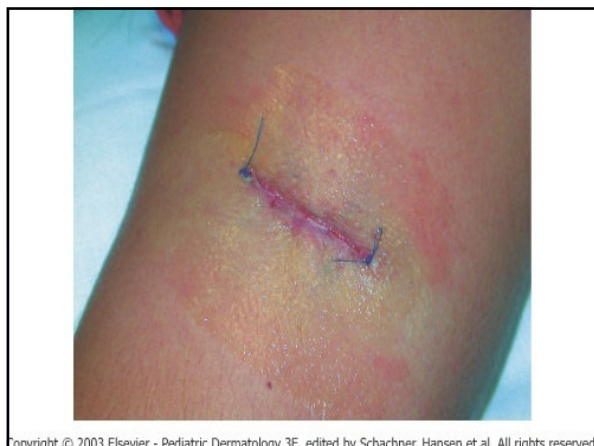Copyright © 2003 Elsevier - Pediatric Dermatology 3E, edited by Schachner, Hansen et al. All rights reserved



Copyright © 2003 Elsevier - Pediatric Dermatology 3E, edited by Schachner, Hansen et al. All rights reserved



Copyright © 2003 Elsevier - Pediatric Dermatology 3E, edited by Schachner, Hansen et al. All rights reserved



Treatment:

Topical

Systemic

62

Topical Treatments

Various formulations:

- Ointment
- Cream
- Gel
- Solution
- Lotion

63

Topical steroids

7 Categories:
according to strength

64

Phototherapy

Ultraviolet light A or B
with or without psoralen

PUVA (Psoralen + UVA)

New modalities:

- Narrow band UVB
- UVA – 1
- Excimer laser(308nm)

65

Dermatology subspecialties

- Pediatric dermatology
- Photomedicine
- Laser
- Hair Disorders and Transplantation
- Dermatologic surgery
- Allergy/Contact dermatitis
- Dermatopathology
- Immunodermatology
- Others

