

اوسس

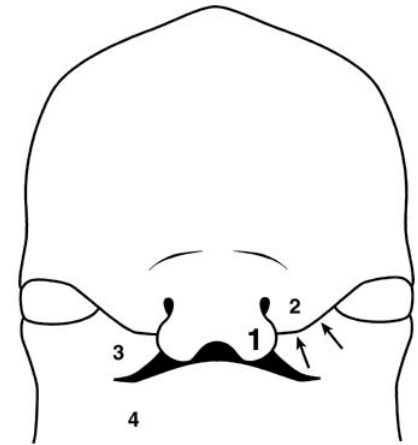
Dr. Abdulrahman Hagr Al-Ghamdi MBBS FRCS(c)
Assistant Professor King Saud University
Otolaryngology Consultant
Otologist, Neurotologist & Skull Base Surgeon
King Abdulaziz Hospital

Nose

- *Embryology*
- *Anatomy*
- *Physiology*
- *Investigation*
- *Nasal septum, vestibule & choanal atresia*

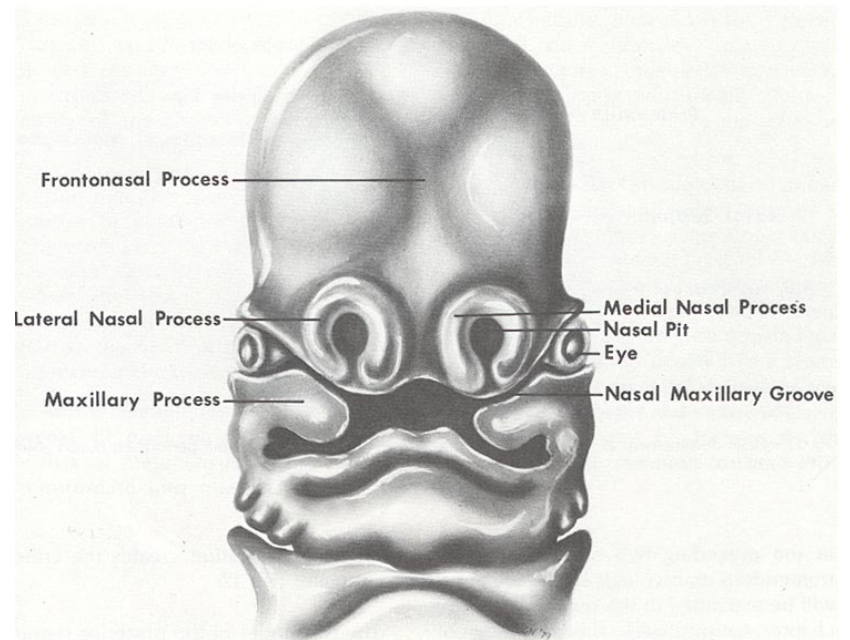
Nose

- *Embryology*
- *Anatomy*
- *Physiology*
- *Investigation*
- *Nasal septum, vestibule & choanal atresia*



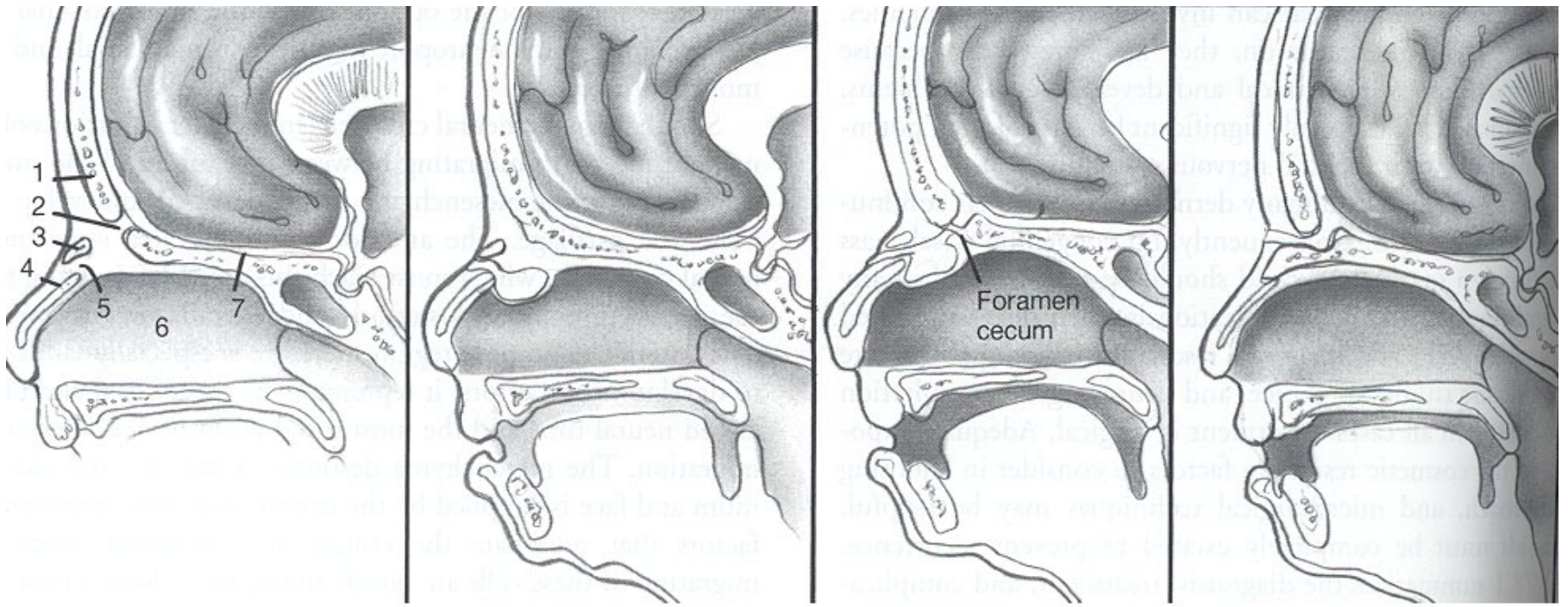
Nose

- 2 nasal pits invaginate
→ nasobuccal
membrane NBM
(*Choanal Atresia*)
- NBM ruptures (10 w)
→ communication nose +
Nasopharynx



Sinuses

- **Maxillary Sinuses**
 - Present at birth
- **Ethmoid Sinus**
 - Evaginations of the lateral nasal wall (3rd m gestation)
 - Are present at birth
 - Adult size by age 12
- **Frontal Sinus**
 - Evagination of the anterior nasal capsule (4th m gestation)
 - Rarely present at birth; visible until age 2
- **Sphenoid Sinus**
 - Outpuchings of the superior nasal vault (4th m gestation)
 - Rarely present at birth, usually seen around 4y



Congenital masses

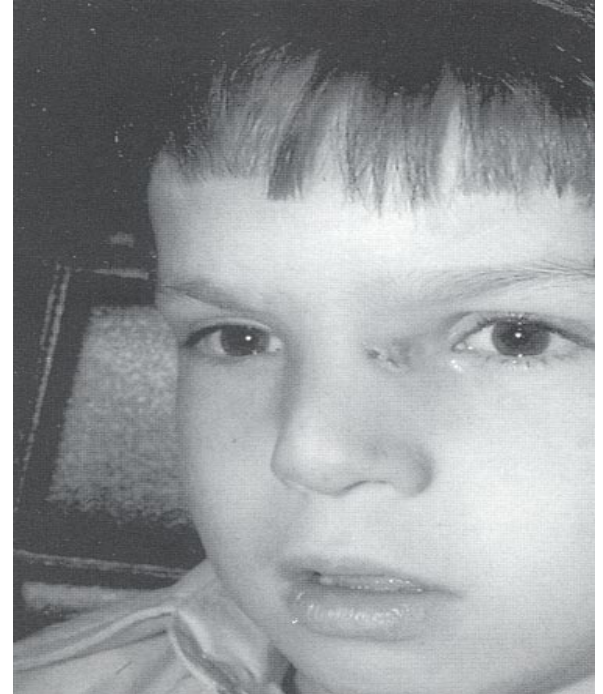
- Dermoid sinuses and cysts
- Gliomas
- Encephaloceles

Congenital masses

- Have potential intracranial connections
- Mass on nasal dorsum or as intranasal mass
- Biopsy can lead to meningitis and CSF leak
- Treatment is surgical excision

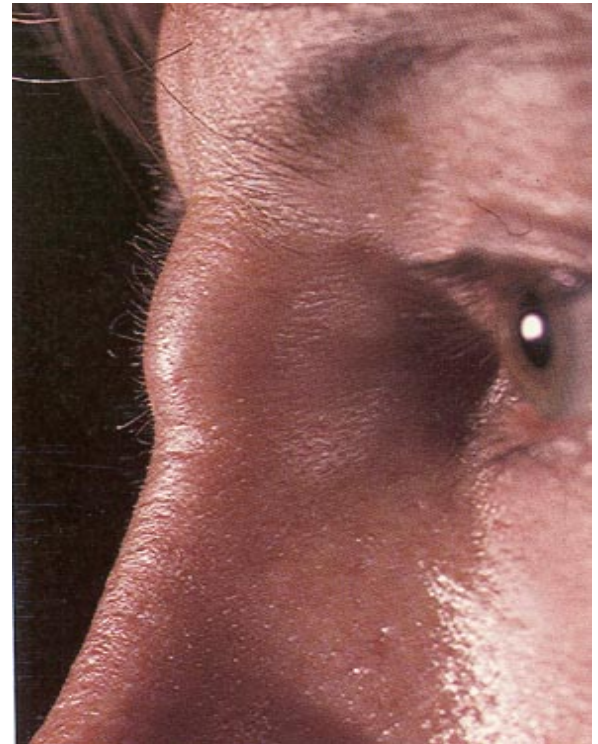
Dermoids

- Cyst or sinus
- Most common congenital midline mass
- Ectodermal and mesodermal
- Midline nasal pit, fistula
- Tract with hair at opening
- Secrete pus or sebaceous material

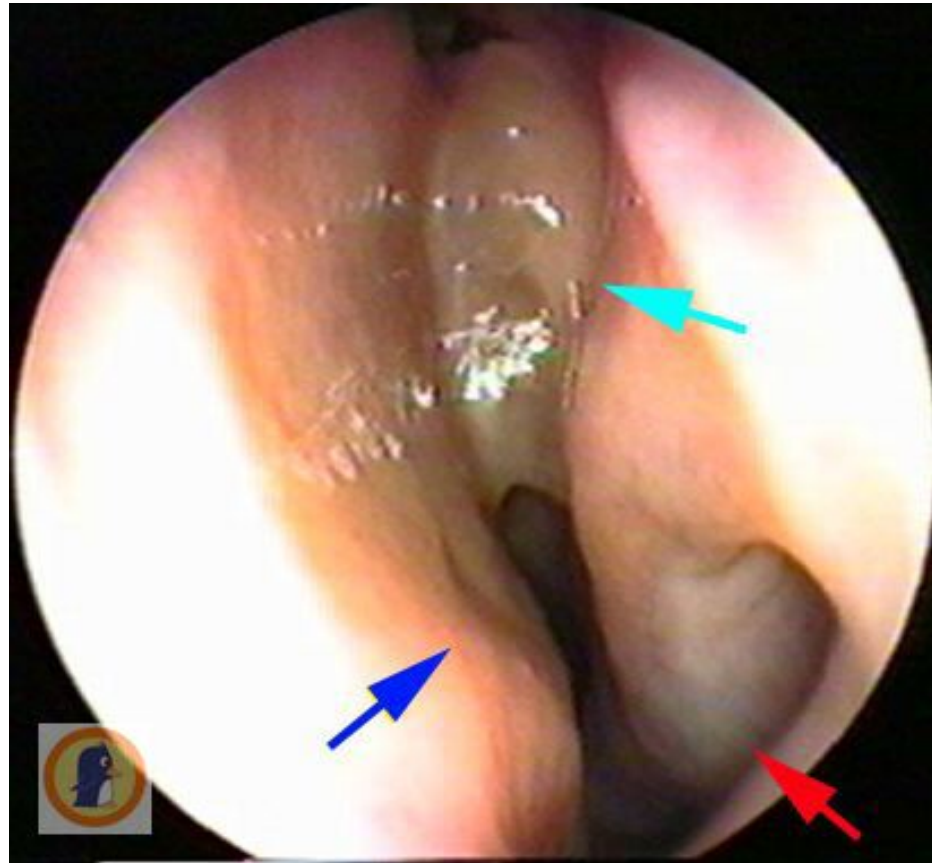


Complications

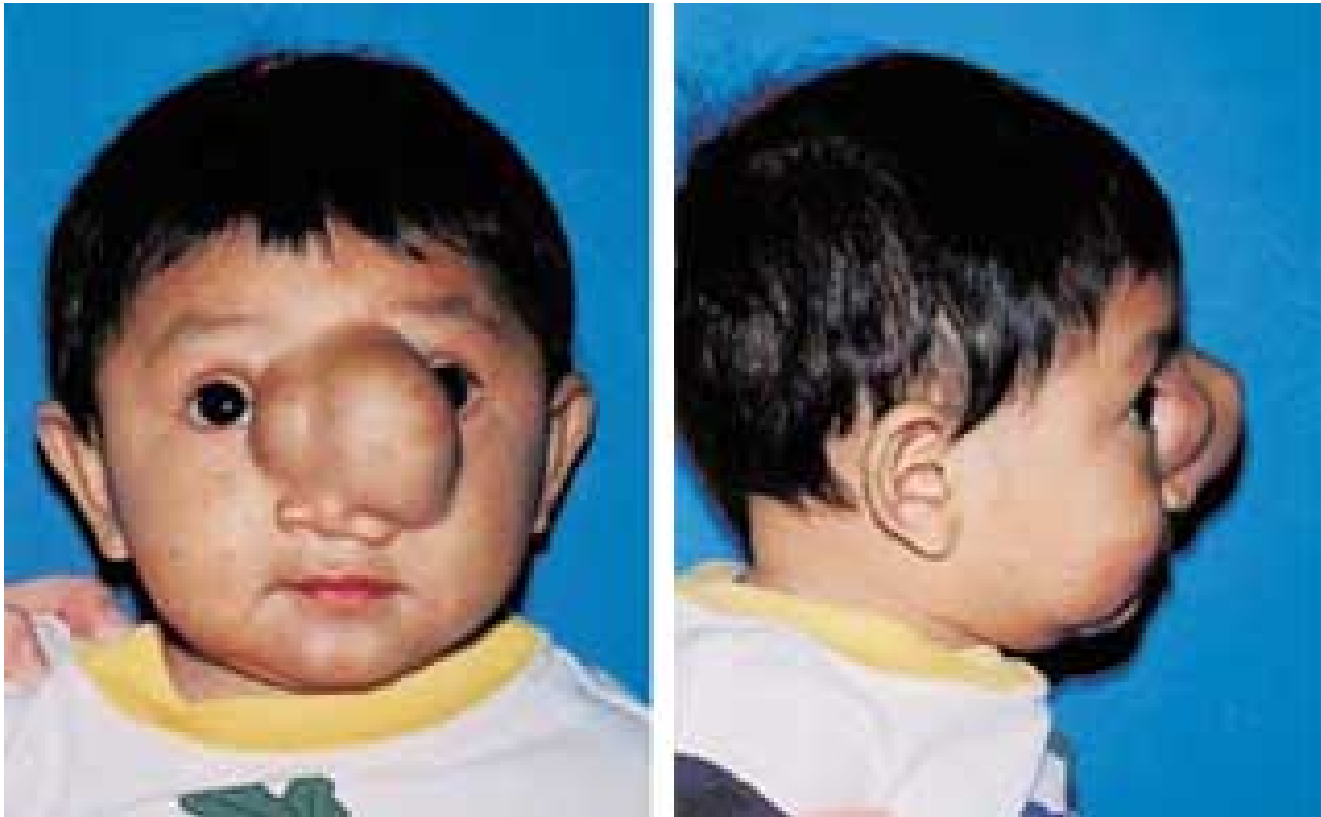- Intermittent inflammation
- Abscess
- Osteomyelitis
- Broaden nasal root
- Meningitis
- Cerebral abscess



Gliomas

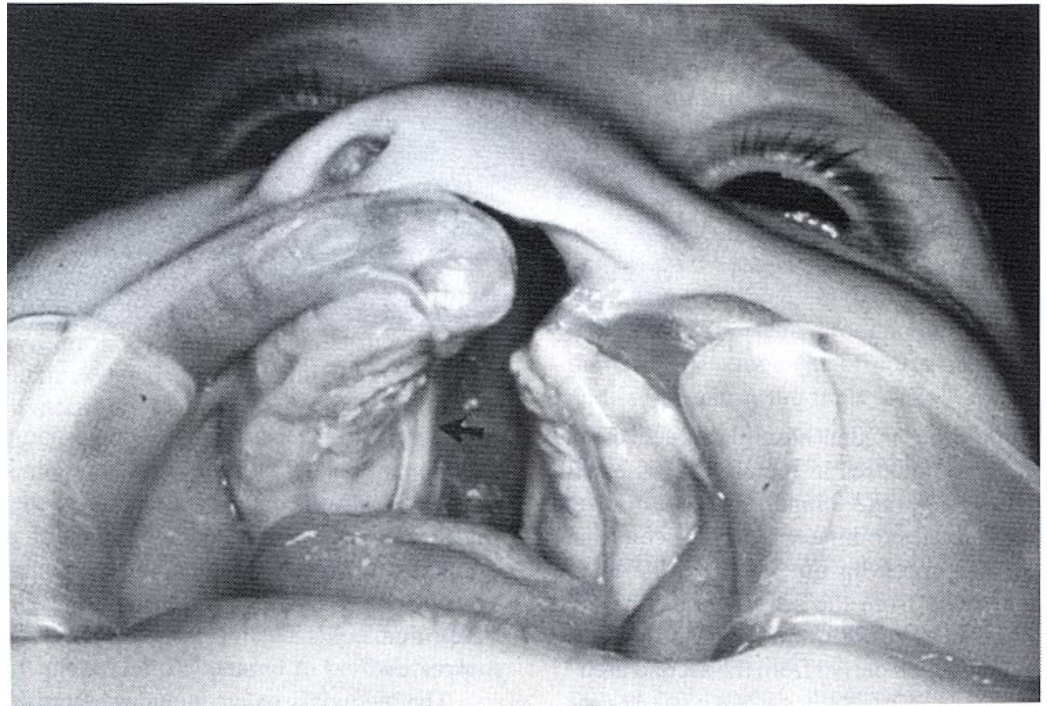


Encephaloceles



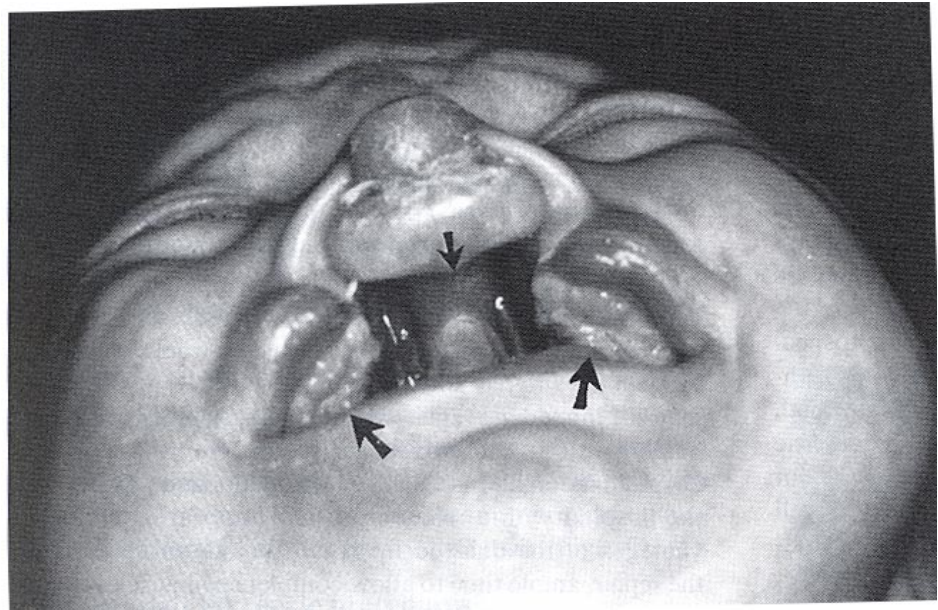
Cleft Anatomy - The Nose

- Ipsilateral LLC
 - flattened
 - rotated downward
- Short columella
- Bifid tip



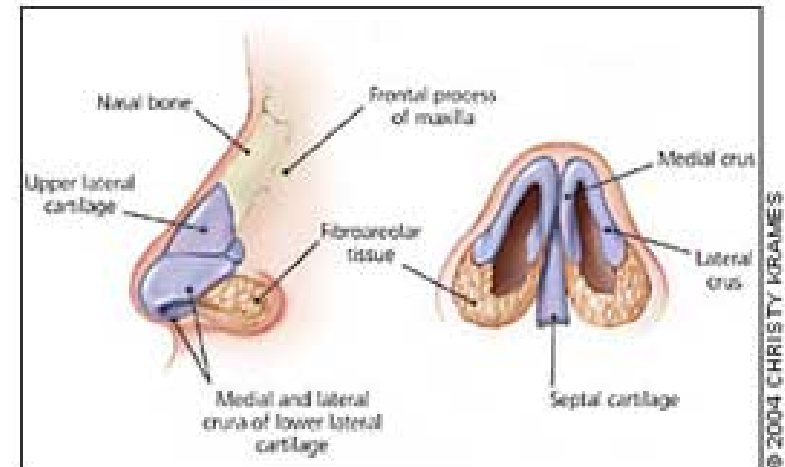
Cleft Anatomy: continued

- Bilateral Cleft
Lip/Alveolus/nose



Nose

- *Embryology*
- *Anatomy*
- *Physiology*
- *Investigation*
- *Nasal septum, vestibule & choanal atresia*

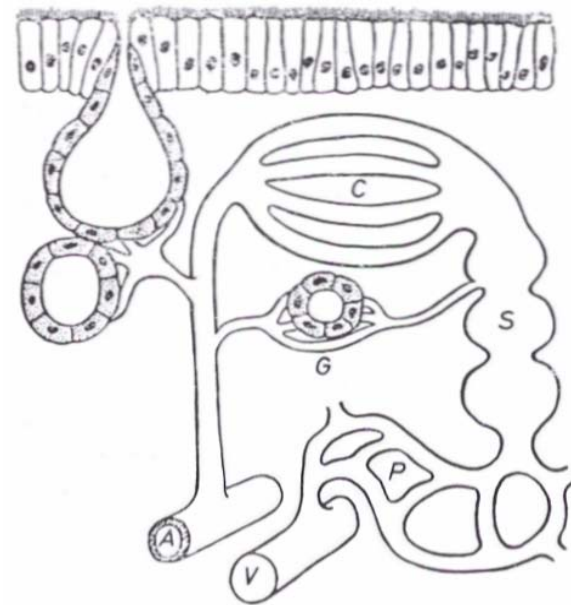


Epithelium

- Anteriorly (Skin)
 - Stratified squamous epithelium
- All other surfaces.
 - Pseudostratified ciliated columnar (respiratory epi)
 - Muocsa secretes → Mucous blanket
 - Cleaning
 - Filtering (traps bacteria)
 - Maintain the moisture nose.

Sub-mucosa (Temp)

- Sinusoids
- Capillaries



Nasal septum

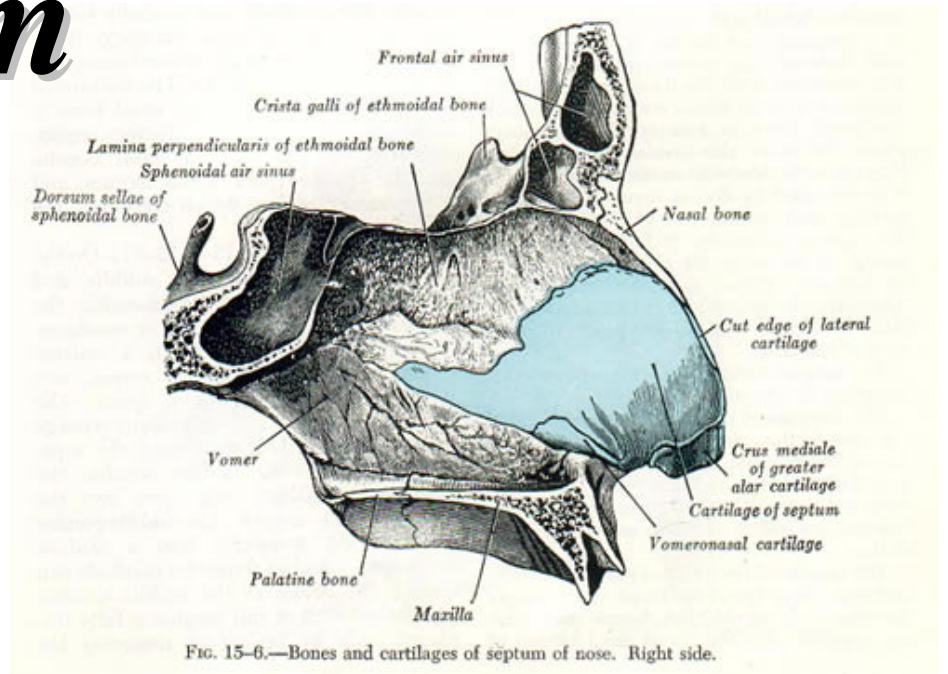
Significance: functional and aesthetic.

1. Main support of the external nose
2. Divides the nose into two cavities
3. Supports the mucosal lining

Nasal septum

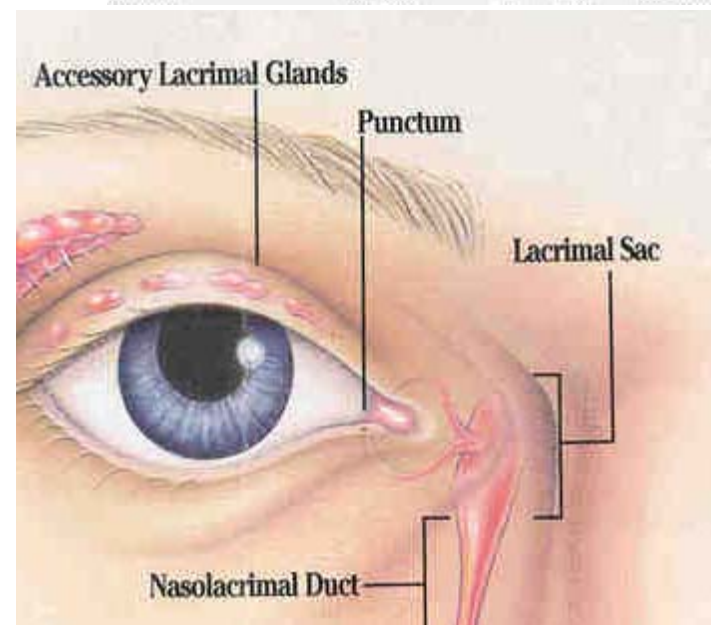
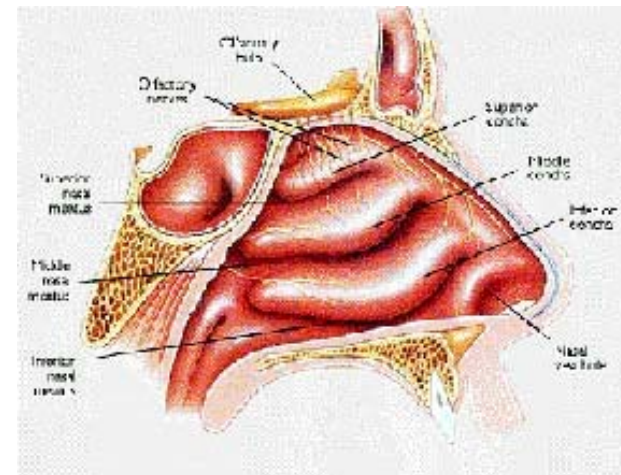
Septum include the

1. Nasal bones.
2. Vomer
3. Frontal bone
4. Palatine bone
5. Maxilla and premaxilla,
6. Perpendicular plate of the ethmoid,
7. Quadrilateral cartilage

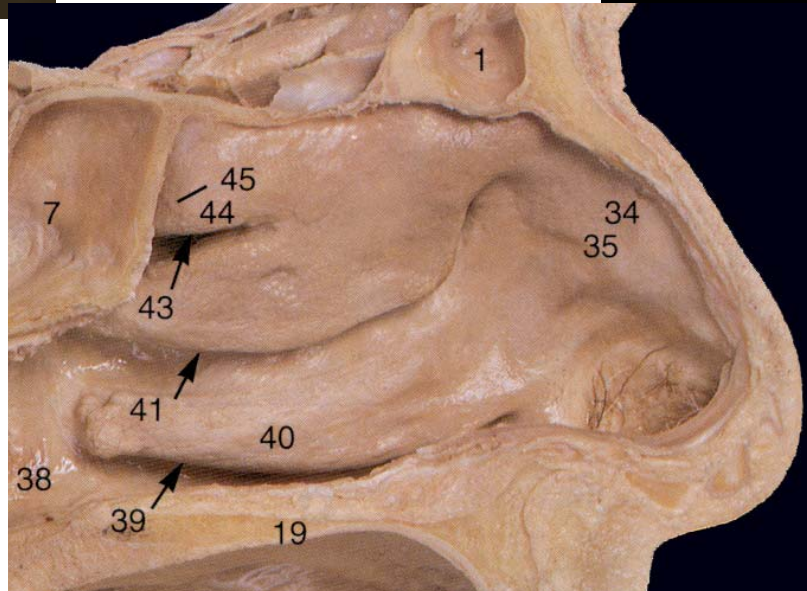
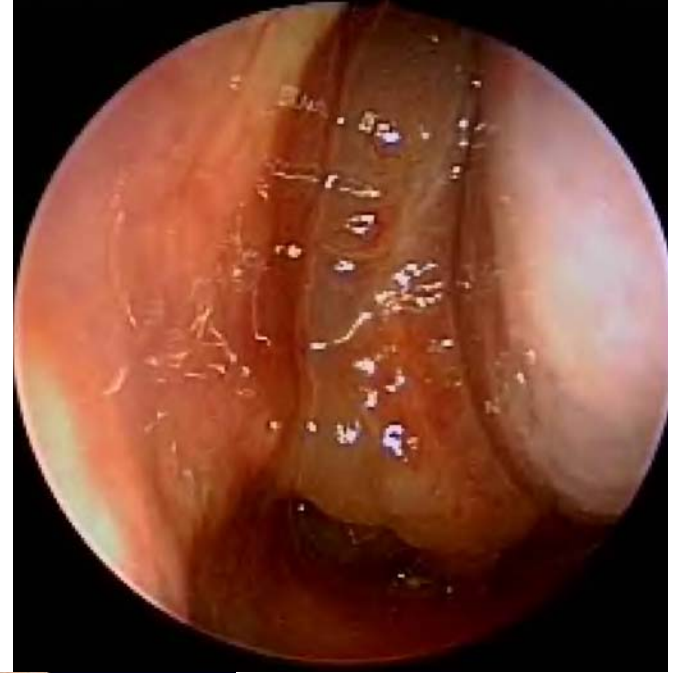
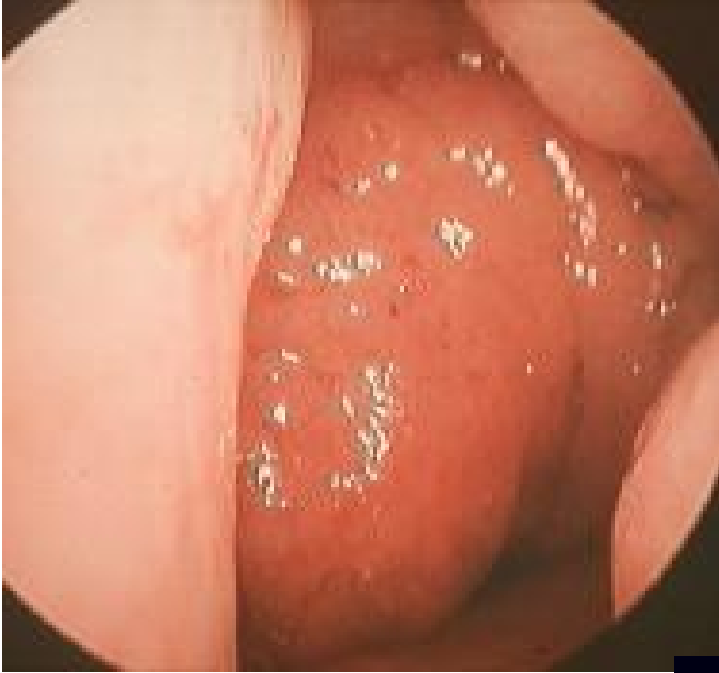
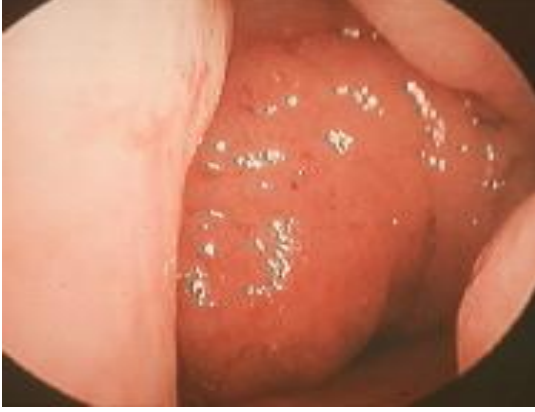Turbinates

- Inferior, middle, and superior
- Thin bone covered by an adherent mucoperiosteum.
- The turbinates
 - Maximize surface area
 - Rapidly humidify
 - Warm the inspired air

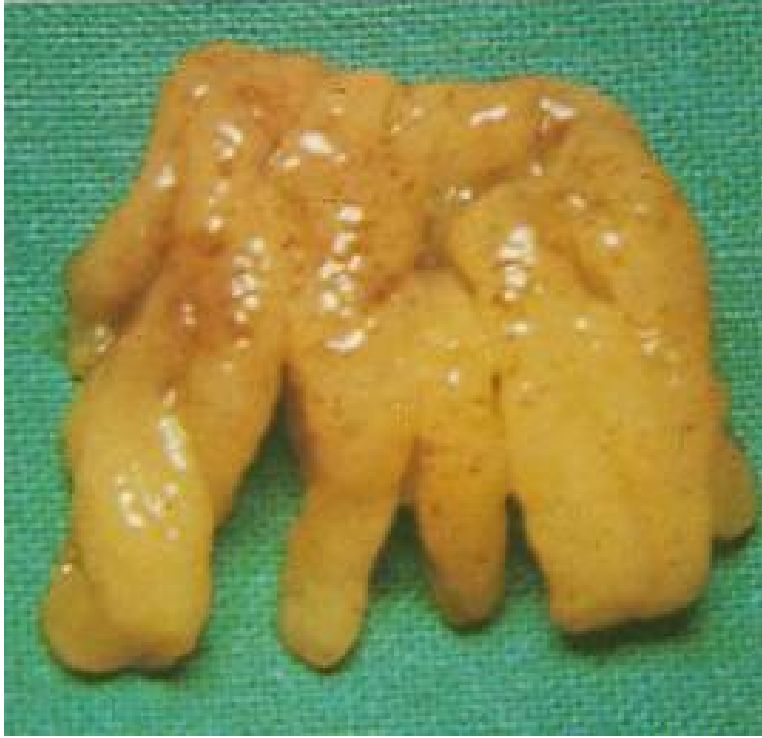

لحميات؟



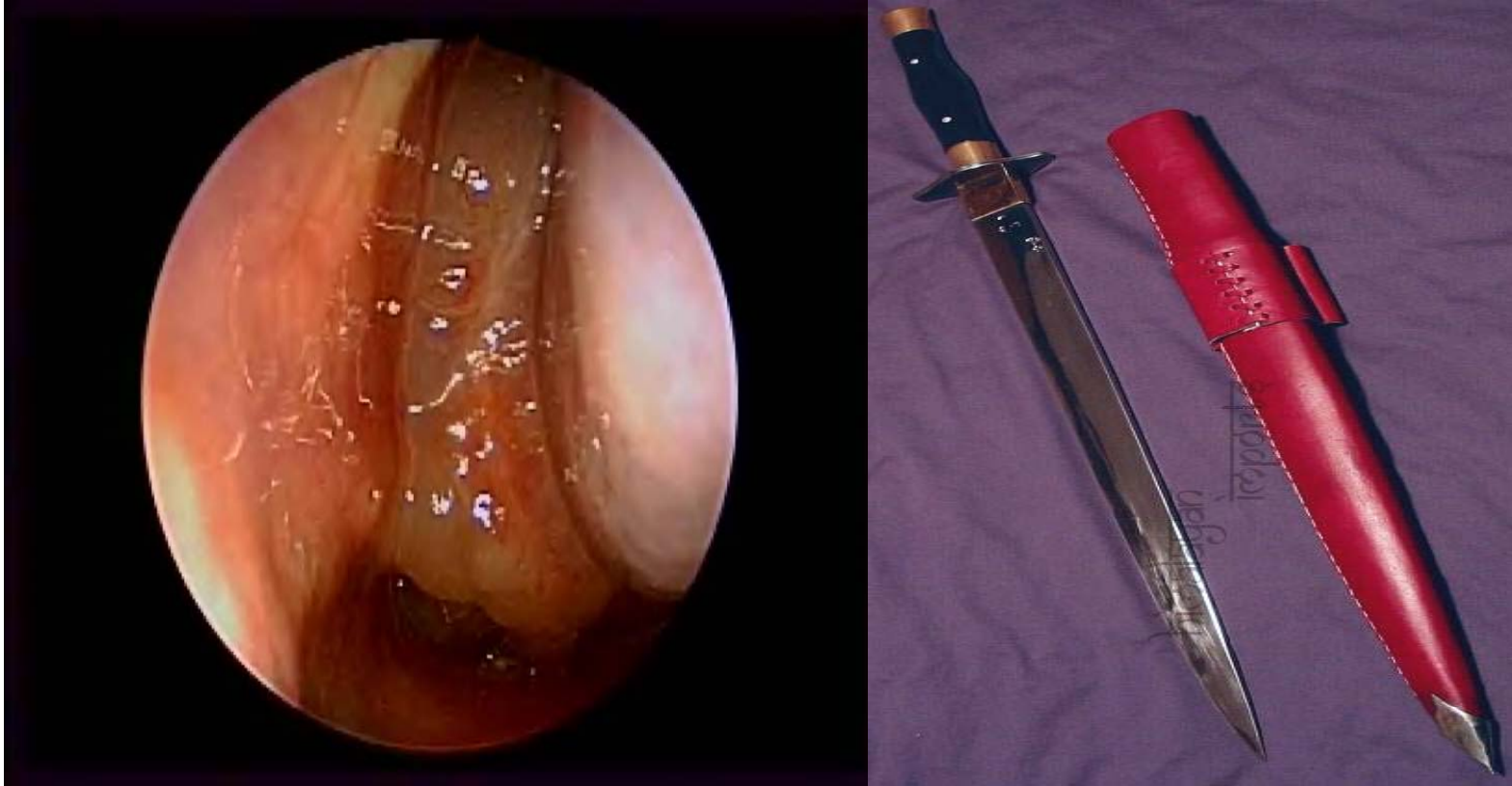

Adenoid = الناميات



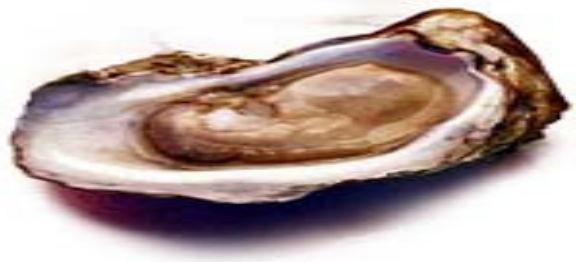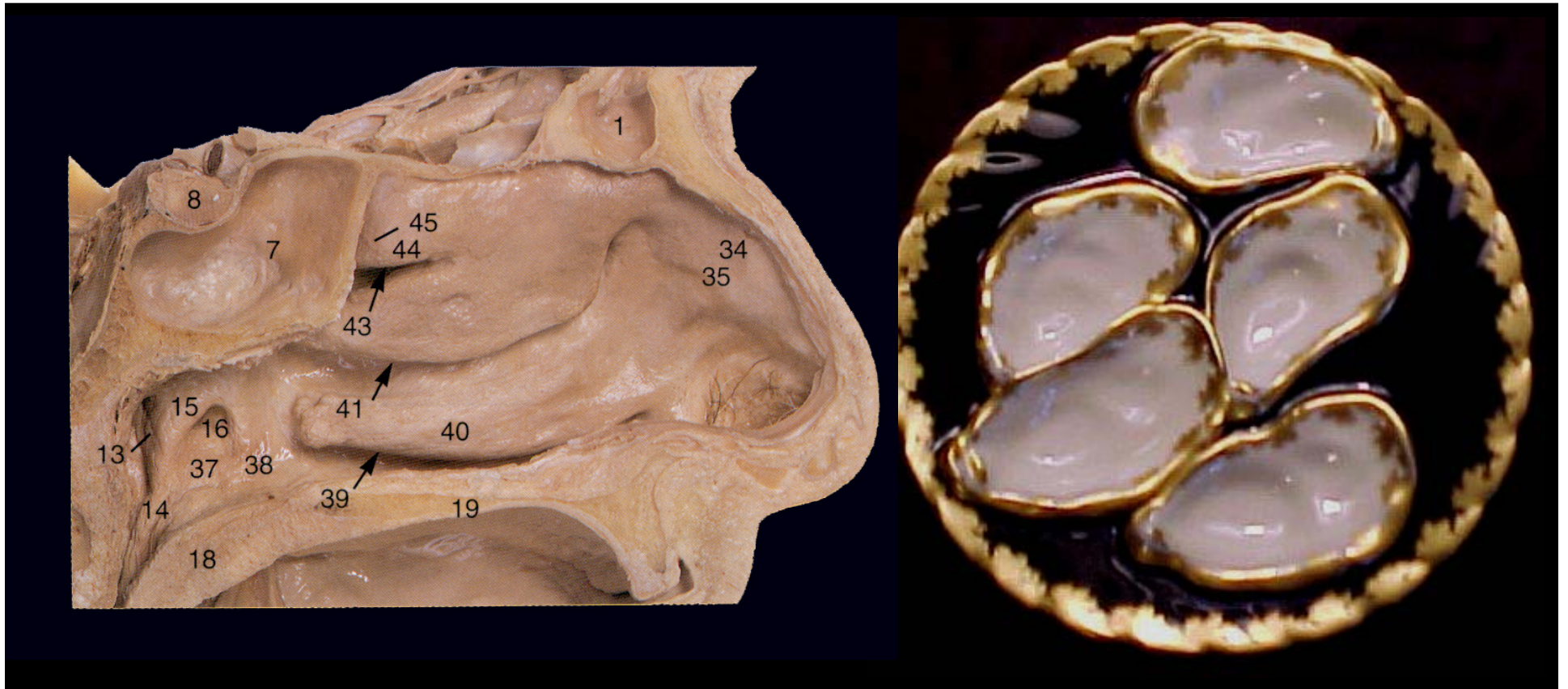
النامية : الكرمة ذات نوام كثيرة

Polyps = سئيلات

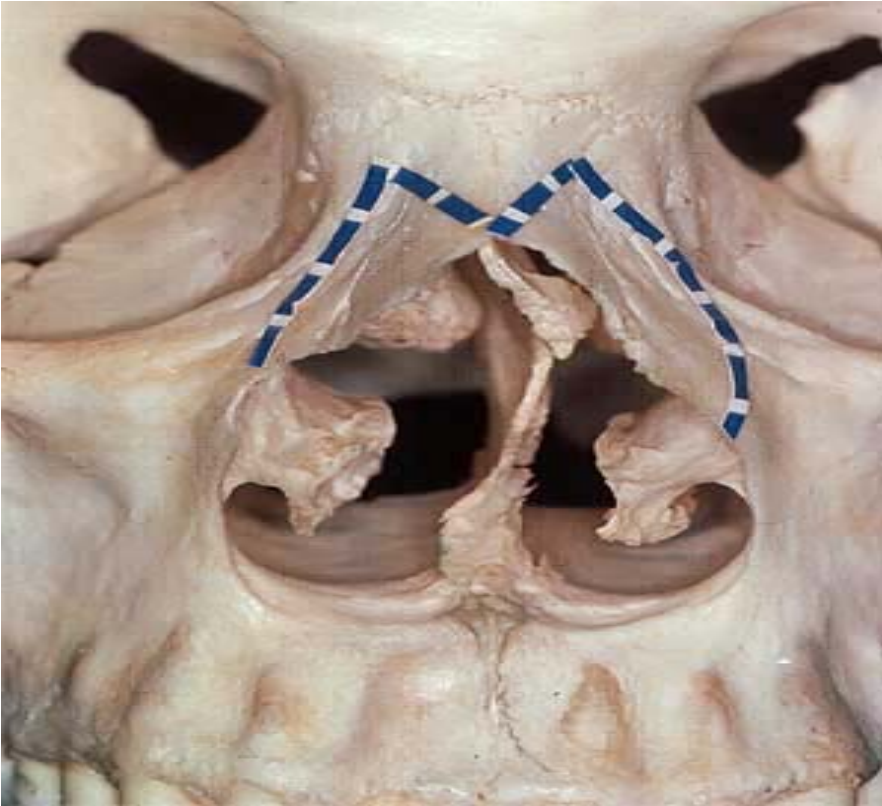


منحدرٌ / خارج سليلُ أسرةِ كذا، أي منحدرٌ منها؛
”سيف الله المسلول“ السيفُ المُستَلُّ من غمده

Turbanate= محار



Concha = فرینکات



Blood Supply

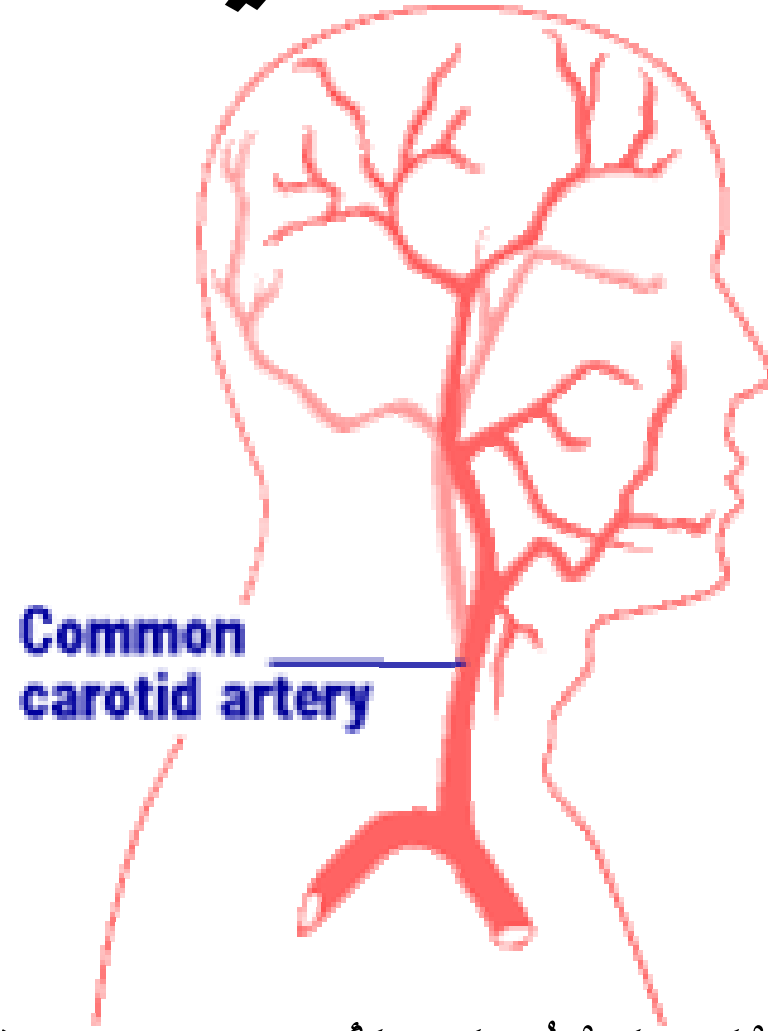
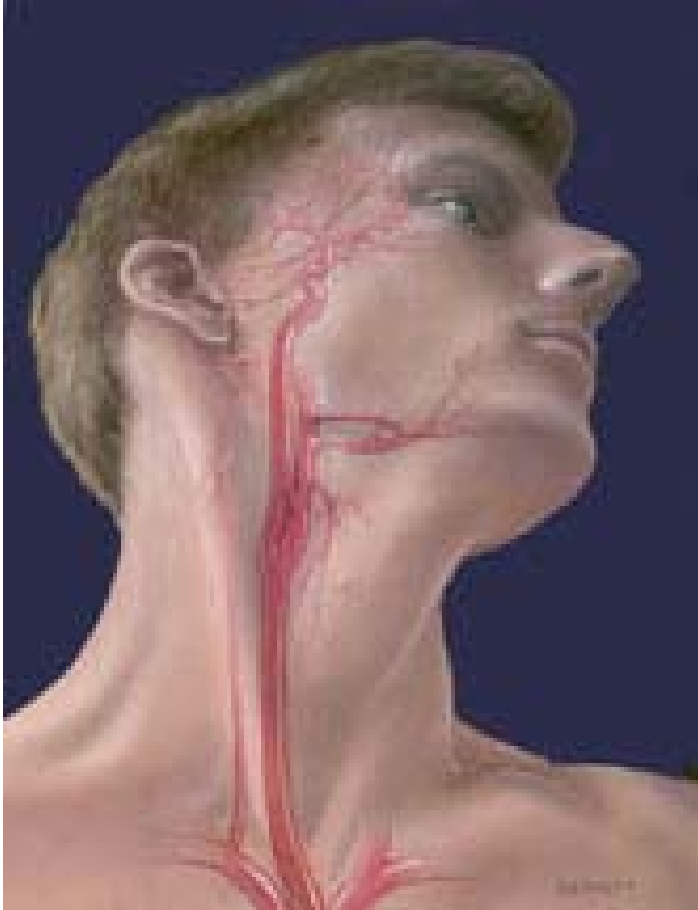
External Carotid Artery

- Sphenopalatine artery**
- Greater palatine artery**
- Ascending pharyngeal artery**
- Posterior nasal artery**
- Superior Labial artery**

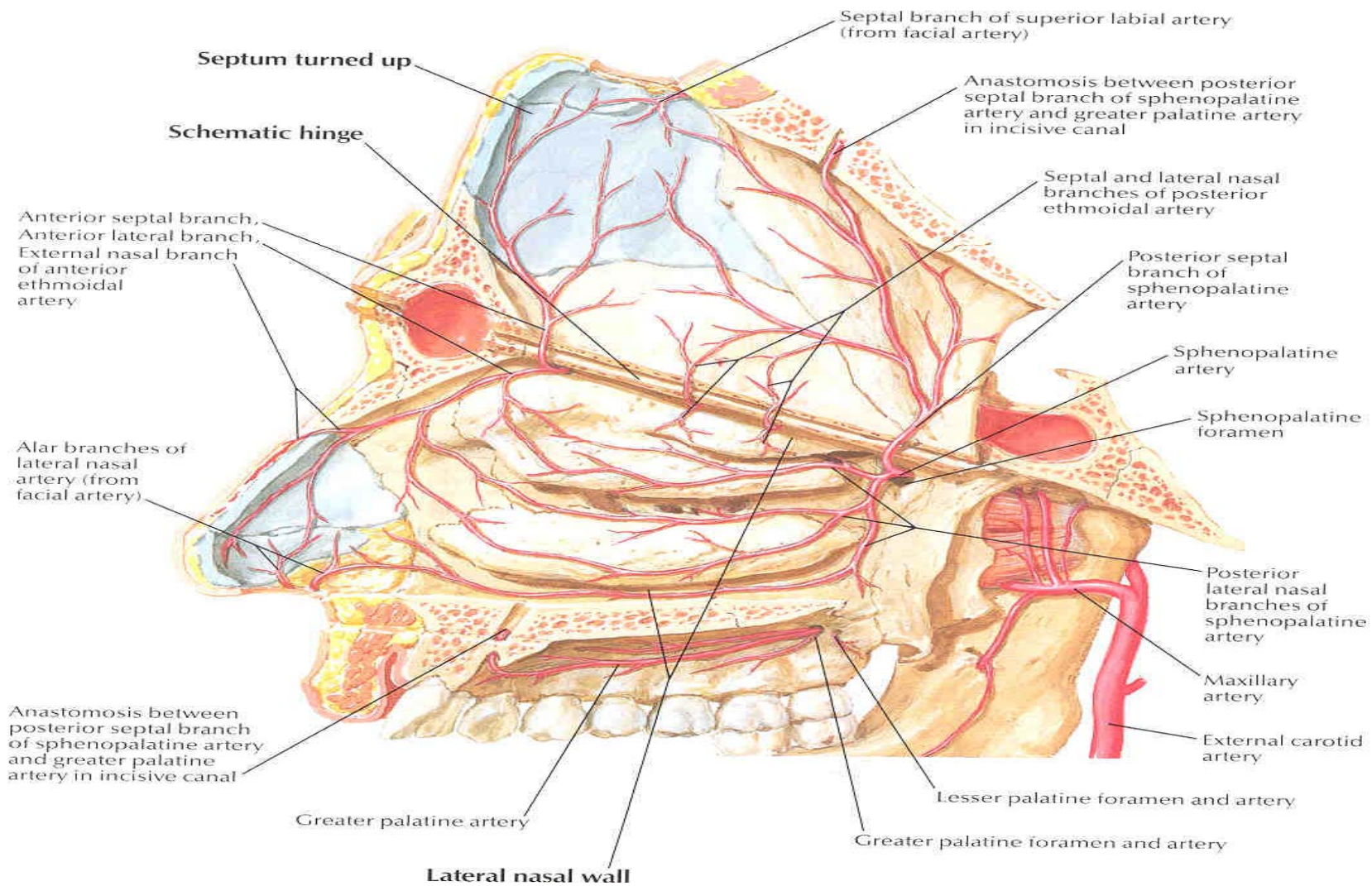
Internal Carotid Artery

- Anterior Ethmoid artery**
- Posterior Ethmoid artery**

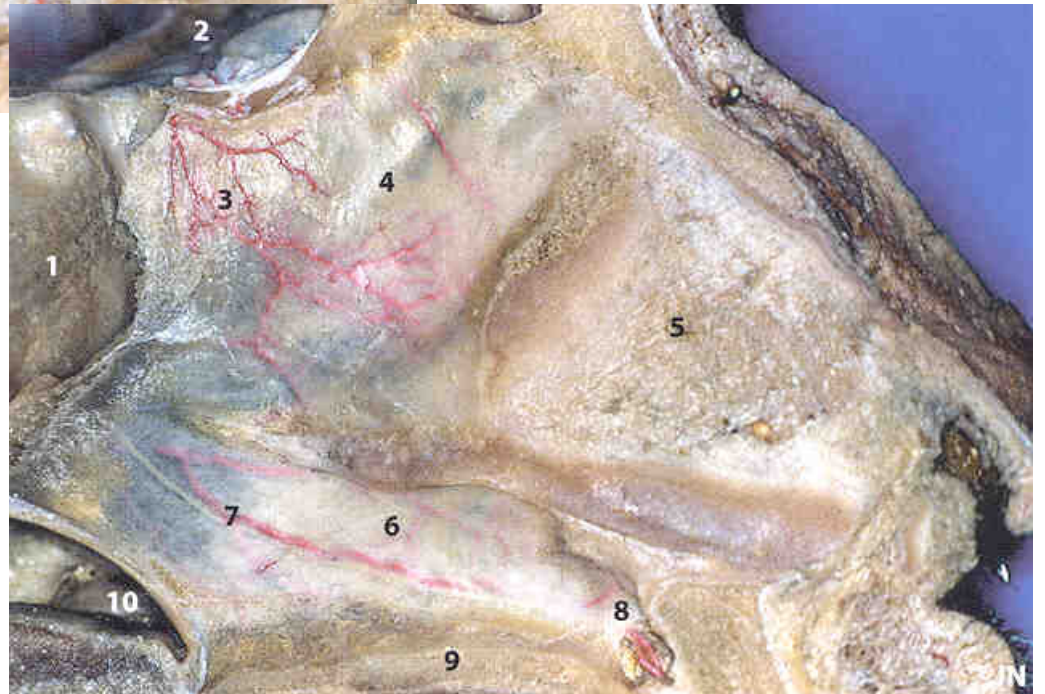
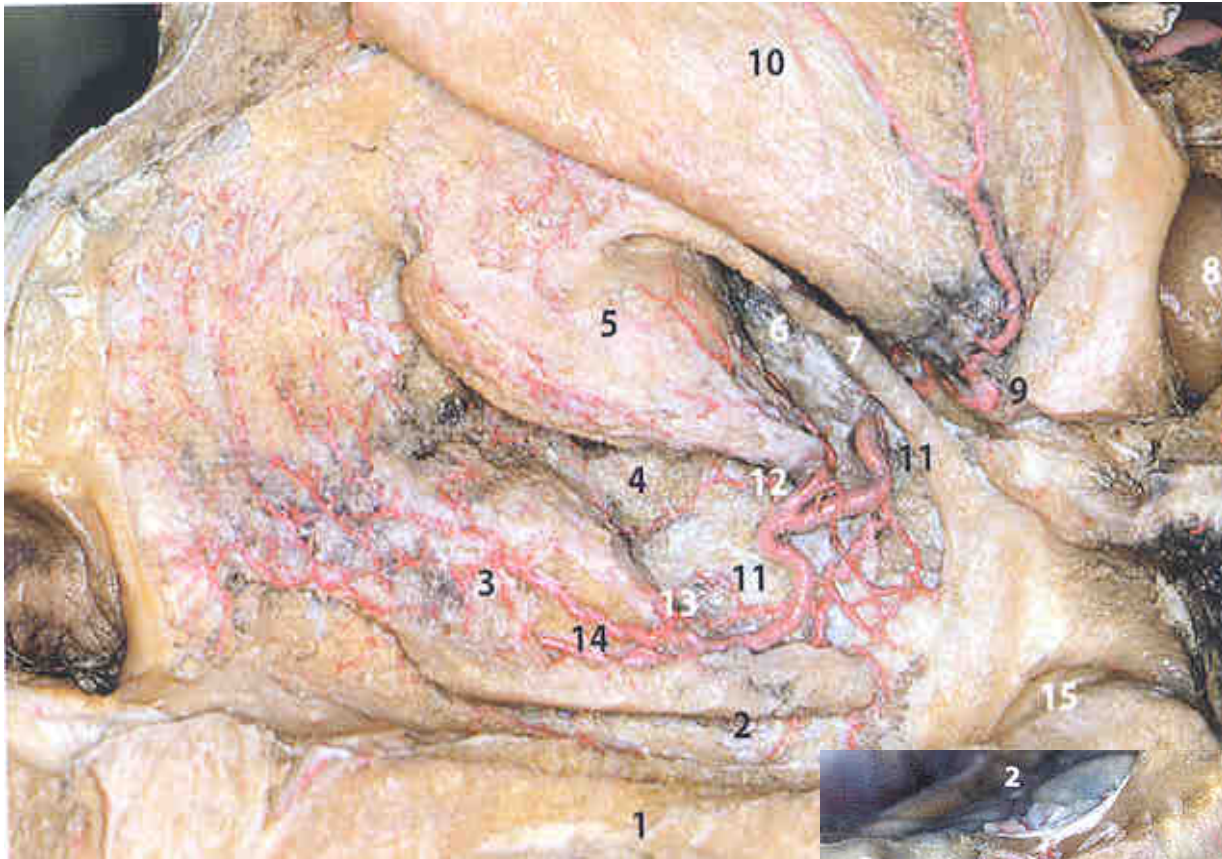
Carotid = سبائي



(وَيَوْمَ لَا يَسْئَلُونَ لَا تَأْتِيهِمْ) سبب لانقطاع الأيام عنده.... انقطاع الدم عنده



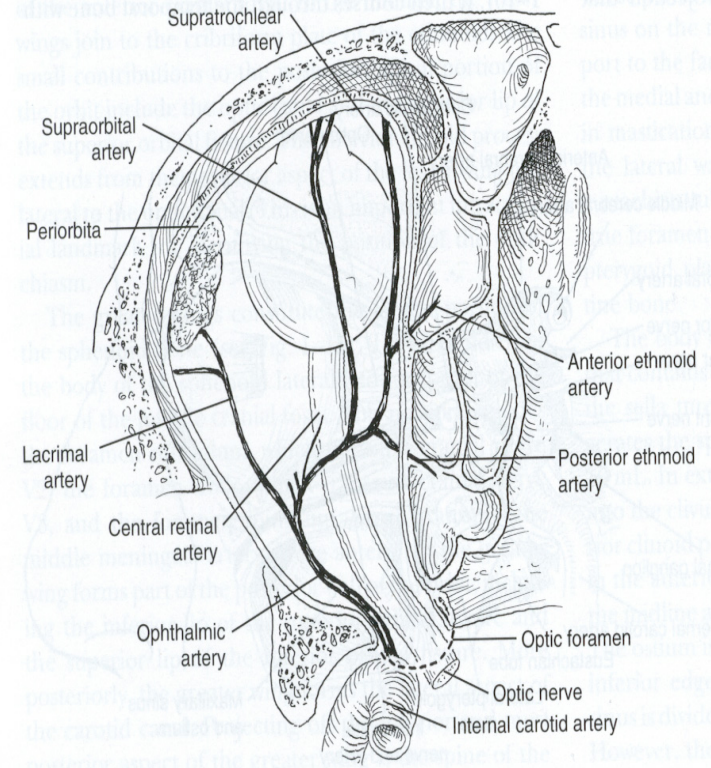
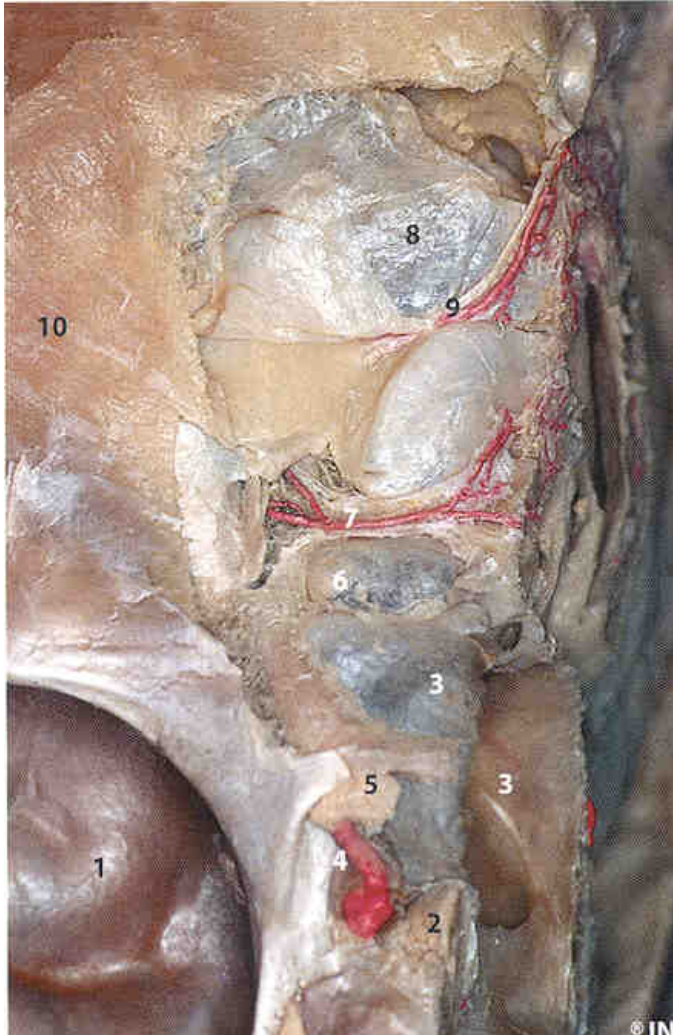
Anatomy of the Nasal Cavity and Vasculature

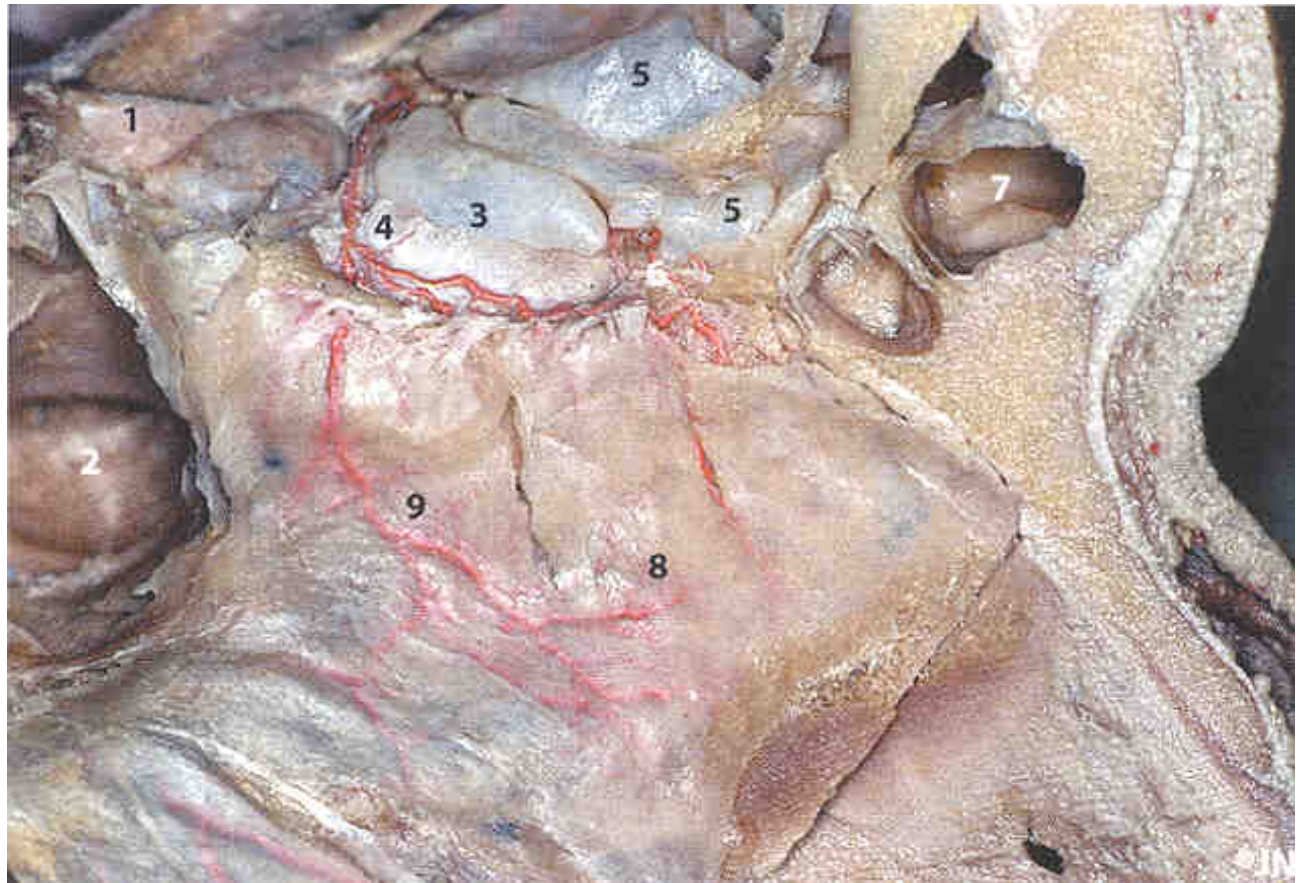


Sphenopalatine AA

Ethmoid AA

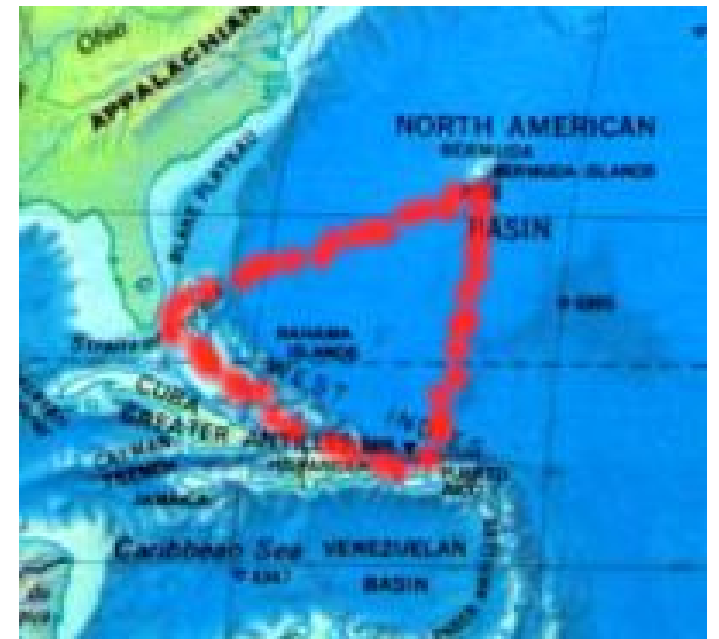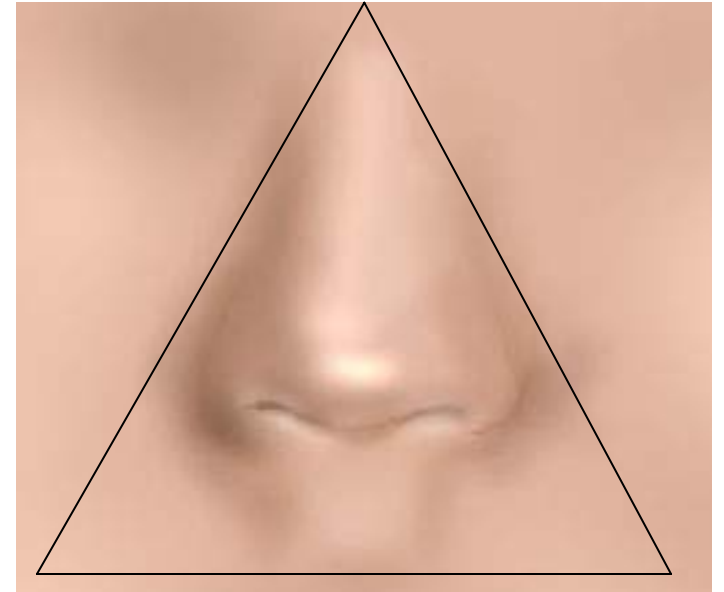
Greater Palatine A





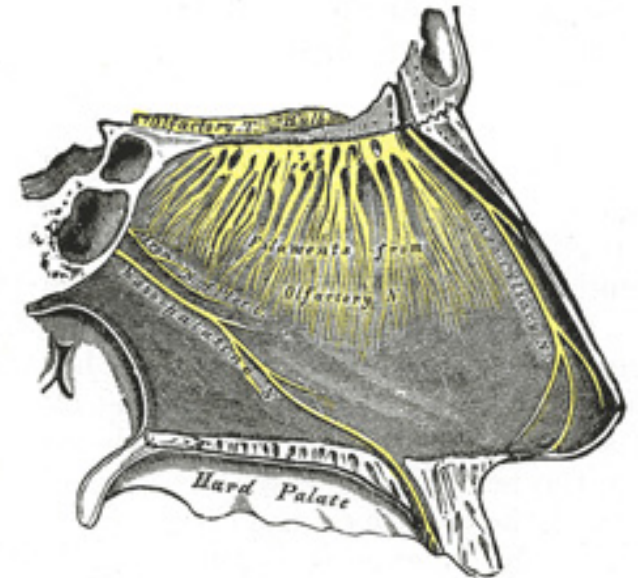
Venous Drainage

- Valve-less
- To Cavernous sinus
- Bermuda triangle



Innervation

- Autonomic vidian
 - vascular tone,
 - turbinate congestion
 - Nasal secretions
- Smell olfactory
- Sensory components. Trigeminal
 - Pain
 - Temperature
 - Touch.

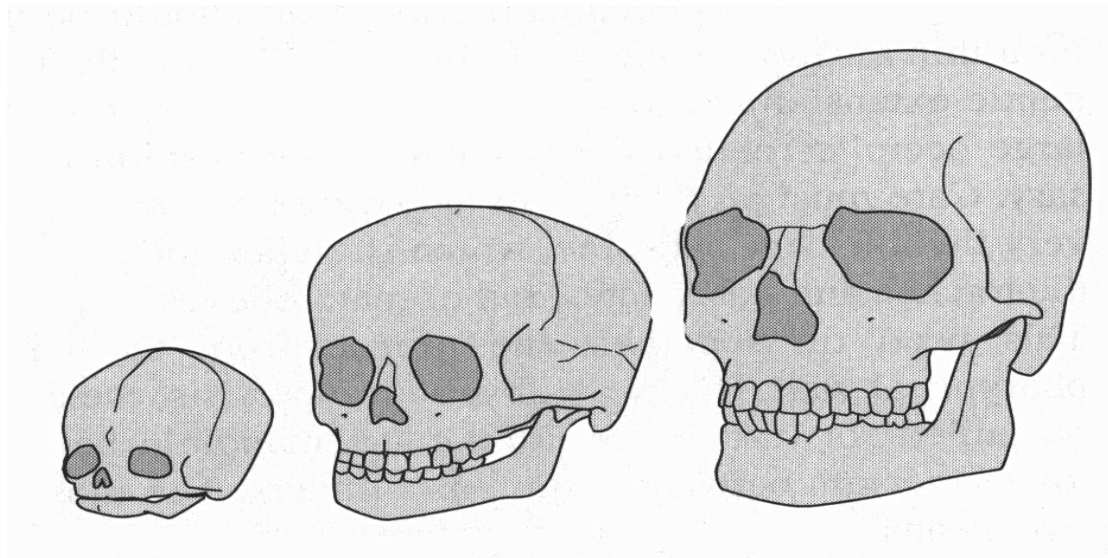


Anatomy

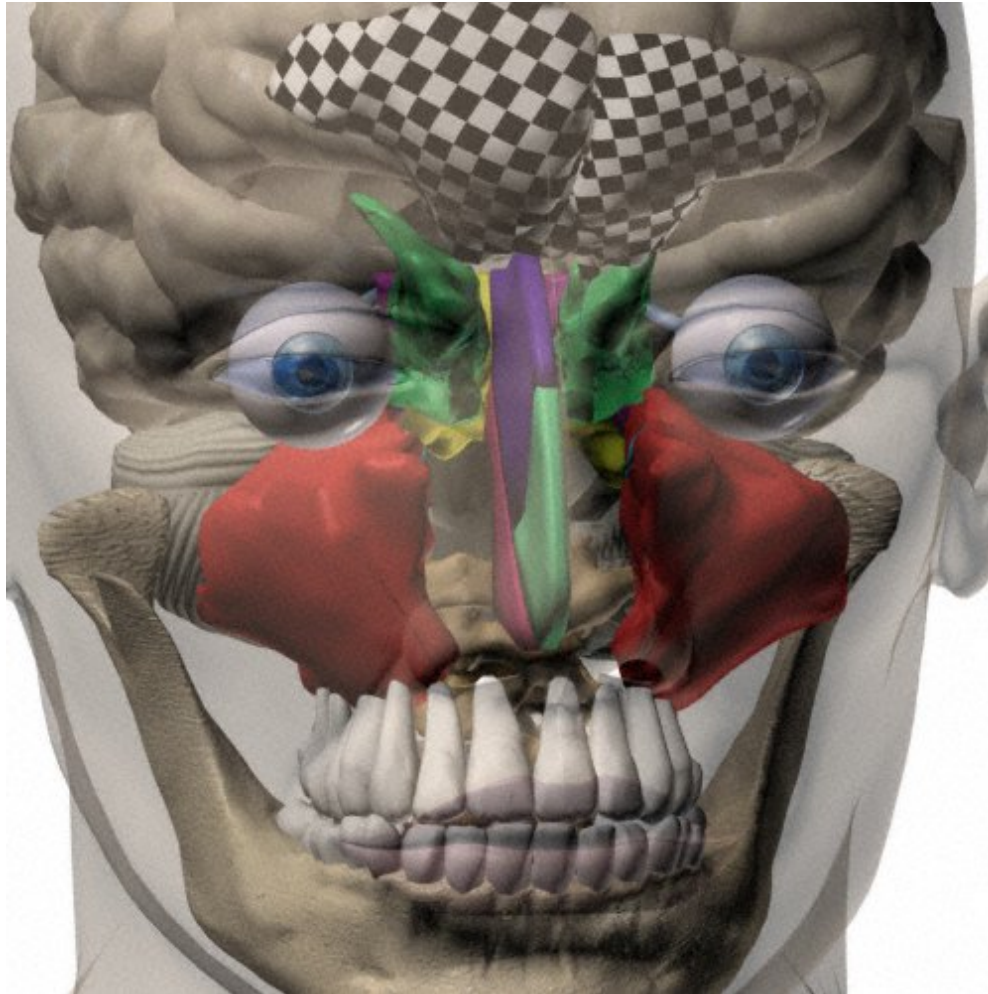- 4 paired paranasal sinuses

Maxillary, ethmoid, frontal and sphenoid

- “Anterior” and “posterior” sinuses

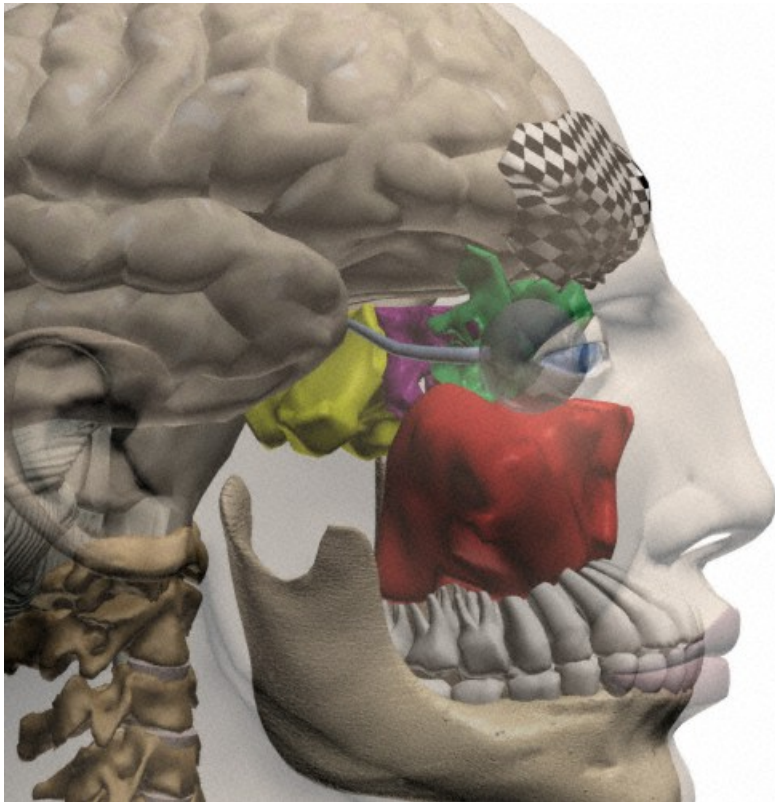


Sinus Anatomy: Front View

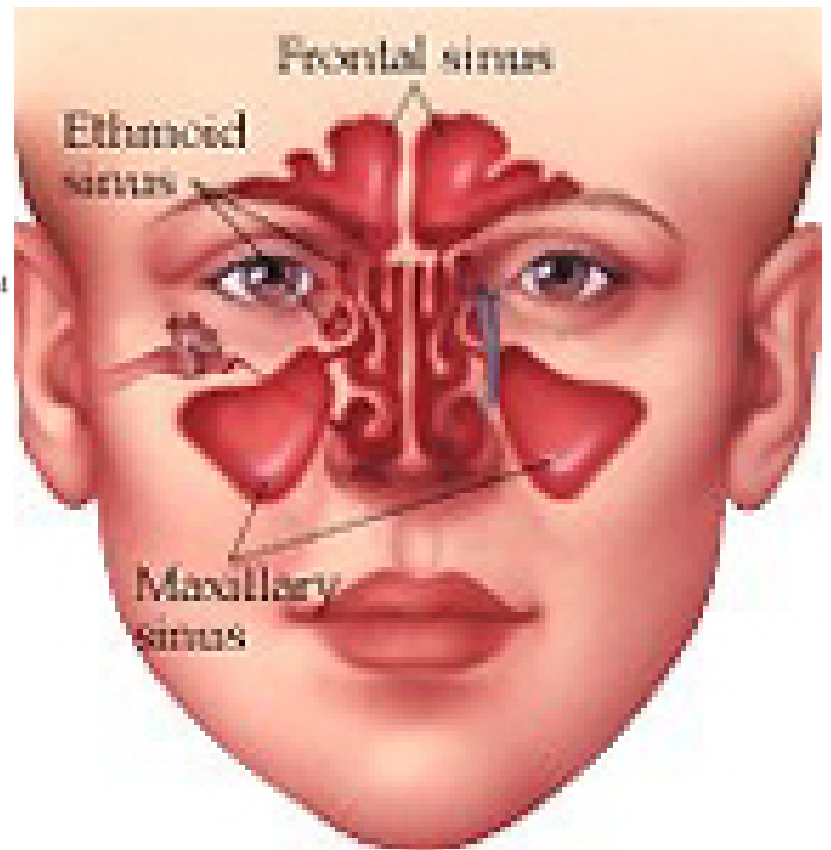
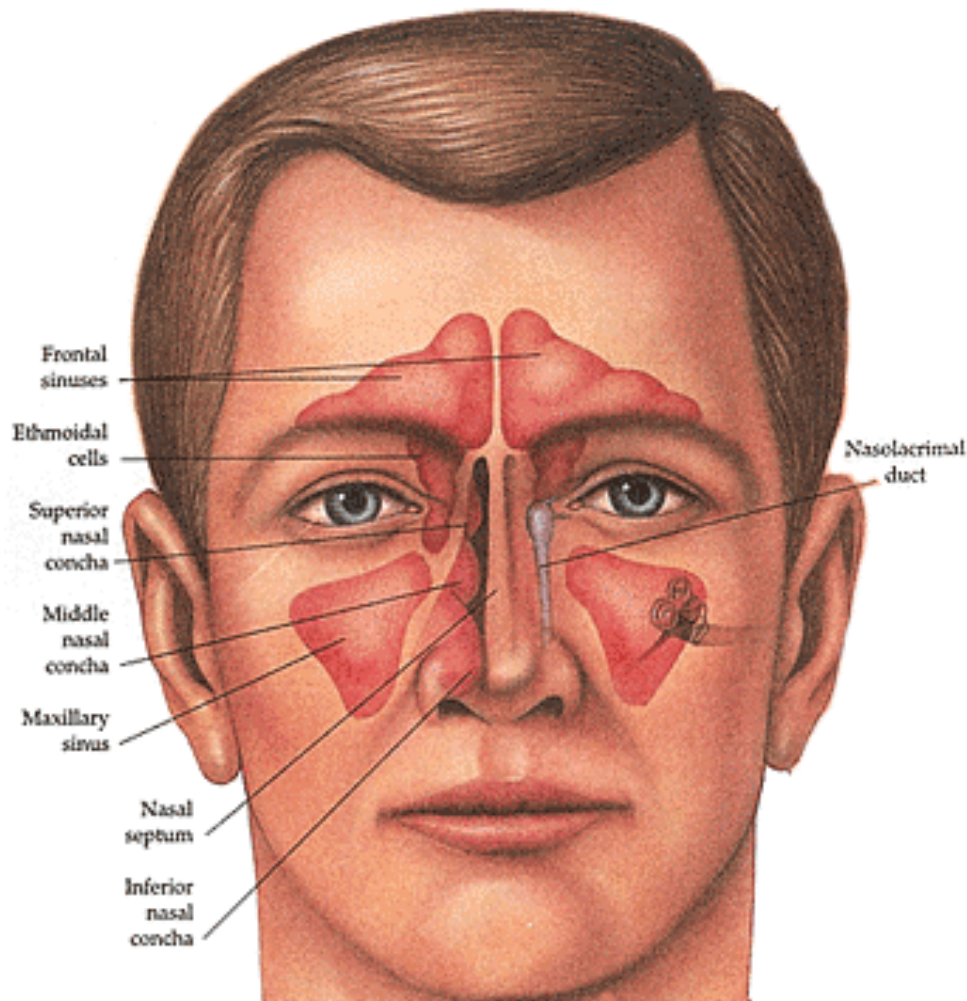


- frontal sinus=black check
- maxillary sinus=red,
- anterior ethmoid sinuses=green
- posterior ethmoid sinuses= purple,
- sphenoid sinus=yellow

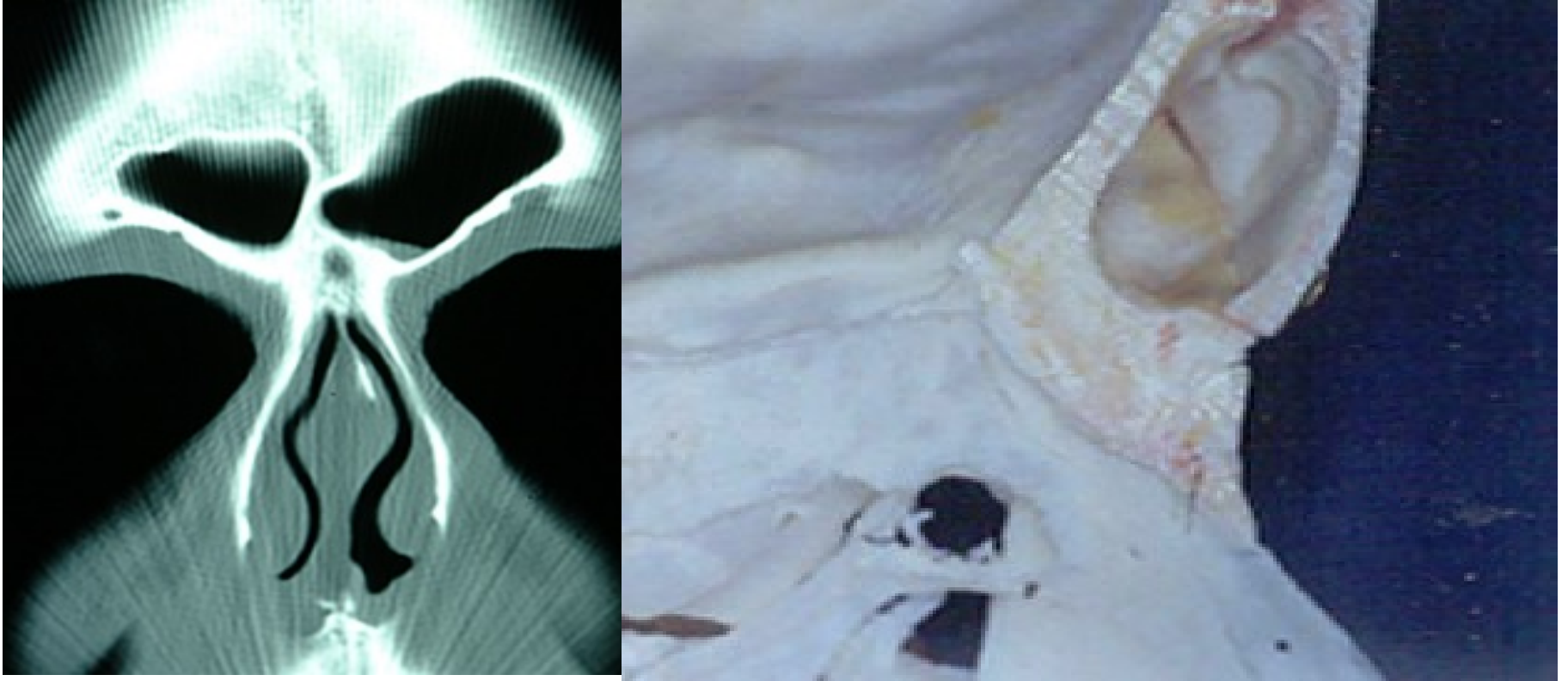Sinus Anatomy: Side View



- frontal sinus=black check
- maxillary sinus=red,
- anterior ethmoid sinuses=green
- posterior ethmoid sinuses= purple,
- sphenoid sinus=yellow

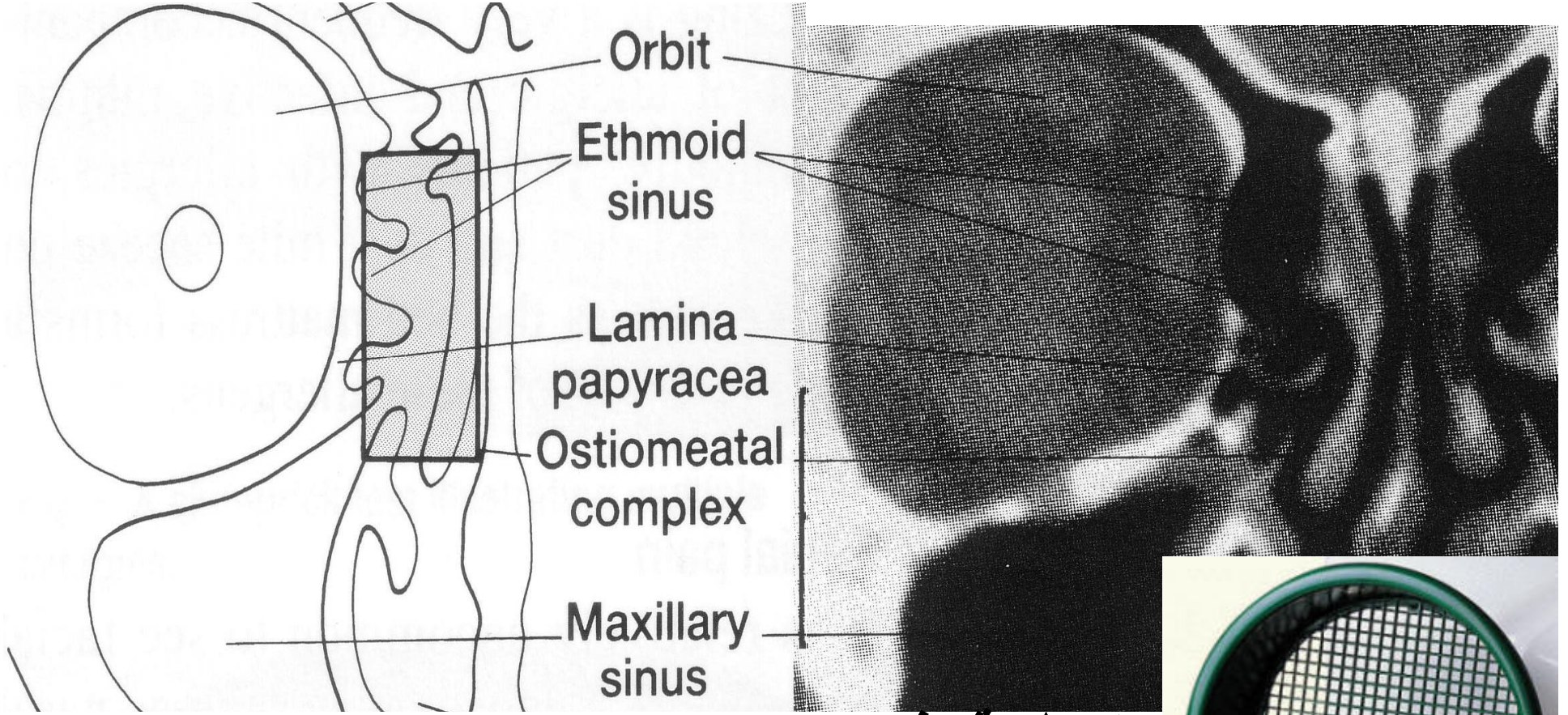


الجبهي = Frontal



(يَوْمَ يُحْمَى عَلَيْهَا فِي نَارِ جَهَنَّمَ فَتُكْوَى بِهَا **جِبَاهُهُمْ**) التوبة

Ethmoid sinuses = الجيوب الغربالية

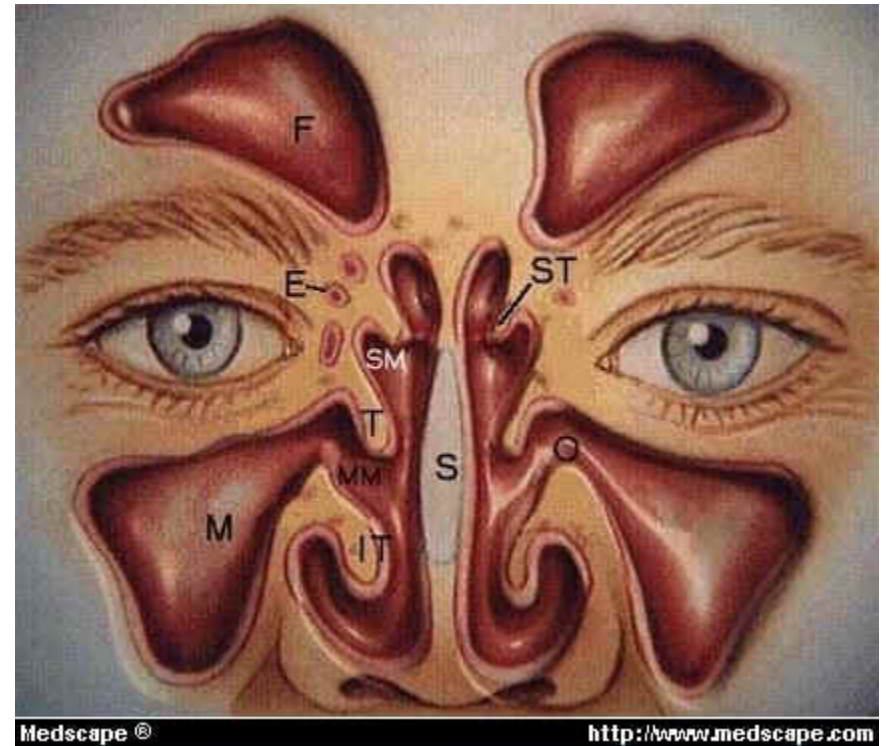


الخطيئة يذم زوجته

أغربالا إذا استودعت سرا
تنحي فاجلسي مني بعيدا
وكانونا على المتحدثينا
اراح الله منك العالمين

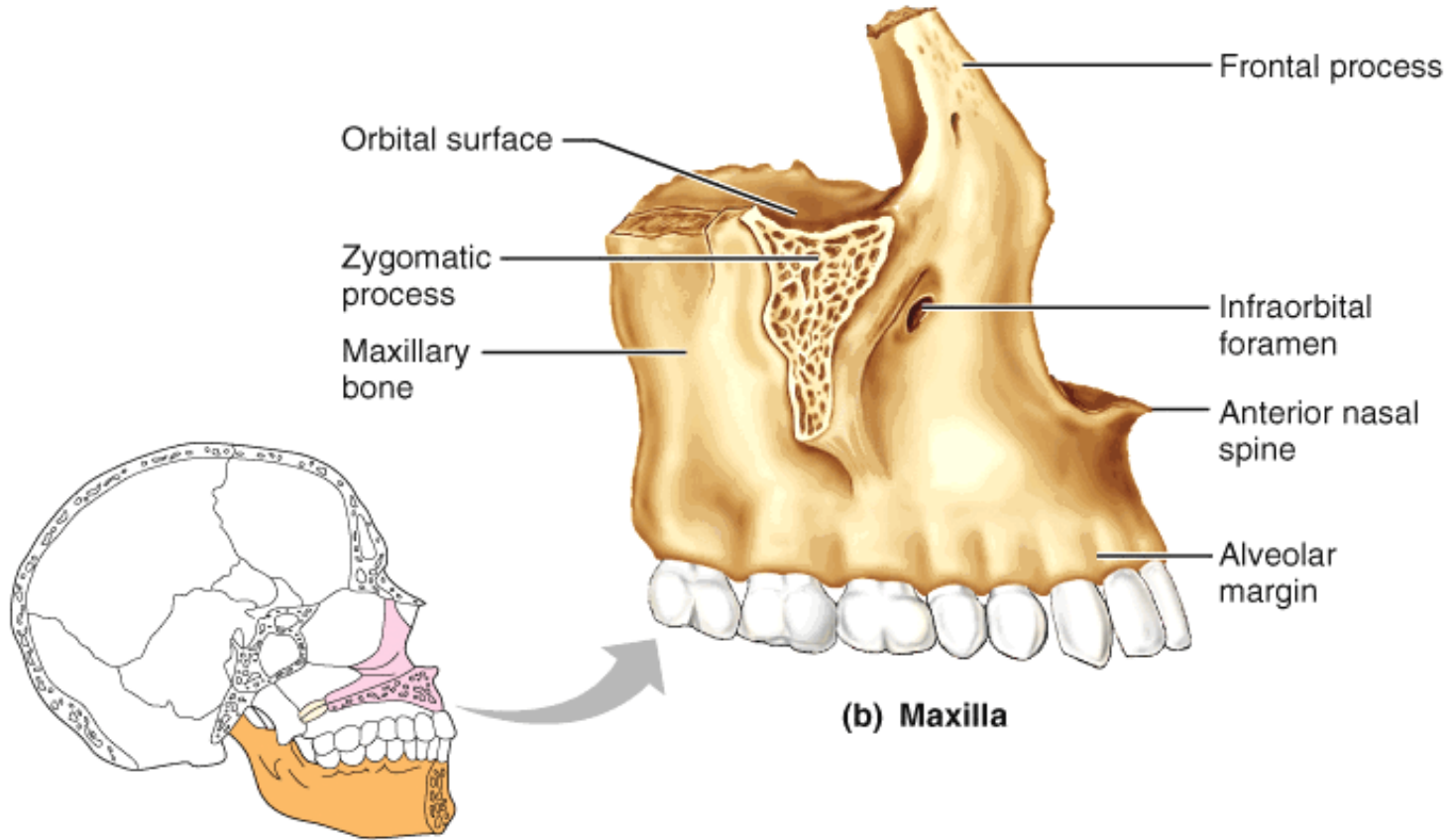
The Maxillary Sinuses

- The largest sinus
- The infraorbital nerve runs along roof
- Drainage !??



((وما اوتيتم من العلم إلا قليلا))

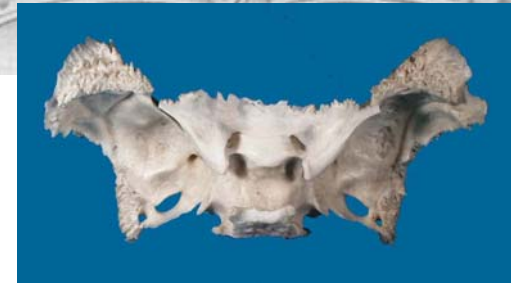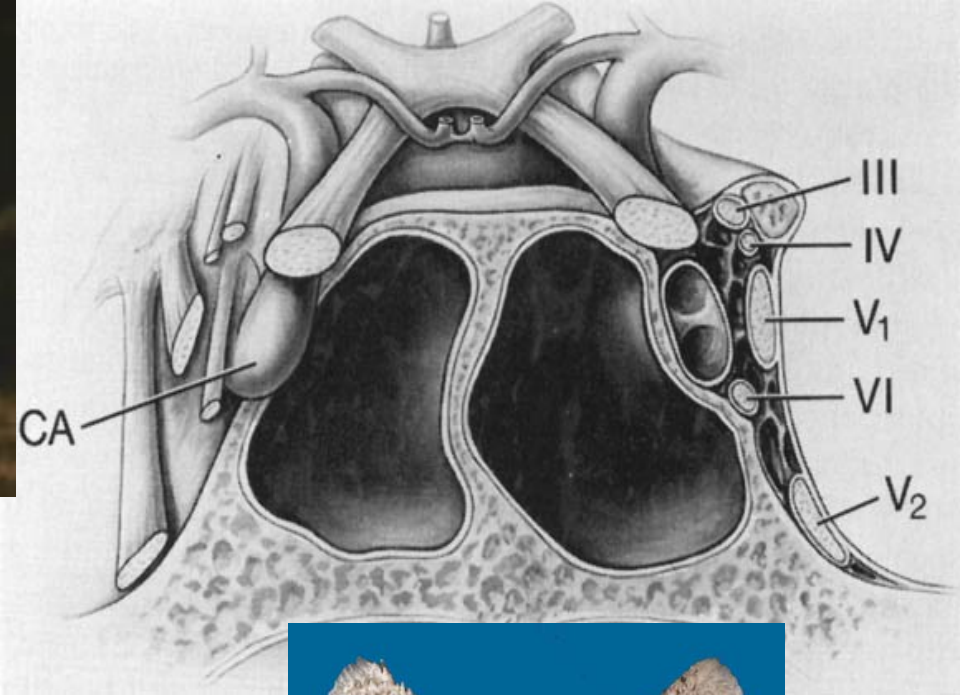
Maxillary antrum = الجيب (الغار) الفكّي



Copyright © 2001 Benjamin Cummings, an imprint of Addison Wesley Longman, Inc.

(فكّ رَقَبَتَهُ) ... "مَقْتَلُ الرَّجُلِ بَيْنَ فَكِّهِ" :وأريد لسانه

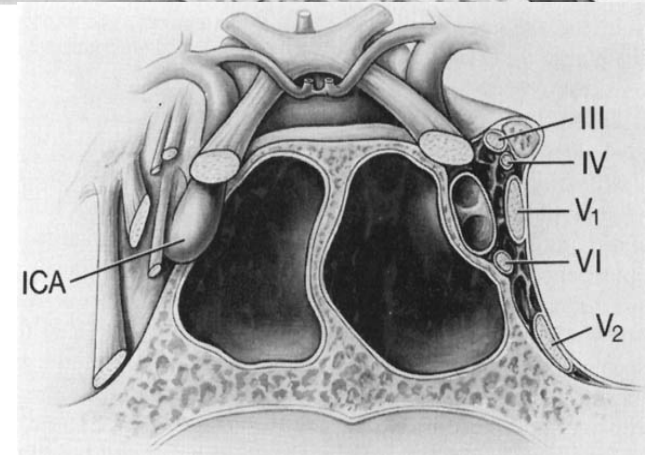
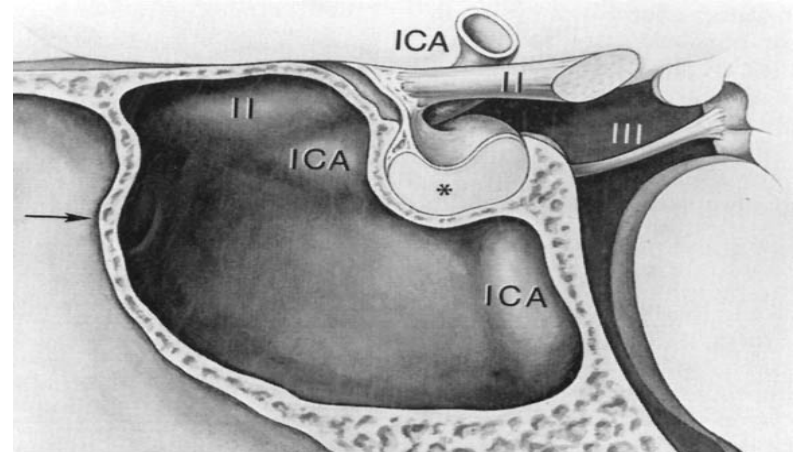
Sphenoid = وتدّي



(أَلَمْ نَجْعَلِ الْأَرْضَ مِهَادًا وَالْجِبَالَ أَوْتَادًا)

Sphenoid Sinuses

- Superiorly
 - Optic nerve
- Posteriorly
 - Pons
- Laterally
 - Cavernous sinus
 - CNIII, IV and VI
 - Carotid artery (Dehiscent in 50%)



Osteomeatal Complex

- Anterior ethmoids
- Containing the ostia of
 - Maxillary
 - Frontal,
 - Anterior ethmoid sinuses
- Lateral to the middle turbinate

Nose

- *Embryology*
- *Anatomy*
- *Physiology*
- *Investigation*
- *Nasal septum, vestibule & choanal atresia*

Nose Physiology

- 20,000 L of air we breathe in each day
- 50% of total airway resistance at all ages
 - Obligate nose breathers until >3 months
 - Problems when mouths closed or feeding
- Infant: nose blockage= respiratory distress

Physiology: Effect of Edema

Poiseuille's law



If radius is **halved**, resistance increases **16fold**

Nasal Physiology

(وفي أنفسكم أفلا تبصرون)

On inspiration

- Airstream funnels through the vestibule
 - Squeezes through the narrow valve
- velocity decelerates by r^4 in the nasal cavity
- Warming
 - Humidification
 - Removal of antigenic particles
 - Smell

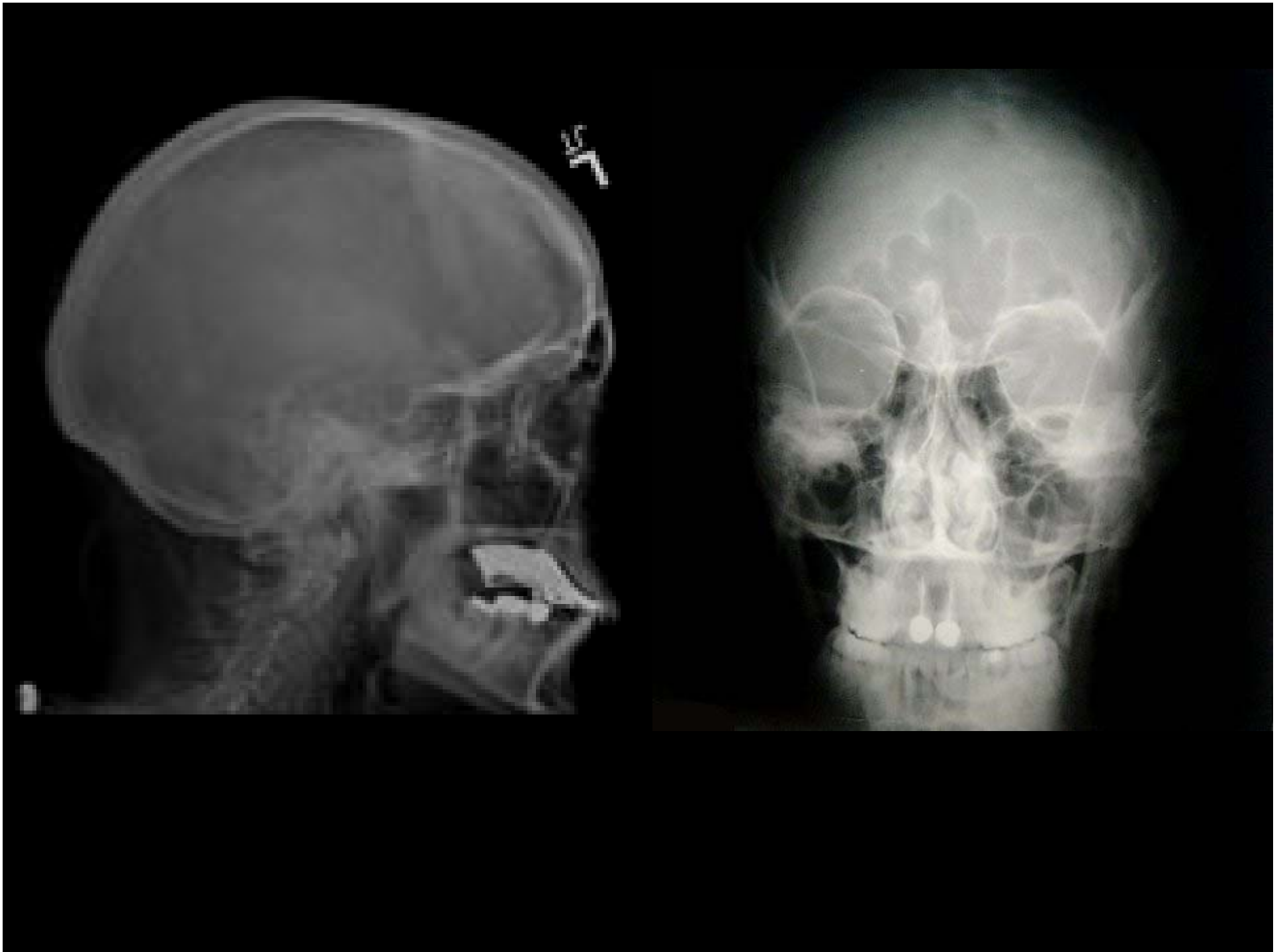Turbinates Physiology

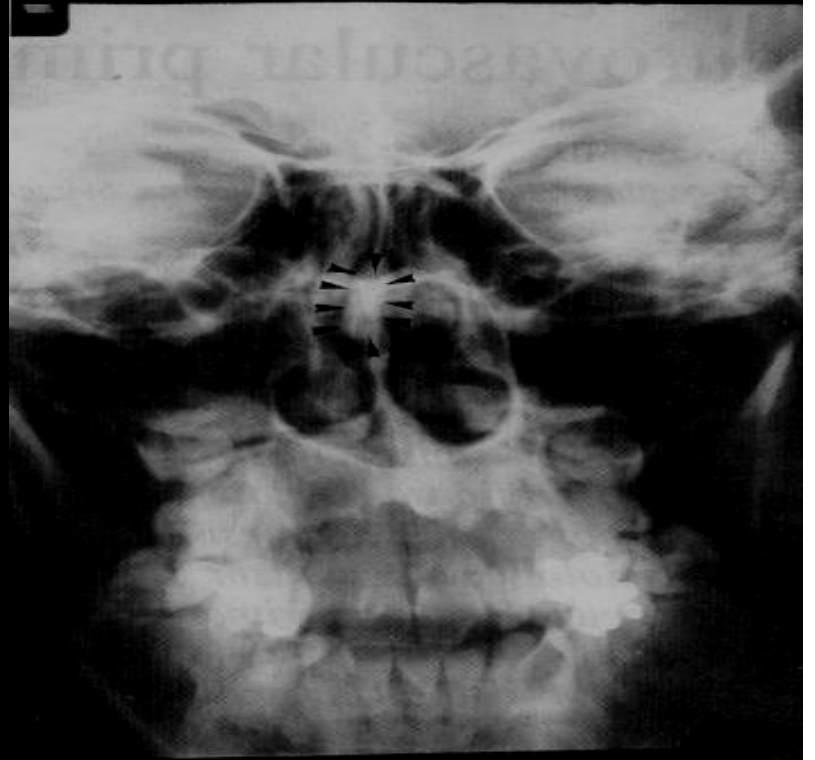
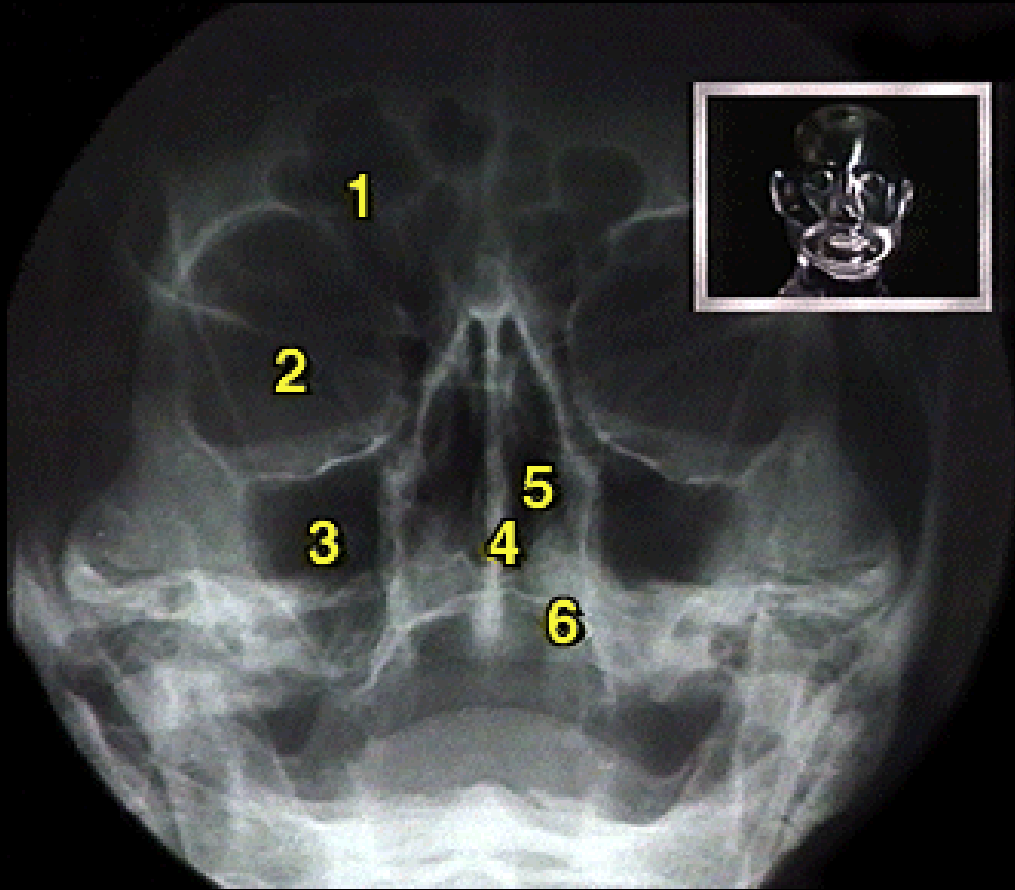
(وفي أنفسكم أفلا تبصرون)

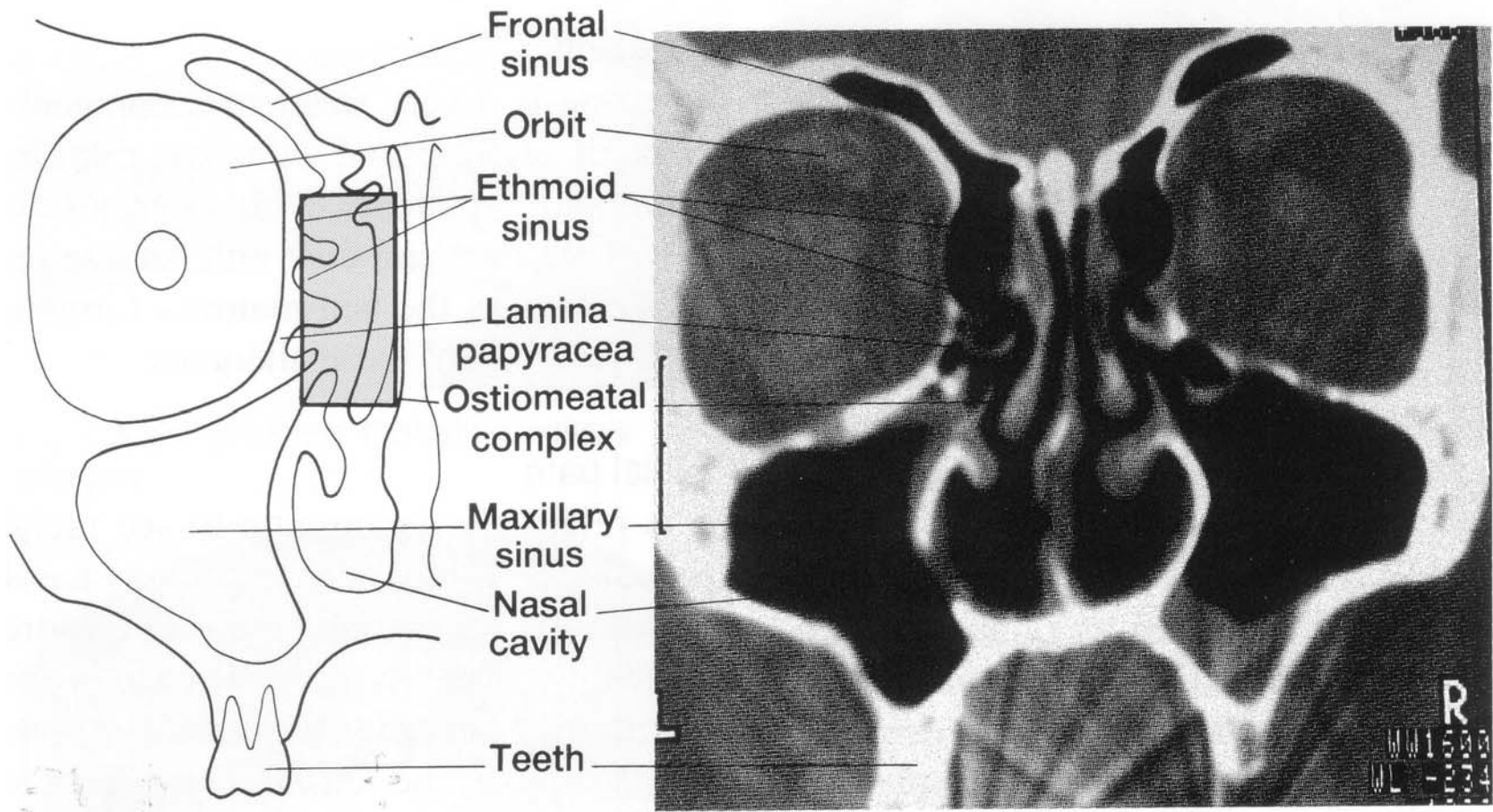
- Side filled up while the opposite Decongested.
- Controlled by autonomic nervous system
- 2.5 hours duration
- Turn from one side to the other while sleeping

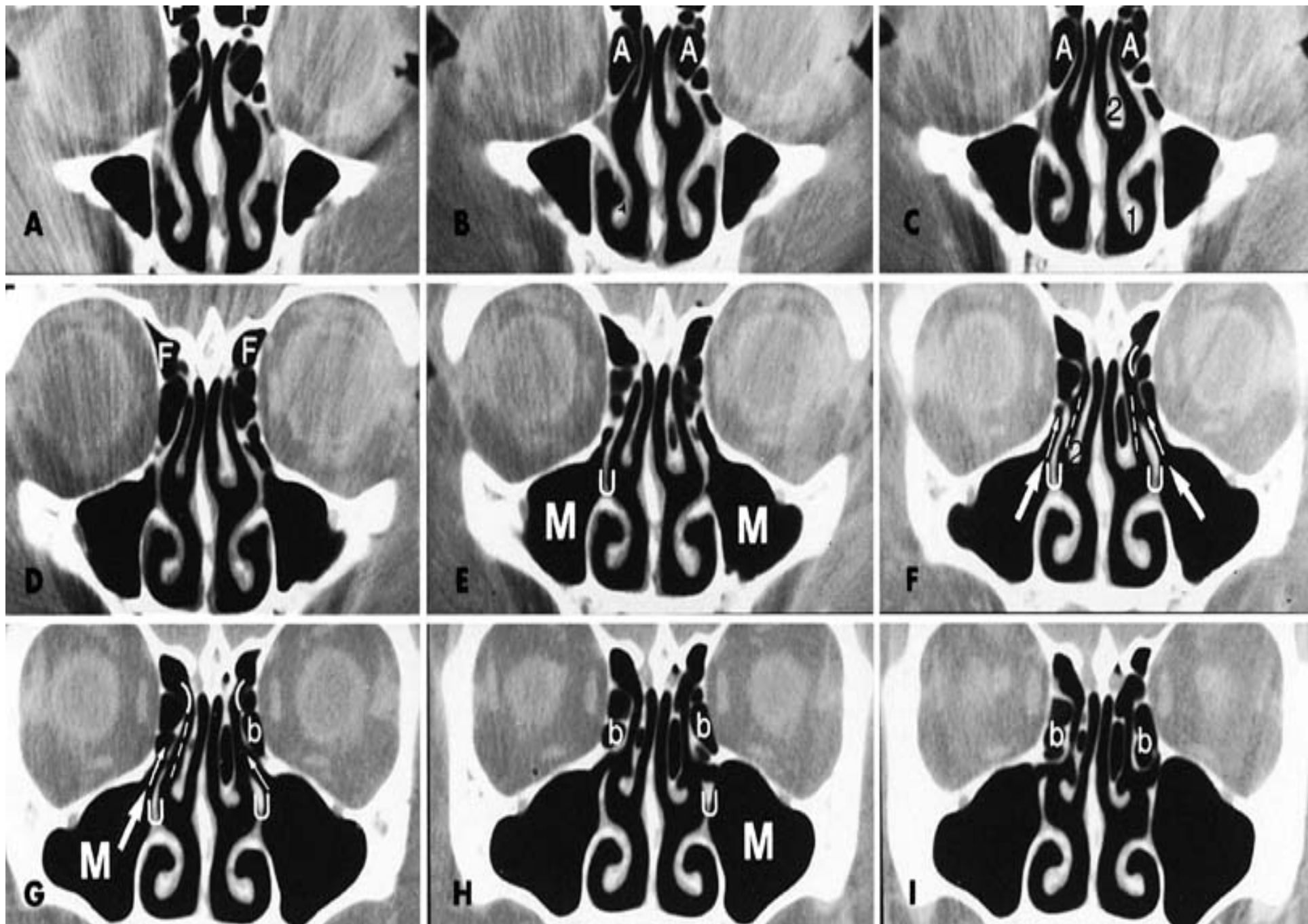
Nose

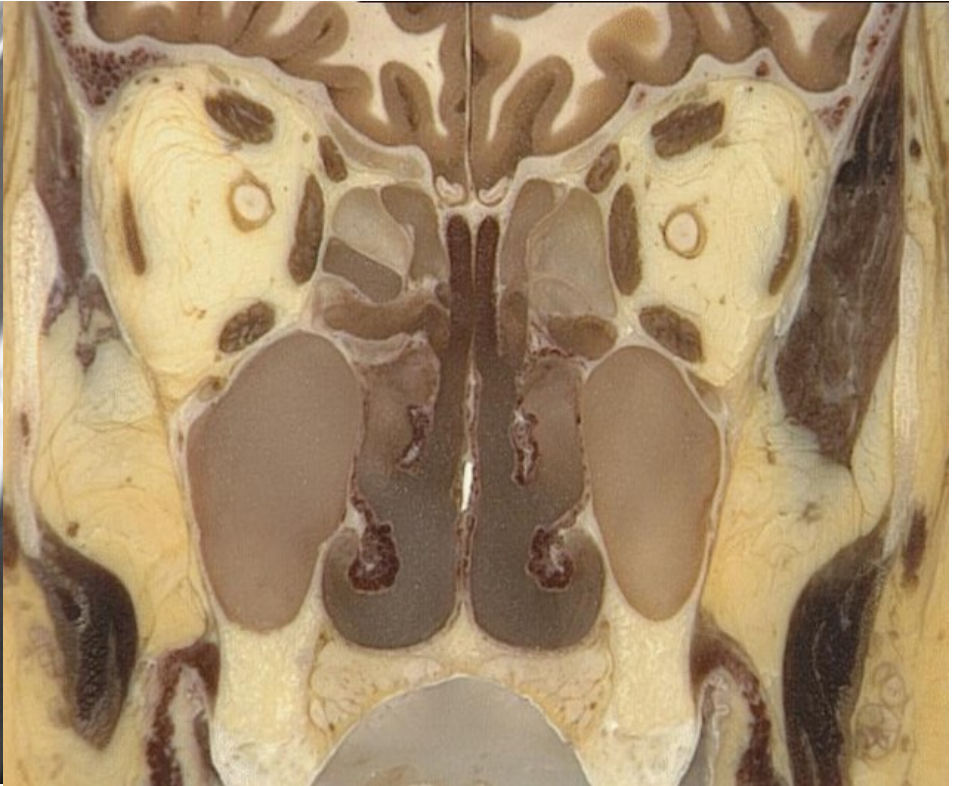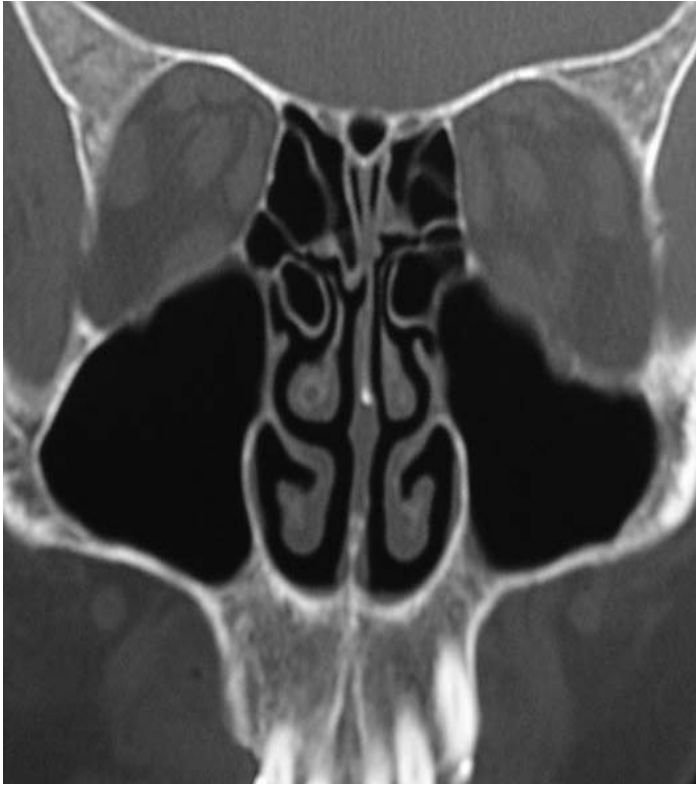- *Embryology*
- *Anatomy*
- *Physiology*
- *Investigation*
- *Nasal septum, vestibule & choanal atresia*

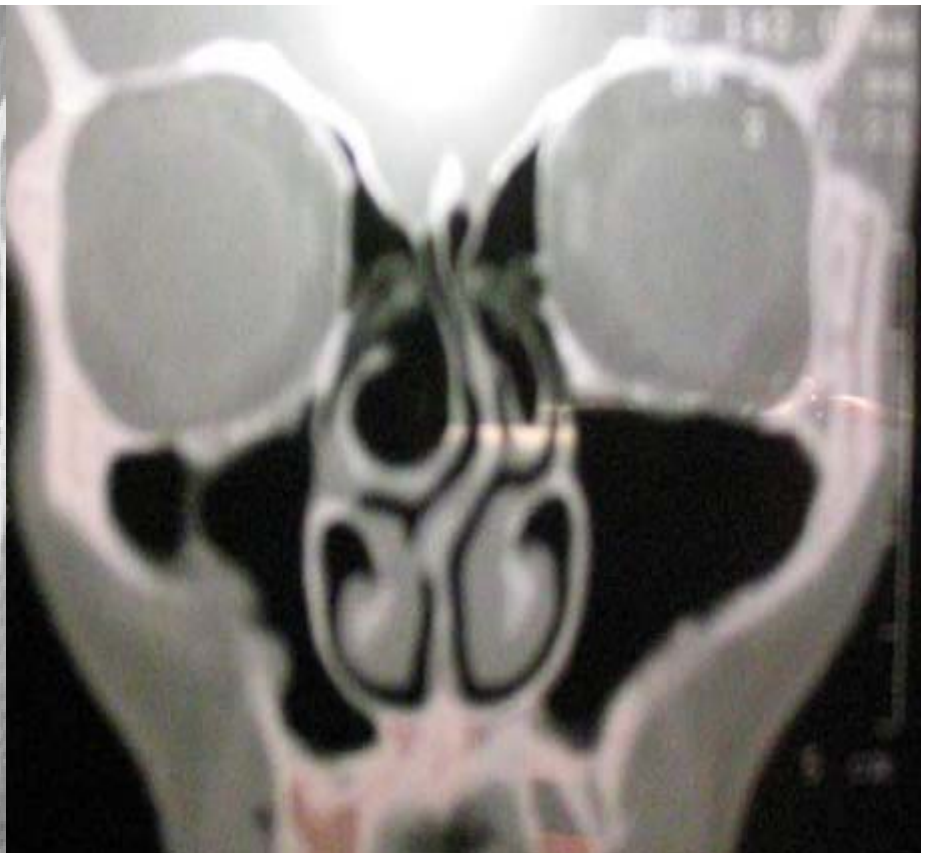
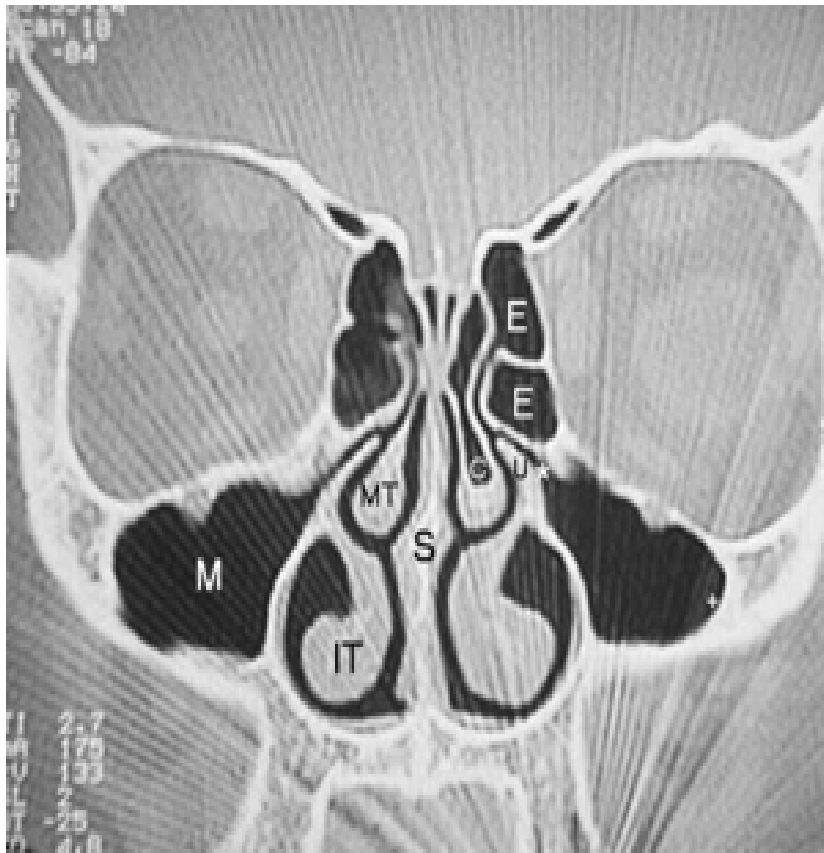
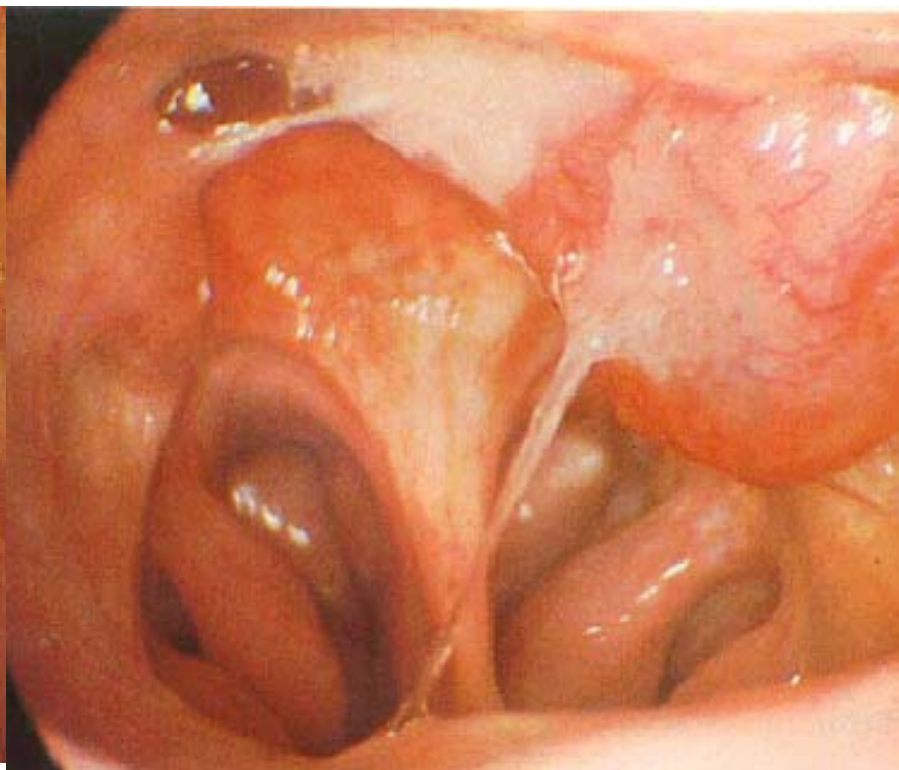
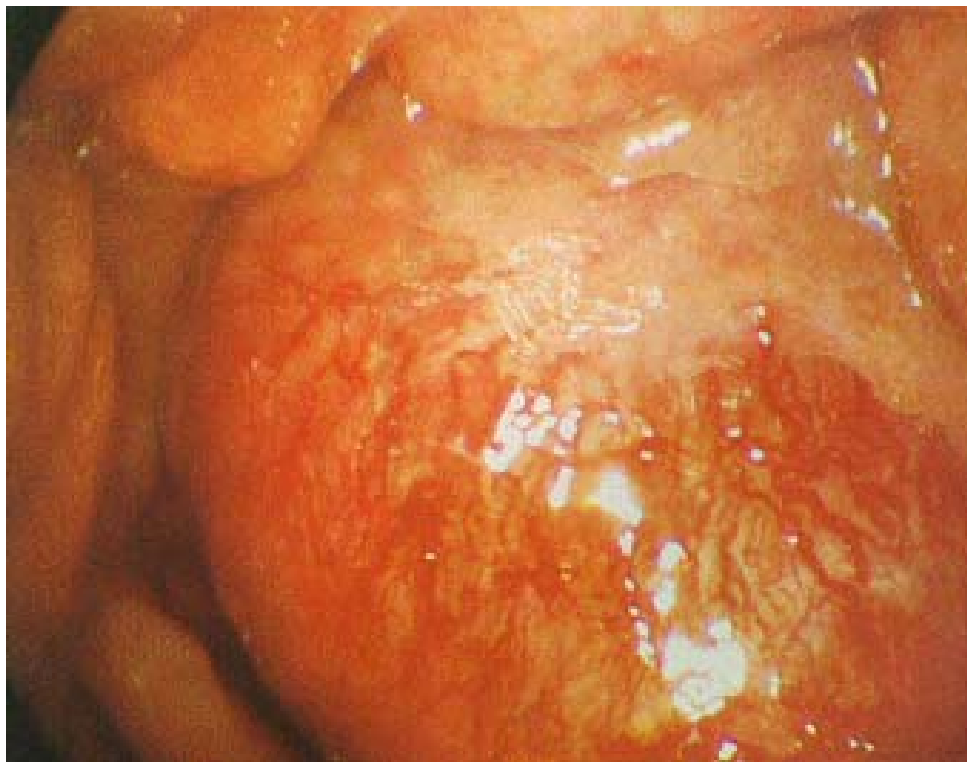


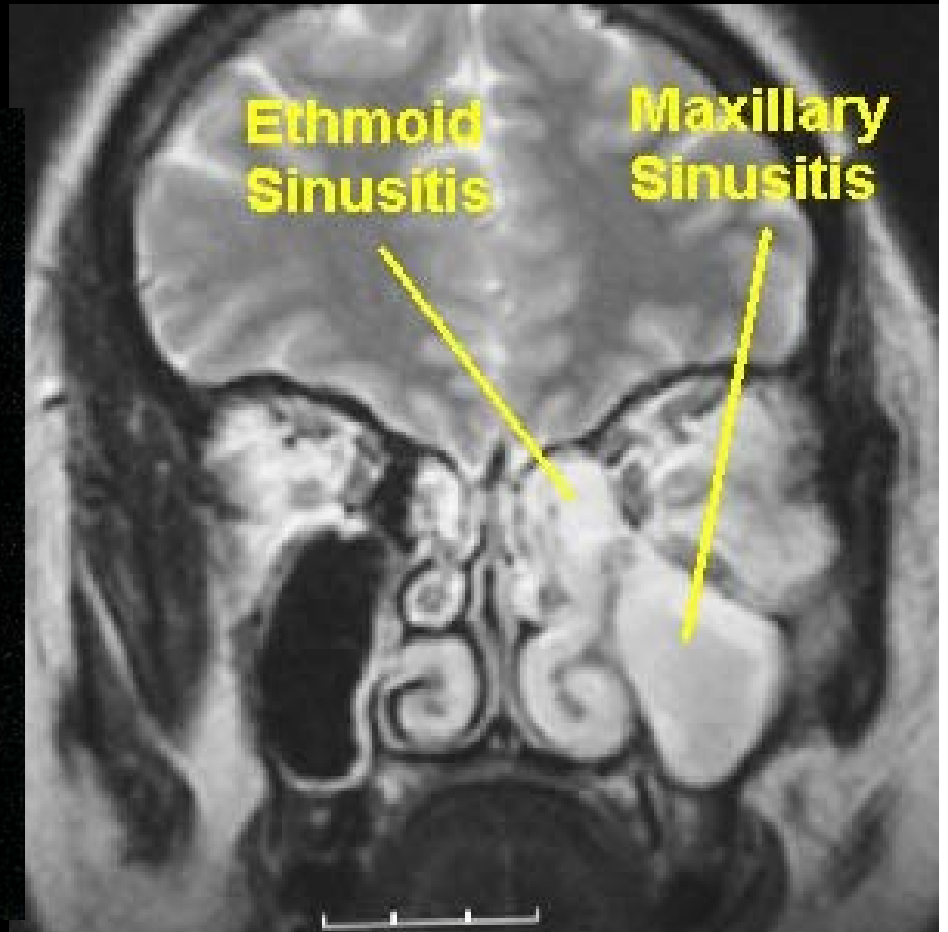
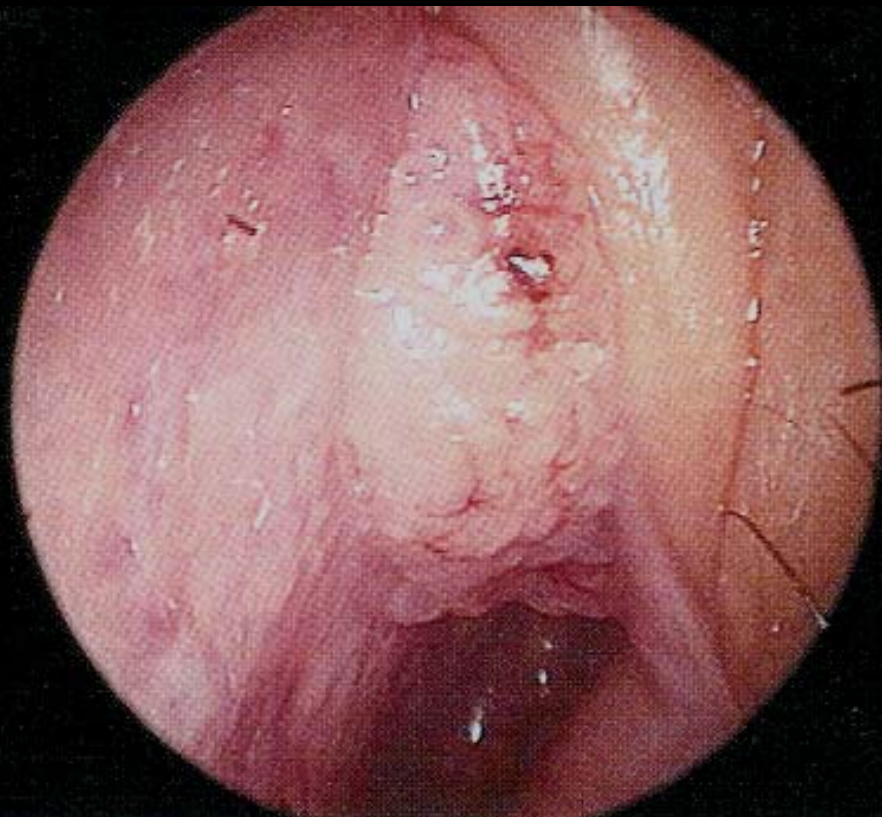




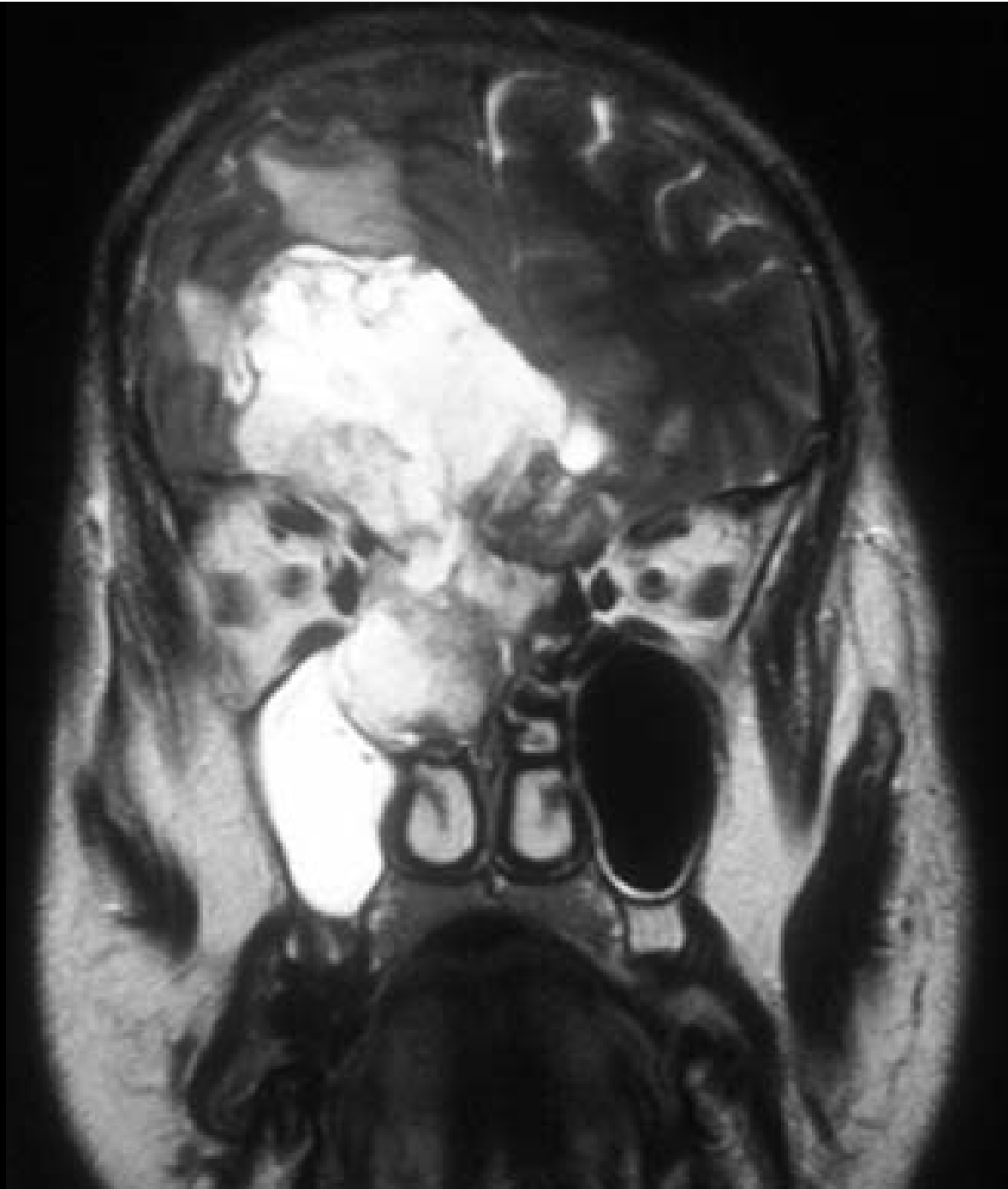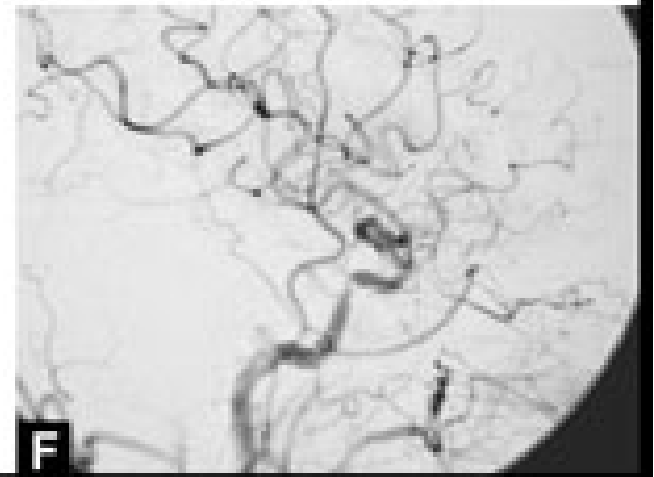
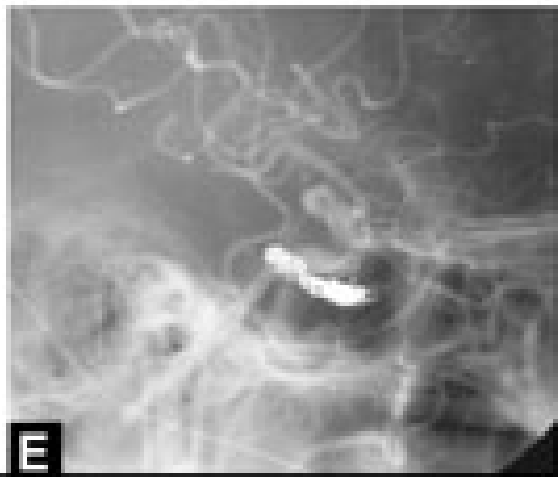
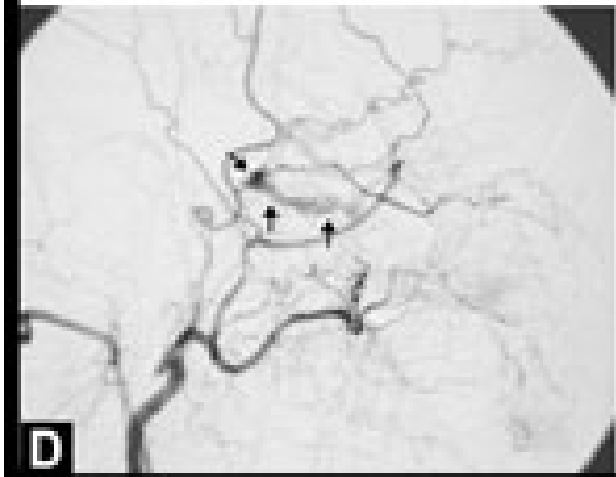
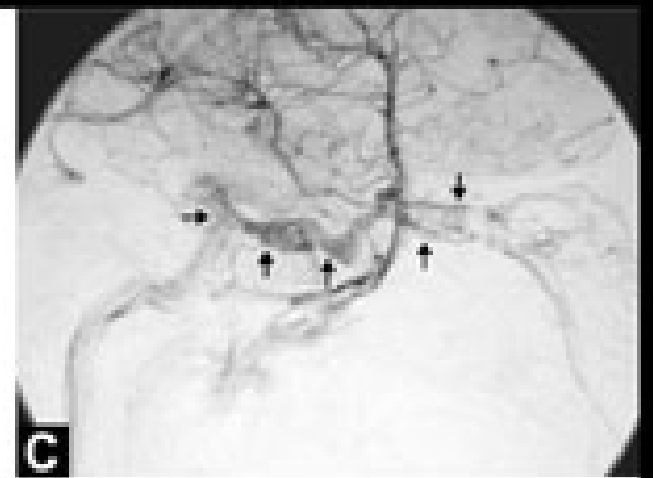
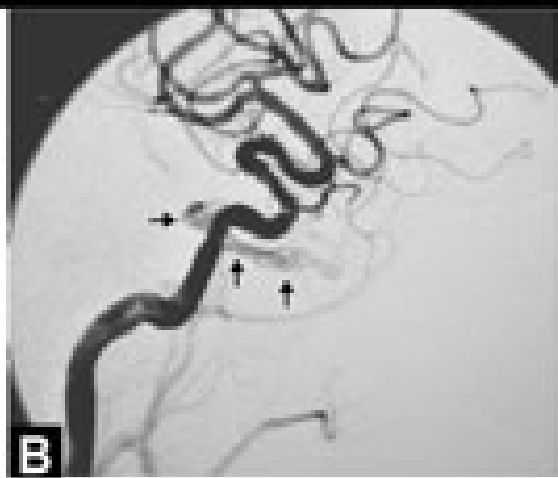



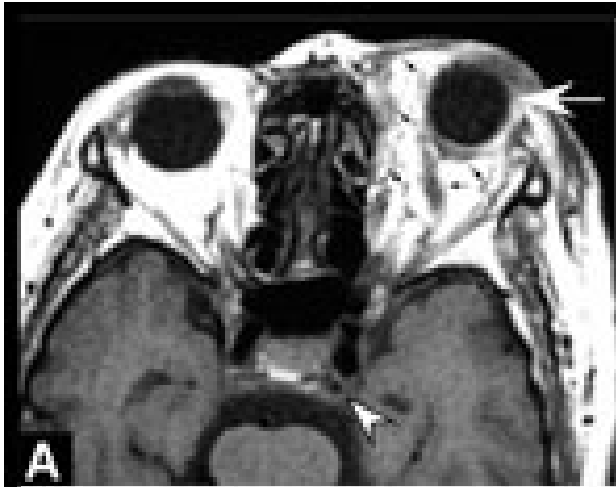








Nose

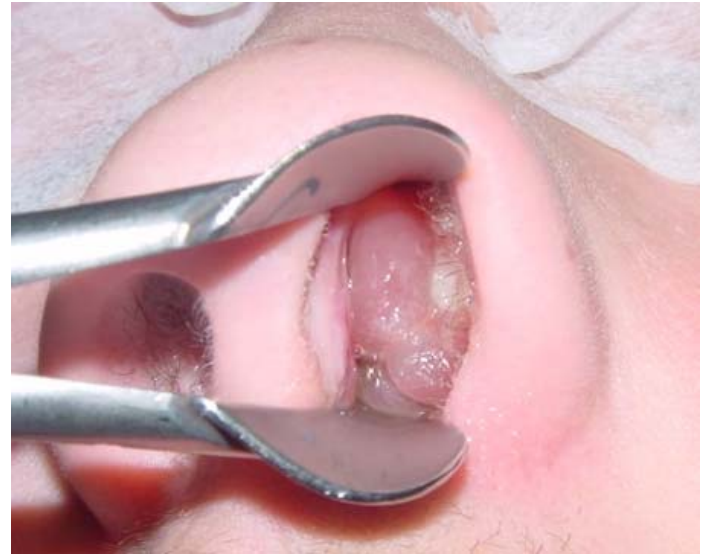- *Embryology*
- *Anatomy*
- *Physiology*
- *Investigation*
- *Nasal septum, vestibule & choanal atresia*

Nasal septum

- **Vestibule**
- **DNS**
- **Epistaxis**

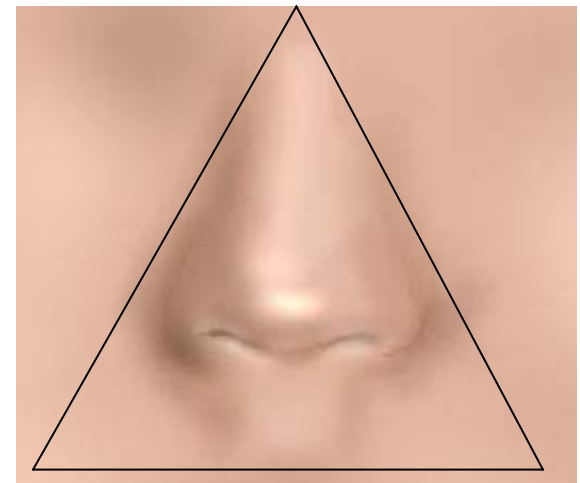
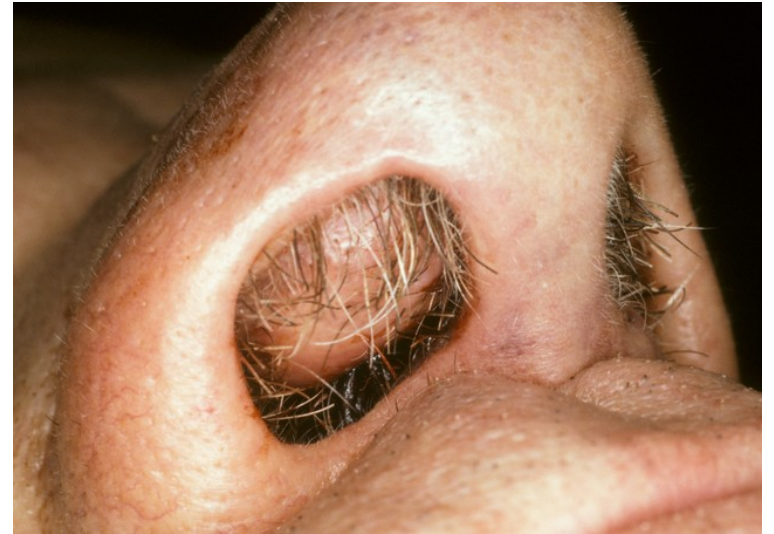Vestibule

- **Hair**
- **Skin**
- **Cartilage**

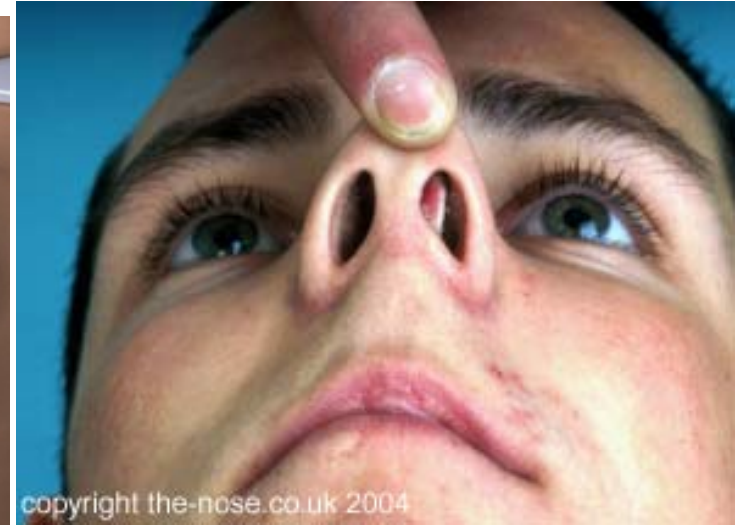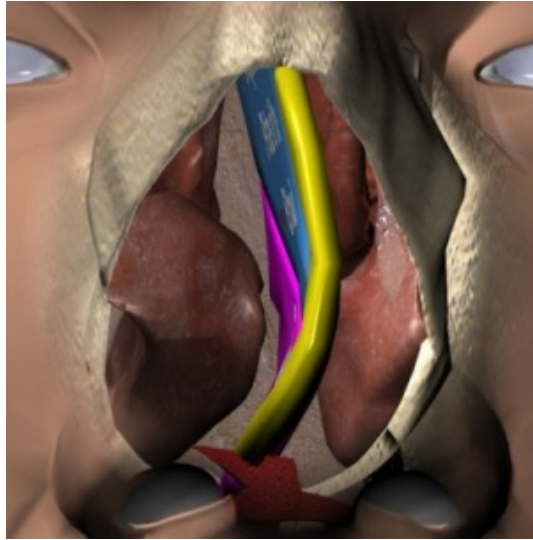
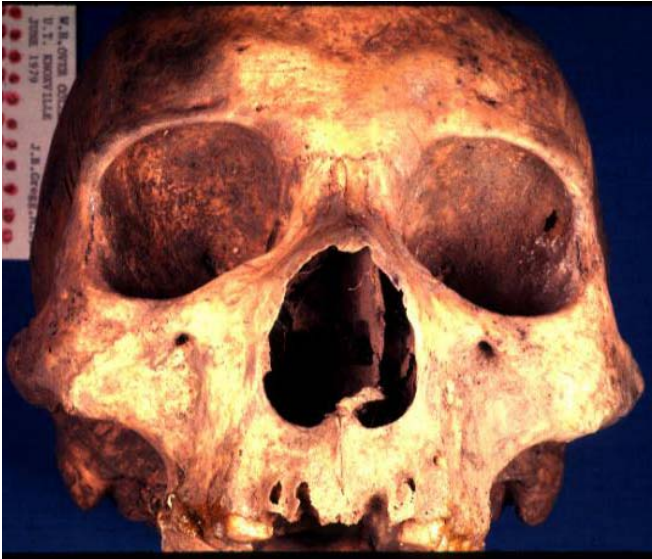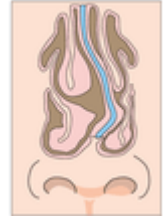


Furunculosis

- 55 y male
- Fever
- Headache
- L.O.C.
- Died




D.N.S

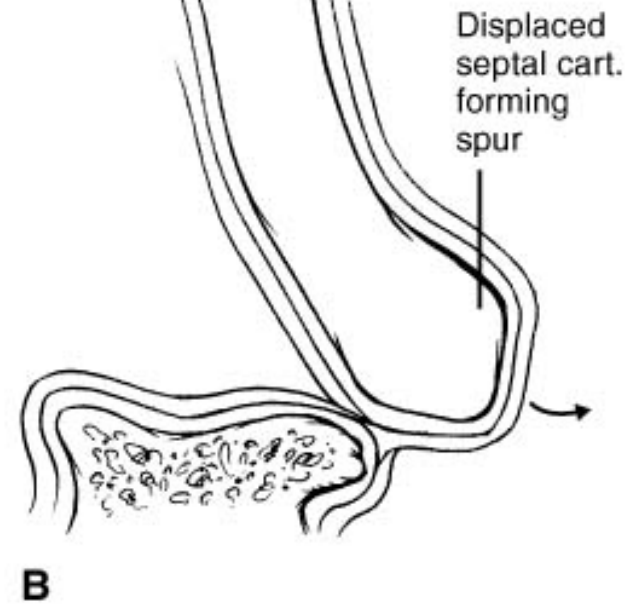
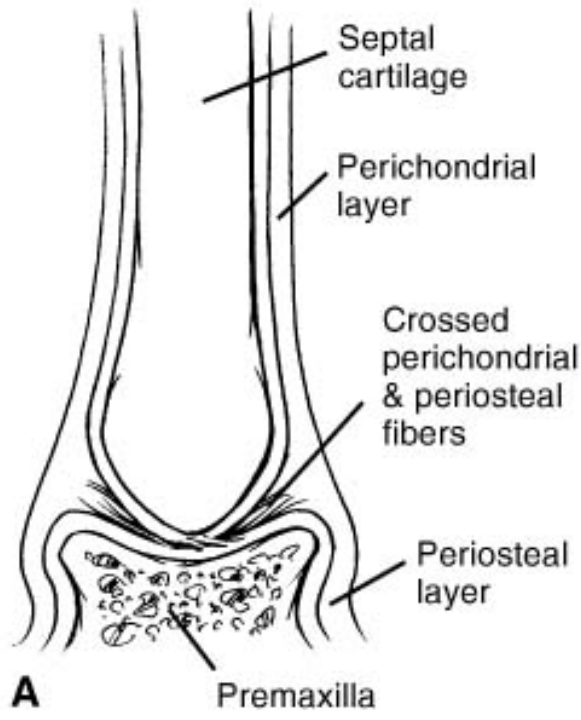


Physiology: Effect of Edema

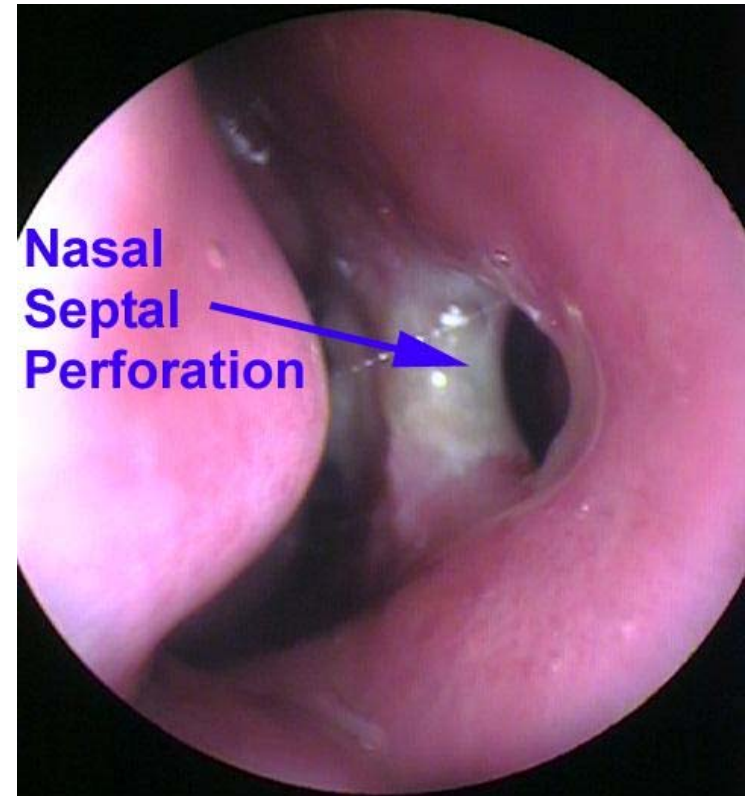
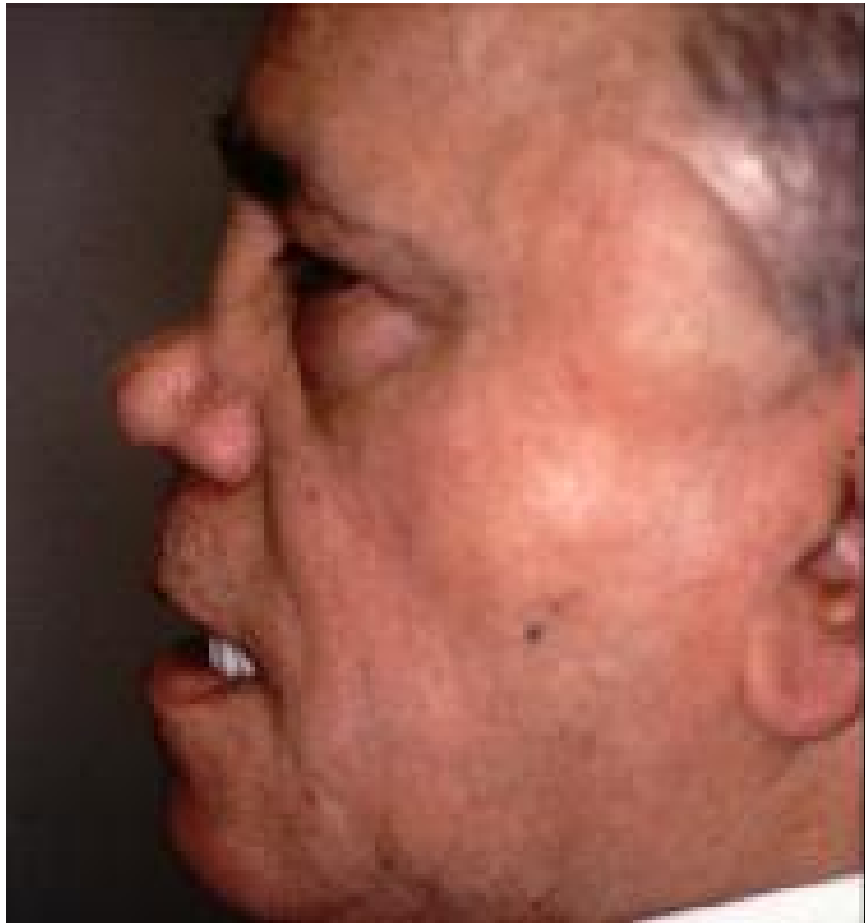Poiseuille's law



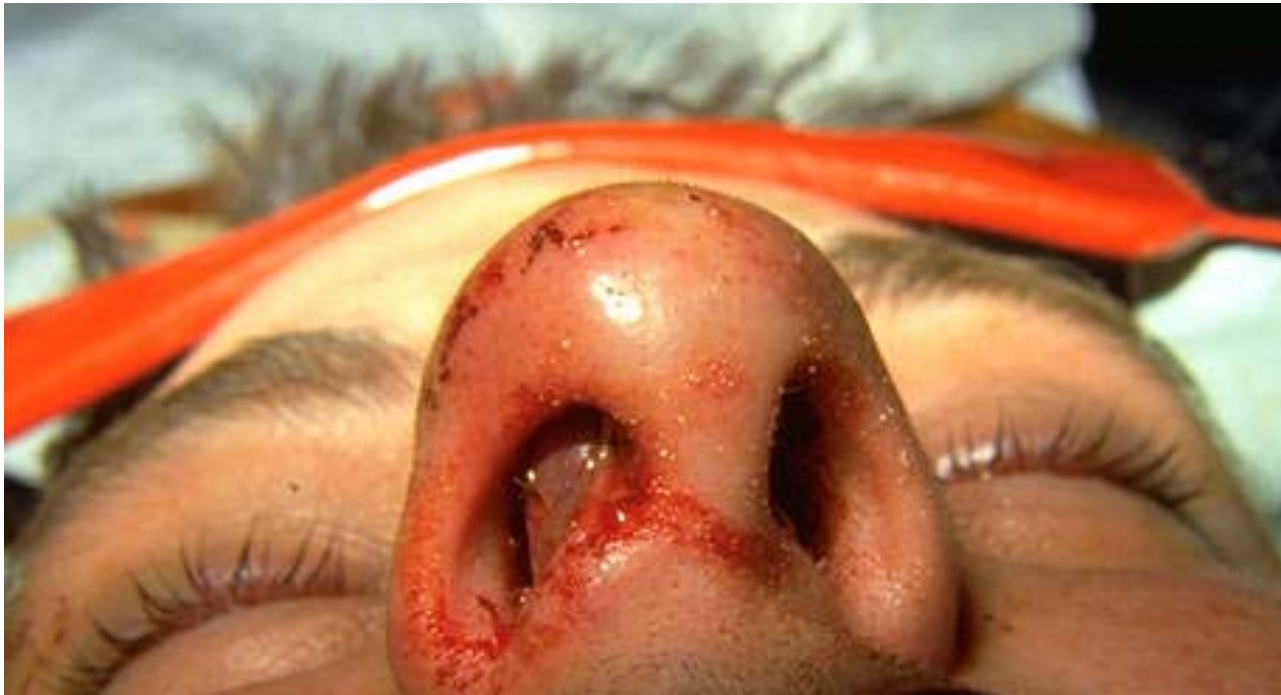If radius is **halved**, resistance increases **16fold**

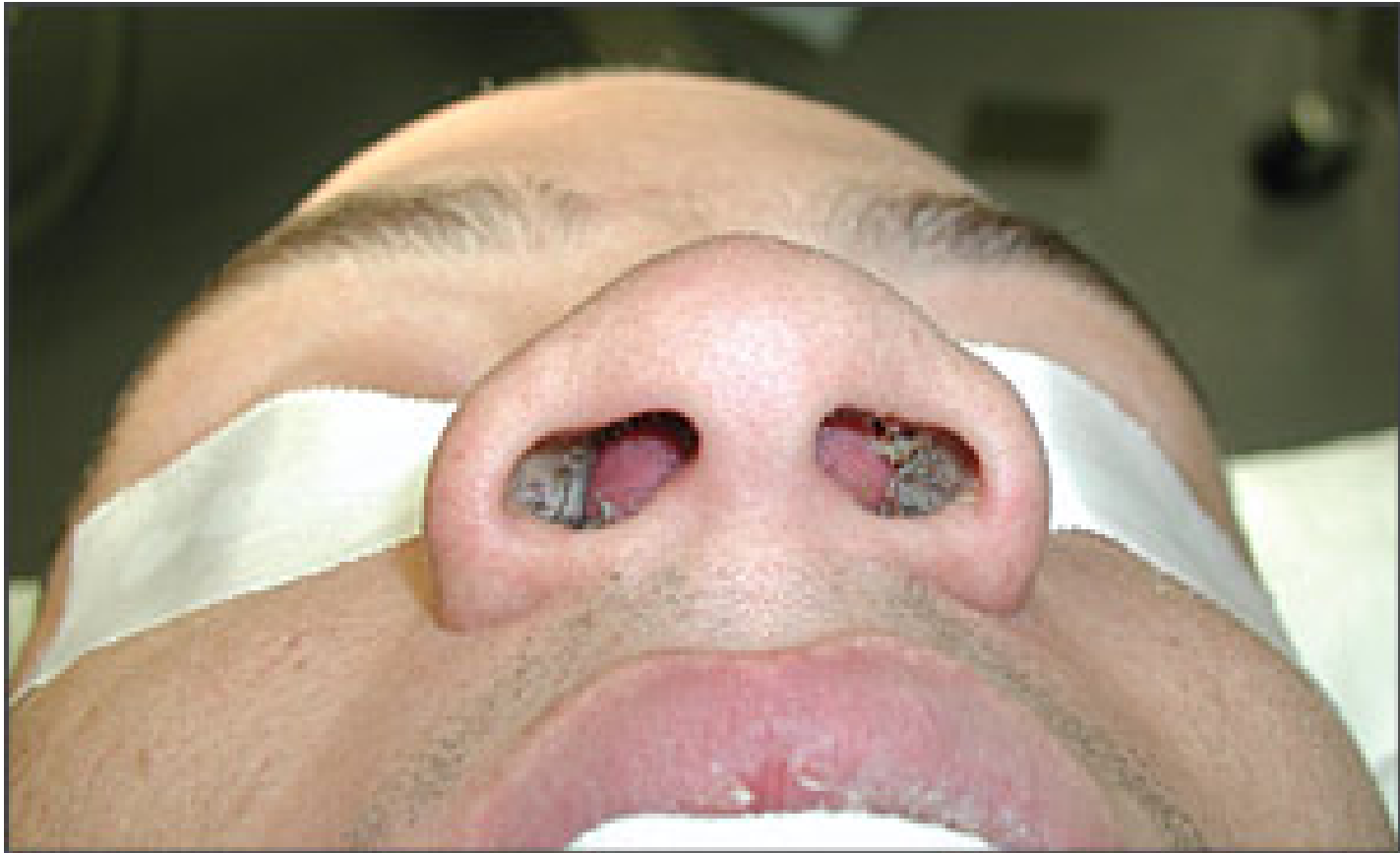

Cx Septoplasty



Septal hematoma





Epistaxis

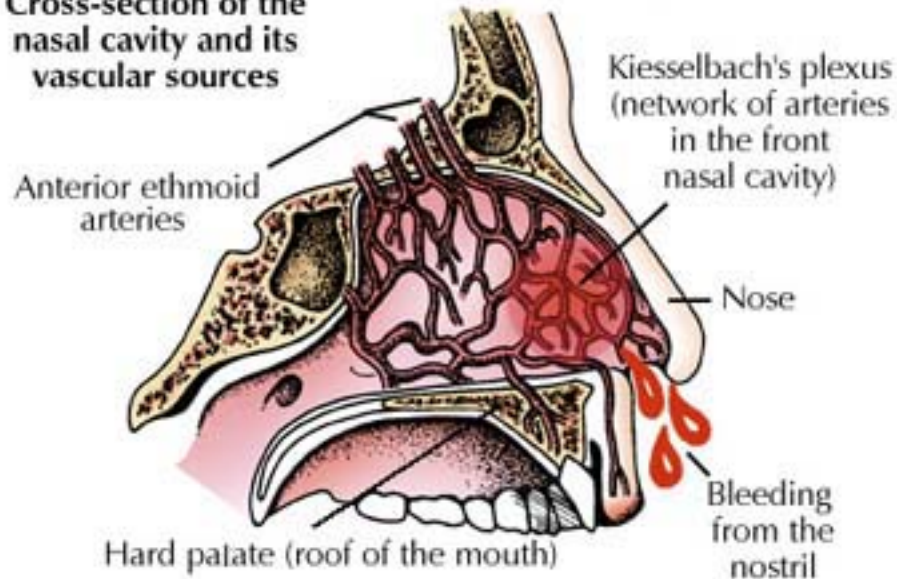
- 10% of the population experience an episode of epistaxis each year.
- 10% of those will see a physician.
- 1% of those seeking medical care will need a specialist.

Anatomy/Physiology of Epistaxis

- Anatomy
 - Nasal cavity
 - Vascular supply
- Physiology
 - Vascular nature
 - Mucosa

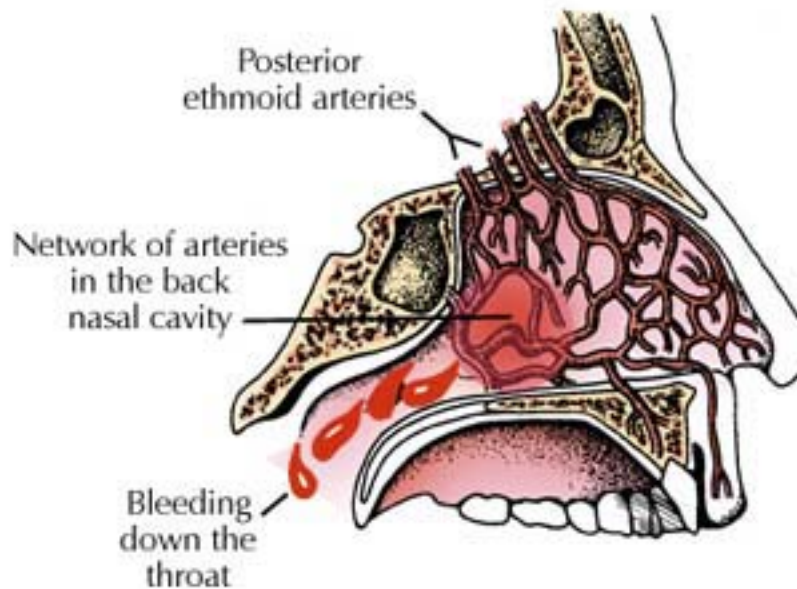


Cross-section of the nasal cavity and its vascular sources



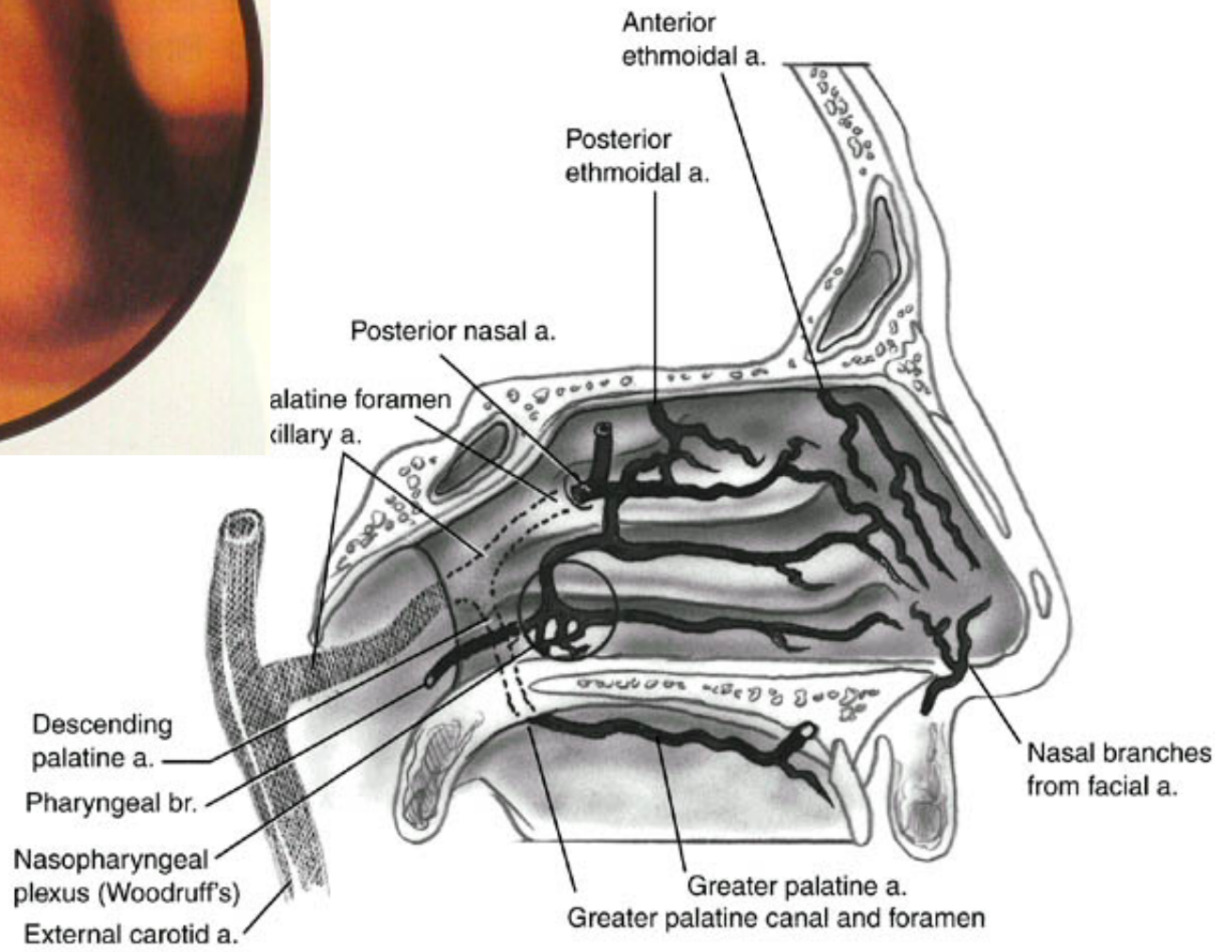
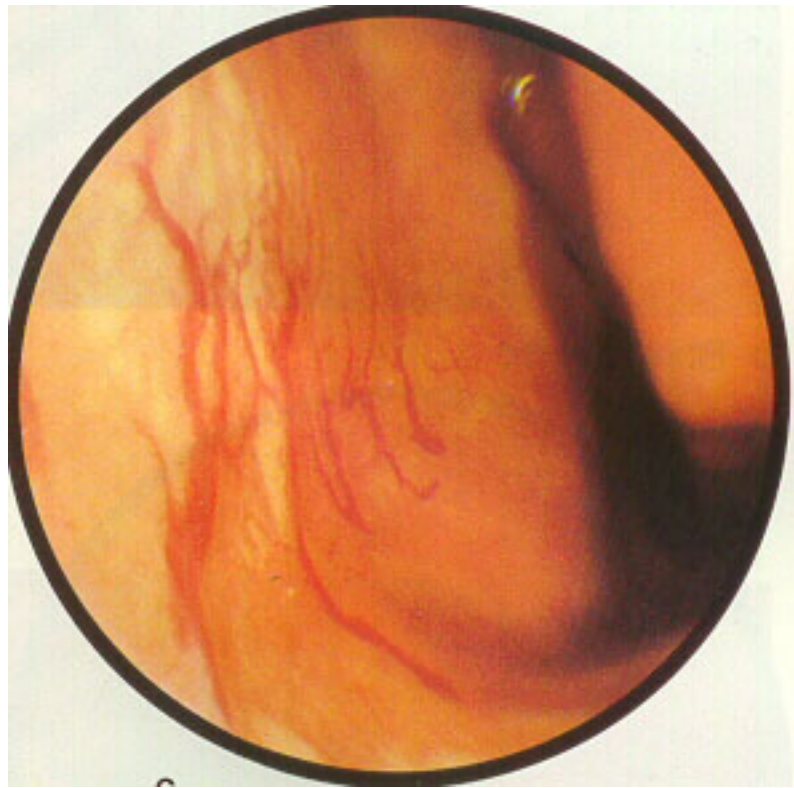Kesselbach's Plexus/Little's Area:

- Anterior Ethmoid (Opth)
- Superior Labial A (Facial)
- Sphenopalatine A (IMAX)
- Greater Palatine (IMAX)



Woodruff's Plexus:

- Pharyngeal & Post. Nasal AA of Sphenopalatine A (IMAX)



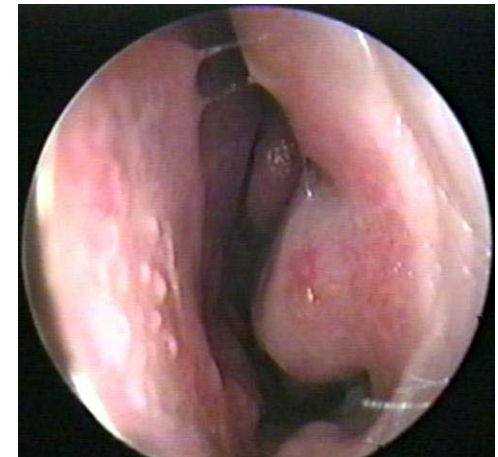
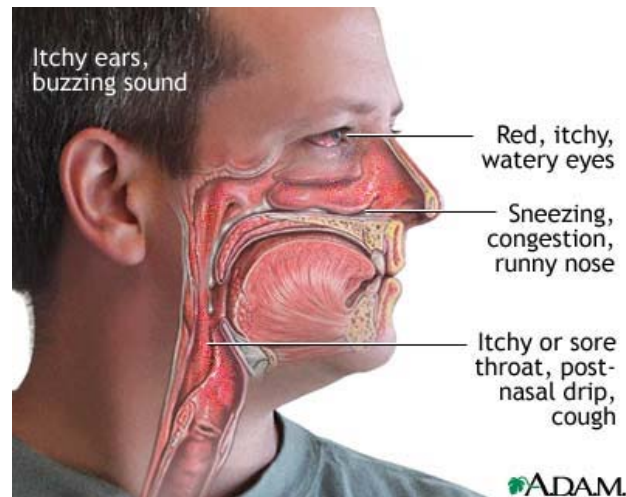
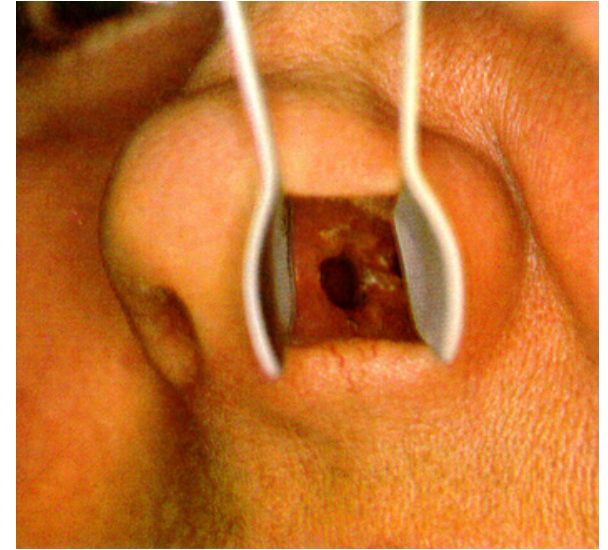
Why bleeding from the nose ?

Vascular organ secondary to incredible heating/humidification requirements

- Vasculature runs just under mucosa (not squamous)
- Arterial to venous anastamoses
- ICA and ECA blood flow

Local Factors - Trauma

- Nose picking
- Nose blowing/sneezing
- Nasal fracture
- Nasogastric/nasotracheal intubation



Local Factors –

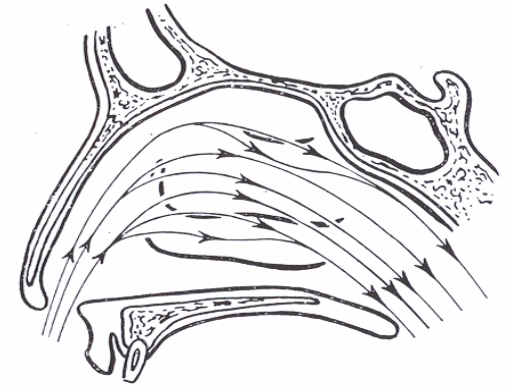
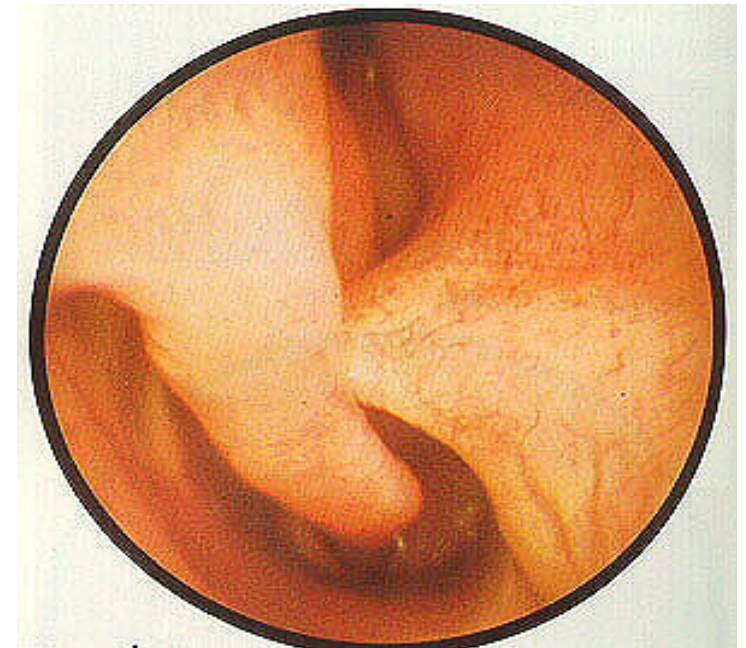


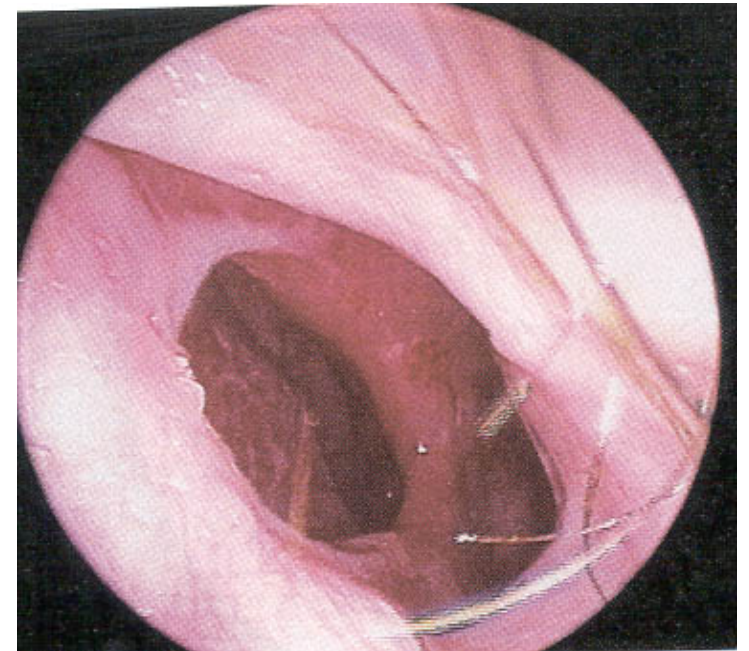
Figure 6.2 Diagram of inspiratory air currents

- Cold, dry air—more common in wintertime
- Dry heat—Phoenix and Death valley
- Anatomic abnormalities



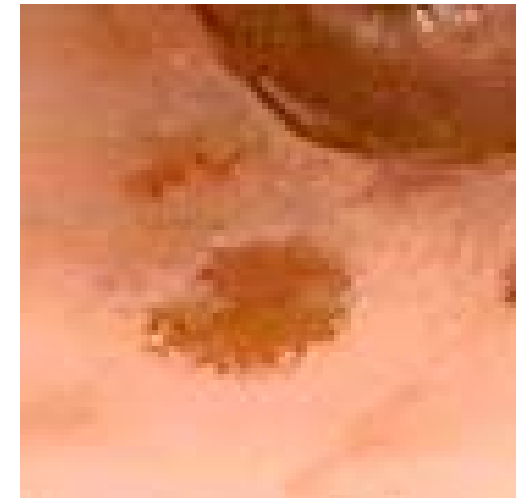
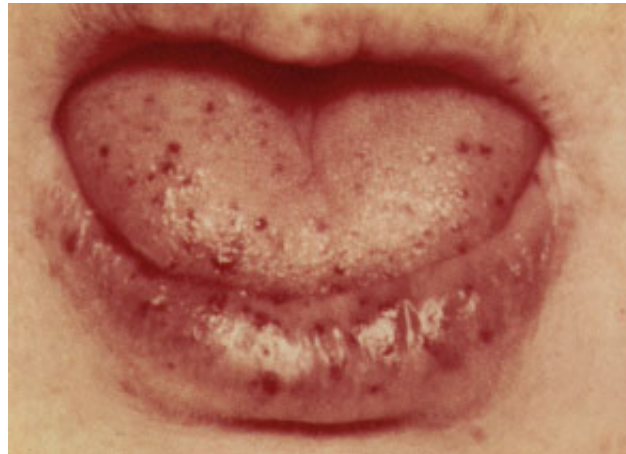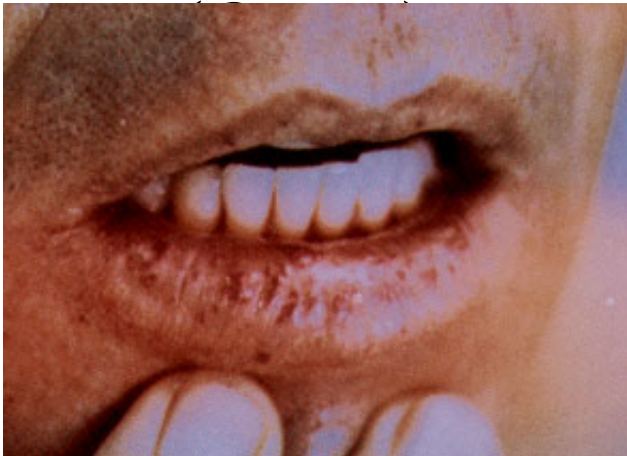Local Factors - Other

- Self-inflicted (pedi)
- Foreign bodies
- Infectio
- Septal perforation
- Chemical (cocaine, nasal sprays, ammonia, etc.)



Systemic Factors -- Vascular

- Hypertension/Arteriosclerosis
- Hereditary Hemorrhagic Telangiectasias

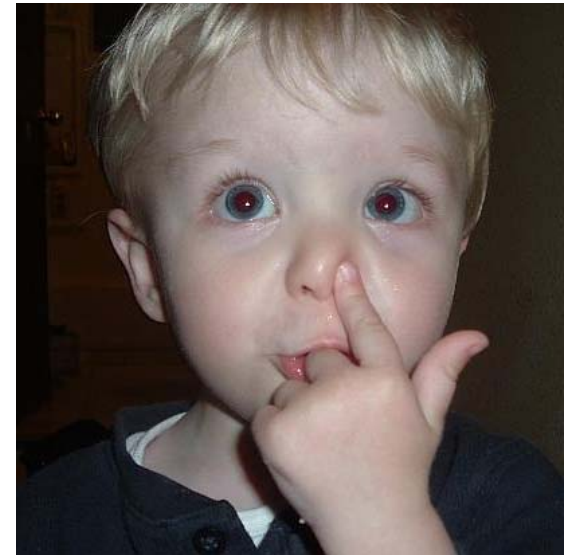

Systemic Factors – Coagulopathies

- **Thrombocytopenia**
- **Platelet dysfunction**
 - Systemic disease (Uremia)
 - Drug-induced (Coumadin/NSAIDs/.....)
- **Clotting Factor Deficiencies**
 - Hemophilia
 - VonWillebrand's disease
 - Hepatic failure
- **Hematologic malignancies**

Etiology and Age

- Children
 - Foreign body
 - Nose picking
 - Coagulation d/o)
- Adults—trauma, idiopathic
- Middle age—tumors
- Old age--hypertension



Initial Management


- **ABC's**
- **Medical history/Medications**
- **Vital signs—need IV?**
- **Physical exam**
 - **Anterior rhinoscopy**
 - **Endoscopic rhinoscopy**
- **Laboratory exam**
- **Radiologic studies**




bayonet forceps



vaseline gauze



good light



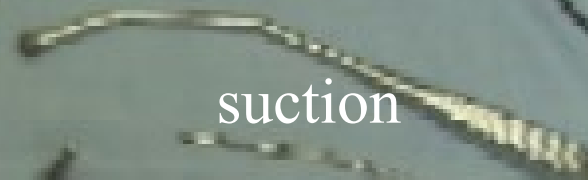
bacitracin



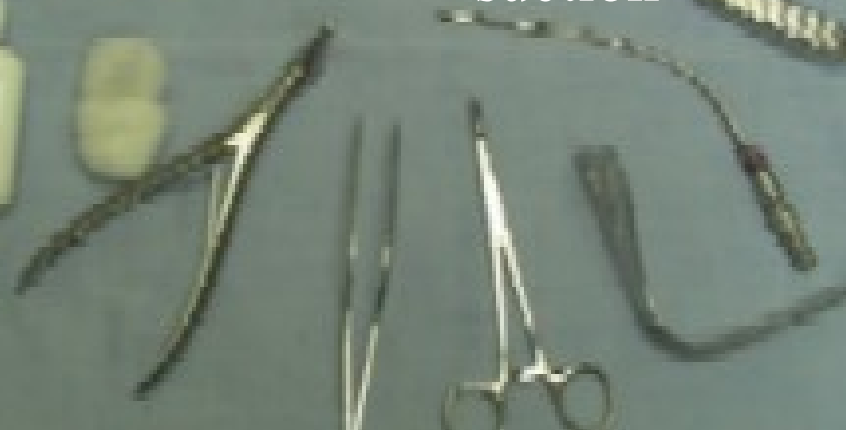gelfoam



suction




anesthetic



epistat



endoscopes




silver nitrate



suction bovie/bipolar

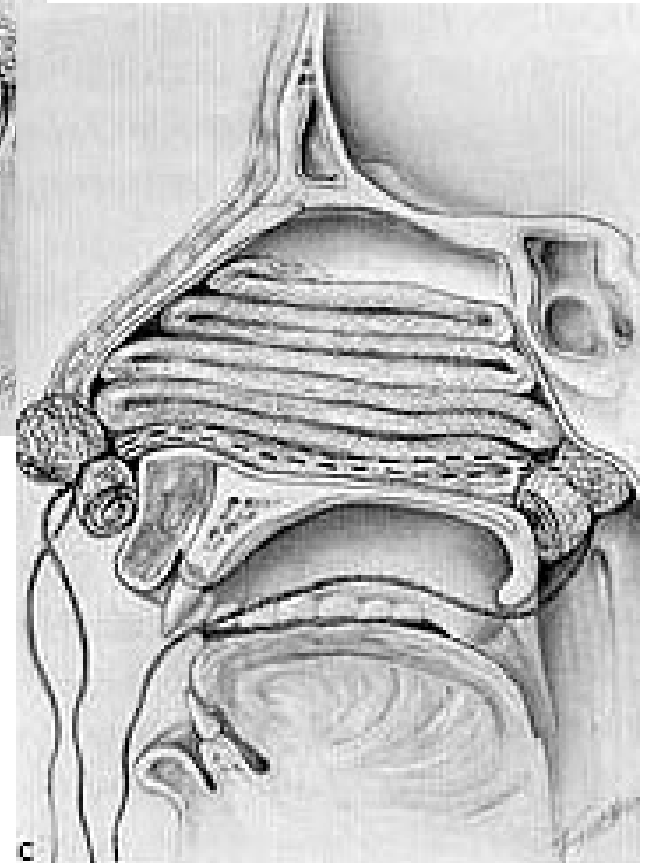
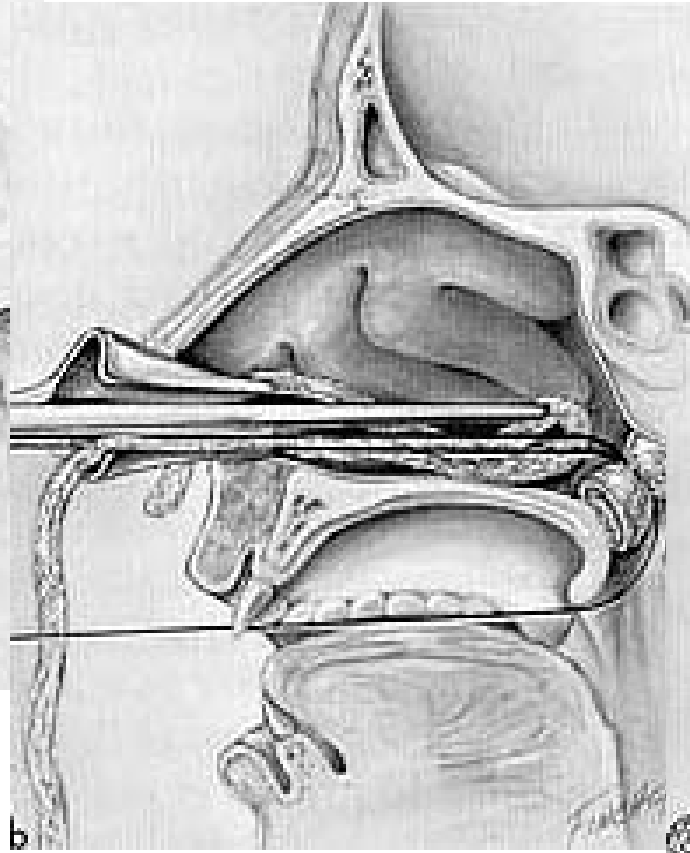
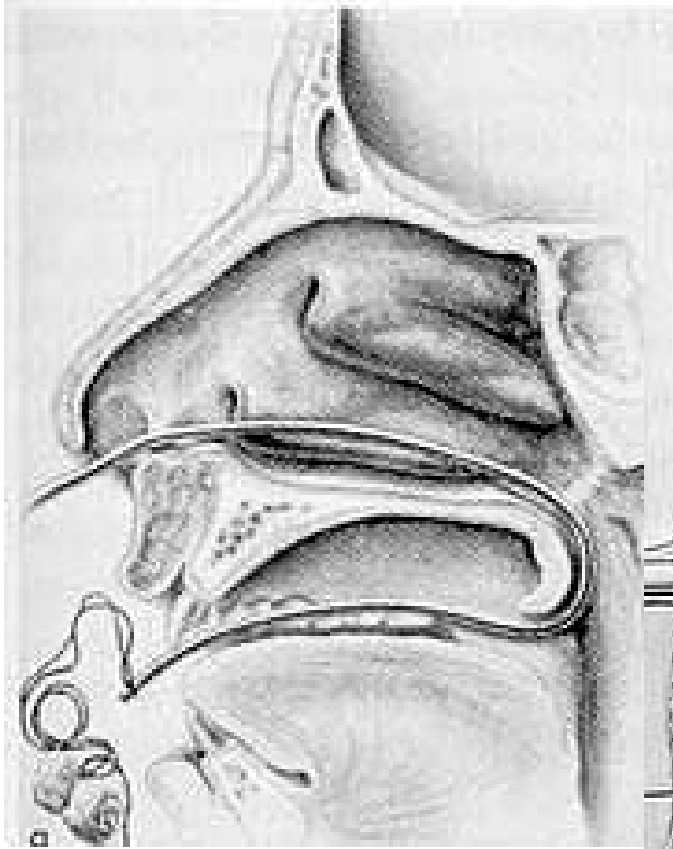
merocels

surgicel

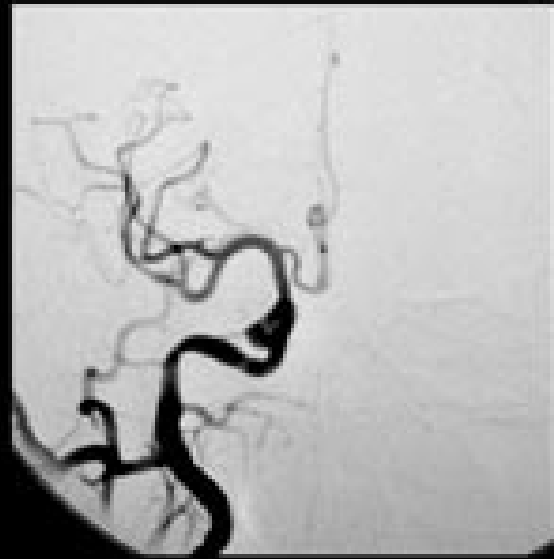
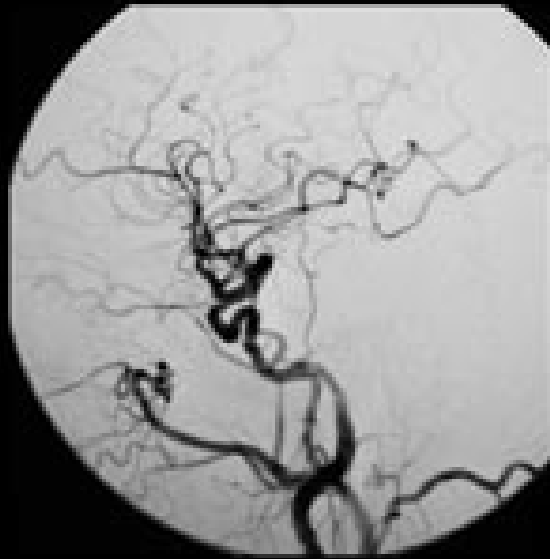
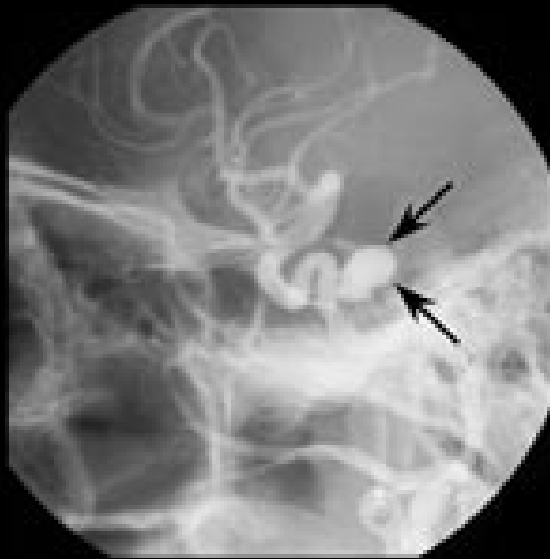
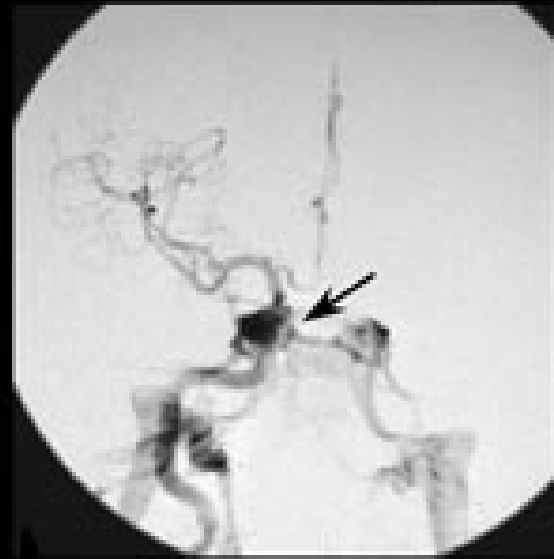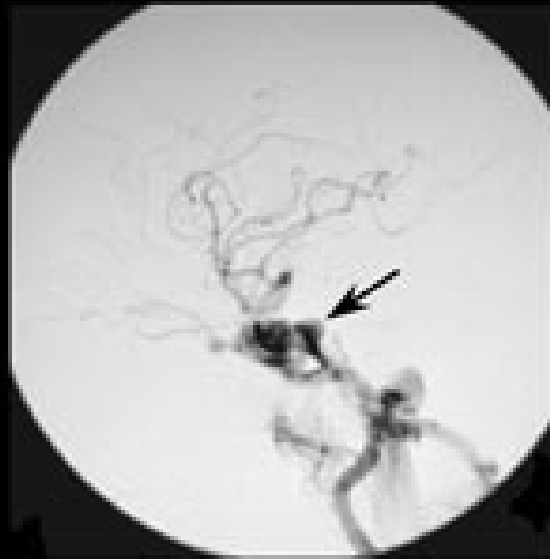
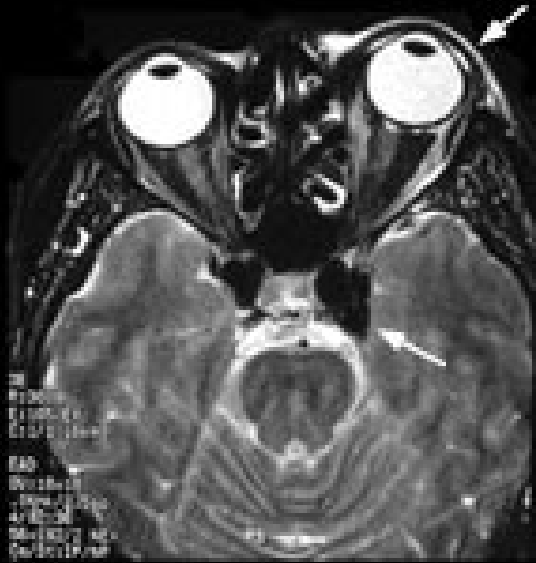


Treatments

- Control of hypertension
- Correction of coagulopathies
- Topical decongestants/vasoconstrictors
- Cautery (AgNo₃ vs. TCA vs. Bipolar vs. Bovie)
- Nasal packing (effective 80-90% of time)
- Surgery/embolization



TSS—Nugauze vs. Merocel
Electron microscopy



Non-surgical treatments

- Humidity/emollients
- Discontinue offending meds
- Nasal saline sprays
- Avoidance of nose picking/blowing
- Sneeze with mouth open
- Avoid straining/bed rest

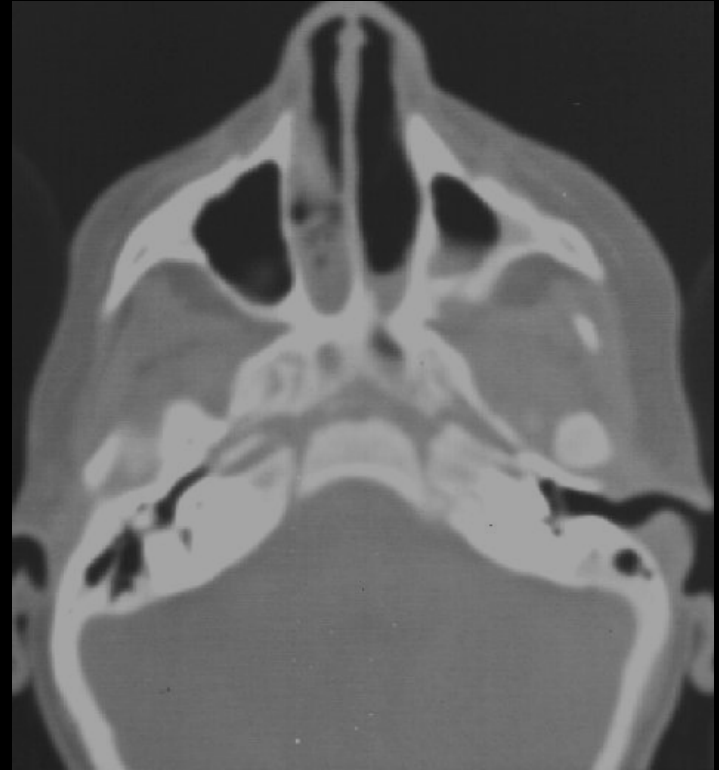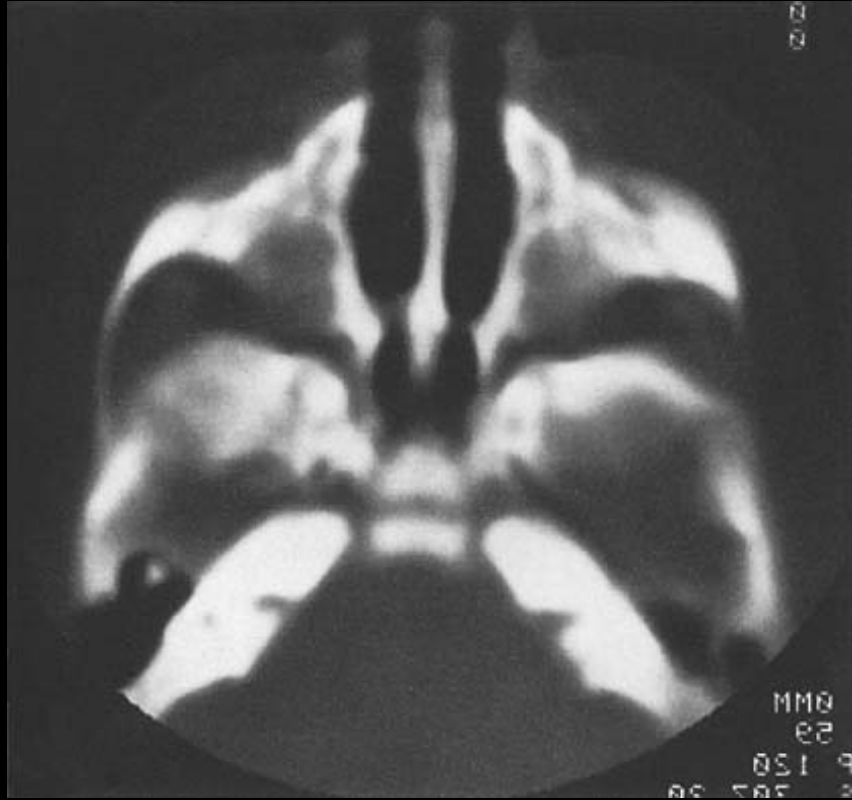
Choanal Atresia

- Airway Concerns—
- CHARGE association
- Bilateral – immediate airway support
- If definitive surgery delayed b/c of other anomalies, tracheotomy necessary

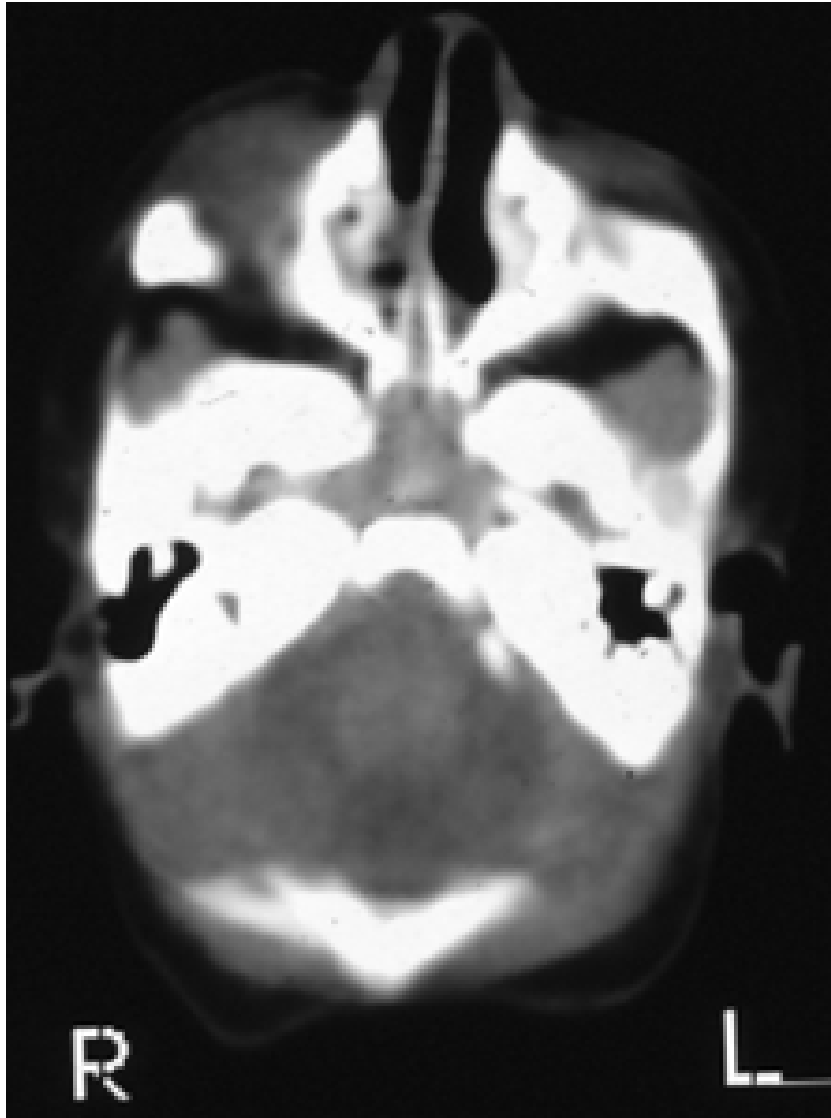
C.H.A.R.G.E.

1. Coloboma
2. Heart defect (tetralogy of Fallot, ASD, VSD)
3. Atretic choanae
4. Retarded growth
5. Genitourinary anomalies
6. Ear malformations

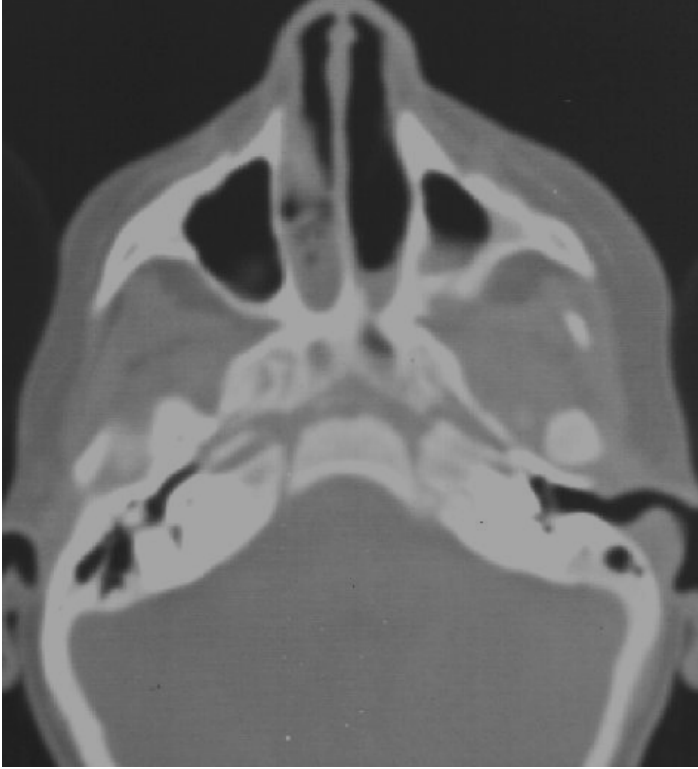*must have 4 out of 6 categories



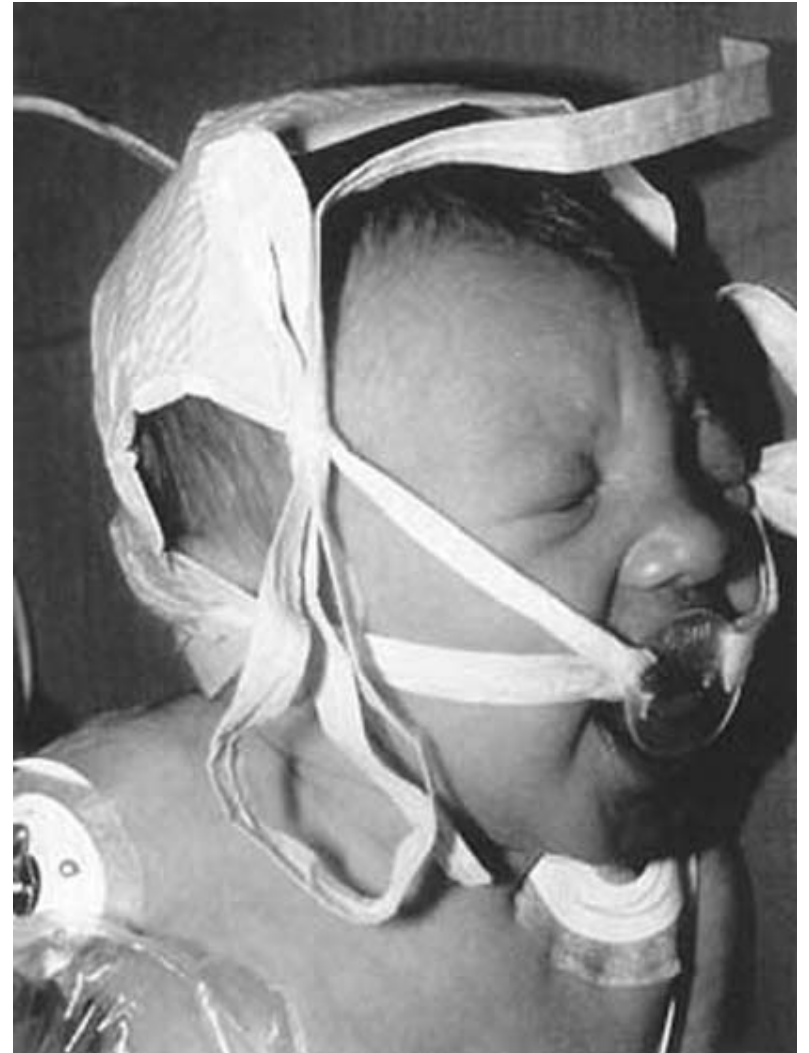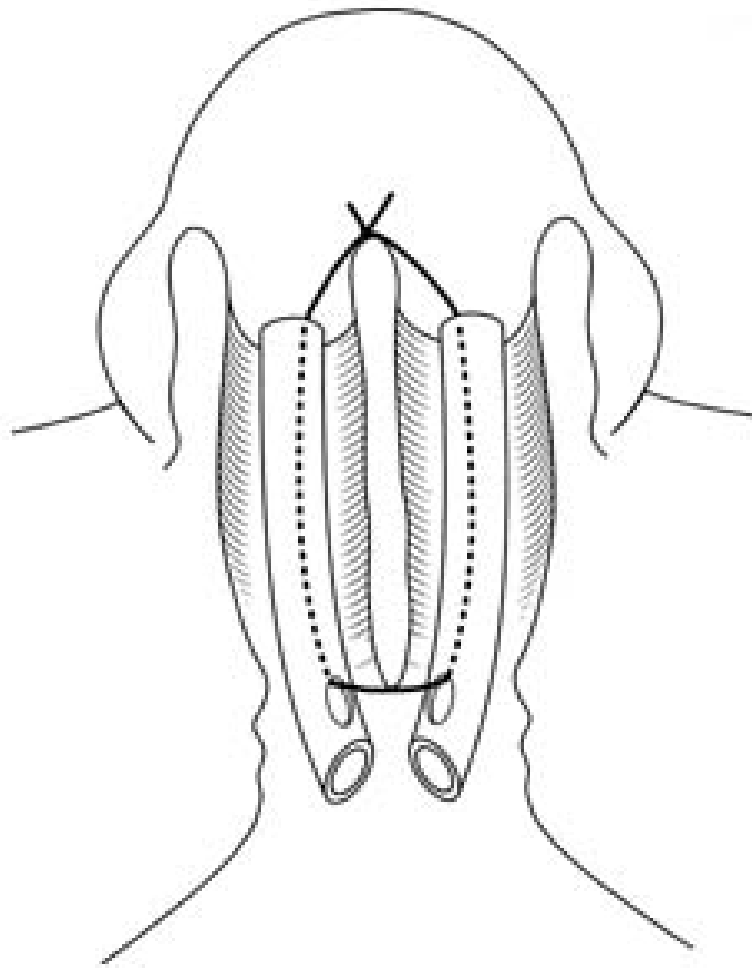
Choana = قطع



Atresia = رتق

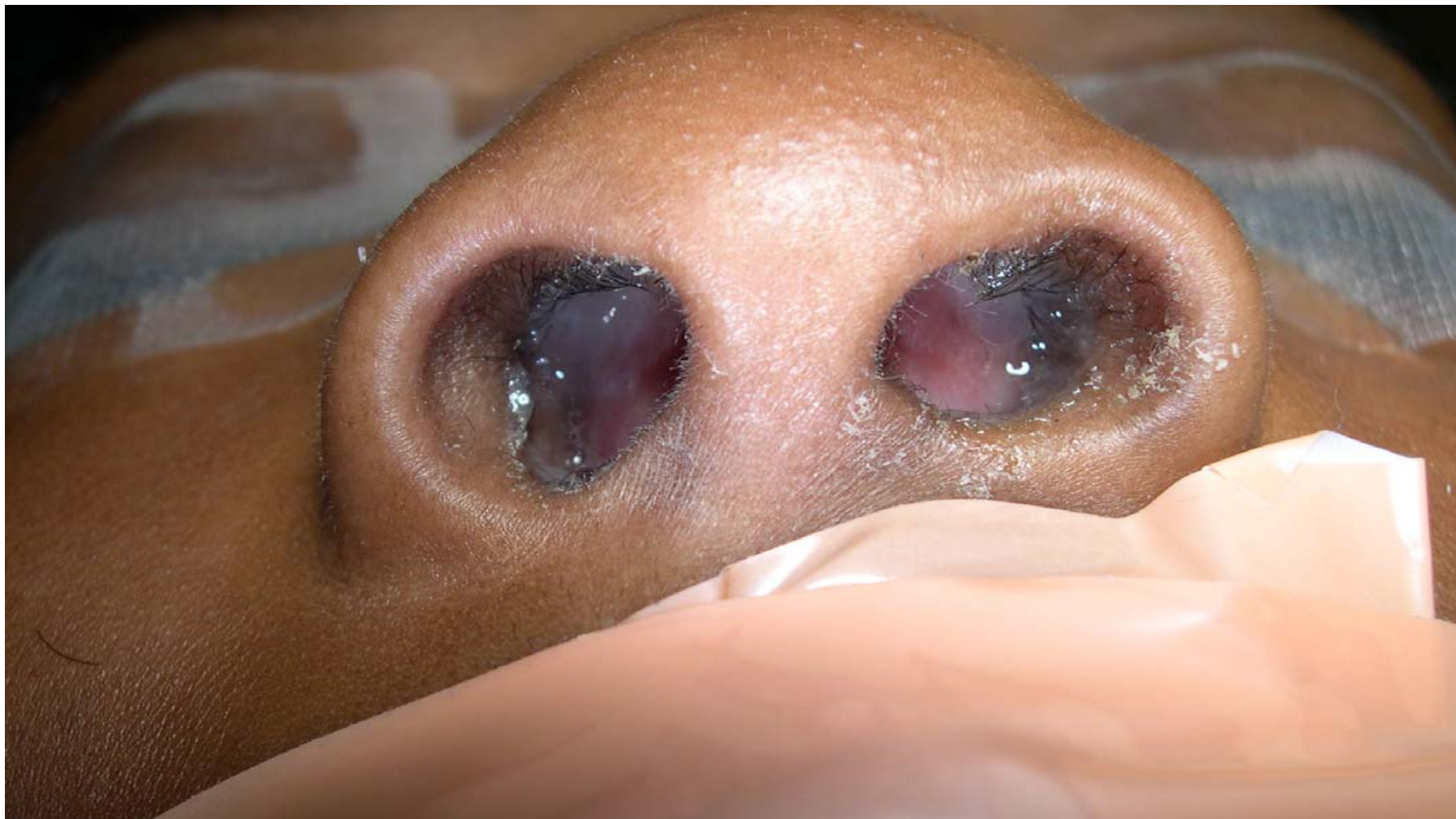

الرَّتْقُ: الشيءُ المرتوقُ أي المسدودُ والملتئم
(أَوْ لَمْ يَرَ الَّذِينَ كَفَرُوا أَنَّ السَّمَوَاتِ وَالْأَرْضَ كَانَتَا رَتْقًا فَفَتَقْنَاهُمَا)

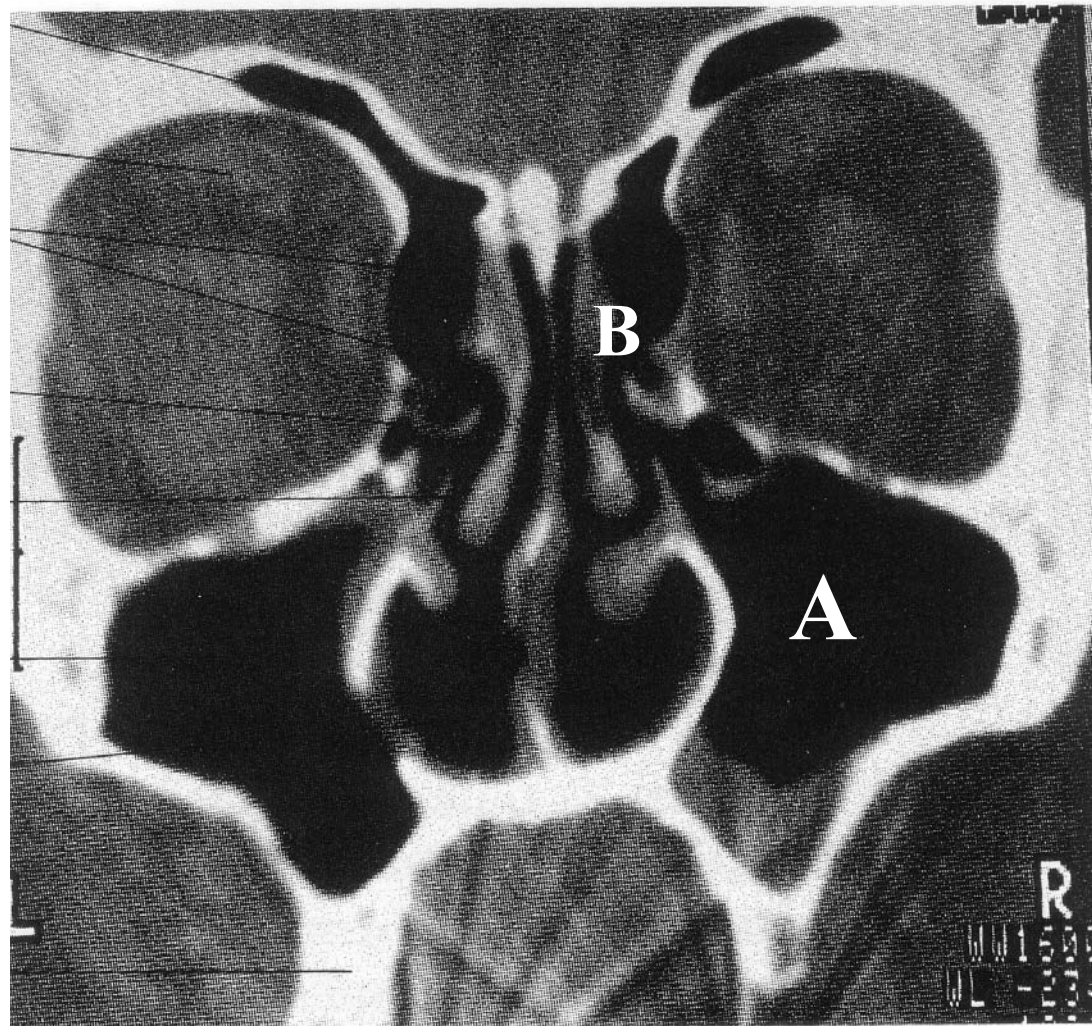


**What do
you think?**

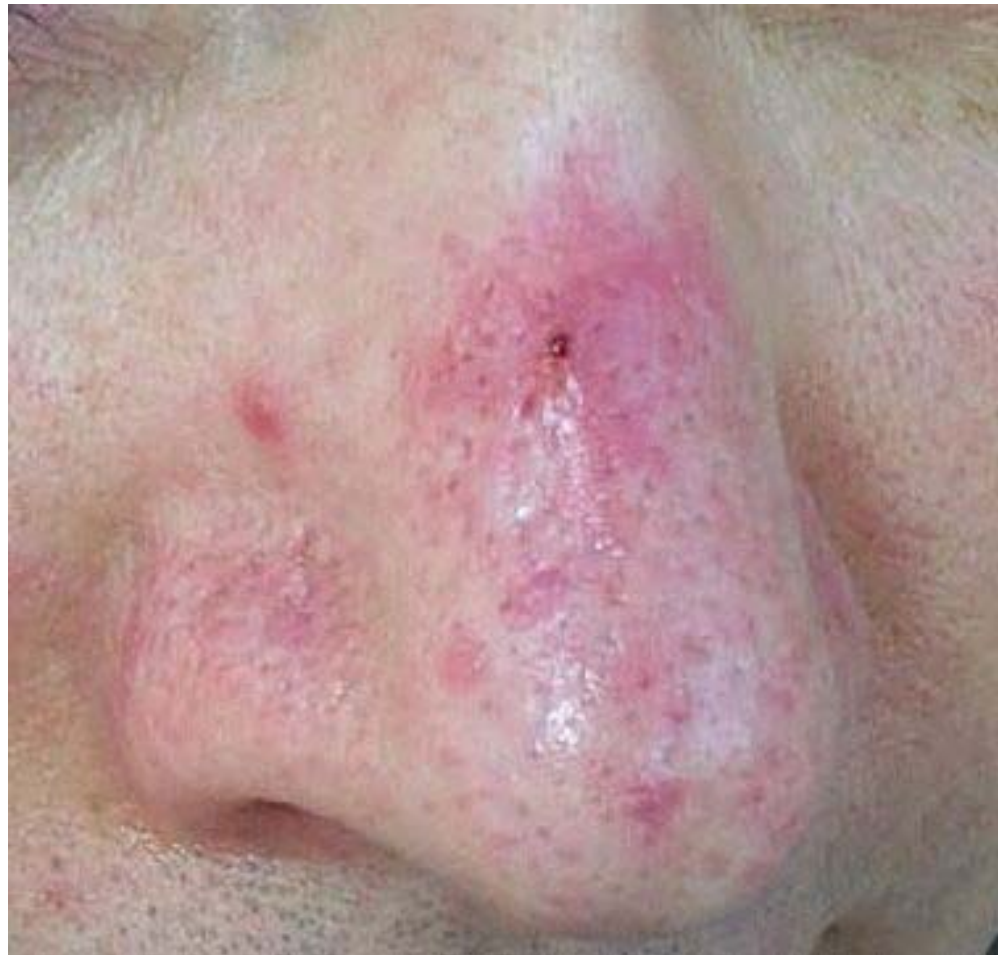25 Y in RTA, fever nasal obstruction



What is A & B?



Give 2 complications of this infection



Thanks