

بِسْمِ اللَّهِ الرَّحْمَنِ الرَّحِيمِ

# BASIC ANATOMY AND PHYSIOLOGY

**DR. YASSER AL-FAKY**

**M.D., M.Sc (Ophth.), FRCS**

# ANATOMY

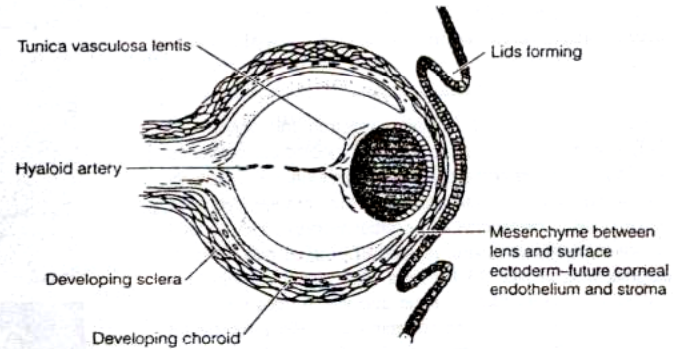

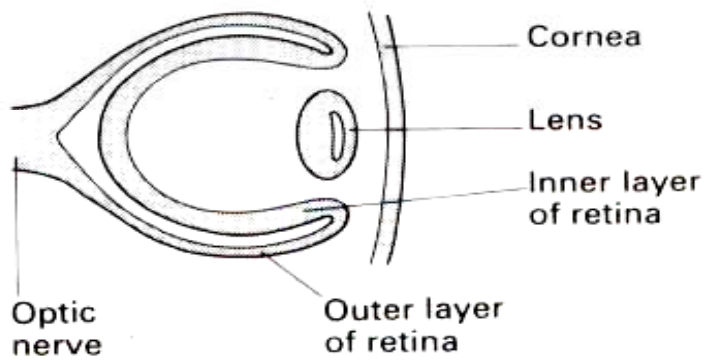
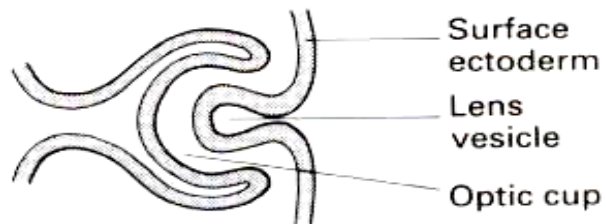
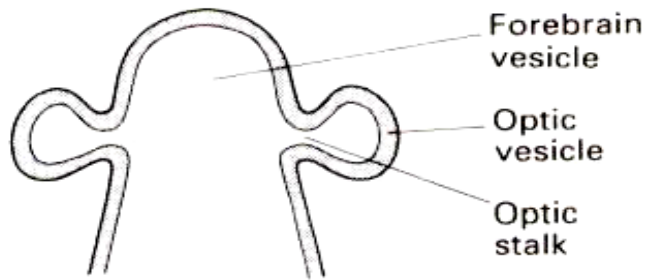
The word "ANATOMY" is rendered in a bold, 3D, sans-serif font. The letters have a vertical gradient from bright yellow at the top to a deep orange at the bottom. They are set against a solid black background. On the left side, a large, smooth, blue arc curves upwards and to the right, partially overlapping the text.

# *EMBRYOLOGY OF THE EYE*

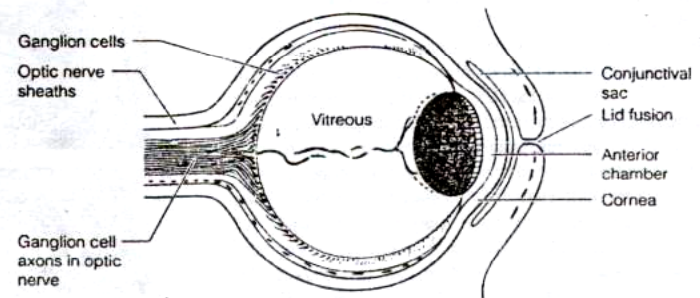
- This highly specialized sensory organ is derived from neural ectoderm, mesoderm and surface ectoderm.
- The eye is essentially an outgrowth from the brain (neural ectoderm).
- Started as *Optic vesicle* connected to the forebrain by *Optic stalk*.

## *EMBRYOLOGY (cont.)*

- Invagination of both the optic vesicle to form *Optic cup* and the optic stalk to form *Choroidal fissure* inferiorly.
- Surface ectoderm invaginate to form the lens vesicle.
- Mesodermal tissues invade the developing eye to share in vascular, muscular and supportive tissues of the eye.




mm)



# *DEVELOPMENT OF THE EYE AFTER BIRTH*

- At birth, the eye is relatively large in relation to the rest of the body.
- The eye reaches full size by the age of 8 years.
- The lens continues to enlarge throughout the life.
- The iris has a bluish color due to little or no pigment on the anterior surface.
- During early infant life, the cornea & sclera can be stretched by raised IOP → enlargement of the eye.



Palpebral  
fissure

Dorsum nasi

Infraorbital  
foramen

Mental  
protuberance

Supraorbital  
notch

Eyelids

Zygomatic bone

Ala nasi

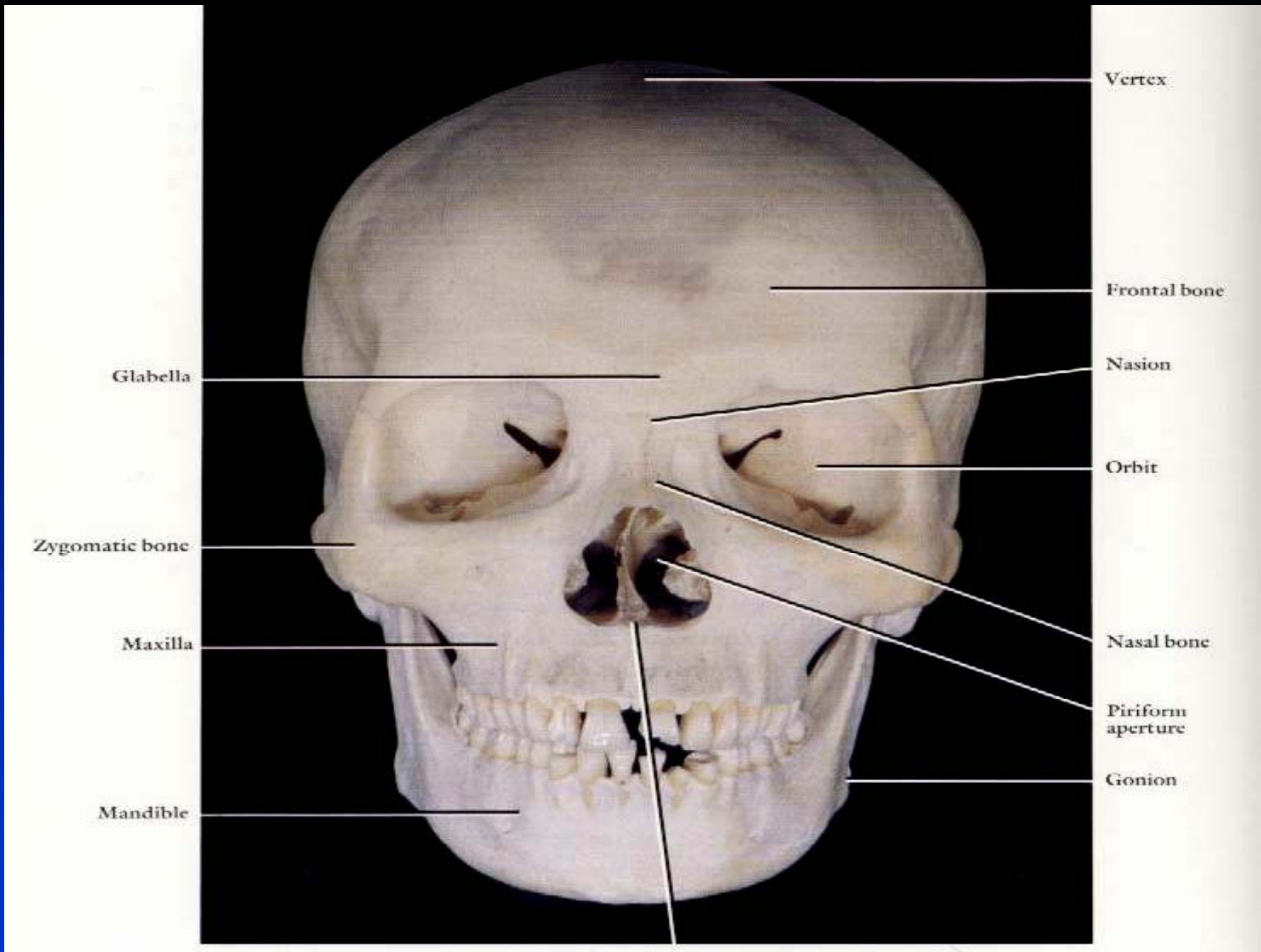
Lips

Mental foramen



# THE ORBIT

- As a socket, contains & protect the eye.
- The weakest parts are the floor & the medial wall.
- Seven bones contribute the bony orbit.
- Surrounded by nasal sinuses.
- Important openings are:
  - ◆ Optic foramen.
  - ◆ Superior orbital fissure.
  - ◆ Inferior orbital fissure.



Glabella

Zygomatic bone

Maxilla

Mandible

Vertex

Frontal bone

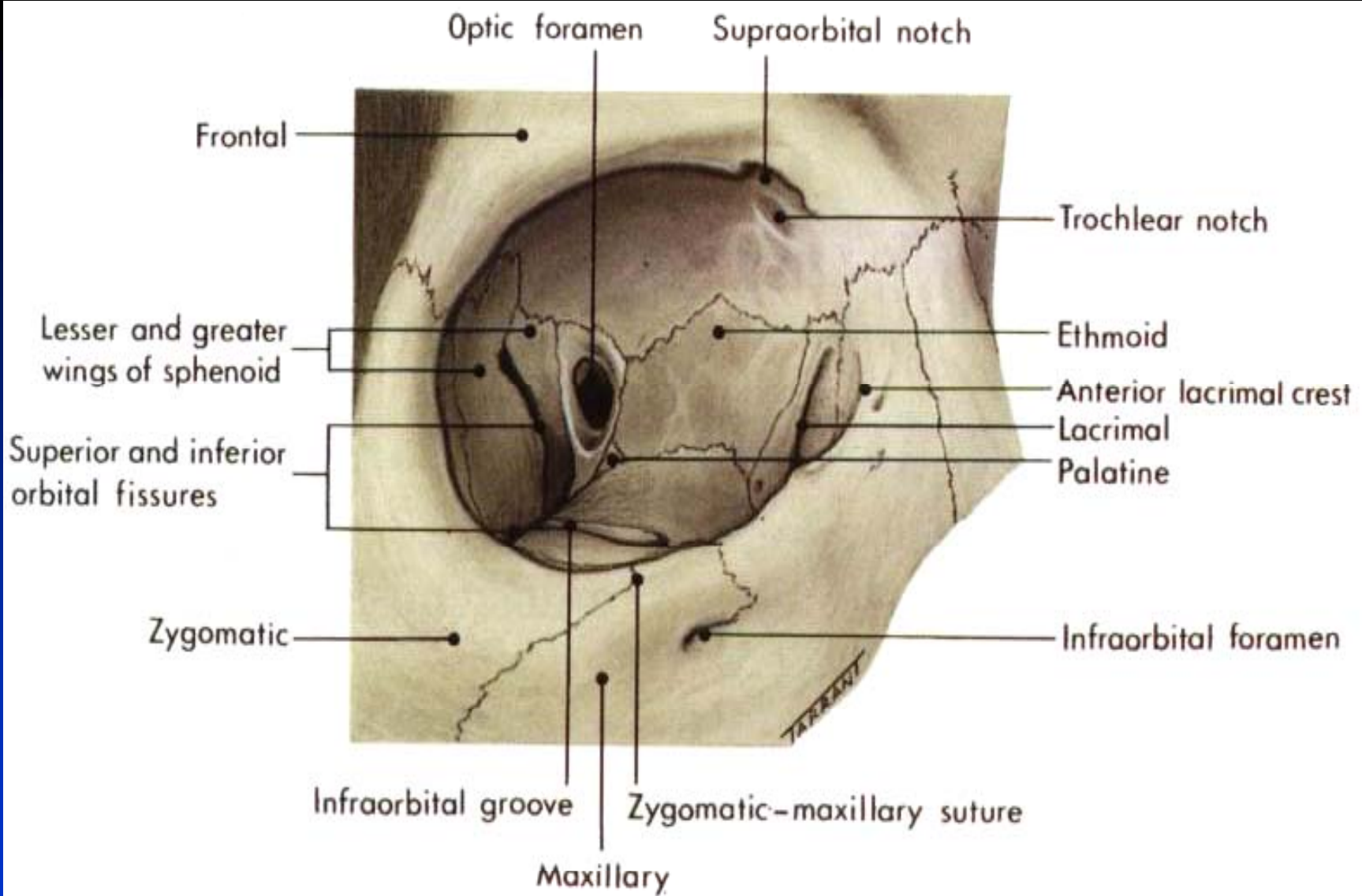
Nasion

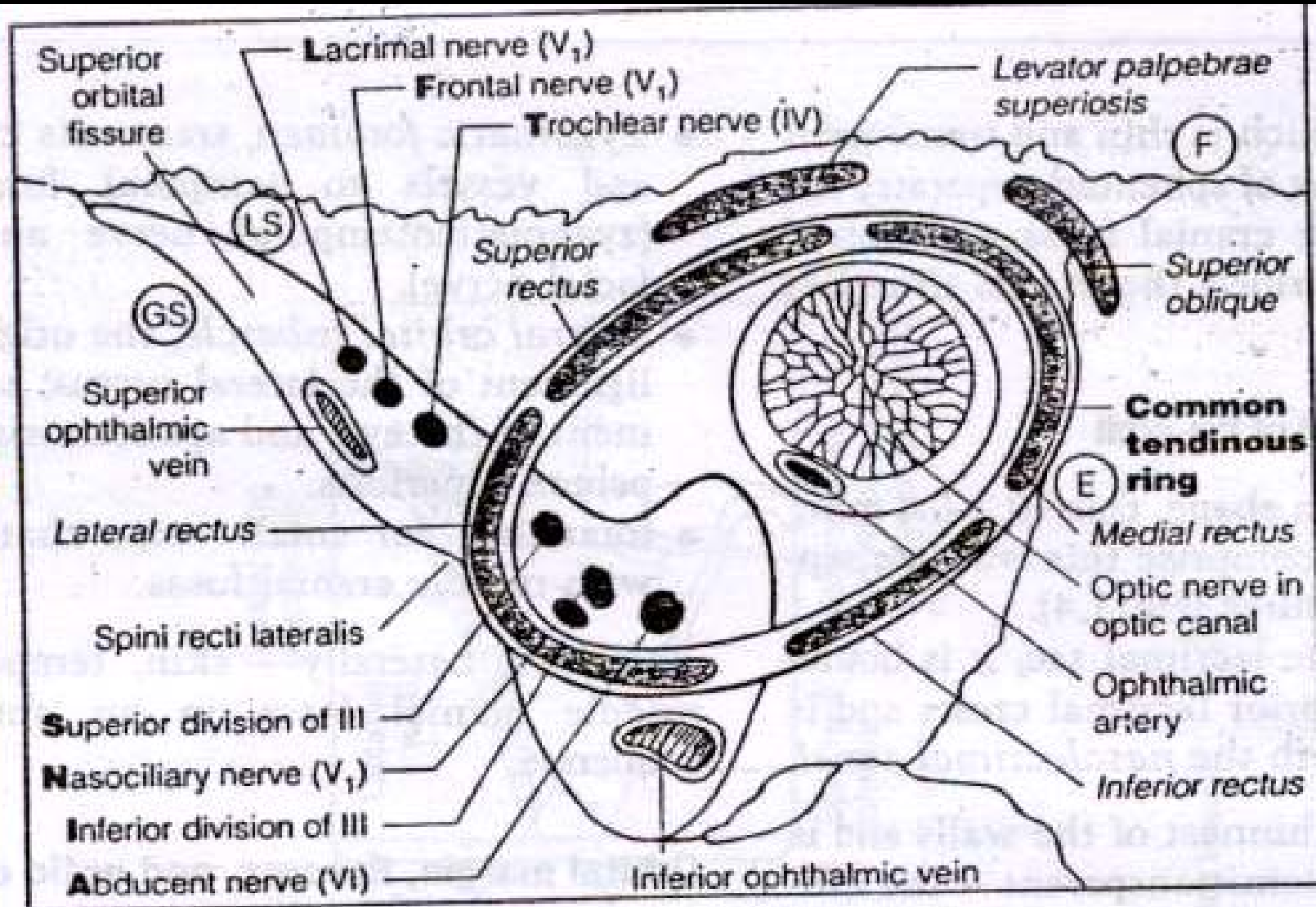
Orbit

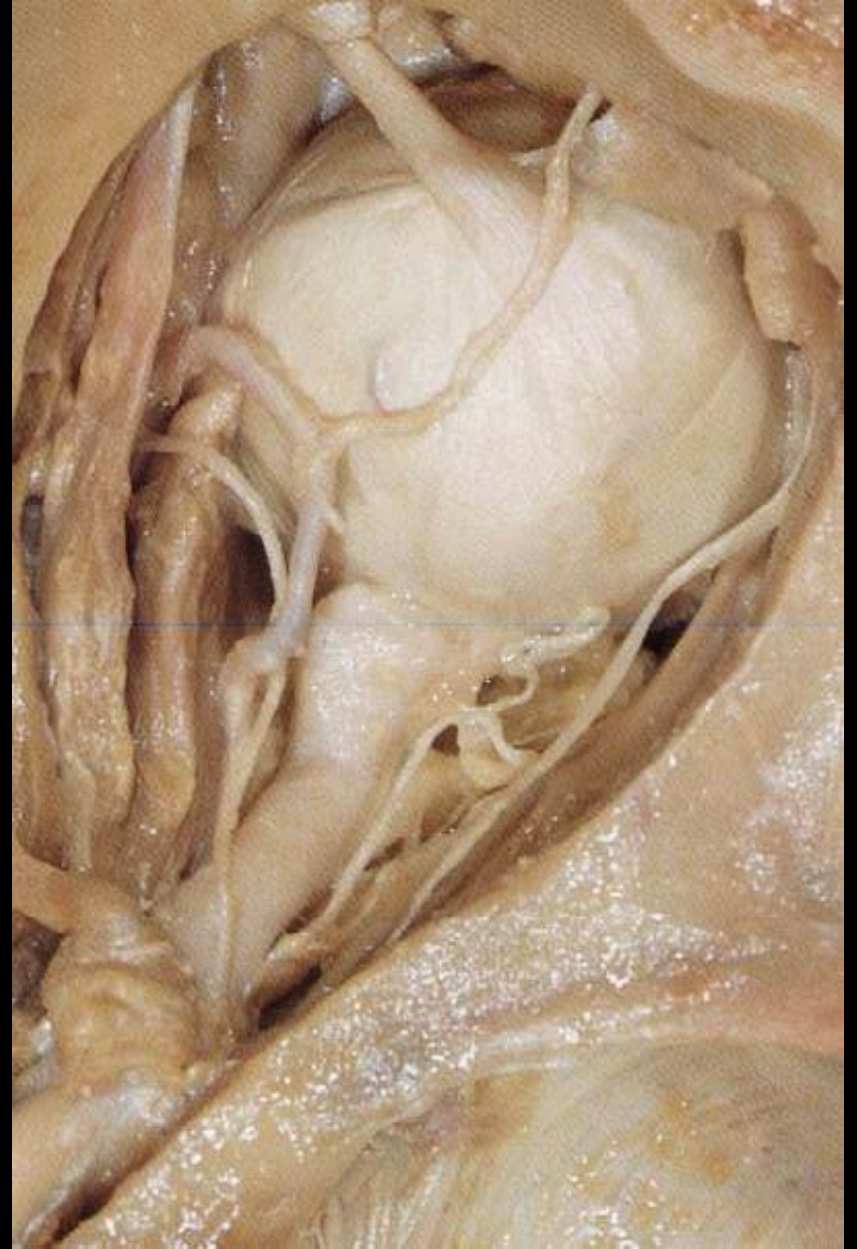
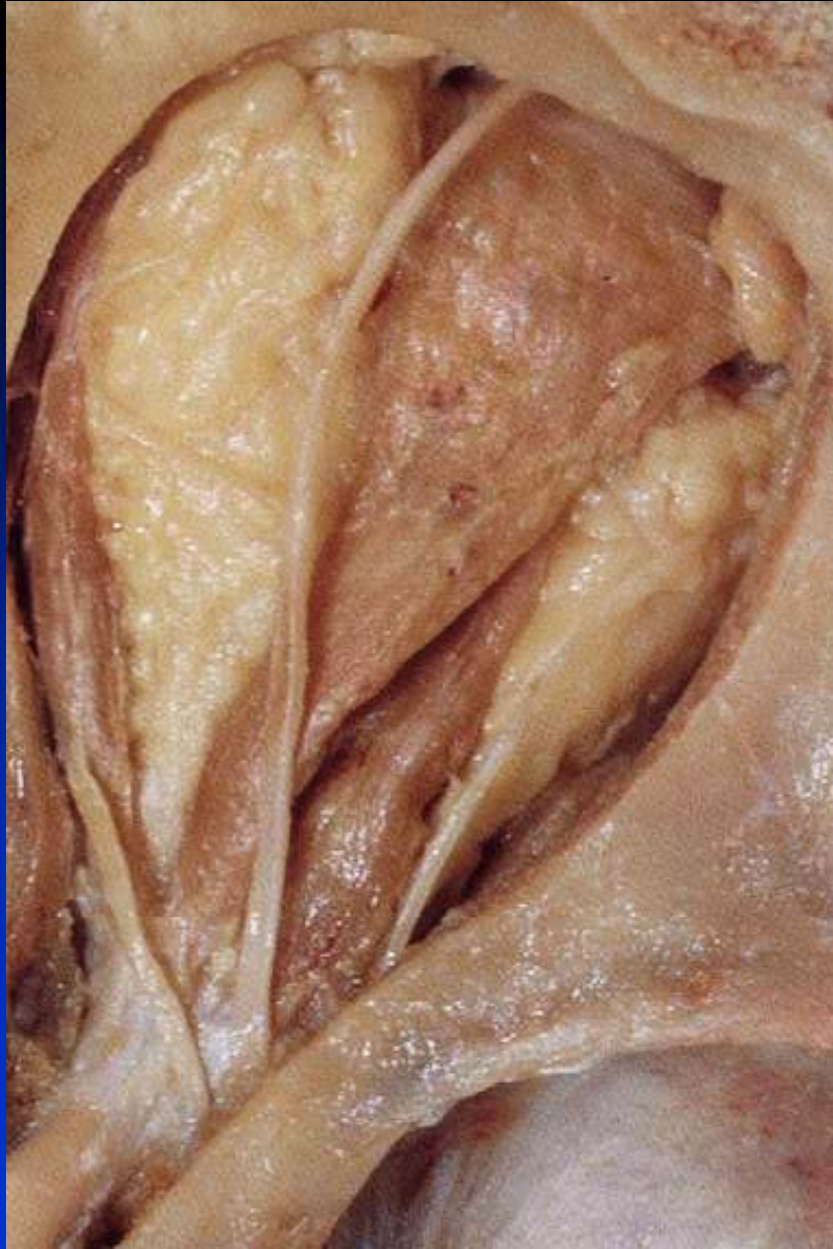Nasal bone

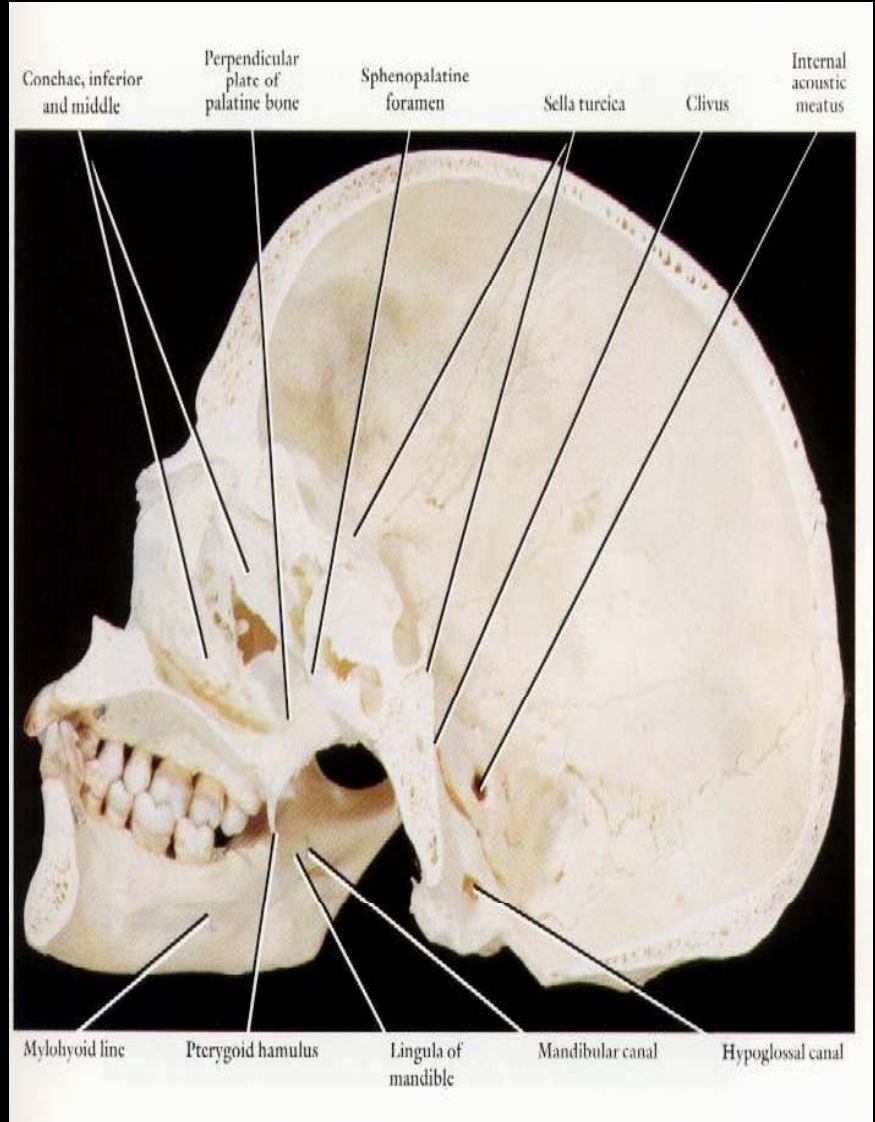
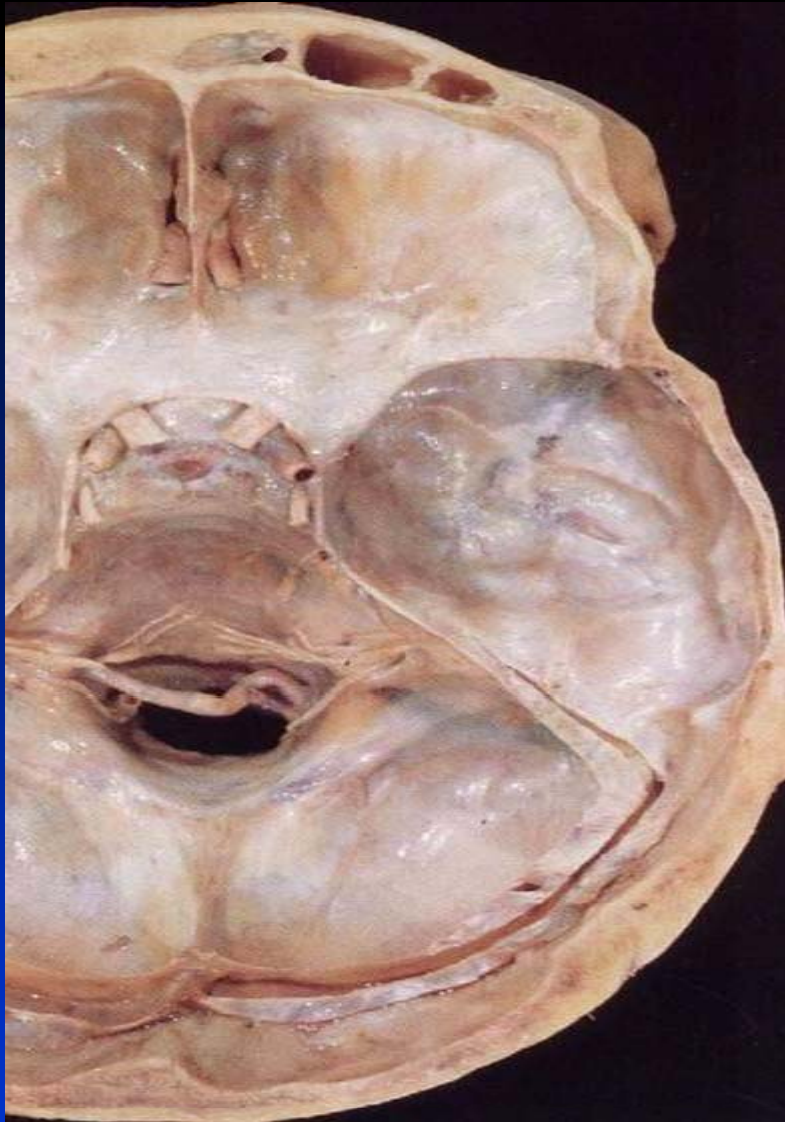Piriform aperture

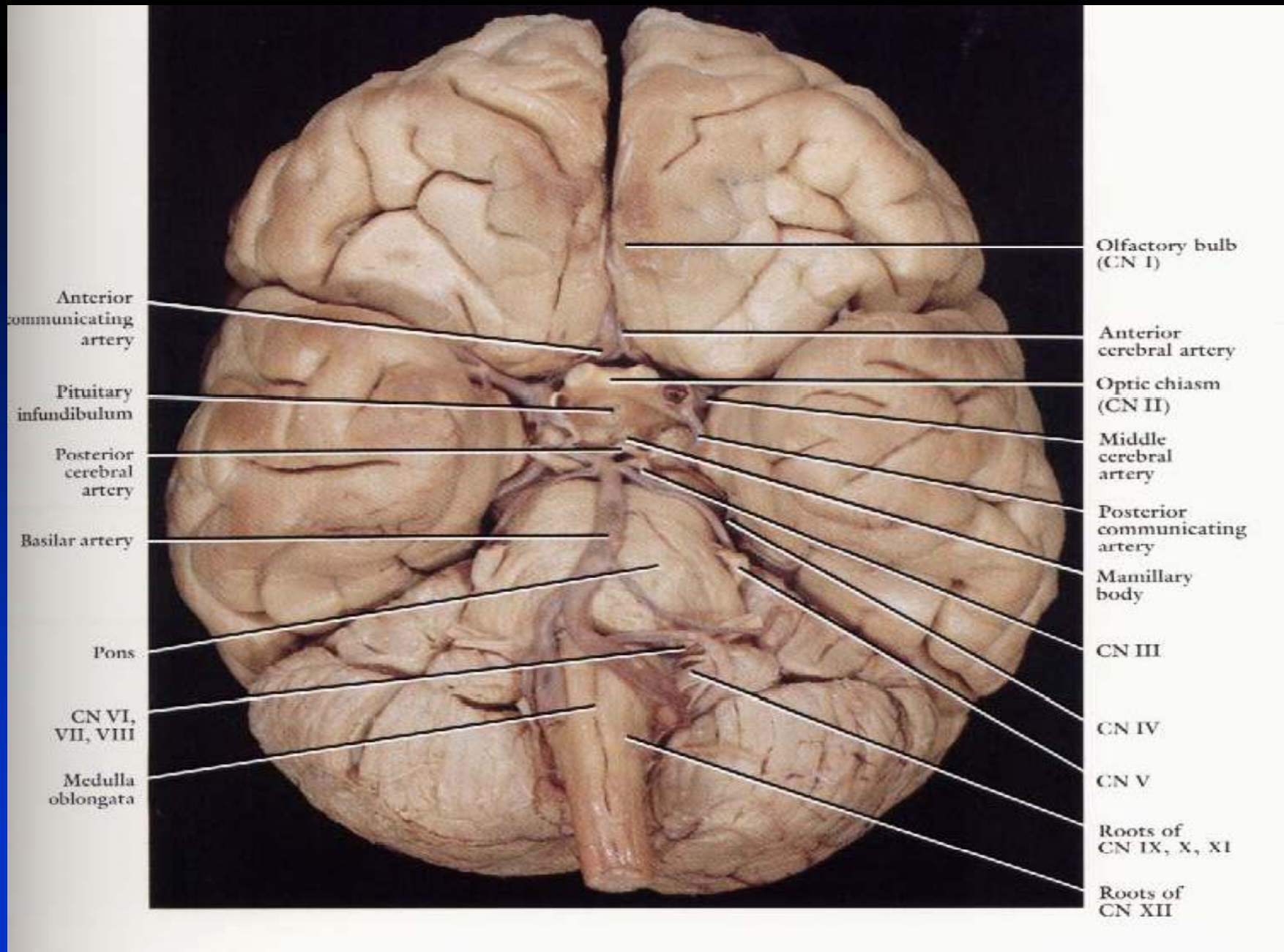
Gonion





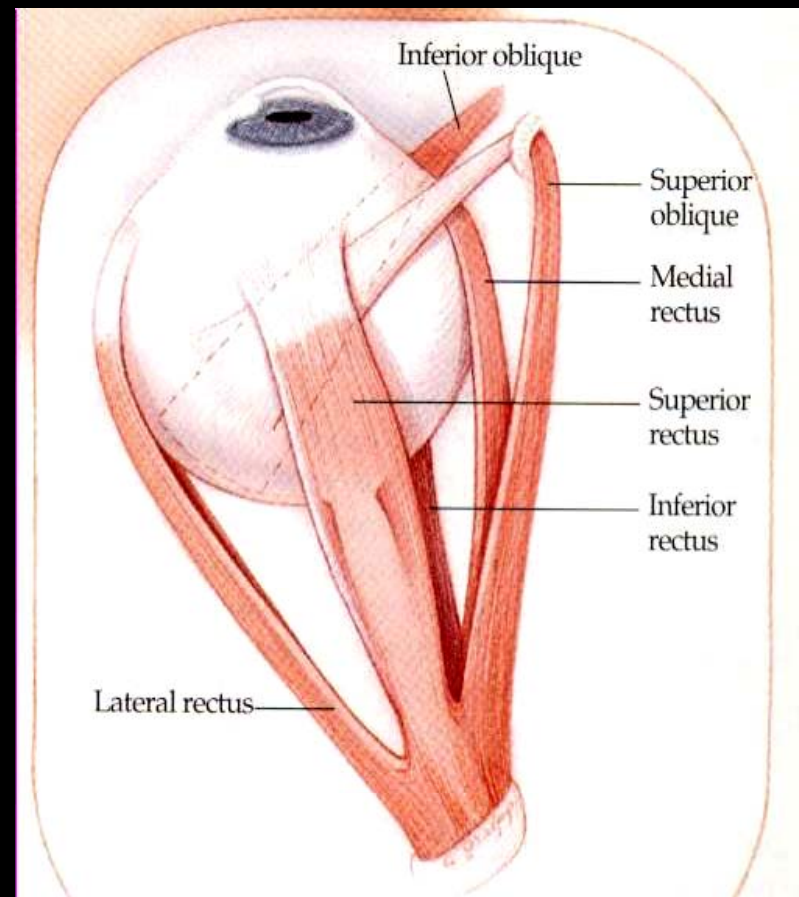






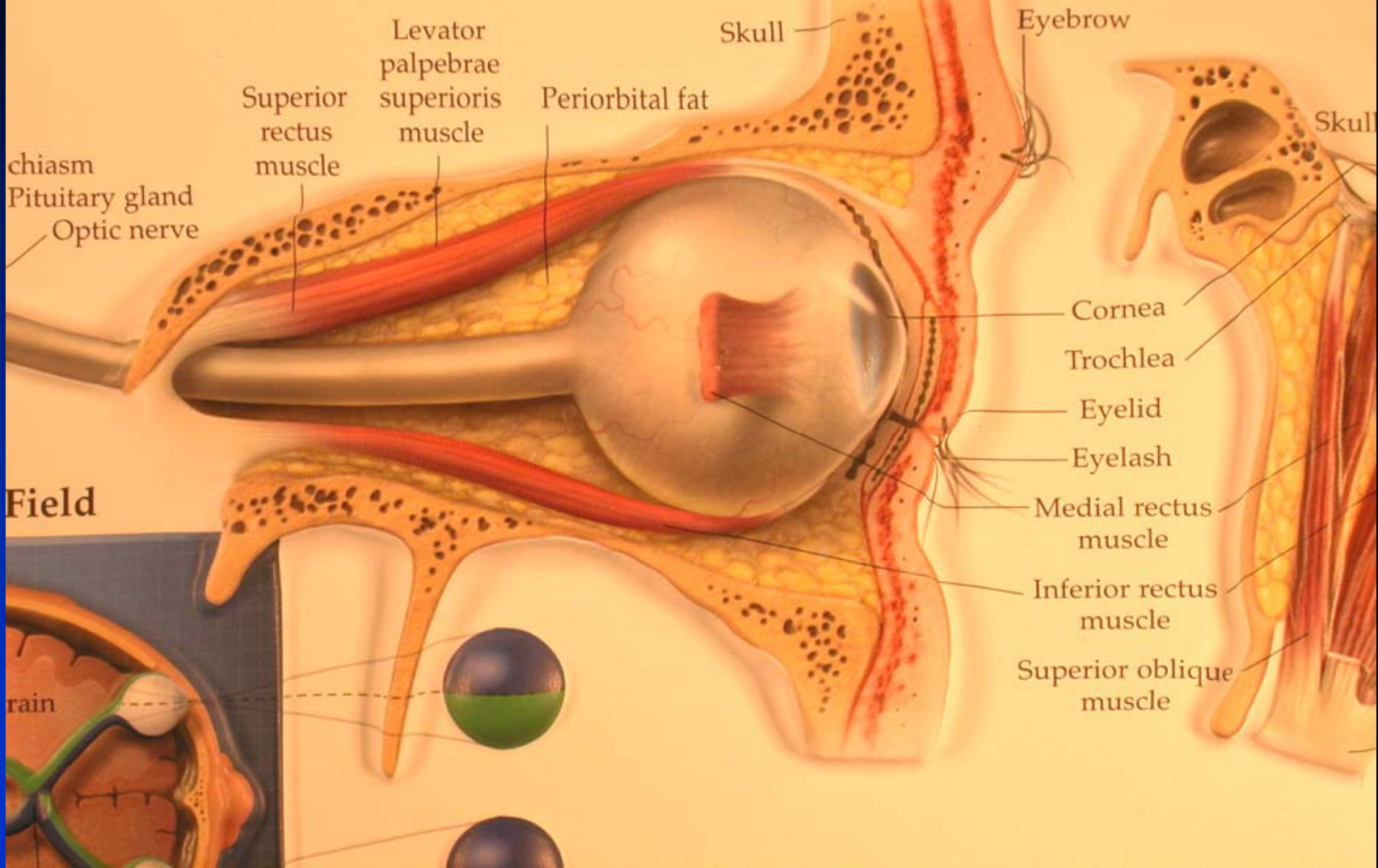
# THE EXTRAOCULAR MUSCLES

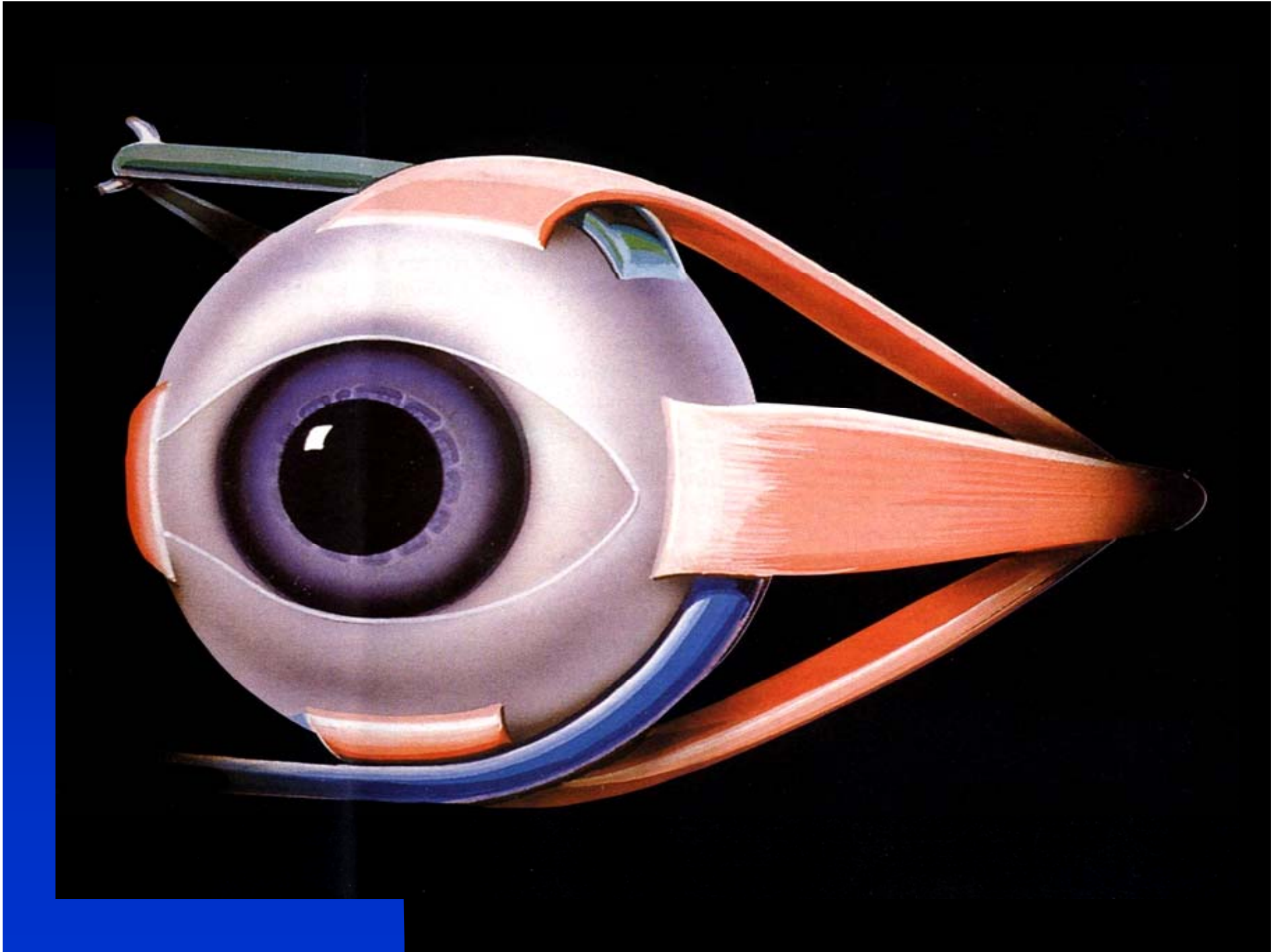
- Four recti & two oblique muscles.
- All are supplied by Oculomotor n. except superior oblique (Trochlear n.) & lateral rectus (Abducent n.).

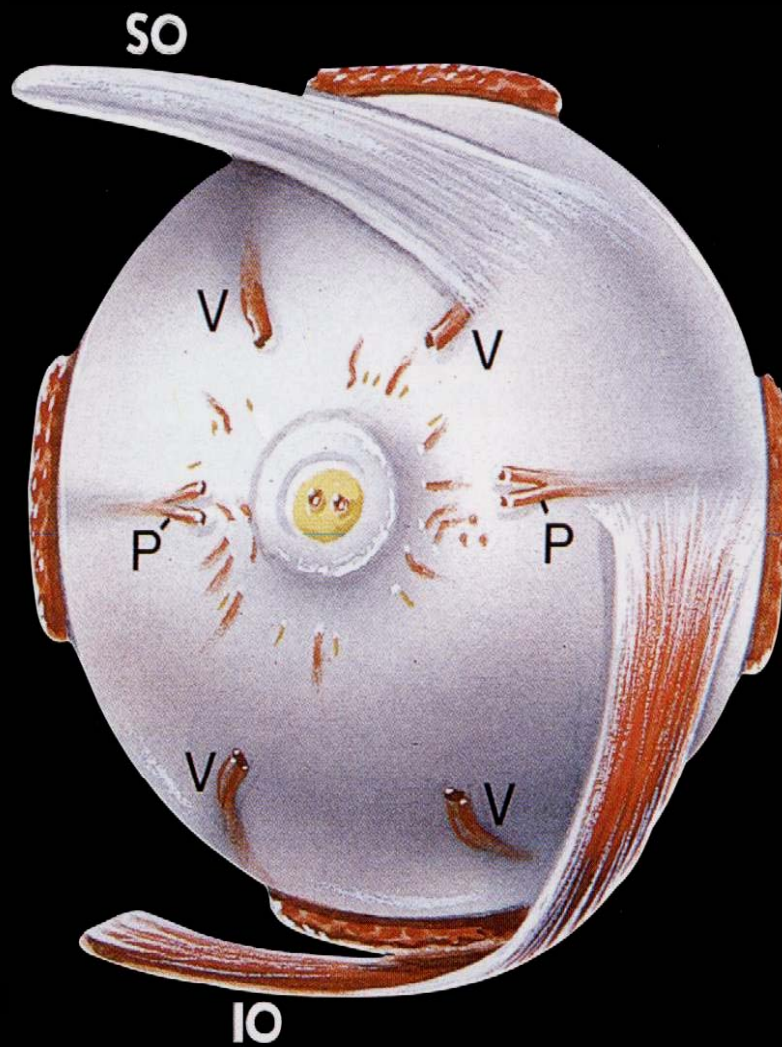
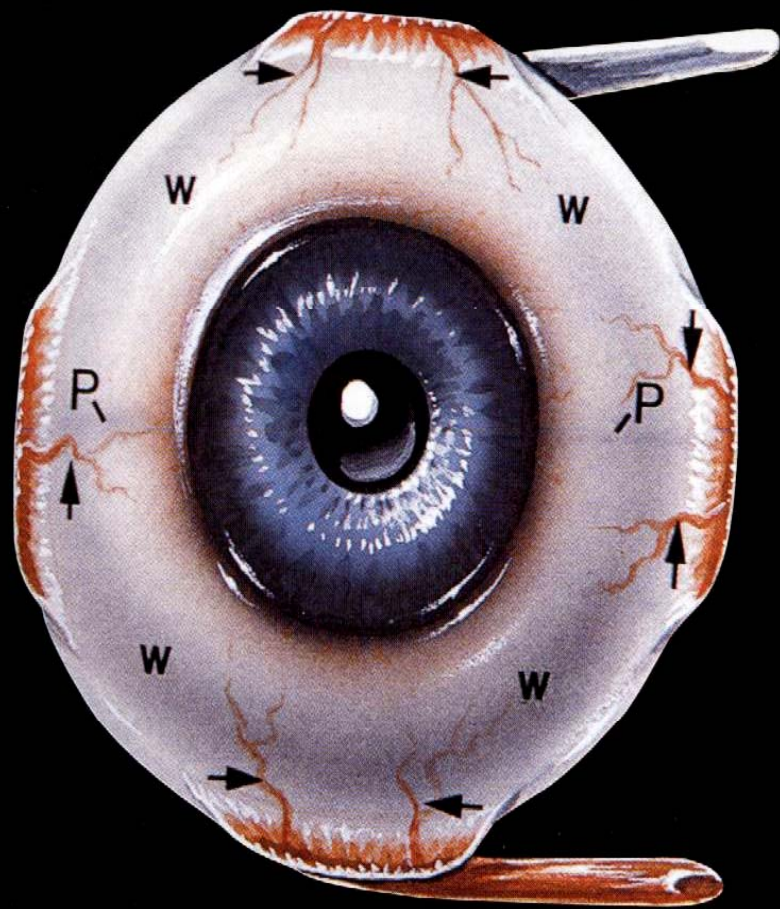




# Lateral View

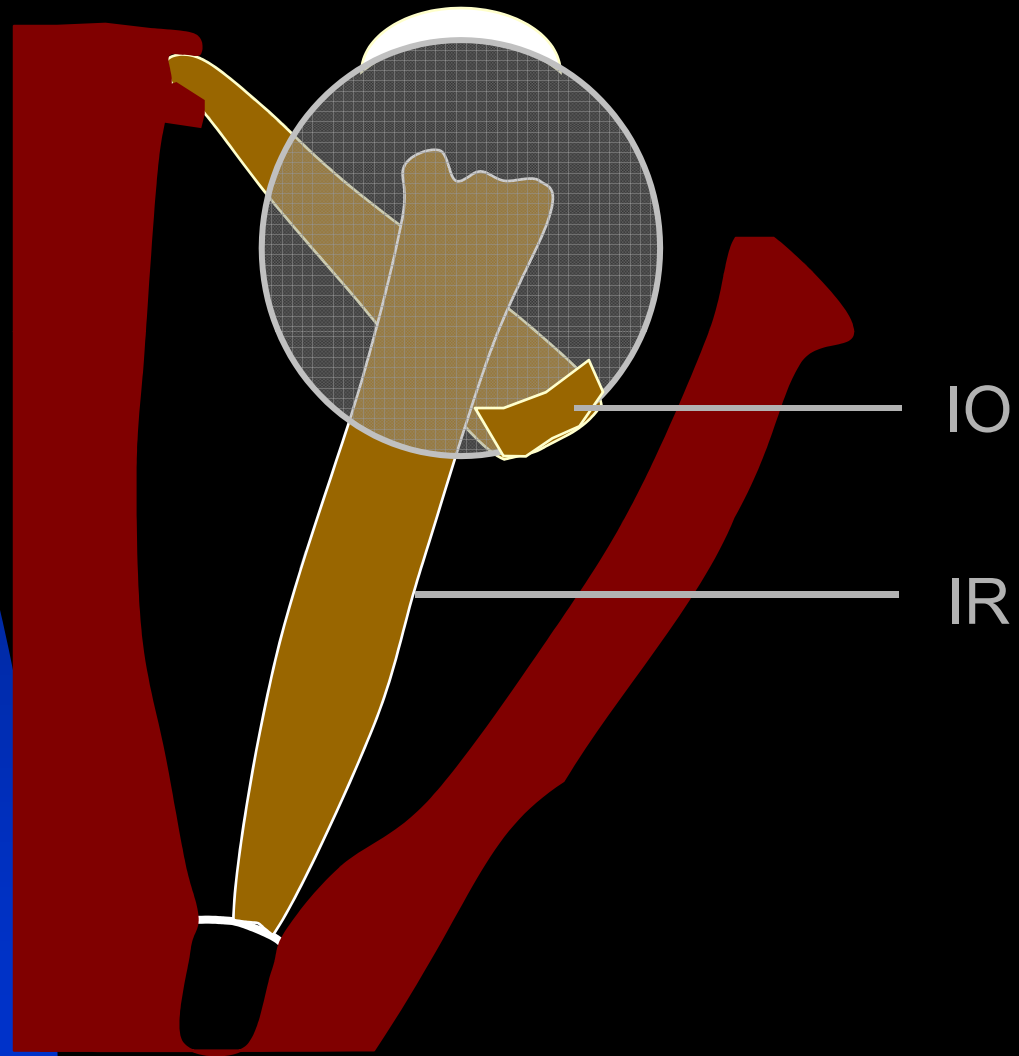




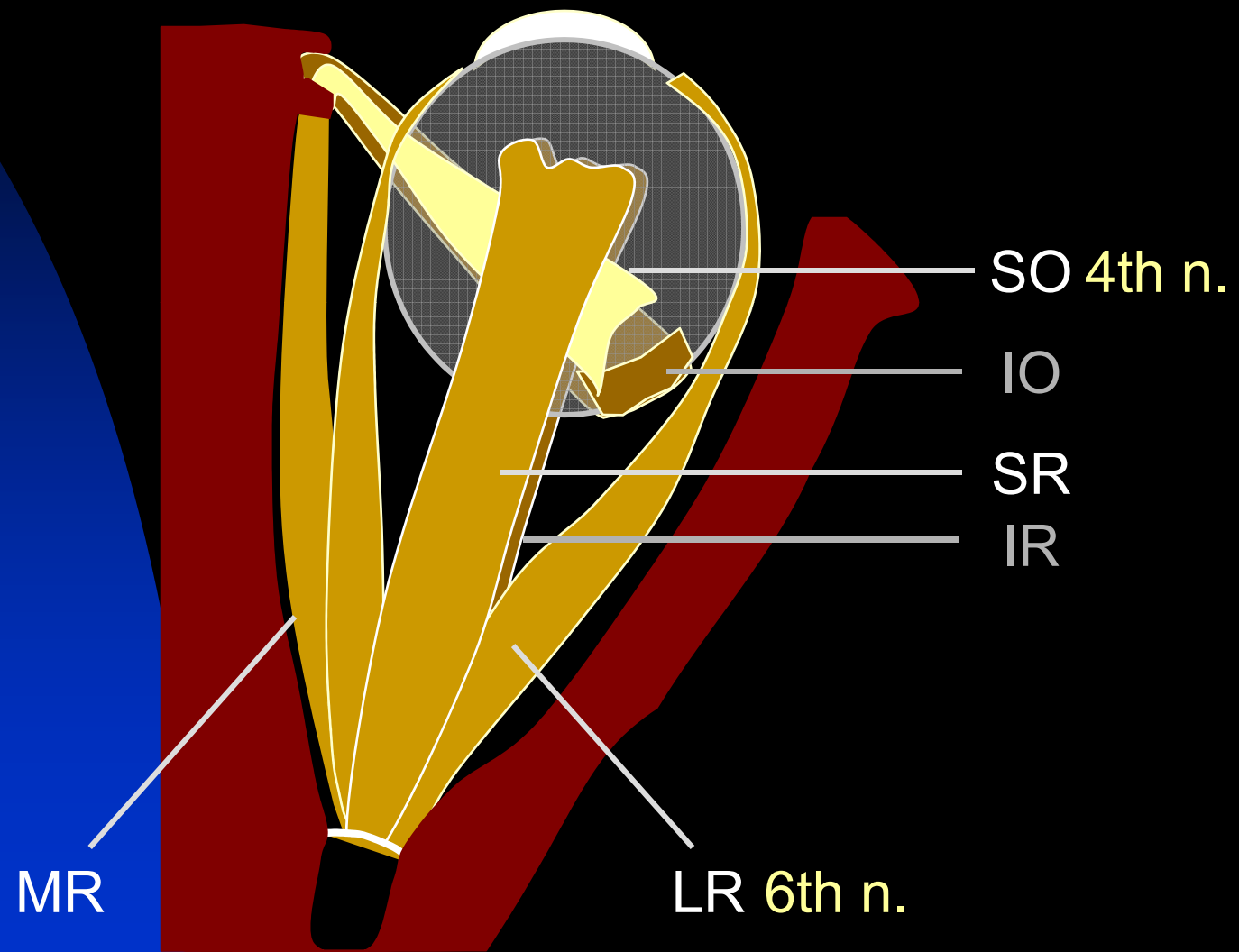


**3rd, 4th, 6th cranial nerves**

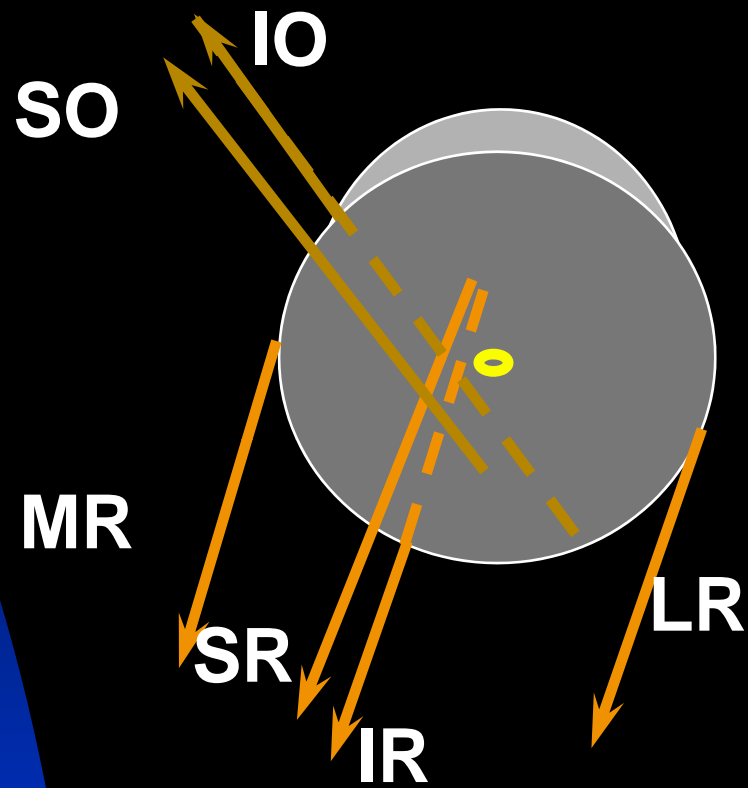
# Attachment of eye muscles:



# Attachment of eye muscles:




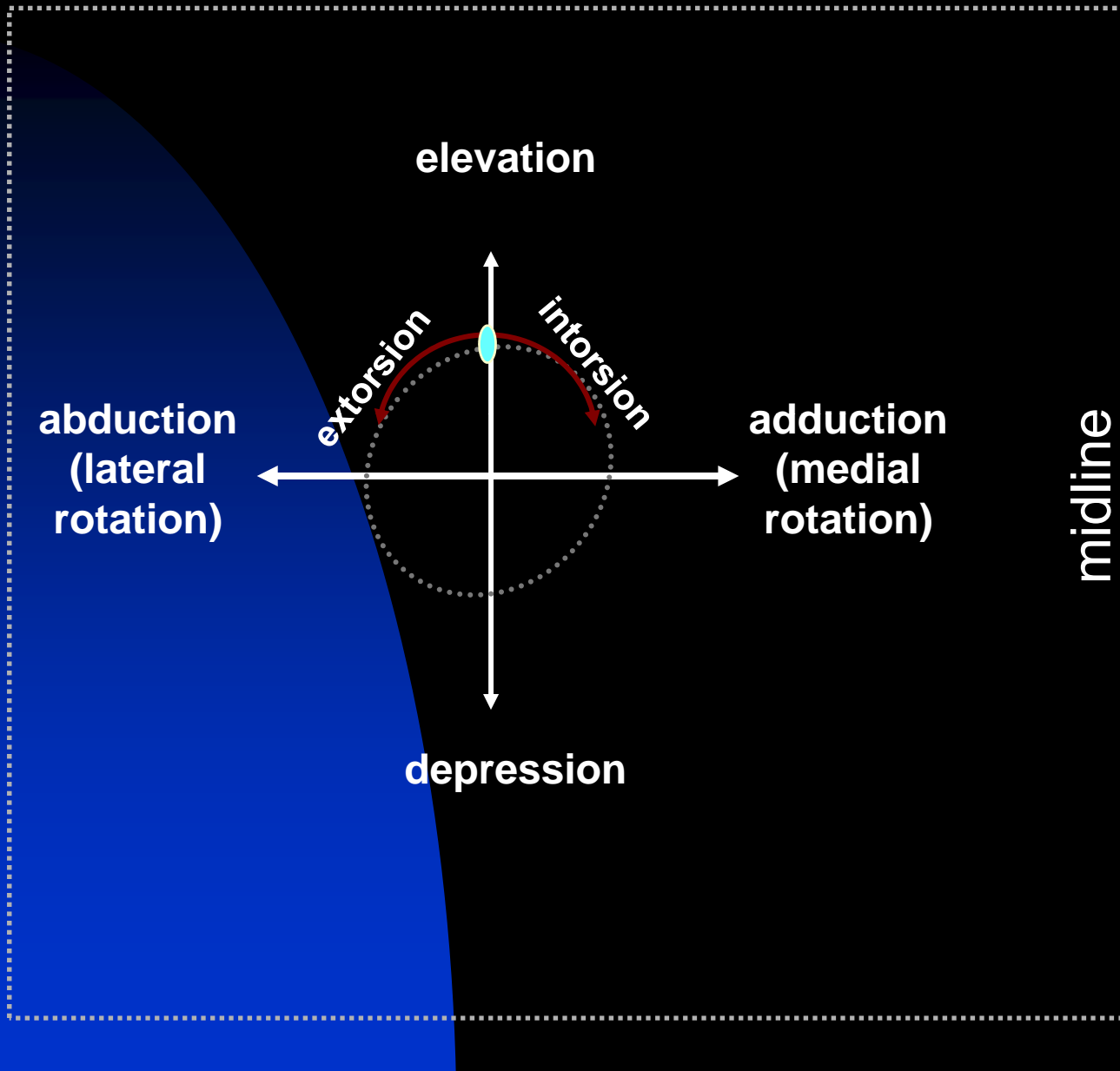
# Attachment of eye muscles:



*(View from above)*

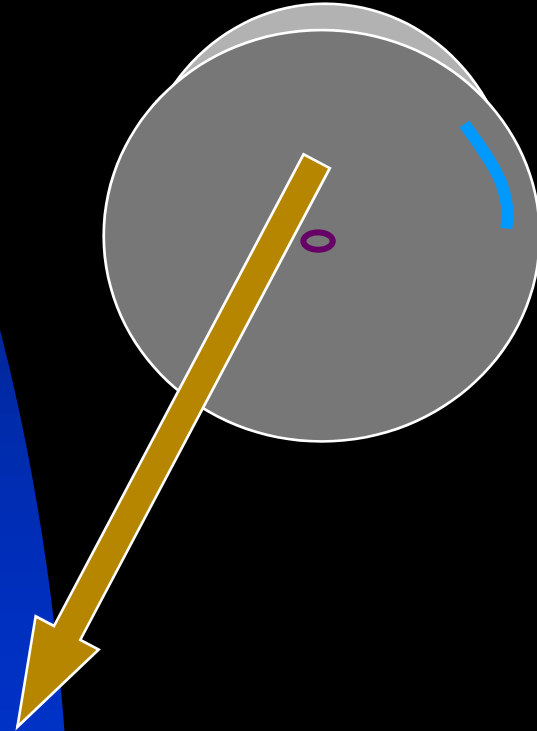


# Innervation & action of eye muscles:







## Deduction of action from muscle attachment (E.g.: SR)

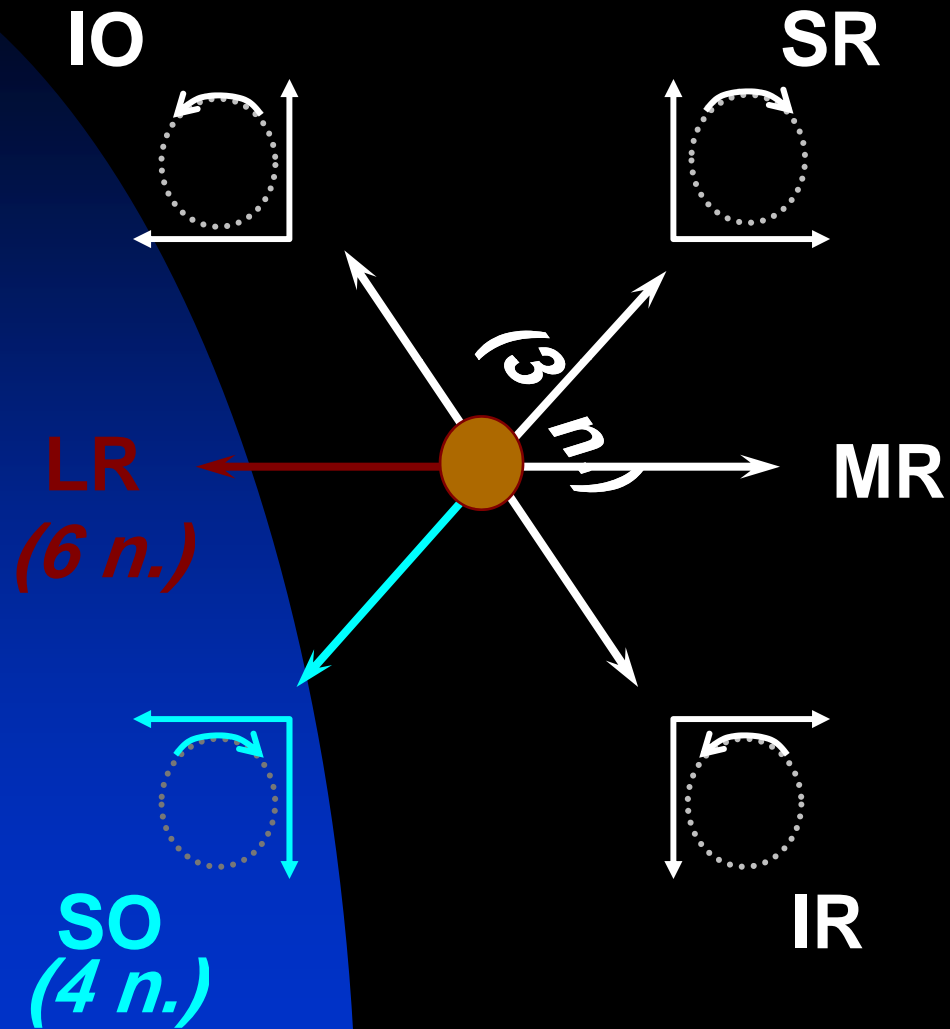


*(View from above)*

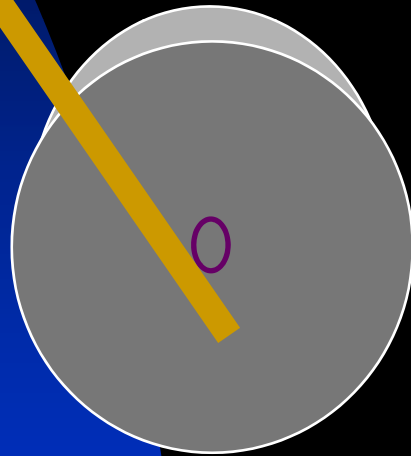




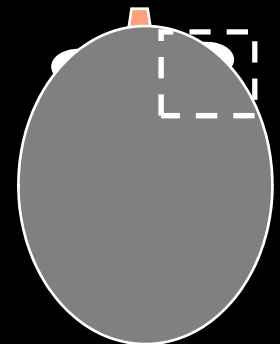
# Innervation & action of eye muscles:





Person to look *medially* & down




*head, from above*



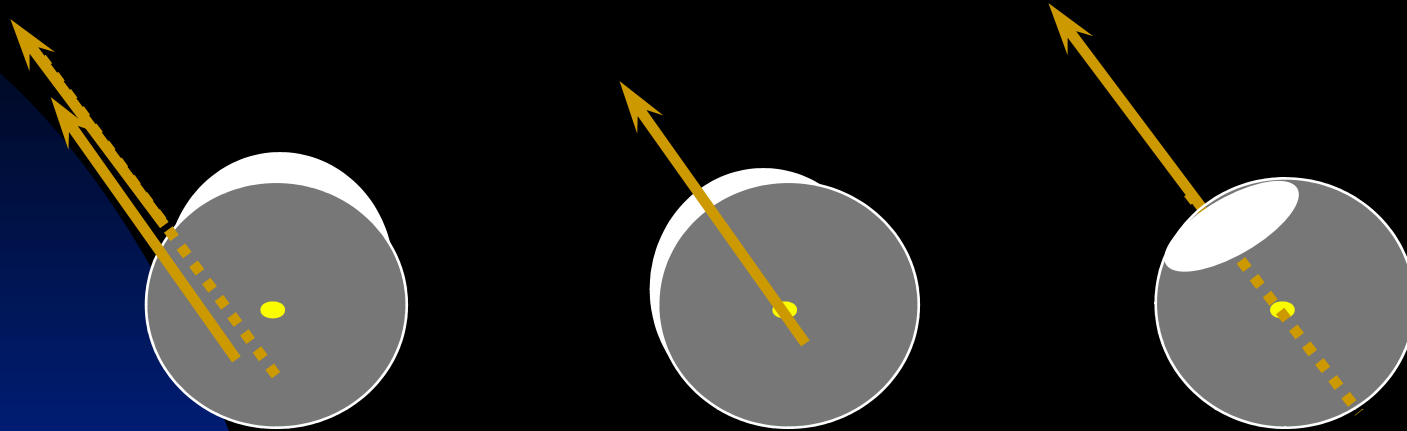




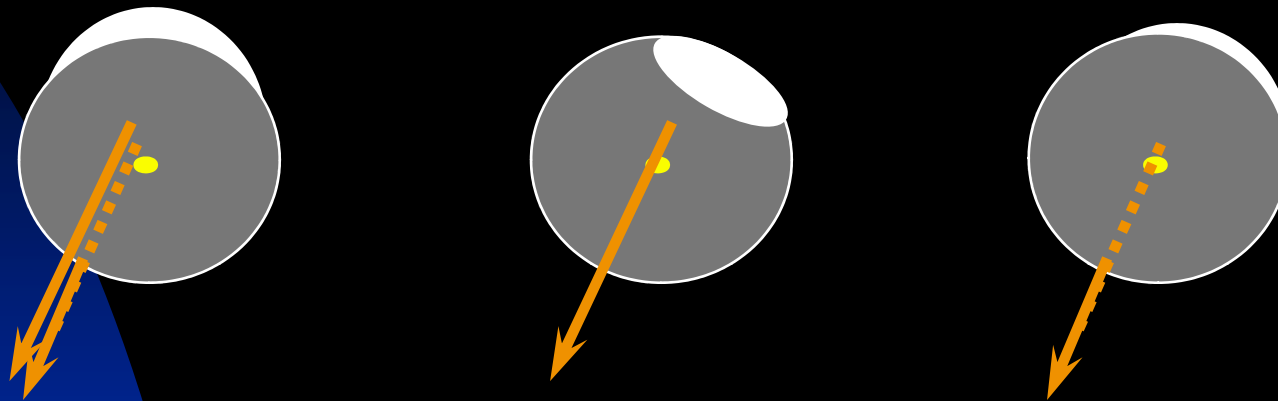




Hence:



- **When eye is adducted:**
  - SO is almost a pure depressor  
*(IV n.)*
  - IO is almost a pure elevator  
*(III n.)*  
*They pull through the centre*



- **When eye is abducted:**
  - SR is almost a pure elevator
  - IR is almost a pure depressor

*They pull through the centre*

## Hence for clinical test :

- SO
- IO
- SR
- IR

### Direction to look

**Down and in**

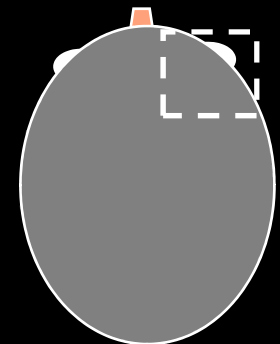
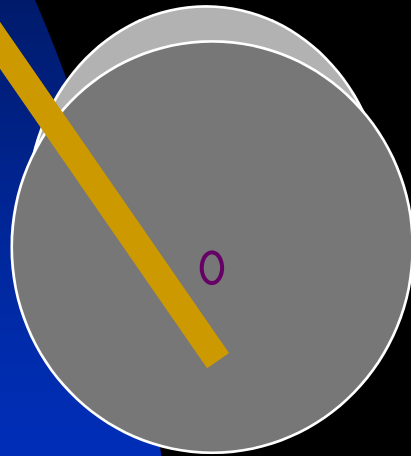
**Up and in**

**Up and out**

**Down and out**


# How does SO (4th n.) pull the eyeball ?


Person to look *laterally* & down




*head, from above*

*this part of SO is tendinous* NHK CUHK 98

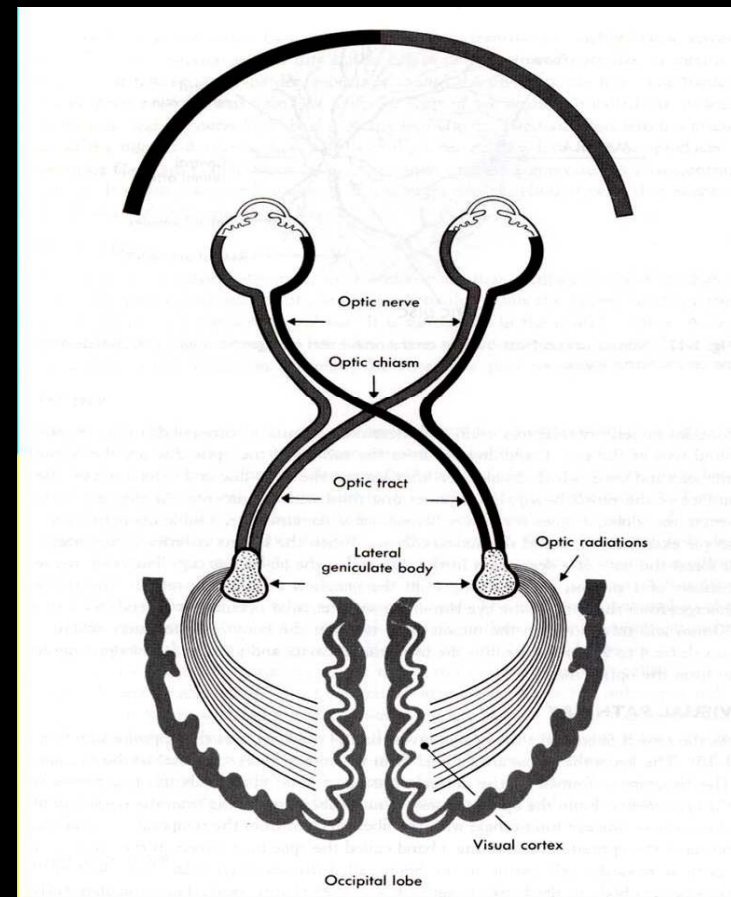






# The Visual Pathway

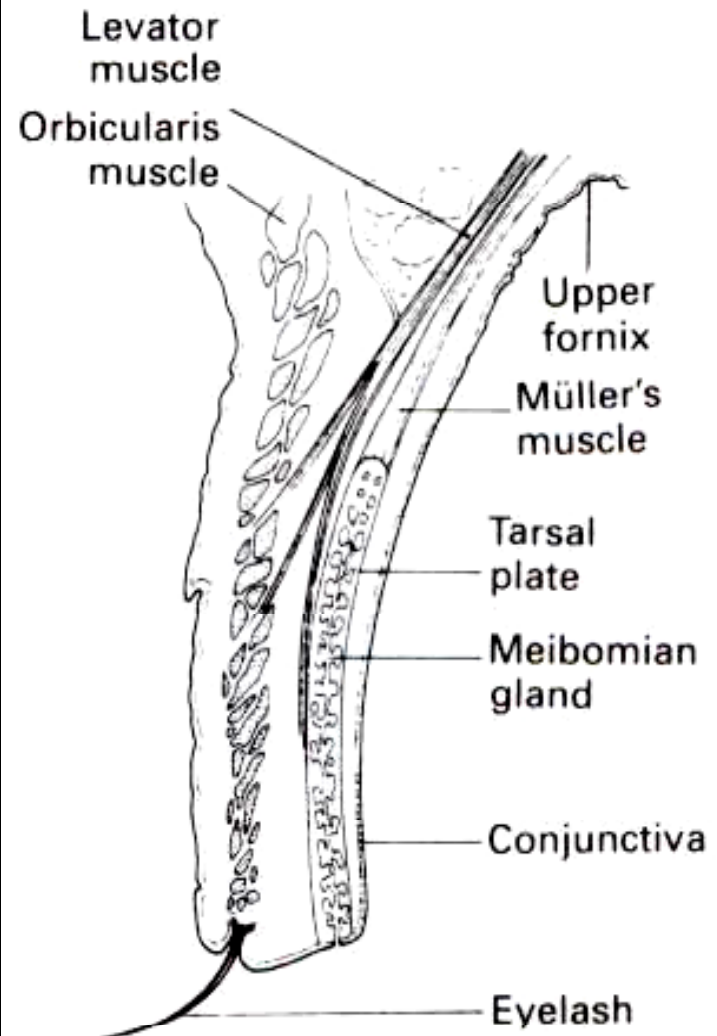
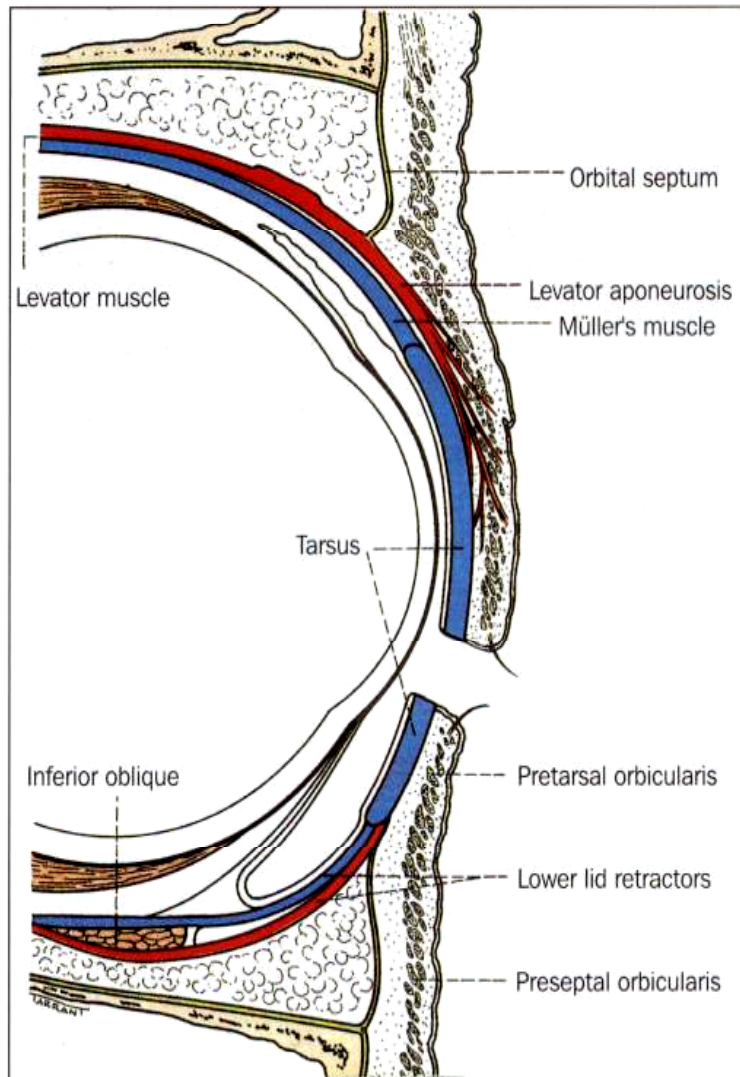
- Visual Pathway: Three neurons
  1. Bipolar cell, lies within the retina.
  2. Ganglion cell, synapse in lateral geniculate body.
  3. Third neuron terminates in visual cortex.





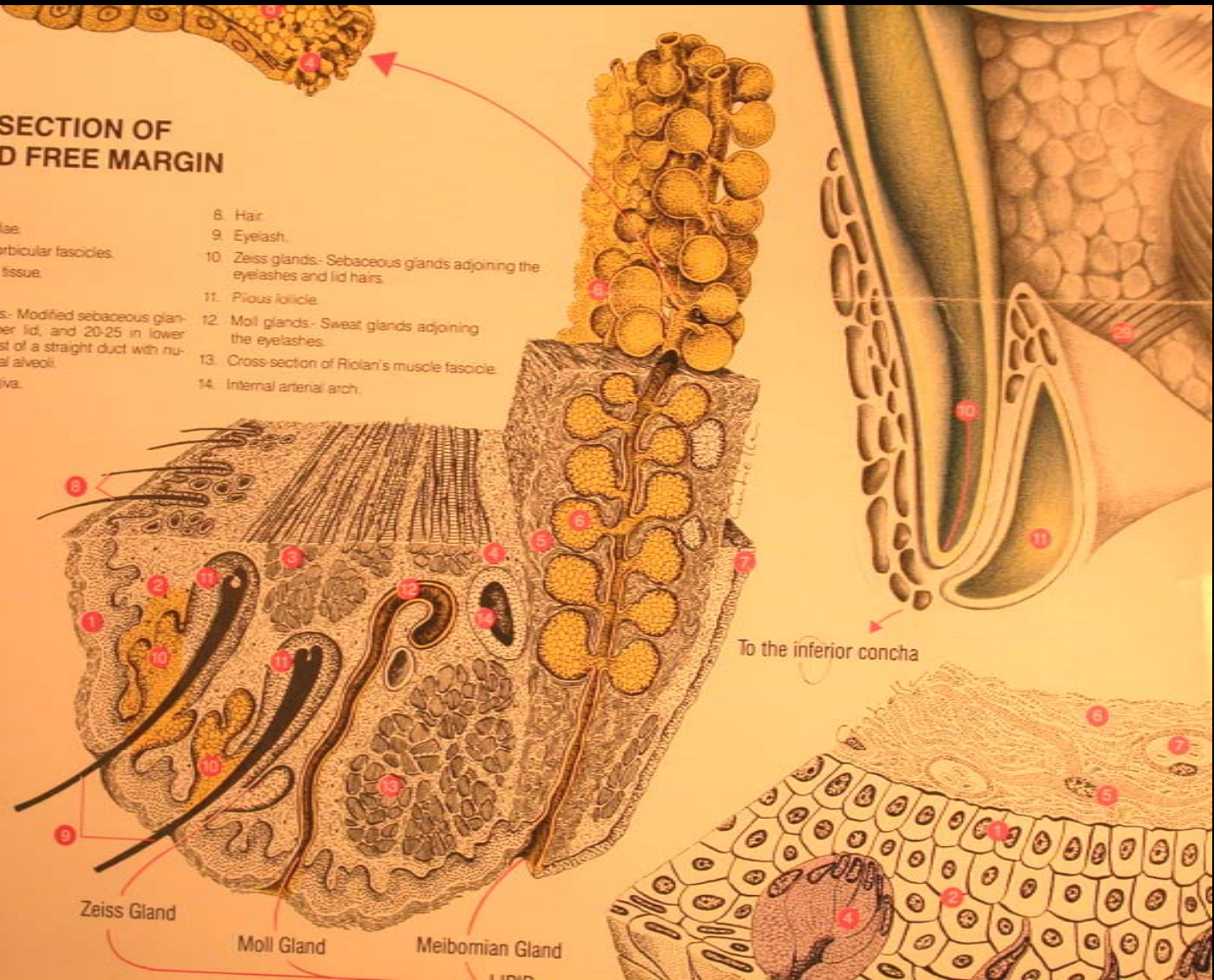
# THE EYELIDS

- They provide a protective covering for the eye.
- The lids are closed by Orbicularis oculi muscle (Facial n.) and opened with Levator palpebrae muscle (Oculomotor n.), Muller's muscle (Sympathetic supply) & Lower lid retractors.



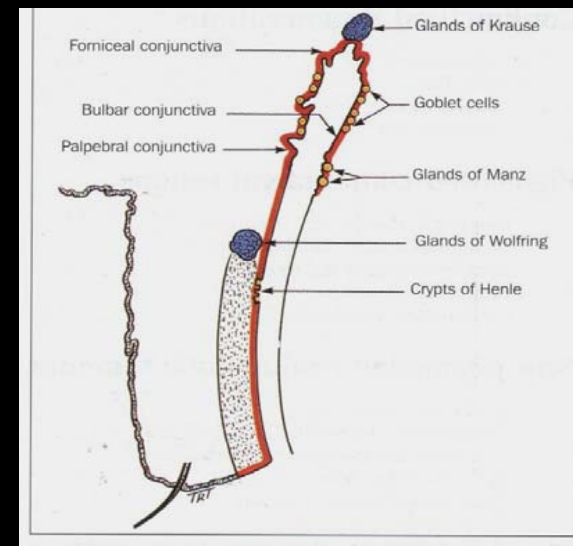
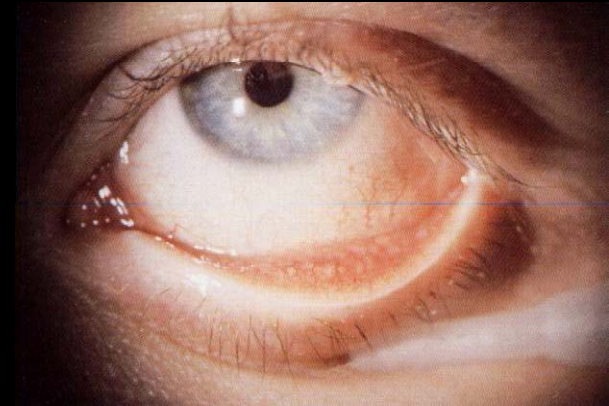
## SAGITAL SECTION OF UPPER LID FREE MARGIN

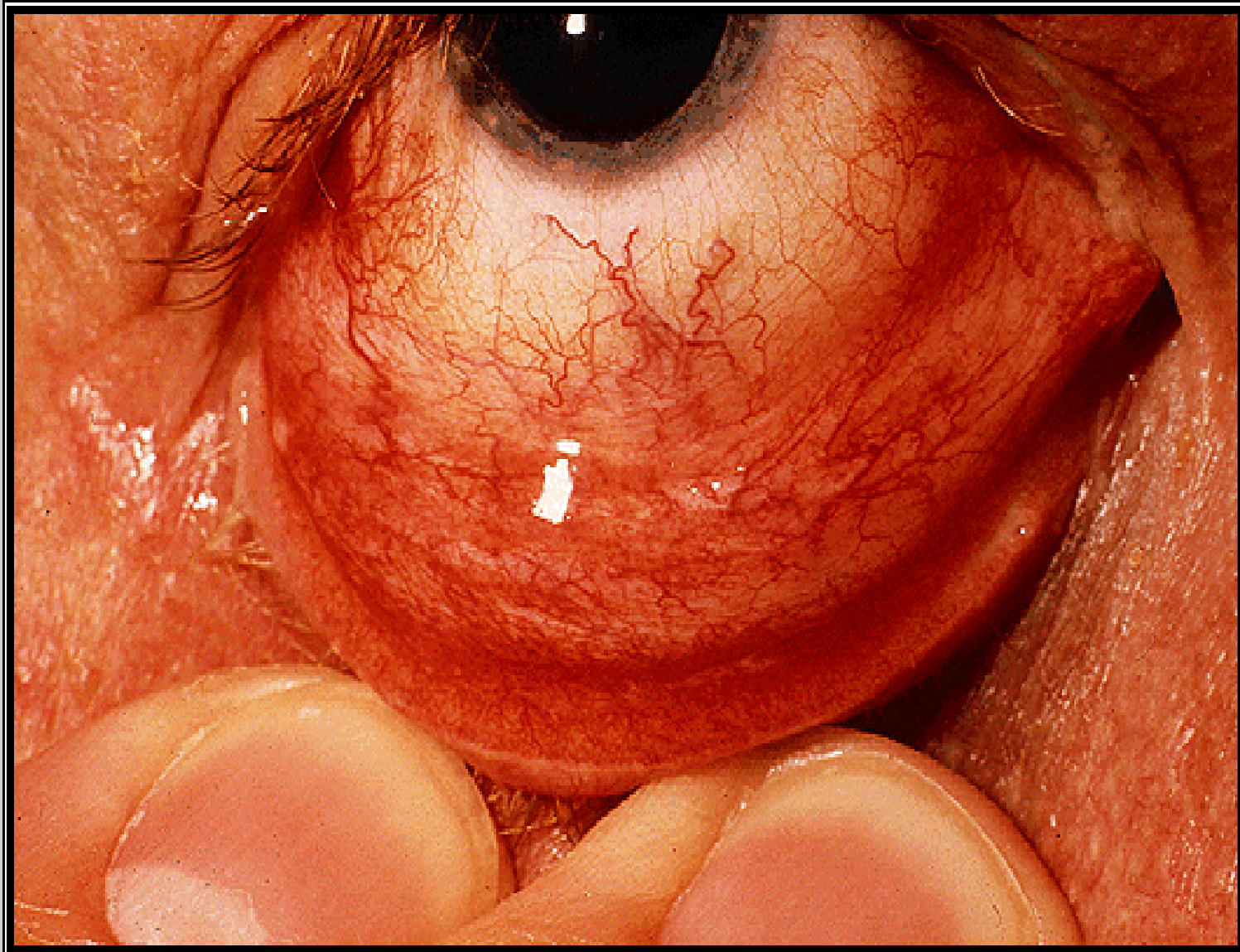
- |   |  |
|---|--|
| 1. Epidermis.   | 8. Hair.   |
| 2. Dermis with papillae.  | 9. Eyelash.  |
| 3. Cross-section of orbicular fascicles.  | 10. Zeiss glands.- Sebaceous glands adjoining the eyelashes and lid hairs. |
| 4. Submuscular cell tissue.   | 11. Piloeris follicle.   |
| 5. Tarsus.  | 12. Moll glands.- Sweat glands adjoining the eyelashes.                    |
| 6. Meibomian glands.- Modified sebaceous glands (25-30 in upper lid, and 20-25 in lower one), which consist of a straight duct with numerous small lateral alveoli. | 13. Cross-section of Riolan's muscle fascicle.                             |
| 7. Palpebral conjunctiva.   | 14. Internal arterial arch.  |

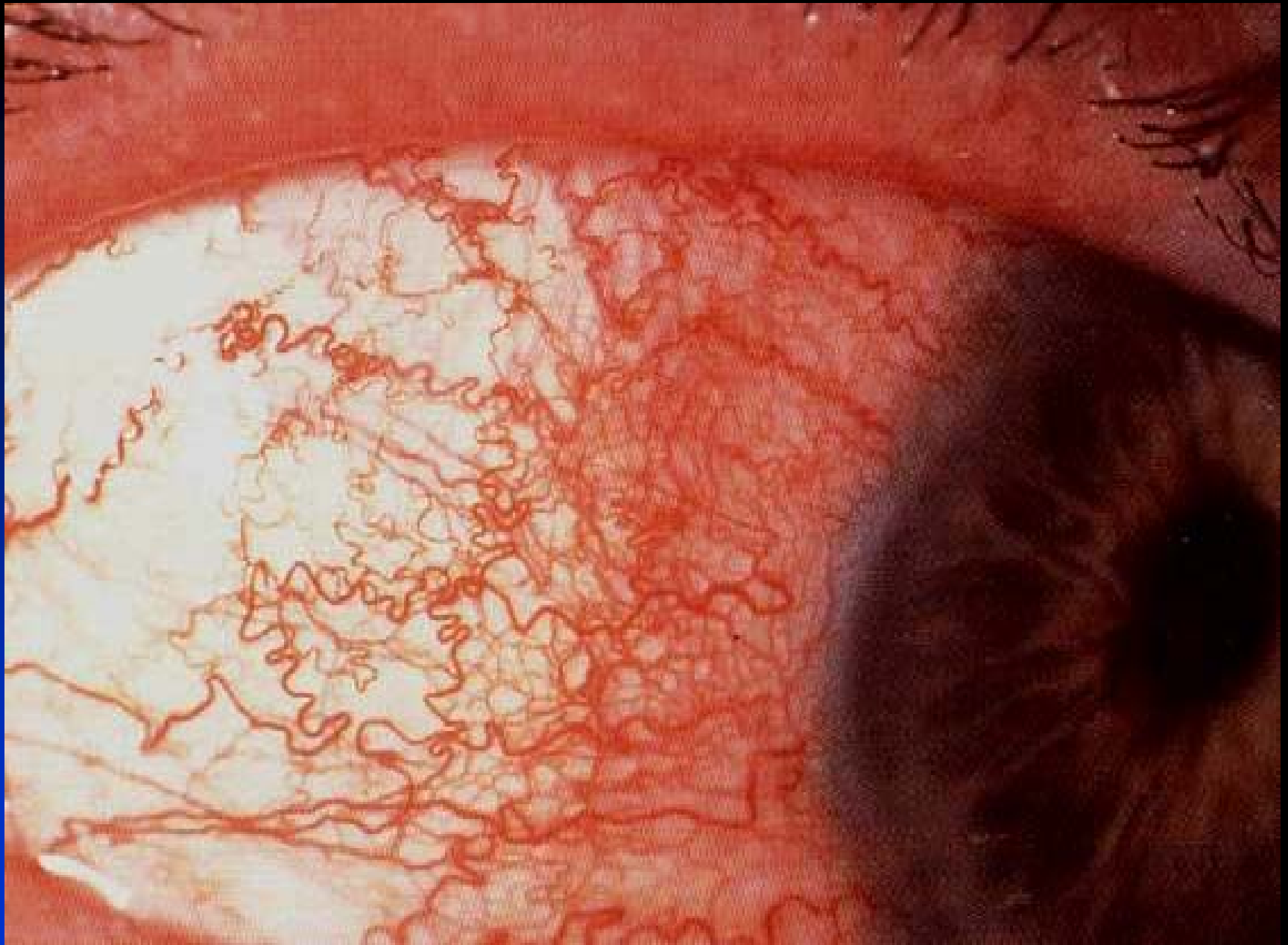


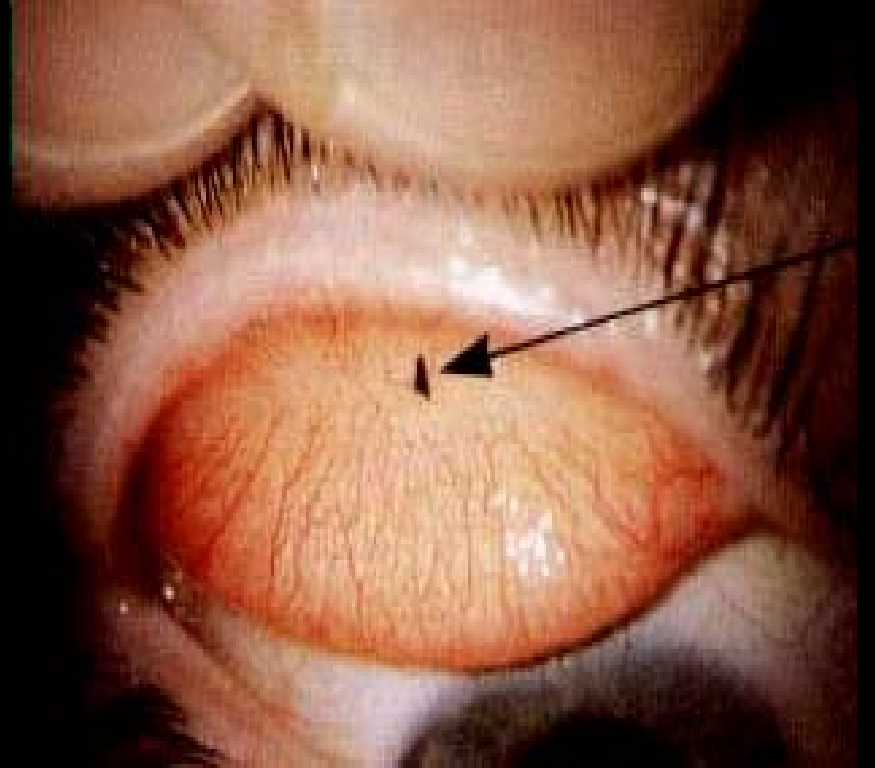
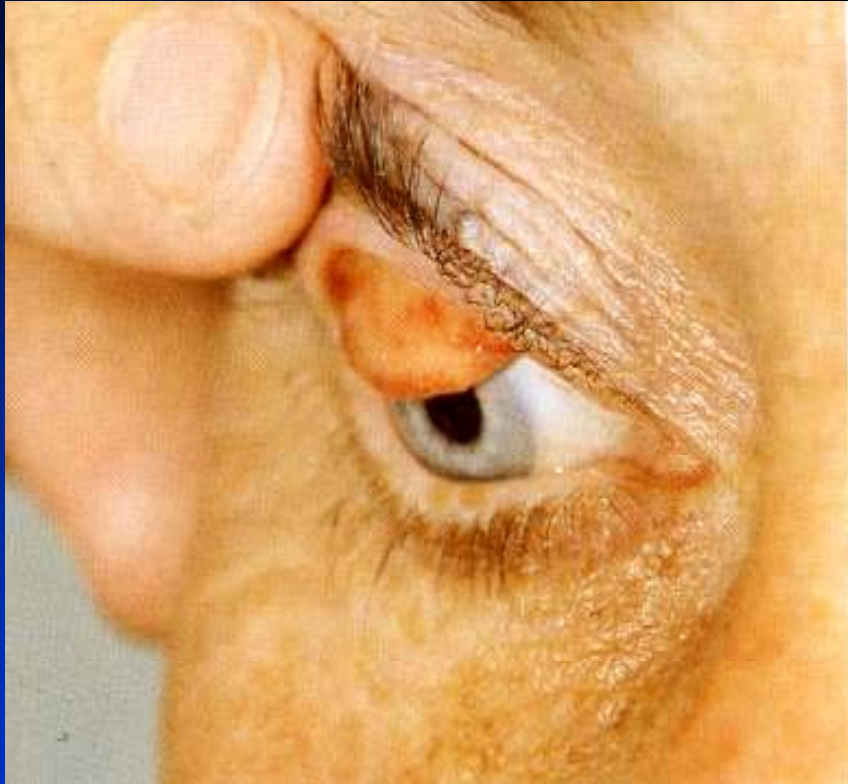# CONJUNCTIVA

- **Three parts:**
  1. Bulbar conjunctiva.
  2. Palpebral conjunctiva.
  3. Forniceal conjunctiva.
- **The stroma (no adenoid tissues until 3 months after birth).**
- **Follicles & Papillae.**
- **Injection and chemosis.**
- **Limbus.**





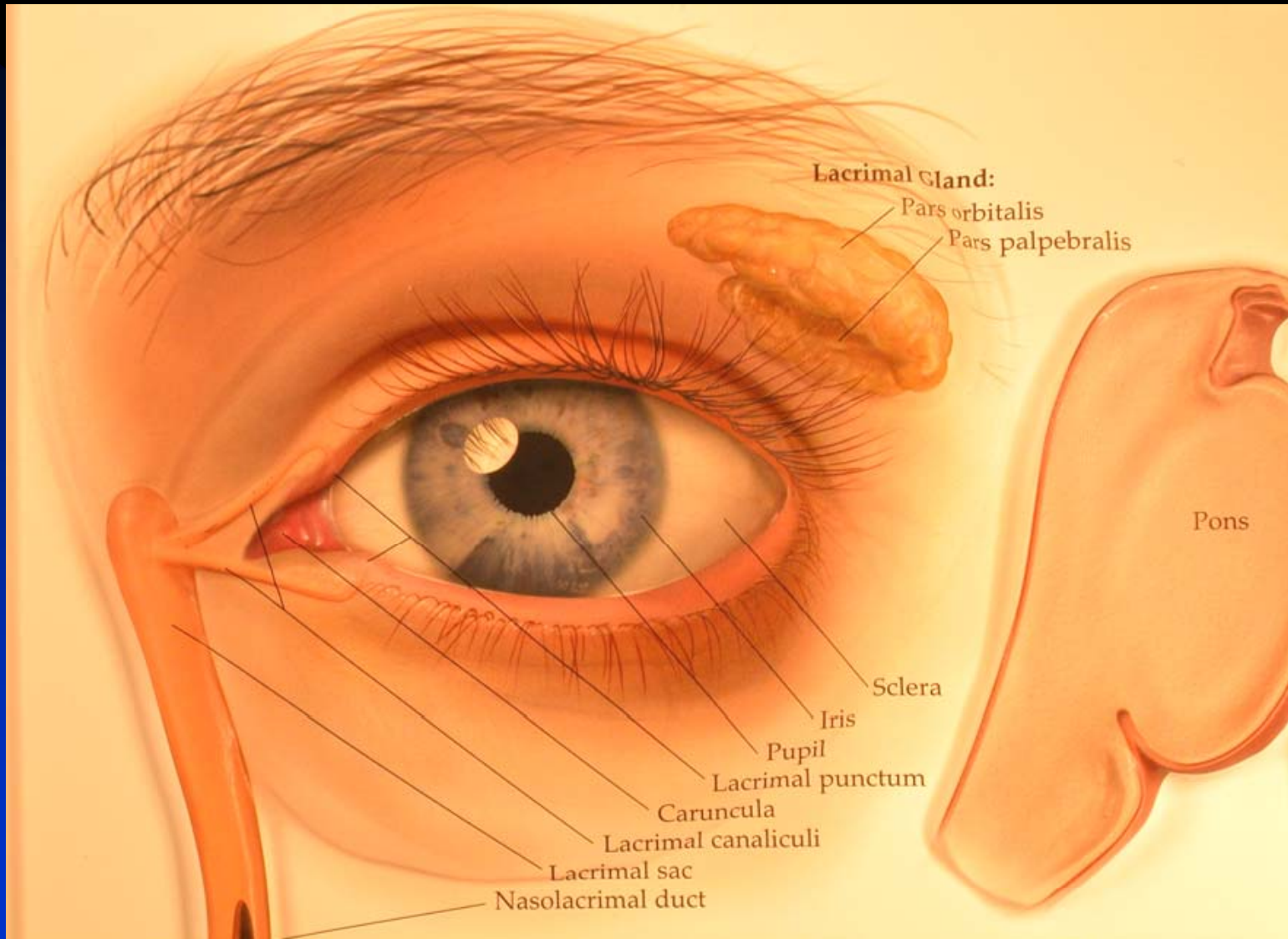


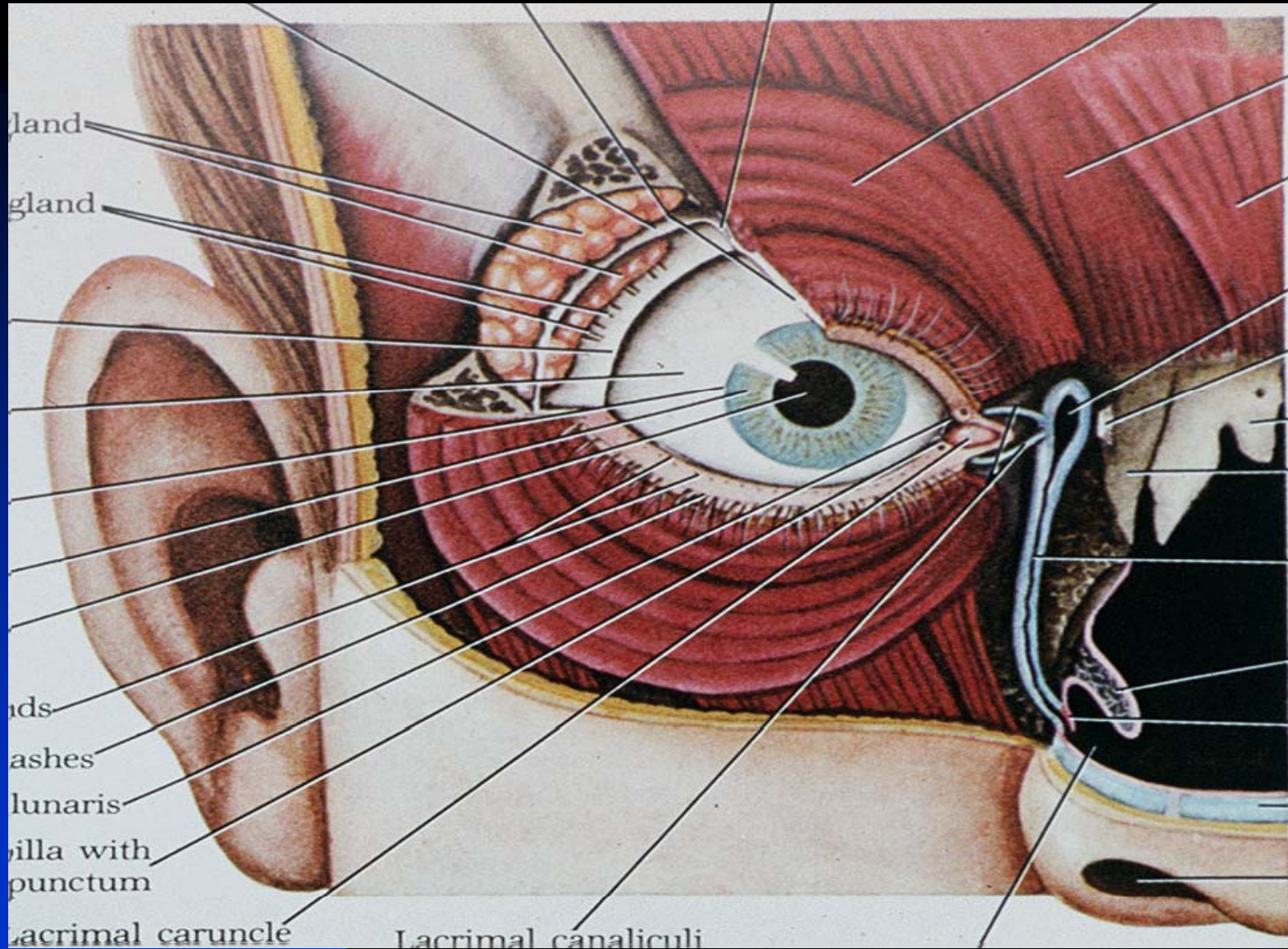


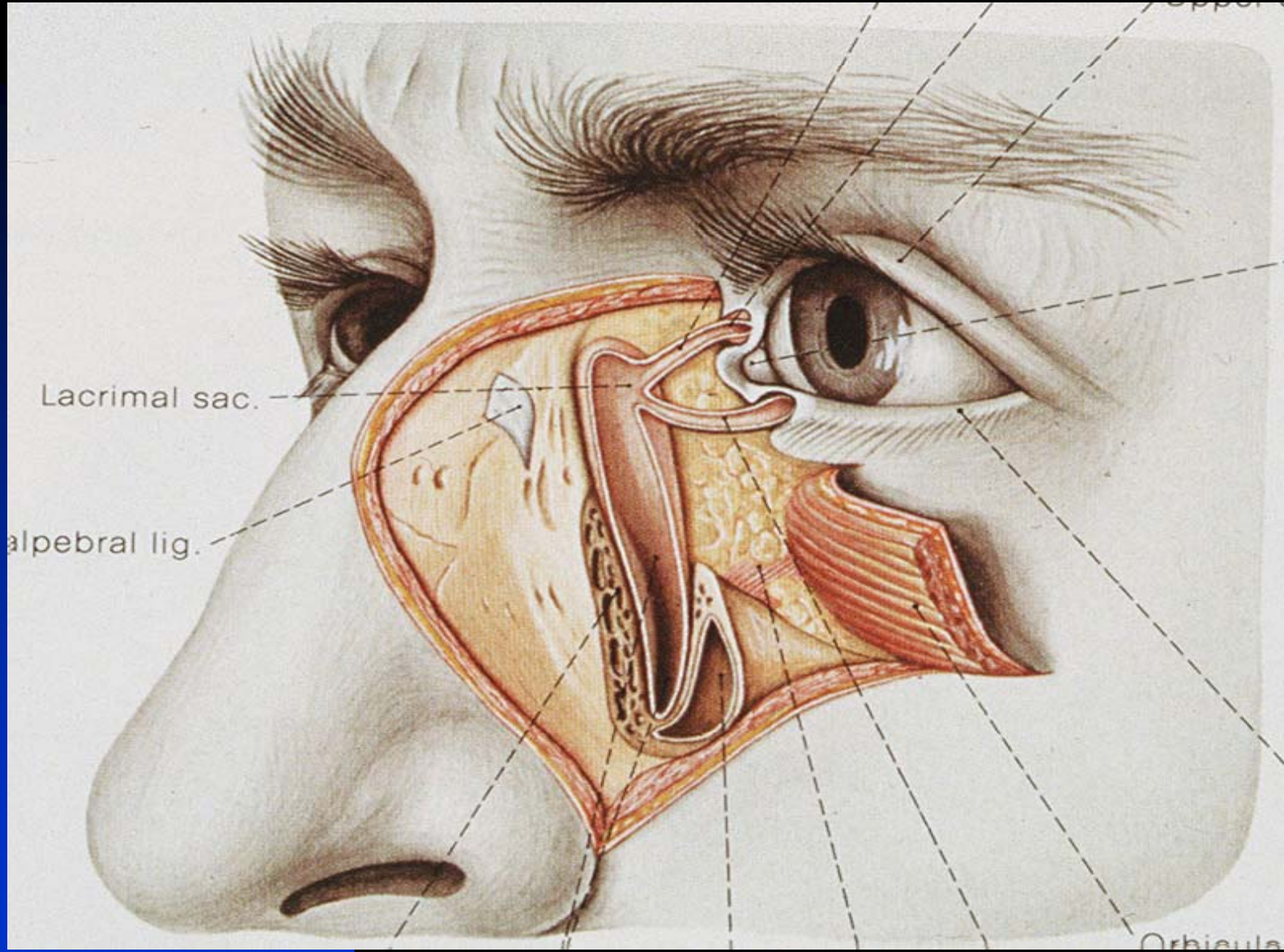
# *THE LACRIMAL APPARATUS*

- Lacrimal gland secretes tears into the upper fornix of the conjunctival sac which are spread over the surface of the cornea as a tear film by blinking of the lids.
- Tears accumulate at the inner canthus and drain into the lacrimal sac via the puncta & canaliculi.
- The sac is continuous inferiorly with the nasolacrimal duct which opens into the nasal cavity just beneath the inferior turbinate.





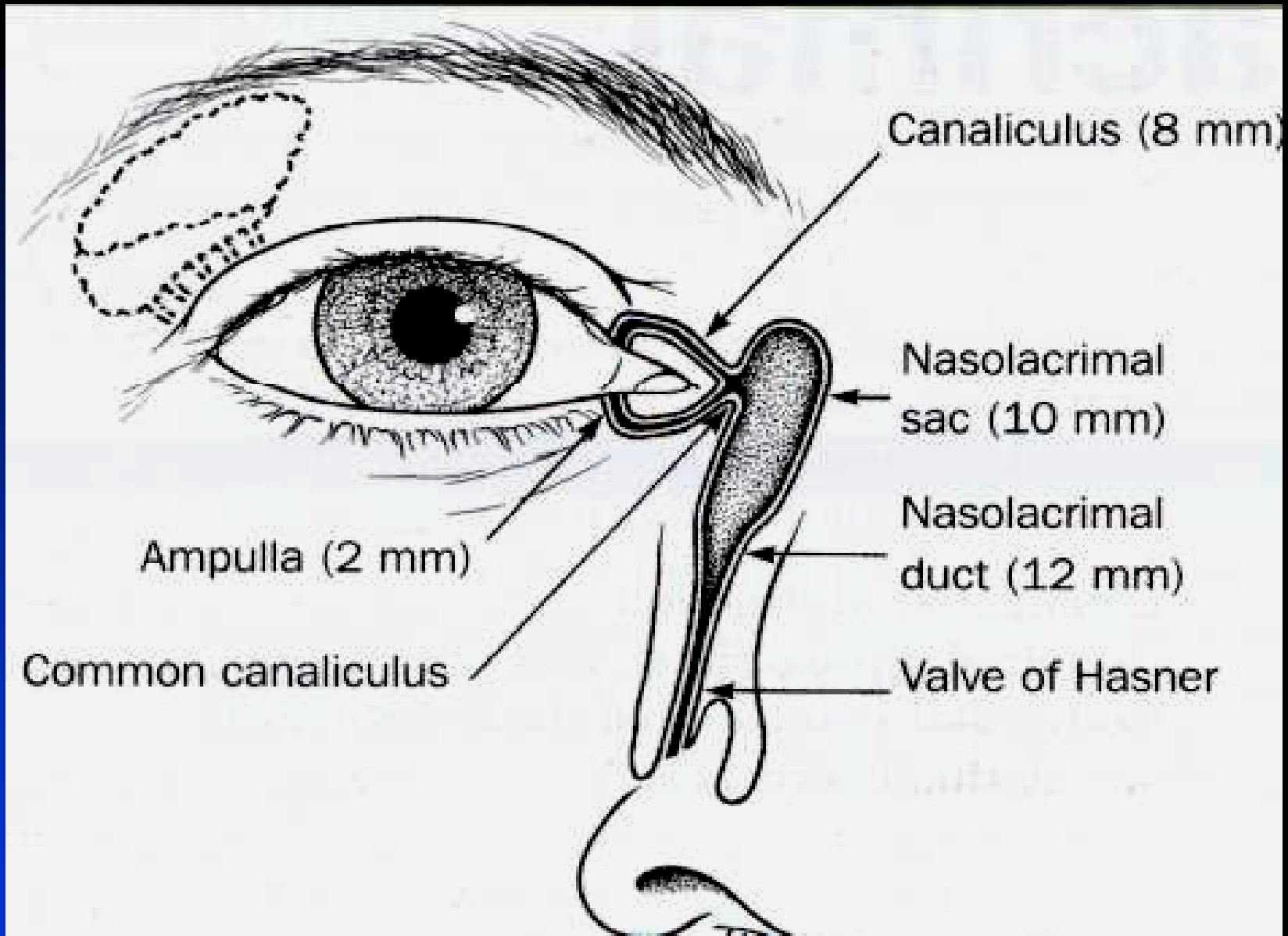




Lacrimal sac.

Alpebral lig.

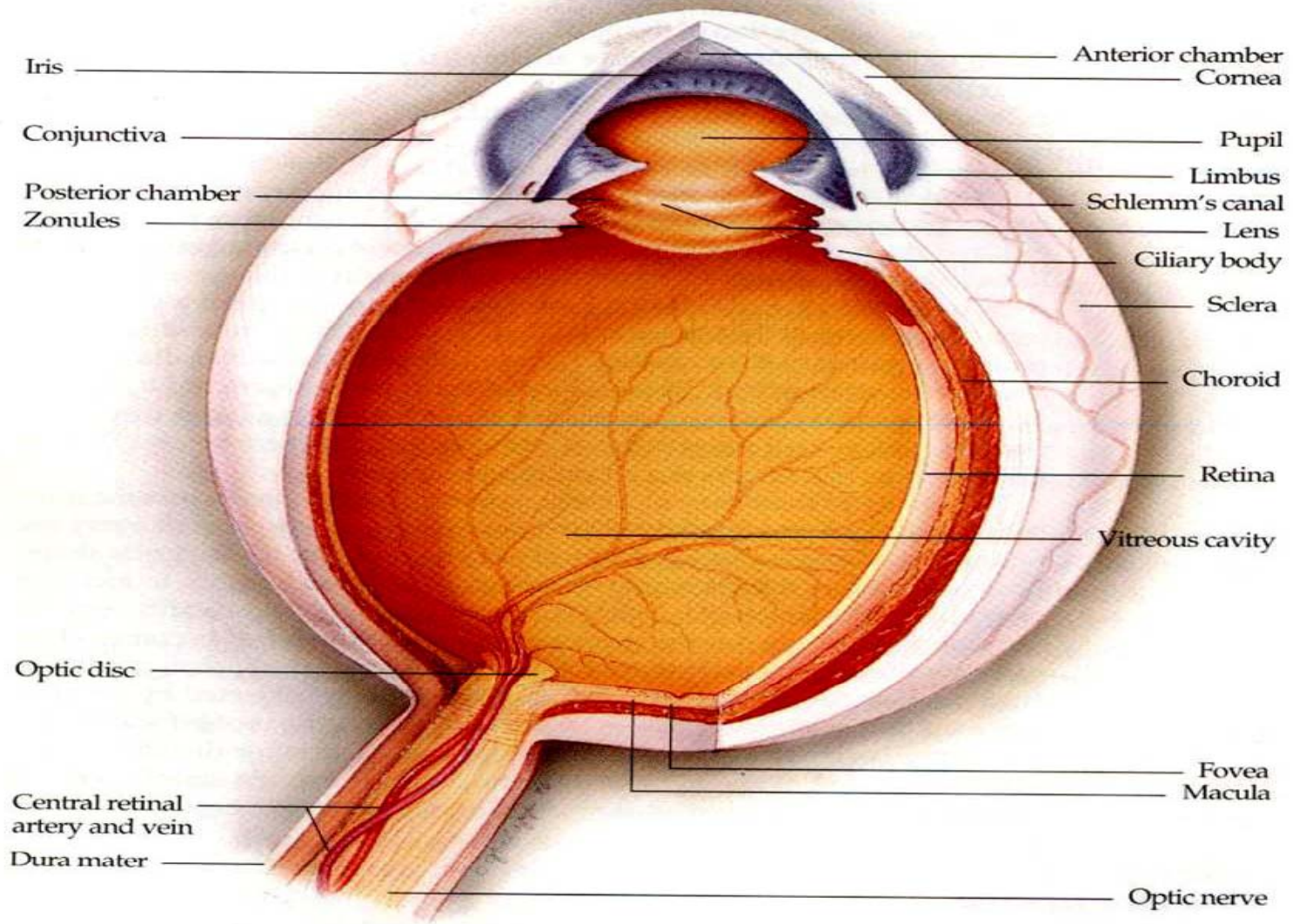
Orbicle



# THE EYE (GLOBE)

- Two spheres with different radii:
  - Cornea, window of the eye.
  - Sclera, opaque shell.

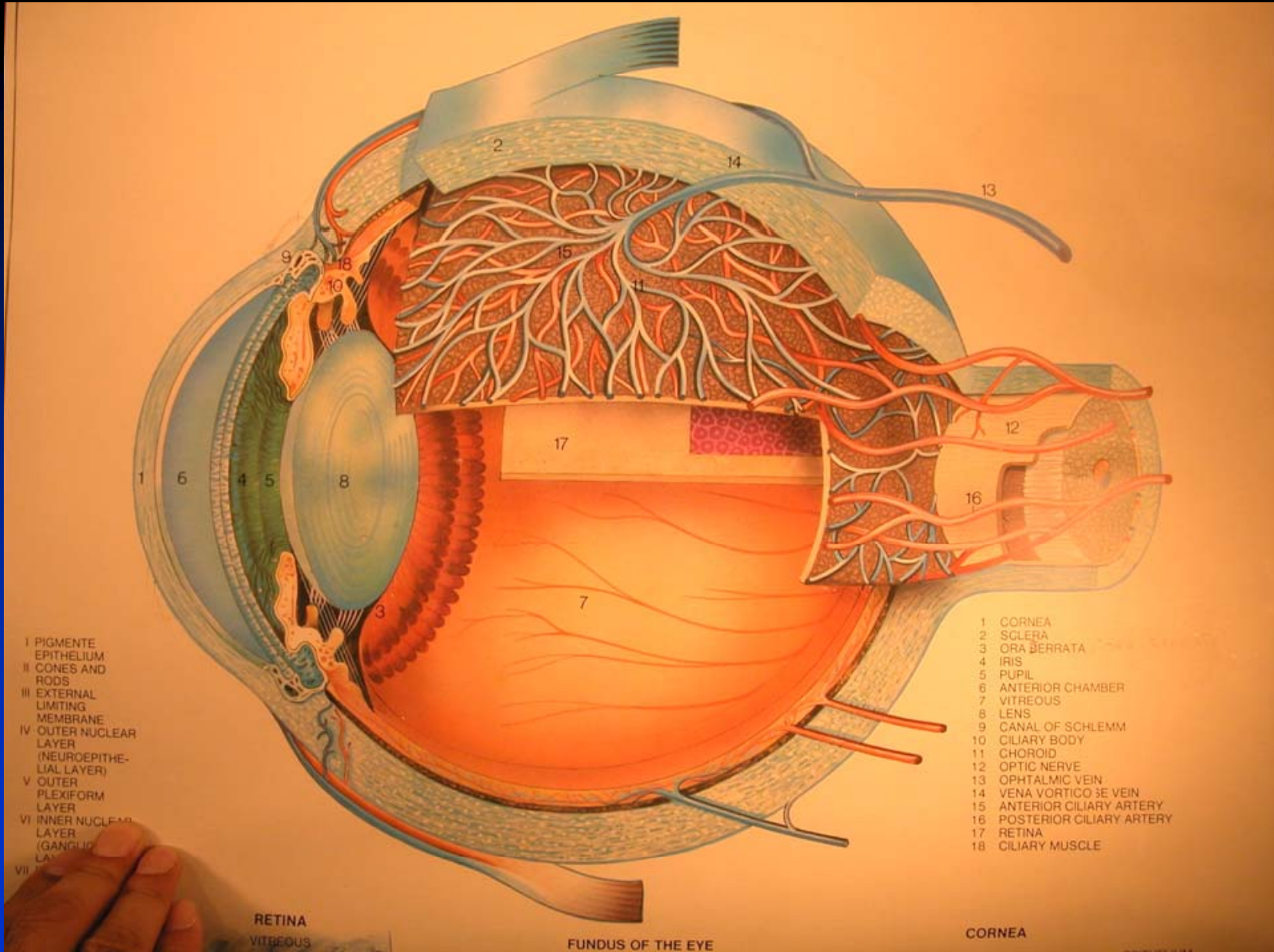
\*\*\* The eye measures approximately 24 mm in all its main diameters.



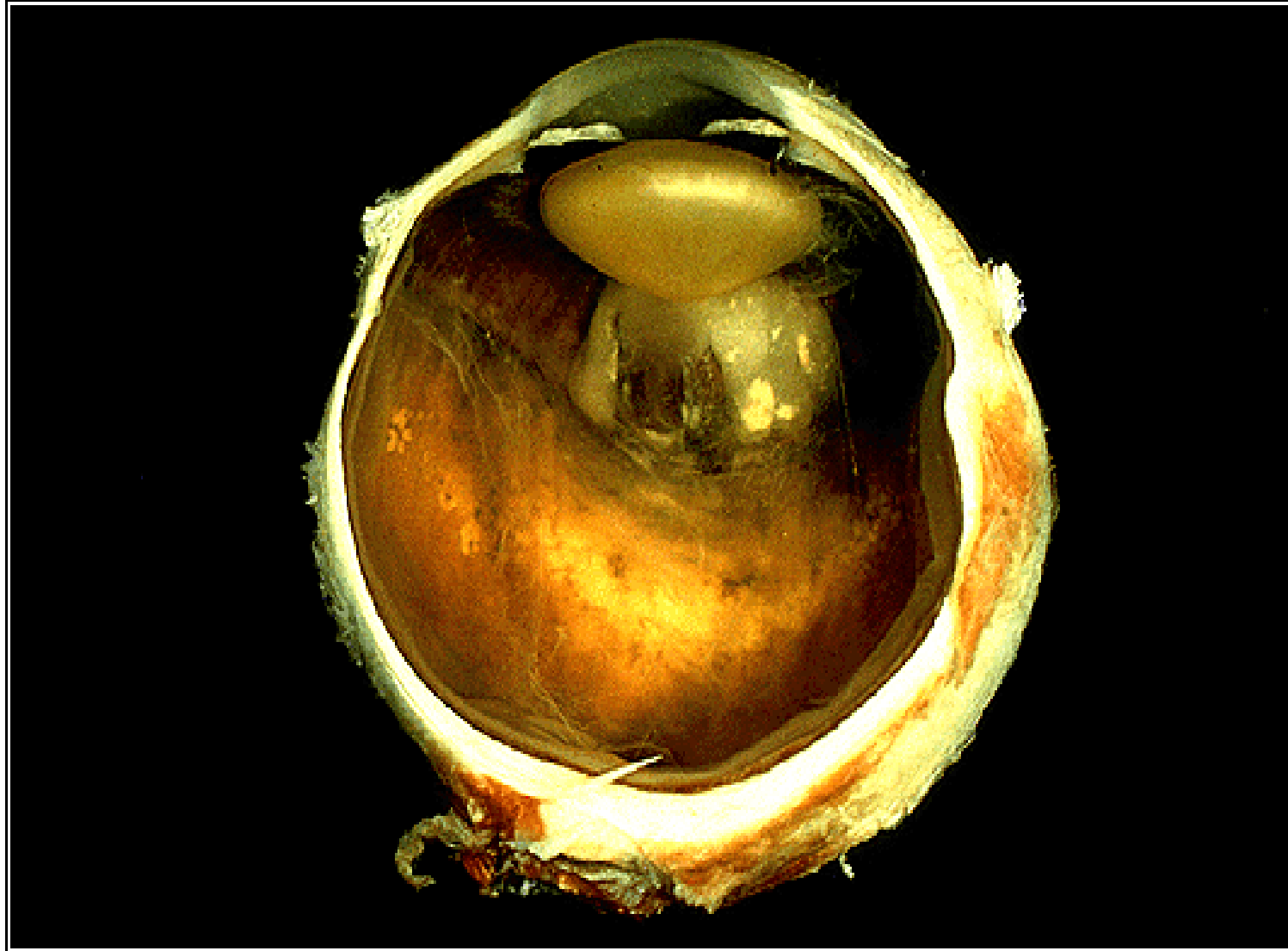
# The coats of the eye

## \*\*\* Three layers:

- The outer: inelastic coat, transparent cornea and opaque sclera.
- The middle, vascular coat, The Uvea: choroid, ciliary body and iris.
- The inner: The Retina, extends forwards to within 6 mm of the limbus.



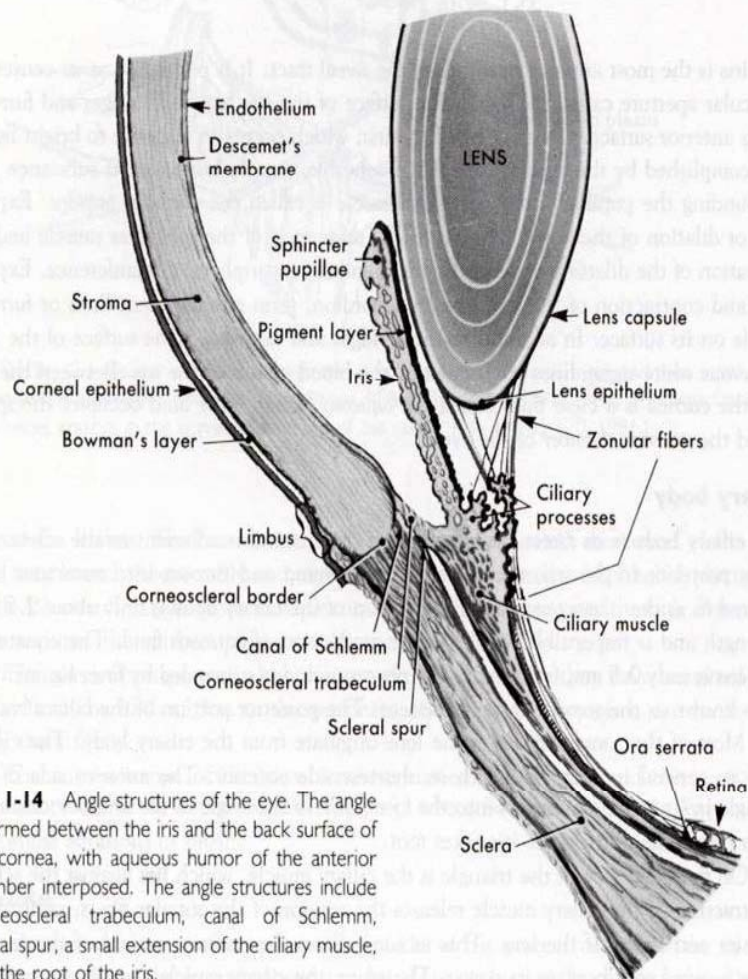




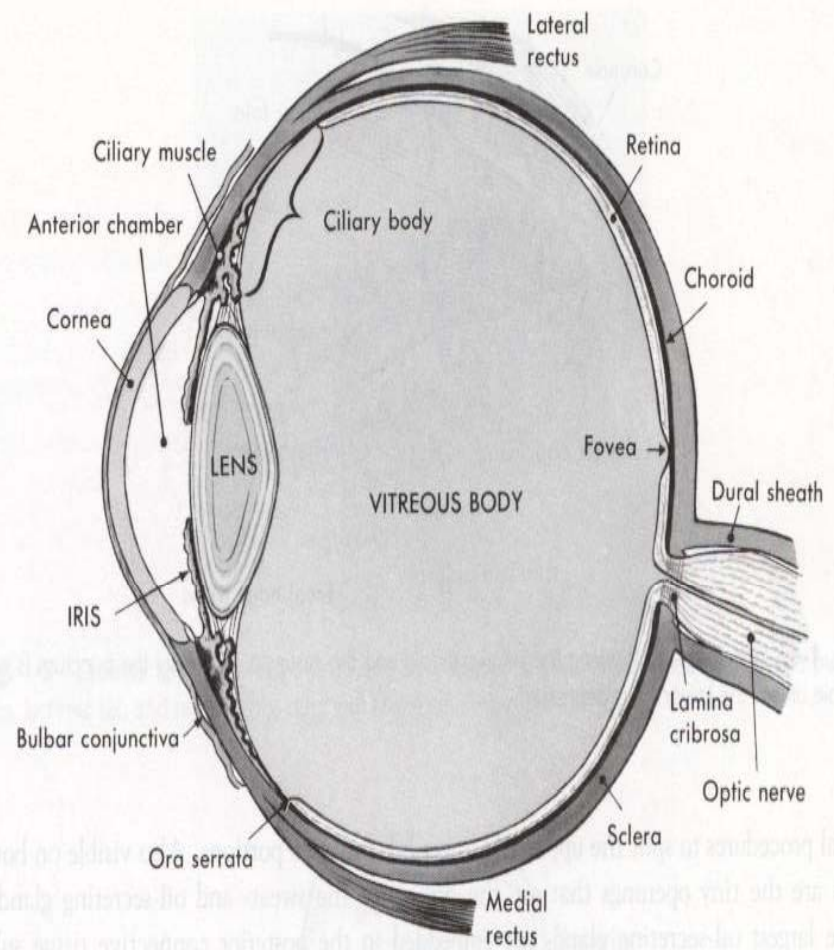
# The Chambers of The Eye


## **\*\*\*Three optically clear spaces:**

- The anterior chamber, in front of the iris
- The posterior chamber, immediately behind the iris. These two chambers which communicate through the pupil are filled with clear aqueous humour.
- The vitreous cavity: filled by gel-like structure, The Vitreous.



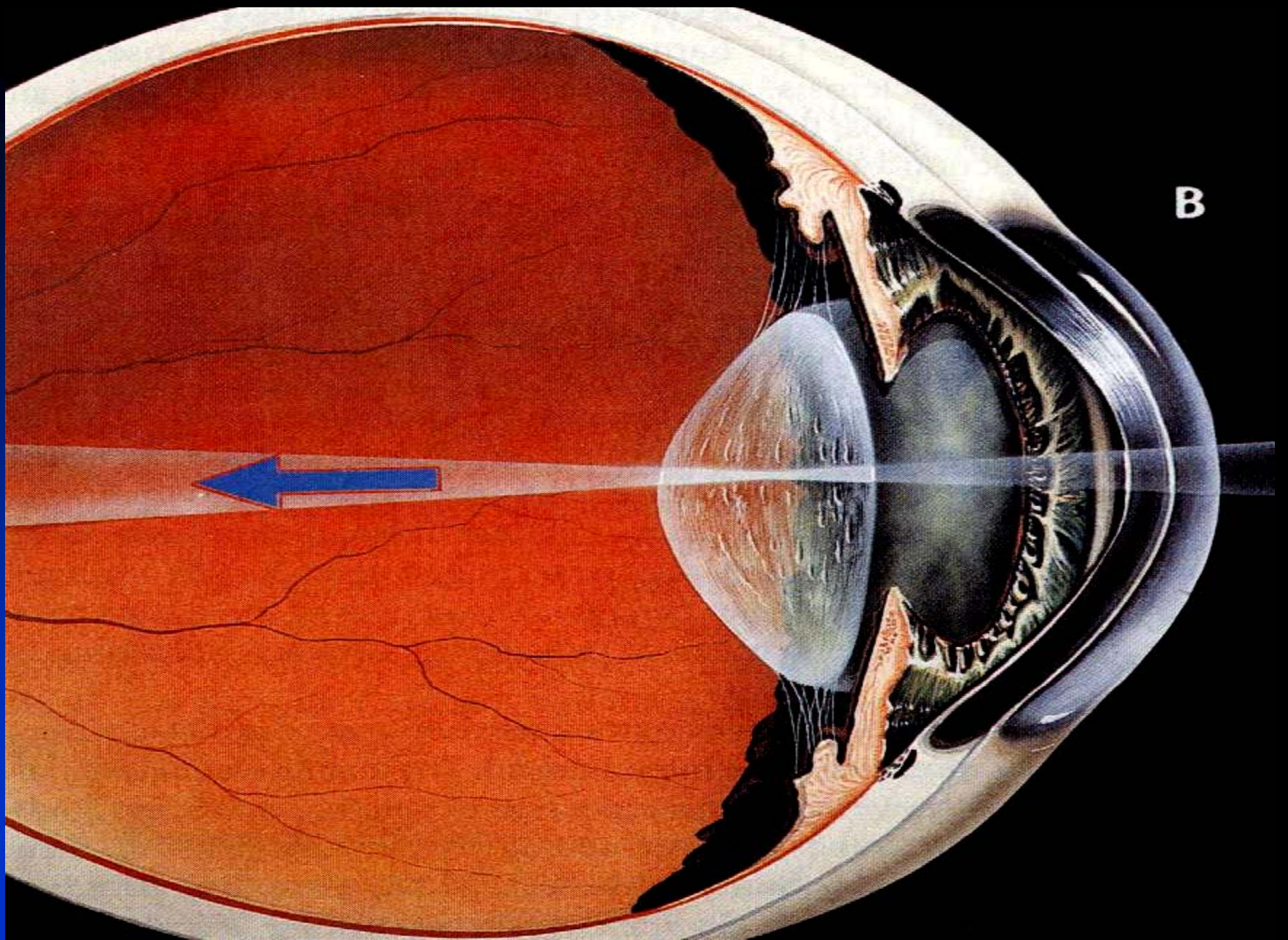
**Fig. 1-14** Angle structures of the eye. The angle is formed between the iris and the back surface of the cornea, with aqueous humor of the anterior chamber interposed. The angle structures include corneoscleral trabeculum, canal of Schlemm, scleral spur, a small extension of the ciliary muscle, and the root of the iris.

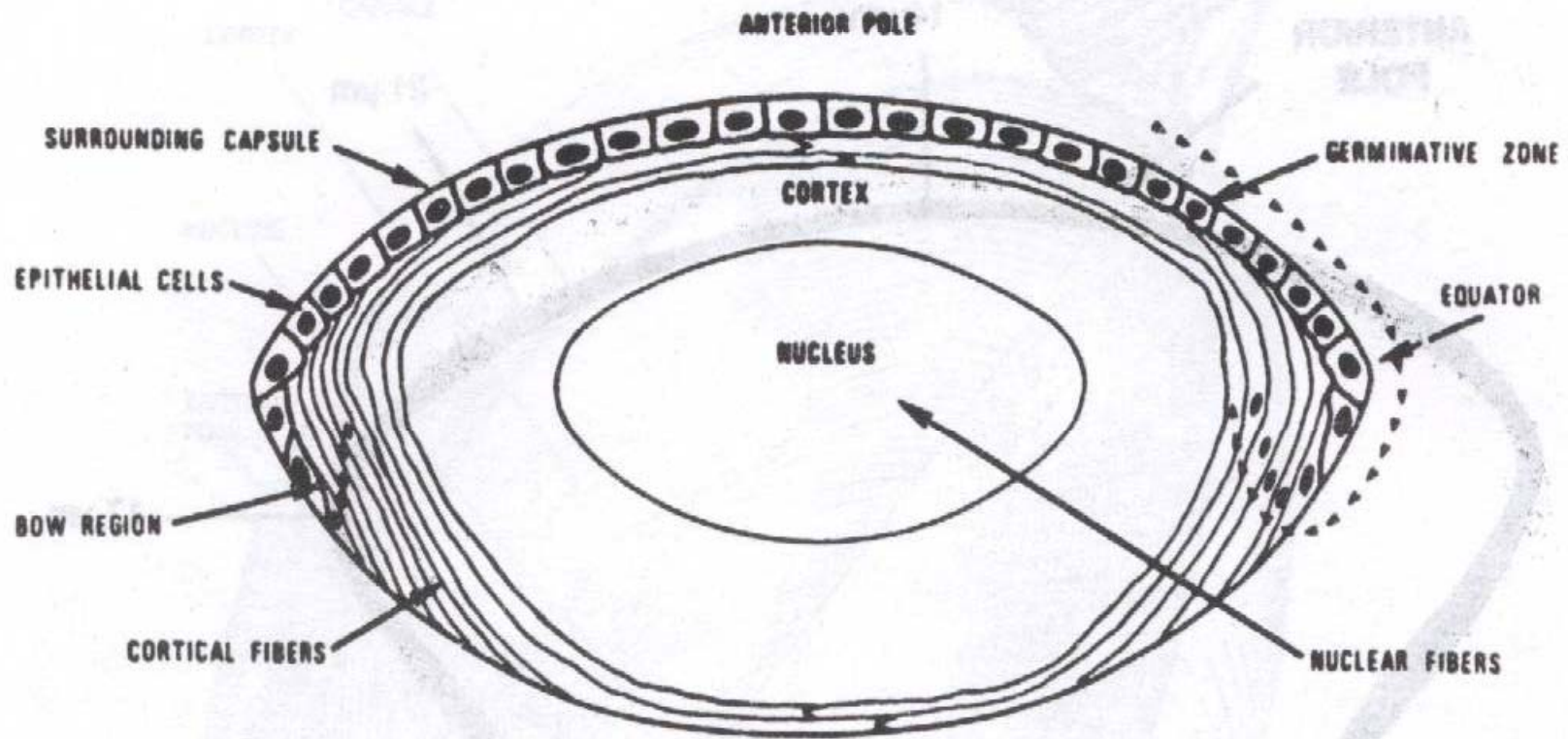


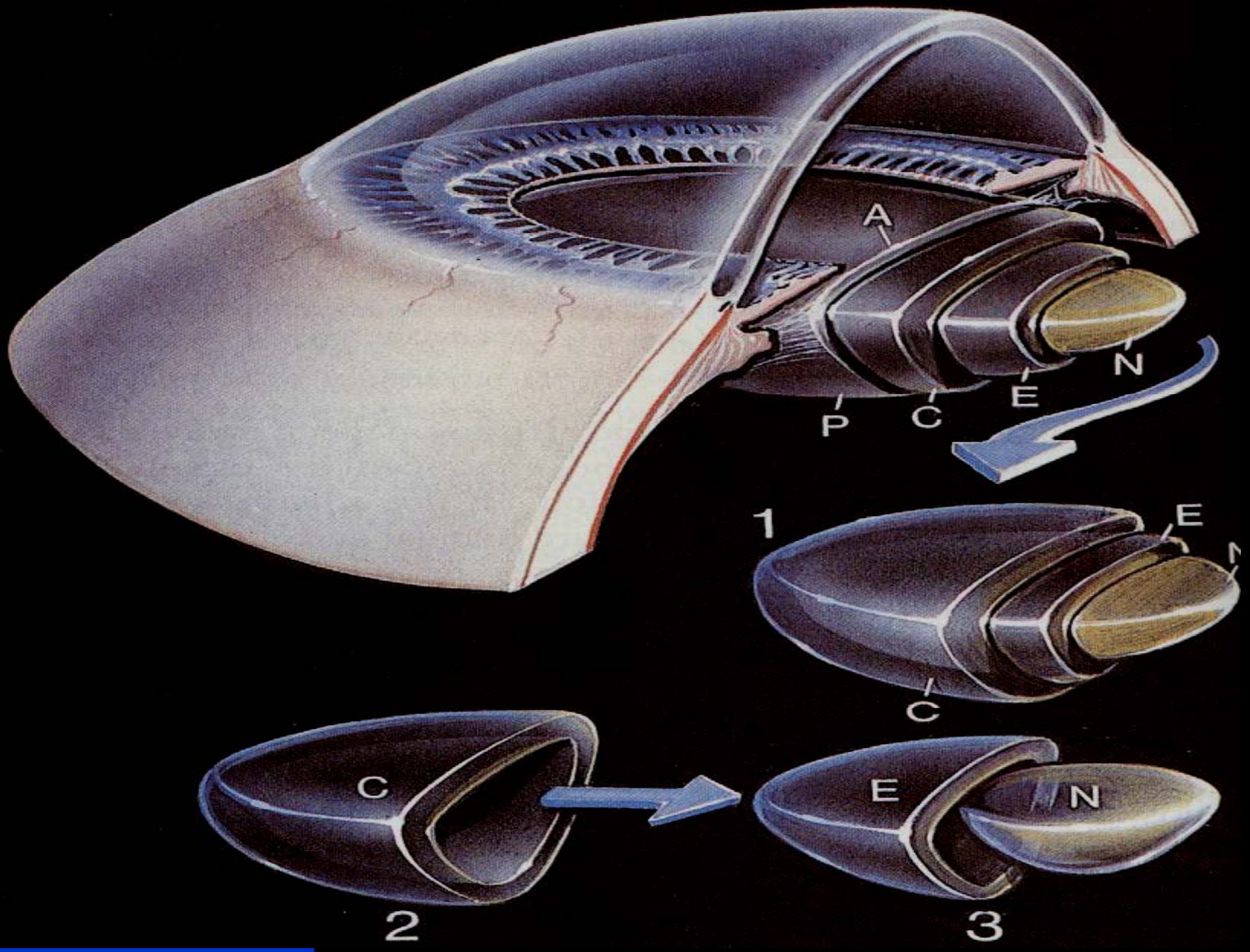


# The Lens

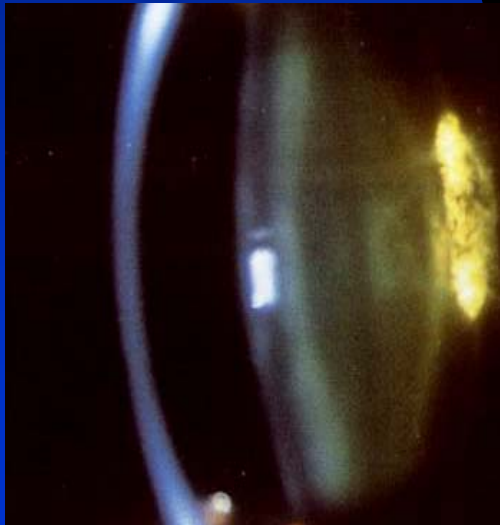
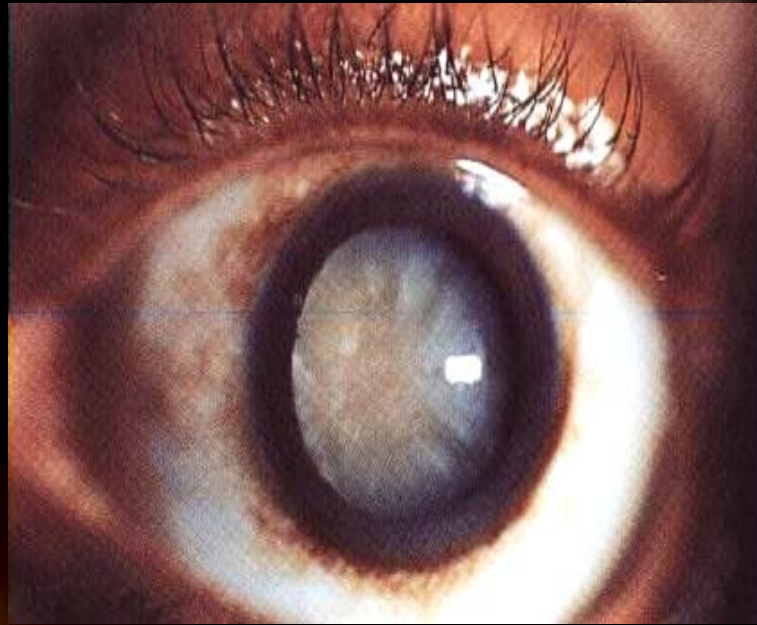
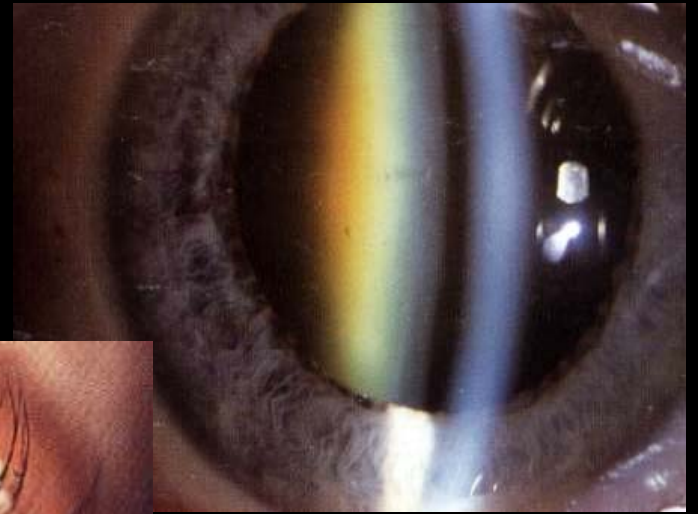
- The crystalline lens is the only structure continuously growing throughout the life.
- Changeable refractive media.
- Capsule, epithelium and lens fibers.
- Congenital anomalies and effect of systemic diseases.
- Cataract.





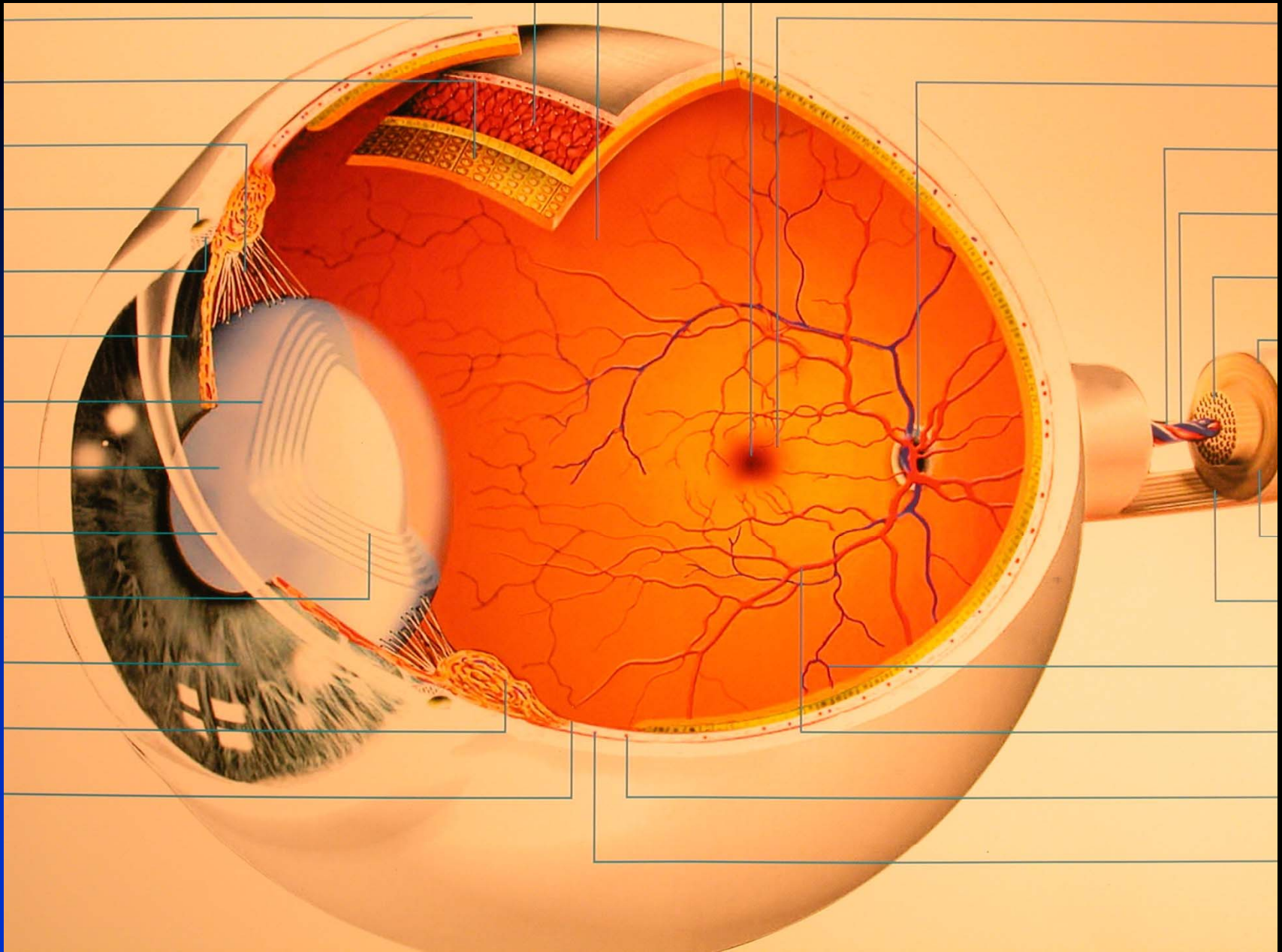

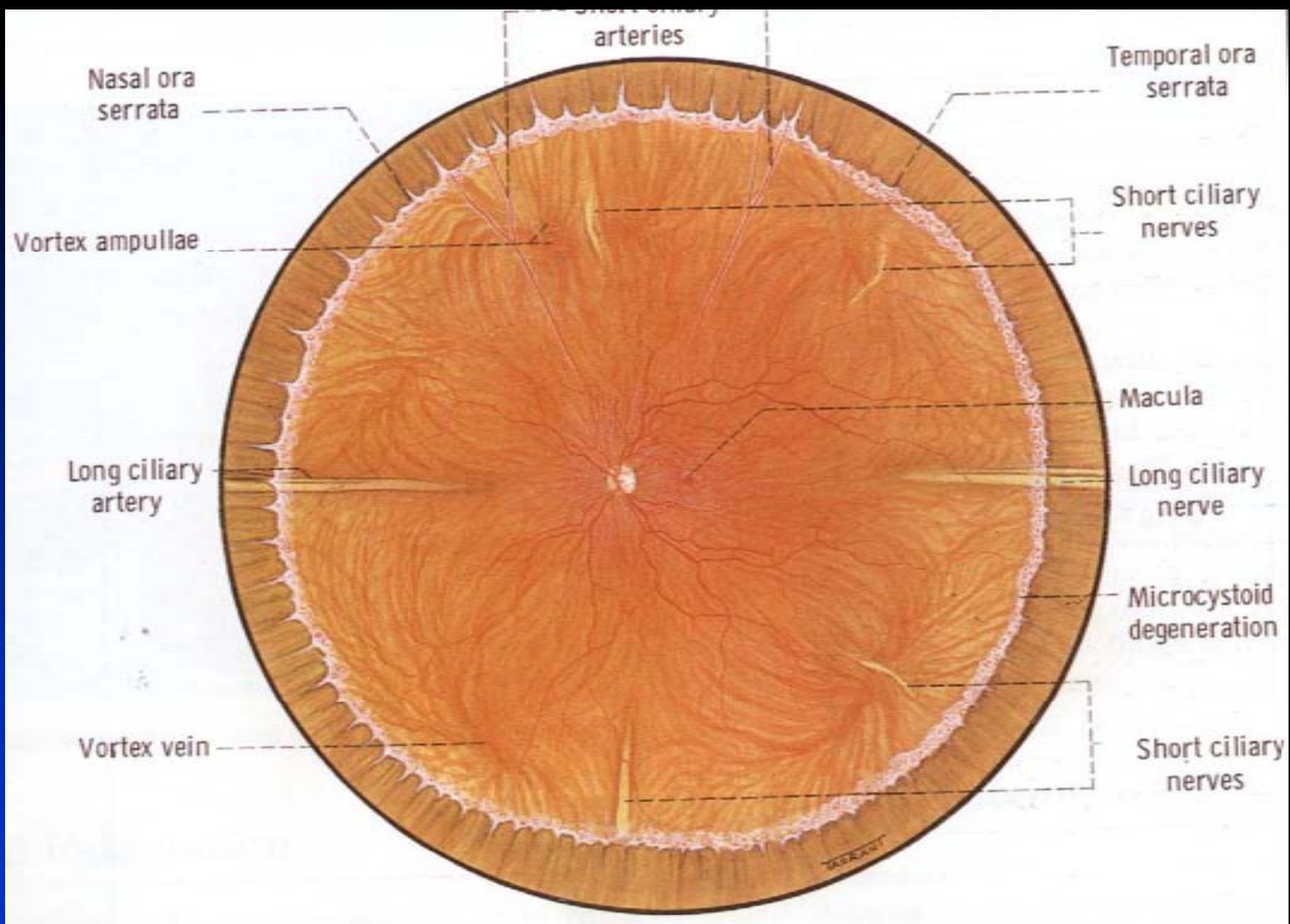


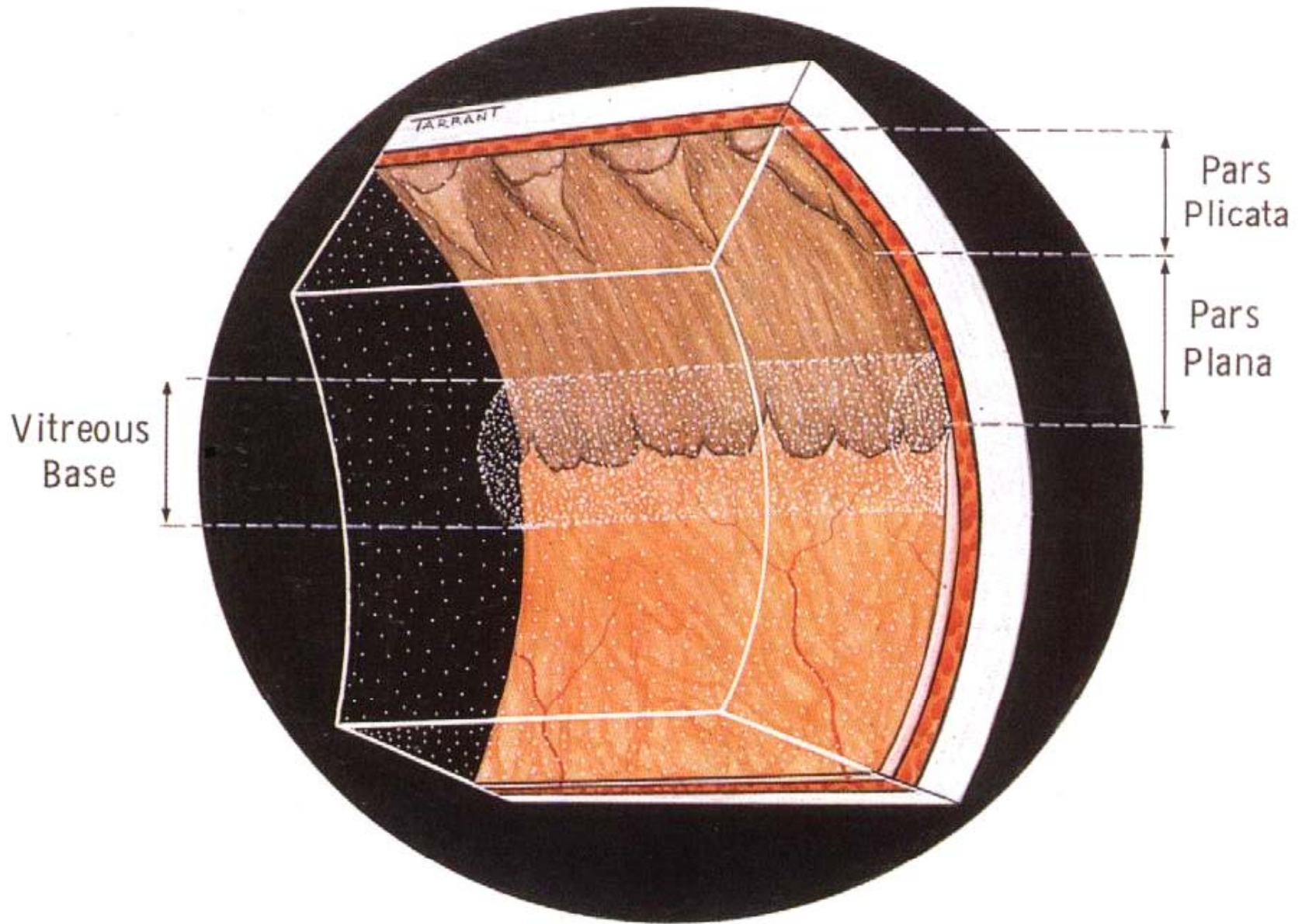


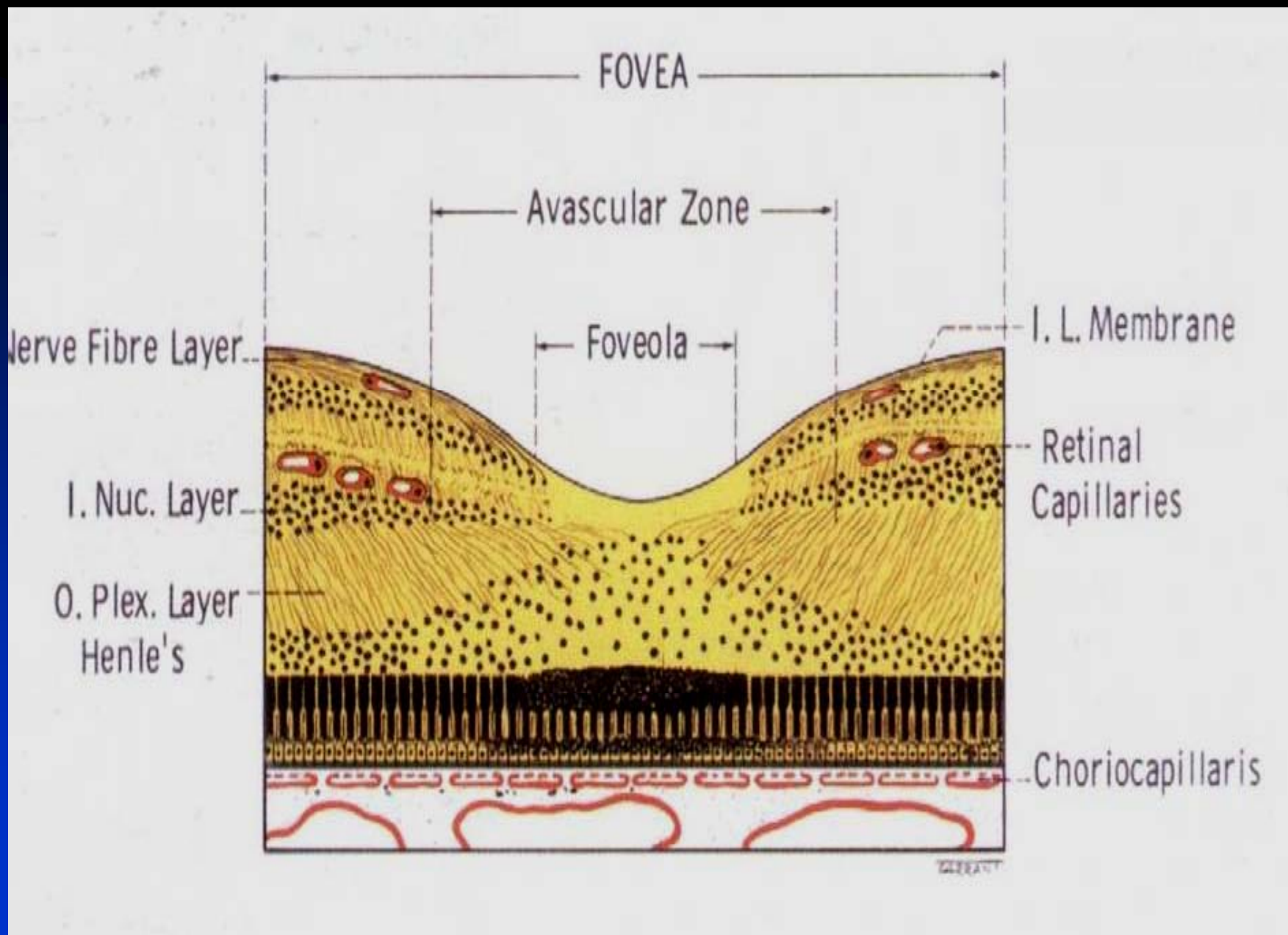
# Retina and Vitreous

- Vitreous attachment.
- Optic nerve head, macula, fovea, retinal background, Ora serrata, and retinal vasculature.
- Effect of systemic diseases.
- Retinal detachment.









# FUNDUS OF THE EYE

NASAL

TEMPORAL

PILLA

TIC NERVE

SUPERIOR  
TEMPORAL  
VEIN

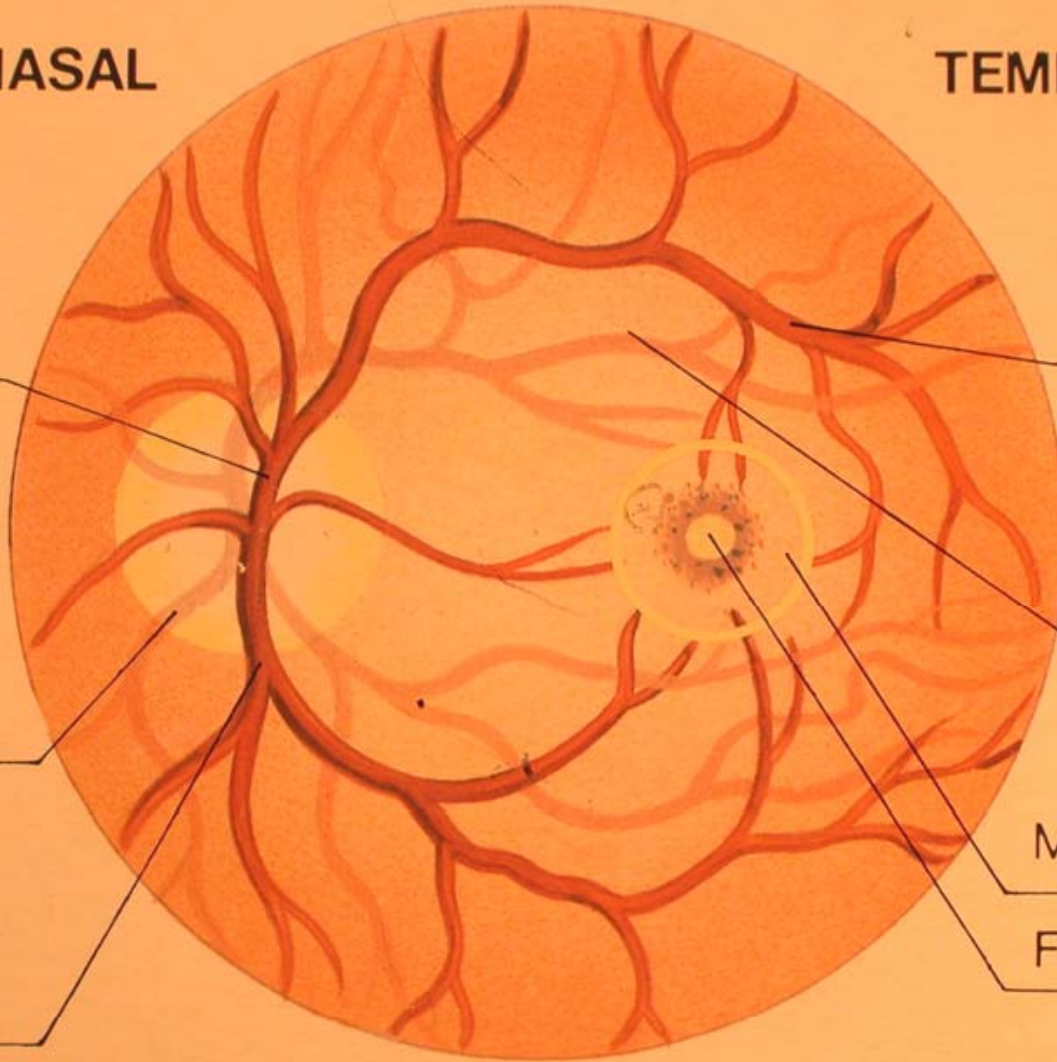
ERIOR  
SAL  
TERY

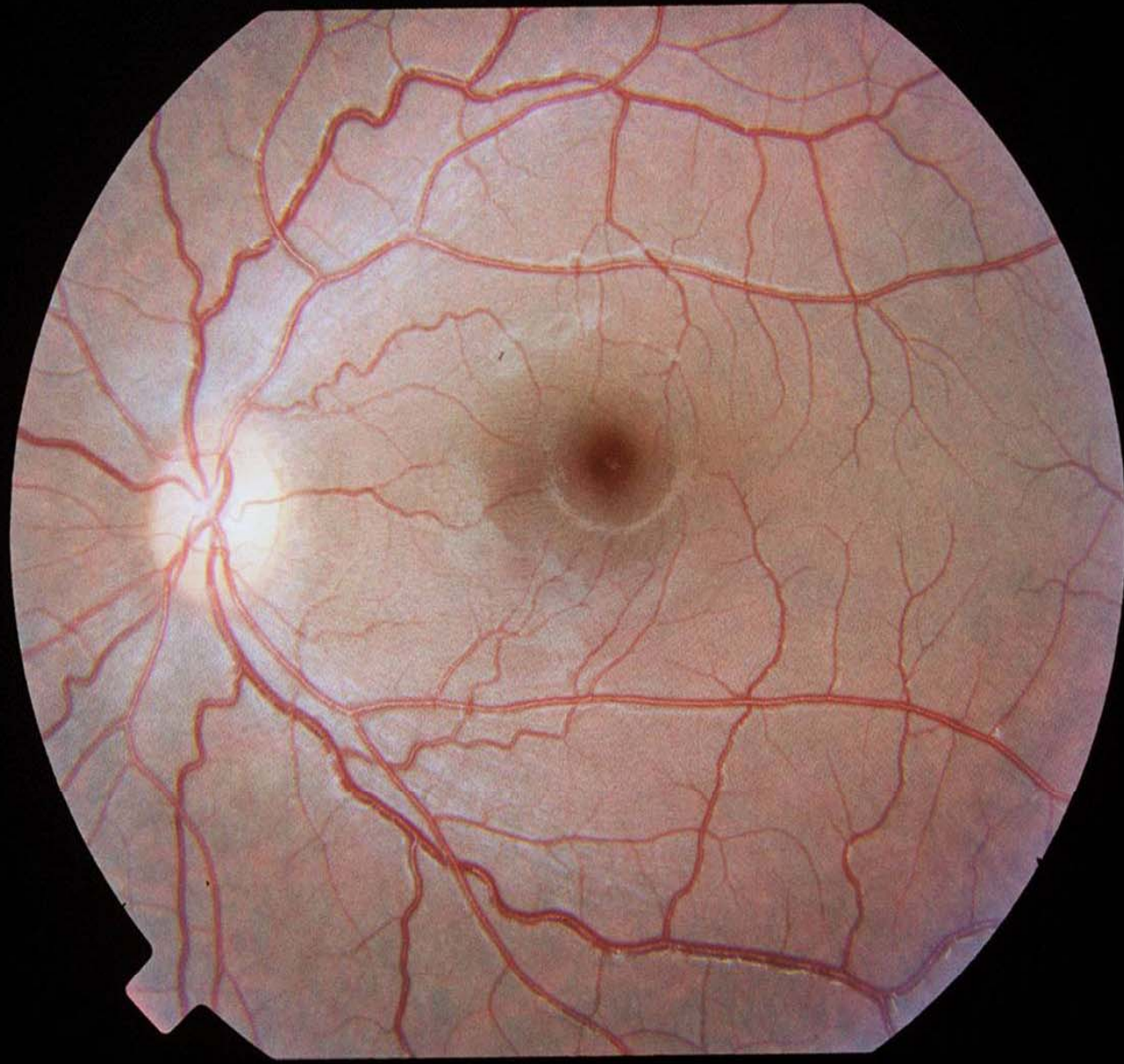
SUPERIOR  
TEMPORAL  
ARTERY

ERIOR  
MPORAL  
N

MACULA LUTEA

FOVEA CENTRA





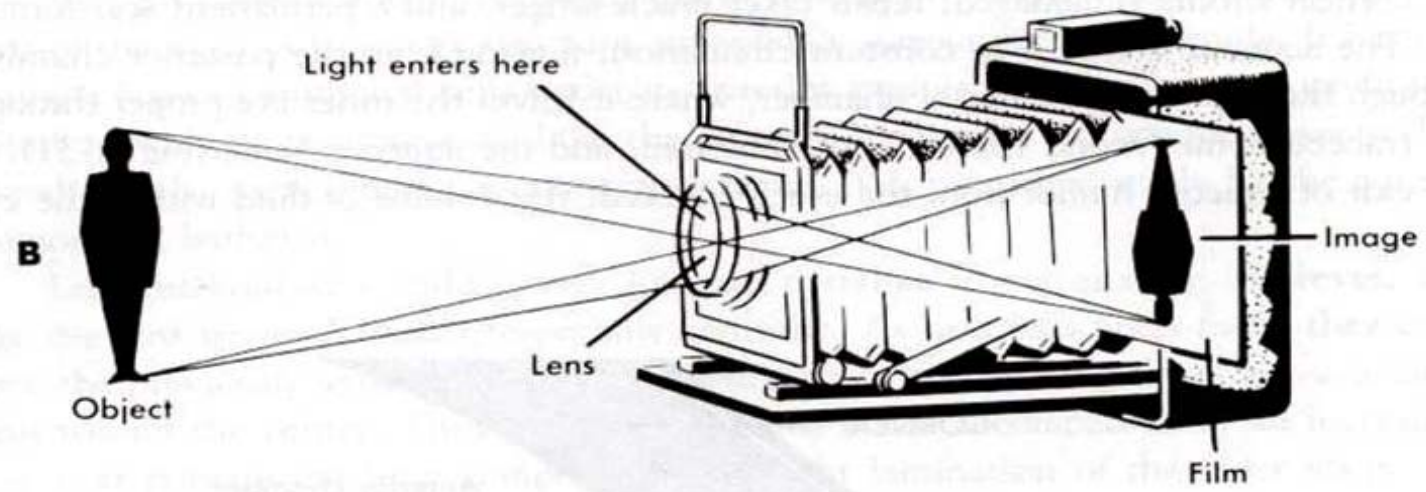
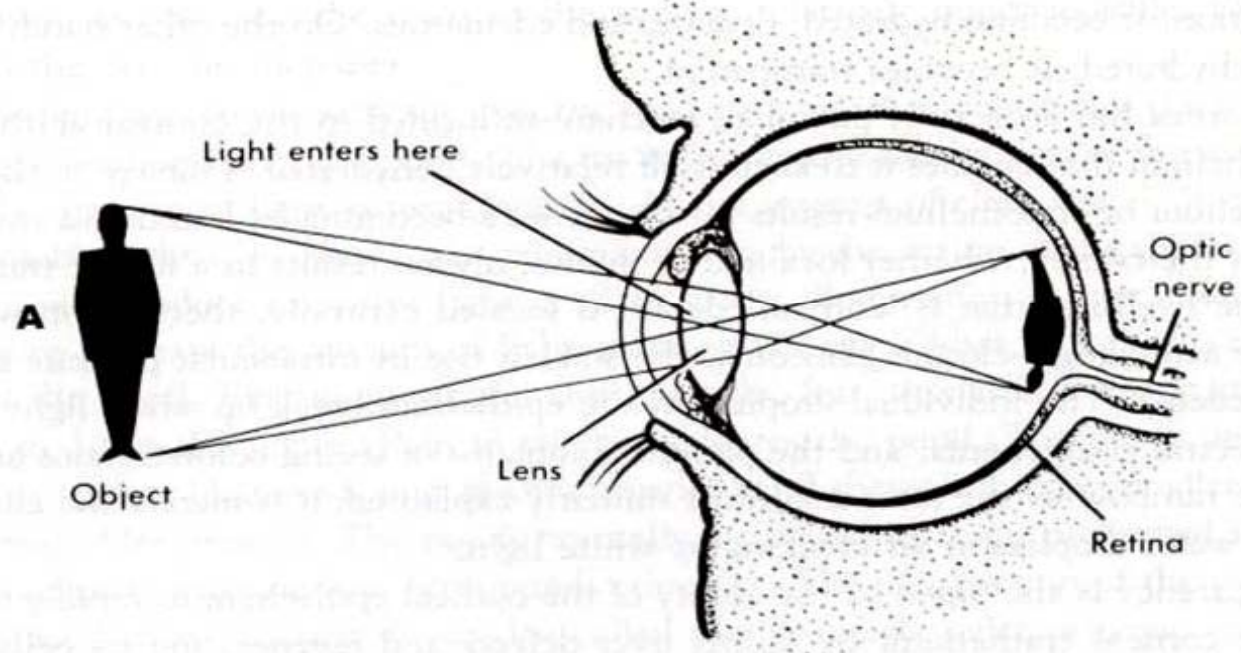


# PHYSIOLOGY

The word "PHYSIOLOGY" is rendered in a bold, 3D, sans-serif font. The letters have a vertical gradient from bright yellow at the top to a dark orange at the bottom. The text is slanted upwards from left to right. The background is black, with a large blue arc on the left side that partially overlaps the text.

# Optics of the Eye

- The eye is like a camera. Light must have a clearly pathway to be clearly focused on the sensory receptors of the retina, i.e., Clear cornea, anterior chamber, lens and vitreous cavity.
- The Refractive power of the eye is about  $\pm 58$  dioptries.



# Optics of the Eye (cont.)

- The cornea is the major refracting element of the eye with a power of approximately 40 dioptries. If the curvature is greater in one meridian than the other → Astigmatism
- The refractive power of the lens is about 17 dioptries at rest. Accommodation able to change the power of the lens markedly depends on age.

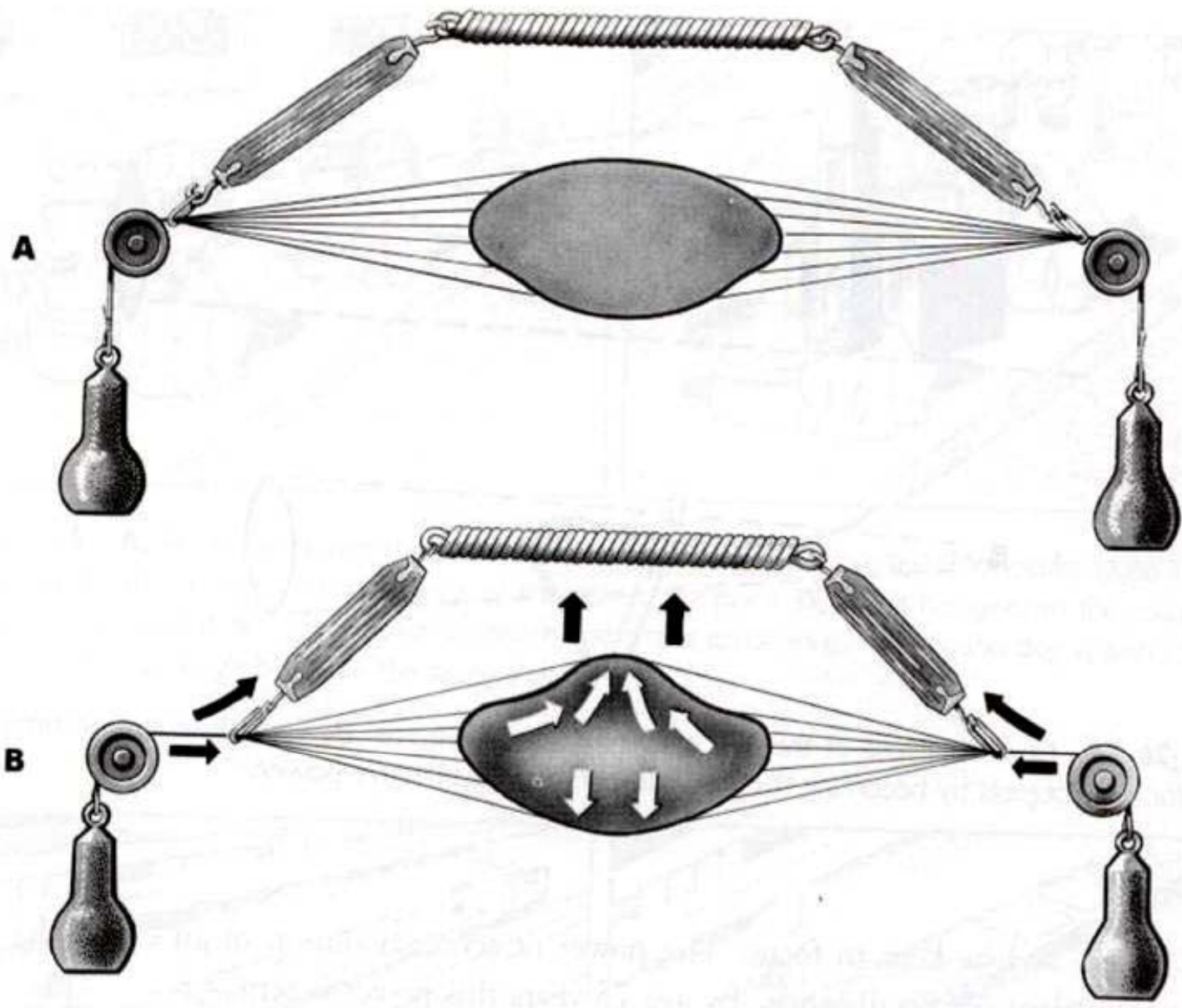
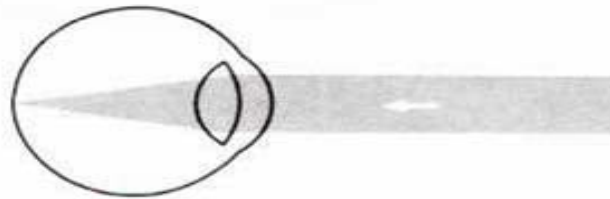
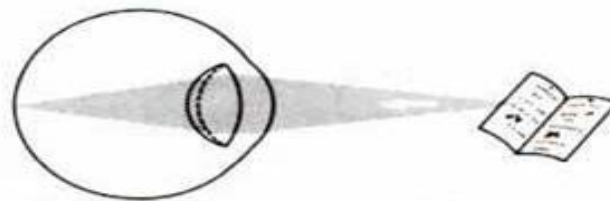


Fig. 1.29. Active tension

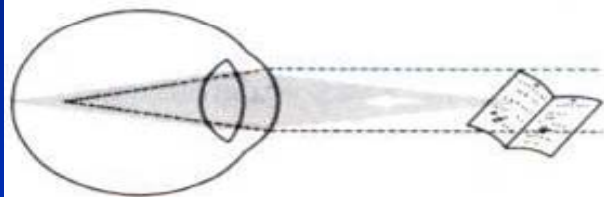
- ***Emmetropia***: Optically normal eye in which rays of light from a distant object are focused on the retina without accommodation.
- ***Myopia***: Light focused on front of the retina, corrected by concave lens.
- ***Hypermetropia (hyperopia)***: Light focused behind the retina, corrected by convex lens.



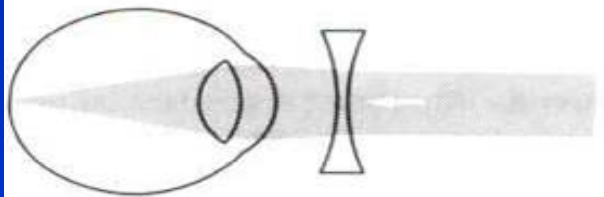
Emmetropia.



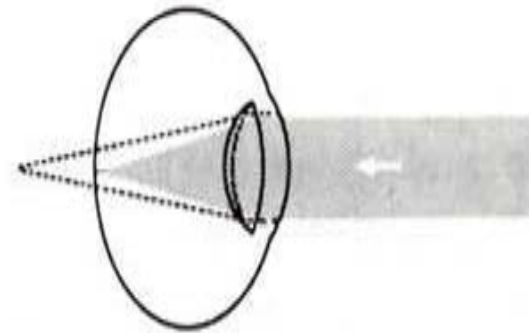
Accommodation.



Myopia.



Correction of myopia.



Hypermetropia.

# The intraocular pressure

- The pressure within the eye is maintained at a steady level by continuous formation & drainage of aqueous.
- Aqueous is secreted by the ciliary epithelium → posterior chamber → anterior chamber (through the pupil) → drained through the anterior chamber angle.
- The intraocular pressure, (IOP), is normally 10 – 21 mmHg; increased IOP called Glaucoma.
- High IOP almost always due to an obstruction of aqueous outflow.



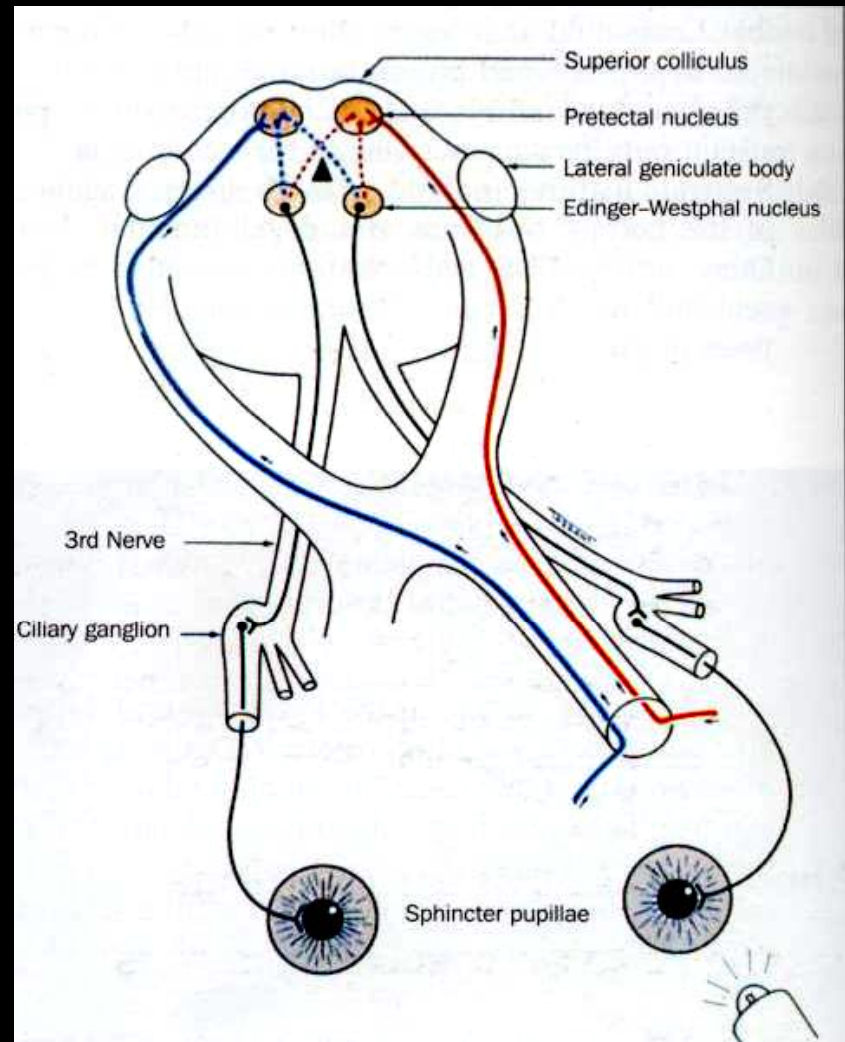
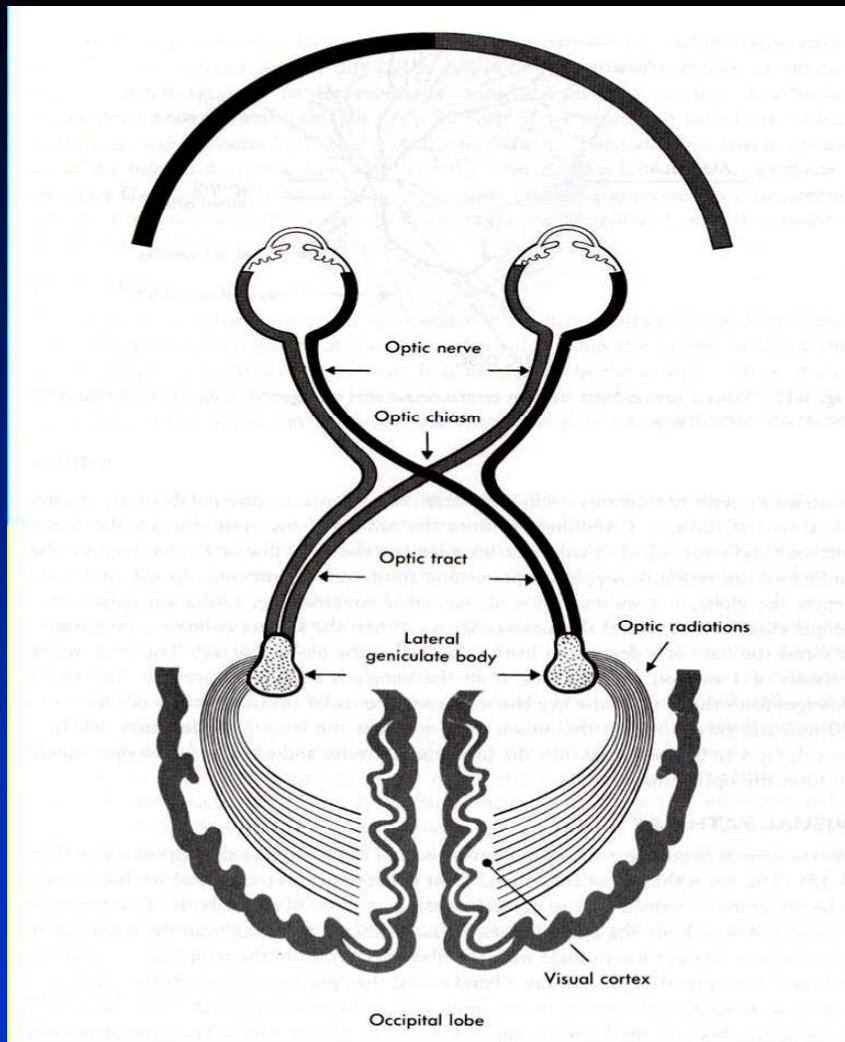
# VISION

- ***The retina:***

- The central retina contains yellow pigment, Xanthophyll, the so called macula lutea ( yellow spot).
- It is divided into retinal pigment epithelium & neurosensory retina.
- Photoreceptors contains visual pigment which consists of a large protein (opsin) attached to retinal (vitamin A aldehyde).

# VISION (cont.)

- Light splits the opsin from the retinal with initiation of a graded electrical potential → Transmitted through the visual pathway to be processed in the visual cortex (occipital lobe) → vision sense.
- Visual Pathway: Three neurons
  1. Bipolar cell, lies within the retina.
  2. Ganglion cell, synapse in lateral geniculate body.
  3. Third neuron terminates in visual cortex.



# Lacrimal Apparatus

- Tear secretion.
- Layers of precorneal tear film.
- Drainage of tear.

