

# Neuro-ophthalmology Review

## First Hour

Thomas M. Bosley, MD  
Professor of Ophthalmology  
King Saud University

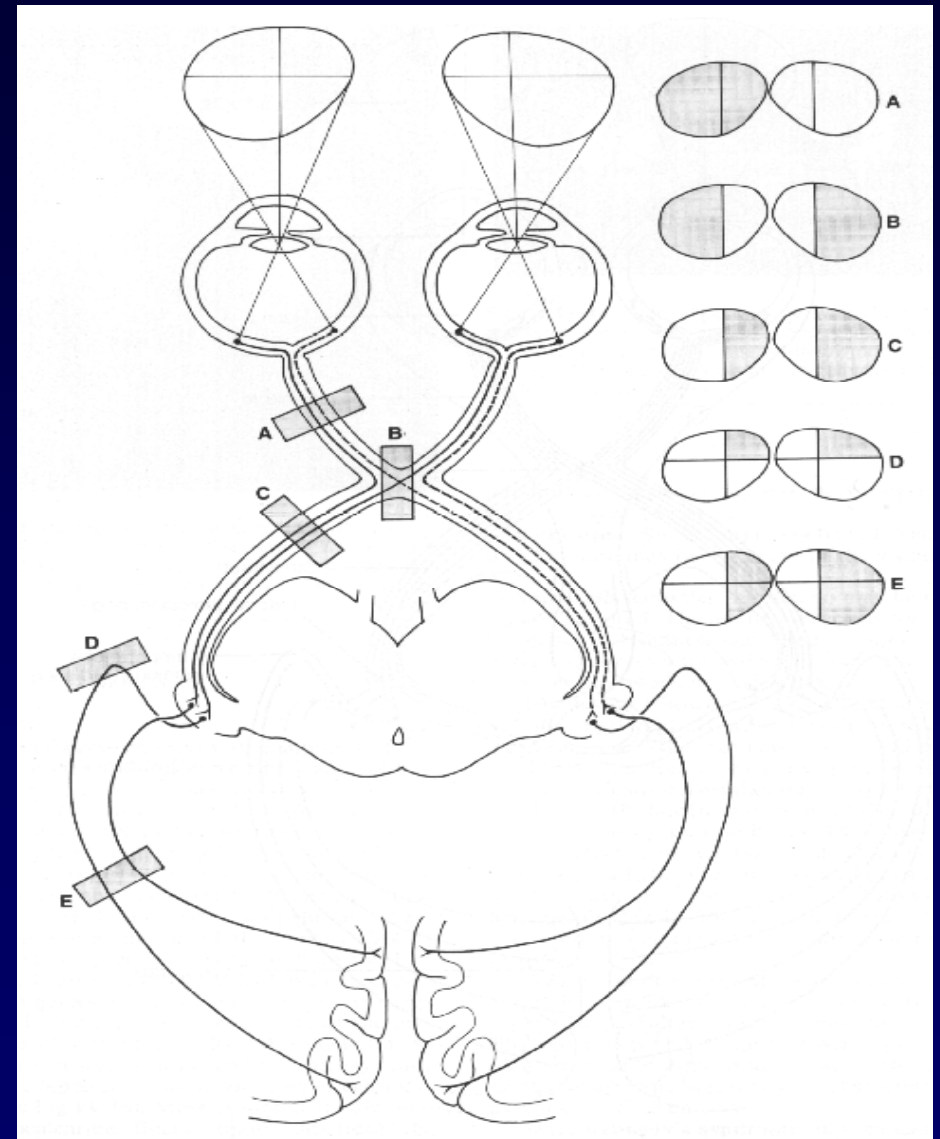
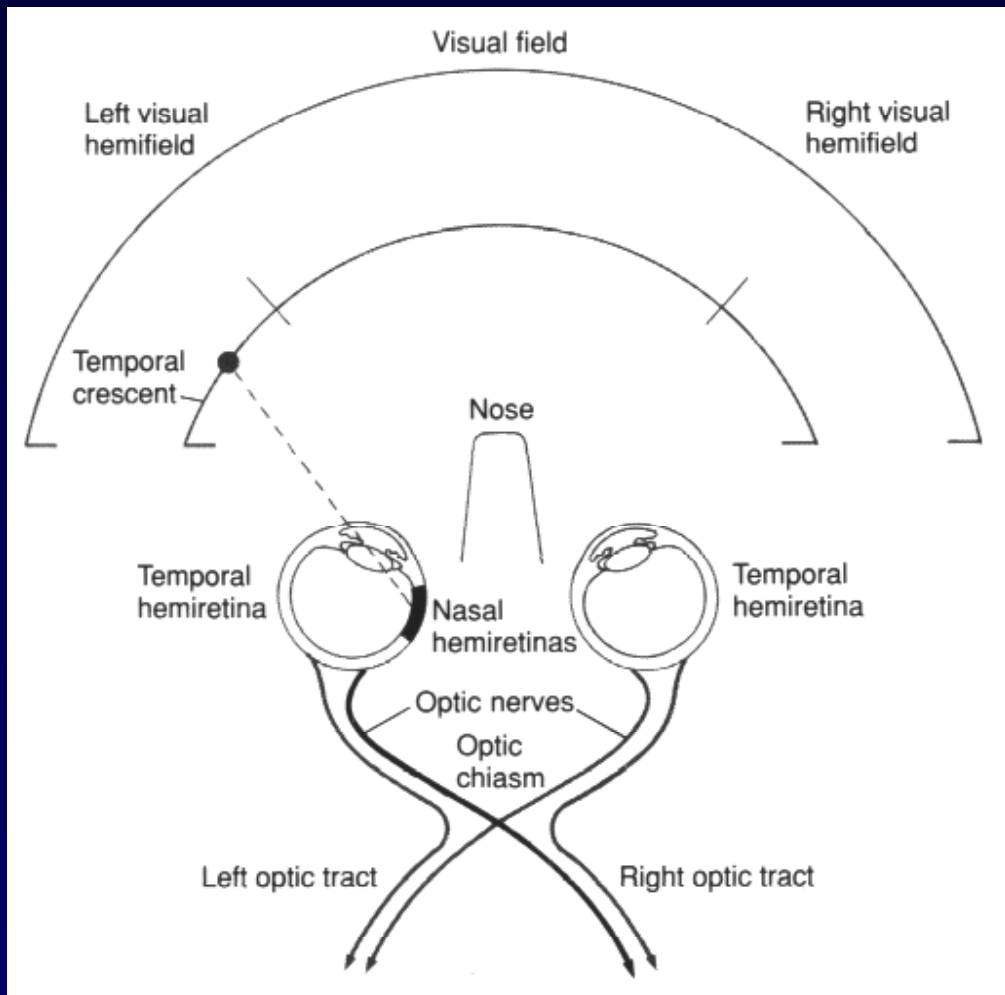
# Neuro-ophthalmology

- Afferent
- Efferent
- Other
- Anatomy
- Examination
- Diagnoses
- Tests





# Afferent Anatomy



# Afferent Visual System

- Visual acuity
- Color vision
- Visual field
- Pupil examination
- Fundoscopy
- Anatomy
- Examination
- Diagnoses
- Tests

# Examination

- Visual acuity
- Color vision
- Visual field
- Pupil examination
- Fundoscopy

Distance

Ishihara  
Near

Confrontation  
AOC

Gittmann

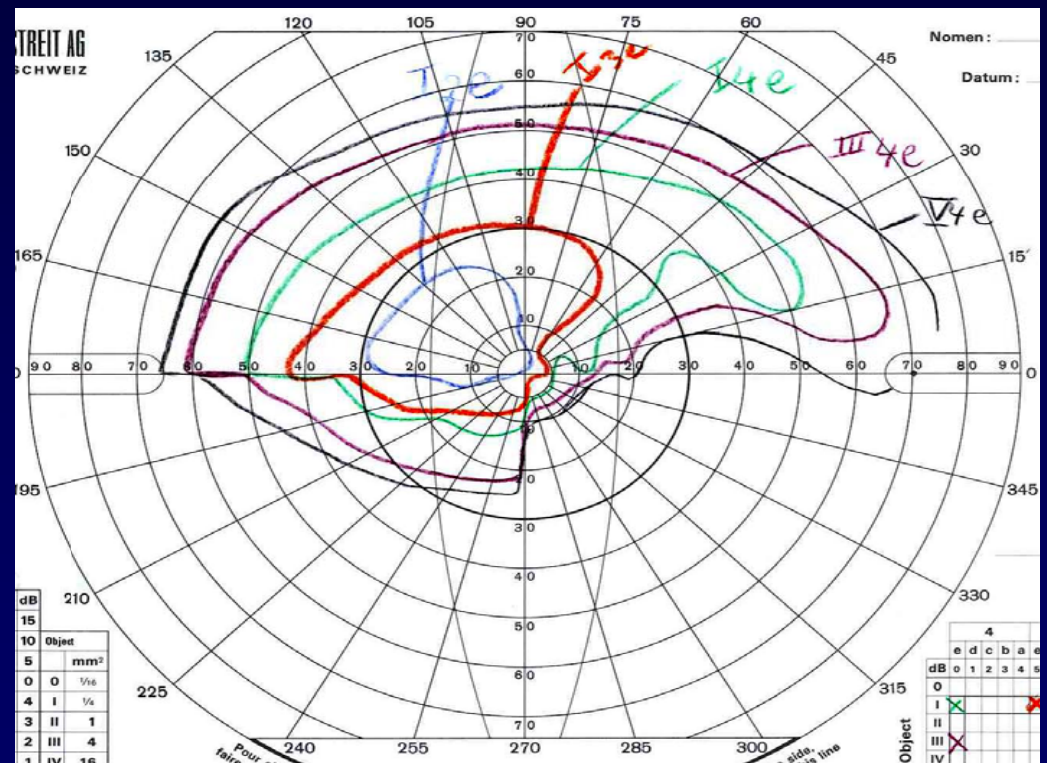
Direct ophthalmoscopy  
Dumphy

Slit lamp and lens

Indirect ophthalmoscopy

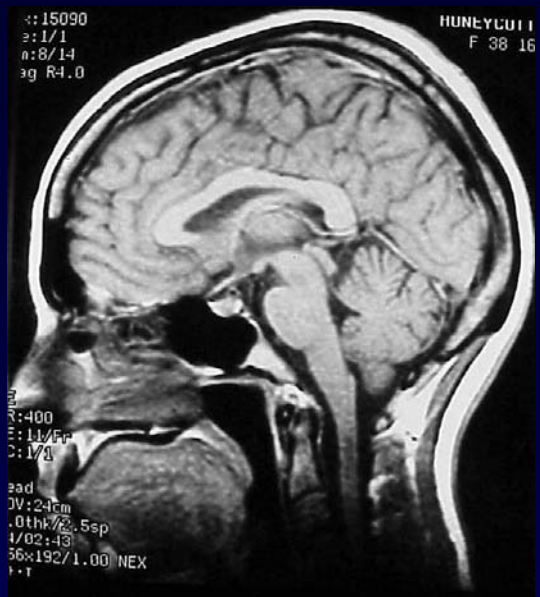# 35 yo woman

- Reported 3 months of gradual visual loss OU
- 7 months pregnant
- Rapid visual loss OU over 1 week before N-O evaluation
- VA at presentation OD 20/40 and OS NLP

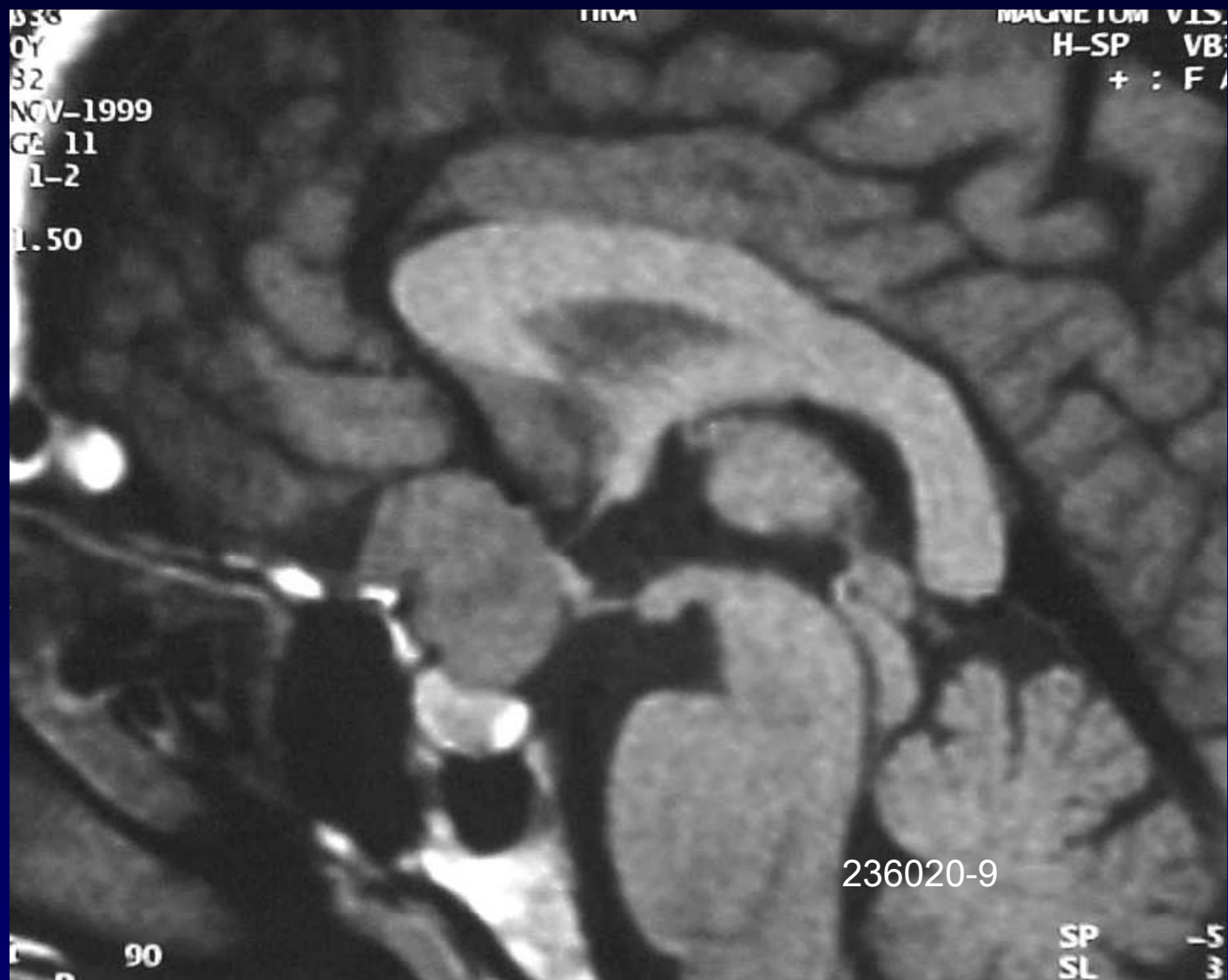


236020-9

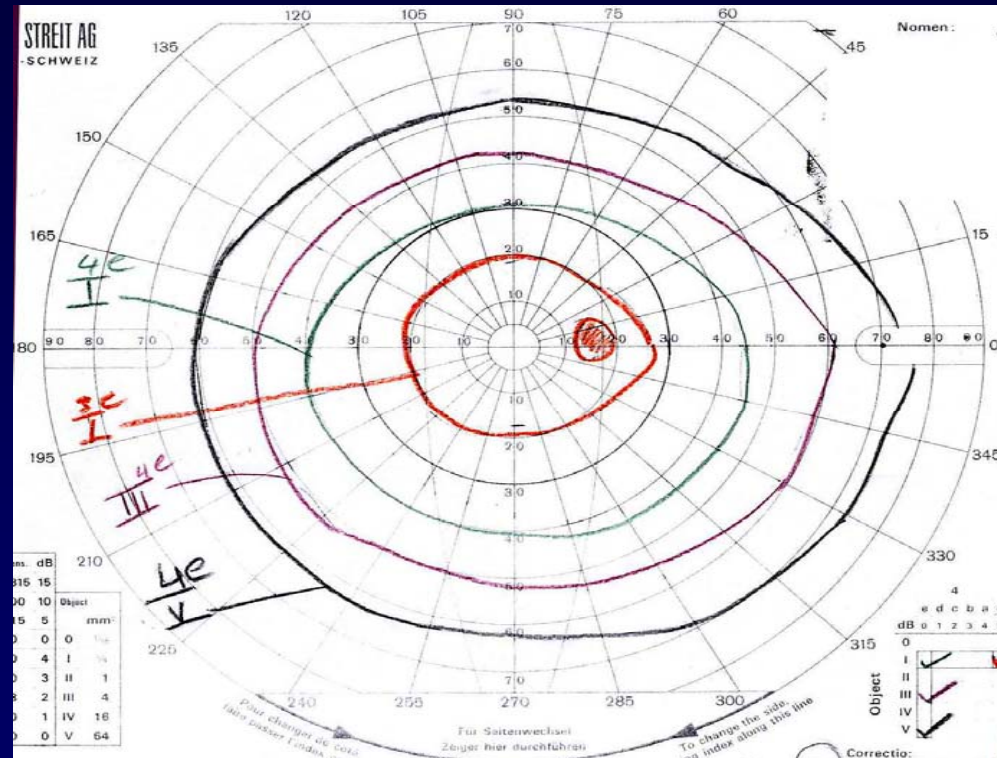
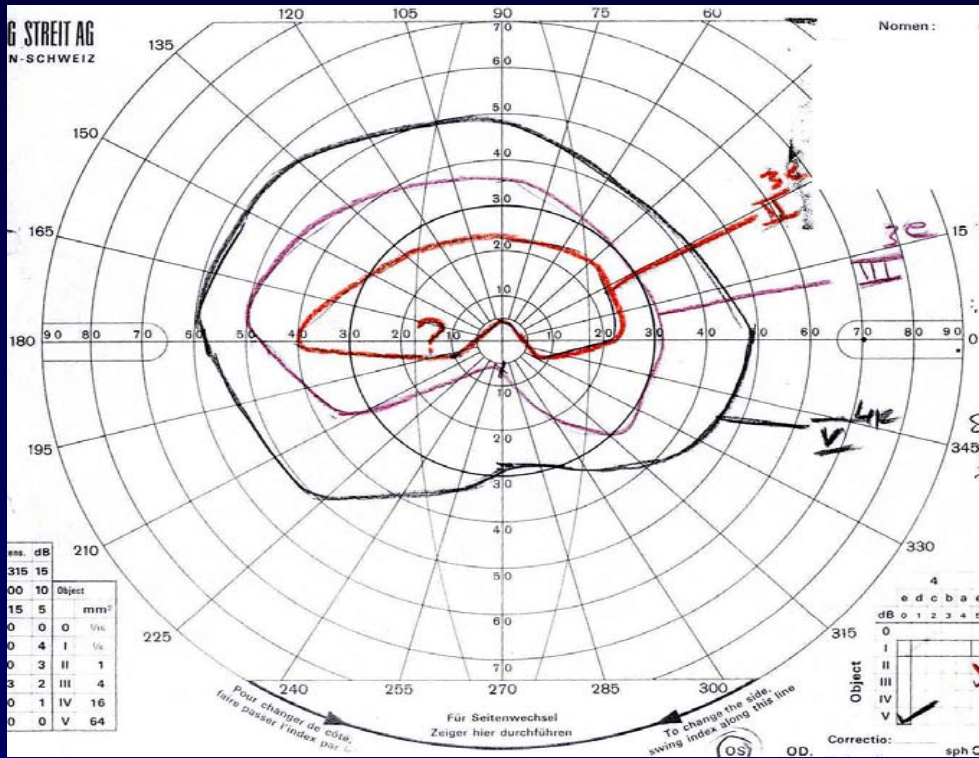




Normal sagittal scan

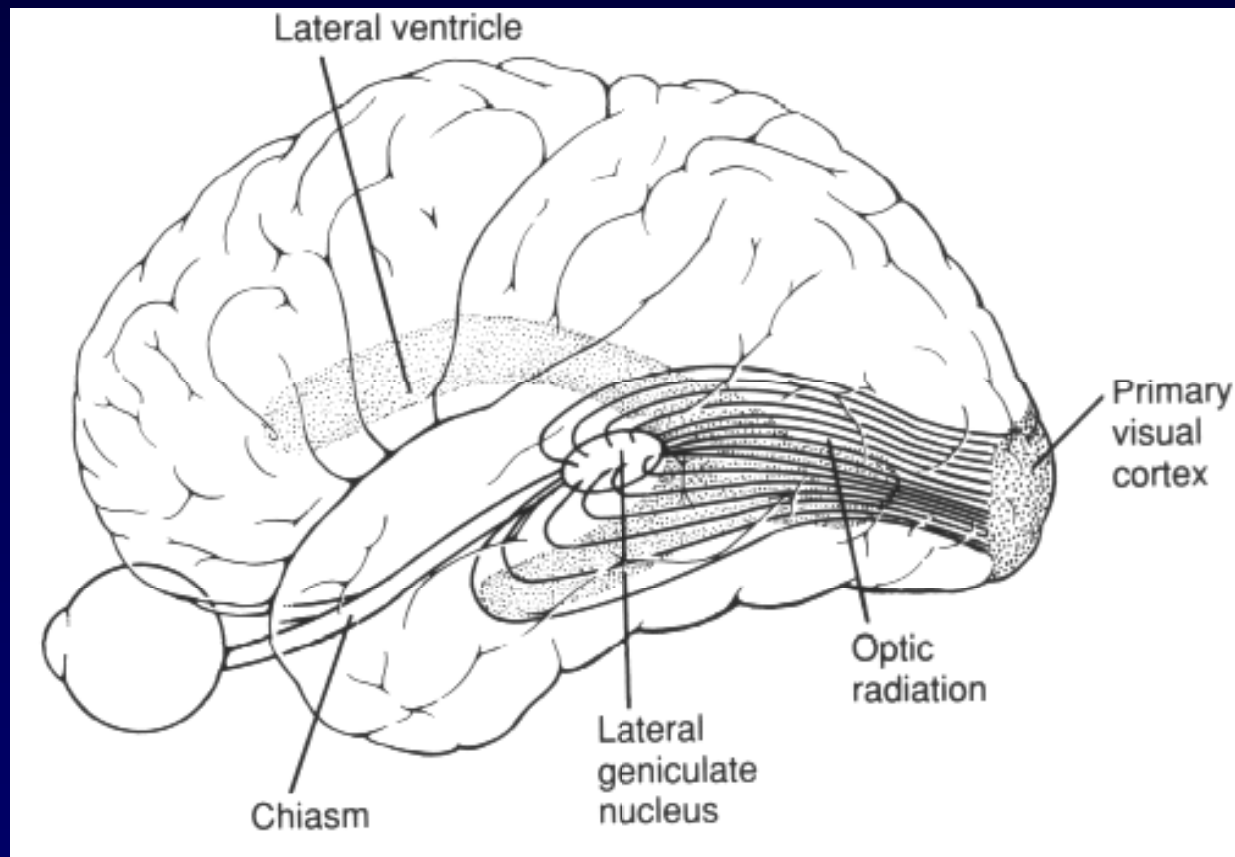


# Post-op visual fields

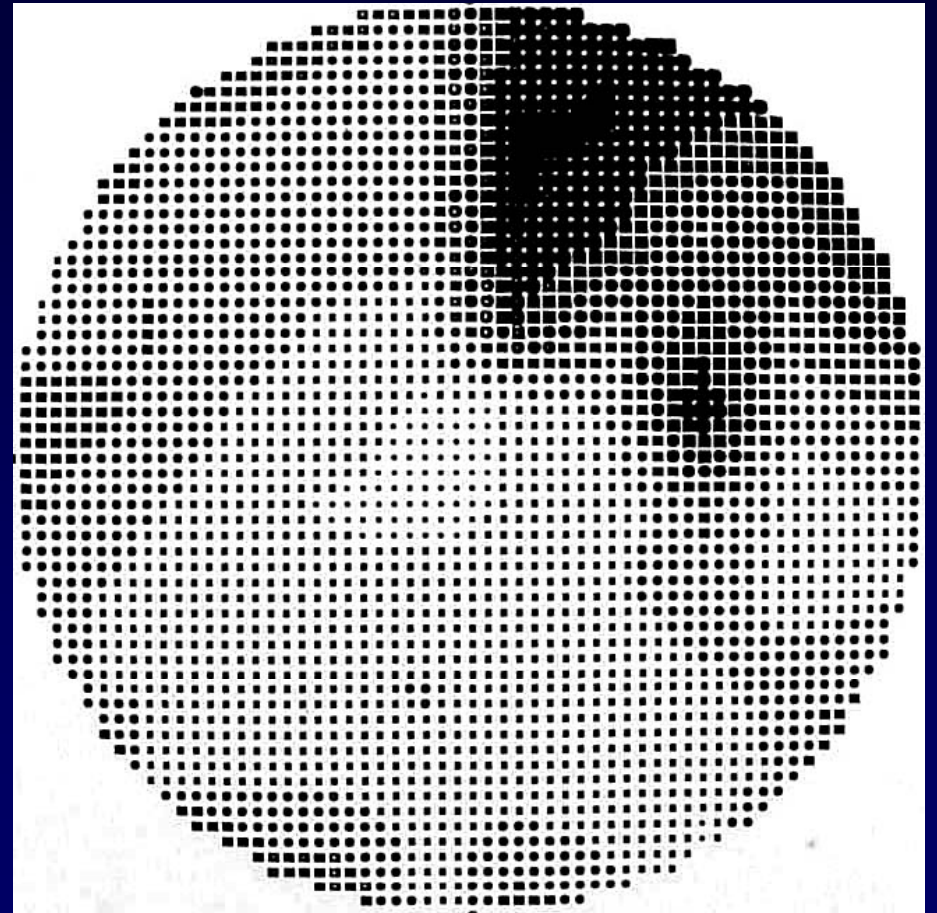



236020-9

# Before Temporal Lobectomy



# After temporal lobectomy



# Afferent Visual System

- Compression
- Trauma
- Inflammation
- Ischemic
- Congenital and genetic problems
- Anatomy
- Examination
- Diagnoses
- Tests

# Afferent Diagnoses

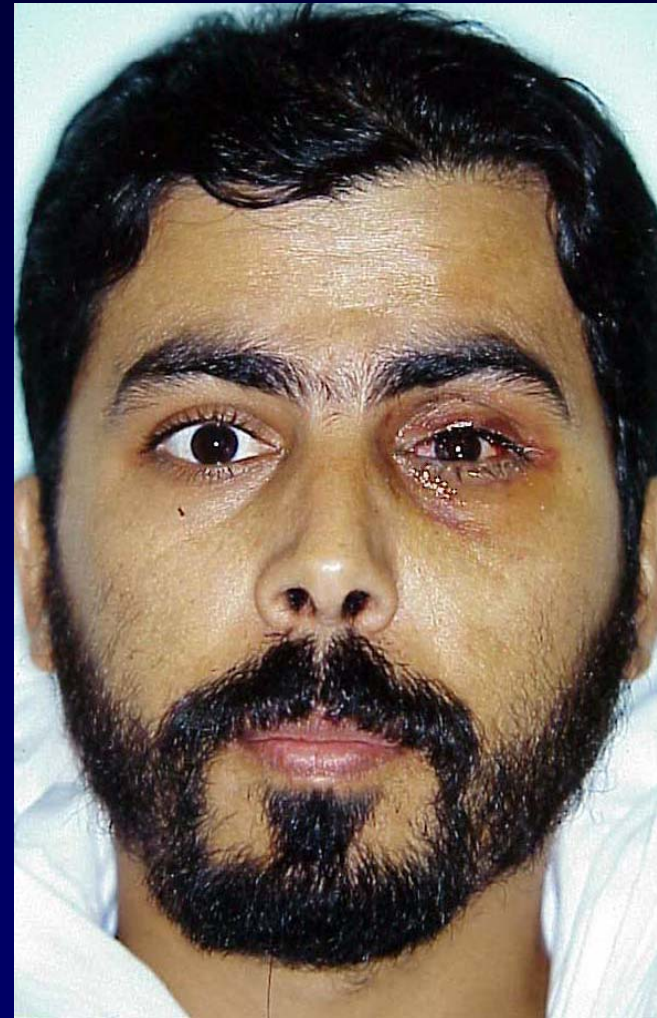- Compression
  - Intraorbital ON
- Trauma
  - Intracranial ON
- Inflammation
  - Optic chiasm
- Ischemic
  - Optic tract
- Congenital and genetic problems
  - Posterior afferent system

# Afferent Diagnoses

- Compression
- Trauma
  - Globe
  - Intraorbital ON
  - Optic canal
  - Optic chiasm
  - Occipital lobe
- Inflammation
- Ischemic
- Congenital and genetic problems

## 25 yo man

- Firecracker exploded near left eye
- NLP OS



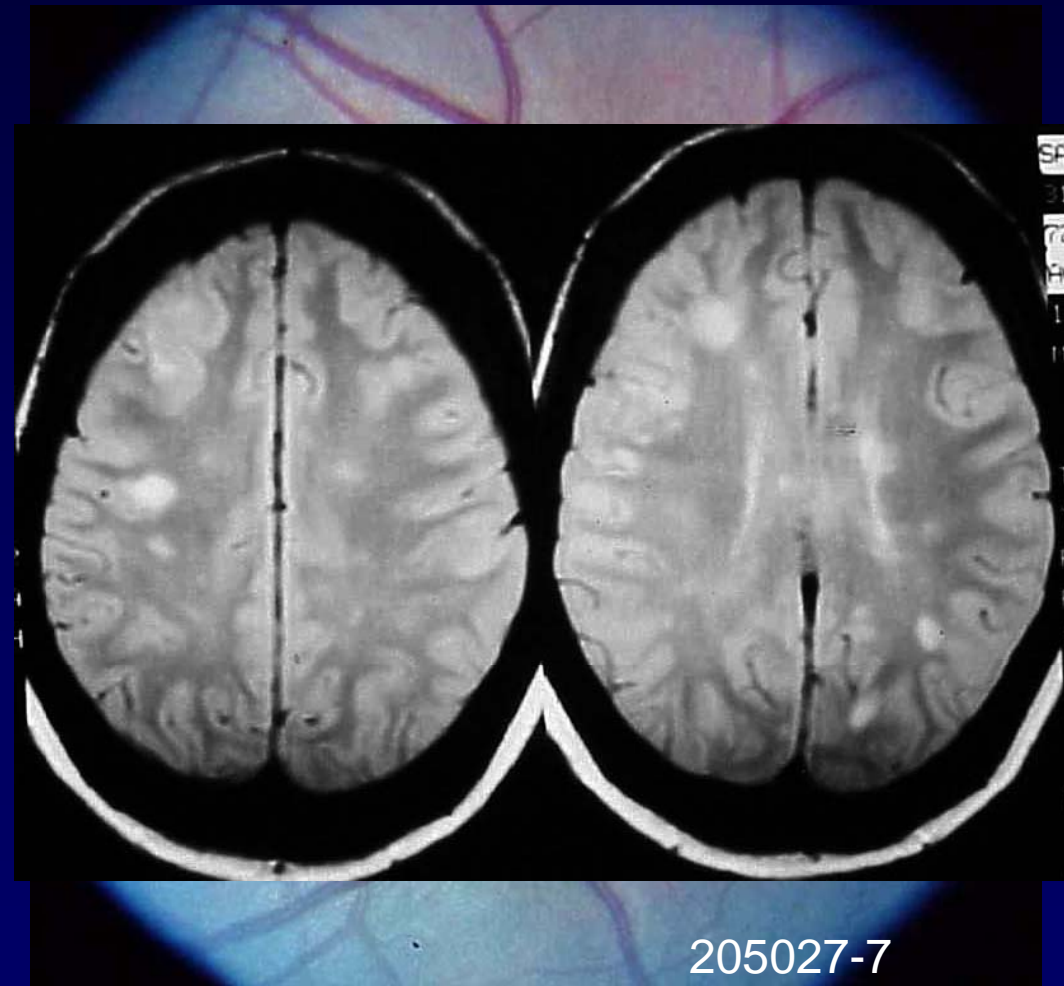


# Afferent Diagnoses

- Compression
- Trauma
- Inflammation
  - Optic neuritis
  - Orbital pseudotumor
  - Other
- Ischemia
- Congenital and Genetic problems

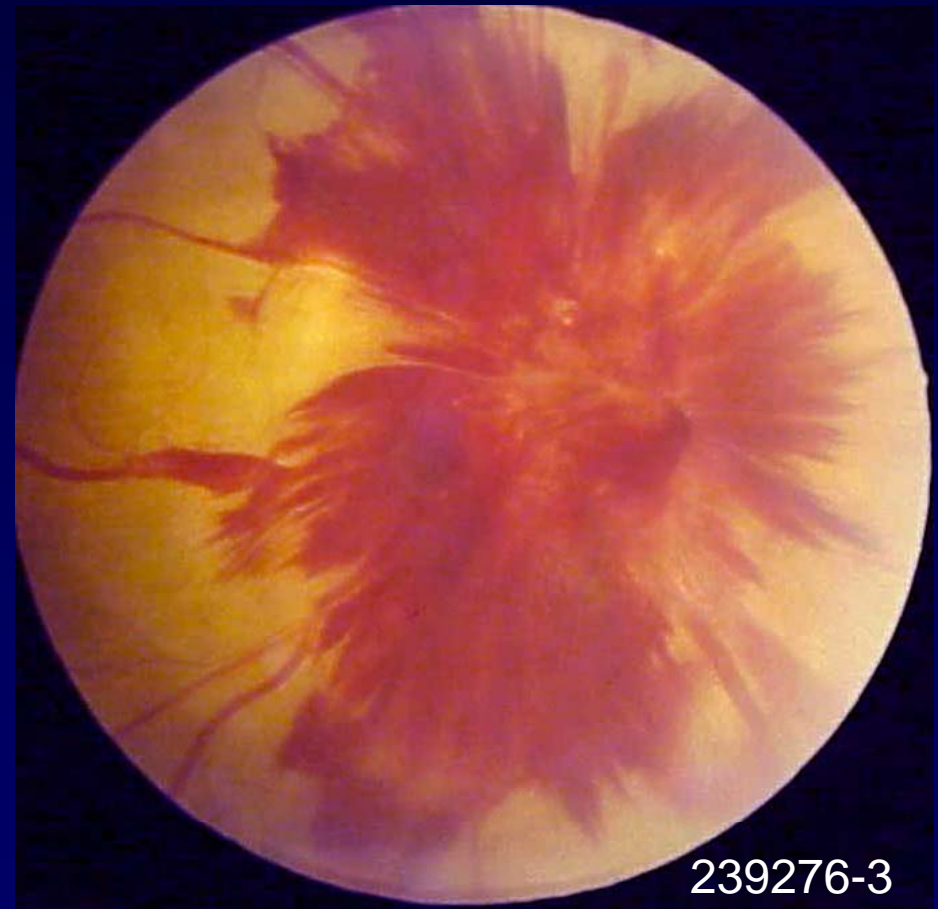
## 27 yo woman

- Developed blurred vision OD and mild right periorbital pain
- VA 20/50
- MRI abnormal
- Diagnosis multiple sclerosis



## 28 yo woman

- Developed modest left periorbital pain 3 weeks ago
- Some blurring of vision OS
- B-scan showed posterior scleritis



239276-3

# Afferent Diagnoses

- Compression
- Trauma
- Inflammation
- Ischemia
- Congenital and genetic problems

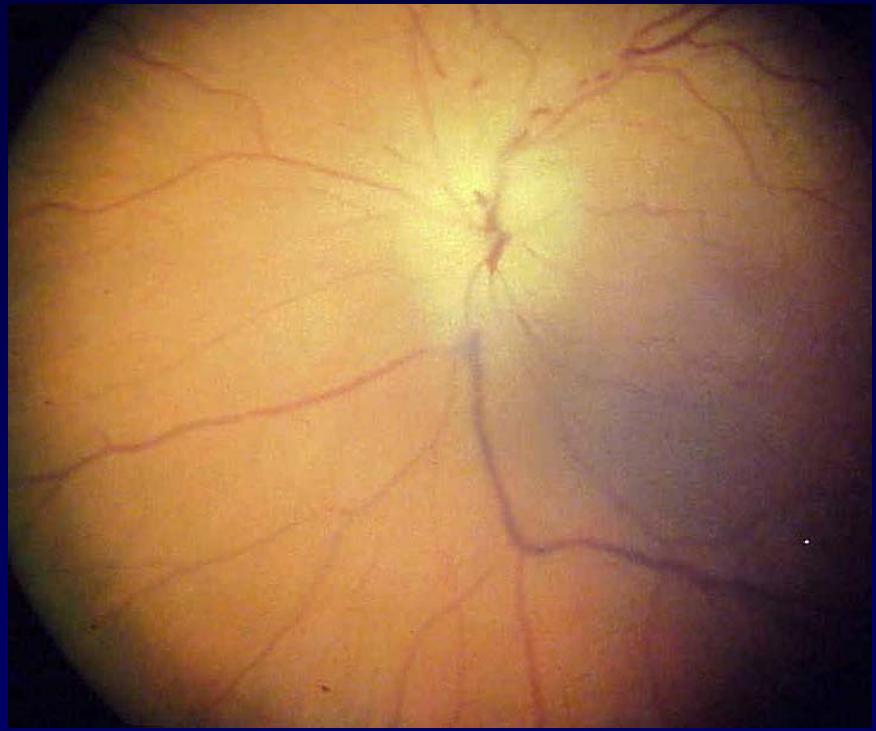
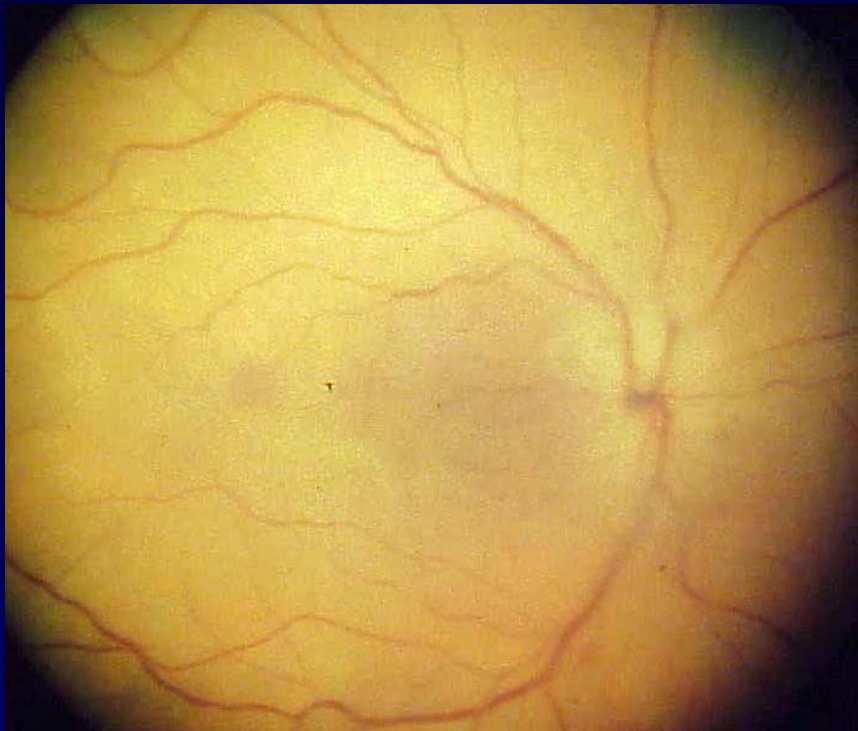Non-arteritic ischemic optic neuropathy

Central retinal artery occlusion

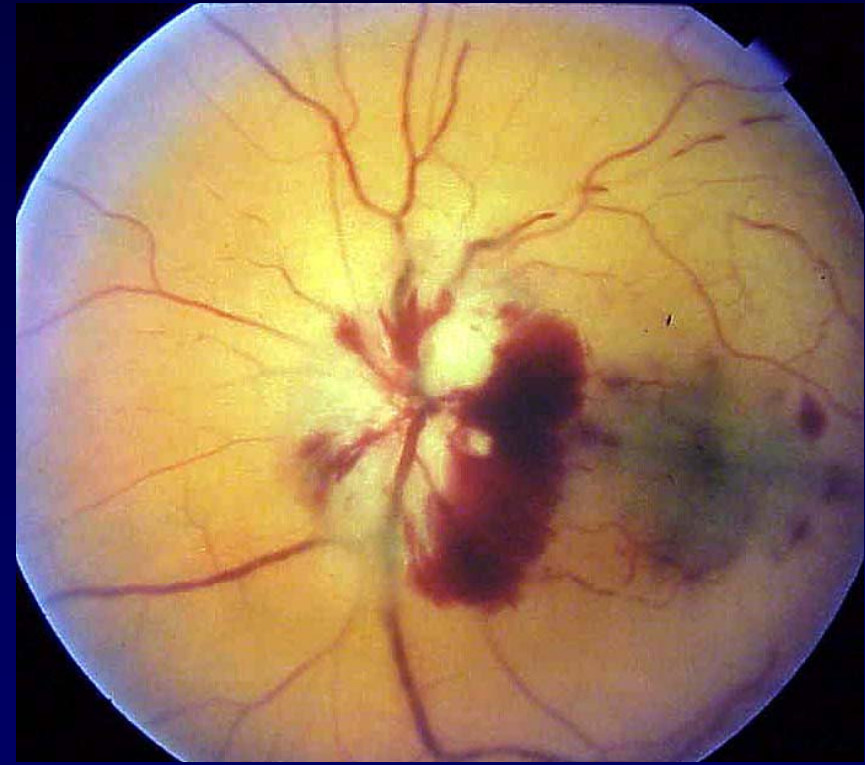
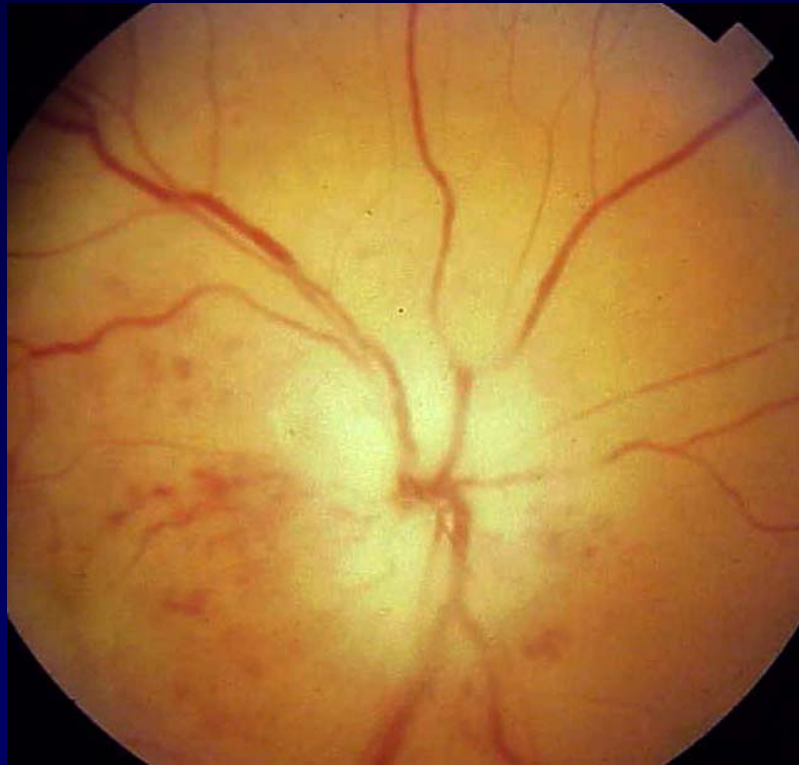
Other retinal emboli

Giant cell arteritis with ION

# Giant Cell Arteritis, Day 2



# Giant Cell Arteritis, Day 4



# Afferent Diagnoses

- Compression
- Trauma
- Inflammation
- Ischemia
- Congenital and genetic problems

Congenital retinal dystrophies

Optic nerve hypoplasia

Leber hereditary optic neuropathy

Dominant and recessive optic atrophy

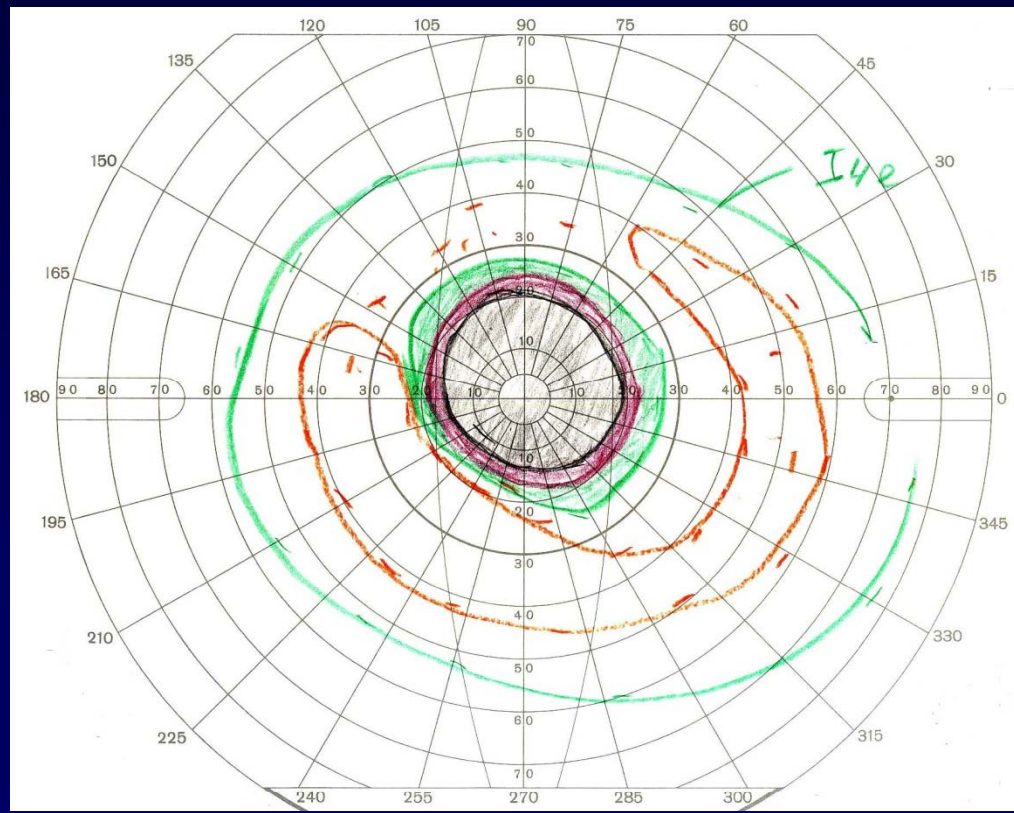
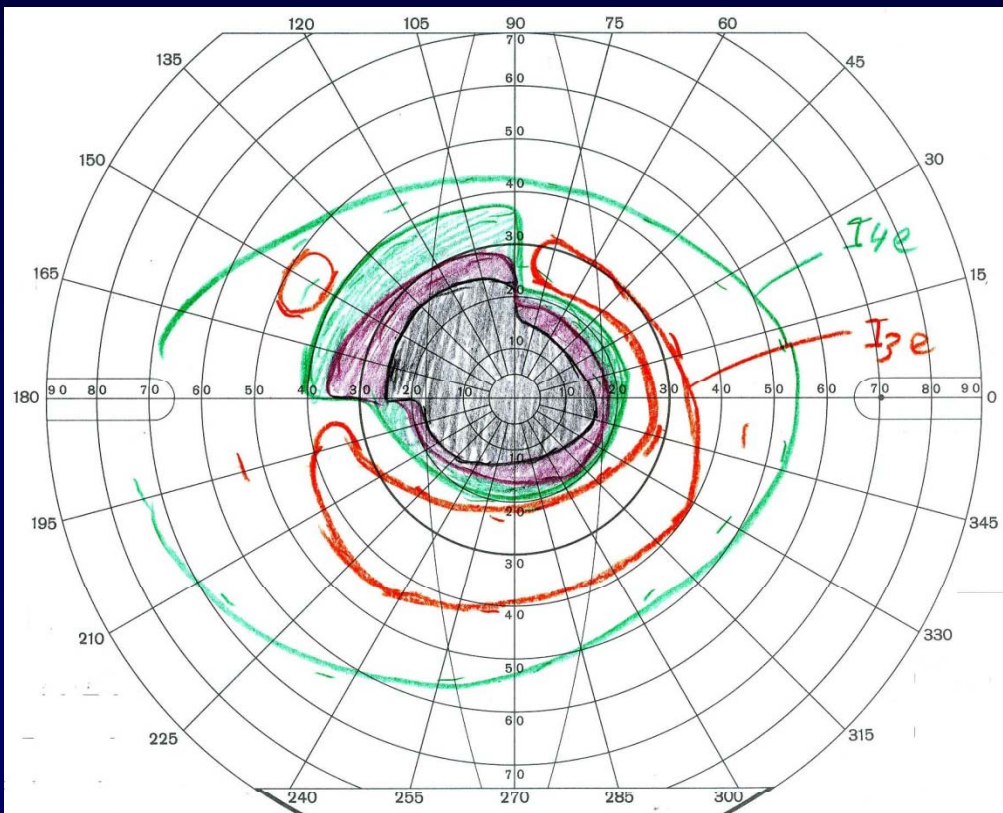
Glaucoma

# 14 yo girl

- Vision OS began to decline gradually without pain
- First visit with VA OD 20/40 and OS CF at 3'
- Pale, flat optic disks OU
- VA 1 month later CF at 3' OU
- VA 10 months later 20/20 OU
- Diagnosis LHON-like optic neuropathy

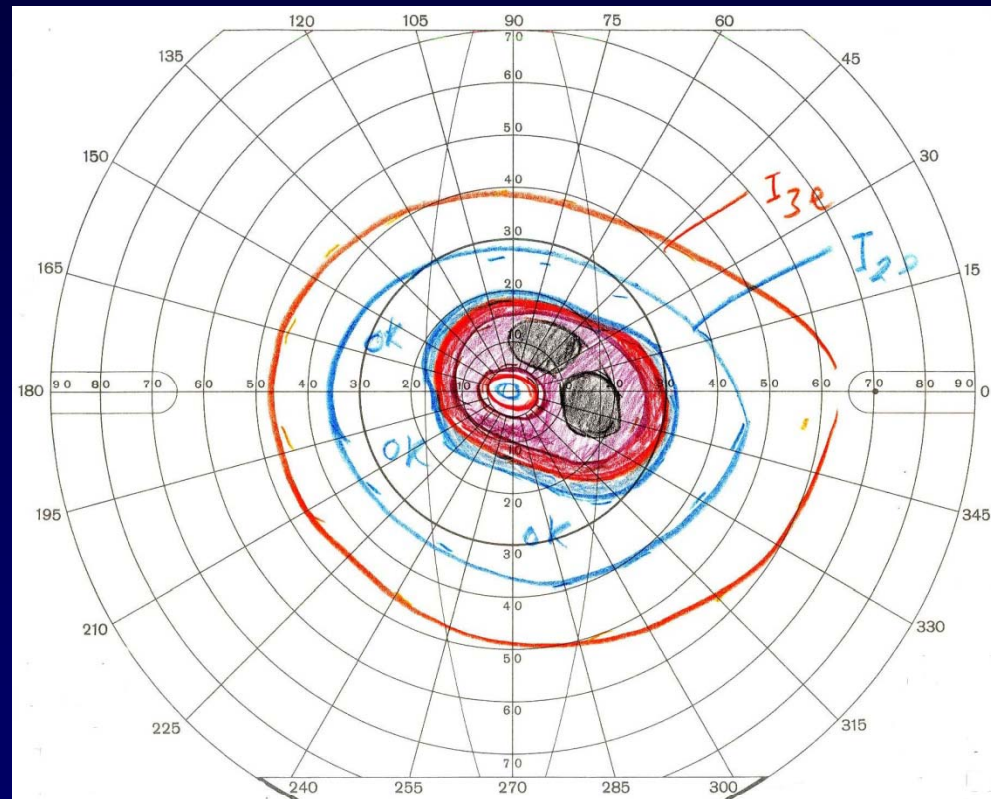
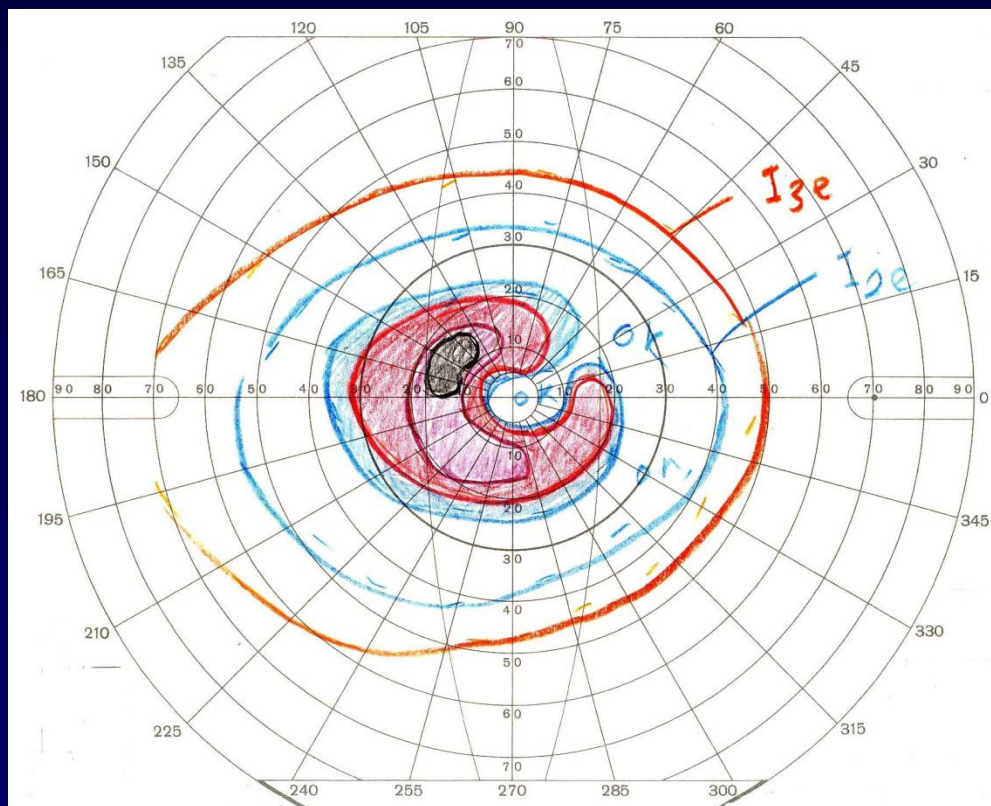


# VF 1 month later



234962-1

# VF 10 months later



234962-1

# Afferent Visual System

- During exam
- Neuro-imaging
- Blood tests
- Ultrasound
- Anatomy
- Examination
- Diagnoses
- Tests

# Tests

- During exam
- Neuro-imaging
- Blood tests
- Ultrasound
- Visual fields
- CT and B-scans
- Vasculitis (ESR, CBC, ANA, CRP)
- MRI scan
- VDRL
- ERG/VEP
- Orients (BUN, Creatinine, U/A)
- Carotid Doppler
- Liver function tests (SGOT, SGPT, alkaline phosphatase)
- Electrolytes
- Genetic evaluation