





# Components of the course

- Lectures
- Clinics
- OR
- Clinical sessions

# Marks distribution

- 40 marks for the MCQs
- 60 marks for the OSCE



## 2. References

- Vaughan and Asbury's general Ophthalmology  
By: Paul Riordan-Eva (published by LANGE)
- Clinical Ophthalmology: A Systematic Approach  
By : Jack T. Kanski (published by Butterworth Heinemann)







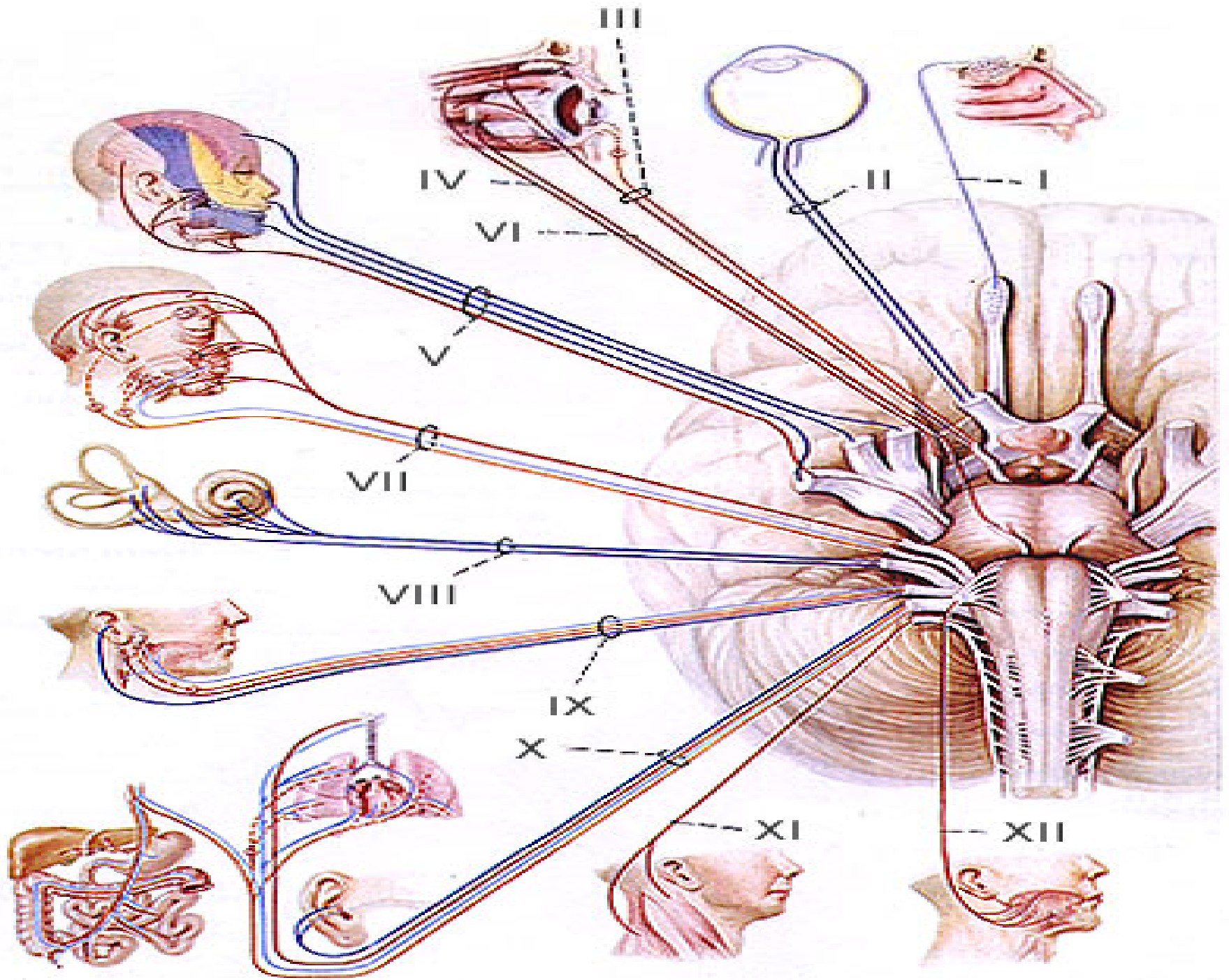
- Of all the organs of the body, the eye is most accessible to direct examination.
- The external anatomy of the eye is visible to inspection with unaided eye and with fairly simple instruments.
- The health or disease of a large portion of the body can be determined simply by looking at the eye.

- The eye is so intimately connected with the rest of the body that it reveals enormous amount of general information.
- Eye is the only part of the body where blood vessels and central nervous system tissues can be viewed directly.

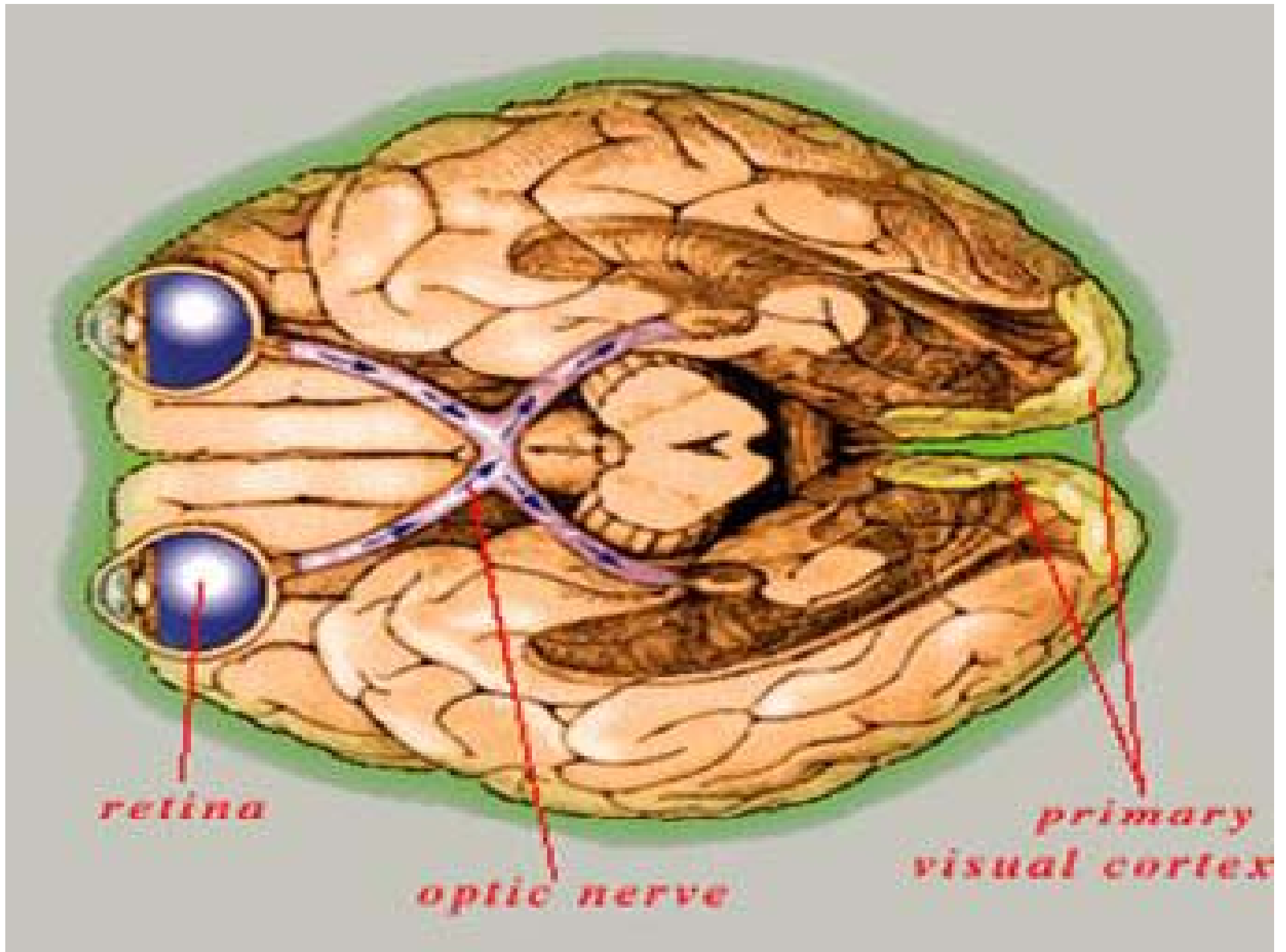




- The 12 cranial nerves provide us with a large part of our information about the brain. Of these , the eye examination evaluates CN II, III, IV, V, VI, VII, VIII.
- In addition, it provides information about the autonomic pathways. (*sympathetic /parasympathetic*)

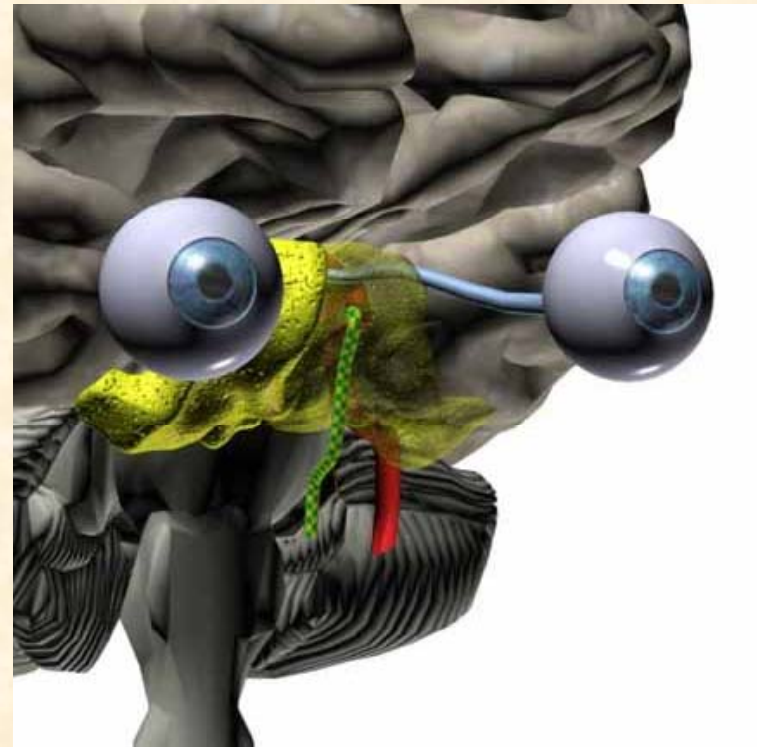
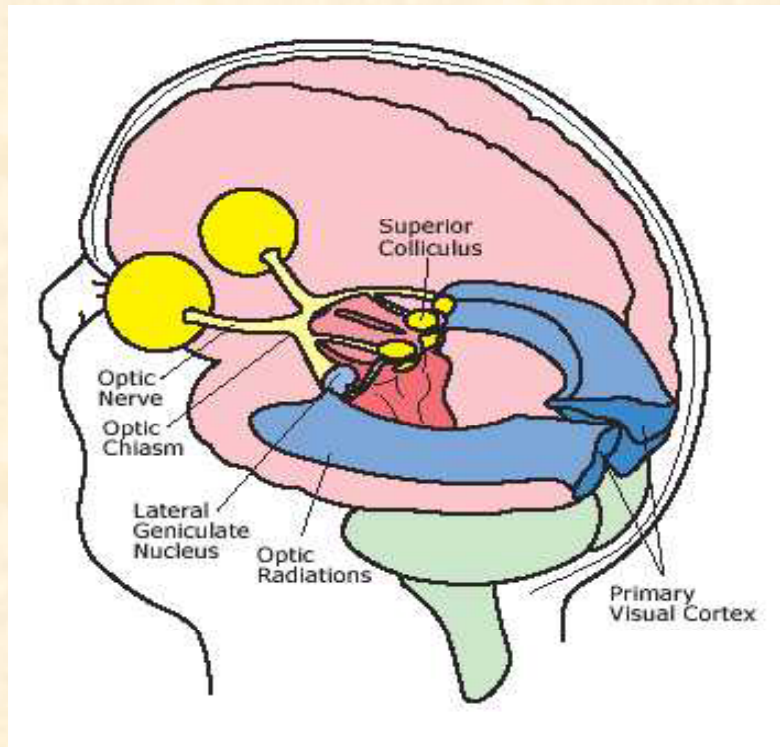


- ④ The best known connection between the brain and the eye is the ON.
- ④ The visual pathways, which extends from front to back across the brain can be studied easily and safely using perimetry. It can differentiate accurately between lesions of the temporal, parietal, and occipital lobes.

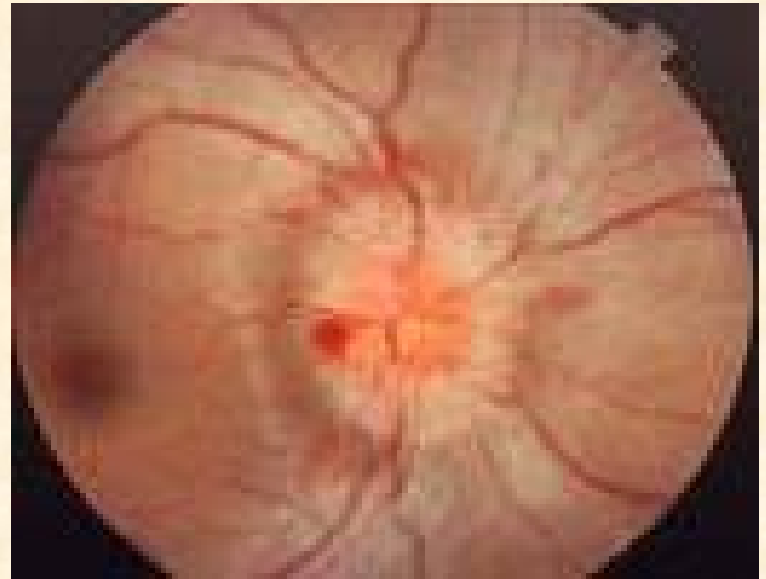



- In addition, the ON has important clinical relationships to the pituitary gland, the middle ventricles, the venous sinuses, the meningeal and bony structures of base of the skull.

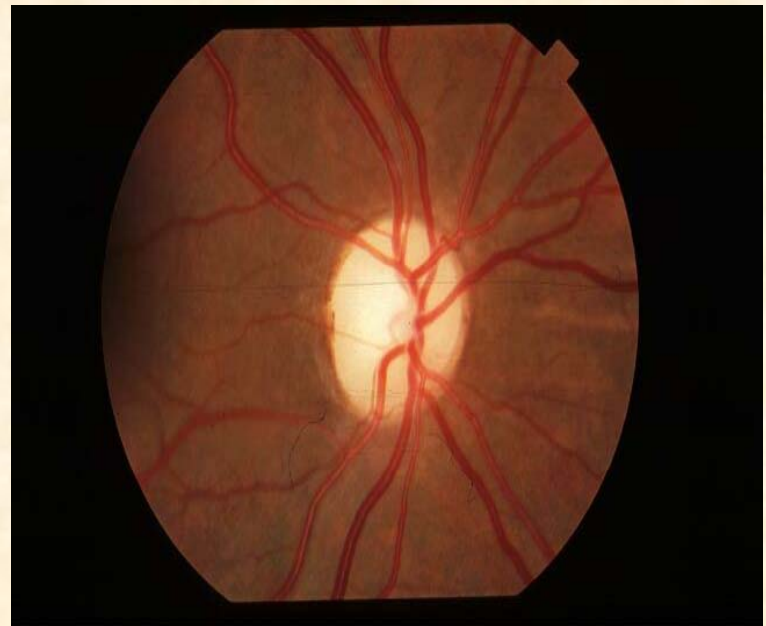


ON has the diagnostically useful capability of swelling with  $\uparrow$  ICP (*papilledema*).

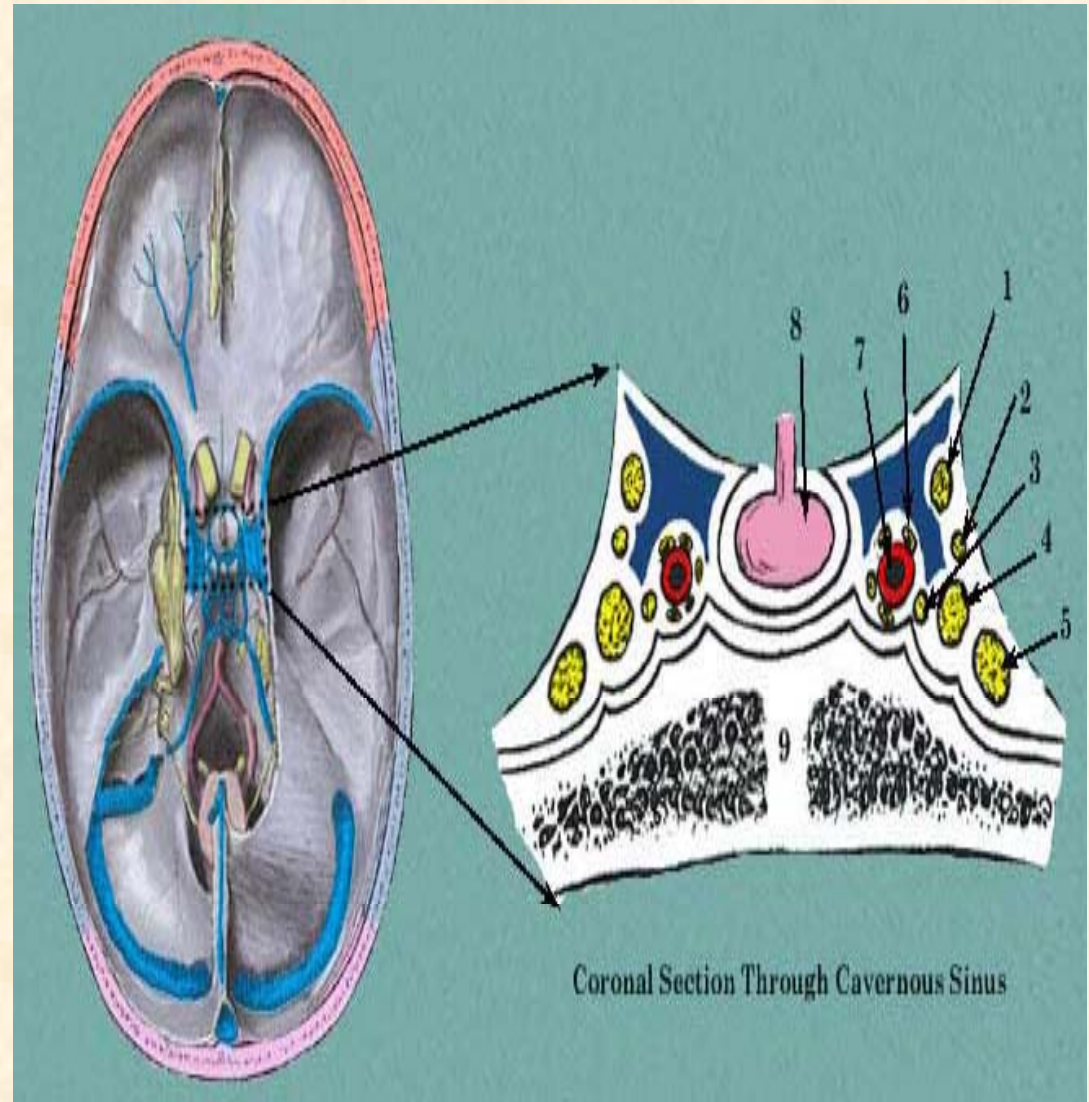


Or

visibly pale (*optic atrophy*) when its nerve fibers damaged at any point from Retina  $\rightarrow$  LGB.



The study of **CN III, IV, V, VI** can evaluate the brain stem, cavernous sinus, and apex of orbit.

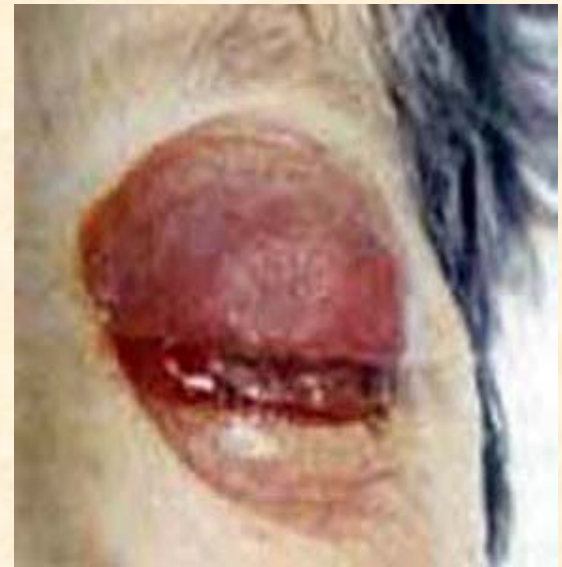
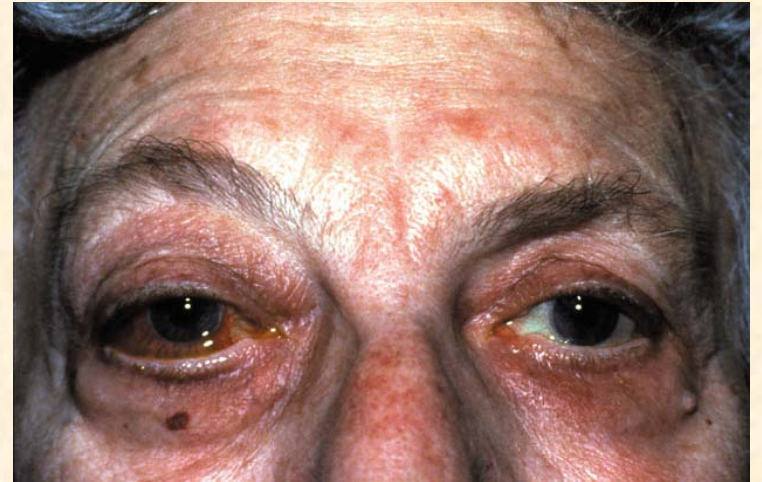
- ④ Unilateral dilated pupil after head injury can occur due to pressure on pupil constrictor fibers of CN III.
- ④ CN VI involved in mastoid infection (petrous ridge)
- ④ Parotid gland, Inner ear disease → CN VII.
- ④ Nystagmus → CN VIII





❖ Venous flow disorder:  
cavernous sinus thrombosis,  
carotid – cavernous fistula  
(orbital congestion)



- ❖ Arterial emboli can reach the retina from carotid artery , heart valves, subacute endocarditis.
- ❖ Specific disease of the vessels like: PAN, temporal arteritis, HTN.



❖ Hematological disorders of all types can manifest in the fundus.

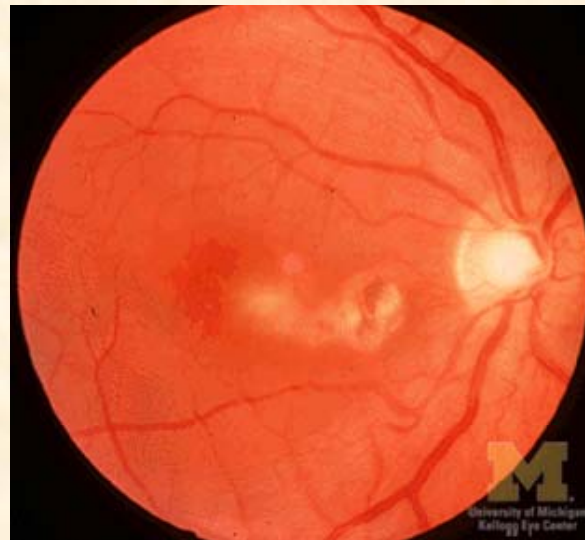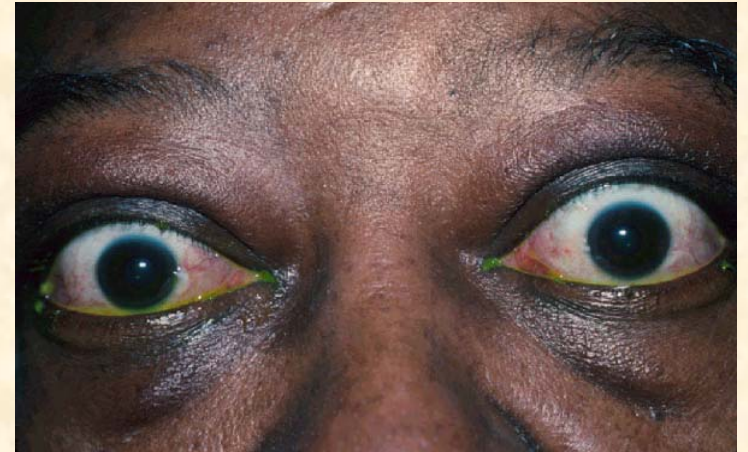❖ Almost all metabolic disorders can affect the eye:

**DM** :DR, cataract, RE, ophthalmoplegia.

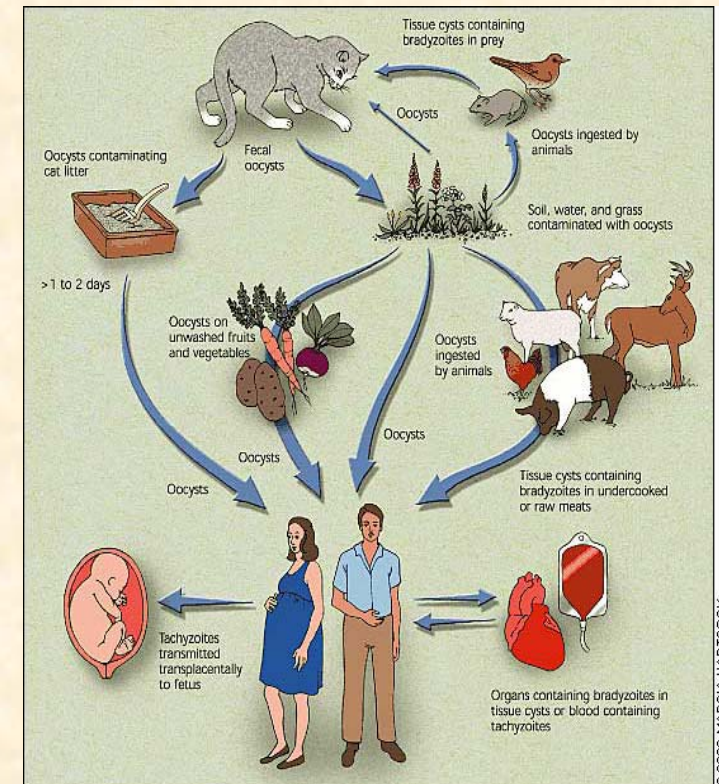
**Hypothyroidism** : cataract

**Wilson's disease**.

❖ Thyroid eye disease:  
Exophthalmos, Lid retraction.



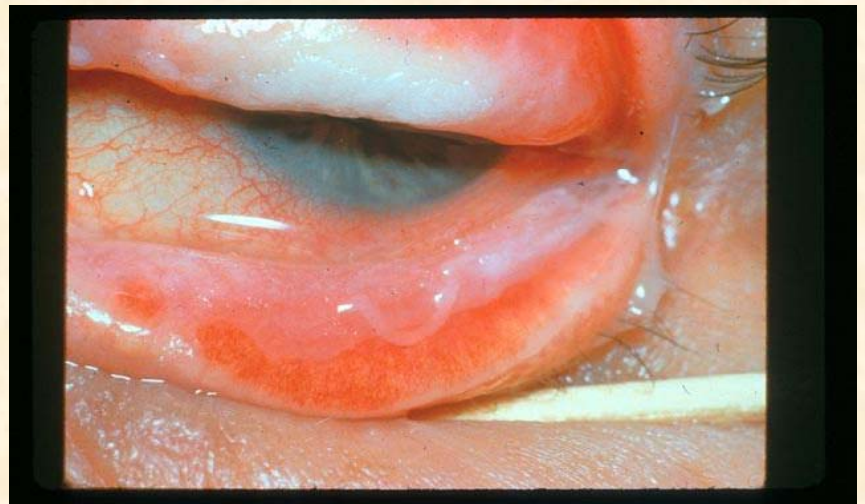
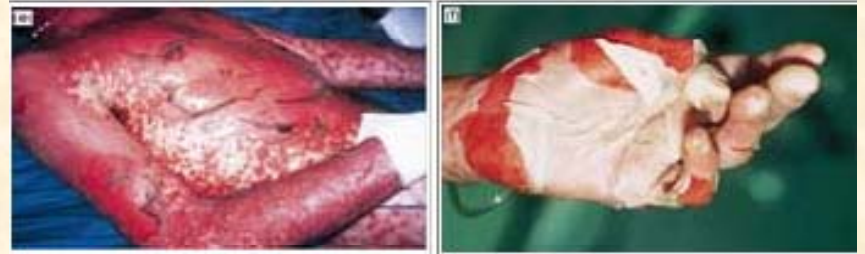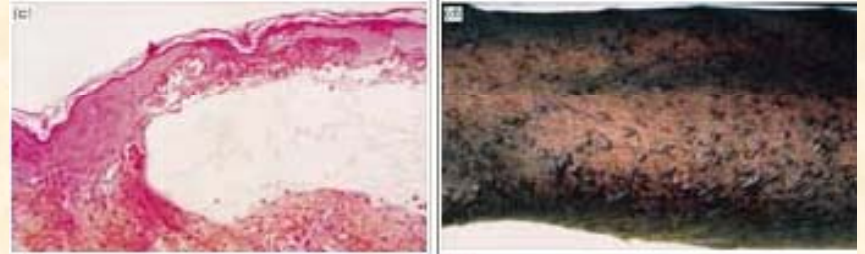
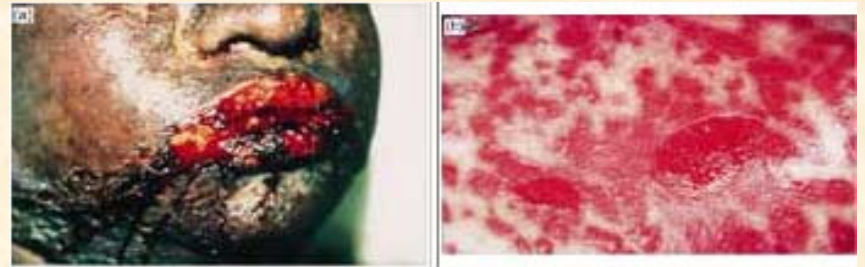❖ Infections:  
(Syphilis, Toxoplasmosis, Rubella)



❖ Mucocutaneous disorders:  
SJS, pemphigus

❖ Elastic tissue:  
(Pseudoxanthoma elasticum)

❖ Allergy: VKC



❖ Chromosomal abnormalities:

Trisomy: 13, 15, 21.

❖ The eye is a delicate indicator of poisoning:

-Morphine addict → meiotic pupil

-Lead poisoning, vitamin A intoxication

→ papilledema

- I could go on and on about the discoveries possible in our most important square inch. **"EYE"**

- 90% of our information reaches our brain via sight.

- Unfortunately, of all the parts of the body, the eye is the most vulnerable to minor injury.



- Obtain an ocular and systemic history.
- Determine the optical and health status of the eye and visual system.
- Identify risk factors for ocular and systemic disease.
- Detect and diagnose ocular diseases.

- Establish and document the presence or absence of ocular symptoms and signs of systemic disease.
- Discuss the nature of the findings and the implications with the patient.
- Initiate an appropriate response.  
e.g. further diagnostic tests, treatment, or referral.



An antique book with a dark green, textured cover and a gold-tooled spine. The word "HISTORY" is written in a white, elegant cursive font across the front cover. The book is bound in a traditional style with visible raised bands on the spine. A small, reddish-brown ribbon bookmark is tucked into the bottom of the book. The book is set against a plain, light brown background.

*HISTORY*

- ④ It is a gathering information process from the patient guided by an educated and active mind.
- ④ It is a selective guided and progressive elicitation and recognition of significant information
- ④ History by skilled person can arrive at the proper diagnosis in 90% of patients.

- ④ It gives vital guidance for:
  - (a) physical examination
  - (b) laboratory work
  - (c) Therapy

❖ Failure to take history can lead to missing vision or life threatening conditions.

Chief complaint: *"The patient's own words"*

"she cannot see with the RE"

You should not come to conclusion that her problem is nearsightedness and write down "Myopia of RE".

- The patient needs will not be satisfied until he/she has received an acceptable explanation of the meaning of the chief complaint and its proper management.

## History of the Present Illness:

- ④ Detailed description of the chief complaint to understand the symptoms and course of the disorder.
- ④ Listen and question and then write down in orderly sequence that make sense to you.

- \* The time sequence  
when, How fast, what order did events occur?
- \* Frequency, intermittency
- \* location, Laterality
- \* Severity
- \* Associated symptoms
- \* Documentation (old records, photo)  
e.g ptosis, proptosis, VII N palsy.

- gradual painless decrease vision both eyes for 1y.
- Sudden painless decrease vision RE for 10 min.

## "cannot see with RE"!!

- ? Only distance vision blurred.
  - ? Blind spot is present in the center of VF
  - ? Right side of VF of the RE lost
  - ? Right VF of both eyes lost
  - ? A diffuse haze obscures the entire field of RE
- 
- ❖ *Each of these has different diagnostic implication*
  - ❖ *Most pt. has difficulty providing precise and concise description*

# Disturbances of vision:

- Blurred or decreased central vision
- Decreased peripheral vision. (glaucoma)
- Altered image size.  
(micropsia, macropsia, metamorphopsia).
- Diplopia (monocular, binocular)
- Floaters
- Photopsia (flash of light)



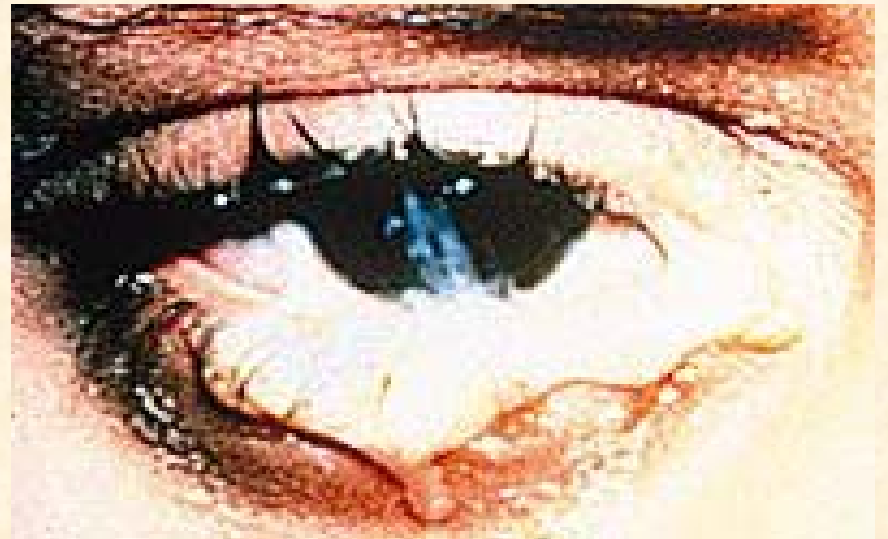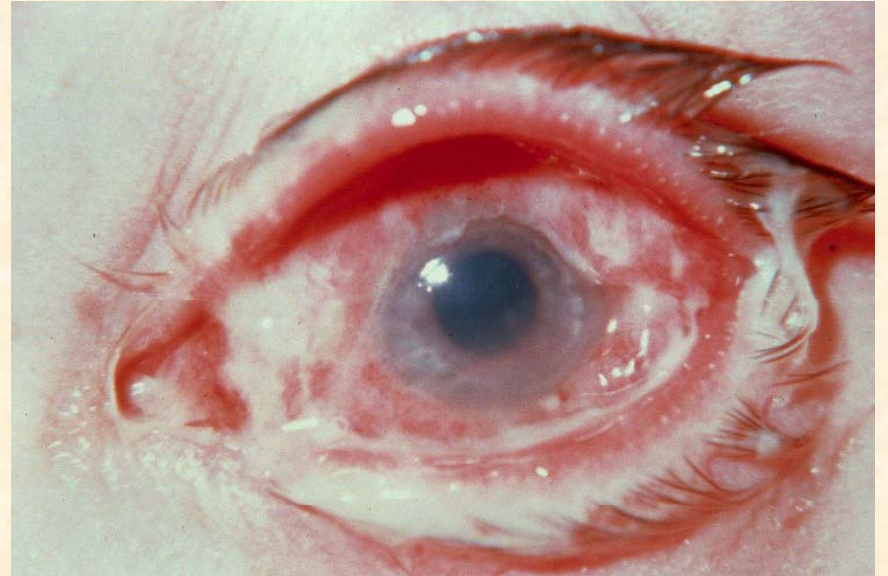- Color vision abnormalities.
- Dark adaptation problems.
- Blindness  
(ocular, cortical).
- Oscillopsia  
(shaking of images).

# Ocular pain or discomfort:

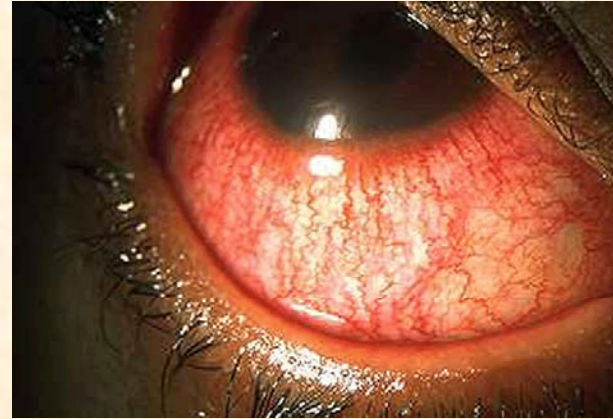
- Foreign body sensation
- Ciliary pain  
(aching, severe pain in or around the eye, often radiating to the ipsilateral forehead, molar area)
- Photophobia
- Headache
- Burning
- Dryness
- Itching: patient rub the eye vigorously (allergy)
- Asthenopia (eye strain)

## Abnormal ocular secretions:

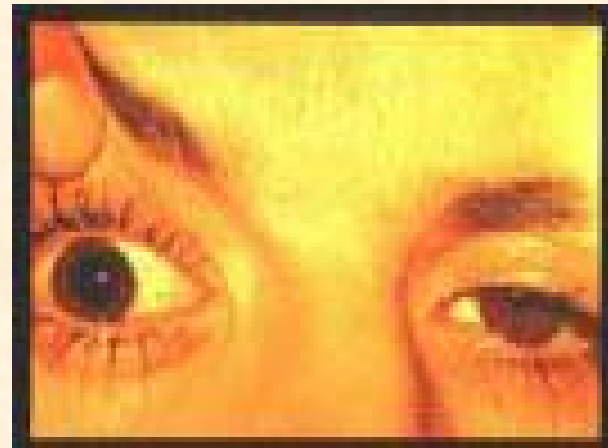- Lacrimation, epiphora
- Dryness
- Discharge  
(purulent, mucopurulent, mucoid, watery)



- Redness, opacities, masses



- Anisocoria



# Family history:

- Many eye conditions are inherited

RE, glaucoma, strabismus, retinoblastoma, neoplastic, vascular disorders

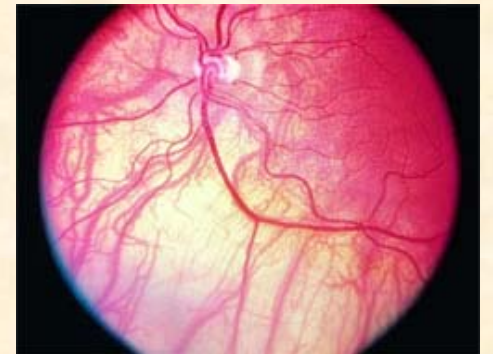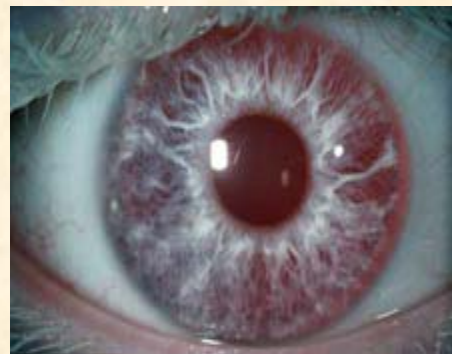
- Familial systemic disease can be helpful in ophthalmic evaluation and diagnosis

Atopy, thyroid diseases, DM, certain malignancies.

- Ask about any eye problem in the family background?



- Ask specifically about corneal diseases, glaucoma, cataract, retinal diseases or other heritable ocular conditions.



④ Ask questions designed to confirm or exclude your tentative diagnosis

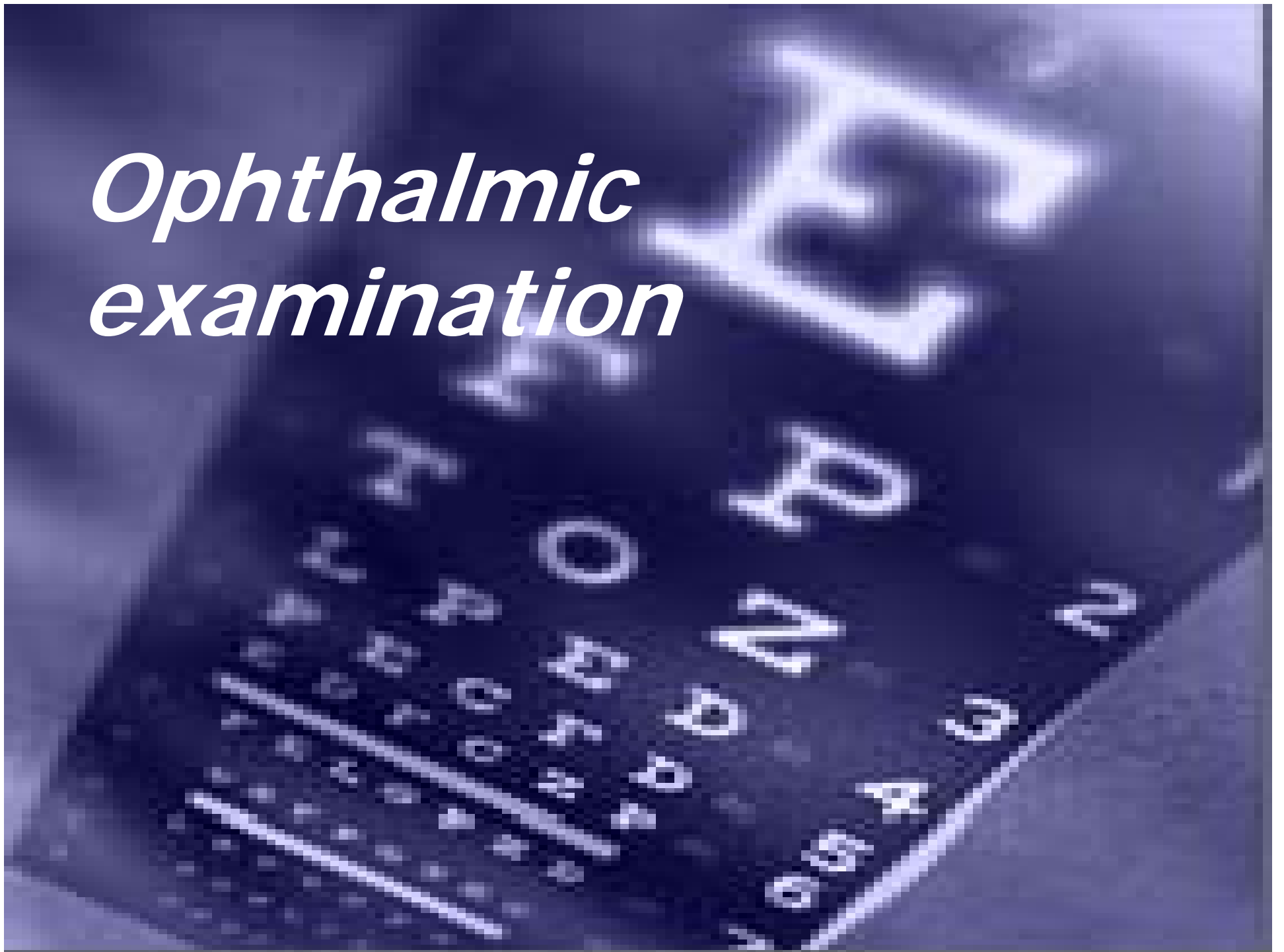- significant positive
- significant negative

“Significant is equal to expected”

④ predict the physical and lab. finding likely to be present.

④ any discrepancy between the history and physical examination requires explanation

# *Ophthalmic examination*





*The Purpose is to evaluate:*

1. Function
  - visual
  - non visual
    - eye movement
    - alignment
2. Anatomy
  - the adnexa (lid and periocular tissues)
  - the globe
  - the orbit

# Ophthalmic examination

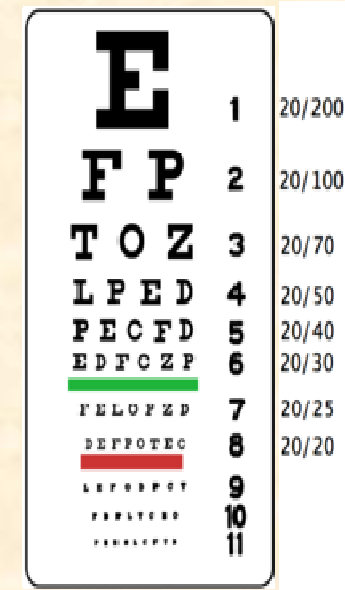

- Visual acuity
- External examination
- Motility and alignment
- Pupil examination
- Slit lamp biomicroscopy
- Tonometry
- Ophthalmoscopy
- Gonioscopy
- Retinoscopes

# Vision:

- Vital sign (MUST)
- Good vision
  - intact neurological visual pathway
  - structurally healthy eye
  - Proper focus
- Subjective

# How to test the vision?

- display of different –sized targets shown at a standard distance from the eye.
- Snellen chart.
- 20/20, 6/6
- Uncorrected, corrected

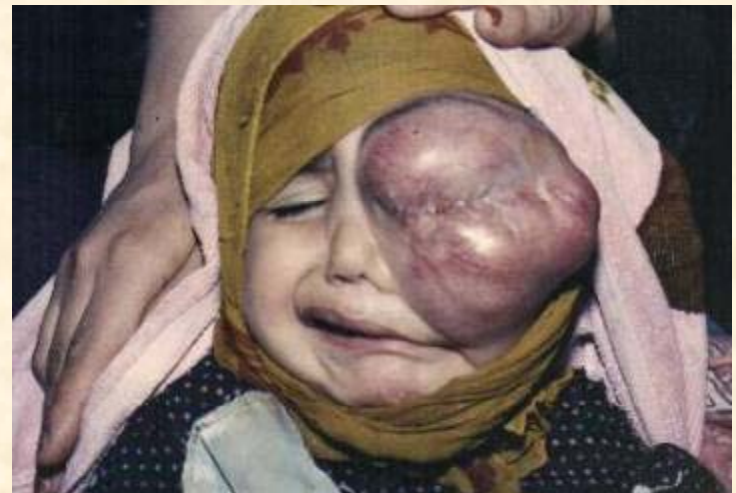
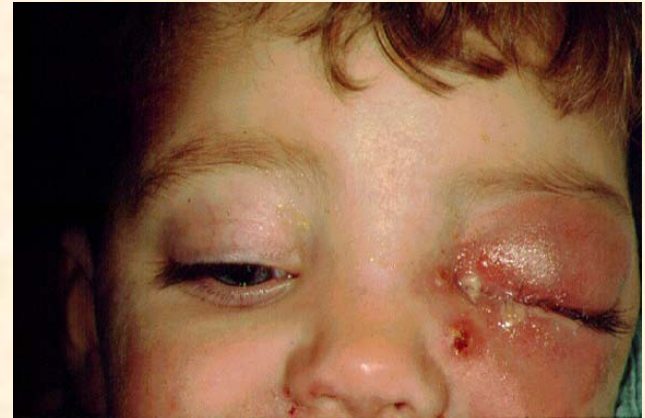
# Testing poor vision:

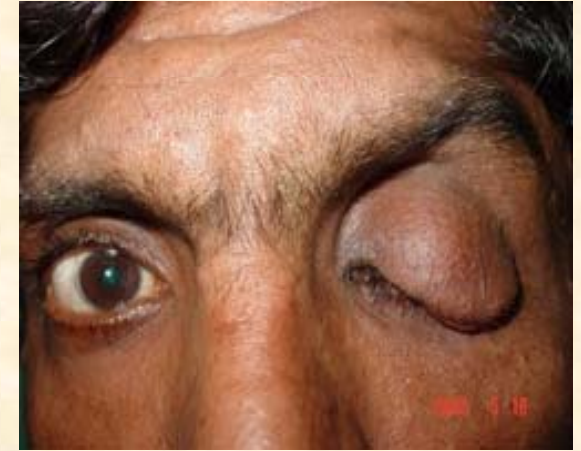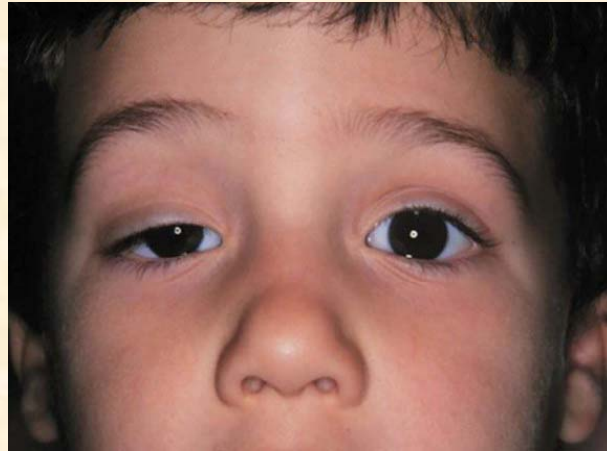- If the patient is unable to read the largest letter <(20/200)
- Move the patient closer e.g. 5/200
- If patient cannot read:
  - count fingers (CF)
  - hand motion (HM)
  - Light perception (LP)
  - No light perception (NLP)

# External examination:

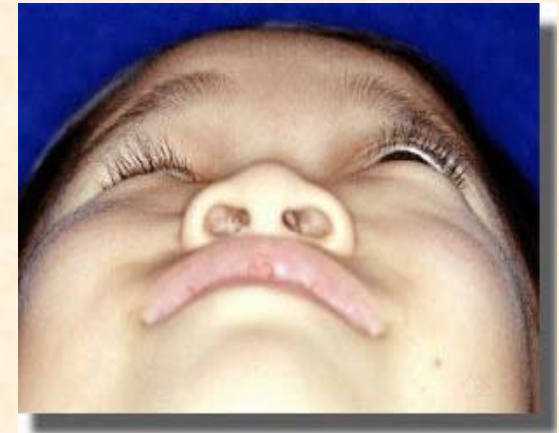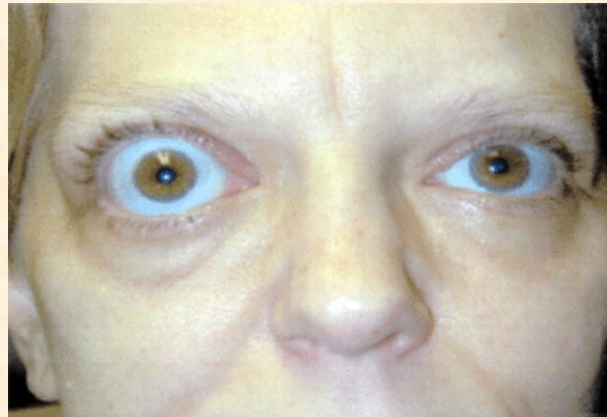- Evaluate by gross inspection and palpation.
- Ocular adnexa. (lid, periocular area)
- Skin lesions, growths, inflammatory lesions.



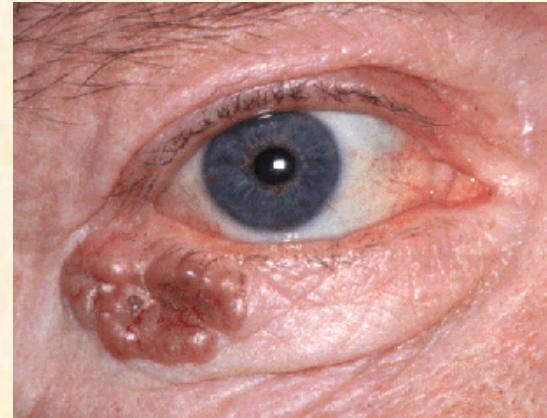
- Ptosis



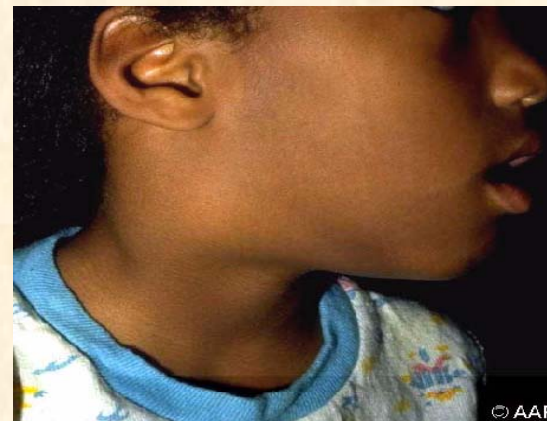- Proptosis,  
exophthalmos,  
enophthalmos



- Palpation of bony rim, periocular soft tissue.



- General facial examination e.g. enlarged preauricular lymph node, temporal artery prominence.

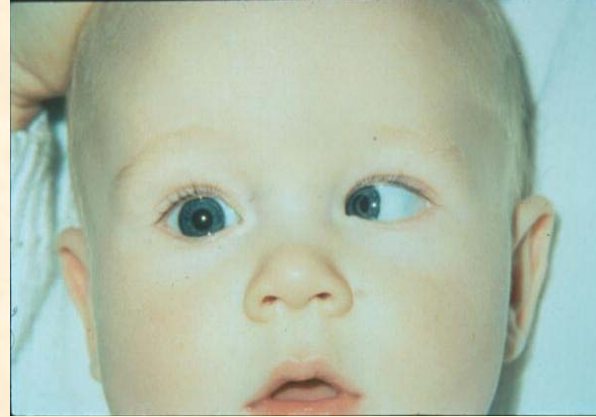



# Ocular motility:

*Evaluate* - *Alignment*  
- *Movements*

- Misalignment of the eyes



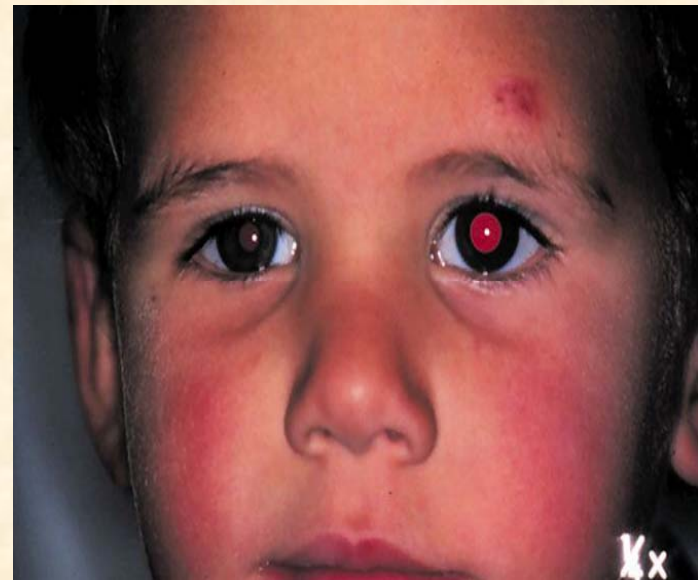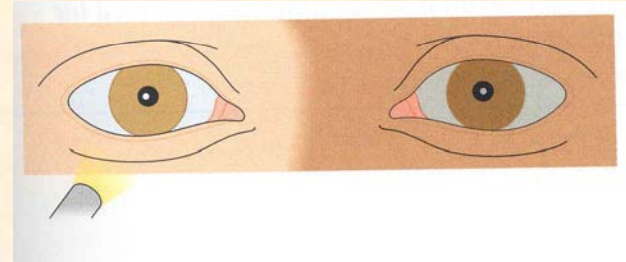
## Movement:

- Follow a target with both eyes in each of the four cardinal directions of gaze.
- Note
  - speed
  - smoothness
  - range
  - symmetry
  - unsteadiness of fixation  
e.g nystagmus

# Pupils:

Examine for size, shape, reactivity to both light and accommodation.

- Direct response and consensual response.
- Afferent pupillary defect (Marcus Gunn pupil)
- Efferent pupillary defect.



- Pupillary abnormalities:
  - neurologic disease
  - previous inflammation – adhesion
  - acute intraocular inflammation - spasm
    - atony
  - prior surgical trauma
  - effect of systemic or eye medication
  - benign variation of normal

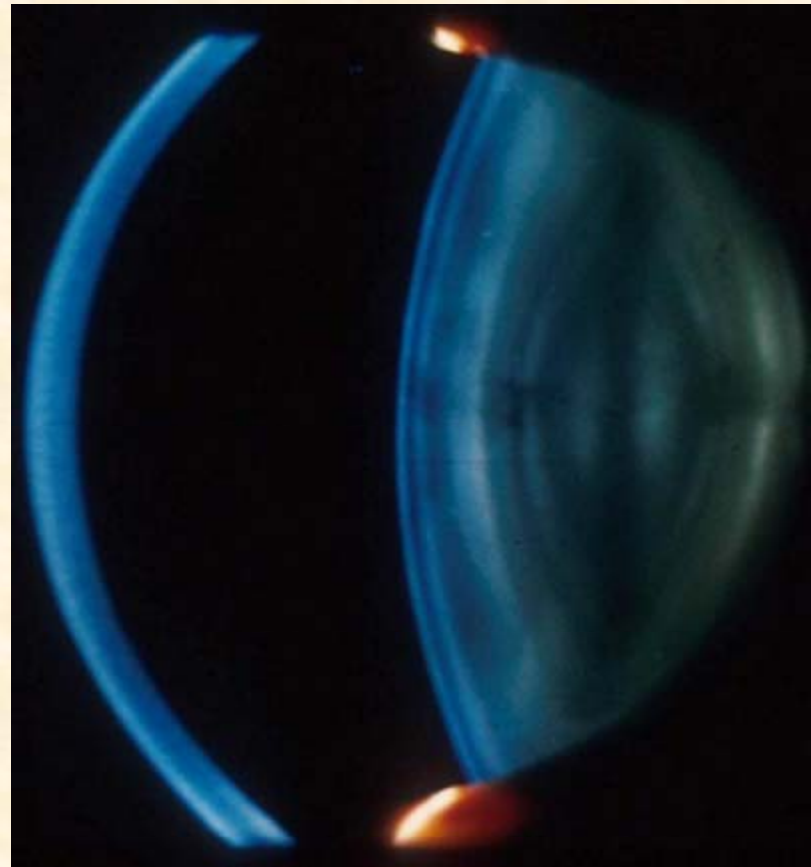
# Slit lamp examination:

Is a table-mounted binocular microscope with special illumination source.

A linear slit beam of light is projected onto the globe – optic cross section of the eye.



- Slit lamp alone, the anterior half of the globe (anterior segment) can be visualized.



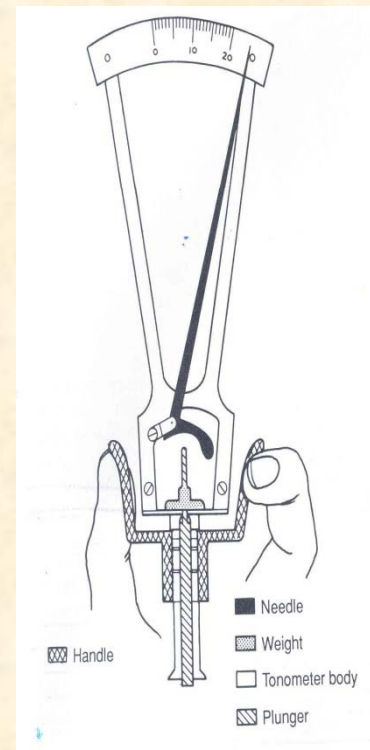
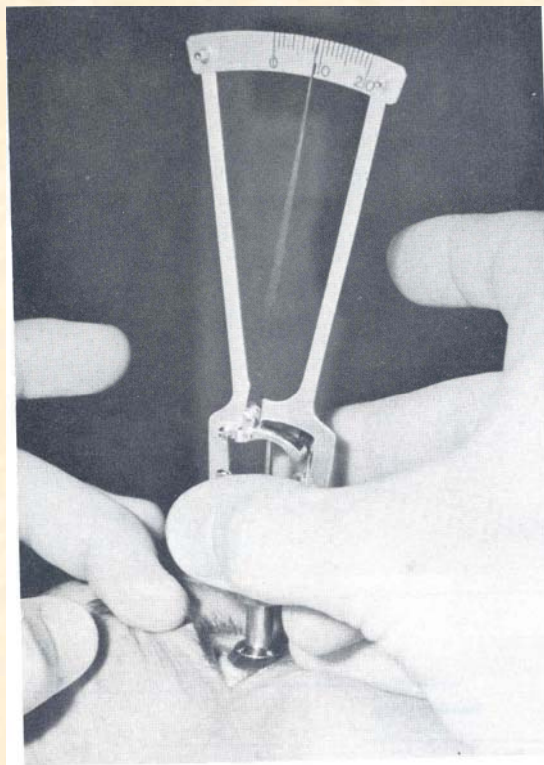
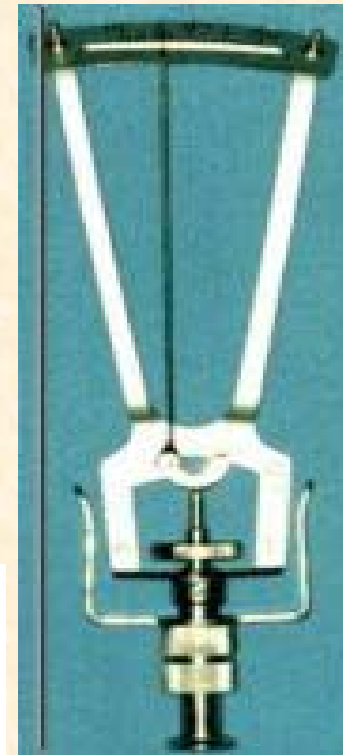
# Tonometry:

- The globe is a closed compartment with constant circulation of aqueous humor.
- This maintains the shape, and relatively uniform pressure within the globe.
- Normal pressure 10 – 20 mmHg.



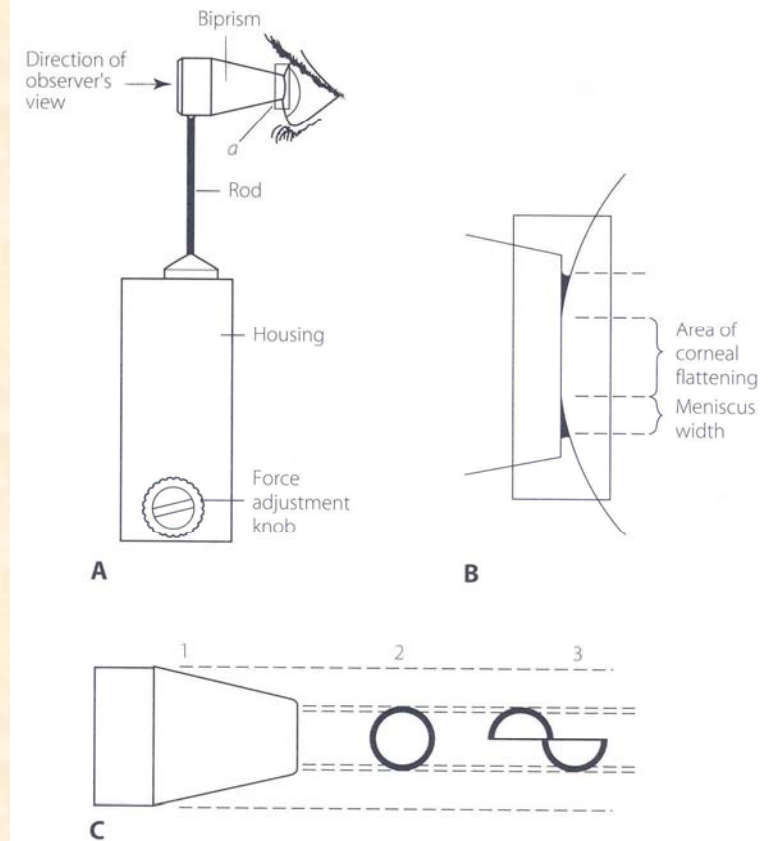
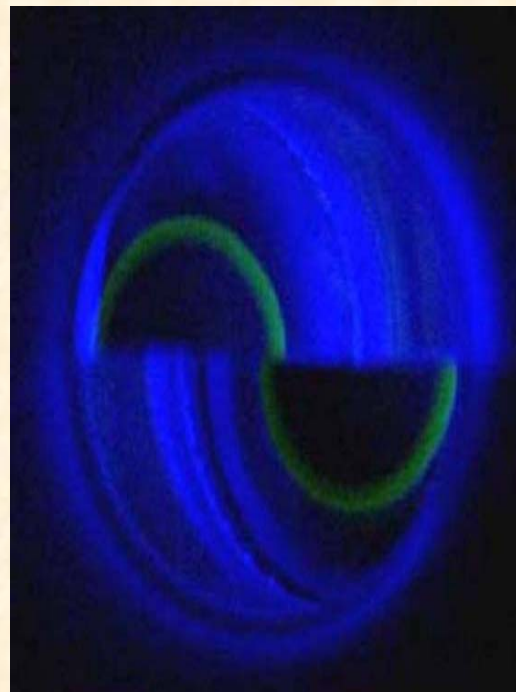
# Types of tonometry:

## Schiotz tonometer

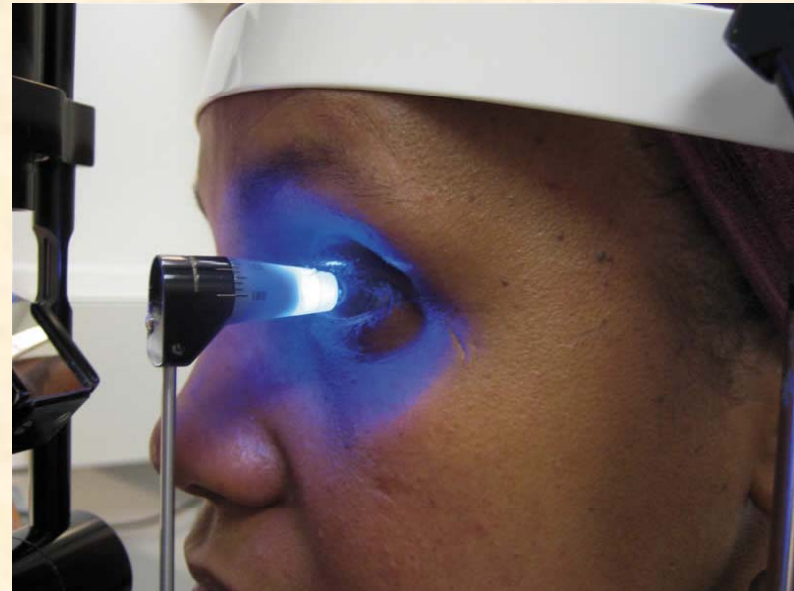

Scale Reading	Plunger Load			
	5.5 g	7.5 g	10.0 g	15.0 g
0.0	41.4	59.1	81.7	127.5
0.5	37.8	54.2	75.1	117.9
1.0	34.5	49.8	69.3	109.3
1.5	31.6	45.8	64.0	101.4
2.0	29.0	42.1	59.1	94.3
2.5	26.6	38.8	54.7	88.0
3.0	24.4	35.8	50.6	81.8
3.5	22.4	33.0	46.9	76.2
4.0	20.6	30.4	43.4	71.0
4.5	18.9	28.0	40.2	66.2
5.0	17.3	25.8	37.2	61.8
5.5	15.9	23.8	34.4	57.6
6.0	14.6	21.9	31.8	53.6
6.5	13.4	20.1	29.4	49.9
7.0	12.2	18.5	27.2	46.5
7.5	11.2	17.0	25.1	43.2
8.0	10.2	15.6	23.1	40.2
8.5	9.4	14.3	21.3	38.1
9.0	8.5	13.1	19.6	34.6
9.5	7.8	12.0	18.0	32.0
10.0	7.1	10.9	16.5	29.6
10.5	6.5	10.0	15.1	27.4
11.0	5.9	9.1	13.8	25.3
11.5	5.3	8.3	12.6	23.3
12.0	4.9	7.5	11.5	21.4
12.5	4.4	6.8	10.5	19.7
13.0	4.0	6.2	9.5	18.1
13.5	3.6	5.6	8.6	16.5
14.0	3.2	5.0	7.8	15.1
14.5	2.8	4.5	7.1	13.7
15.0	2.4	4.1	6.4	12.6
15.5	2.1	3.7	5.8	11.4
16.0	1.8	3.3	5.2	10.4
16.5	1.5	3.0	4.7	9.4
17.0	1.3	2.7	4.2	8.5
17.5	1.1	2.4	3.8	7.7
18.0	0.9	2.2	3.4	6.9
18.5	0.8	2.0	3.1	6.2
19.0	0.7	1.8	2.8	5.6
19.5	0.6	1.6	2.6	5.0
20.0	0.5	1.5	2.4	4.5

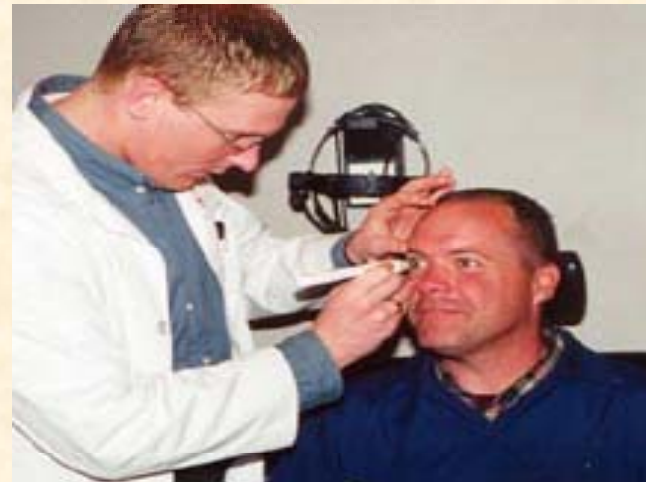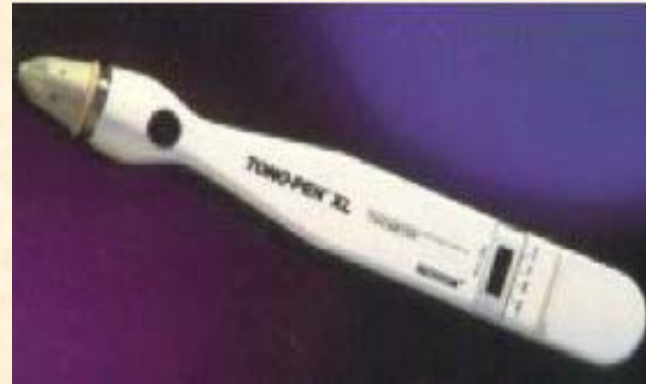# Goldman tonometer



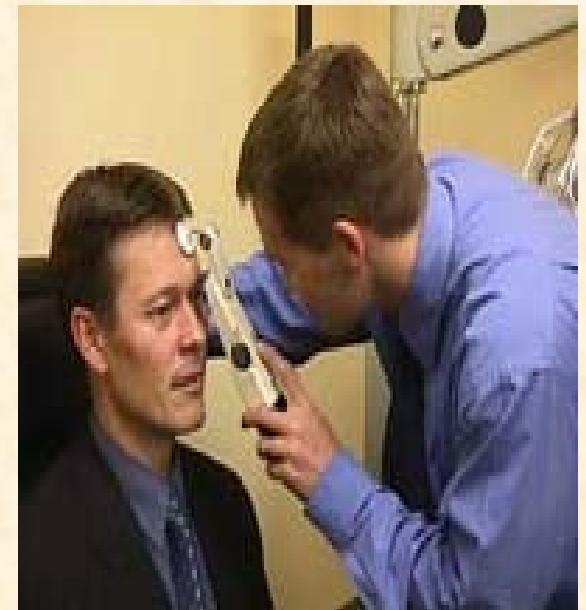- Glodmann  
applanation  
tonometer



# Tonopen tonometer



# Perkin tonometer



Air-puff tonometer



## Diagnostic medication:

1. Topical anesthesia e.g. tetracaine, benoxinate used prior to ocular contact with diagnostic lenses instruments and also before corneal scrapping.





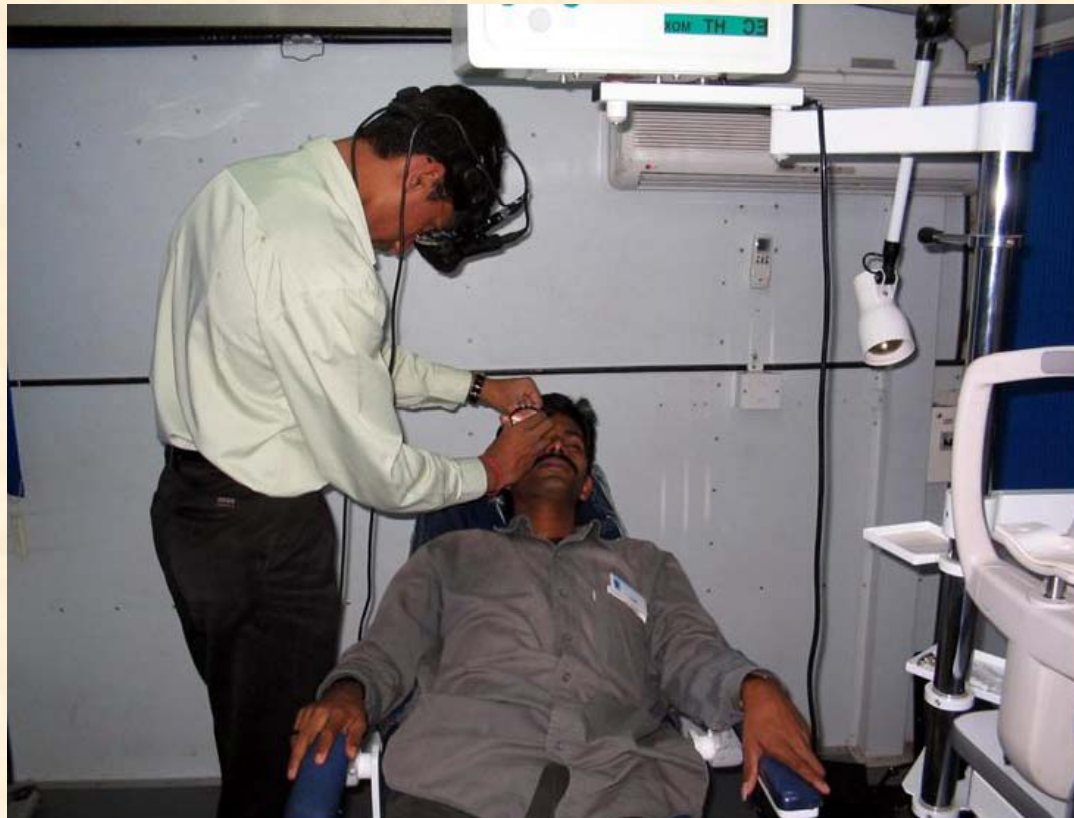# Ophthalmoscopy:

- *Direct ophthalmoscopy:*
- handheld instrument.
- standard part of the general medical examination.
- Portable

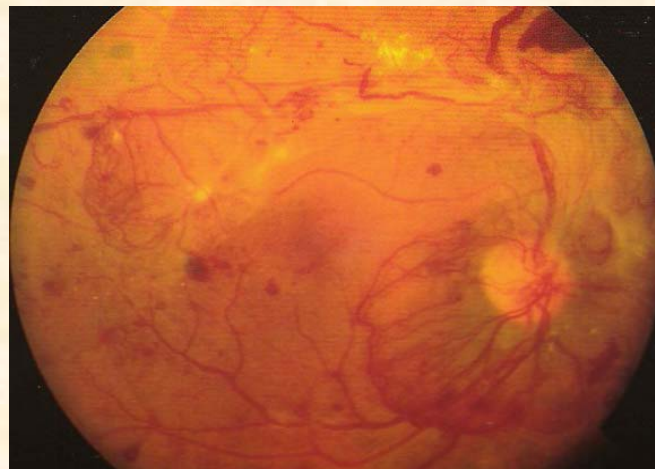
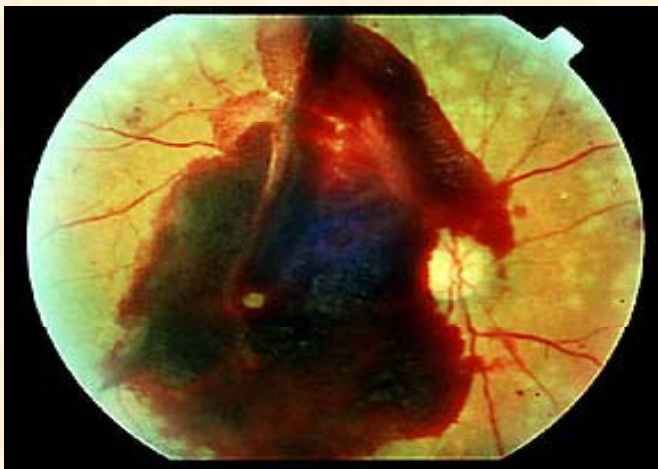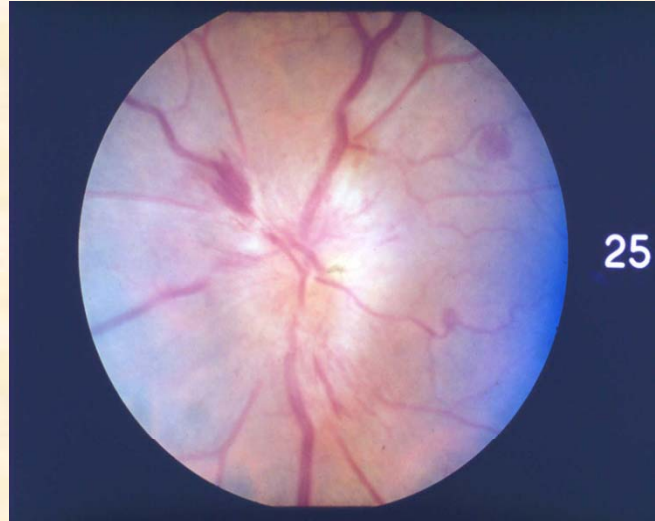

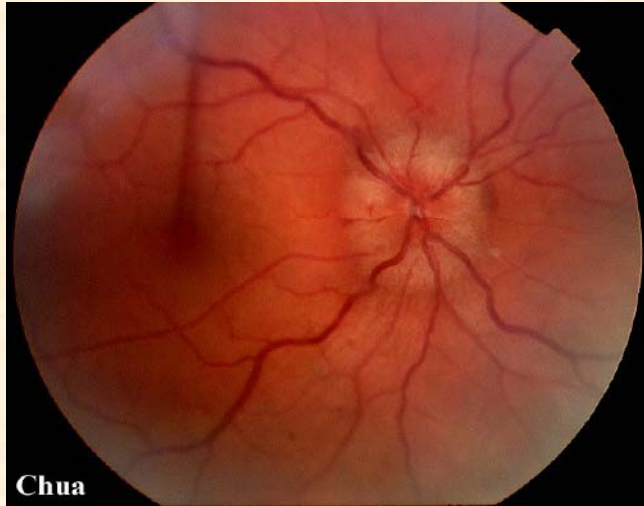
# *Indirect ophthalmoscope*





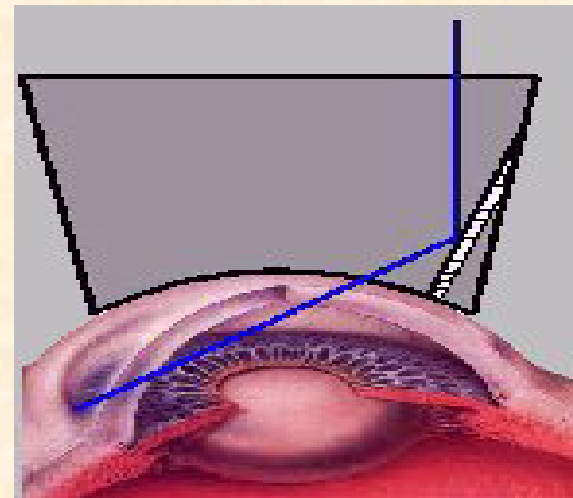
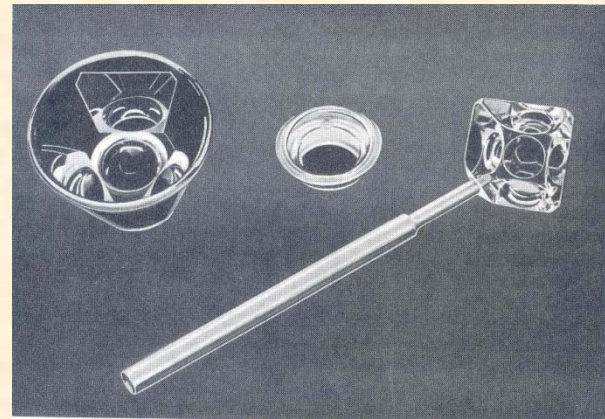




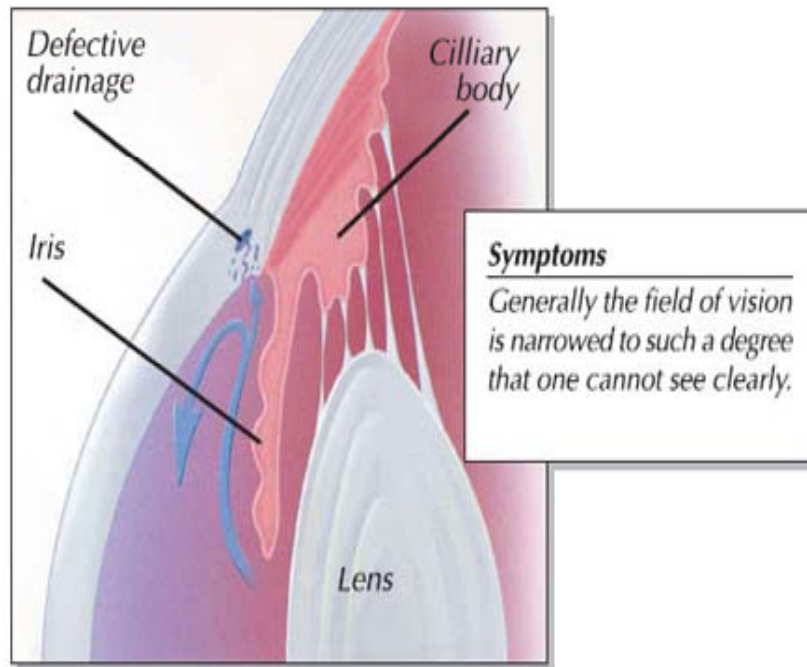
Disadvantage:

1. Inverted retinal image.
2. Brighter light is uncomfortable to the patient.

- Special lenses:
  - Goniolens
  - other lenses allow evaluation of the posterior segment.

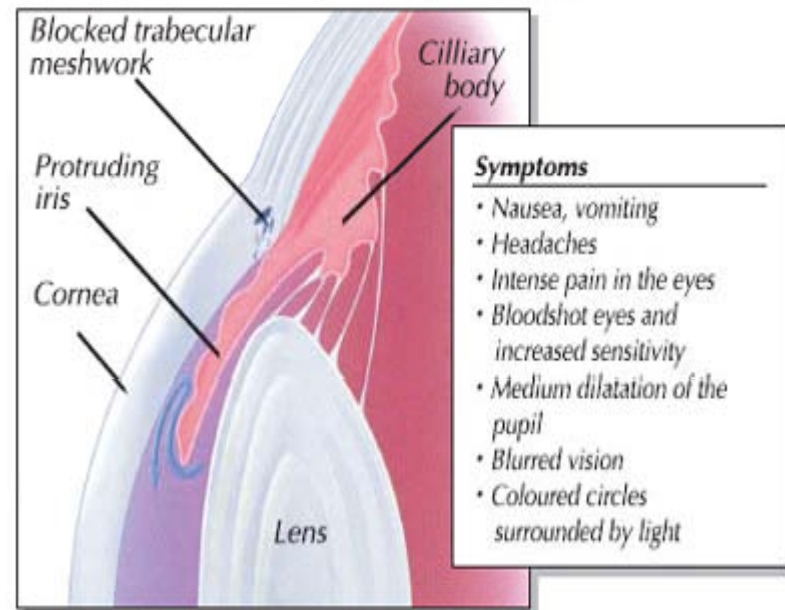


## OPEN ANGLE GLAUCOMA



The angle is open but drainage is defective.

## CLOSED ANGLE GLAUCOMA



The angle between the iris and the cornea narrows or closes, blocking the drainage of the aqueous humor.



# Retinoscope

