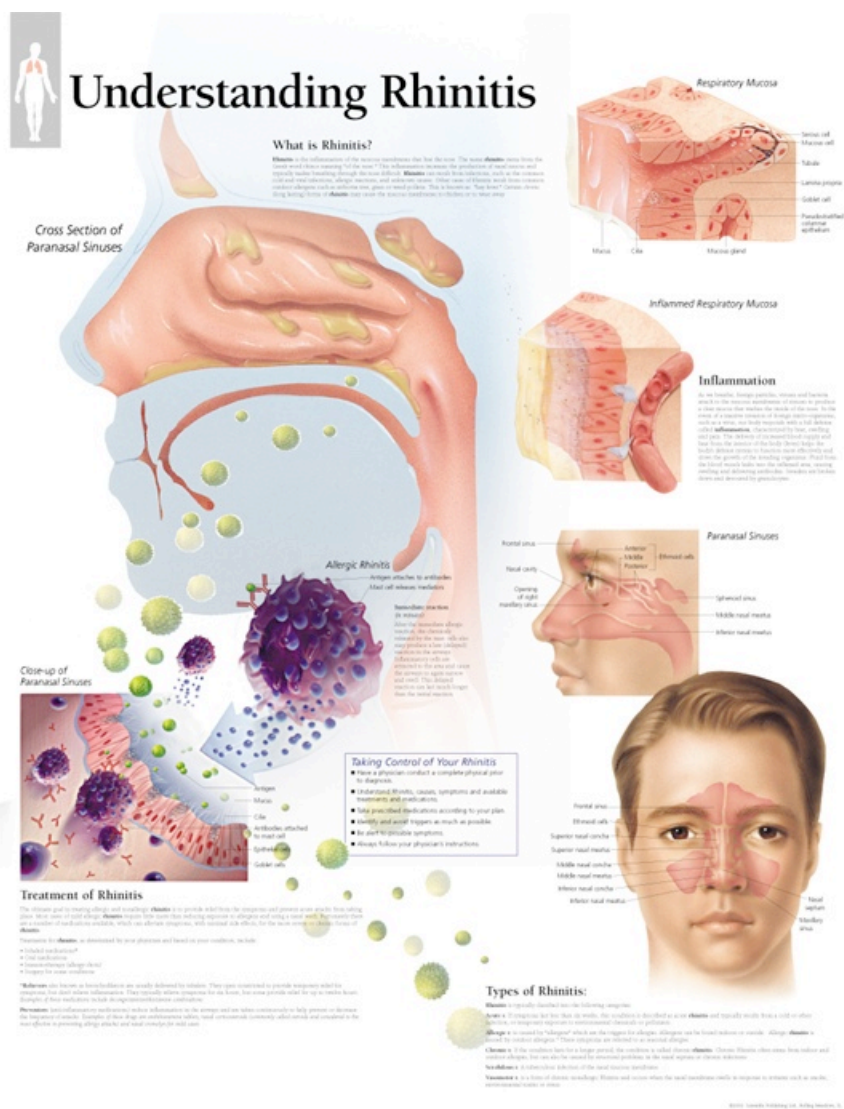

Nose 2 (Rhinitis)

429 ENT Team (F2)

Sources: - Dr. Sameer Bafaqeeh's lecture. - ENT Team Notes (Nose 2).

- LECTURE NOTES ON Diseases of the Ear, Nose and Throat by P.D. BULL, Ninth Edition

Objective:

- Acute and chronic rhinitis
- Allergic and non-allergic rhinitis
- Vestibular and furunculosis
- Nasal polyps (allergic and antrochoanal) etc
- Radiology illustration (e.g. CT scan)

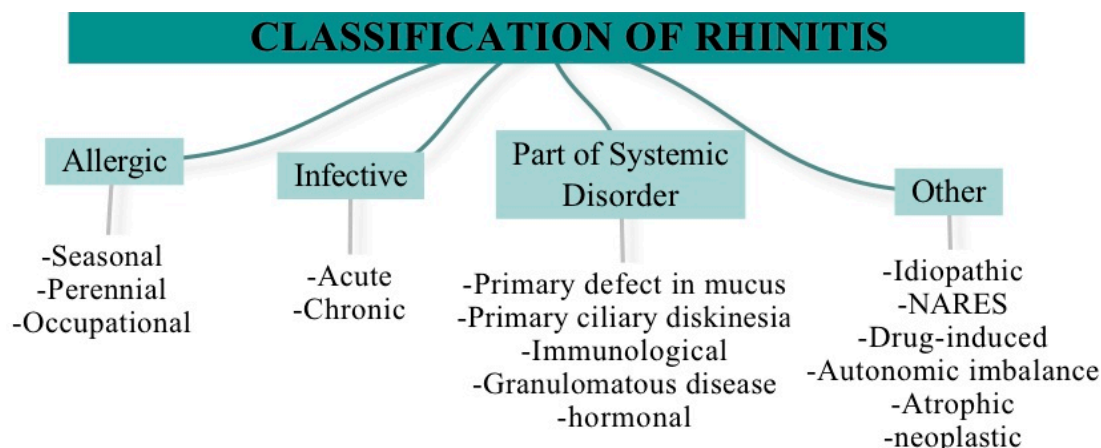
Done by: Nourah AlSyefi

Introduction:

- * Rhinosinusitis: Disease of the nose that has the similar findings in the sinuses because they are all lined by the same columnar ciliated epithelium.
- * All sinusitis causes must be coming from the nose
- * As well as causing typical symptoms, rhinitis can significantly impair quality of life.
- * While seasonal allergic rhinitis (hay fever) is confined to the pollen season, allergic rhinitis is often perennial.
- * Allergic factors can be identified easily & specific avoidance or therapy prescribed.
- * AR in the last years due to pollution >> increased allergen >> sensitizations.
- * AR & asthma usually coexist and proper treatment of the nose will lead to pulmonary improvement.
- * Any obstruction around the osteomeatal complex will lead to sinusitis and rhinosinusitis

Incidence:

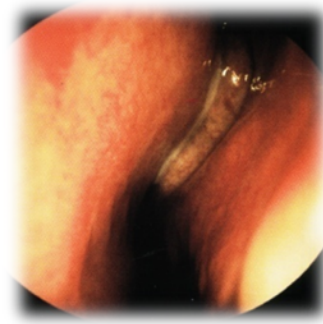
It affects 20-30% of the population (1 person in 6)



1- Acute Rhinitis (common cold):

Clinical stages :

1. Dry prodromal stage (few hours)
2. The Catarrhal stage (few days)
3. Mucous stage (3-5 days)
4. Resolution stage (5 days- 1 week)
5. Secondary bacterial infection



prodromal stage	Catarrhal stage	Mucous stage	Resolution stage	Secondary bacterial infection
Generalized Symptoms: • Chills, cold & heat . • Headache, fatigue. • Loss of Appetite . • Subfebrile temperature. • (Itching, burning, dryness, irritation) of the nose and throat.	• Watery profuse Secretions. • Nasal Obstruction. • Loss of smell. • Lacrimation . • Rhinolalia clausa (hyponasality of the voice). • Constitutional symptoms worsen.	• All generalized symptoms become improved. • Thick secretions. • Local symptoms regress.	• usually in one week.	• Greenish yellow secretions. • Resolve slowly.
Examination: • Nothing but mucosa pale & dry	Examination: • The mucosa deep red +swollen around the turbinate . • Secret profusely .			Most common organism: • Haemophilus Infl. • Streptococc Pneumoniae.
❖ <u>If the initial stage was catarrhal:</u> • It will be due to: Influenza , Parainfluenza , adenovirus ,Rheovirus, Coronavirus , Enterovirus, myxovirus& Respiratory syncytial virus. • Symptoms will be as before in addition to: Entire respiratory tract, G.I.T,Meninges,Pericardium , Kidneys & Muscles.				

Pathogenesis:

- Usually due to rhinovirus
- more than 100 types that are related to Picorna group
- I.P: 1-3 days
- Spread by : Droplet
- Initiated by cooling the body

Diagnosis:

Usually difficult to diagnose in the beginning and must be differentiated from AR & vasomotor rhinitis

D.D :

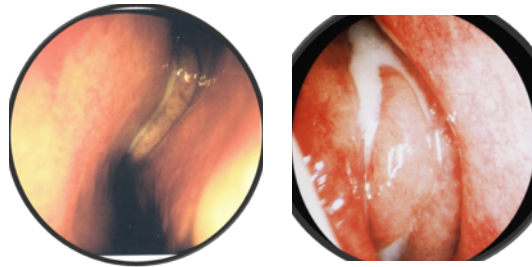
- Acute Exanthema
- VMR (vasomotor rhinitis)
- N. Diphtheria
- Allergic
- Cog. Syphilis

Treatment:

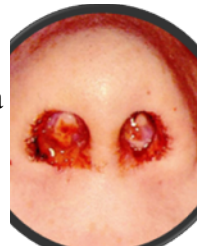
Symptomatic treatment	Prophylaxis
<ul style="list-style-type: none"> •Nasal decongestant. •Oral decongestant. •Antibiotics(in 2dry bacterial infection). •Steam inhalations. •Infrared lamps. •Analgesics. •Bed rest. 	<ul style="list-style-type: none"> •Sauna baths •Therapeutic regimens •Hydrotherapy •Sports •Vitamin C •Careful hygiene •Adenoidectomy(in children) •Immunization [not available in Coryza virus] •Vaccines [available for Influenza]

Infective rhinosinitis:**Same as acute rhinitis:**

- Common Cold
- Large number of viruses
- Droplet spread
- Resolves or 2nd bacterial:
- Haemophilus influenza & Streptococcus pneumonia
- Hypersecreting & hypertrophic
- Muco-purulent >> rhinosinusitis

**2- Chronic Rhinitis:**

Due to chronic irritation Or Inflammation>>Hypertrophy of Nasal Mucosa>>Hyperemia edema(True tissue hypertrophy)

**Symptoms:**

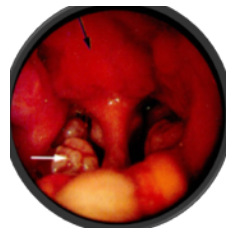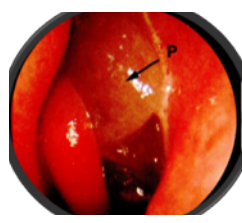
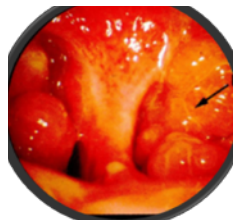- | | |
|---|--|
| <ul style="list-style-type: none"> ● Nasal obstruction ● Tough, Stringy, Colorless secretions (rarely purulent) ● Post nasal catarrh ● Rhinolalia clausa(hyponasality) ● 2nd dacryocystitis (an inflammation of the nasolacrimal sac) ● 2nd pharyngitis | <ul style="list-style-type: none"> ● Fatigue ,sleeplessness ● Unsteady or woozy feeling ● Headache ● Feeling of pressure in the head ● Psychological & physical well-being loss ● Epiphora(tearing) |
|---|--|

Pathogenesis (Causes):

- Recurrent inflammation
- Sinusitis
- masses in nasopharynx (Enlarged adenoid,tumor)
- VMR & Side effects of drugs
- Tobacco, smoke, dust, chemicals, acquired toxins, temperature extremes , humidity
- Pregnancy, menstruation, menopause
- Endocrine disturbances
- Heart & circulatory diseases
- Infective allergy “late-type allergy”

Diagnosis (imp):

From Hx:	On examination:
Long-standing disease	Dark red & bluish-violet swelling turbinate
History of toxins	Narrowed or obstructed nasal cavity
NOT improved with nasal decongested	Mucosa: Granular then nodular surface demonstrating Micro-polyps then nasal polypi
	Mulberry-like masses

**Differential diagnosis:**

- Sinusitis
- Adenoidal hypertrophy
- Tumors(biopsy)
- Foreign bodies
- Wegener's granuloma
- Specific infections
- allergy

Treatment

Conservative	Surgical (the only way to improve Sx)
Treatment of etiological agents	Reduction of the inferior turbinate by sclerosing agents, cryoprobe, or the laser.
Drug overuse controlled	-Electrocoagulation>> multiple, localized scars in N.M(turbinate)
Endocrinologic investigation	-Cryosurgery>>partial obliteration
Environment & occupation	-CO2 or argon laser>>mucosal scars (evaporation or coagulation)
Symptomatic treatment by decongestant nose drops (Not in long term)	Turbinectomy or mucotomy
	Turbinoplasty (the best approach)

The classification "seasonal" and "perennial" allergic rhinitis has been changed to "intermittent" and "persistent" allergic rhinitis

3- Allergic rhinitis :

- * All rhinitis has allergic factors except 20-30% are not and called non allergic rhinitis or vasomotor rhinitis.
- * Due to inhalation of the allergen.
- * The disease is hereditary
- * AR Antigens are usually wind-borne [eg ; grass & tree pollens],HDM ,fungi,dog &cat dander
- * Types: Seasonal, Perennial, Occupational.

a- Seasonal Allergic rhinitis :

- Start at Early Spring by [tree pollen] تراب then in Midsummer by [grass pollen]
- and end in Autumn by [molds] لقاح

b- Perennial Allergic rhinitis :

Causes

- The **house dust mite** is the most common cause.
- A mountain hut in Sweden. (go there to escape AR!)
- Fungi, animal hair, house dust & mites.
- Houseplants: [primulas & rose].
- Food: [fish, strawberries, nuts, eggs ,milk, & flour].

c- Occupational allergies:

- [bakers, hairdressers & painters]
- (e.g.; latex, powders, paint vapors)

The Classic Reaction

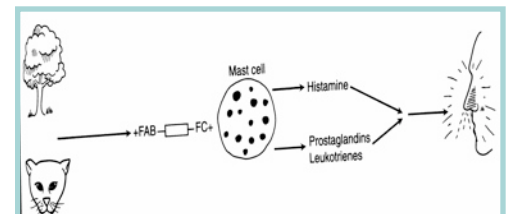
- Type1 IgE mediated reaction, produced in Plasma. cells and regulated in T-Lymphocytes.
- IgE has a crystallized fraction that bind to MC (mast cell) then release protein(Fab).
- Fab +Antigen lead to triggering of mast cell degranulation and release of material like (Histamine, Leukotrine, Prostaglandin).
- These substances causes :Mucosal edema & nasal secretion.

Note:

- Nonorganic substances can induces inflammatory reaction and nonspecific irritants like: smoke and dust >> Vasoactive substances (the reaction is not IgE mediated but it's IgG).
- Physical factors can affect the mast cell like: Temperature change & alcohol.

KEY POINTS :

- Seasonal allergic rhinitis occurs only when pollens in the air (hay fever).
- Perennial rhinitis occurs all year round & can be a myriad of substances, although house dust mite is high on the list.



Diagnosis of AR:

- Detailed medical history.
- ENT examination.
- Other tests as appropriate: allergy tests, endoscopy, nasal smear, nasal swab, radiology, nasal airway assessment, olfaction, blood tests.

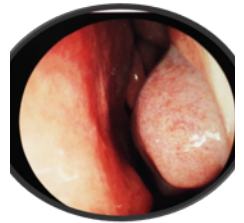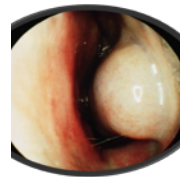
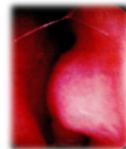
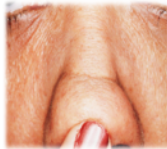AR Symptoms:

• “**SNEEZERS AND RUNNERS**”: Itchy nose, sneezing, watery rhinorrhoea, nasal congestion (variable), diurnal rhythm (worse during day), often associated conjunctivitis.

• “**BLOCKERS**”: Little or no sneezing, thick catarrh (with post nasal drip), no itch, constant symptoms - possibly worse at night.

Examination:

- allergic crease
- Nasal mucosa : livid & pale
- The turbinates : swollen
- Clear secretion : +++

**Investigation:**

- | | | |
|--|--------------------------|-------------------------|
| • Skin prick testing | • Nasal Cytology | • Intracutaneous tests |
| • RAST (radioallergosorbent test) | • IgE | • Mucociliary clearance |
| • Typical history | • Rhinomanometry | • Rhinoscopy tests |
| • Patch tests | • Nasal provocation test | • P.N.S. CT |

D.D of AR:

- | | | |
|-----------------------------|--|---|
| • Vasomotor rhinitis | • Common cold | • Cerebrospinal rhinorrhoea |
| • Polyps. | • Granulomas
e.g. Wegener's Granulomatosis. | • Mechanical factors: deviated septum, hypertrophic turbinates, foreign bodies. |
| • Coryza | | • Tumors. |

Treatment:

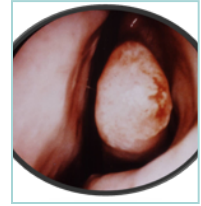
Causal Treatment	Symptomatic Treatment (imp)
<ul style="list-style-type: none"> • Immunotherapy or Desensitization. • Allergen Avoidance. • Local or systemic inhibitions of H substance. 	<ul style="list-style-type: none"> • Antihistamines. • Topical Steroids & Cromoglycate. • Systemic Steroids. • Nasal Decongestant. • Anticholinergic. • Antibiotics. (after culture & sensitivity) • Polypectomy & turbinoplasty.

Prognosis & Complications:**Prognosis :**

- Good prognosis
- Regresses with time
- Some times → bronchial asthma

Complications:

- Nasal sinuses
- L.R.T.
- **Nasal or sinuses polyps**

**Indications for surgery:**

- Anatomical abnormalities
- Excessive mucosal swelling
- Presence of irreversibly diseased tissue

Surgical procedure:

- Polyp removal
- Turbinate surgery
- Removal of adenoids
- Correction of septal deformities
- Sinus drainage

4- Vasomotor Rhinitis

Symptoms : as Perennial Allergic Rhinitis

Has a paroxysmal course

Examination:

- Livid, pale nasal mucosa.
- Profuse watery secretion
- Nasal turbinates swollen

Pathogenesis

- Neurovascular disorder of blood supply of nasal cavity but No specific antibodies and No specific reflex hypersensitivity.
- Caused by various influences e.g: Change of temperature or humidity
Alcohol , dust, smoke, mechanical irritation, stress, anxiety neurosis, endocrine disorders, rhinitis of pregnancy.
- Drugs: (e.g., antihypertensive agents as reserpine or beta-blockers, oral contraceptives)
- Drug abuse: (imidazoline & catechol derivatives, clomethiazole, etc.)

Diagnosis

By exclusion (Typical history, Negative allergen tests, No elevated IgE in the secretion)

Differential diagnosis

(Allergic Rhinitis, Foreign body in the Nose, Common Cold)

Treatment: (imp)

Conservative:	Surgical :
<ul style="list-style-type: none"> •Elimination of irritant factors. •Antihistamines. •Nasal decongestant drops. •Oral decongestant drugs. •Steroids (e.g., beclomethasone). •Metabolic & endocrine systems. •Sedatives. •Imidazoline preparations (Potential for habituation). 	<ul style="list-style-type: none"> •Turbinate surgery Electrocautery, cryosurgery, laser. (Turbinoplasty is the best) •Correction of anatomical deformity. •Conchotomy. •Parasympathetic nasal fibers divisions (Pterygoid canal n., vidian n., greater petrosal n.) M.C.F.

Prognosis

It maybe Uncertain or Pt. may suddenly improves or become resistant to treatment

5- Rhinitis Sicca Anterior:**Pathogenesis:**

Anterior part of the septum usually exposed to hot, dry weather. so trauma or dryness >> irritation to this part >> Crusts formation and attempt to remove it >> Nasal bleeding>> septal perforation.

On examination:

- Nasal septum is dry
- Mucosal surface is: Raw, roughened, & granular.
- Crustation >>ulceration>> Septal perforation

Differential Diagnosis

- Chemical injury (Chromium workers)
- Iatrogenic septal perforation
- Trauma
- Lupus
- Leprosy
- syphilis

Treatment:

- Nasal ointments
- Septal perforation closure

- Main causes of septal perforation in KSA are: surgery then nose picking.
- But in foreign country is : sniffing drugs.

6- Pregnancy Rhinitis:

- Nasal swelling & obstruction
- Start at the 2nd half of pregnancy
- Resolve after delivery

7- Rhinitis Medicamentosa (imp):

Reversible or irreversible damaged mucosa caused by topically or systemically applied drugs:-

- Hyperplastic Rhinitis
- Dryness of the nasal mucosa
- Toxic Rhinopathy (Vasoactive substances)

“Acute intoxication in infants & small children”

8- Atrophic Rhinitis & Ozena (imp):

Atrophic rhinitis + foul smell = Ozena

Types:

- Primary: rare
- Secondary: common, and it's due to massive cutting of the turbinate in surgery, trauma or Occupational exposure to: Glass, wood, asbestos, etc.
- Mainly in women, at puberty, Flattened nose & broad Face (due to fullness of crustation)

Examination:

- Greenish-yellow or brownish-black crusts
- Wide nasal cavity
- Atrophic mucosa & dry: Subepithelial layer fibrosis
- Fetid secretion & crusts (Ozena)
- Anosmia & social problem
- Nasal obstruction

Pathogenesis

- Unknown cause but is multifactorial
- Common in orientals than in whites than in blacks
- Respiratory epith. >> sq. metaplasia
- Destroyed mucociliary cleaning system
- Bacterial proteolysis decomposed the thick & gluey secretions

Differential Diagnosis


- Atrophic rhinitis with fetor (ozena)
- Tumors of the Nose & Sinuses
- Purulent Rhinitis & Sinusitis
- Rhinolith & foreign body
- Gumma due to stage III Syphilis
- Nasal diphtheria & Nasal Tuberculosis
- glanders

Treatment:

Conservative(better than surgery)	Operative
<ul style="list-style-type: none"> •Nasal douching. •Alkaline nasal lotion. •Greasy ointments. •Oily nasal drops, emulsions , or ointments. •Steam inhalations. •Osmotic Powders :Dextrose. 	<ul style="list-style-type: none"> •Bolstering of the Nasal Mucosa(Cartilage or Bone chips). •Median Displacement of the lateral nasal wall by internal rotation of the mobilized lateral nasal wall.

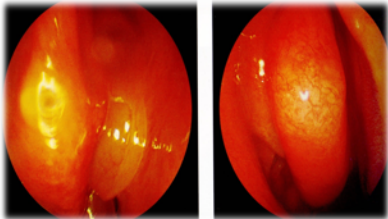
9- Nasal polyps:

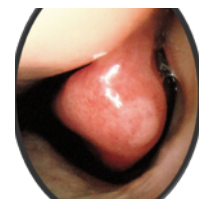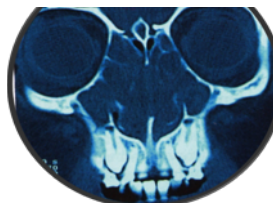
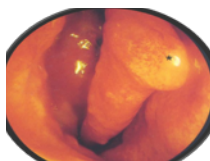
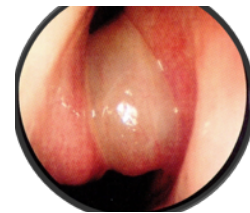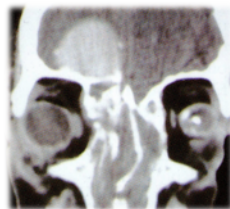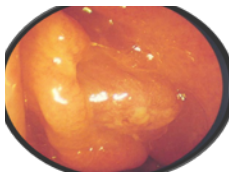
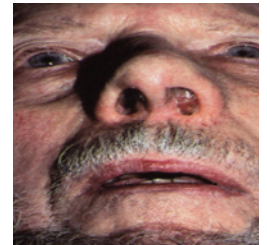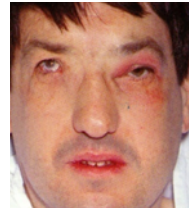- Benign pedicle or sessile pale gray sacks of mucosa.
- Usually ethmoid sinus is affected .
- Etiology : infection, allergic, 90% eosin.
- Any age is possible but uncommon in children(exclude encephalocele) .
- Male affected more than female but if the pt. is having asthma the ratio is equal.
- Mostly bilateral(if unilateral think of inverted papilloma, encephalocele or carcinoma).
- 100 to 1000 times histamine / serum (histamine is 100 times more than serum indicating mast cell degranulation in sinuses). “causes of mast cell degranulation extreme temp. ,drugs, &complement factors.”
- If the eosinophil >90% it suggests association with AR.
- 50% nasal polyps will develop asthma (proper treatment of the polyp will improve asthma).
- 80% have ASA or Semper's triad (polyp, aspirin sensitivity and asthma).
- Nasal polyposis is chronic & recurrent disease.
- Patient have Miserable time and they respond well to Salicylate-free diet.

Clinical Feature:	examination:	Investigation
<ul style="list-style-type: none"> •Nasal obstruction, decrease sense of smell, sneezing, rhinorrhea and Postnasal drip: clear, yellow or green (depend on degree of eosinophilia or infection). •Hyponasal voice [permanent cold]. •No pain unless secondary infection. •No bleeding no discharge but if there is bleeding or serosanguinous discharge think of carcinoma 	<ul style="list-style-type: none"> • Bilateral pale, glistening gray sacks of polyp hanging from the sinuses. • Frog face (in a massive polyp)  •differentiate between polyp and turbinate by pushing it with a probe if it's movable and painless >> polyp if not >> turbinate 	<ul style="list-style-type: none"> •CT scan (because FESS is usually indicated) •Skin tests [H. dust or pollen] •In Child do : •CT scanning to exclude (Encephalocele) •Sweat test to exclude (Cystic Fibrosis)



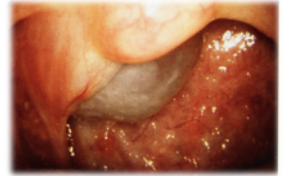
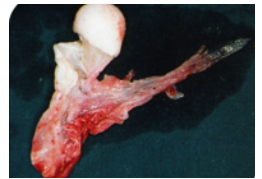
Treatment:

Medical treatment	Surgical Treatment
<p>Topical steroids : good in 50% First line of management 1- month course & review Head down position [drops] Aqueous spray :daily basis Patient must be aware of unwanted effects of steroid sprays</p>	<p>Nasal polypectomy(Partial or total ethmoidectomy) Postoperatively Topical steroids :- -Minimal time is 3 months</p>
<p>Systemic steroids :Short reducing dose (it may lead to Avascular necrosis of the head of femur)</p>	

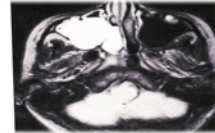
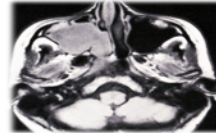


Antrochoanal polyp:

- Long pedicle unilateral solitary benign polypoidal lesions
- Unknown etiology
- Dumbbell shape
- Arises in the intramural maxillary sinus cysts in the post. aspect of the sinus
- Can recur after treatment.
- Unilateral nasal blockage

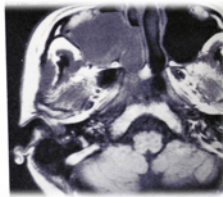
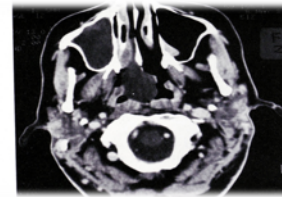
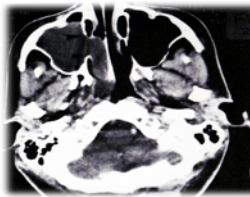
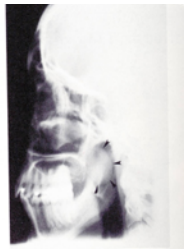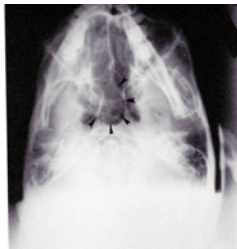
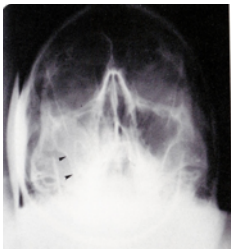**Surgical treatment:**

- Endoscopic nasal removal (by FESS)
- Caldwell-Luc procedure
- Snare Simple polypectomy :20%recurrence

**D.D :**

Inf. Turbinate enlargement, polypoid rhinosinusitis, juvenile N angiofibroma, mucus R cyst, mucocele, benign or malignant nasopharyngeal tumors

Preop. Components identification by it's characteristic radiographic appearance



Nasal vestibulitis	Furunculosis
<ul style="list-style-type: none"> •infection of the skin of the nasal vestibule. •It affects both children and adults •caused by pyogenic staphylococci •The site becomes sore and fissured and crusting will occur. •Diagnosis: a swab for culture and sensitivity. •Treatment, which needs to be prolonged, consists of topical antibiotic/antiseptic ointment and systemic flucloxacillin. 	<ul style="list-style-type: none"> •Abscess in a hair follicle is rare but must be treated seriously as it can lead to cavernous sinus thrombosis. •The tip of the nose becomes red, tense and painful. •Systemic antibiotics should be given without delay, preferably by in- jection. + Drainage may be necessary but should be deferred until the patient has had adequate antibiotic treatment for 24 h. In recurrent cases, diabetes must be excluded.