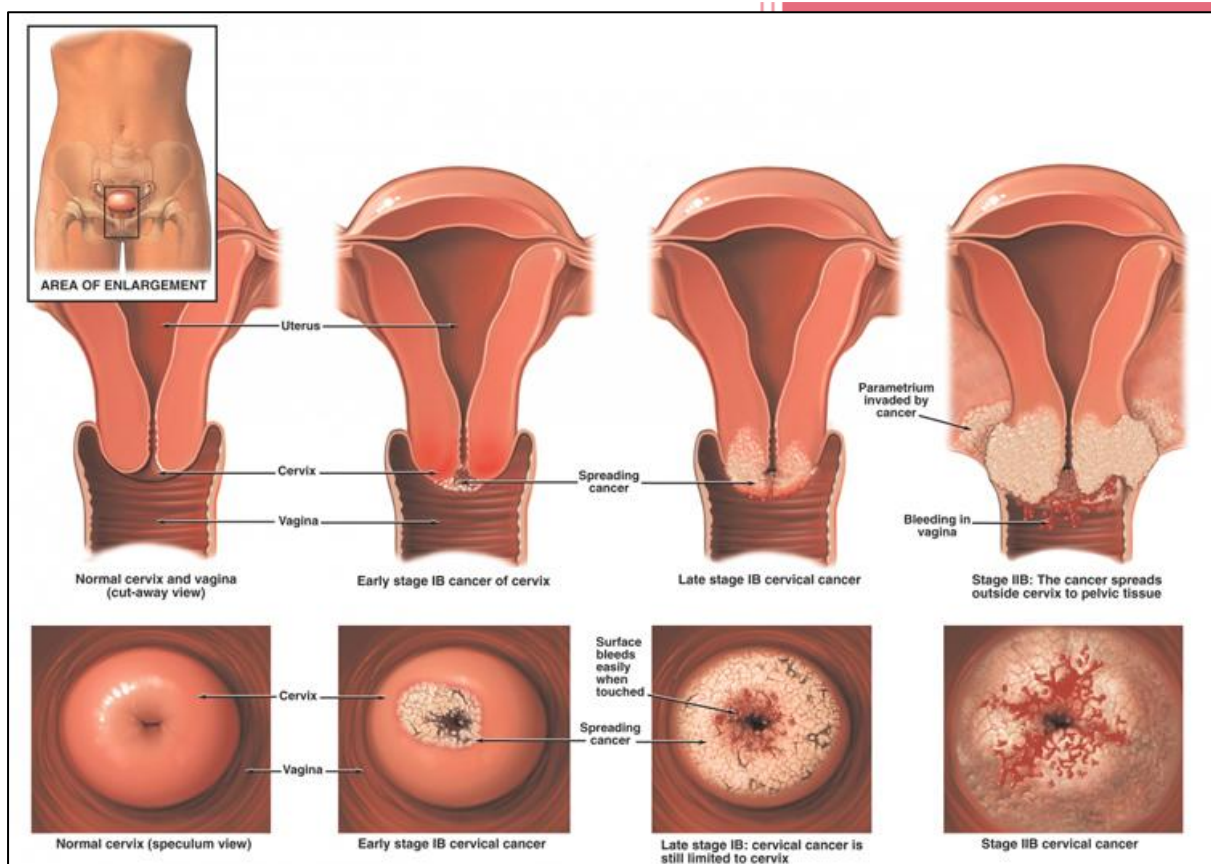


CIN and Cervical Cancer



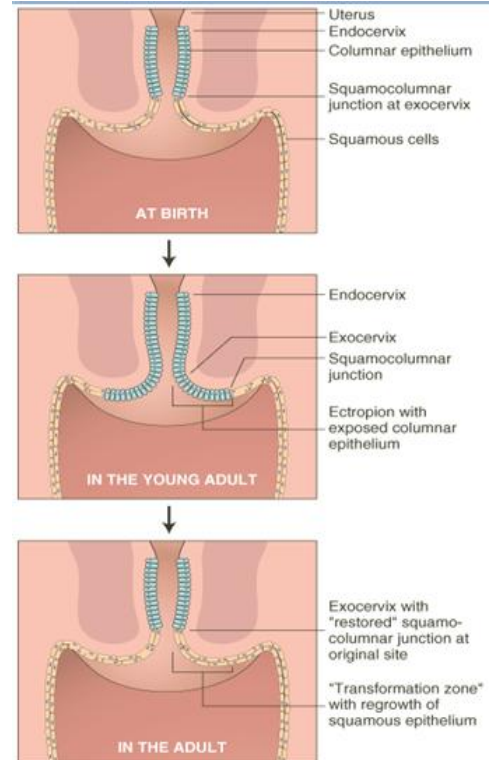
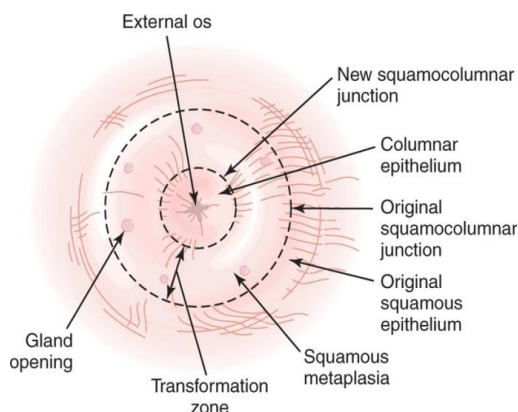
429 Ob/GYN Team

Sources: Dr. Adar's lecture, BRS Obstetrics & Gynecology 2ed by E. P. Sakala, and Essentials of Obstetrics & Gynecology 4ed by Hacker & Moore, MCQs at the end are from 428 Ob/GYN MCQ booklet.

Cervical Intraepithelial Neoplasia and Cervical Cancer

NORMAL DEVELOPMENTAL CHANGES IN CERVICAL TOPOGRAPHY

1. During **early embryonic development**, the cervix and upper vagina are covered with **columnar epithelium**.
2. During **intrauterine development**, the columnar epithelium of the vagina is progressively replaced by squamous epithelium.
3. **At birth**,
 - a. In most normal girls the region of columnar epithelium is limited to the endocervix and the central ectocervix.
 - 1) **Adenosis** is found in **4%** of normal girls and **30%** of DES daughters. The columnar epithelium extends onto the vaginal fornices.
 - 2) Macroscopically, the columnar epithelium has a red appearance because it is only a single layer thick, allowing blood vessels in the underlying stroma to show through it.
 - b. The embryologic squamous and columnar epithelia are designated the **original and native** squamous and columnar epithelia.
 - c. **The squamocolumnar (SC) junction:** the junction between the original squamous and columnar epithelia on the ectocervix.
4. **During adolescence and first pregnancy**, a new SC junction is formed through squamous metaplasia of the columnar epithelium to **stratified squamous epithelium**.
 - a. The new SC junction is more proximal to the external os than the original SC junction.
 - b. **The transformation (T) zone:** is the area between the two SC junctions.

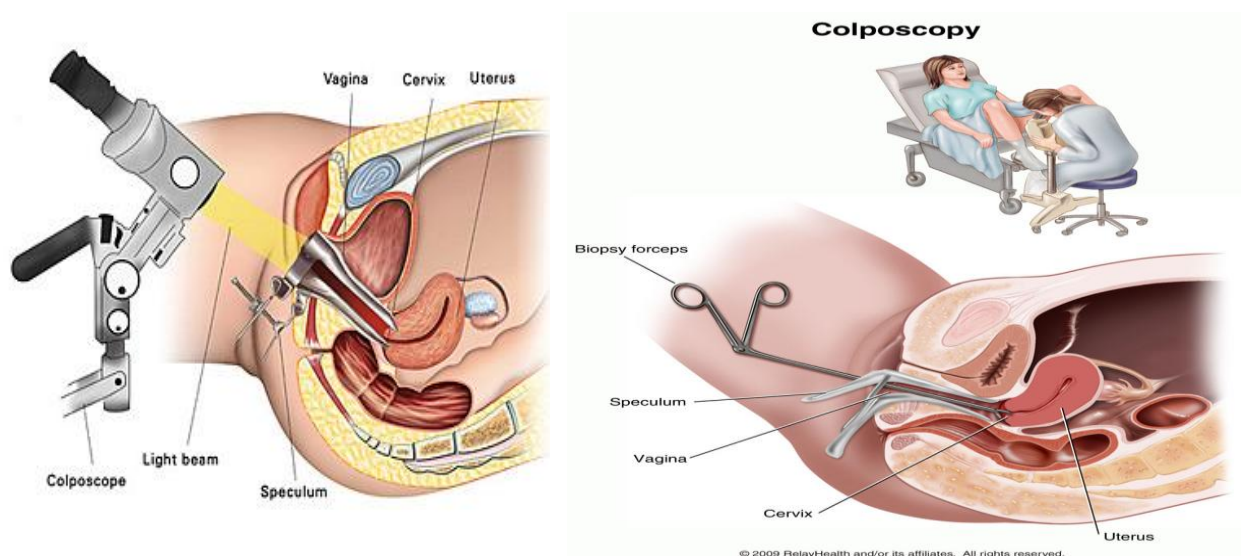


Diethylstilbestrol (DES) is a synthetic form of the female hormone estrogen. It was prescribed to pregnant women between 1940 and 1971 to prevent miscarriage, premature labor, and related complications of pregnancy. The use of DES declined after studies in the 1950s showed that it was not effective in preventing these problems. Women who took DES during pregnancy have an increased risk of breast cancer. Increased risks of clear cell adenocarcinoma of the vagina and cervix and of breast cancer have been found for daughters of women who took DES during pregnancy; fertility problems are also more common among these daughters. Exposed individuals, also, have increased risk for abortion, premature delivery, or ectopic pregnancy.

VISUALIZATION OF THE CERVIX

Colposcopy

- Colposcopy is the inspection of well-illuminated cervix with a low-power, short-focal length binocular **colposcope** with biopsy of abnormal areas. It is performed as a confirmatory test for evaluation of women with abnormal cervical cytologic findings.
- To perform a colposcopy, a **speculum** is inserted to expose the cervix → the cervix is painted with a **3%-5% aqueous acetic acid solution** to remove adherent mucus and cellular debris and enhance vascular changes that accompany pathologic alterations of the cervix.
- The colposcopic evaluation is considered "**adequate**" or "**satisfactory**" → if the complete T zone and the full extent of the lesion(s) are visualized. If either of the them cannot be visualized → the evaluation is considered "**inadequate**" or "**unsatisfactory**" for the purpose of ruling out CIN and invasive carcinoma.
- This means that the **squamocolumnar junction** should be visible in its full length.



Colposcopic Appearance of The Normal Cervix

The most important anatomical concept is to **identify the transformation zone** where cervical intraepithelial neoplasia (CIN) and invasive cervical carcinoma arise.

The squamous epithelium

- Appears as a smooth translucent epithelium with a **pinkish tinge** after application of normal saline solution.
- Often no vascular patterns are seen on the original squamous epithelium, but occasionally, a network of capillaries may be visible.

The metaplastic epithelium

- Appears **light pink**. Less pink compared to the original squamous epithelium.
- Tree-like branching vessels may be observed on the newly formed **metaplastic squamous epithelium**.

The columnar epithelium

- The columnar epithelium is a single-cell layer, mucous producing, tall epithelium that extends between the endometrium and the squamous epithelium. Columnar epithelium appears red and irregular with stromal papillae and clefts. It is found in the endocervix, surrounding the cervical os, or (rarely) extending into the vagina.

- Each columnar villous structure contains a fine capillary and the blood in the capillary and the vascularity of the underlying connective tissue give the columnar epithelium its strikingly reddish appearance.
- Small polyps may be detected during examination of the endocervical canal.

The T zone

1. The T zone can be identified by the presence of gland openings that are not covered by the squamous metaplasia and by the paler color of the metaplastic epithelium compared with the original squamous epithelium.
2. In some women, nabothian follicles can be found in the T zone.
3. **The vast majority of CIN lesions occur in the transformation zone** and the most severe changes tend to be closer to or abutting rather than farther from the new squamocolumnar junction.

Nabothian follicles (cysts): cysts that result from the process of squamous metaplasia. A layer of superficial squamous epithelium entraps an invagination of columnar cells beneath its surface. The underlying columnar cells continue to secrete mucus and mucus retention cyst is created. Nabothian cyst on the cervix are **so common** that they are considered the normal variant.

The original SC junction:

Away from the os towards the outer part of the ectocervix, no more crypt openings or nabothian follicles are apparent. The original squamocolumnar junction forms the outer, caudal, or **distal border** of the transformation zone through its entire 360-degree circumference. Sometimes, it is the subtle color variation between the native and metaplastic squamous epithelium that defines the original squamocolumnar junction.

The new SC junction

- The inner or **proximal border** of the transformation zone, which is defined as the line of demarcation where the metaplastic squamous and native columnar epithelia meet.
- throughout its entire 360-degree circumference, if the colposcopist is able to trace the entire new squamocolumnar

junction successfully, the colposcopic examination is classified as adequate or satisfactory with respect to evaluation of the transformation zone.

- The new squamocolumnar junction tends to recede towards, and into the canal as a woman ages.
- If the junction is proximal to the os in the canal, it requires additional effort to visualize the entire junction.

- Both the original and mature squamous metaplastic epithelium stain **mahogany brown** or **black** with Lugol's iodine solution, while columnar epithelium does not.
- Immature squamous metaplastic epithelium usually does not stain with iodine or may partially stain if it is partially glycogenated.
- In postmenopausal women, squamous epithelium may not fully stain with iodine, due to the atrophy of the epithelium.

Lugol's iodine: applied to the vagina and cervix. Normal vaginal and cervical tissue stain brown due to its high glycogen content, while tissue suspicious for cancer does not stain, and thus appears pale compared to the surrounding tissue. Biopsy of suspicious tissue can then be performed.

Colposcopic Features after Application of 5% Acetic Acid

Squamous epithelium

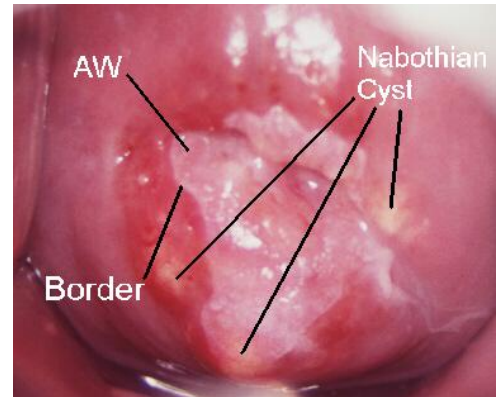
- The colour of the squamous epithelium dull in contrast to the usual pink hue, and the translucence is diminished so that it looks somewhat pale.

Columnar epithelium

- Less dark red than it was with saline and the pale **acetowhitening** of the villi may resemble a grape-like appearance.
- In pregnant women, the villi are hypertrophied and the grape-like appearance will be easier to observe.

Squamous metaplasia

- The squamocolumnar junction may be prominently visible as a sharp, white line due to the presence of actively dividing immature squamous metaplasia around the edge medial to the junction.
- The new squamocolumnar junction may not be visible in postmenopausal women as it recedes into the endocervical canal.



Three stages of development of squamous metaplasia may be recognized:

1. In the earliest stage, the translucence of the columnar epithelial villi is lost and the villi become opaque at their tips;
2. **Immature squamous metaplasia:** the villi widen and flatten and successive villi fuse in clusters and sheets with glassy, pinkish-white, finger-like membranes pointing towards the external os.
3. **Mature squamous metaplasia:** the immature metaplastic epithelium becomes a fully developed mature metaplastic squamous epithelium resembling the original native squamous epithelium, except for the presence of some crypt openings and nabothian retention follicles in the metaplastic epithelium.

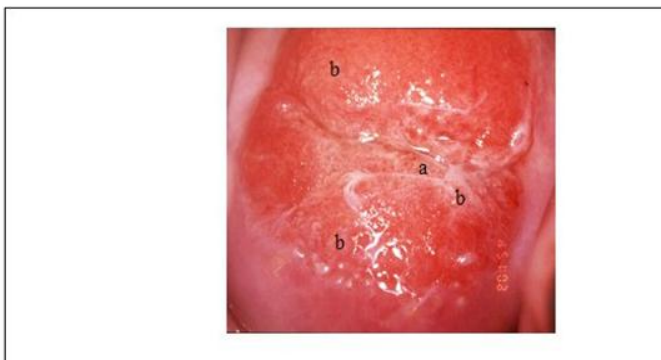


FIGURE 6.8: The earliest colposcopic changes in immature squamous metaplasia (after application of 5% acetic acid) in which the tips of the columnar villi stain white (a) and adjacent villi start fusing together (b).

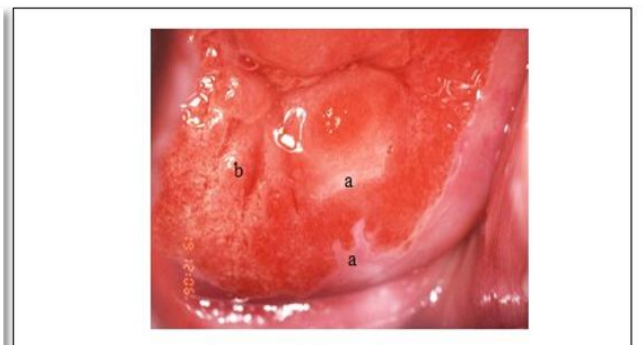


FIGURE 6.9: Immature squamous metaplasia: The columnar villi have fused together to form thin membrane (a). The adjacent villi are fusing together (b) (after 5% acetic acid application)

- There may be numerous crypt openings and islands of columnar epithelium scattered throughout the metaplastic epithelium.

CERVICAL INTRAEPITHELIAL NEOPLASIA AND CERVICAL CANCER

Overview

- Cervical cancer is the most common cause of death from cancer in women.
- It is the **second** most common malignancy in women worldwide.
- About **80%** of new cases reported each year occur in developing countries.
- In developed countries, regular screening with Pap smears has markedly decreased the incidence of the disease.

Epidemiology

- A positive association between cancer of the cervix and multiple, interdependent social factors:
- Black and Mexican Americas → related to lower socioeconomic status.
- Multiparous women → related to early age of marriage and early age of first pregnancy.
- Cervical cancer usually affects women of middle age or older, but it may be diagnosed in any reproductive-aged woman.
- Cervical cancer is rare in celibate group such as nuns.
- Smoking is a high risk factor for carcinoma of cervix. Smoking is related to **squamous cell carcinoma** only not adenocarcinoma. Some studies have found mutagens in cervical mucus higher than those found in the blood. Smokers, also, had a higher level of DNA modification in cervical epithelium than did non-smokers, this suggest direct biochemical evidence of smoking as a cause of cervical cancer.
- In adolescence, the cervix is at more risk
 - Active metaplasia is occurring. Active proliferation and cellular transformation from columnar to metaplastic to squamous epithelium, so the interaction between the carcinogen and cervix is increased.
 - Once this process of metaplasia is complete, the cervix may no longer be at high risk.

Risk Factors

Major risk factors include:

1. Young age at first coitus (<20).
2. Multiple sexual partners.
3. Promiscuous male partners (Sexual partner with multiple sexual partners).
4. History of sexually transmitted diseases.
5. Young age at first pregnancy.
6. High parity.
7. Lower socioeconomic status.
8. Smoking.
9. Age. Invasive carcinoma of cervix is more common in older women. **25%** of all cervical cancer occurred in women older than 65 years of age. Increasing age is, also, associated with more advanced disease.
10. Strong evidence now implicates human papillomaviruses (HPVs) as a **prime cause** of cervical cancer.

HPV viral DNA has been detected in more than **90%** of squamous intraepithelial lesions (SILs) and invasive cervical cancers. SILs are found predominantly in younger women. Invasive cancers detected more in women aged **10-15** years older, suggesting **slow progression** of cancer.

HPV infection occurs in a high percentage of sexually active women. Most of these infections clear **spontaneously** within months to a few years. A small proportion progress to cancer.

Three main factors have been postulated to influence the progression of low-grade SILs to high-grade SILs:

- A. **The type and duration of viral infection**, with high-risk HPV type and persistent infection predicting a higher risk for progression.
- B. **Host conditions** that compromise immunity, multiparty or poor nutritional status.
- C. **Environmental factors**, smoking, oral contraceptive use, or vitamin deficiencies.

various gynecologic factors: age of menarche, age of first intercourse, and number of sexual partners – increase the risk for cervical cancer.

Clinical Presentation

- Abnormal Papanicolaou test result.
- The first symptom is abnormal vaginal bleeding, usually **postcoital**.
- Vaginal discomfort, malodorous discharge, and dysuria are not uncommon.

The tumor grows by extending upward to the endometrial cavity, downward to the vagina, and laterally to the pelvic wall. It can invade the bladder and rectum directly.

Late symptoms: constipation, hematuria, fistula, and ureteral obstruction with or without hydronephrosis or hydroureter, reflect local organ involvement.

The triad of leg edema, pain, and hydronephrosis suggests pelvic wall involvement.

The common sites for distant metastasis include extra-pelvic lymph nodes, liver, lung, and bone.

Physical Findings

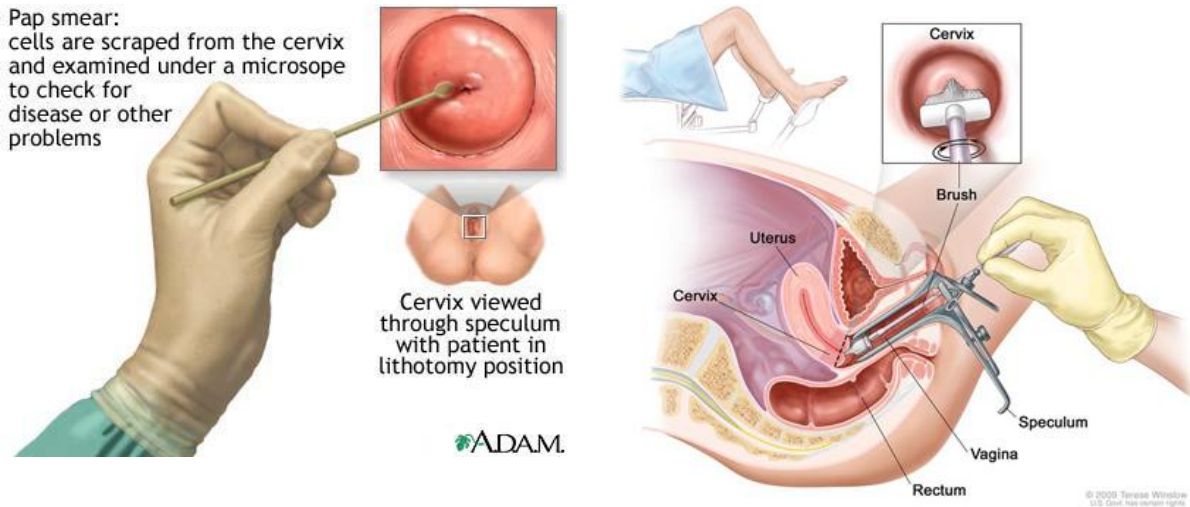
- In early-stage, the cervix can be relatively normal.
- As the disease progresses, the cervix may become abnormal in appearance, with gross erosion, ulcer, or mass.
- Rectal examination may reveal an external mass or gross blood from tumor erosion.
- Bimanual examination findings often reveal pelvic metastasis.
- Leg edema suggests lymphatic/vascular obstruction from tumor.
- If the disease involves the liver, some patients develop hepatomegaly.

Pulmonary metastasis is usually difficult to detect upon physical examination unless pleural effusion or bronchial obstruction becomes apparent.

Screening of cervical cancer

- the standard method for cervical cancer screening is **Papanicolaou test** (Pap smear). Retrospective data have shown that screening with a Papanicolaou test reduces the incidence rate of cervical cancer by **60-90%** and the death rate by **90%**.
- The false-negative rate of a Papanicolaou test is **20%**, which mostly results from **sampling error**. Physicians can reduce sampling error by ensuring **adequate** material is taken from both the endocervical canal and the ectocervix. Smears without endocervical or metaplastic cells must be repeated.
- Upon physical examination, suspicious or grossly abnormal cervical lesions should undergo **biopsy** regardless of cytologic findings.

- Women should have regular cervical screening even if they have received the HPV vaccine, because the vaccine does not protect against all high-risk HPV viral types.



Screening recommendations

American College of Obstetricians and Gynecologists (ACOG) guidelines:

- ❖ Screening should begin about 3 years after initiation of sexual intercourse.
- ❖ Annual screening should begin no later than age 21 yrs.
- ❖ At age 40 and more Pap smears may be every 2-3 years after 3 consecutive negative results if no history of CIN II or III, immunosuppression, HIV infection or DES exposure in utero.

American Cancer Society (ACS) guidelines:

- ❖ Screening should begin about 3 years after initiation of sexual intercourse but no later than 21 yrs..
- ❖ Screening should be done every year with conventional Pap tests or every 2 years Using liquid-based Pap tests.
- ❖ At or after age 30, women who have had three normal test results in a row may get screened every 2-3 years.
- ❖ Women 70 years or older who have had three or more normal Pap tests and no abnormal Pap in the last 10 years, And women with total hysterectomy may choose to stop cervical cancer screening.

- Women with high risk factors (DES exposure, HIV infection, or other immunodeficiencies) should continue yearly screening.

Classification of an Abnormal Pap Smear

Bethesda system was devised to classify cytologic abnormalities in pap smears.

Bethesda Classification of Cytologic Abnormalities

Specimen Adequacy

1. Satisfactory for evaluation (note presence/absence of endocervical/transformation zone component)
2. Unsatisfactory for evaluation (specify reason)
3. Specimen rejected/not processed (specify reason)
4. Specimen processed and examined, but unsatisfactory for evaluation of epithelial abnormality (specify reason)

General Categorization (Optional)

1. Negative for intraepithelial lesion or malignancy
2. Epithelial cell abnormality
3. Other

Interpretation/Result

1. Negative for Intraepithelial Lesion or Malignancy

- Organisms (e.g., *Trichomonas vaginalis*)
- Reactive cellular changes associated with inflammation (includes typical repair), radiation, intrauterine contraceptive device
- Atrophy

2. Epithelial Cell Abnormalities

A. Squamous Cell

- Atypical squamous cells of undetermined significance (ASCUS) cannot exclude high-grade squamous intraepithelial lesion (HSIL) (ASC-H)
- Low-grade squamous intraepithelial lesion (LSIL) encompassing: human papillomavirus/mild dysplasia/cervical intraepithelial neoplasia (CIN I)
- HSIL encompassing: moderate and severe dysplasia, carcinoma in situ; CIN II and CIN III
- Squamous cell carcinoma

B. Glandular Cell

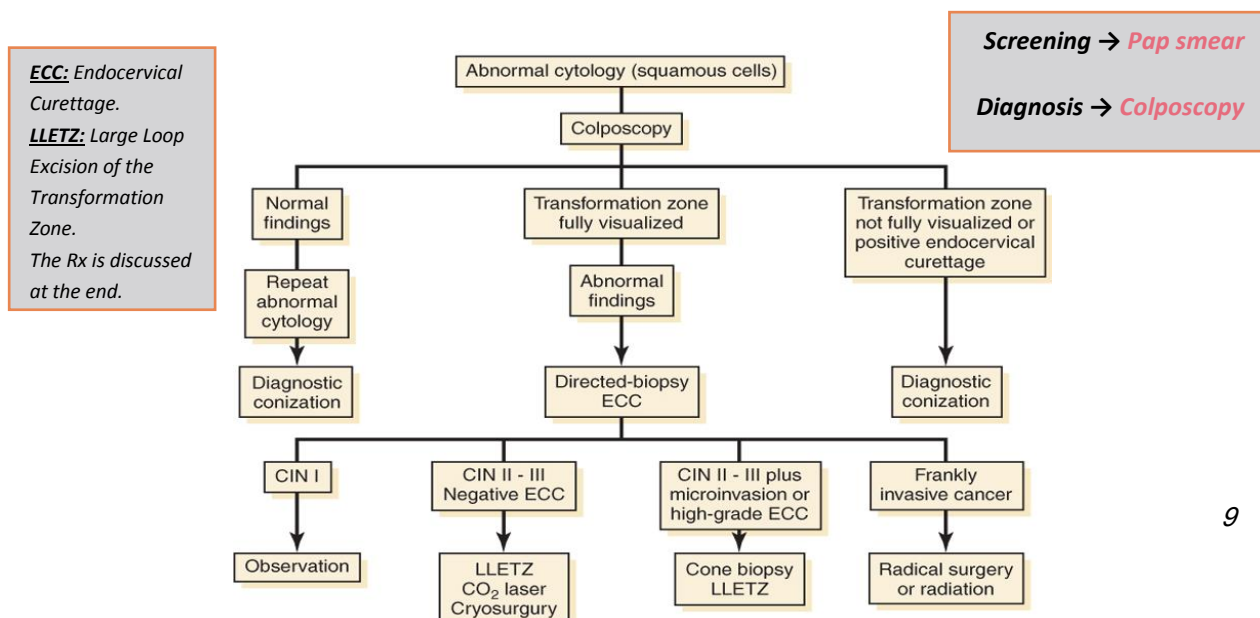
- Atypical glandular cells (AGC) (specify endocervical, endometrial, or not otherwise specified)
- Atypical glandular cells, favor neoplastic (specify endocervical or not otherwise specified)
- Endocervical adenocarcinoma in situ (AIS)
- Adenocarcinoma

Other

For example, endometrial cells in a woman ≥ 40 years of age

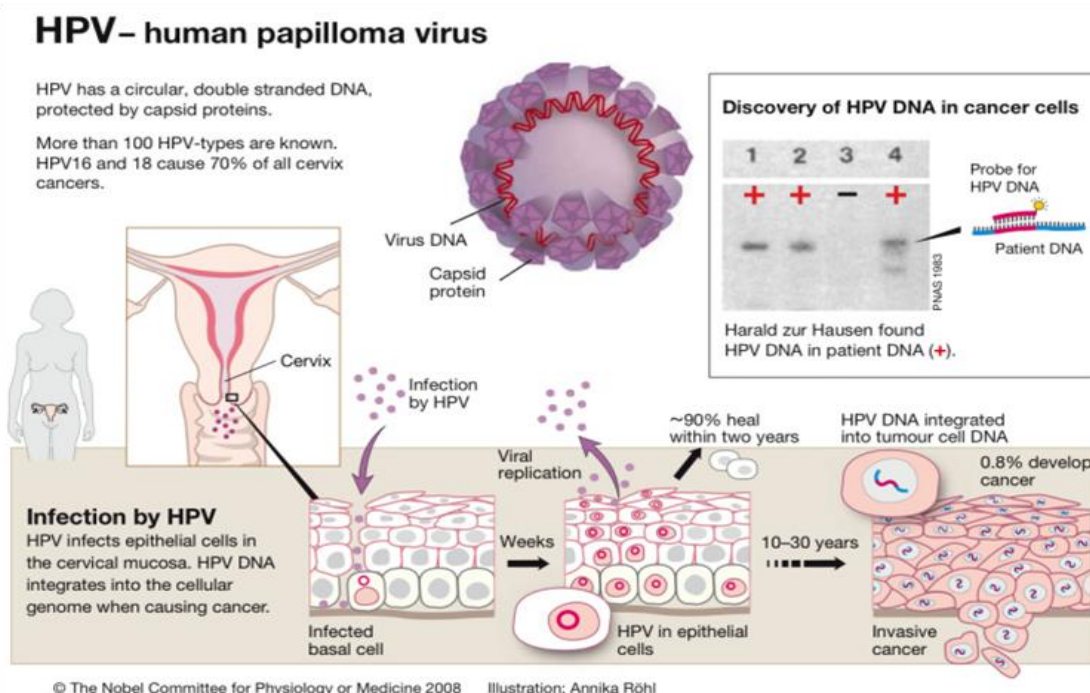
Evaluation of a Patient with an Abnormal Pap Smear

Patients with atypical squamous cells of undetermined significance (ASCUS) found on their smear may have to repeat test in 6 months. **HPV testing** may be used to triage such patients. **Colposcopy** is used to diagnose CIN and cervical cancer. About **6%-10%** of patients with an ASCUS smear will have high-grade CIN on colposcopy. HSIL is almost always evaluated with colposcopy. (The management of ASCUS will be discussed in details later)



Human Papilloma Virus (HPV)

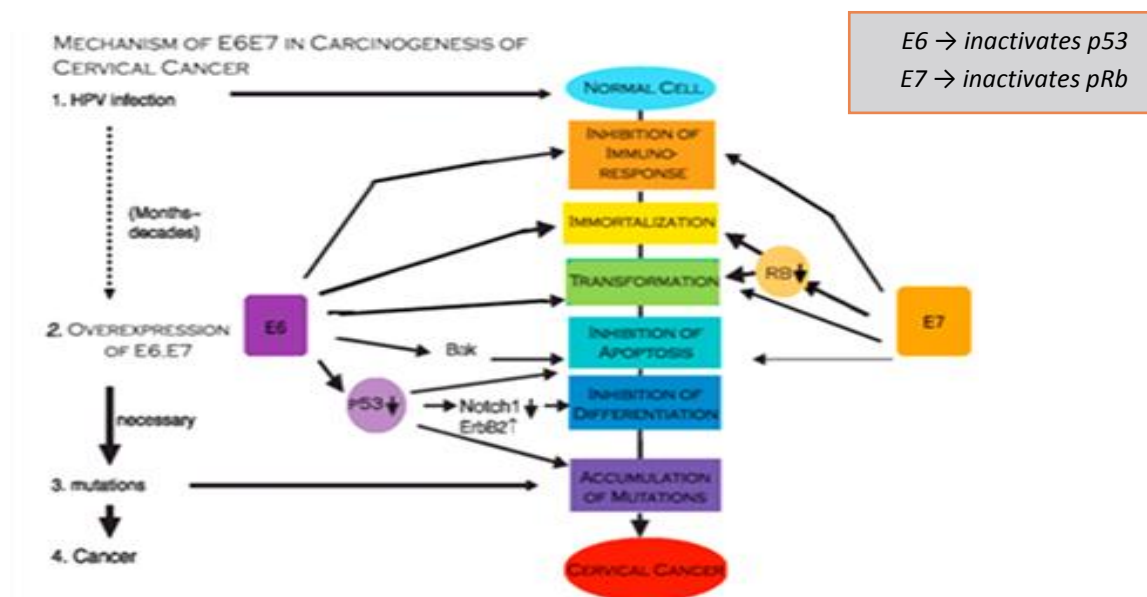
- HPV is a heterogeneous group of viruses that contain closed circular double-stranded DNA.
- The viral genome encodes 6 early open reading frame proteins (i.e., E1, E2, E3, E4, E6, E7), which function as **regulatory proteins**, and 2 late open reading frame proteins (i.e., L1, L2), which make up the **viral capsid**.
- Infections caused by these viruses are usually not systemic but result in local infections manifesting as **warty papillary condylomatous lesions**.
- HPV-infected cells contain both the fully formed viral particles and their DNA.
- Replication of the virus occurs only in the cell nuclei, in which DNA synthesis is low.
- Mature HPV particles are never found in replicating basal or parabasal cells but are found in the **koilocytotic cells** (cells with enlarged nuclei and cytoplasmic vacuoles) in the superficial layer.
- HPV, like HSV-2 may also have a latent intranuclear form in which only fragments of the viral DNA are expressed.
- ~ 30 HPV types primarily infect the squamous epithelium of lower anogenital tracts of both males and females.
- Low- risk types (**6,11**) are mainly associated with benign lesions such as condyloma which rarely progress to a malignancy.
- High-risk types (**16,18**) are detected **50-80%** of squamous intraepithelial lesions (SILs) and in up to **90%** of invasive cancers.
- The major difference between the 2 types is that after infection, the low-risk HPVs are maintained as **extrachromosomal** DNA episomes, while the high-risk HPV genome is found integrated into the host cellular DNA.
- less common, types 31, 33, 35, 39, 45, 51, 52, 56, 58, 59, 68, 73, and 82 should also be considered carcinogenic.



HPV infection

- The integration usually occurs in the L1/L2 region, resulting in disrupting gene integrity and expression.
- The open reading frames encode DNA-binding proteins that regulate viral transcription and replication.

- With HPV 16 and 18, the E2 protein represses the promoter from which the E6 and E7 genes are transcribed, because of integration, the E6 and E7 are expressed in HPV-positive cervical cancer.
- E6 & E7 are the only viral factors necessary for immortalization (prevention of apoptosis) of human genital epithelial cells.
- The two oncoproteins (E6&7) form complexes with the host regulatory proteins such as **p53** and **pRb** (retinoblastoma susceptibility gene).
- High-risk HPV E6 binds with p53 causing rapid degradation of p53 preventing its normal function, which is responding to DNA damage induced by radiation or chemical mutagens, without this binding, levels of p53 increase and growth arrest of cells may occur which allows repair of damaged DNA to take place or apoptosis to occur. (**p53 is a tumor-suppressor protein that is activated in response to stress including DNA damage. Its activation results in DNA repair, growth-arrest and apoptosis of abnormal cells. In cancer, HPV E6 inactivates p53 preventing its normal function**).
- E7 protein binds to pRb, this interaction inactivates pRb and pushes the cell cycle into the S phase and induces DNA synthesis.
- the functional loss of both P53 and the pRb genes leads to resistance to apoptosis, causing uncensored cell growth after DNA damage. This ultimately results in progression to malignancy.



Gynecologic Lesions Associated with HPV

Manifestation	Common HPV types	Less common HPV types
Condyloma acuminata (anogenital warts) – Benign growths on squamous epithelium of external genitalia and perianal regions; rarely become malignant	6, 11	2,16,30,40,41,42,44,54,55,61
CIN*, VIN** – Progressive changes in cervical mucosa leading to dysplasia and possible carcinoma in situ .	16,18,31	6,11,30,34,35,39,40,42-5,52,52,56-9,61,62,64,66,67,69
Cervical cancer	16,18,31,45	6,10,11,26,33,35,39,51,52,55,56,58

- HPV-18 is more virulent than HPV-16.
- Prognosis was worse in patients with cervical CA. if no HPV type is present.
- HPV-18 is more frequently associated with **adenocarcinoma** of the cervix and type 16 with **squamous** cancer.

* Cervical Intraepithelial Neoplasia.
 ** Vaginal Intraepithelial Neoplasia.

- There is a positive association of high gravidity and *squamous* cancer and an inverse association with adenocarcinoma.
- Age of first intercourse and number of sexual partner is of greater risk of *squamous* carcinoma than adenocarcinoma.

HPV Testing

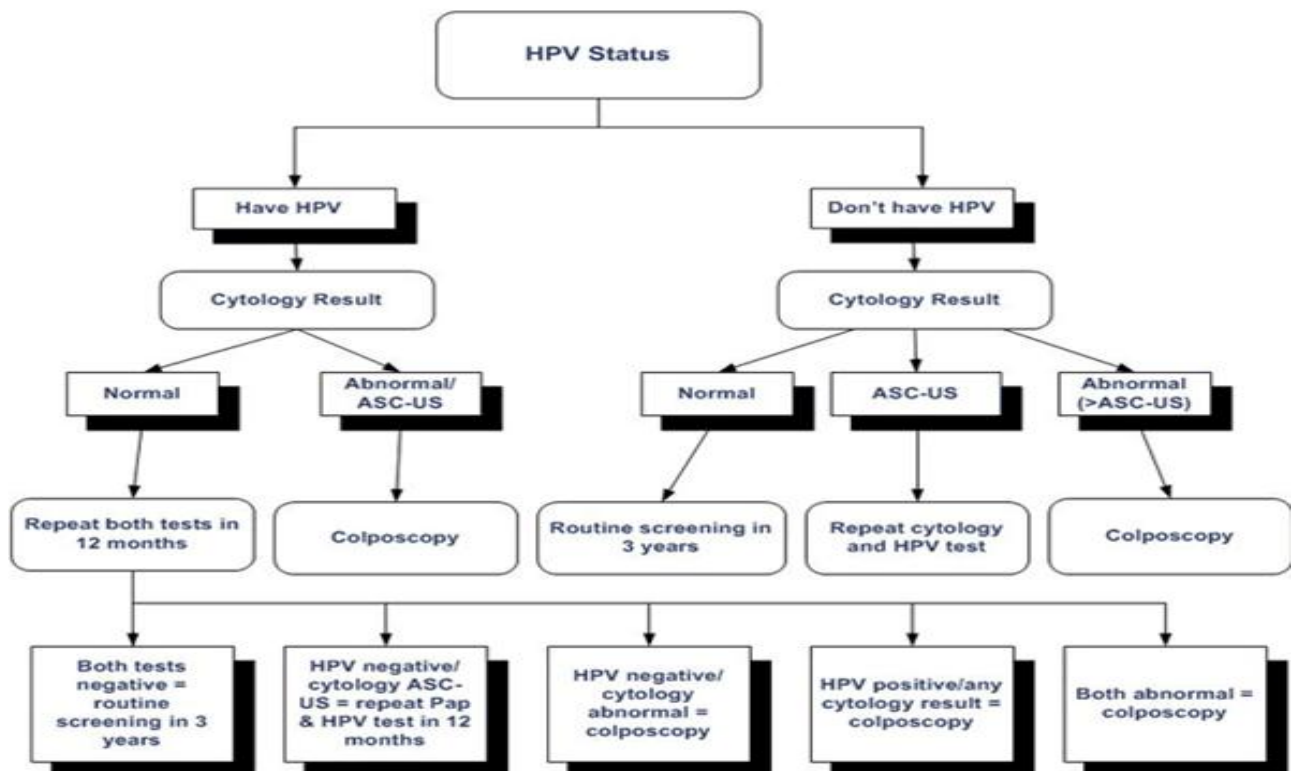
- Southern blot analysis for HPV DNA was considered the gold standard.
- Filter in situ hybridization → *insensitive*
- Dot blot (Vira Pap/ Vira type kits → *insensitive*
- HPV profile kit (test HPV 7-14) uses radio-labeling → *replaced*
- **Second-Generation Digene Hybrid capture (HC2):**
 - ✓ greater sensitivity
 - ✓ less time
 - ✓ use chemiluminescence substrate instead of radiolabeling
 - ✓ FDA approved
 - ✓ requires separate RNA probes
 - ✓ test both low and high risk HPV.
 - ✓ This test is indicated for women aged 30 years and older, in conjunction with the Papanicolaou test.

HPV Transmission

- HPV DNA is ubiquitous and endemic.
- Most common method of transmission → *sexual*.
- Non-sexual transfer is not rare.

HPV Management

Patient Management Based on HPV Results



HPV Vaccination

- (HPV) vaccine is now available for prevention of HPV-associated dysplasias and neoplasias, including cervical cancer, genital warts (condyloma acuminata), and precancerous genital lesions.
- The immunization series should be completed in girls and young women aged 9-26 years.
- **Papillomavirus vaccine (Gardasil):** Quadrivalent HPV recombinant vaccine. Vaccine efficacy mediated by humoral immune responses following immunization series.

Human Immunodeficiency Virus

- The role of human immunodeficiency virus (HIV) infection in the pathogenesis of cervical cancer is not fully understood.
- Studies have shown a higher prevalence of HPV in HIV-seropositive women, and the HPV prevalence was directly proportional to the severity of immunosuppression.
- Impaired lymphocyte function has been postulated to enhance latent or subclinical HPV activity, resulting in a higher rate of persistent infection.
- Whether HIV has a synergistic effect on HPV infection, either by direct molecular interaction or through an indirect immunologic effect, remains unclear.

Differential Diagnosis

1. Cervicitis

- Cervicitis is an inflammation of the uterine cervix.
- Infectious cervicitis might be caused by *Chlamydia trachomatis*, *Neisseria gonorrhea*, *Trichomonas vaginalis*, herpes simplex virus (HSV), or human papilloma virus (HPV).
- Noninfectious cervicitis caused by local trauma, radiation, or malignancy.
- The infectious etiologies are significantly more common than the noninfectious causes, and all possible infectious causes of cervicitis are sexually transmitted diseases (STDs).

2. Endometrial Carcinoma

- Corpus cancer is the most frequently occurring female genital cancer.
- the **fourth** most common cancer among women.

3. Pelvic Inflammatory Disease

It is an inflammatory disorder of the uterus, fallopian tubes, and adjacent pelvic structures. Risk factors for PID include young age at first intercourse, multiple sexual partners, intrauterine device (IUD) insertion, and tobacco smoking.

4. Vaginitis

- Vaginitis is defined as the spectrum of conditions that cause vulvovaginal symptoms, itching, burning, irritation, and abnormal discharge.
- The most common causes of vaginitis in symptomatic women are bacterial vaginosis (BV) (22-50%), vulvovaginal candidiasis (17-39%), and trichomoniasis (4-35%)

5. Vaginal cancer

6. Metastatic cancer to cervix (rare)

Abnormal Colposcopic Findings

1. Atypical transformation zone.
2. Keratosis.
3. Aceto-white epithelium.
4. Punctuation.
5. Mosaicism.
6. Atypical vessels.
7. Frank invasive carcinoma.
8. Unsatisfactory colposcopic finding.

The colposcopic hallmark of the cervical intraepithelial neoplasia is an area of sharply delineated **acetowhite epithelium**. Within the epithelium, there may be abnormal vascular pattern.

There are two basic changes in the vascular architecture in patients with CIN: **Punctuation** and **mosaicism**.

Punctuation: single-looped capillaries lying within the sub epithelial papillae, seen as dots as they course toward the surface.

Mosaicism: fine network of capillaries disposed parallel to the surface in a mosaic pattern.

Both patterns may be seen together within the same area of the cervix. With microinvasive carcinoma, extremely irregular patterns are found. The irregularity in size, shape, and arrangement of the terminal vessels becomes even more striking in frankly invasive carcinoma, with exaggerated distortions of the vascular architecture producing comma-shaped, corkscrew-shaped, and dilated, blind-ended vessels.

CERVICAL INTRAEPITHELIAL NEOPLASIA

Cytology of CIN

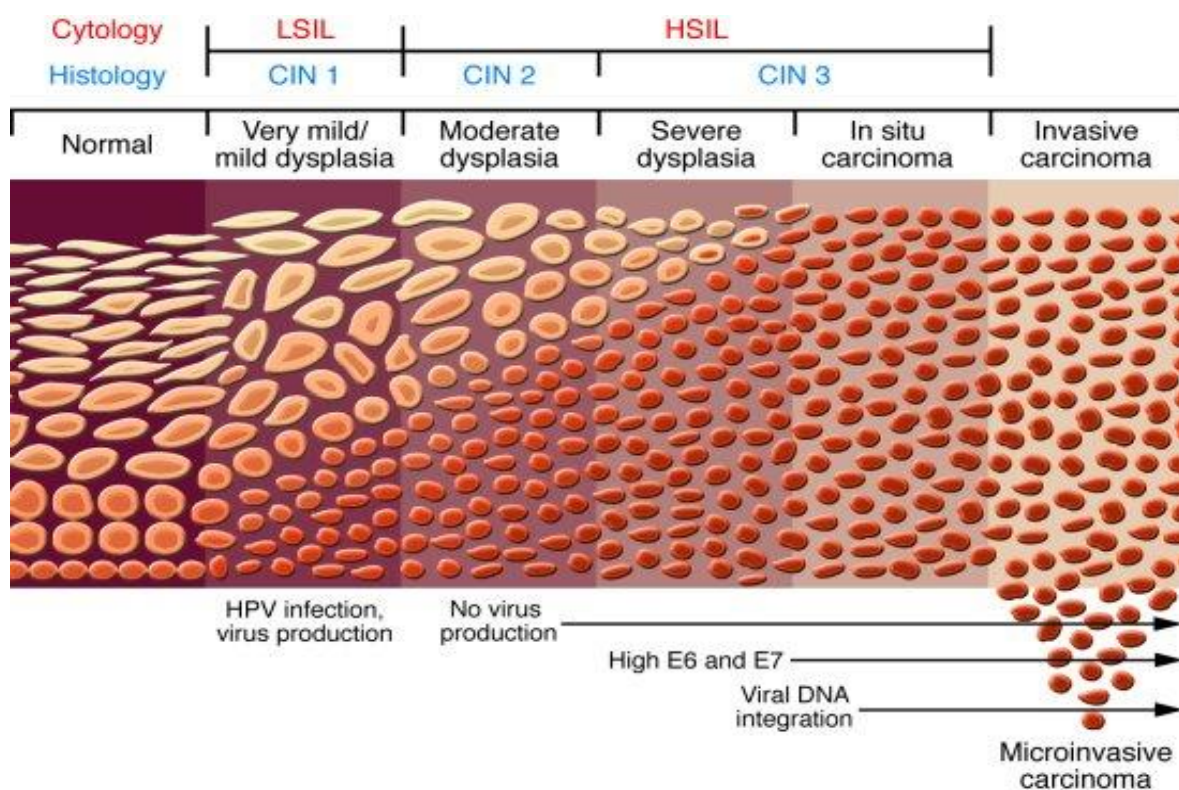
- CIN may be identified by microscopic examination of cervical cells in a cytology smear stained by the **Papanicolaou technique** (Pap smear).
- In cytological preparations, individual cell changes are assessed for the diagnosis of CIN and its grading.
- In contrast, histological examination of whole tissues allows several other features to be examined.
- Cytological assessment of CIN, based on nuclear and cytoplasmic changes is often quite challenging.

Cervical Cytology – Features of Dysplastic Cells

- Nuclear enlargement with variation in size and shape is a feature of all dysplastic cells .
- Increased intensity of staining (hyperchromasia).
- Irregular chromatin distribution with clumping.
- Mitotic figures and visible nucleoli.
- nuclear polymorphism and variation in nuclear size (anisokaryosis).
- Abnormal nuclei in superficial or intermediate cells indicate a **low-grade CIN**,
- whereas abnormality in nuclei of parabasal and basal cells indicates **high-grade CIN**.
- The amount of cytoplasm in relation to the size of the nucleus (nuclear-cytoplasmic ratio) is one of the most important principles for assessing the grade of CIN. Increased ratios are associated with more severe degrees of CIN.

Diagnosis and Grading of CIN by Histopathology

- The disease asymptomatic.
- The proportion of the thickness of the epithelium showing mature and differentiated cells is used for grading CIN.
- Final diagnosis of CIN is established by the histopathological examination of a cervical **punch biopsy** or excision specimen.
- Nuclear abnormalities are assessed when a diagnosis is being made.
- There is a strong correlation between the proportion of epithelium revealing maturation and the degree of nuclear abnormality.
- Mitotic figures infrequent in normal epithelium and, if present, they are seen only in the parabasal layer.
- As the severity of CIN increases, the number of mitotic figures increases; seen in the superficial layers of the epithelium.
- less differentiation → higher mitotic figures.



Cervical Intraepithelial Neoplasia – Grades

CIN I

- CIN I there is good maturation with minimal nuclear abnormalities and few mitotic figures.
- Undifferentiated cells are confined to the deeper layers (**lower third**) of the epithelium.
- Cytopathic changes due to HPV infection may be observed in the full thickness of the epithelium.

- **CIN I** : involvement of inner 1/3 of the epithelium.
- **CIN II** : involvement of inner 1/2 to 2/3 of the epithelium.
- **CIN III** : involvement of full thickness of the epithelium.

CIN II

characterized by dysplastic cellular changes mostly restricted to the lower half or the **lower two-thirds** of the epithelium, with more marked nuclear abnormalities than in CIN 1 .

CIN III

differentiation and stratification may be totally absent or present only in the superficial quarter of the epithelium with numerous mitotic figures.

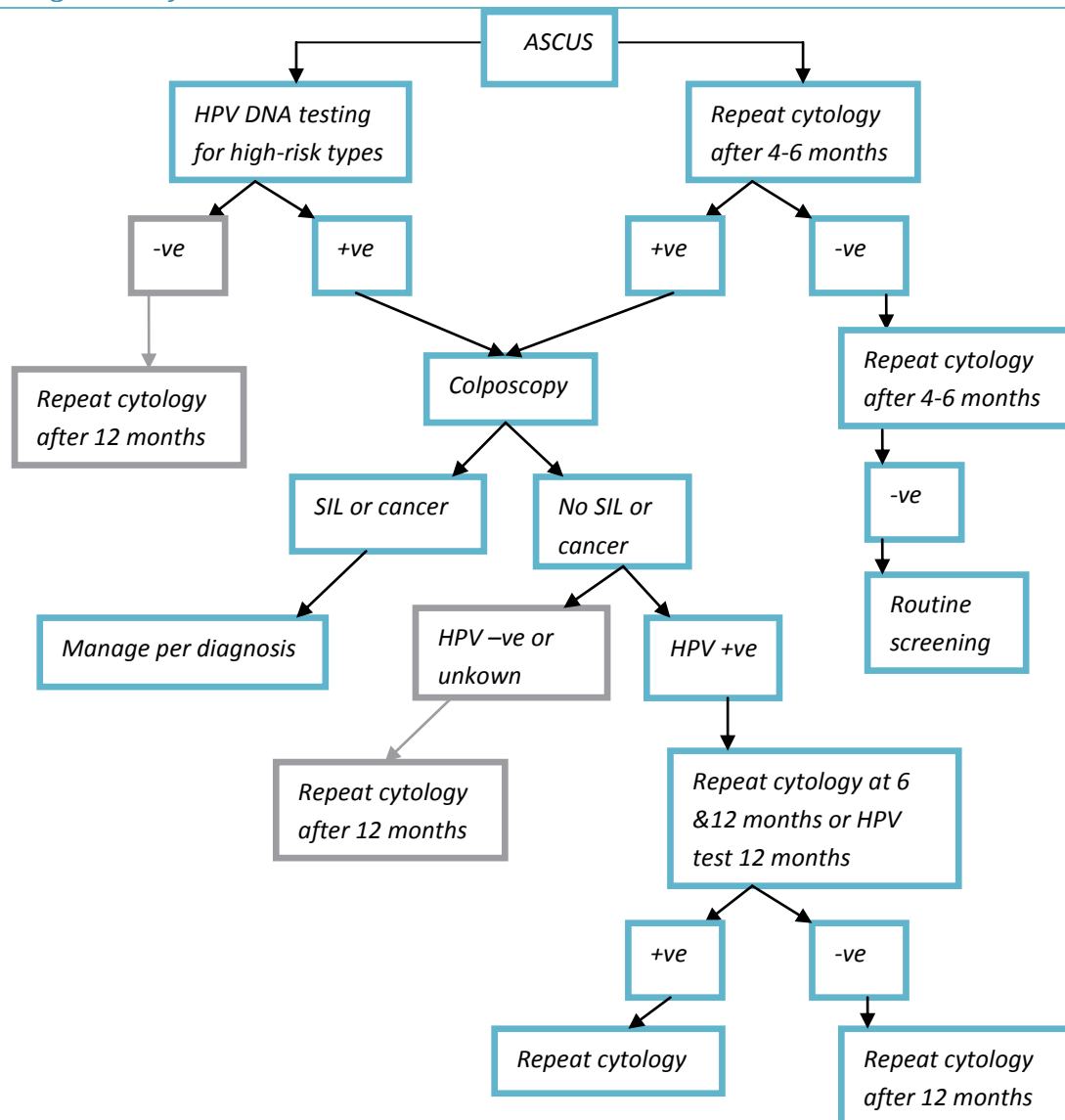
Natural History of CIN

Table 2.3: Regression, persistence and progression probabilities of CIN

CIN category	Regression	Persistence	Progression to CIN 3	Progression to invasive cancer
CIN 1	57%	32%	11%	1%
CIN 2	43%	35%	22%	1.5%
CIN 3	32%	56%	-	12%

75% of cervical dysplasia in pregnancy undergo complete involution.

Management of ASCUS



- Post menopausal women with (ASC-US) or atrophy → intravaginal estrogen cream (7days) → repeat cytology after 7days→
 - -ve → repeat the test 4-6 months.
 - +ve → colposcopy.
- Immunocompromised and HIV with (ASC-US) → colposcopy.
- Pregnant (ASC-US) → managed as non pregnant.

Management of Low-Grade Squamous Intraepithelial Lesion (LGSIL)

- 15-30% LSIL will have CIN II or III identified in subsequent biopsies.
- CIN I and koilocytosis majority has spontaneous resolution→ follow-up conservative management.
- If persist or progress→ should be treated.

Management of High-Grade Squamous Intraepithelial Lesion (HGSIL)

- HSIL have 70-75% chance of having biopsy confirmed CIN II & III and 1-2% Invasive cervical cancer. → colposcopy & Endocervical curettage (ECC) and then excisional therapy.
- During pregnancy → colposcopy but **no ECC** → if high suspicion of invasive cancer → biopsy in 2nd trimester and follow-up till postpartum. (ECC can induce abortion).

Treatment of CIN

Treatment of **CIN I** → **Observation** because most cases regress spontaneously.

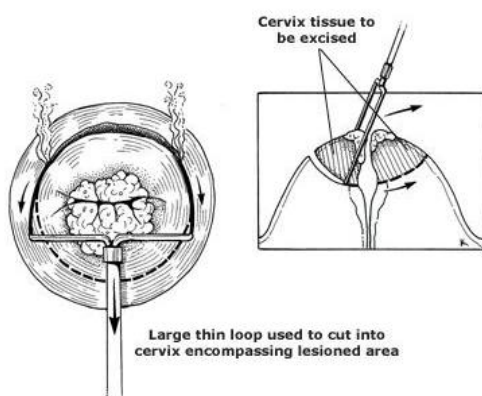
Active treatment is indicated for **CIN II and III**.

Superficial Ablative techniques

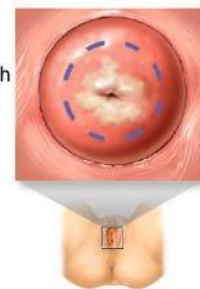If the T zone is visible, CIN II and III are treated with superficial ablation. The techniques used are:

1. Large Loop Excision of the Transformation Zone (LLETZ).
2. Carbon dioxide laser.
3. Cryosurgery.

Large Loop Excision of the Transformation Zone



Compressed nitrogen gas flows through a cryo probe making the metal cold enough to freeze and destroy the abnormal cervical tissue



Cervix as viewed through speculum with patient in lithotomy position

ADAM.

Other types of treatment

1. **Cervical conization:** IT is mainly a diagnostic technique, but it may be used for treatment (if the T zone is not visible).
2. **Hysterectomy:** rarely necessary for the treatment of CIN. It may be applicable if there is concomitant uterine or adnexal disease.
3. Local excision, Electrocautery.

Invasive Cervical Cancer

Staging

Table 38-1. INTERNATIONAL FEDERATION OF GYNECOLOGY AND OBSTETRICS (FIGO) STAGING OF CERVICAL CARCINOMA

PREINVASIVE CARCINOMA	
Stage 0	Carcinoma in situ, intraepithelial carcinoma (cases of stage 0 should not be included in any therapeutic statistics)
INVASIVE CARCINOMA	
Stage I	The carcinoma is strictly confined to the cervix.
Stage Ia	Invasive cancer is identified only microscopically. All gross lesions even with superficial invasion are Ib cancers. Invasion is limited to a measured stromal invasion, with a maximal depth of 5 mm and a horizontal extension of not more than 7 mm.
Stage Ia1	Measured invasion of stroma not greater than 3 mm in depth and 7 mm in width
Stage Ia2	Measured invasion of stroma greater than 3 mm and not greater than 5 mm and width not greater than 7 mm
Stage Ib	Clinical lesions confined to the cervix or preclinical lesions greater than stage Ia
Stage Ib1	Clinical lesions not greater than 4 cm in size
Stage Ib2	Clinical lesions greater than 4 cm in size
Stage II	The carcinoma extends beyond the cervix but has not extended to the pelvic wall or to the lower third of the vagina.
Stage IIa	No obvious parametrial involvement
Stage IIb	Obvious parametrial involvement
Stage III	The carcinoma has extended to the pelvic wall. On rectal examination, there is no cancer-free space between the tumor and the pelvic wall. The tumor involves the lower third of the vagina. All cases with hydronephrosis or non-functioning kidney should be included, unless they are known to be due to another cause.
Stage IIIa	Tumor involves lower third of the vagina with no extension to the pelvic wall.
Stage IIIb	Extension onto the pelvic wall and/or hydronephrosis or nonfunctioning kidney
Stage IV	The carcinoma has extended beyond the true pelvis or has clinically involved the mucosa of the bladder or rectum. A bullous edema, as such, does not permit a case to be allotted to stage IV.
Stage IVa	Spread of the growth to adjacent organs
Stage IVb	Spread to distant organs

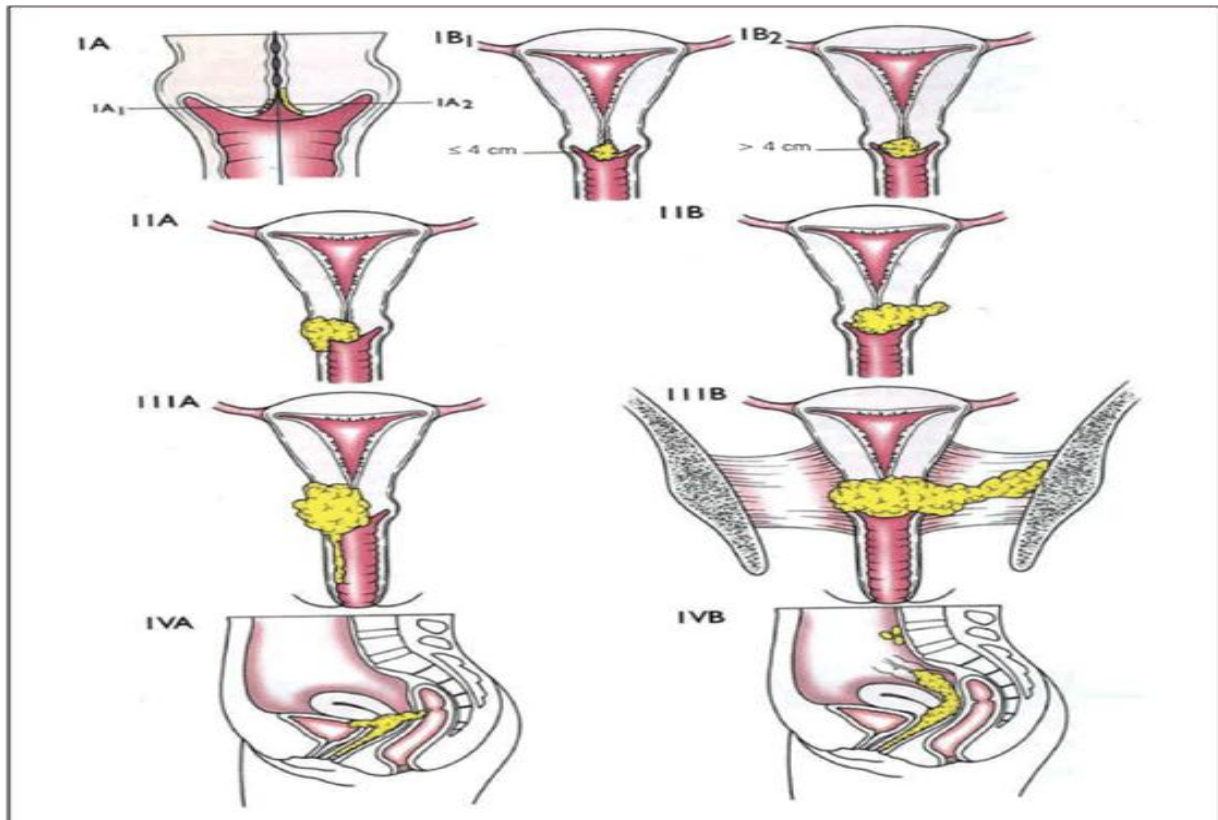


Figure 1. Staging of uterine cervix carcinoma according to FIGO⁽³⁾.

ADENOCARCINOMA IN SITU (AIS)

- AIS is a premalignant glandular condition and is the precursor to cervical adenocarcinoma. It arises from the columnar epithelium.
- Less common than squamous cell carcinoma.
- In AIS, normal columnar epithelium is replaced by abnormal epithelium showing: loss of polarity, increased cell size, increased nuclear size, nuclear hyperchromasia, mitotic activity, reduction of cytoplasmic mucin expression and cellular stratification or piling.
- Abnormal branching and budding glands with intraluminal papillary epithelial projections lacking stromal cores observed.
- **It is sub-divided based on the cell types into:** endocervical, endometrioid, intestinal and mixed cell types. The majority of AIS are found in the transformation zone.

AIS may be associated with CIN of the squamous epithelium in one- to two-thirds of cases.

Management of Atypical Glandular cells (AGS) and AIS

- < 35 y/o → colposcopy, indicated biopsy and Endocervical curettage (ECC).
- > 35 y/o → colposcopy, indicated biopsy, ECC and endometrial biopsies.

Miscellaneous uncommon or rare cancers of the cervix

It include variants of squamous cell carcinoma (SCC) and adenocarcinomas, mixed carcinomas:

1. **small-cell carcinoma** that are similar to neuroendocrine tumors occurring elsewhere,
2. **sarcoma**,
3. **lymphoma**
4. **Melanoma**
5. **Metastatic tumors**.

Most metastases are from the **endometrium**, and in some patients with extensive or bulky cervical involvement, determining the true origin of the lesion may be difficult. Other common sources of metastases include the **ovary**, **colon**, and **breast**.

Histopathologic types

Squamous cell carcinoma (SCC) accounted for **80-90%** of all cervical malignancies.

The major histopathologic SCC subtypes include:

1. well-differentiated, keratinizing, large-cell SCC (25% of cases).
2. moderately differentiated, non-keratinizing, large-cell SCC (70% of cases).
3. small-cell undifferentiated carcinoma (about 5% of cases), which is associated with a distinctly poor prognosis.

The histologic patterns of adenocarcinoma include:

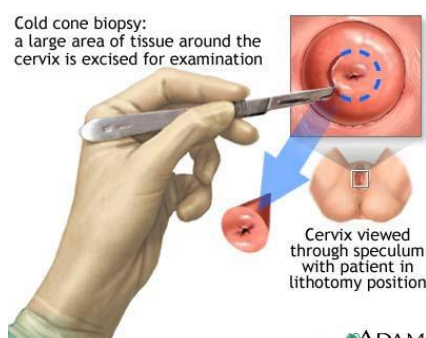
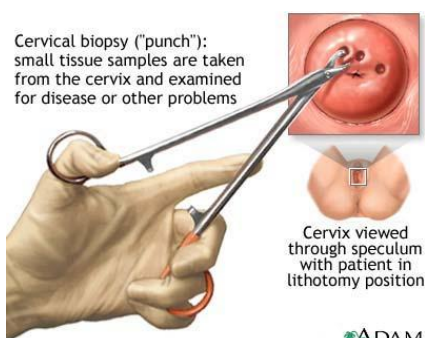
1. Well-differentiated mucinous adenocarcinoma.
2. Papillary adenocarcinoma.
3. Clear-cell pattern that contains glycogen but no mucin.
4. Many of these lesions may simulate endometrial adenocarcinoma.

There is a relatively higher incidence of poorly differentiated and more aggressive histologic subtypes of cervical adenocarcinoma that are associated with a poorer prognosis than SCC.

Diagnosis

Laboratory Studies

- A Papanicolaou test should be performed in every patient suggested to have a diagnosis of cervical cancer (**Screening**).
- The patient should be referred to a gynecologist for **colposcopy**, **direct biopsies**, and **endocervical curettage (ECC)**.
- After the diagnosis is established, a complete blood cell count and serum chemistry for renal and hepatic functions should be ordered to look for abnormalities from possible metastatic disease.



Colposcopy indications

- Colposcopy is indicated when the presence of a malignant or premalignant lesion in the cervix, vagina, or vulva is suspected.
- Another specific indication is evaluation of a patient who presents with postcoital vaginal bleeding.
- The most common situation arises as the result of cervical cytological screening as part of a routine health maintenance evaluation (when there is abnormal cytologic finding).

Imaging Studies

- Imaging studies are performed for staging purposes.
- A routine **chest radiograph** rule out pulmonary metastasis.
- **CT scan** of the abdomen and pelvis to look for metastasis in the liver, lymph nodes, or other organs and to rule out hydronephrosis/hydroureter.
- In patients with bulky primary tumor, **barium enema** studies to evaluate extrinsic rectal compression from the cervical mass.
- The use of **positron emission tomography (PET) scan** is now recommended for patients with stage IB2.

Other Tests

The International Federation of Gynecology and Obstetrics (FIGO) guidelines for staging are limited to colposcopy, biopsy, conization of cervix, cystoscopy, and proctosigmoidoscopy.

- surgical staging frequently is recommended.
- In patients with bulky primary tumor, **cystoscopy** and **proctoscopy** should be performed to help rule out local invasion of the bladder and the colon.

Treatment

Treatment according to stage

Stage 0: (CIS)

Treatment options for stage 0 cancer include loop electrosurgical excision procedure (LEEP), laser therapy, conization, and Cryotherapy. (same as CIN II and III).

Stage Ia: (Microinvasive Carcinoma)

→The treatment of choice for stage IA disease is surgery—**total hysterectomy**.

- **Ia1** → extrafascial abdominal or vaginal hysterectomy is appropriate treatment, and conization with good margins (if the patient wants to maintain fertility).
- **Ia2** → If lymphatic or vascular space involved, modified radical hysterectomy and pelvic node dissection. Radical trachelectomy (Surgical removal of the cervix) with pelvic lymph node dissection is appropriate for fertility preservation in **stage IA2 and B1**.
- Patients with medical co-morbidities who are not surgical candidates can be successfully treated with radiation.
- Intracavitary radiation is an option for selected patients.

Intracavitary radiation: internal radiation therapy in which radioactive material sealed in needles or catheters is placed directly into a body cavity.

Stage Ib or IIa disease:

- Treatment options are either combined external beam radiation with brachytherapy or radical hysterectomy with bilateral pelvic lymphadenectomy.

Brachytherapy: radiotherapy where a radiation source is placed inside or next to the area requiring treatment.

Stage IIb-IVa

- For locally advanced cervical carcinoma (**stages IIb, III, and IVa**), there is a dramatic improvement in survival with the combined use of chemotherapy and radiation.
- Radiation therapy begins with a course of external beam radiation to reduce tumor mass to enable subsequent intracavitary application. Brachytherapy is delivered using afterloading applicators that are placed in the uterine cavity and vagina.
- using cisplatin-based chemotherapy in combination with radiation for patients with locally advanced cervical cancer (**stages IIB, III, and IVA**) represents the standard of care.

Stage IVb and recurrent cancer

- These patients are treated with chemotherapy. For many years, single agent cisplatin represented the standard of care. Recently, the combined use of cisplatin and topotecan was shown to significantly improve survival compared with single-agent cisplatin.
- Palliative radiation is often used individually to control bleeding, pelvic pain, or urinary or partial large bowel obstructions from pelvic disease.
- Total pelvic exenteration may be considered in patients with an isolated central **pelvic recurrence**. (In this surgery, the uterus, cervix, ovaries, fallopian tubes, vagina, bladder, urethra, and rectum are removed)

Surgical Care

- Carcinoma in situ (stage 0) is treated with local ablative measures such as cryosurgery, laser ablation, and loop excision.
- Hysterectomy should be reserved for patients with other gynecologic indications to justify the procedure.
- After local treatment, these patients require lifelong surveillance.
- Invasive procedures such as nephrostomy or diverting colostomy sometimes are performed in this group of patients to improve their quality of life.
- Special effort should be made to ensure comprehensive palliative care, including adequate pain control for these patients.

Medications

Chemotherapy should be administered in conjunction with radiation therapy to most patients with stage Ib (high risk) to IVa.

Cisplatin is the agent used most commonly, although 5-fluorouracil also is used frequently.

- For patients with metastatic disease, cisplatin remains the most active agent.
- Topotecan, ifosfamide, and paclitaxel also have significant activity in this setting. The combination of topotecan and cisplatin improves overall survival.
- acute toxicities are also increased.

Chemotherapy

- **Cisplatin (Platinol)** : intrastrand cross-linking of DNA and inhibition of DNA precursors are among proposed mechanisms of action. Used in combination with radiation therapy.
- **5-Fluorouracil (Efudex, Adrucil, Fluoroplex)**: Pyrimidine antagonist. Several mechanisms of action have been proposed, including inhibition of thymidylate synthase and inhibition of RNA synthesis. Also, it is a potent radiosensitizer.
- **Ifosfamide (Ifex)**:
Forms DNA interstrand and intrastrand bonds that interfere with protein synthesis.
- **Paclitaxel (Taxol)**:
Mechanisms of action are tubulin polymerization and microtubule stabilization.
- **Topotecan**:
Inhibits topoisomerase I, inhibiting DNA replication. Patients who have received prior chemotherapy should be given a lower dose initially.

Vaccines

Papillomavirus vaccine

Adult

- <26 years: 0.5 mL IM administered as 3 separate doses; administer second and third doses 2 and 6 mo after first dose, respectively.
>26 years: Not established.

Pediatric

- <9 years: Not established.
>9 years: Administer as in adults.

Complications

Complications from radiation alone

- During the acute phase of pelvic radiation, the surrounding normal tissues such as the intestines, the bladder, and the perineum skin often are affected.
- Acute adverse gastrointestinal effects include diarrhea, abdominal cramping, rectal discomfort, or bleeding. Diarrhea usually is controlled by either loperamide (Imodium) or atropine sulfate (Lomotil). Small, steroid-containing enemas are prescribed to alleviate symptoms from proctitis.
- Cystourethritis also can occur, which leads to dysuria, frequency, and nocturia. Antispasmodics often are helpful for symptom relief.
- Urine should be examined for possible infection.
- If urinary tract infection is diagnosed, therapy should be instituted without delay.
- Proper skin hygiene should be maintained for the perineum, and topical lotion should be used in case erythema or desquamation occurs.
- Late sequelae of radiation usually appear 1-4 years after treatment.

- *The major sequelae include rectal or vaginal stenosis, small bowel obstruction, malabsorption, and chronic cystitis.*

Complications from surgery

- *The most frequent complication of radical hysterectomy is **urinary dysfunction** as a result of partial denervation of the detrusor muscle.*
- *Other complications include foreshortened vagina, ureterovaginal fistula, hemorrhage, infection, bowel obstruction, stricture and fibrosis of the intestine or recto sigmoid colon, and bladder and rectovaginal fistulas.*

Prognosis

- *Prognosis of cervical cancer depends on disease stage.*
- *In general, the 5-year survival rate for stage I disease is higher than 90%, for stage II is 60-80%, for stage III is approximately 50%, and for stage IV disease is less than 30%.*

MCQs

1. Screening is effective in preventing which of the following cancers:

- A. Vulva.
- B. Cervix.
- C. Endometrial.
- D. Ovary.
- E. Fallopian tube.

Answer: B.

2. Untreated patients with cervical cancer usually die with:

- A. Cachexia and starvation.
- B. Bowel obstruction.
- C. Renal failure and uremia.
- D. Multi organ failure.
- E. Cerebrovascular accidents.

Answer: C.

3. Occult carcinoma of the cervix:

- A. Stage IA.
- B. Micro-invasive carcinoma.
- C. Best treated by cone biopsy.
- D. Found incidentally in a surgical specimen following hysterectomy.
- E. Frequently associated with negative cytology.

Answer: D.

4. All the following is true regarding carcinoma of the cervix EXCEPT:

- A. The region originates within the transformation zone in the majority of cases.
- B. The disease is more common in multiparous women.
- C. It is unlikely for the disease to cause ureteric obstruction.
- D. The lesion is typically squamous in nature.
- E. Spread to iliac nodes usually.

Answer: C.

5. 28 year old lady P3+2 presented to the clinic with history of irregular menstrual cycle for 2 months. She has no history of post-coital bleeding. She had Pap smear which showed high-grade squamous cell intraepithelial lesion (CIN II). The proper management is:

- A. Follow-up and repeat Pap smear after 6 months.
- B. Laser cone biopsy
- C. Examination under anesthesia and D & C.
- D. Colposcopic assessment and pelvic biopsy.
- E. Cryotherapy and antibiotic.

Answer: B.

6. The most common benign neoplasm of the cervix and endocervix is a:

- A. Polyps.
- B. Hematoma.
- C. Nabothian cyst.
- D. Cervical hood.
- E. Gartner duct cyst.

Answer: A.

7. Risk factors for cervical cancer include all the following, EXCEPT:

- A. Nulliparity.
- B. Multiple sexual partners.
- C. History of papilloma virus infection.
- D. Smoking
- E. Sexual activity at early age.

Answer: A.

8. The most common clinical presentation of early cervical cancer is:

- A. Foul-smelling vaginal discharge.
- B. Asymptomatic.
- C. Post-coital bleeding.
- D. Pelvic pain with leg edema.
- E. Lower back pain.

Answer: C.

9. Significant risk factors for cervical cancer are all of the following, EXCEPT:

- A. 1st sexual intercourse at a young age.
- B. Multiparity.
- C. Cigarette smoking.
- D. Human papilloma virus.
- E. HIV-seropositivity.

Answer: E.

10. Which one of the following stages is the FIGO clinical staging for cervical carcinoma when the pelvic sidewall is not involved, but the lower one third of the vagina is involved?

- A. Stage IIa.
- B. Stage IIb.
- C. Stage IIIa.
- D. Stage IIIb.
- E. Stage IV.

Answer: C.