

Principle of Fractures

- **A Fracture is a Break in the continuity of bone**
- It could be complete or incomplete (green-stick fracture)
 - Complete usually in old people.
 - Incomplete usually in pediatric due to high water content in the bone.



Fig. 1 Complete fracture

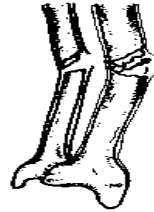

Fig. 2 Incomplete fracture

◆ Classification of fracture:

- It may classify in different ways:
- Depending on communication with external environment :
 - 1- Simple (closed): Does NOT communicate with external environment
 - 2- Compound (open): Communicate with external environment, Infection!!→orthopedic emergency.
"Note: In-out open fracture (the bone get out of the skin) OR out-in open fracture (anything broke the bone and get inside)".
- Depending on the presence or absence of soft tissue (viscera, nerve, blood vessel) damage:
 - 1- Complicated : Associated with damage to nerves, vessels or internal organs
 - 2- Non-complicated.

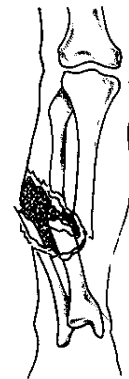

Fig. 4 Open fracture tibia

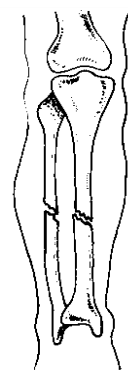


Fig 3. closed fracture tibia

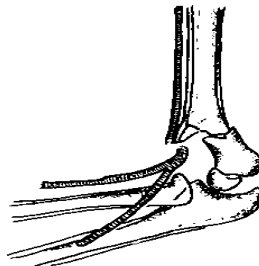


Fig. 5 A supracondylar fracture of the humerus with damage to the brachial artery

- Depend on amount of force ; it is classified into :

1- Traumatic fracture.	
2- Pathological : Fracture abnormal bone Cyst, Tumor, Infection	<p style="text-align: center; font-size: small;">Fig 6 Pathological fracture - simple bone cyst</p>

Other special classification e.g.: fracture around the hip, ankle, etc.

Group A1

- **Dislocation** : Complete separation of the articular surface . Distal to proximal fragment Anterior, Posterior, Inferior, Superior .can't move.

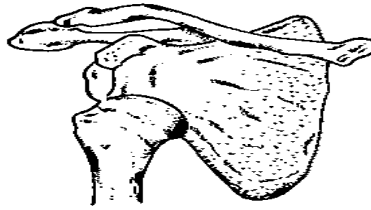


Fig. 7 Dislocation of the shoulder

- **Subluxation**:-Incomplete separation (partial separation). Joint Function in Anatomical position Only, can be moved!!

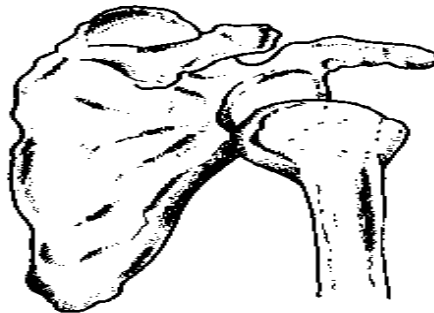


Fig. 8. Subluxation of the shoulder

Note: The **Dislocation&Subluxation** can be associated with Fracture.

◆ Mechanism of injury:

The line and extent of the fracture are determined by:

- 1- Amount of physical force.

Trivial force = Pathological

Magnitude = Non-pathological

- 2- Direction of physical force (direct or indirect)((we don't have to know the details just the fracture can be direct & indirect force))

Details: غي مطلوب



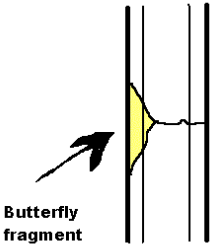


A-direct force:

- The bone fractured at the point of impact.
- Usually associated with complicated fracture. 🙌
- 3types:
 - 1- Trapping force: lead to transverse fracture.
 - 2- Crushing force; lead to comminuted fracture.
 - 3- Penetrating force; lead to comminuted fracture.

N.B. comminuted fracture: one in which the bone is splintered or crushed.

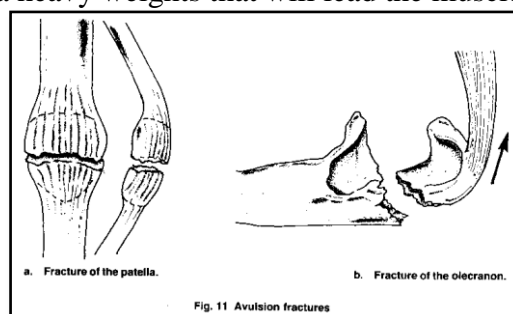
Group A1B- Indirect force:

- It is a force which is exerted at a distance from the site of the fracture.
- Less chance to association with complicated fracture.👉
- 5 types:

1- Twisting force; lead to spiral fracture.		2- Angulation force; lead to transverse fracture .(may need ORIF or 3weeks casting)	
3- Angulation +axial compression force; lead to partial transverse fracture +butterfly (a separate triangular fragment).👉 N.B. The axial fracture in spine occurs at: <i>thoracolumbar</i> .	 <p>Butterfly fragment</p>	4- Twisting + angulation + axial compression; lead to short oblique fracture.90%need surgery. maybe it takes time if conservative	
	5- Vertical compression force → in spine or lower limbs ;lead to comminuted fracture Direction of Force On Cancellous Bones:- Direct OR Indirect Comminuted Pattern Burst		

Indirect force due to Resisted Muscle Action: - “Avulsion” Transverse pattern

Note: i.e. Bodybuilders lift a heavy weights that will lead the muscle to break the bone.



◆ Diagnosis:

A. History :(Note: always it's acute history of trauma.)

- ❖ Ask about history of trauma; to exclude pathological fractures.
 - * Pathological (trivial)
 - * Non-pathological (magnitude)
- ❖ Mechanism of trauma to suspect :(asks about: Fall from height, RTA, pedestrian, Driver....?)
 - 1- The possible injury
 - 2- The association with soft tissue injury
 - 3- Help in management (by reverse the force during reduction).
- ❖ Complaints :
 - Pain: sharp, sudden in onset, aggravated by movement, relived by rest, usually not referred. (Localized).
 - Lose of function.
 - Deformity.
 - Symptom related to complications.
- ❖ Ask about other systems especially in head, chest and abdominal injuries.
- ❖ Past medical, surgical history.
- ❖ Past drug history (important in pathological fracture).♫

Commonest Presentation

B. Examination :

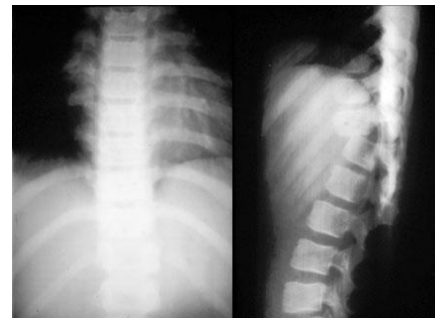- ❖ General examination :
 - ✓ Sign due to fracture or trauma :
 - Vital signs, Shock A,B,C
 - Any associated injury to head, chest, or abdomen.
 - ✓ Sign related to the cause fracture (especially to the pathological fracture) for example; cancers of lung or prostate. (Full examination if we suspect pathological fracture.)
- ❖ Local examination :(always compare)

Look	Feel	Move	Do
Simple Vs. compound fracture	Localized Tenderness	Active Vs. passive movement	Special test: a) Circulation b) Nerves
Any deformity		Abnormal movement	Measurement: shortening
Hematoma		Crepitus	
Skin lesion → look for open fracture			
Swelling			

C. X-rays:

Essential requirements: 2 views 2 Joints

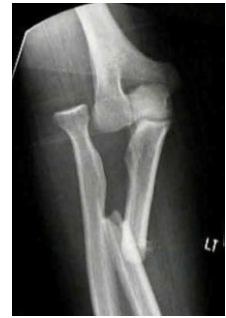- ❖ Two views:
 - Antero-posterior (AP view) and lateral view.
 - It is need for 2 reasons:
 - Some fracture may show in one view only,e.g.: undisplaced fracture of the neck of the femur.
 - To determine the degree of displacement at the fracture site.



Group A1

❖ Two joints:

- Joints above and below the site of fracture.
- It is needed for two reasons:
 - ◆ To detect any associated injury.
 - ◆ To determine the angulation at the fracture site.
- Pre and post reduction.

Occasional requirements:

- Two limbs for comparison, especially in children.
- Repeat the X-ray after 1-2 weeks (Two Occasions):
- Indication if the X-ray doesn't show a fracture.
- (**Note:** common in bones with less blood supply e.g.: scaphoid, femoral neck,...)
- Applied most commonly in suspected fracture to the scaphoid.
- Special X-ray, e.g. stress films to ligamentous injuries (decrease its use nowadays since the MRI has taken the job).

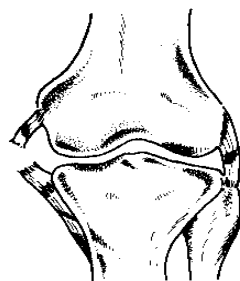


Fig. 13 The knee looks normal although the medial ligament is ruptured

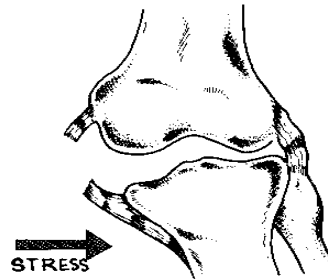


Fig. 14 Same knee under valgus stress shows widening due to the ruptured medial ligament.

◆ **Description of the fracture on X-ray:**

- Situation:
 - Side (right or left)
 - Site (upper, middle, or lower).
- Pattern: Line of the fracture (transverse, spiral, or comminuted)
- Displacement which could be:
 - ◆ Shift (**how much is the bone displaced**) (lateral, medial, anterior, or posterior)
 - ◆ Tilt (**angle**) (angulation)
 - ◆ Twist (rotation) (internal or external)
 - ◆ Shortening (overriding or impaction)

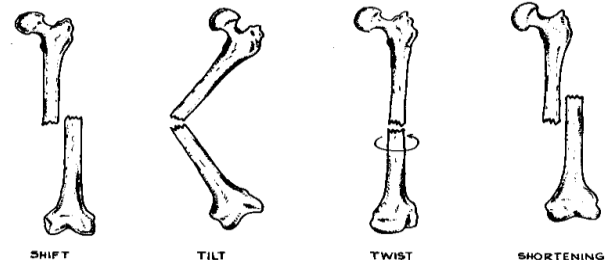


Fig. 15 Displacement

◆ **Management:**

Repair of the fracture:

a- **Primary repair:**

- With Rigid Internal Fixation
- No Callus formation
- Active Haversian remodeling
- Long time to heal

b- **Secondary Repair:**

- **Without rigid fixation**
- **Commonest type even with I.F.** (internal fixation)
- Fast healing → **because of the presence of the hematoma**
- Callus formation

◆ Healing of fracture:

- ◆ Factor that affect the rate and effectiveness of healing process:
 - Age
 - Line of fracture
 - Systemic or local disease.

A. fracture healing without rigid fixation :

- ❖ **Stage I:** hematoma formation: Clot formation (**Note:** hematoma formation has all the supplement of bone healing).
- ❖ **Stage II :** traumatic inflammation :
 - More fibrin will accumulate to already present clot.
 - Increase blood flow and infiltration of leukocyte.
- ❖ **Stage III :** Demolition:
 - Macrophage will take place through removal of inflammatory exudates, fibrin, RBC's and debris.
 - Remove any bone fragment undergoes necrosis by macrophage and osteoclasts.
- ❖ **Stage IV:** formation of granulation tissue.
- ❖ **Stage V :** woven bone and cartilage formation :
 - By the activity of osteoblasts.
 - Formation of external intermediate and internal callus (callus: unorganized network of woven bone, which is absorbed as healing, is completed, and ultimately replaced by true bone).
- ❖ **Stage VI:** Formation of lamellar bone: Form over the woven bone and cartilage.
- ❖ **Stage VII.** Remodeling: (Note: The remodeling can't be happened if the bone twisted.)
 - Continuation of osteoclastic removal and osteoblastic laying down of bone.
 - External callus will removed slowly, intermediate callus converted to compact bone while the internal callus will hollow into narrow cavity which contain cancellous bone.

B. Fracture healing with rigid internal fixation :

- The bone heals by primary vascular bone formation.
- No formation of external or internal callus.☞

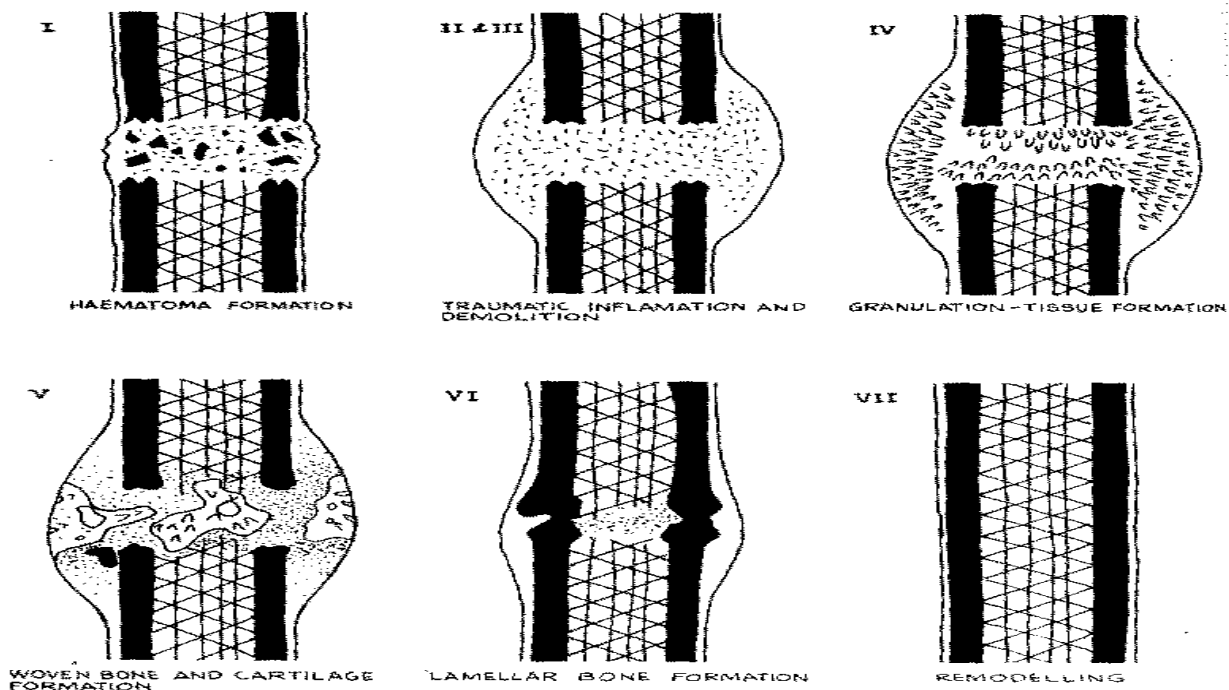


Fig. 37 Stages in fracture repair without rigid fixation

Group A1

Time Factor- Perkin's formula		
	Union	Consolidation (remodeling)
Upper limb	Spiral: 3 weeks Transverse : 6 weeks	Spiral=6 weeks Transverse =12 weeks
Lower Limb	Spiral:6 weeks Transverse:12 weeks	Spiral =12 weeks Transverse =24 weeks

N.B. Remodeling takes double the time of union .AND the children take the half of the period.

◆ Fractures in children:

- Fracture in children has a special consideration for the following reasons:
 - 1) Healing is more rapid.
 - 2) Open reduction is rarely indicated, except in cases of fracture into joints♣ .
(Note: We always start the management with closed reduction until we need to do open reduction.)
 - 3) High remodeling rate. Especially in angular deformities not in rotation deformities.
 - 4) Growth disturbance in epiphyseal injuries.
 - 5) Often missed due to poor communication with the child .b/c the child often tends to cry.
 - 6) X-rays of both limbs for comparison are required .especially if it is near joints.
- Children differ than adult in:
 - 1) Children bones are more malleable, allowing a plastic type of bowing injury.
 - 2) The periosteum is thicker than adult & usually remain intact on one side of fracture♣.
 - 3) Usually incomplete so, green stick fracture is common.
- Fracture caused by child abuse :
 - Multiple areas of large ecchymosis in different stages of resolution (from black & blue to brown & green) also are pathognomic of child abuse.
 - Mostly occurs between birth and 2 years of age.
 - Most commonly occurs in long bones (humerus , tibia , femur)
 - bone scan or a skeletal survey generally is indicated
 - It may be diagnose d by excludition :
 - 1-Heamophilia
 - 2- metabolic bone disease
- ☒ N.B. multiple fractures in different stage of healing are almost indicative of abuse.
- ☒ N.B. growth plate b/w metaphyseal&epiphyseal.

Note:






- The growth plate is the weakest point more than bone & soft tissue also it's the most common place in injury.
- Injury in the growth plate (in the side or middle of growth plate) can cause deformity (e.g. angular deformity, leg length discrepancy...).
- We have to compare to the other limb in case of fracture.
- We have to apply a cast if we suspect fracture with no x-ray sign of fracture.

A. Physeal injuries :

- Represent 30% of fractures.♣
- Occurred twice as often in the upper extremities as in the lower extremities .
- Commonly used classification is that of salter and harris , which is based on the roentgenographic appearance of the fracture .

N.B. before applying the Salter & Harris classification you should note the open growth plate.

Salter & Harris classification for physeal injury

Type	Features	Treatment	Prognosis
 I	Epiphysis is completely separated. No fracture through bone.	By closed reduction	Excellent No growth – disturbance
 II	Commonest type (70%) Small fracture through metaphysis.	By closed reduction	Excellent No growth – disturbance
 III	It is intra –articular fracture .(only in epiphysis)	Accurate reduction is essential. Open reduction may be necessary.	Good
 IV	It is intra –articular fracture (in epiphysis +metaphysis)	Open reduction is almost always necessary.	Can be favorable if anatomically reduced.
 V	Due to severe crushing force. No epiphyseal displacement.	No reduction Just immobilization by plaster of paris cast.	Poor. Cessation of growth Angular deformities often occur.

NB : type I and IV are identical on Xray but Type I usually come acute

B. Birth fracture:

- Generally it is iatrogenic.
- These fractures occur most commonly in the clavicle "most common", humerus ,hip ,and femur .(long bones)
- They rarely require surgery.
- It is frequently diagnosed as pseudopalsy, infection, or dislocation.
- It may be present as a mass or deformities (length deformity is a common)
- Treatment:conservative.

◆ Pathological fracture:

- ◆ It is a break of the continuity of bone within an abnormal bone structure.
- ◆ Abnormal bone structure could be due to :
 - 1) Congenital disease (osteogenesis imperfect).(defect in type II collagen)
 - 2) Infection (osteomyelitis).
 - 3) Fracture through a cyst.
 - 4) Metabolic disease (osteoporosis, osteomalacia, Paget's disease).
 - 5) Primary bone tumors.(rare)
 - 6) Metastatic bone tumors. (more common) especially from:
(Kidney –thyroid- lung – prostate – breast...cancer's)

❖ **Diagnosis :**

✓ **History :**

- ◆ Insignificant amount of trauma.
- ◆ Constitutional symptoms.
- ◆ History of malignancy.
- ◆ Family History.

✓ **Examination :**

☒ **General :**

- a) Sign of malignancy ,e.g.: weight loss
- b) Sign of infection.

☒ **Local:**

- a) Tenderness, pain and swelling.
- b) Muscle spasm and deformity is minimal

✓ **Investigation :**

➤ **Radiology :**

- 1) X-rays, MRI, CT scan of the lesion site (are essential).
- 2) CRX and CT-chest to detect pulmonary metastasis .b/c the sarcomas of the bone metastasis to the lung.
- 3) Bone scan, PET scan.

➤ **Laboratory :**

- 1) Specific tests e.g. raised acid phosphatase in prostatic cancer, and positive bence jones protein (BJP) IN multiple myeloma.
- 2) Non-specific tests e.g. CBC, ESR, CRP, and LDH.

❖ **Management :**

- Aim: to make patient more functional and pain free for the remaining life span. (Saving life, limb, and its function).
- Early operative stability (e.g. by internal fixation) should be carried out.
- Other methods in advanced cancer such as chemotherapy, radiation, hormonal.
- Indication for prophylactic internal fixation (metastasis): مهمه
 - 1) Involvement of the cortex
 - 2) Increased pain
 - 3) Pure lysis
 - 4) Weight bearing area.

◆ **Aim of management:**

General aim: To Save the Life of Patient

Local aim: *Rapid Recovery* of Injured Part and Its Function.

⊙ General aim (save the life) by :

- Full general examination.
- Treat life threatening injury :
 - 1- Head, chest or abdominal injury.
 - 2- Shock

⊙ Local aim :

- Save the limb:
 - By early detection and treatment of:
 - Ischemia
 - Infection
- Save the function :
 - 1) Reduction
 - 2) Immobilization
 - 3) Soft tissue treatment
 - 4) functional activity & rehabilitation

1) Reduction :

- Should be Under Anesthesia
- Closed or Open
- Study X-Ray and direction of force
- The basic Maneuvers :
 - Traction
 - Reverse mechanism of Injury
 - Direct pressure

❖ Standards of reduction :

- Anatomical Reduction is Ideal for all type of fracture.
- Anatomical Reduction is *a MUST* be achieved in☺☺ :

**absolute
reduction**

{

- Dislocation
 - Intra-articular fractures (displaced fracture involves the joints especially in young patient.
 - Fractures both bones Forearm, to avoid loss of pronation and supination.
- X-Ray Image Intensifier help control reduction
- Remember to Assess Reduction after 10 Days☺☺ !
- Reduction can be “Acceptable” if :-
- Alignment will NOT affect Function, so some loss of opposition and slight degree of angulation (less than 10 degree) are acceptable.
- Remolding CAN correct deformity
- Remolding can correct :-
 - Angular deformities NOT Rotational deformities ☺
 - Children MORE than Adults

❖ Time of reduction:

- **Immediate Reduction** is a MUST in:
 - * Vascular Injury(risk of ischemia)
 - * Spinal Cord or Nerve Injury (risk of Para or quadric plegia)
- **Urgent R. in: (Note:** Within 6 - 24 hours but we are afraid from infection so we have to reduce it)
 - OPEN fractures ; “Save Limb”→ **from infection**
 - Dislocations Need Urgent reduction for Pain and pressure on surrounding pressure.
- CLOSED fractures **CAN wait** if Facilities do not permit Urgent management.

❖ Immobilization

“Life is Movement, and Movement is Life”

- Do NOT Immobilize Any Joint Unnecessarily👉
- Applied after fracture reduction until union.
- Can be achieved by:
 - Plaster of Paris
 - Traction
 - Internal Fixation
 - External Fixator

❖ Open fractures (compound fracture):

- ◆ Fracture site communicate with the external environment👉
- ◆ Emergency management
- ◆ Infection will occur with delayed or inadequate treatment👉

N.B. periosteum is rich in blood supply, thick in children →faster healing.

⊙ Management :**A. general care:**

- Aim: (save life, save limb, then save function).
- Antibiotics directed against staphylococci (most common), and as needed👉.
- Tetanus prophylaxis.
- In ER:
 - 1) Splint to prevent further damage.
 - 2) Check for tetanus.
 - 3) Start with antibiotic.
 - 4) If there is gross contaminated remove.
 - 5) Put wet sponge&send to OR.
- N.B. do not irrigate, debride or clean in ER.

B. local care:

- Aim: save the limb and function.
- Steps of operative procedure:
 1. Clean:
 - Fracture site is covered; Sterile Gauze
 - Skin shaved, Limb Cleaned “ Betadine”
 2. Irrigation: Plenty of Saline or Water Dilution is the Solution For pollution
 3. Debridement(Excise Wound):
 - Deride = Unleash tight structures
 - Skin: Excise edges, incise to explore!
 - Deep Fascia: open widely, Don’t Suture!
 - Dead Muscles: Excise Liberally
 4. Decontamination of the bone:
 - Curette ends, remove dirt
 - Remove small detached fragments
 - Keep large pieces
 - Reduce Fracture, Avoid Internal Fixation

Group A1

5. Closure

- Primary Closure Ideal! Skin Best Dressing
- Avoid Wound Tension
- Avoid primary suture of Nerves & tendons Except *Clean wounds * < 6 hours + *Expert
- Be aware of exception of closure in↓:
 - 1) Wound over 6 hrs.
 - 2) High velocity missile injuries (e.g. gunshot wound)
 - 3) Highly contaminated wounds.
 - 4) If closure cause tension of skin edges.

6. (Note: Reductions)

7. Immobilize.

2nd: look a patient after 48 hrs.

◆ **Complication:**☒ **Delayed Union:-**

- Healing Slow but still Active, Remove the cause!
- Fracture Site Tender
- X- Ray: little Callus, Medulla Open
- Smoking is one of the causes of delayed union

☒ **Non- Union:-**

- Reparative process Stopped, Need Intervention
- Painless, with Abnormal Movement, formation of Pseudoarthrosis (false joint)!
- X- Ray: Sclerosis, Blocked Medulla.

❖ **Delayed Union & Nonunion Causes:-**• **Local :-**

1. Poor Blood Supply
2. Soft Tissue Interposition
3. Infection
4. Inadequate Immobilization
5. Over-Distract
6. Pathology, Tumors

• **General:-**

- 1- Nutrition
- 2- Bone Disease
- 3- Old Age
- 4- Smoking
- 5- Hypothyroidism

☒ **Malunion:-**

- 1- Primary, i.e. Neglected fracture.
- 2- **After Reduction!** Watch X-Ray after 10 Days↓↓.
- 3- Secondary, i.e. unavoidable deformity e.g. crushing injury to Epiphyseal Growth plates causes deformities... fracture with extensive bone loss.

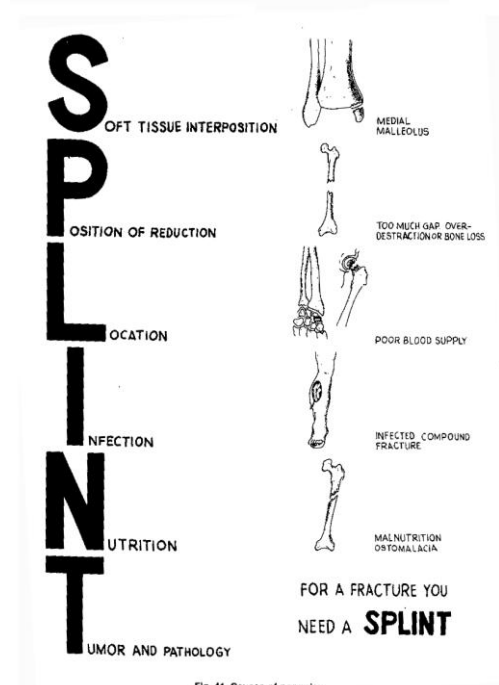


Fig. 41 Causes of nonunion

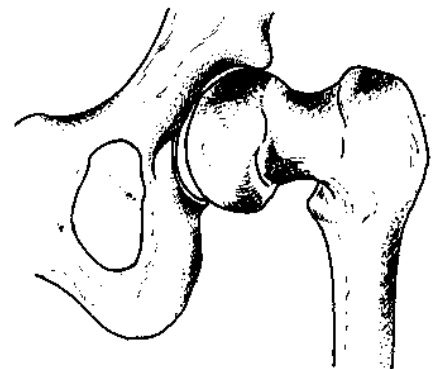


Fig. 43 Malunited fracture

☒ Avascular Necrosis:-

- Death of Bone from; Impairment or Loss of blood Supply.
- In X-ray , it appears as sclerosing area ((bad sign ,mean dead bone))
- The most common sites are☺:
 - ✓ Scaphoid bone
 - ✓ Neck of the femur
 - ✓ Talus
 - ✓ Anatomical snuff box.

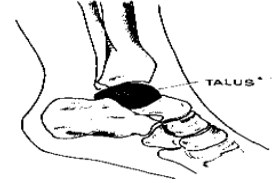
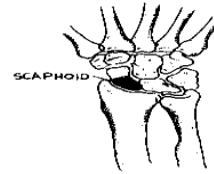
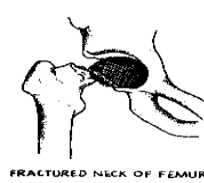


Fig. 44 Common sites of avascular necrosis

☒ Myositis Ossificans:-

- “Not myo! or itis! “
 - Heterotopic Ossification
 - May follow minor trauma
 - Susceptibility
 - Elbow ; Knee; Hip
 - Reflex Sympathetic Dystrophy
-
- Pain & Limitation of movement
 - X-Ray Calcification then Ossification
 - After severe Head Injuries
 - Prevention : Avoid Passive Massage
 - Rest Susceptible site after injury
 - May Need Excision When Mature
 - There is Primary Congenital Form !
 - “Myositis Ossificans Progressiva”

☒ Reflex sympathetic dystrophy

(**Note:** when there is sympathetic nerve damage due to prolonged immobilization (e.g. cast).
Most common in elderly patient. It's look like patches of osteopenia in x-ray)

- “Sudeck’s Acute Bone Atrophy”
 - Commonest Hand and foot # Arm or Leg☺☺!
 - Cause iatrogenic.
- ✓ Diagnosis:
- History : Pain, Swelling, Restriction Movement
 - Examination : Skin :Glossy, Smooth, Stretched with increase in local temperature (due to increase blood flow in the limb)
 - X-rays: show osteoporosis.
- ✓ Treatment :
- Physiotherapy
 - Sympathetic Block
 - ✓ Medical : Drugs,
 - ✓ Surgical: Regional Block Sympathectomy

☒ Compartment Syndrome :

- Elevation of the interstitial pressure in a closed osseofascial compartment that results in microvascular compromise.
 - Normally the interstitial pressure = 0mm/Hg until 20-25 mm/Hg is acceptable.
- ✓ The most common causes of acute compartment syndrome are:
1. fractures,(even open fracture)
 2. soft tissue trauma,
 3. arterial injury,
 4. limb compression during altered consciousness,
 5. Burns.
 6. Other causes include intravenous fluid extravasation and anticoagulants

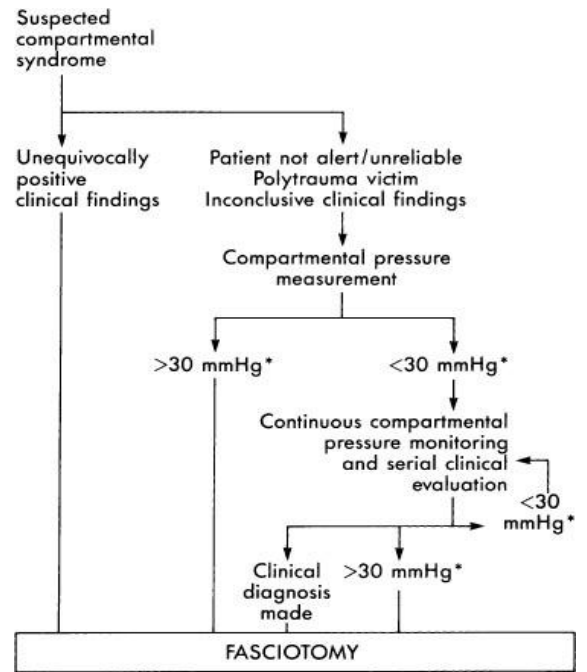
✓ Diagnosis:

- ◆ Symptom: 5 P's → **فوق العاده – اكثر من pain** **الكسر العادي**, pulseless, parasthysia, paralysis, pallor.

- ◆ Level of leg as the level of heart for 20 minutes , if the pain goes that good ,if not →measure the pressure if high →do fasciotomy

✓ Treatment:

- Fasciotomy. N.B. Do not give narcotic.



Mosby, Inc. items and derived items
copyright © 2003, Mosby, Inc. All rights reserved.