

Sport & Soft tissues injuries

❖ Soft tissues injuries:

- Muscle, Tendon, Ligament, Meniscus
- Knee, Shoulder, Ankle

❖ 1- Muscle injury:

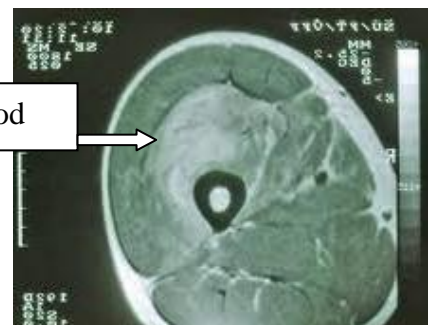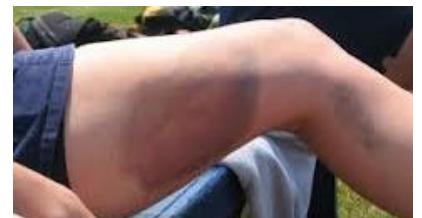- The muscles most at risk are those in which the origin and the insertion **cross two joints**. e.g. (Gastrocnemius, Quadriceps and Hamstring muscles). → **myotendinous junction**
- Frequently injured muscles act in an **eccentric fashion** (i.e., lengthening as they contract). → **ex Quadriceps during walking**
- Frequently injured muscles have a relatively high percentage of **type II (fast-twitch) fibers**.

▪ **A- Muscle Strain** تمزق :

- The most common muscle injury suffered in sports.
- Immediate pain associated with diminished function.
- Both complete and incomplete muscle tears can occur by passive stretch of an activated muscle. → **during movement or walking**
- Muscle tears also typically occur at or near to the myotendinous junction
- It can be partial or complete. Usually presents with immediate pain.
- Treatment:
 - RICE (Rest, Ice, Compression and Elevation) → **Initial therapy FOR ANY sport related injury – MCQ -**
 - NSAID
 - physical therapy

▪ **b- Muscle Contusion:**

- Caused by anon-penetrating blunt injury (direct blow) to the muscle resulting in hematoma and inflammation.
- **Quadriceps** and **Brachialis** muscles are common involved regions.
- Clinical features:
 - Pain with active and passive motion +/- swelling.
 - Decreased range of motion of joints spanned by the injured muscles.
 - Occasionally a permanent palpable mass. → **due to bleeding – NB : this mass may confused with tumors if the pt, come late**
 - Redness and hotness
- Mild forms take a few days to resolve conservatively.
- MRI shows bleeding inside the muscles.
- Treatment:
 - **Short period** of immobilization
 - Followed by early mobilization and Physiotherapy
 - NSAID



▪ **C- Muscle Laceration:**

- I&D followed by suture repair of the fascia, if possible (debridement of debris).

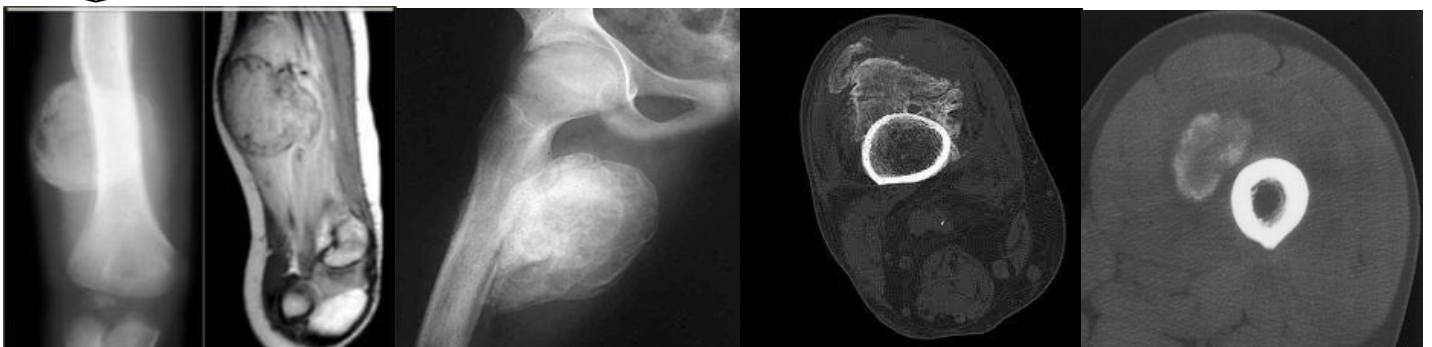▪ **D- Delayed-onset soreness:**

- Structural muscle injury leads to progressive edema formation and resultant increased intramuscular pressure.
- Is primarily associated with eccentric loading–type exercise.
- The pain and stiffness felt in muscles several hours or days after strenuous exercise. Soreness is usually found 24-72 hours after exercise.
- Clinical features: muscular pain that occurs 1-3 days after vigorous exercise.
- Treatment :
 - Will resolve in a few days
 - NSAID

▪ **Complications of Muscle Injuries:**

- **Scar formation and muscle weakness.** → (scar leads to defect of the function)
- **Compartment syndrome:**
 - At the level of the muscle fibers, capillary bleeding and edema can lead to hematoma formation and can cause compartment syndrome in areas in which the volume is limited by the fascial envelope.
 - Patient with **Bleeding disorders** is at high risk
- **Myositis ossificans:**
 - Bone formation within muscle (outside the skeleton) secondary to blunt trauma (**muscle contusion**) .
 - CF:
 - ♦ Early:
 - ♦ Pain, swelling and decreased ROM
 - ♦ Erythema, warmth, induration, tenderness,
 - ♦ Late: painless swelling with decreased ROM
 - This sometimes mimics **osteogenic sarcoma** on radiographs and biopsy . مهمه
 - Increased ESR and serum alkaline phosphatase
 - Myositis ossificans becomes apparent approximately 2 to 4 weeks post-injury
 - Treatment is excision of ossifications when mature.
 - **ALL pics show : Myositis ossificans**

Humoros



❖ Overuse Tendon injuries:

- Function—to transfer force from muscle to bone to produce joint motion.
 - Type of injuries:
 - Overuse tendinopathies
 - Tendon rupture
 - **Overuse Tendinopathy (degeneration) : → present as pain with movement of the involved tendon**
 - **Osteotendinous junction** is the most common site of overuse tendon injury.
 - Tendons are relatively hypo vascular proximal to the tendon insertion. This hypovascularity may predispose the tendon to hypoxic tendon degeneration and has been implicated in the etiology of tendinopathies.
 - Tendinopathy not tendinitis (degeneration and not inflammation)
- NB : start early in athletes But in normal people it start after 40

Most Common Diagnoses and Locations of Chronic Tendinopathies

Diagnosis	Location
▪ Rotator cuff : في الكتف Tendinopathy (supraspinose is mostly affected)	▪ Supraspinatus tendon insertion
▪ Lateral epicondylitis (tennis elbow) → due to overuse of the wrist extension)	▪ Common wrist extensor tendon origin (mainly involved ECRB)
▪ Medial epicondylitis (“golfer’s elbow”) → usually proximal	▪ Common wrist flexor tendon origin (when making a golf swing this tendon is stressed)
▪ Hamstring Tendinopathy	▪ Hamstring tendon origin
▪ Quadriceps Tendinopathy	▪ Quadriceps tendon insertion
▪ Patellar Tendinopathy (jumpers knee)	▪ Patellar tendon origin
▪ De Quervain’s disease	▪ Sheath/pulley of abductor pollicis longus
▪ Achilles Tendinopathy في الناس اللي يجرون او يركضون	▪ Sheath, midsubstance, or calcaneal insertion

- **Overuse Tendinopathies treatment:**

- Goal: reduce pain and return function.
- Mainly is conservative Rx مهمه – سؤال
 - ♦ Rest
 - ♦ Ice (Cryotherapy)
 - ♦ PT (stretching and eccentric strengthening)
 - ♦ Analgesics
 - ♦ Corticosteroids injection
 - ♦ Orthotics and braces → **symptomatic treatment**
 - ♦ Other modalities: U/S, ESWT, iontophoresis and phonophoresis.

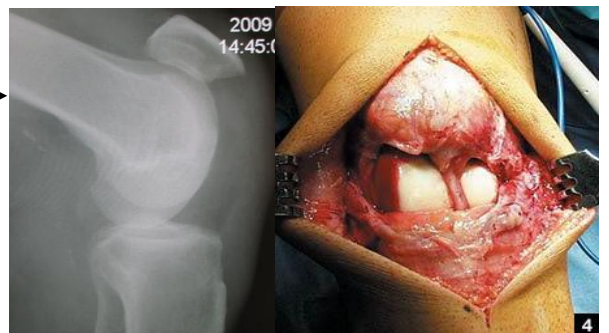
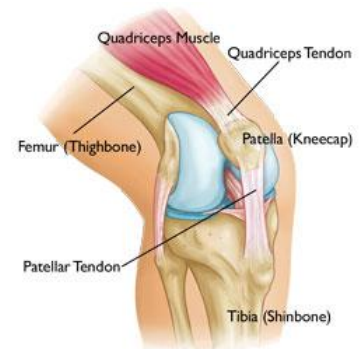
- Surgical treatment:
 - ♦ Failed conservative treatment (at least 3-6 months)
- Excision of abnormal tendon tissue and performance of longitudinal tenotomies to release areas of scarring and fibrosis.

▪ Tendon rupture:

- Knee extensor mechanism
 - Quadriceps tendon
 - Patella tendon
- Achilles tendon
- Partial vs. complete

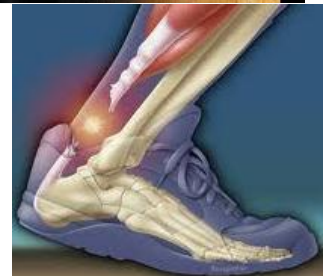- Patella/Quadriceps tendon rupture:

- Predisposing factors:
 - ♦ **Steroid**, chronic disease, and tendinopathy → so
Always inject around the tendon not into it
- Age: Patella < 40 - > 40 Quads - MCQ
- Location: at the tendon attachment to the patella.
- Physical examination:
 - ♦ Tenderness at the site of the injury, hematoma and a palpable defect (GAP) in the tendon.
 - ♦ Unable to extend the knee against resistance or to perform a straight-leg raise (Decrease Range of motion of active extension) مهم
 - ♦ How to differentiate : GAP : distal in patella – proximal in Quadriceps
- X-ray
 - ♦ Patella-alta > ترقى فوق P.T rupture →
 - ♦ Patella-infra > تنزل Q.T rupture
- Rx: usually surgical



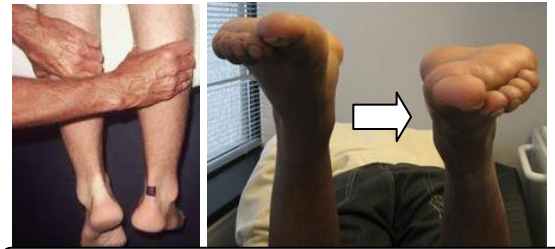- Achilles tendon rupture:

- **Most ruptures (75%) occur during sporting activities .**
- Usually due to eccentric load, rupture occurs while performing actions requiring acceleration e.g. jumping, pushing off
- Injury happens during dorsiflexion (**MOST COMMON**) – because it contracted and length - or plantar flexion of foot.
- History:
 - ♦ The patient reports a “pop” or the sensation of being kicked in the heel during the injury.
 - ♦ Weakness and difficulty walking.
-



Group A1

- Examination:
 - ♦ Increased resting dorsiflexion with the knees flexed, a palpable gap, weak plantar flexion, and an abnormal Thompson test (lack of plantar flexion when squeezing the calf)
 - ♦ Thompson test positive → **loss of push up during walking – Show GAP**
- Diagnosis is clinical, but MRI or ultrasound can confirm.
- Rx: usually surgically مهمه



Thompson tes

L is the affected limb

❖ **Knee:**



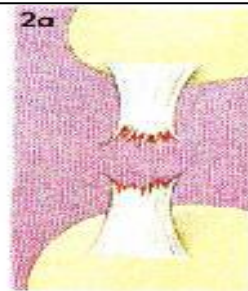

- Mid-substance tear of ligaments usually occur in adults.
- Proximal
- Avulsion
- Ligament intact
- Usually occurs in pediatric age group in the tibia, because ligament is stronger than bone.

Classification : التصنيف مهم

Complete distal

complete proximal

Com. Avulsion



Examples of different types of partial and total ligament ruptures. See the section 'Types of injury' opposite

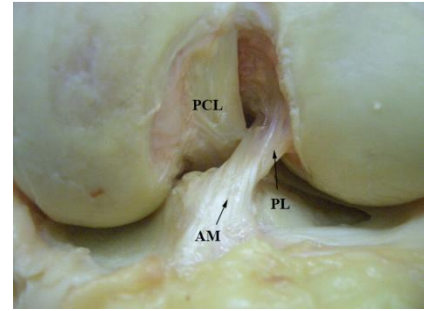
INComplete distal

INcomplete proximal

income Avulsion

❖ **Anterior Cruciate Ligament Injury:**➤ **Anatomy:**

- Originates from notch of the distal femur, proximal fibers travel to the medial wall of the lateral epicondyle. Needed when you change direction immediately or performing rough movements.

➤ **Mechanism of Injury:**

- Noncontact, most common causes (70%) مهمه
- Cutting or Pivoting → **zigzag movement like in Soccer or basketball**
- Contact = MCL (**NB : contact may associated with meniscus injury – MCQ**)
- Sports-Related (80%) , soccer is the commonest sport to cause this accident
- Patient hears a “POP” sound (70%). صوت طقه
- Female: 2-4x > Male

➤ **Symptoms:**

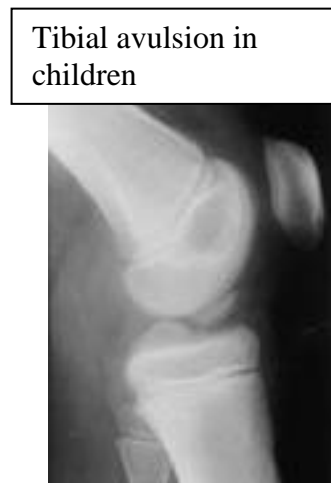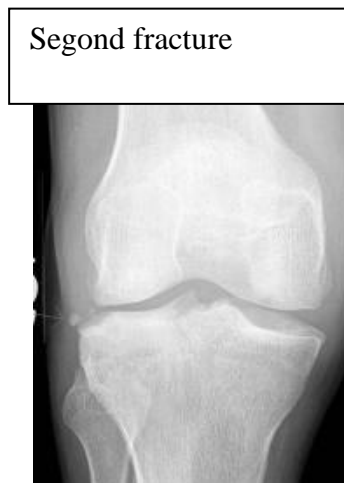- Instability “giving way episodes” – تخوني رجلي
- Swelling (Hemarthrosis) is noted within a 1-2 days of the injury.
- Pain if associated with meniscus tear (moderate to severe)
NB : pt show no problem walking on flat area , it appear if he walks in Zigzag pattern or go down the stairs

➤ **Physical examination:**

- The patient needs to be relaxed and comfortable.
- Must be compared with those of the normal knee.
- A moderate to severe effusion is usually present
- ROM: in acute injury the range of motion may limited by:
 - Pain
 - Effusion
 - Hamstring spasm,
 - ACL stump impingement,
 - Meniscal pathology.
- Special tests:
 - Lachman’s test
 - ADT (Anterior drawer test)
 - Pivot shift test: ispathognomonic for ACL injury (best in the chronic setting)

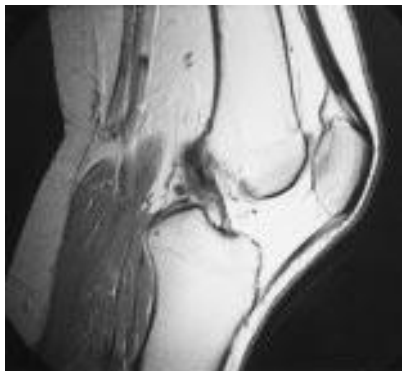
Diagnosis : Mainly clinical➤ **Investigations: → order them if you suspect associated injuries Ex, meniscus**

- **X-ray**, is done to rule out bone, joint fracture, or avulsion injury.
 - Rule out:
 - ♦ Second fracture: fracture of the lateral tibial condyle, usually result of abnormal varus (bowing). Associated with ligamentous and meniscal injury.
 - ♦ Tibial avulsion in children. (wedge shaped)
 - ♦ Treatment of avulsion: if reduced when closed, put a cast. If not reducible, treat surgically.

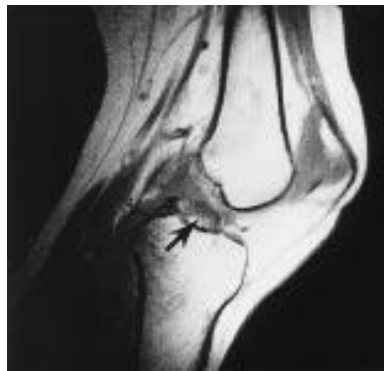

- **MRI**, only performed in acute injury, shows:
 - Bone contusion
 - Posterior part of tibia hits the femur, called kissing lesion.
 - Usually not needed

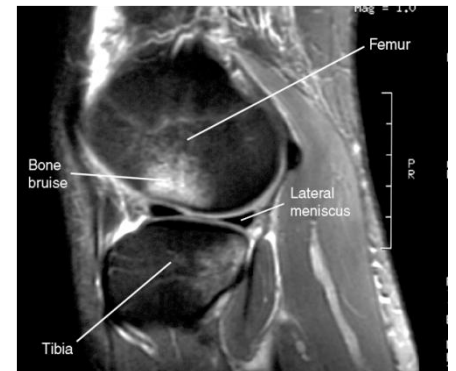
NORMAL



Ruptured ACL



Bone bruise



- In the skeletally mature patient, the femoral insertion or midsubstance is usually the site of disruption .
- In the skeletally immature patient, the tibial attachment may be avulsed with or without a piece of bone.
- **NB : in children it usually show Avulsion → the ligament is intact**

➤ **Injuries associated with ACL disruption:**

- Injuries of the ACL rarely occur in isolation. The effects of other injuries, including:
 - Other ligament sprains (MCL)
 - Meniscal tears
 - Articular cartilage injuries
 - Bone bruises ,
- Complicate the treatment and eventual outcomes of ACL disruptions.
- Long term complication with meniscal damage result in Osteoarthritis. مفاصل

Group A1

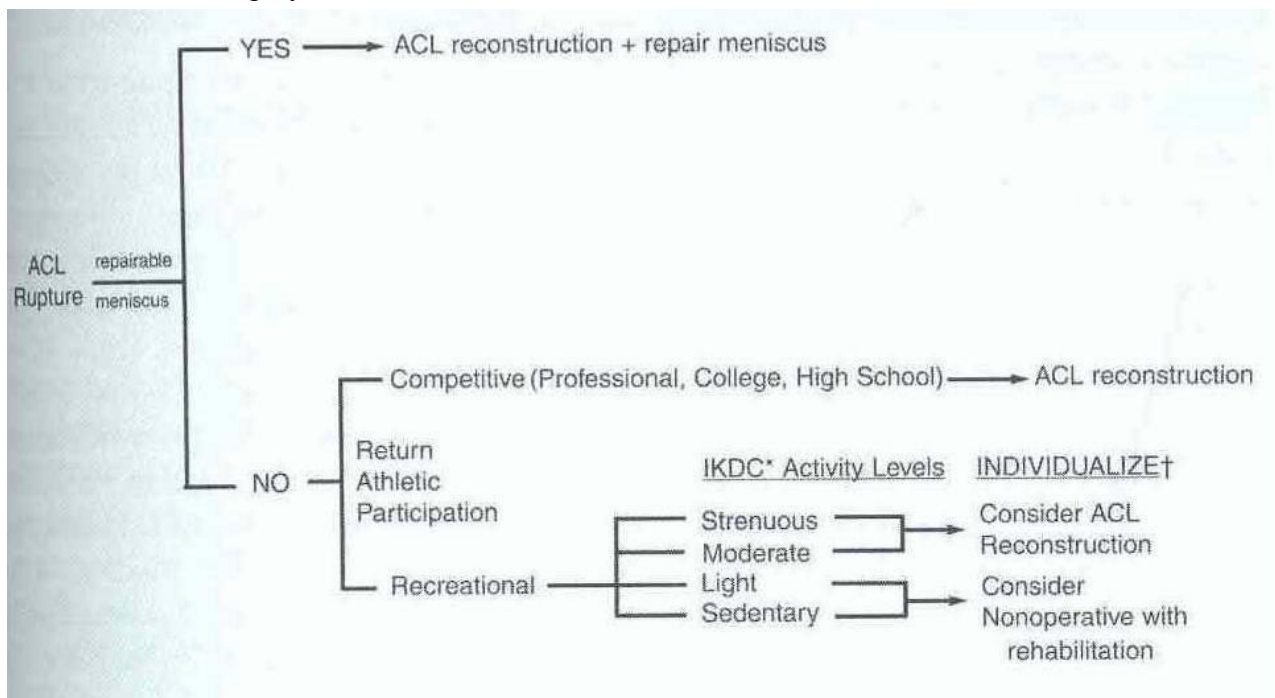
- **Treatment: → depend on 4 factors : 1- Function (instability) 2- profession (job)**
 ➤ **3- Age 4- activity**

• Nonsurgical treatment:

- Appropriate for asymptomatic patients with partial injuries to the ACL.
- Patients who are older or less physically active may elect to modify their activities and proceed with nonsurgical treatment. If nonsurgical treatment fails or knee instability persists, surgery can be performed.
- Nonsurgical treatment involves rehabilitation to strengthen hamstrings and quadriceps, as well as proprioceptive training.
- Activity modification is also an important part of nonsurgical management, as patients who avoid cutting and pivoting sports are at lower risk for knee instability.
- ACL sports braces are available as well. However, they have not been shown to prevent abnormal anterior tibial translation. Functional braces and simple knee sleeves improve proprioception, which may give patients a sense of improved knee function and stability.

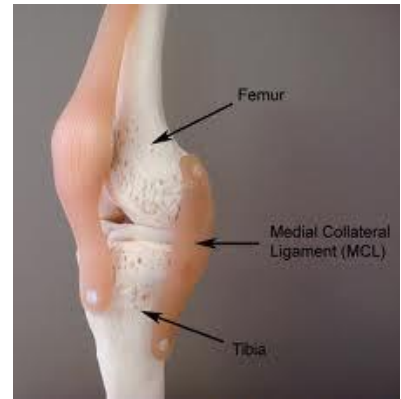• Surgical: → In **athletes – young – loss of function**

- Athletes with ACL injuries rarely return to cutting and pivoting sports, such as basketball, football, soccer, squash, and handball, without first undergoing surgery. For individuals who wish to return to such sports, surgery is generally recommended to avoid instability and secondary meniscal and/or articular cartilage damage.
- Individuals who work in occupations that may involve physical combat, such as police officers, or risk, such as firefighters, should have ACL reconstruction before returning to work.
- Most patients can function well and perform activities of daily living (ADLs) (without instability after a complete ACL injury. However, some have difficulty performing even simple ADLs because of ACL deficiency-related instability, and they may require surgery.



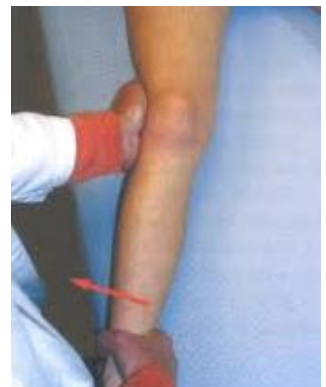❖ **Medial collateral ligament injury → mainly in contact injuries**

- The main function of MCL is to resist valgus and external rotation loads.
- The **Tibial MCL is the most commonly injured** ligament of the knee. The true incidence may be underestimated due to a lack of reporting for lesser grades of injury.
- Concomitant ligamentous injuries (95% are ACL) occur in:
 - 20% of grade I: sprain: mild, no instability clinically, only associated with tenderness.
 - 52% of grade II: partial: tenderness and gapping on the medial knee, partial tear of the ligament
 - 78% of grade III: complete ligamentous tear. Associated with ACL injury
- Concurrent meniscal injuries have been noted in up to 5% of isolated medial ligamentous injuries.
- Usually result from contact injury like a direct blow to the lateral aspect of the knee.
- Can be partial or complete



➤ **Physical examination:**

- Valgus stress test should be performed with the knee at 0° and 30° of flexion (*The leg extended and the examiner's hand on the knee, and abducting the leg with the other hand. An attempt is then made to force the leg at the knee into valgus.*).
 - Laxity at 30°: isolated MCL
 - Laxity at both 0° and 30°: concurrent injury to the posteromedial capsule and/or cruciate ligaments.
- Rule out associated injuries (ACL and M. Meniscus)



➤ **Investigation**

- Is a clinical diagnosis and most of the time does not need further investigation.
- If the injury is severe or suspecting associated injuries (e.g. significant knee effusion) then the **MRI** will be modality of choice.
- X-ray: to rule out fracture (lateral tibia plateau fracture)

➤ **Treatment:**

- Conservative Rx (**mainly – MCQ**)
- Is the mainstay of treatment for the isolated MCL injuries
- Indications:
 - All isolated grade I and II injuries
 - Grade III injuries that are stable in extension without associated cruciate injury
- Crutches, ice, compression, elevation, and anti-inflammatory/pain medication
- No brace is usually required for grade I injuries; crutches can be used as necessary. A knee immobilizer (comfort) or hinged brace (for walking) is recommended for grade II and grade III injuries.

Group A1

- Timing of return to sports is directly related to the degree of injury: Grade I injuries, 5 to 7 days; grade II injuries, 2 to 4 weeks; grade III injuries, 4 to 8 weeks.

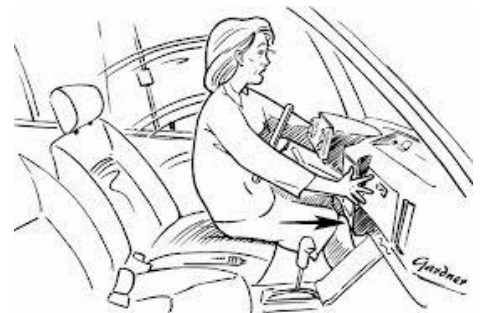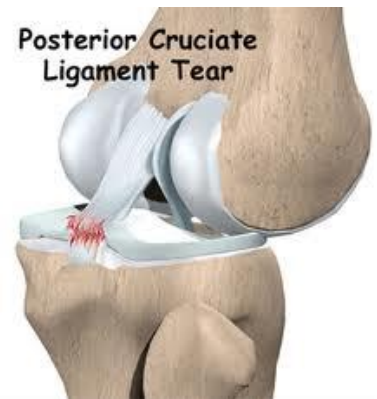- Surgical Rx: if failed Rx+ grade III+ associated with other ligaments injury

❖ **Lateral collateral Ligament injury:** قراءه فقط

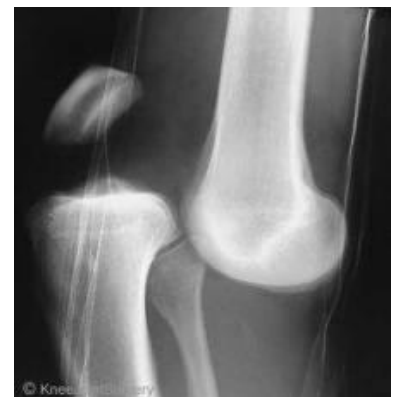- The LCL is the primary restraint to varus stress at 5° and 25° of knee flexion.
- Less commonly injured than MCL
- Injuries to the lateral ligament of the knee most frequently result from motor vehicle accidents and athletic injuries.
- Rx:
 - Isolated injury: non operative
 - Combined injury: surgical

❖ **Posterior cruciate Ligament injury:**

- The PCL is the primary restraint to posterior tibial translation in the intact knee.
- Mechanism of injury:
 - A direct blow to the proximal aspect of the tibia is the most common cause of PCL injury.
 - Dashboard injury مهمه
 - In athletes > fall onto the flexed knee with the foot in plantar flexion, which places a posterior force on the tibia and leads to rupture of the PCL.
- PCL insufficiency significantly increased the risk of developing medial femoral condyle and patellar cartilage degeneration over time.
- Rx
 - Non operative
 - Surgical if combined ligament injury

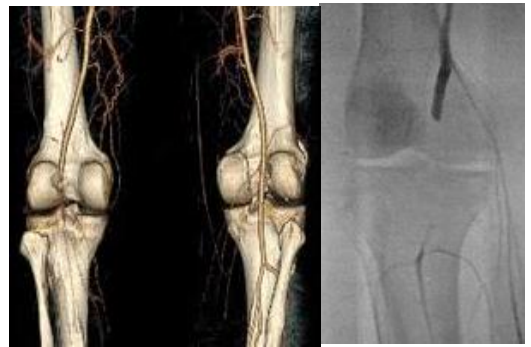❖ **Knee dislocation "Multiligament Knee Injuries":**

- Multiligament knee injuries are usually caused by high-energy trauma and are often considered knee dislocations.
- Less frequently, low-energy trauma or ultra-low-velocity trauma in obese patients can also result in this injury pattern.
- A bicruciate (ACL+PCL) injury or a multiligament knee injury involving three or more ligaments should be considered a spontaneously reduced knee dislocation.
- Knee dislocation should be considered a limb-threatening injury, and careful monitoring of vascular status after the injury is imperative. مهمه

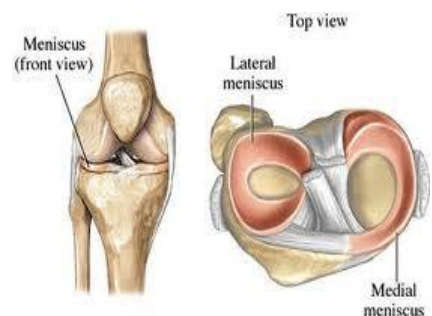


Group A1

- Popliteal artery (estimated at 32%) or peroneal nerve injury (20% to 40%) also can occur. مهمه
 - ➔ So always do ABI ➔ normally < 0.9 ➔ if abnormal do Angiogram ➔ Do immediate reduction
- Describe distal part in relation to the proximal part
- Vascular examination:
 - Critical in an acutely dislocated knee.
 - Pulse and ankle-brachial index (ABI) should be carefully assessed. An ABI of less than 0.90, and most certainly less than 0.80, should be considered abnormal.
 - If there is any concern about an abnormal vascular examination, there should be allowing threshold for ordering an angiogram.
 - If pulses are still abnormal or absent following reduction of the dislocation ‘immediate vascular surgery consultation with intraoperative exploration should be the next step in management.
 - Avascular injury in a knee dislocation is a limb-threatening injury and needs to be corrected within 6 to 8 hours. If not corrected, amputation may be required.
- Neurologic examination: is also critical, as peroneal nerve injury can occur with multiligament injuries, particularly in concomitant lateral/posterolateral corner injuries.
- Management: **Emergent Closed Reduction** and splinting or bracing should be performed immediately .Post-reduction radiographs should be taken to confirm knee reduction and don't forget to do neurovascular assessment before and after reduction (IMP)

❖ **Meniscus: (very common)**

- Anatomy:
 - The menisci are crescent-shaped, with a triangular appearance on cross-section.
 - The lateral meniscus covers 84% of the condyle surface; it is 12 to 13 mm wide and 3 to 5 mm thick.
 - The medial meniscus is wider in diameter than the lateral meniscus; it covers 64% of the condyle surface and is 10 mm wide and 3 to 5 mm thick and it is injured more than the lateral meniscus.
- Meniscus function
 - The meniscus provides stability, absorbs shock, increases articular congruity, aids in lubrication, prevents synovial impingement, and limits flexion/extension extremes.
 - The most important function of the meniscus is load-sharing across the knee joint ‘which it accomplishes by increasing contact area and decreasing contact stress
 - NB : if you remove the meniscus 100% will get early Osteoarthritis



❖ **Meniscus tear:**

➤ Epidemiology of meniscus injuries:

- Meniscus injuries are among the most common injuries seen in orthopedics practices.
- Arthroscopic partial meniscectomy is one of the most common orthopedics procedures.

➤ Incidence:

- Meniscus tears are unusual in patients younger than age 10 years.
- Most meniscus tears in adolescents and young adults occur with a twisting injury or with a change in direction.
- Middle-aged and older adults can sustain meniscus tears from squatting or falling.

➤ History:

- Within acute meniscus tear, an effusion may develop slowly several hours after injury. This differs from an anterior cruciate ligament (ACL) injury, where swelling develops rapidly within the first few hours.
- Patients with meniscus injuries localize pain to the joint line or posterior knee and describe mechanical symptoms of **locking** or catching. مهمه
- Locking.
- Chronic meniscus tears demonstrate intermittent effusions with mechanical symptoms

➤ Physical examination: → **mainly pain in the joint line → mainly in deflexion** وضع التشهد او البوبزه

- Small joint effusions and joint line tenderness with palpation are common findings with meniscus tears.
- Manipulative maneuvers, including the **McMurray** and **Apley tests**, may produce a palpable or audible click with localized tenderness, but they are not specific for meniscal pathology.
- Range of motion is typically normal, but longitudinal bucket-handle tears may block full extension of the knee joint.

Diagnosis : mainly clinical – Do MRI to confirm

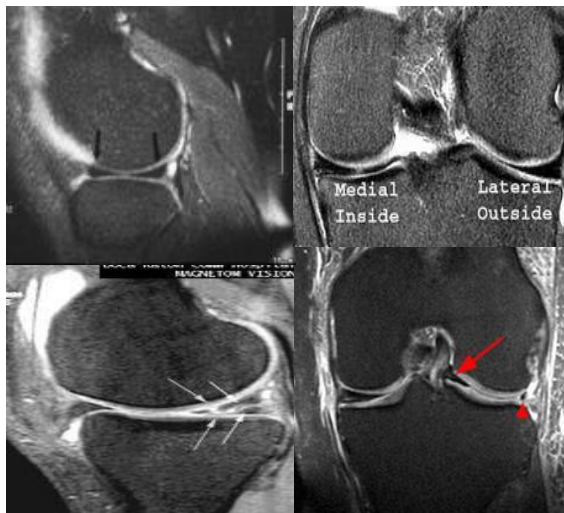➤ Investigation:

- Standard knee radiographs should be obtained for evaluating for
 - Bone injuries or abnormalities.
 - Osteoarthritis.
- **MRI** remains the noninvasive diagnostic procedure of choice for confirming meniscal pathology.



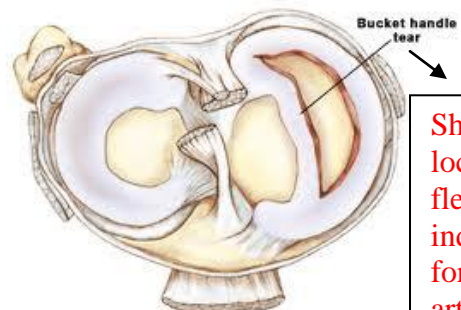
Normal

Normal

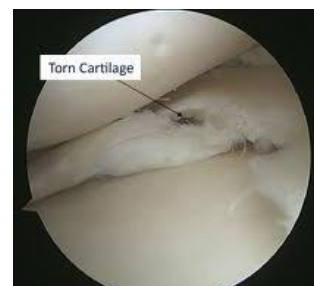

Abnormal triangle

show locked knee



Show locking in flexion → indication for urgent arthroscopy – MCQ



➤ Differential diagnosis:

- Differential diagnosis Prior to MRI, several large studies demonstrated accuracy of the clinical diagnosis of meniscus tears to be 70% to 75%.
- The differential for meniscus tears includes intra-articular and extra-articular diagnoses.
 - **Intra-articular** possibilities include osteochondritis dissecans, medial patella plica, patellofemoral pain syndromes, loose bodies, pigmented villonodular synovitis, inflammatory arthropathies, and osteonecrosis.
 - **Extra-articular** possibilities include collateral ligament injuries, slipped capital femoral epiphysis, bone or soft-tissue tumors, osteomyelitis, synovial cyst, pes or medial collateral ligament bursitis, injury, reflex sympathetic dystrophy, lumbar radiculopathy, iliotibial band friction, and stress fracture.

➤ Treatment:

- **Nonsurgical Management (mainly MCQ)**
 - Not all meniscus tears cause symptoms, and many symptomatic tears become asymptomatic.
 - Tear types that commonly may be managed nonsurgically include:
 - Stable longitudinal tears <10mm in length with <3 to 5 mm displacement
 - Degenerative tears associated with significant osteoarthritis
 - Short (<3mm in length) radial tears
 - Stable partial tears
- Nonsurgical management can include ice, non-steroidal anti-inflammatory drugs, or physical therapy for range of motion and general strengthening of the lower extremities.
- **Surgical indications:**
 - Failure of conservative treatment
 - Locked knee → if it persists do urgent Arthroscope – MCQ
 - Concomitant ACL surgery
- Type of surgical intervention:
 - Excision (Arthroscopic partial/subtotal/ or total meniscectomy)
 - Repair

❖ **Ankle sprain:**

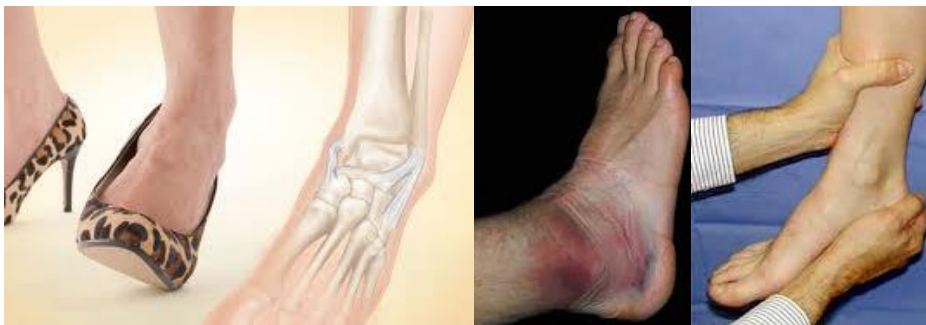- Ankle sprain is a common sports related injury.
- Lateral sprains accounting for 85% of all such injuries. → in inversion position

➤ **Classification of Acute Lateral Ankle Sprains:**

Grade	Description
I	Mild injury to the lateral ligamentous complex. No frank ligamentous disruption is present. Mild swelling, little or no ecchymosis on the lateral aspect of the ankle, and no or mild restriction of active ROM. Difficulty with full weight bearing is sometimes seen. No laxity on examination.
II	Moderate injury and partial tear to the lateral ligamentous complex. Restricted ROM with localized swelling, ecchymosis, hemorrhage, and tenderness of the anterolateral aspect of the ankle. Abnormal laxity may be mild or absent. May be indistinguishable from a grade III injury in the acute setting.
III	Complete disruption of the lateral ligamentous complex. Diffuse swelling, ecchymosis on the lateral side of the ankle and heel, and tenderness over the anterolateral capsule, LCL.

➤ **History and physical examination:**

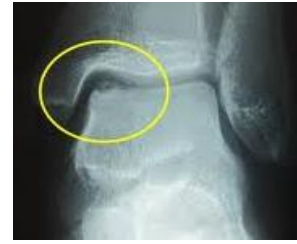- History suggestive of inversion injury
- Localized tenderness, swelling, and ecchymosis over the anterior talofibular ligament (ATFL) and/or calcaneofibular ligament (CFL)
- Examination should localize pain to the lateral ankle.
- The anterior drawer test may demonstrate anterior talar subluxation.
- Thetalar tilt stress test may demonstrate positive tilt to inversion stress.
- Sulcus sign (skin indentation) may be positive with inversion test.

➤ **Investigations:**

- X-ray ankle to rule out associated injuries (lateral process of talus, anterior process of calcaneus, and fifth metatarsal base).
- MRI and MR arthrography can show ligamentous disruption or attenuation, but they provide no distinct advantage over physical examination.
- MRI is most useful when looking for other pathology (peroneal tear, osteochondral lesions of the talus). Consider MRI if pain persists 8 weeks after ankle sprain.

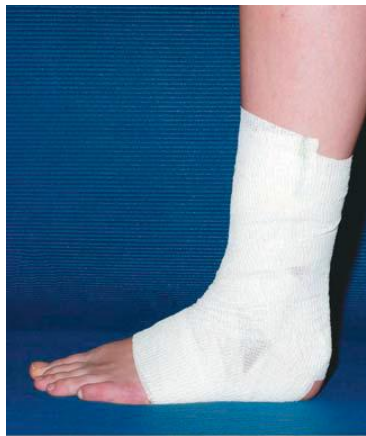➤ **Associated injuries:**

- Osteochondritis dissecans lesions (15% to 25 %)
- Loose bodies (20 %)
- Peroneal pathology (up to 25 %)

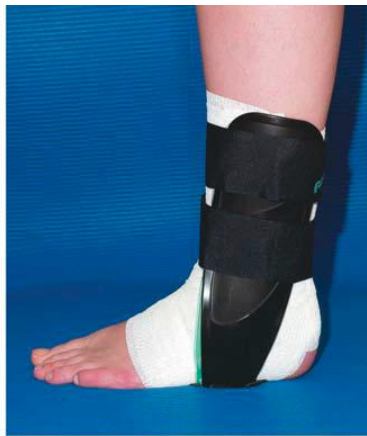

➤ **Treatment:**

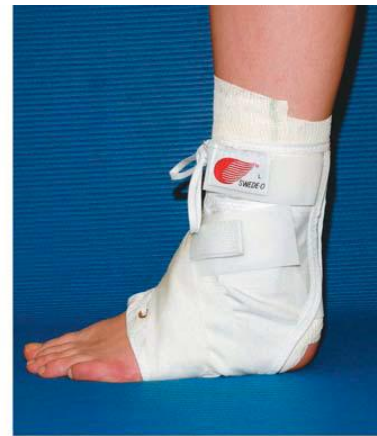- Nonsurgical
 - Initial treatment consists of rest, ice, compression, and elevation (RICE)
 - Early weight bearing and use of a protective brace during functional activities facilitates recovery better than non-weight bearing or immobilization.
 - Functional instability may result and should be treated with a course of physical therapy, emphasizing isometrics and resistive training, peroneal strengthening, range of motion, and proprioceptive training.
 - Maximizing the resistive function of the peroneal musculature can offset mechanical ligamentous instability.
 - Residual mechanical instability may be managed effectively with bracing or taping.
 - Patients may return to unrestricted activity when cutting, running, and hopping on the affected leg are no longer painful.
 - Ninety Percent of acute ankle sprains resolve with RICE and early functional rehabilitation.
- Surgical—Surgery is a reasonable option when an adequate trial of nonsurgical treatment fails to control symptoms.



A



B



C