


Common Shoulder Disorders

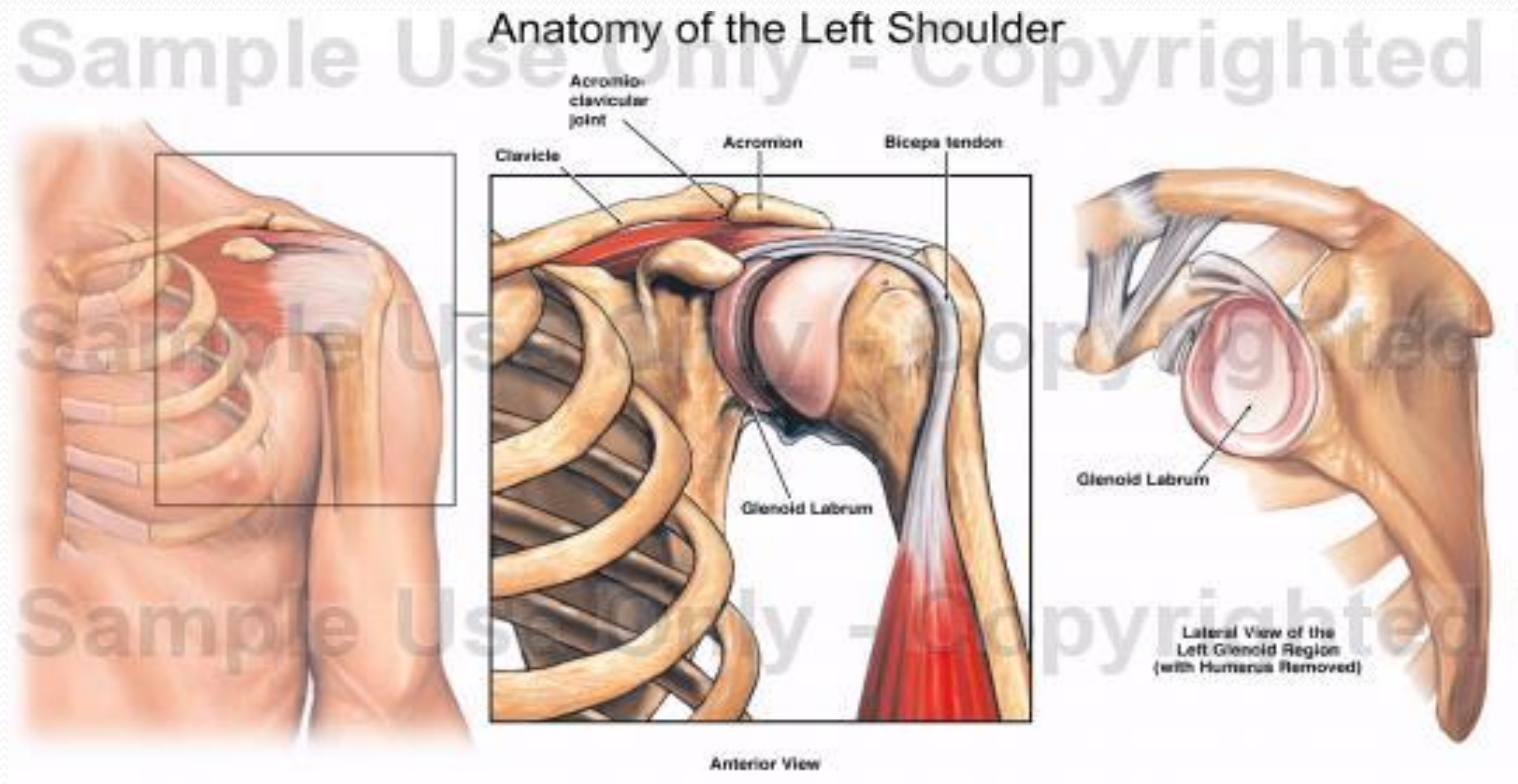
Abdulaziz Al-Ahaideb د عبدالعزيز الأحيدب

MBBS, FRCS(C)

- 
- Basic shoulder anatomy
 - Impingement syndrome
 - Rotator cuff pathology
 - Adhesive capsulitis
 - Acromioclavicular pathology
 - Recurrent shoulder dislocations

Shoulder Anatomy

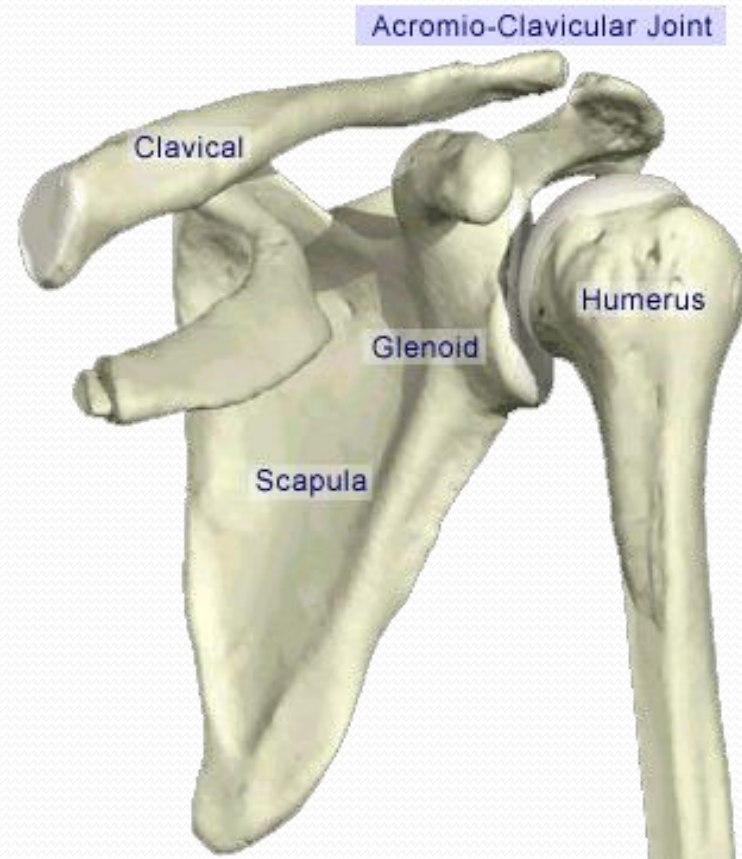- The greatest range of motion body.



Shoulder Anatomy:

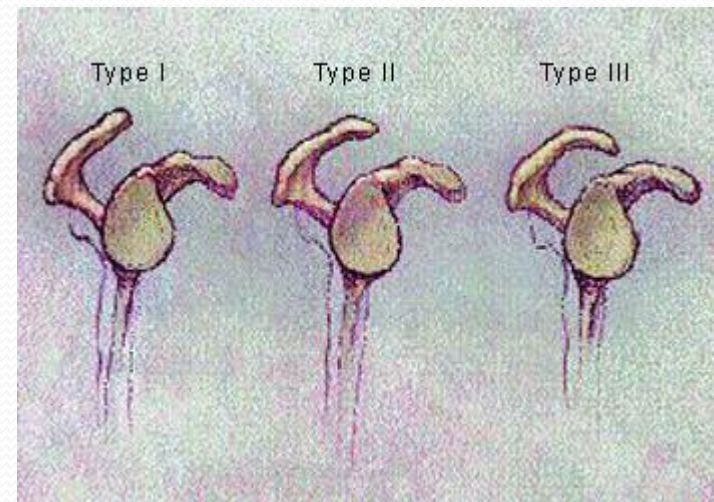
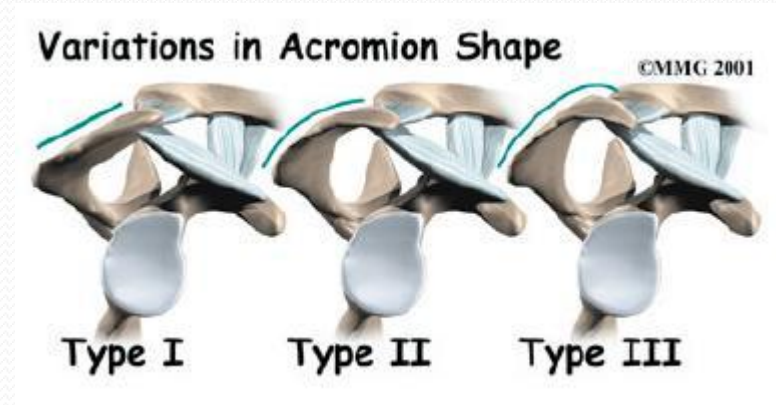
Bony Anatomy

- Humerus
- Scapula
 - Glenoid
 - Acromion
 - Coracoid
 - Scapular body
- Clavicle
- Sternum



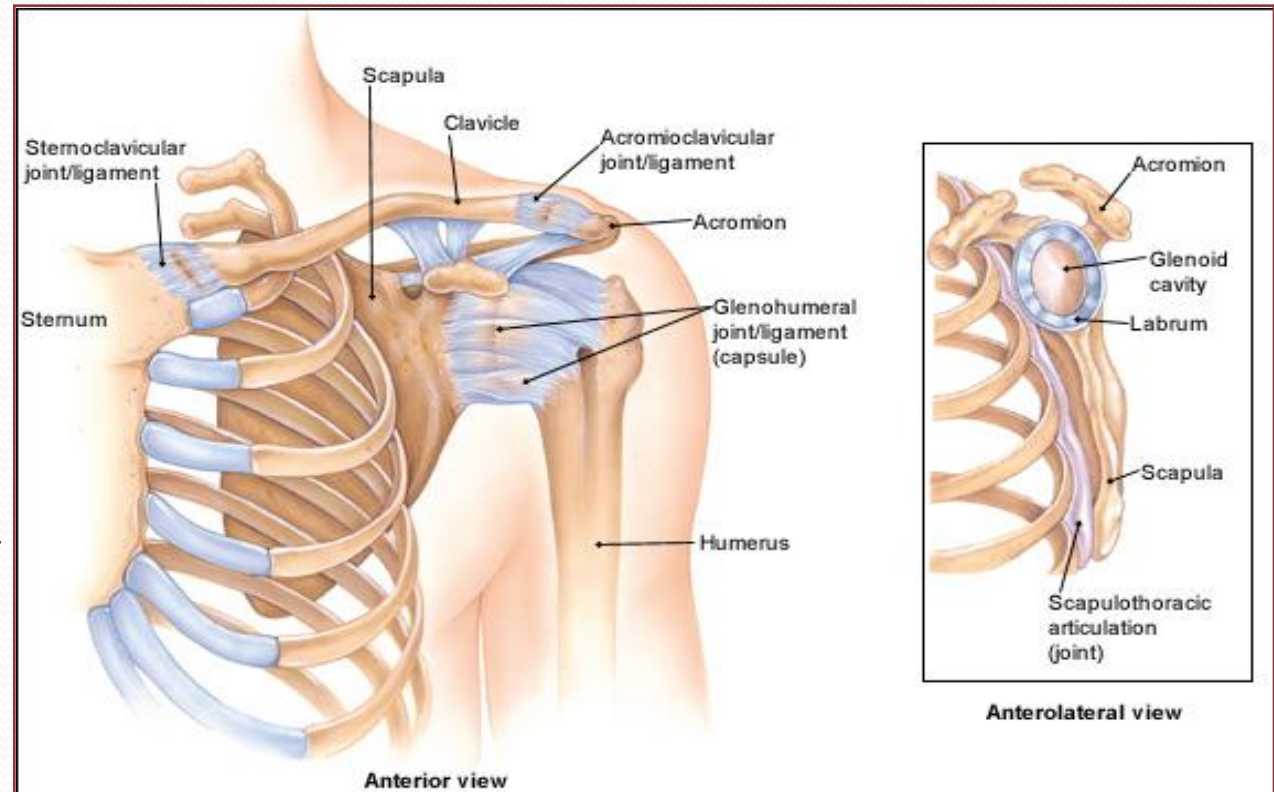
Bones

- *Humerus.*
- *Scapula (acromion):*
 - Type I : flat
 - Type II: curved
 - Type III: hooked
- *Clavicle*



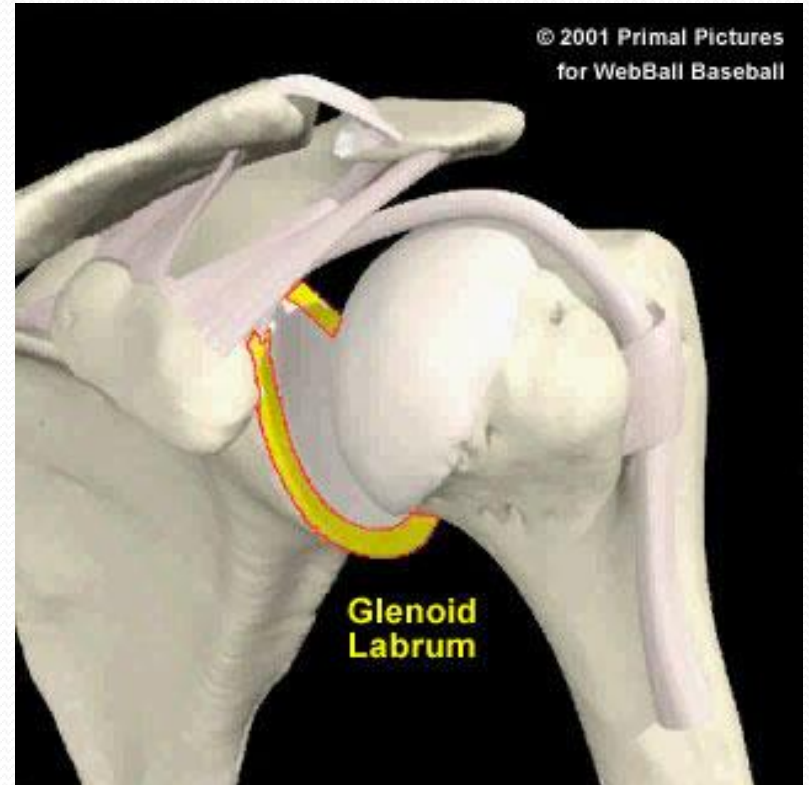
Joints

- *Glenohumeral joint: the main joint*
- *Acromioclavicular (AC) joint*
- *Sternoclavicular (SC) joint*
- *Scapulothoracic joint*



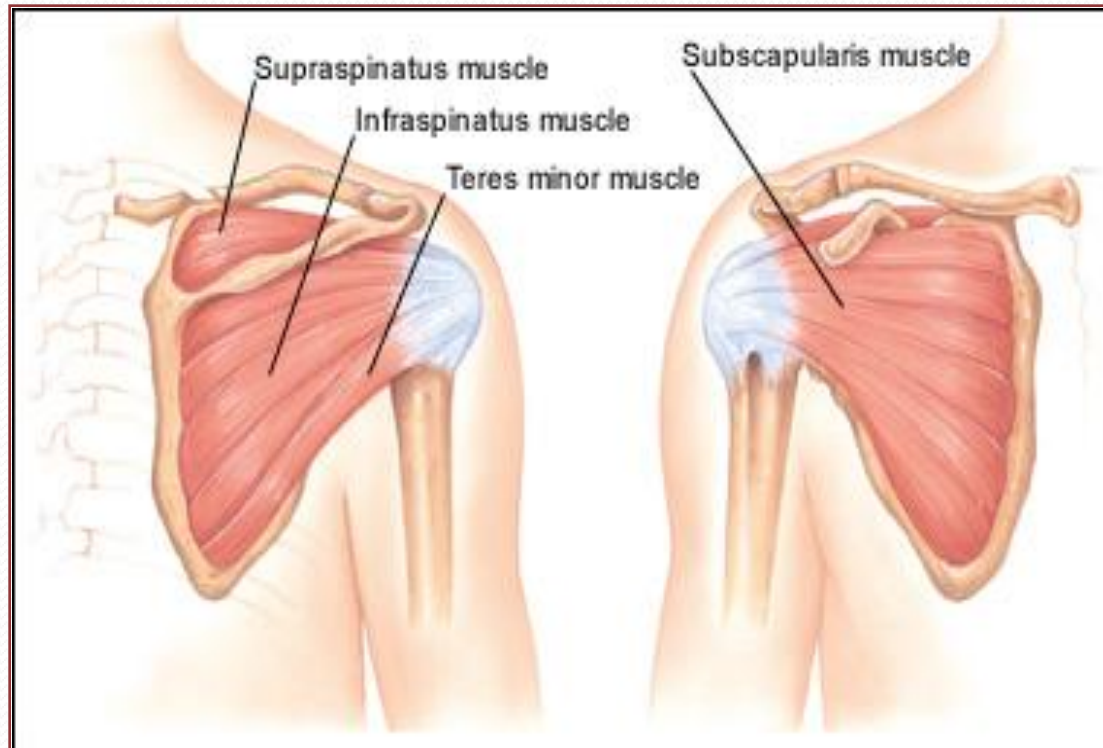
Glenohumeral Joint

- Most common dislocated joint
- Lacks bony stability
- Composed of:
 - Fibrous capsule
 - Ligaments
 - Surrounding muscles
 - Glenoid labrum



Shoulder Anatomy: Rotator Cuff Muscles

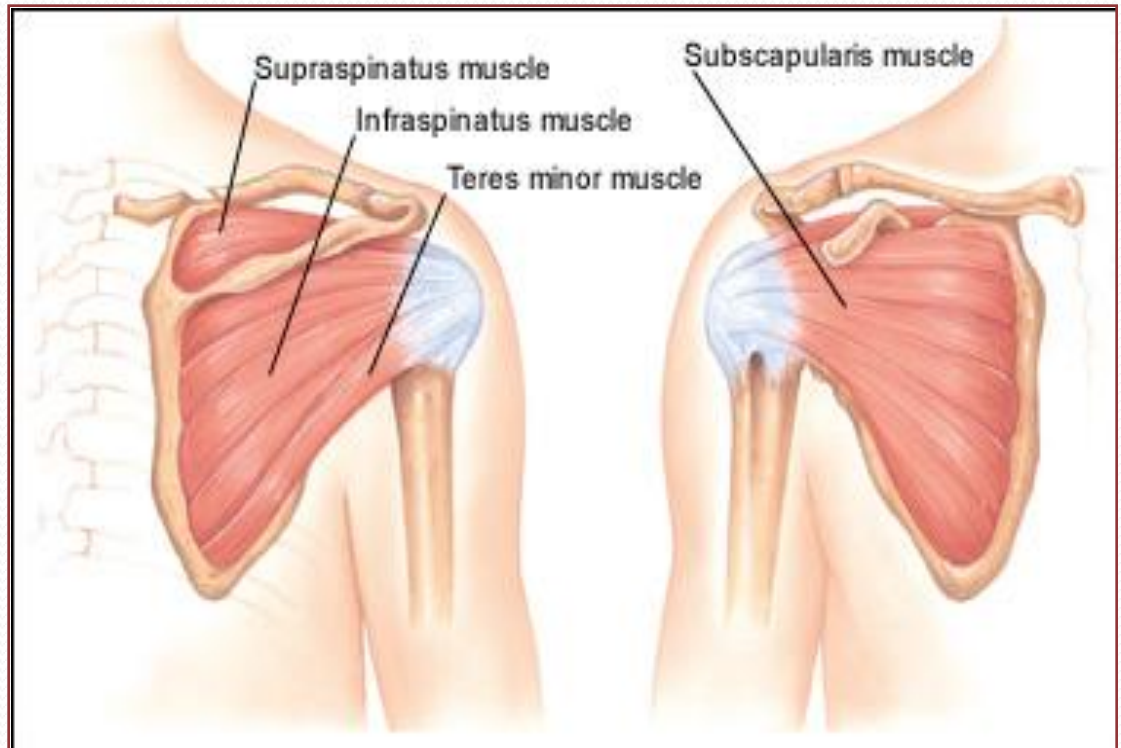
- Depress humeral head against glenoid



Shoulder anatomy:

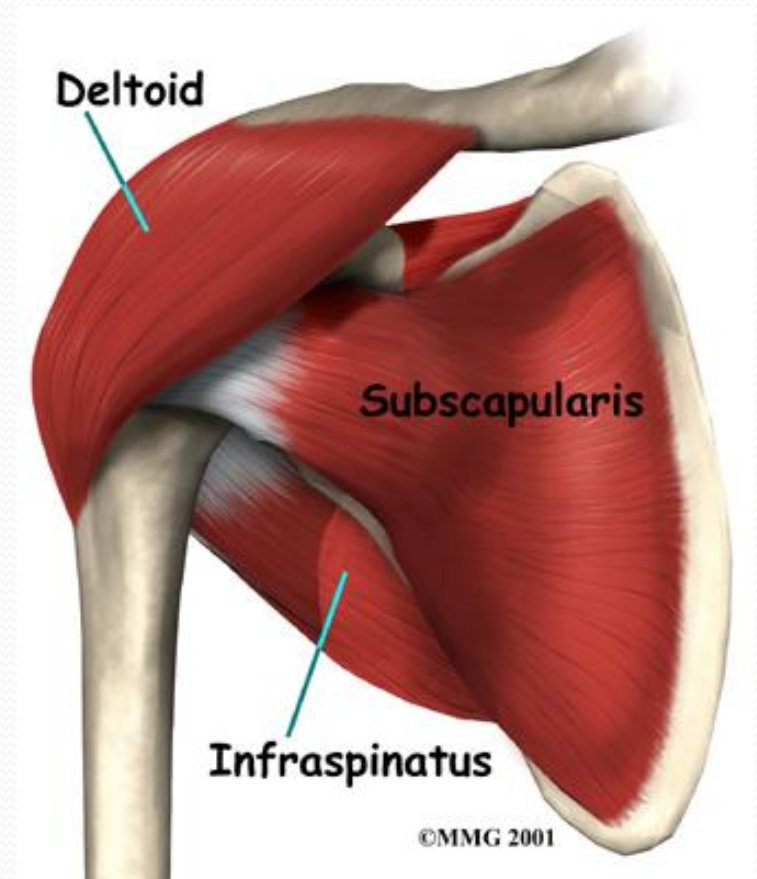
Rotator cuff muscles

- **Supraspinatus:**
 - Abduction
- **Infraspinatus:**
 - External rotation
- **Teres Minor:**
 - External rotation
- **Subscapularis:**
 - Internal rotation



Muscles

- Deltoid:
 - largest, strongest muscle of the shoulder.



Shoulder Anatomy:

Other Musculature

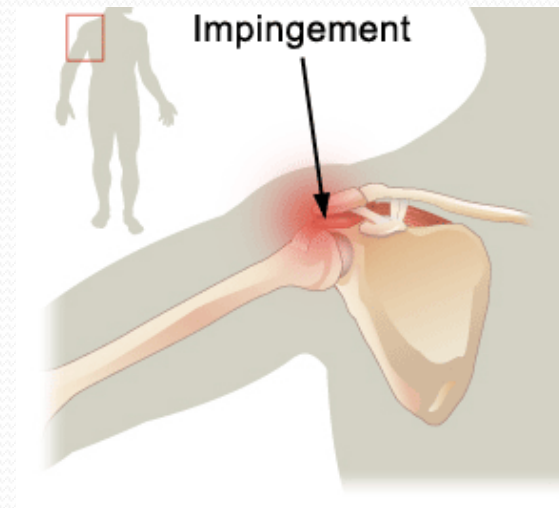
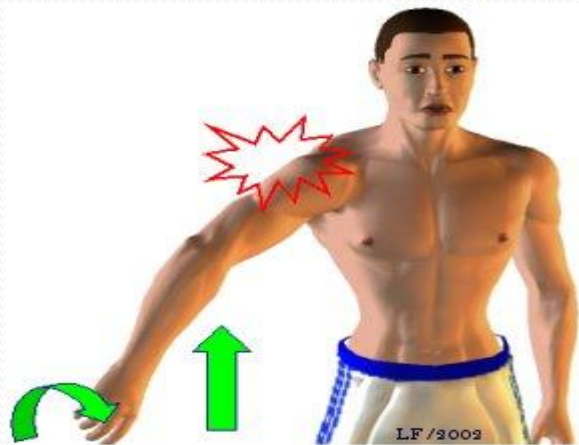
- Pectoralis major, latissimus dorsi, biceps
- Rhomboids, trapezius, levator scapulae, serratus anterior

Subacromial bursa

- *Between the acromion and the rotator cuff tendons.*
- *Protects the acromion and the rotator cuff from grinding against each other.*

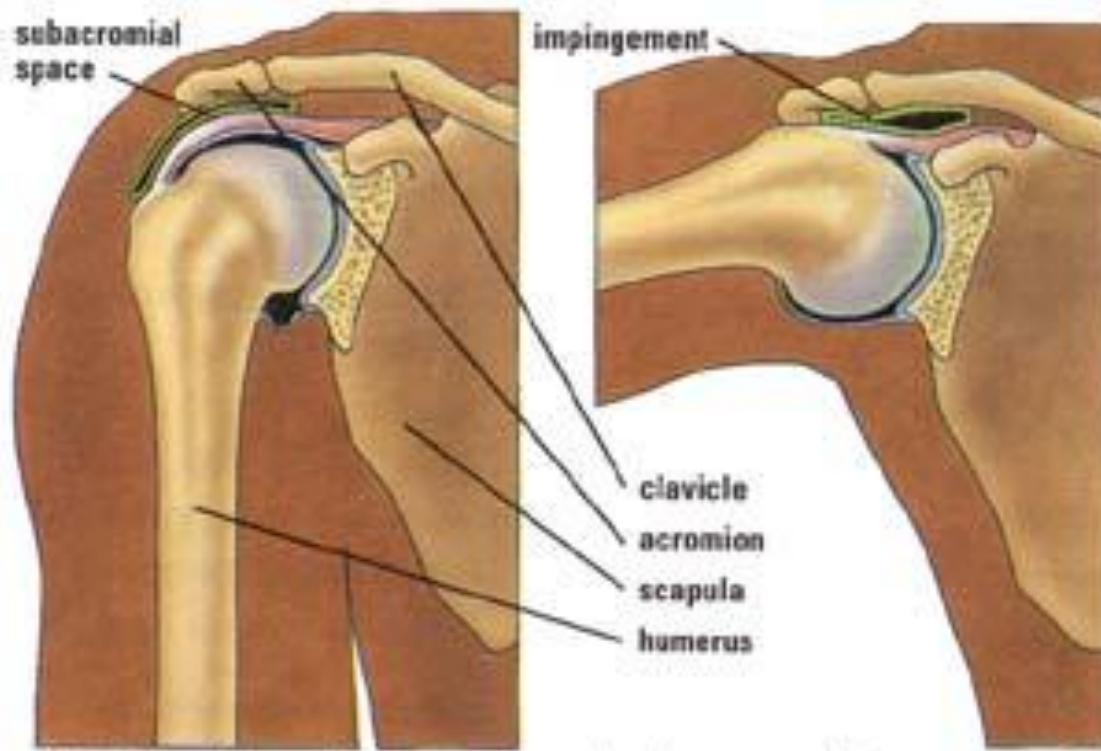
Impingement Syndrome

- Describes a condition in which the supraspinatus and bursa are pinched as they pass between the head of humerus (greater tuberosity) and the lateral aspect of the acromion



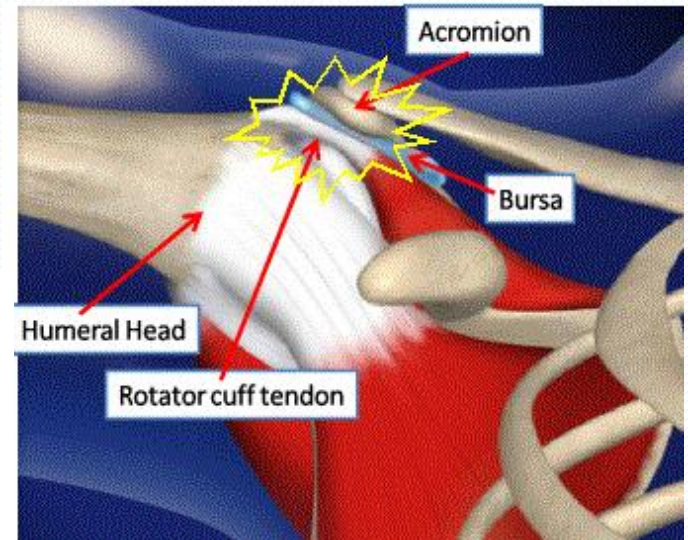
Risk factors

- Age: over 40 years
- Overhead activities
- Bursitis and supraspinatus tendinitis
- Acromial shape: type II & III acromion
- AC arthritis or AC joint osteophytes may result in impingement and mechanical irritation to the rotator cuff tendons



Normal subacromial space.

Impingement of the rotator cuff.



Risk factors

- Age (middle and older age; 40-85y)
- Activity (overhead e.g. lifting, swimming, tennis).
- Acromial shape.
- Posterior shoulder capsule stiffness.
- Rotator cuff weakness.

Symptoms

- Pain in the acromial area when the arm is flexed and internally rotated → Inability to use the overhead position.
- The pain may result from subacromial bursitis or rotator cuff tendinitis
- Pain when sleeping on the affected side..
- Pain will often become worse at night, as the subacromial bursa becomes hyperemic after a day of activity
- Decreased range of motion especially abduction
- Weakness

Differential diagnosis

- Rotator cuff tears
- Calcific tendinitis
- Biceps tendinitis
- Cervical radiculopathy
- Acromioclavicular arthritis
- Glenohumeral instability
- Degeneration of the glenohumeral joint.

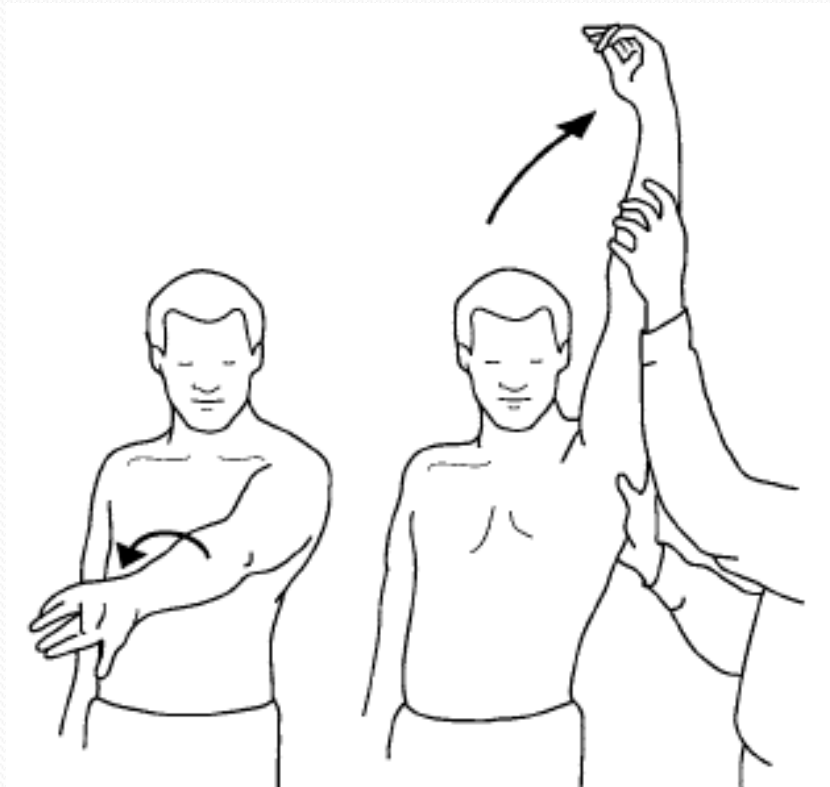
Physical examination

- Atrophy of rotator cuff muscles.
- Decreased range of motion (esp. internal rotation & adduction)
- Weakness in flexion and external rotation.
- Pain on resisted abduction and external rotation.
- Pain on “**impingement tests**”..

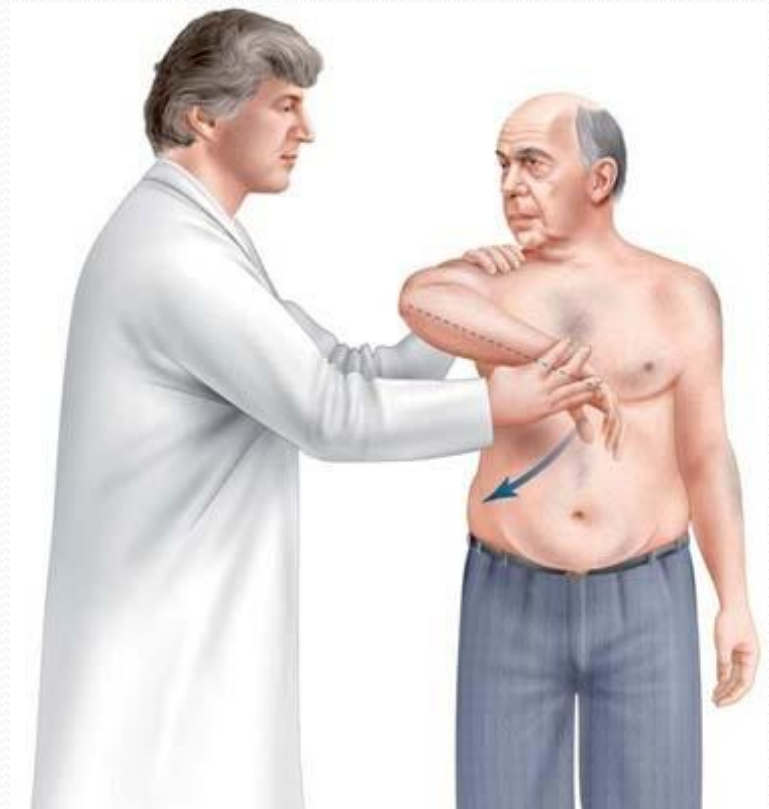
Impingement tests

- **Neer's impingement test:**
passive elevation of the internally rotated arm in the sagittal plane (shoulder forward flexion).
- **Hawkins' impingement test:**
with the elbow flexed to 90 degrees, the shoulder passively flexed to 90 degrees and internally rotated.

Neer's test

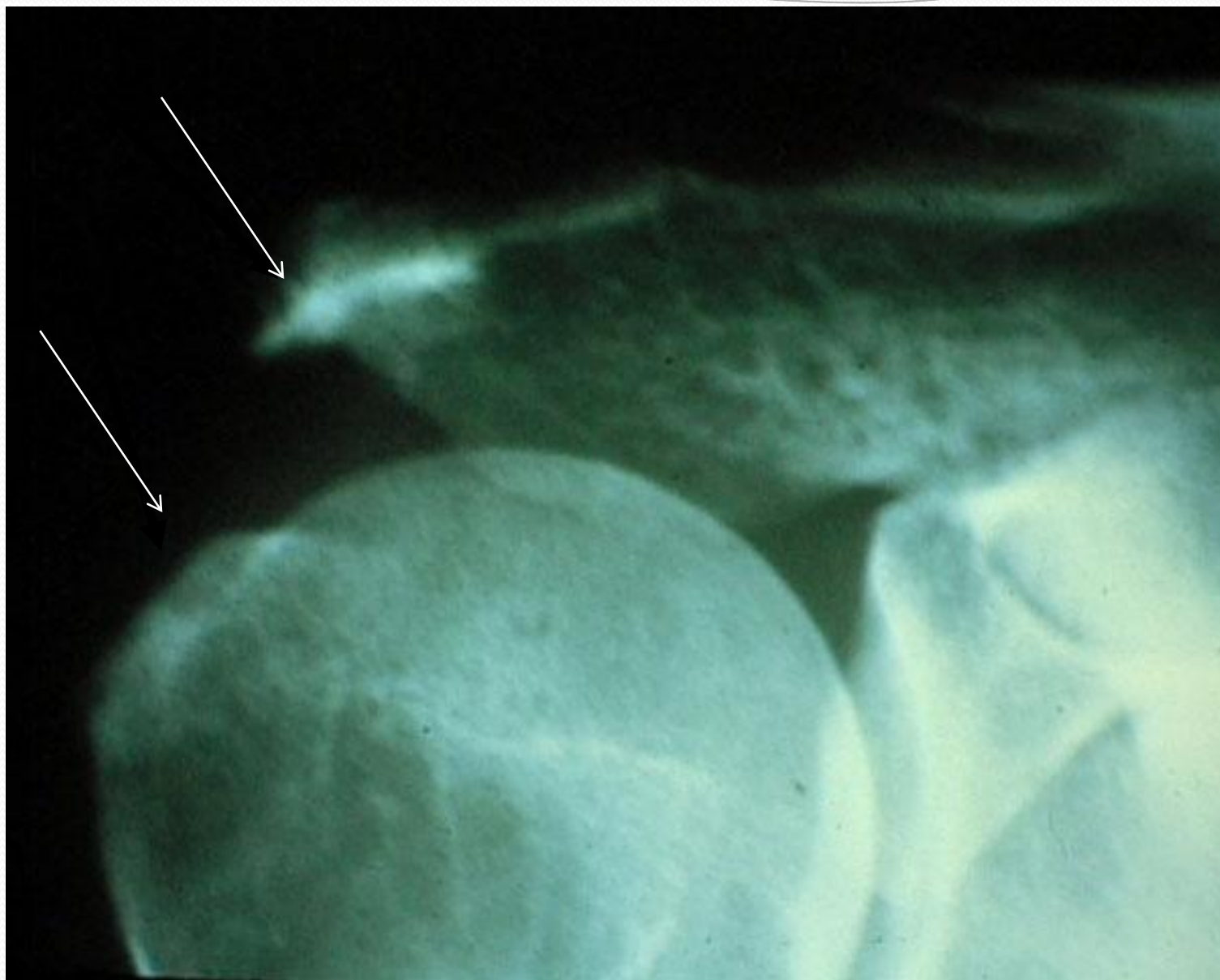


Hawkins test



Radiological findings

- Plain X-rays:
 - Acromial spurs
 - AC joint osteophytes
 - Subacromial sclerosis
 - Greater tuberosity cyst
- MRI:
 - To confirm the diagnosis and rule out rotator cuff tear



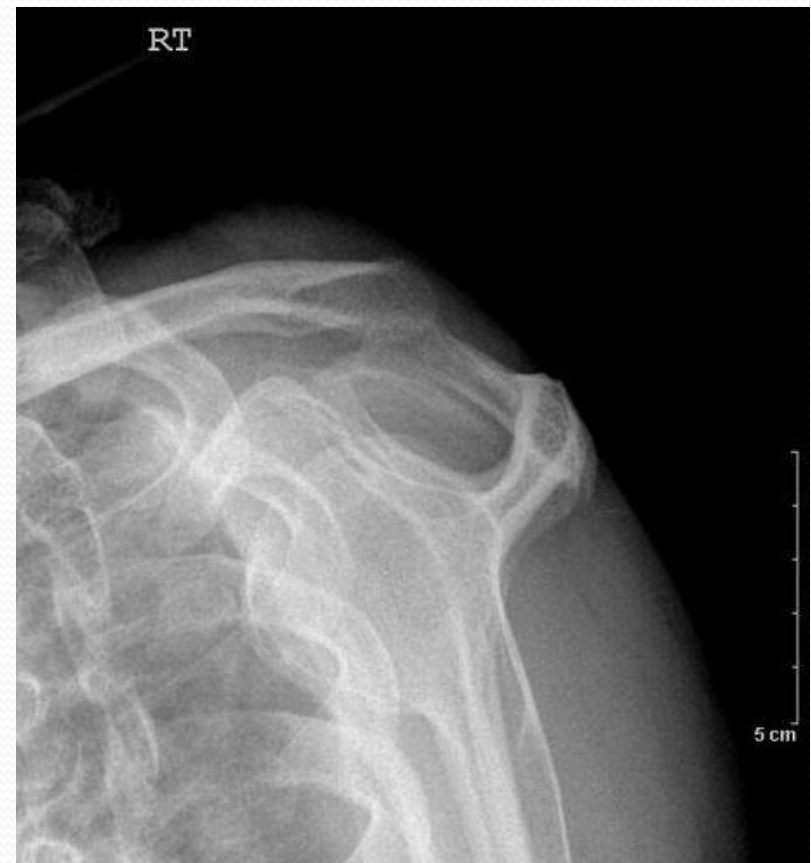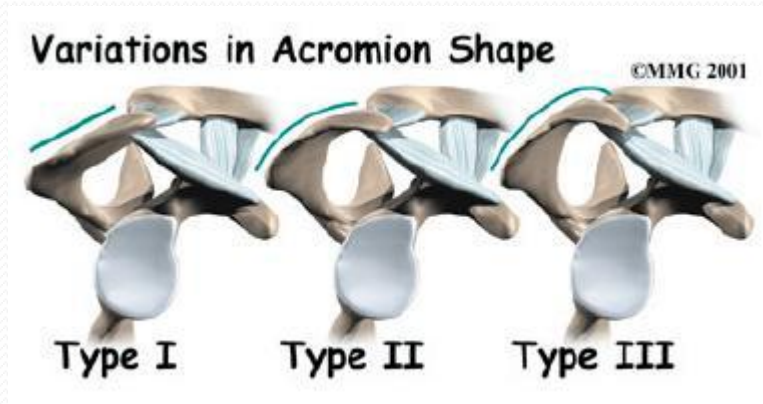
Supraspinatous outlet view

- **Type of acromion:**

I flat

II round

III hooked



Management

- Conservative treatment:
 - Always start with it
- Operative:
 - Indicated when conservative measures fail

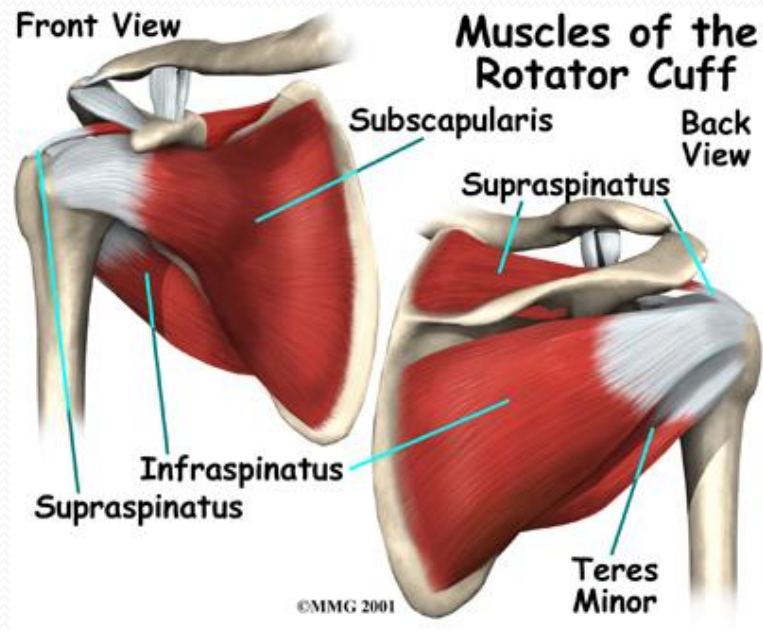
Conservative treatment

- Avoid painful and overhead activities
- Physiotherapy:
 1. Stretching and range of motion exercises
 2. Strengthening exercises
- NSAIDs
- Steroid injection into the subacromial space

Operative treatment

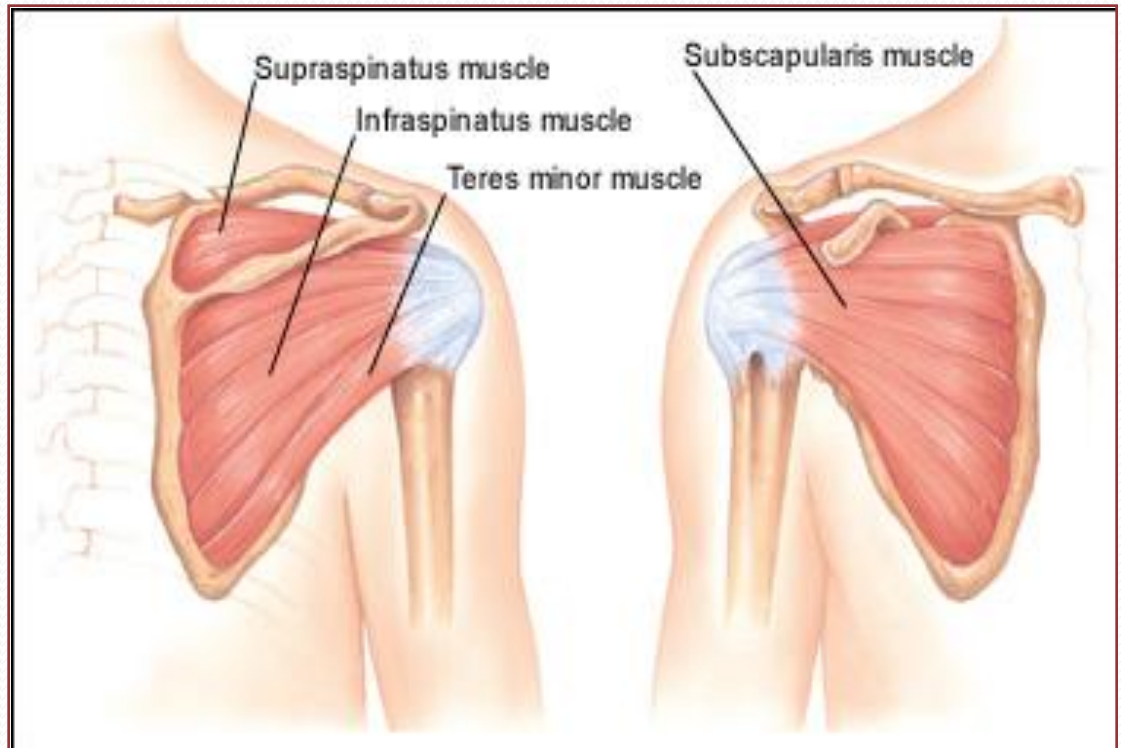
- The goal of surgery is to remove the impingement and create more subacromial space for the rotator cuff
- Indicated if there is no improvement after 6 months of conservative treatment
- The anterolateral edge of the acromion is removed
- Open (called: Acromioplasty) or arthroscopic technique (called subacromial decompression)
- Success rate 70-90%

Rotator cuff



Rotator cuff muscles

- **Supraspinatus:**
 - Initiation of abduction + external rotation
- **Infraspinatus:**
 - External rotation
- **Subscapularis:**
 - Internal rotation
- **Teres Minor:**
 - Internal rotation



Cont” Function of rotator cuff muscles

- Keep the humeral head centered on the glenoid regardless of the arm’s position in space.
- Generally work to depress the humeral head while powerful deltoid contracts

Causes of rotator cuff tears

- Intrinsic factors:
 - Vascular
 - Degenerative (age-related)
- Extrinsic factors:
 - Impingement
 - Acromial spurs
 - AC joint osteophytes
 - Repetitive use
- Traumatic (e.g. a fall or trying to catch or lift a heavy object)

Diagnosis


- History
- Physical examination
- X-rays
- MRI


Wide spectrum

- Partial
- Complete
 - Small
 - Large
 - Massive (irreparable)

Treatment


- Degenerative type: (always start with non-operative)
 - Rest
 - Physio
 - NSAIDs
 - Steroid injection
 - If no improvement of 6 months, surgical repair (open or arthroscopic) is indicated
- Traumatic type: (acute surgical repair)


- 
- If not treated → chronic pain and loss of motion and with time becomes irreparable → rotator cuff arthropathy
 - Complications of surgery: not improving, stiffness



Adhesive Capsulitis

- Also called “frozen shoulder”
- It is characterized by pain and restriction of all movements of the shoulder
(global stiffness)
- Usually self limiting (typically begins gradually, worsens over time and then resolves but may take >2 years to resolve)
- 10 % is bilateral


- 
- Risk factors:
 - DM (esp. insulin dependent)
 - Hypo and Hyperthyroidism
 - Following injury or surgery to the shoulder
 - High cholesterol

- 
- Diagnosis:
 - Mainly clinical
 - X-rays and MRI to rule out other pathologies
 - Stages:
 - Pain (freezing stage)
 - Stiffness (frozen stage)
 - Resolution (thawing stage)

Adhesive Capsulitis

Treatment

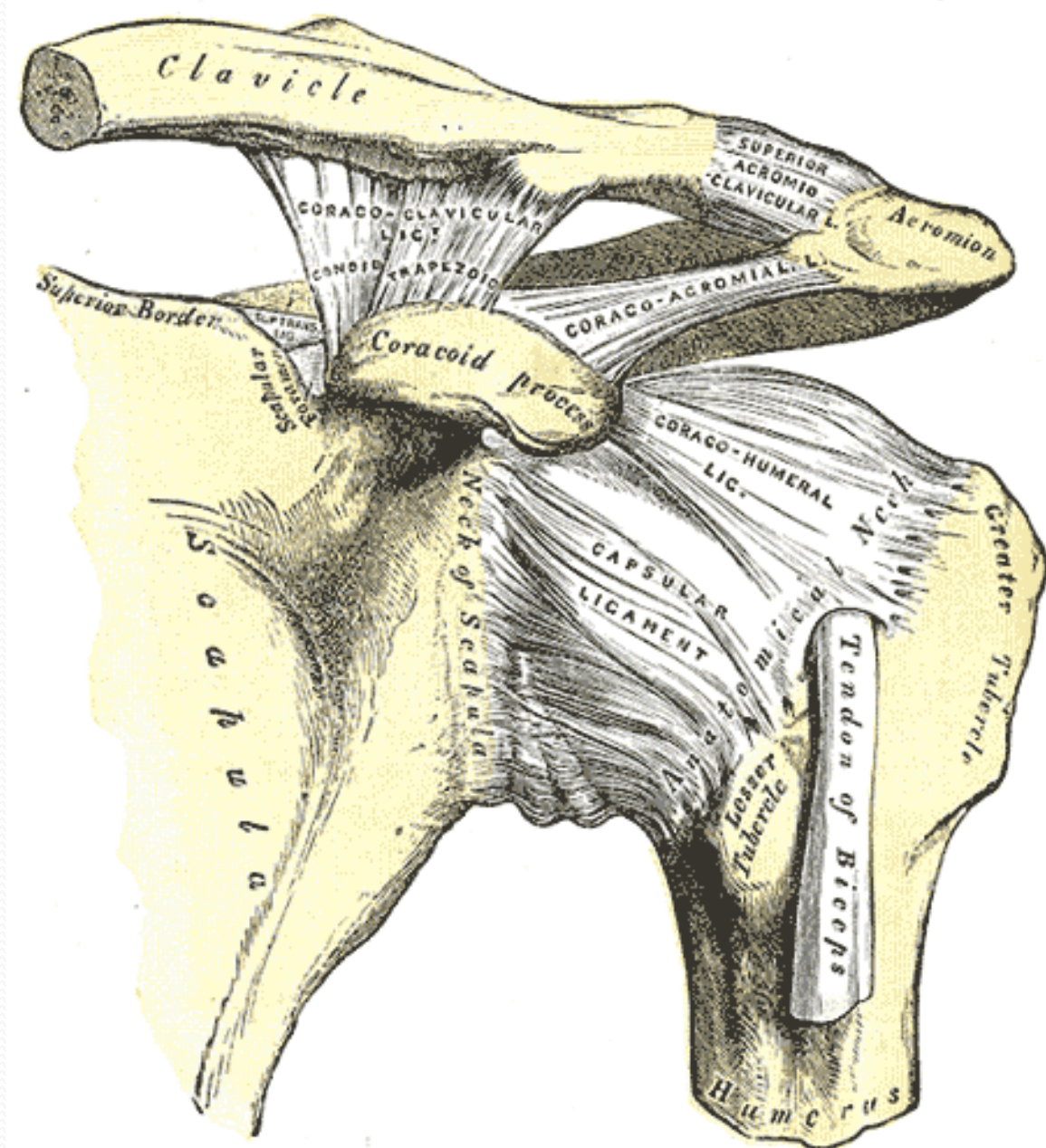
- Resolves if untreated over 2-4 years
- Physiotherapy
- Pain and anti-inflammatory medications
- Steroid injections
- Manipulation under anesthesia
- Arthroscopic capsular release



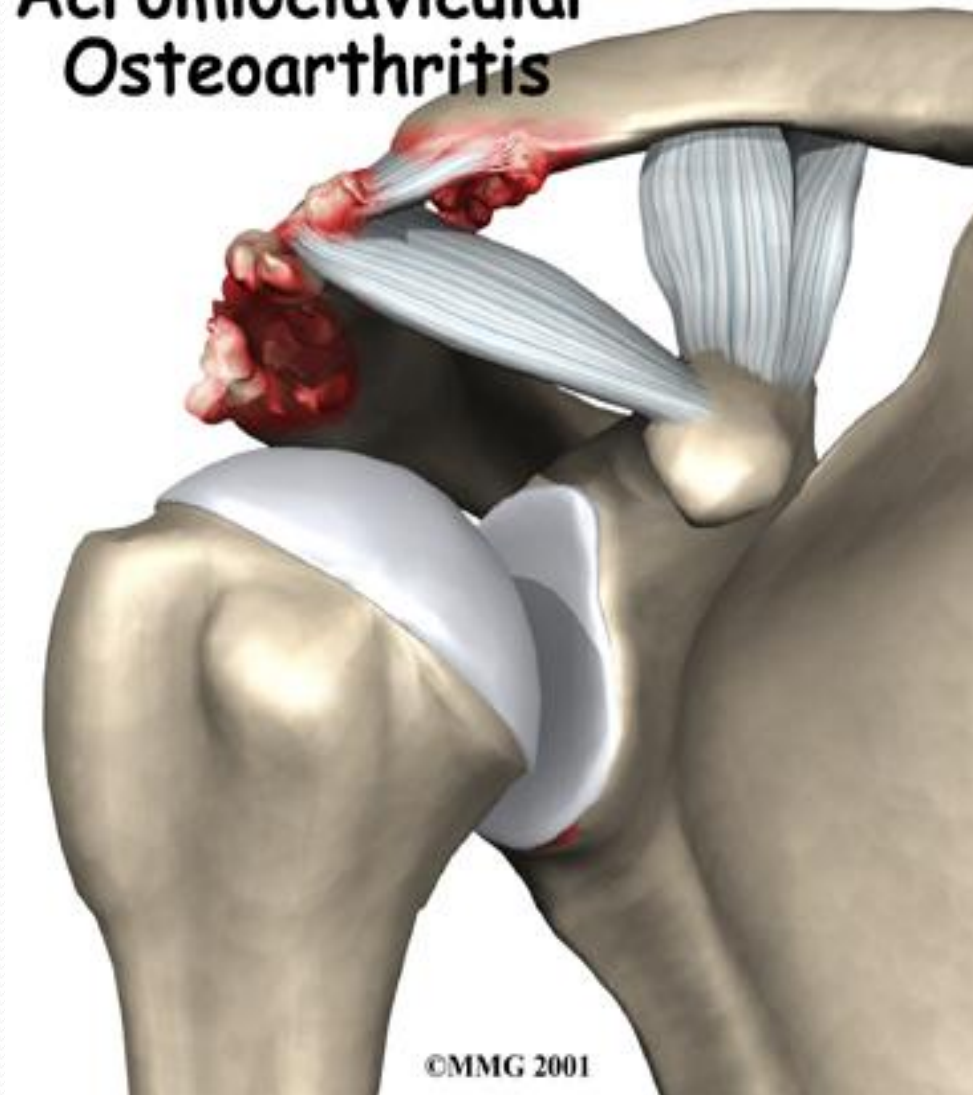
Acromioclavicular Pathology

- The AC joint is different from joints like the knee or ankle, because it doesn't need to move very much. The AC joint only needs to be flexible enough for the shoulder to move freely. The AC joint just shifts a bit as the shoulder moves.

- The joint is stabilized by three ligaments

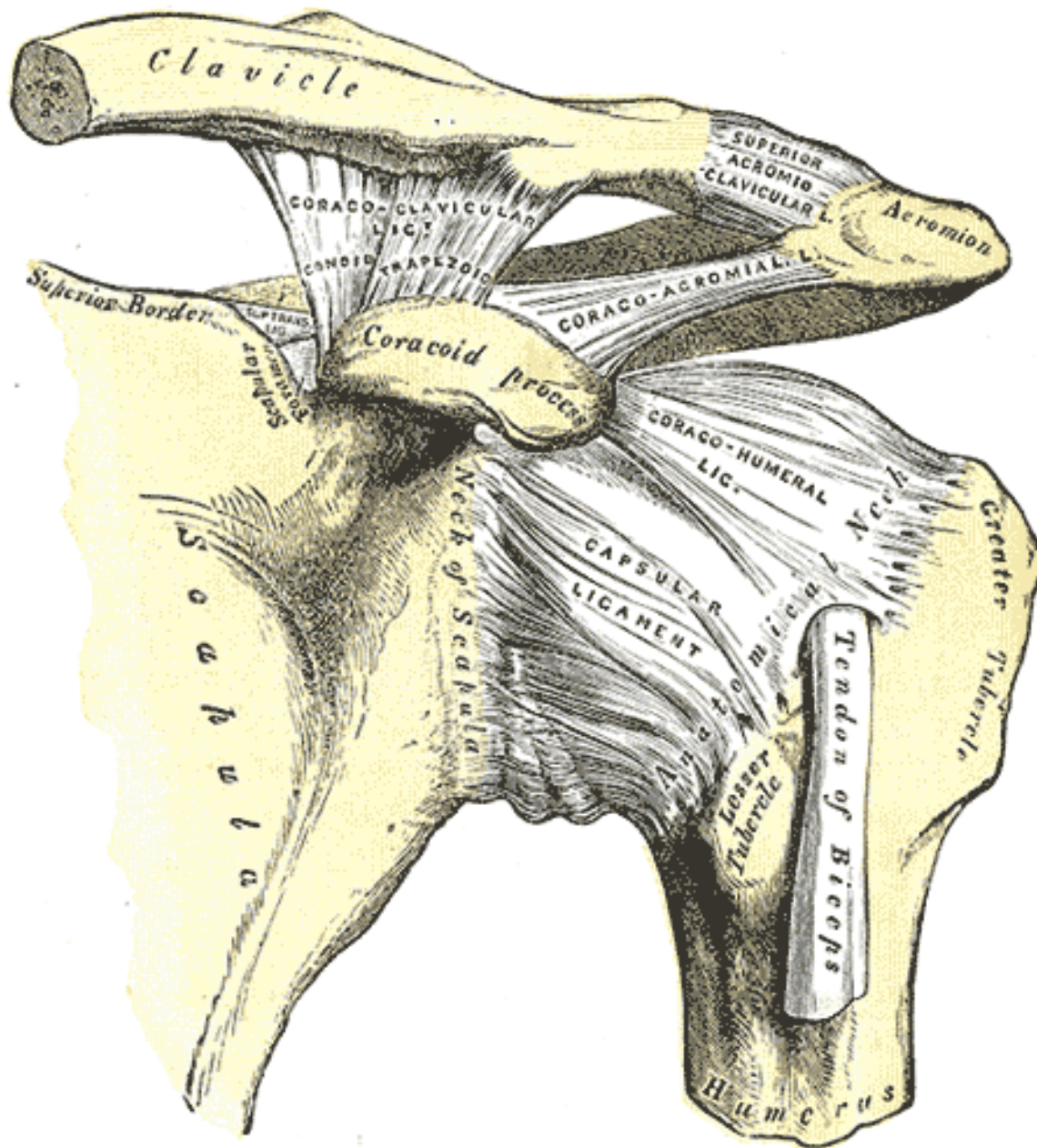


Acromioclavicular Osteoarthritis



Causes of AC Arthritis

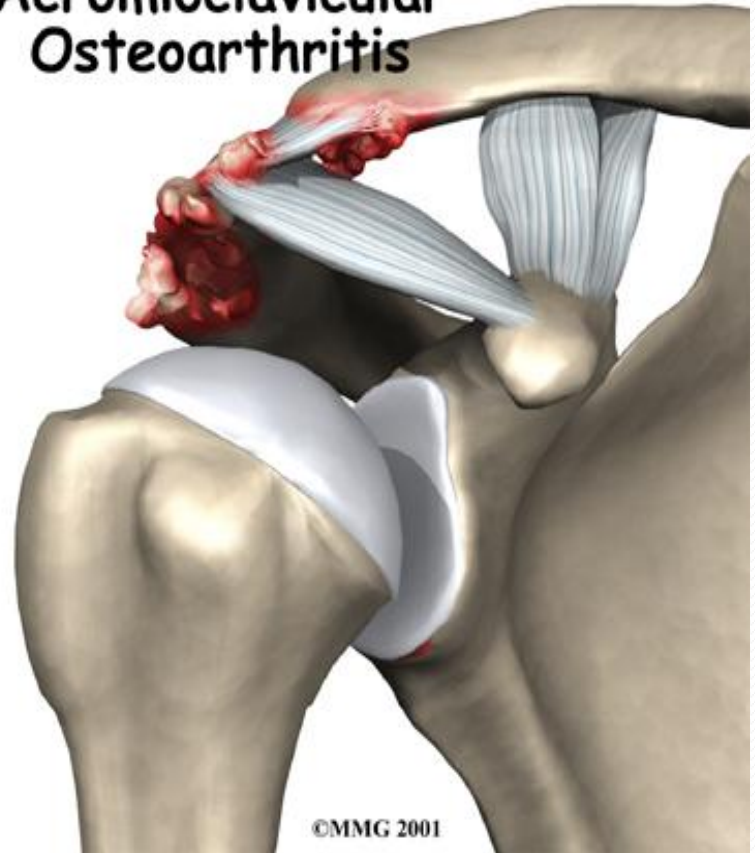
- Degenerative osteoarthritis.(wear and tear in old aged people)
- Rheumatoid Arthritis .
- Gouty Arthritis.
- Septic Arthritis.
- Atraumatic distal clavicle osteolysis in weight lifters.



AC arthritis

- Arthritis is a condition characterized by loss of cartilage in the joint, which is essentially wear and tear of the smooth cartilage which allows the bones to move smoothly.
- Motions which aggravate arthritis at the AC joint include reaching across the body toward the other arm.

**Acromioclavicular
Osteoarthritis**



©MMG 2001

Causes of AC osteoarthritis

- Degenerative osteoarthritis.(wear and tear in old aged people)
- Rheumatoid Arthritis
- Gouty Arthritis
- Septic Arthritis
- Atraumatic osteolysis in weight lifters. (result of repeated movements that wear away the cartilage surface found at the acromioclavicular joint)
- Post-traumatic osteolysis of lateral end of clavicle.(like dislocation or a fracture)

Signs and Symptoms

Pain , which worsens with movement and progressively worsens.(the patient may suffer a night pain which is a sign of arthritis)

It is commonly associated with impingement syndrome

Diagnosis:

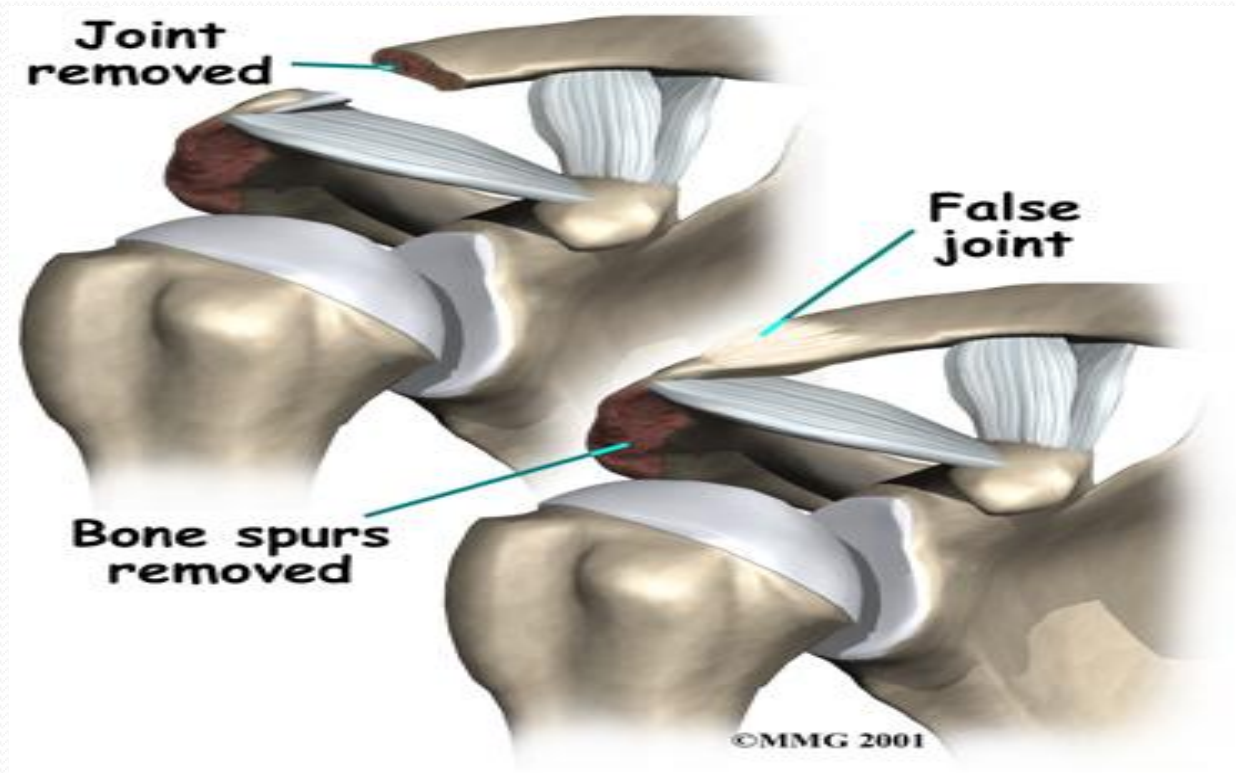
Clinical and by x-rays

AC osteoarthritis

Non-surgical Treatment

- Rest , avoid weightlifting and push-ups
- Pain medications and NSAID to reduce pain and inflammation

Surgical Treatment



Dislocation of the Shoulder

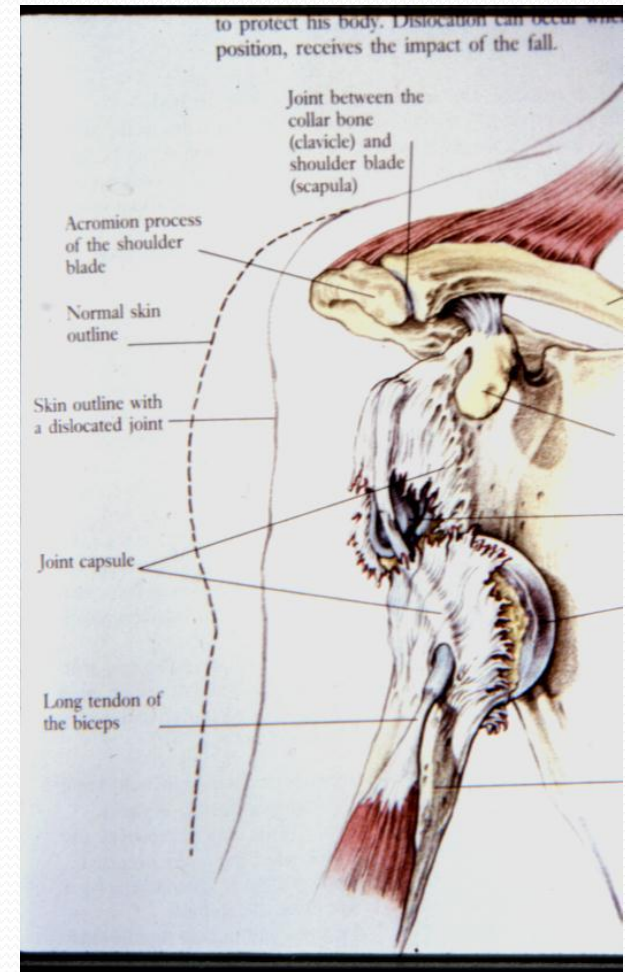
- Mostly **Anterior** > 95 % of dislocations
- **Posterior** Dislocation occurs < 5 %
- True **Inferior** dislocation (luxatio erecta) occurs < 1%
- **Habitual** Non traumatic dislocation may present as Multi directional dislocation due to generalized ligamentous laxity and is **Painless**

Mechanism of anterior shoulder dislocation

- Usually **Indirect** fall on Abducted and extended shoulder
- May be direct when there is a blow on the shoulder from behind

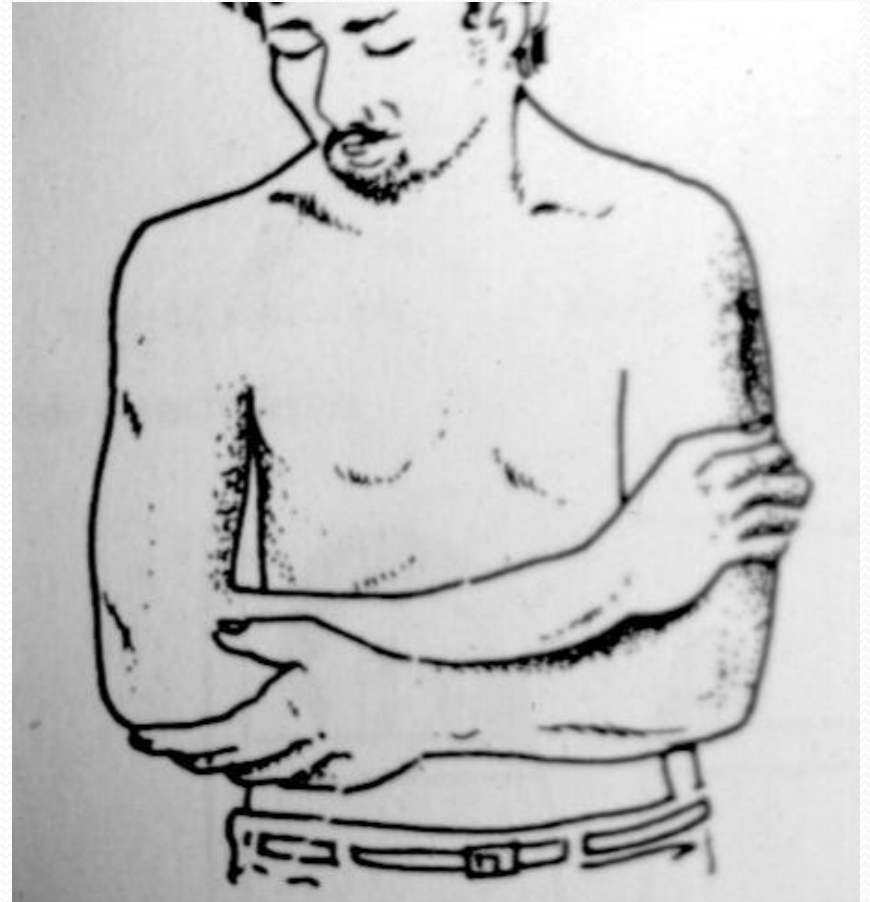
Anterior Shoulder dislocation

- Usually also inferior
- Bankart's Lesion



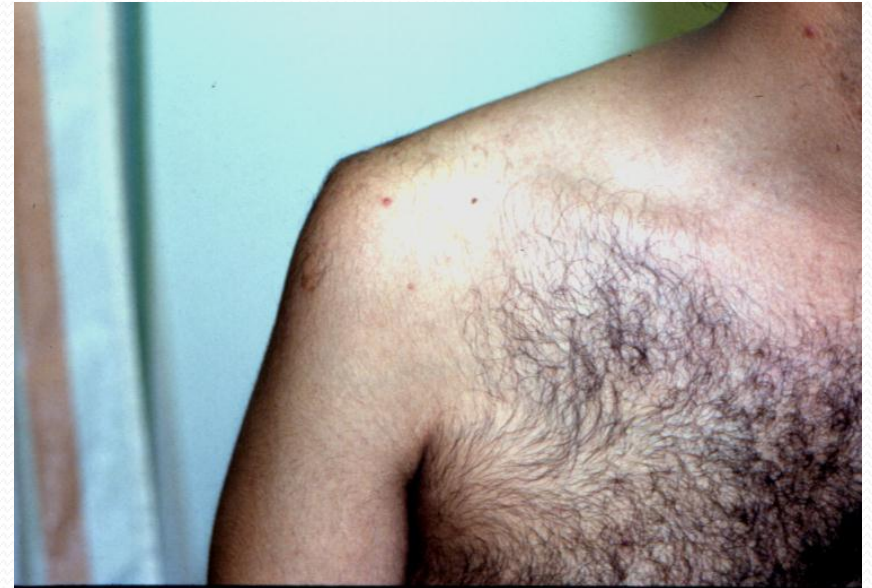Clinical Picture

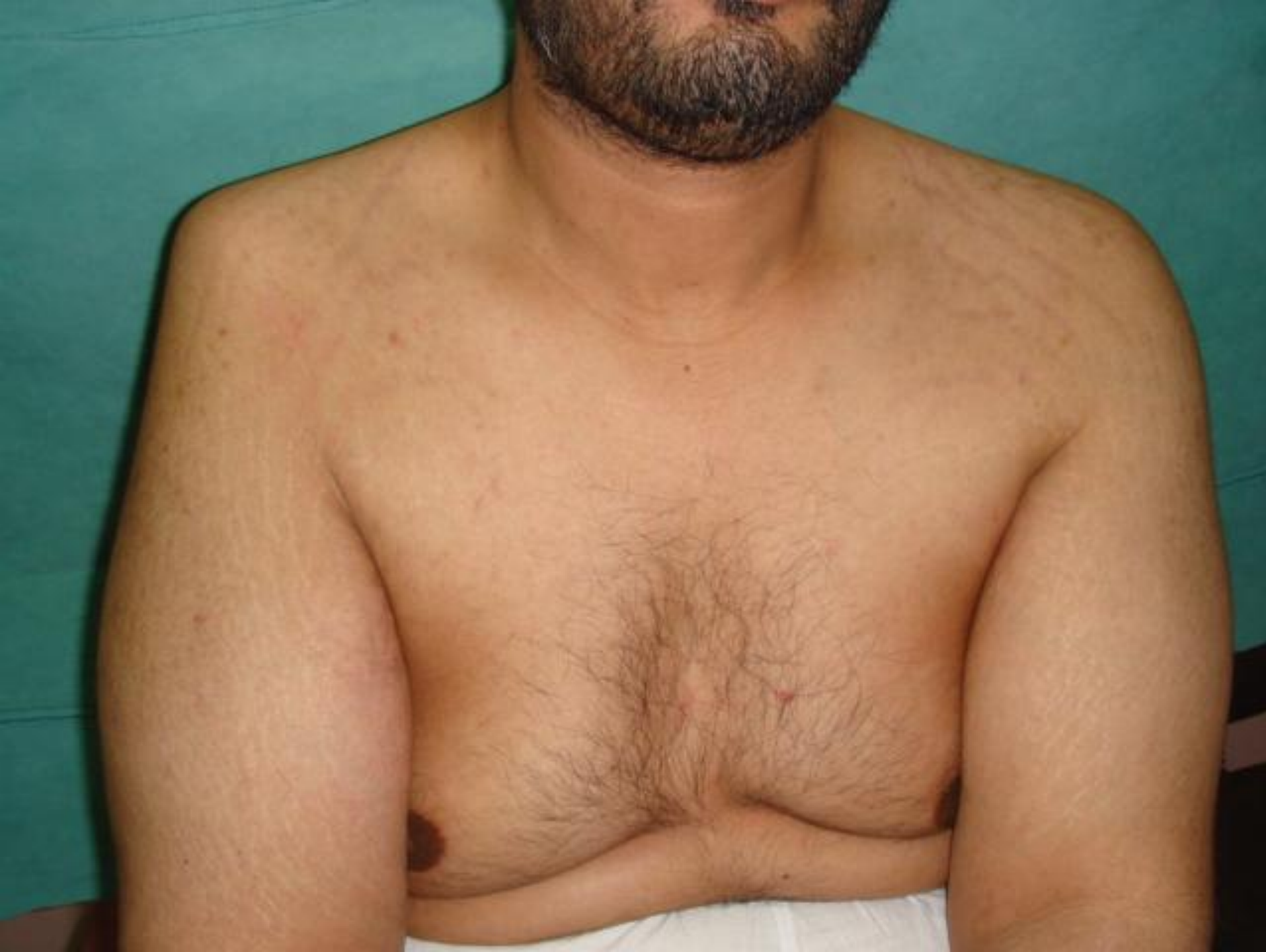- Patient is in pain
- Holds the injured limb with other hand close to the trunk
- The shoulder is abducted and the elbow is kept flexed
- There is loss of the normal contour of the shoulder



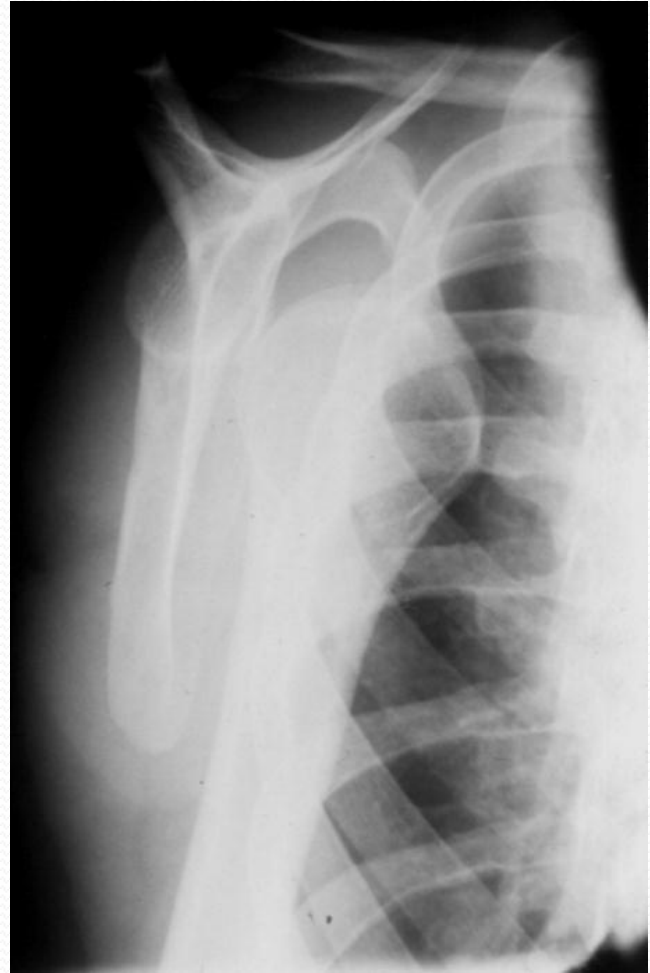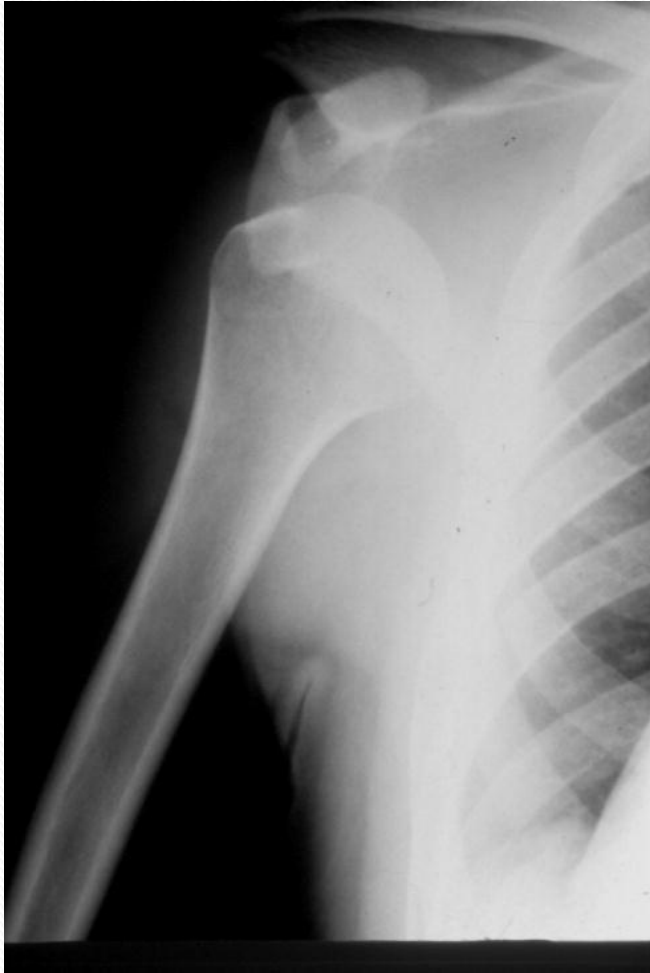Clinical Picture

- Loss of the contour of the shoulder may appear as a step
- Anterior bulge of head of humerus may be visible or palpable
- A gap can be palpated above the dislocated head of the humerus



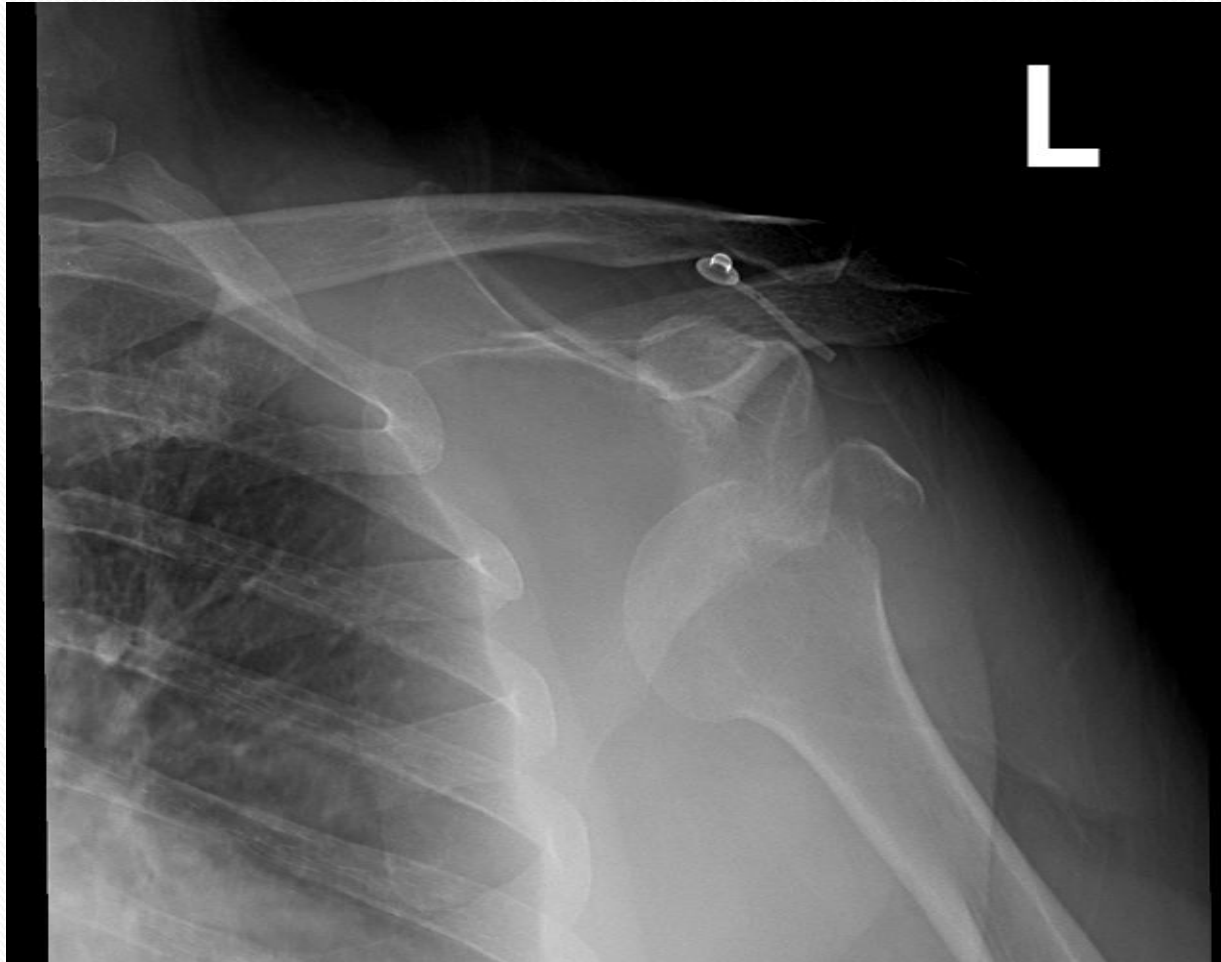


X-ray anterior shoulder dislocation



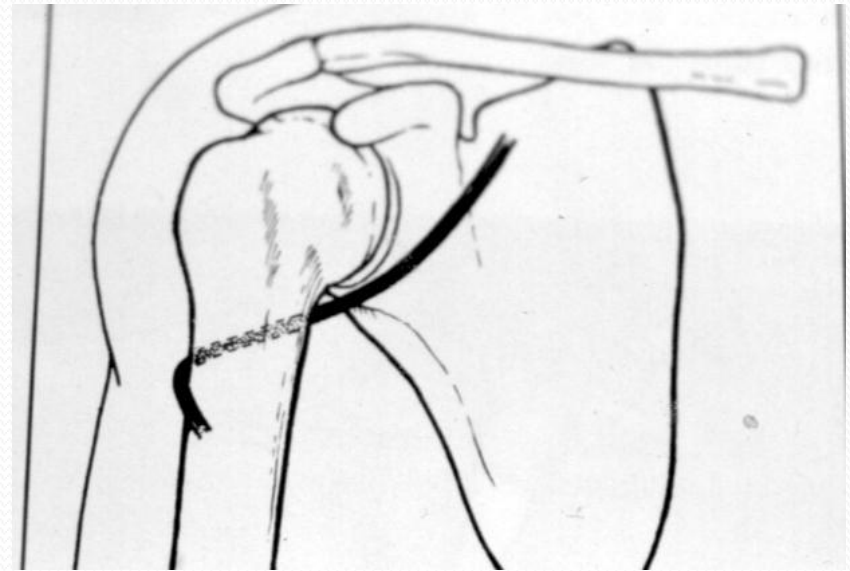
Associated injuries of anterior Shoulder Dislocation

- Injury to the neuro vascular bundle in axilla
- Injury of the **Axillary Nerve** (Usually stretching leading to temporary neuropraxia)
- Associated **fracture**

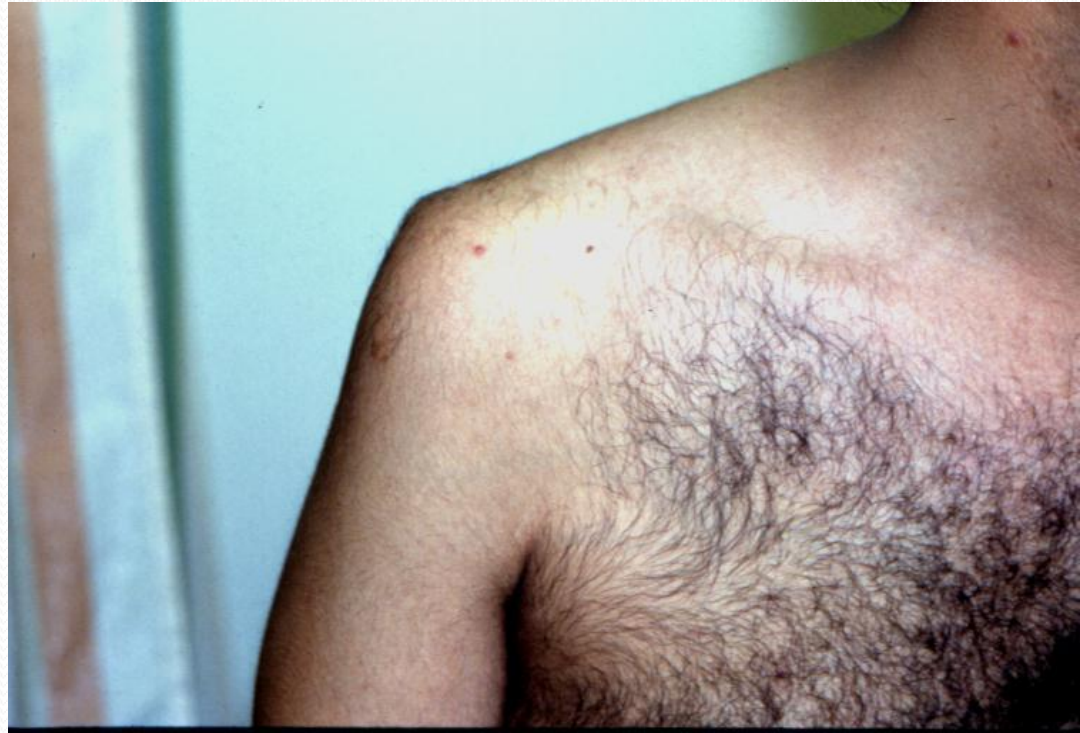
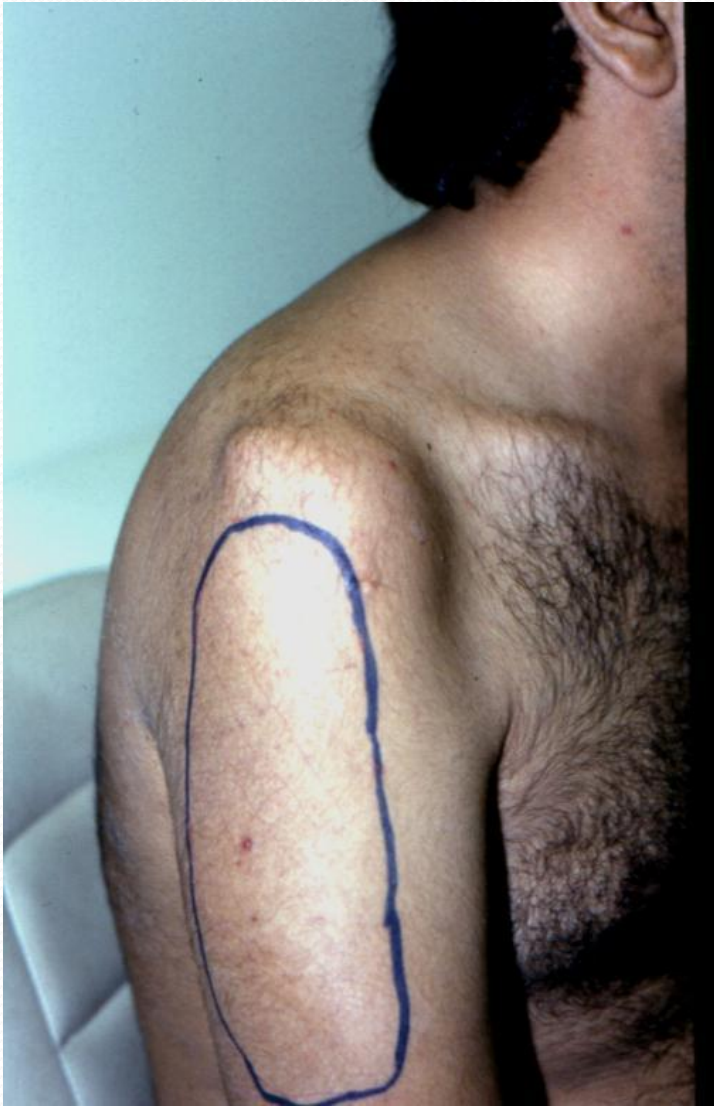
Axillary Nerve Injury

- It is a branch from posterior cord of Brachial plexus
- It hooks close round neck of humerus from posterior to anterior
- It pierces the deep surface of deltoid and supply it and the part of skin over it



Axillary nerve injury



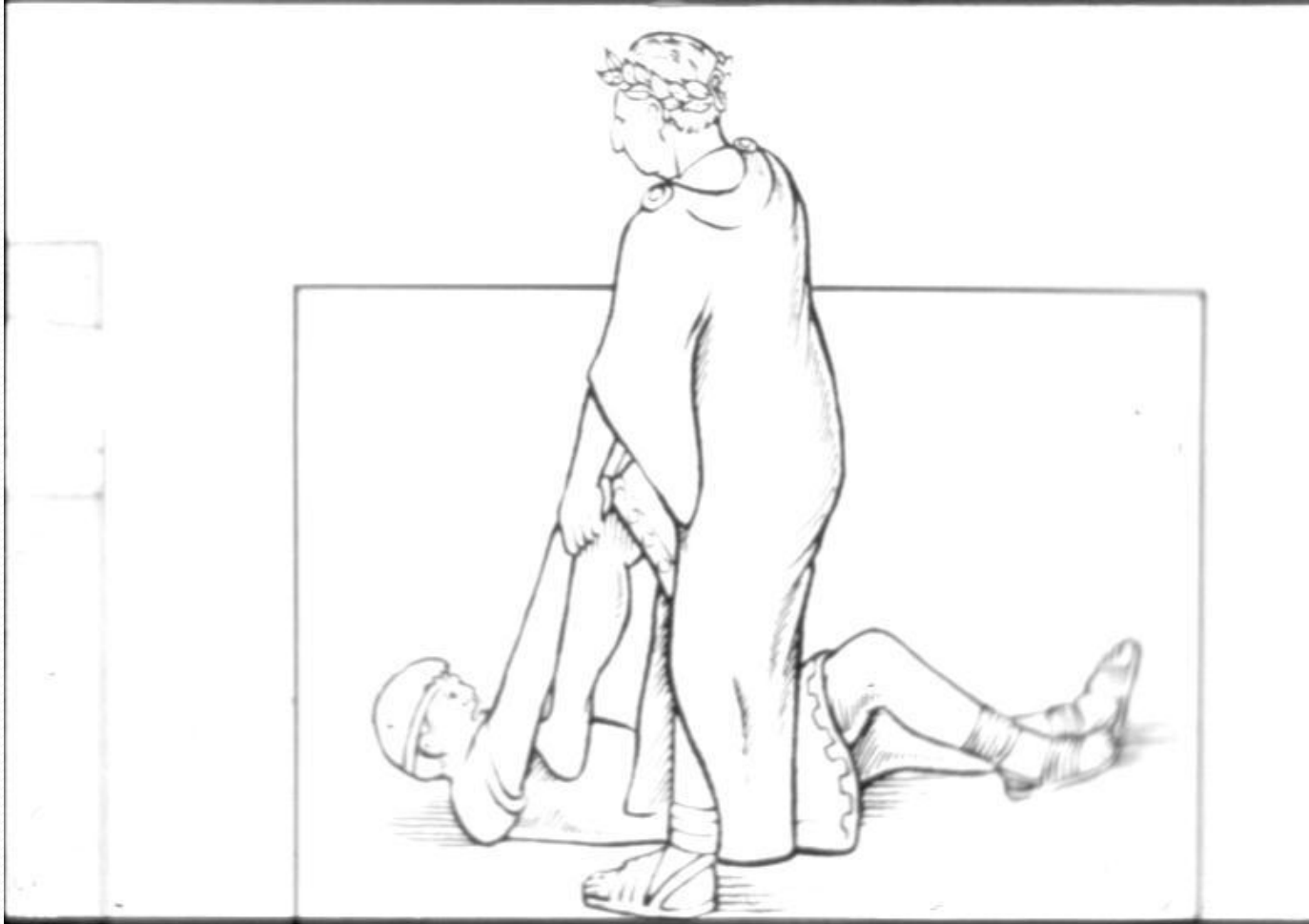
Management of Anterior Shoulder Dislocation

- Is an **Emergency**
- It should be reduced in less than 24 hours or there may be Avascular Necrosis of head of humerus
- Following reduction the shoulder should be immobilised strapped to the trunk for 3-4 weeks and rested in a collar and cuff

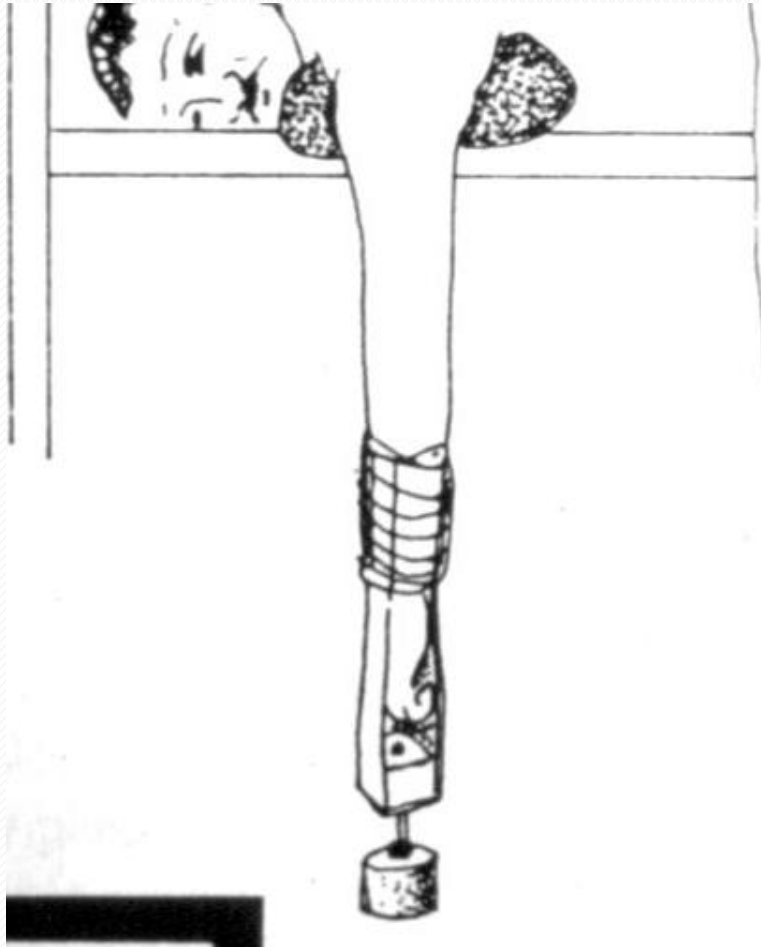
Methods of Reduction of anterior shoulder Dislocation

- **Hippocrates Method** (A form of anesthesia or pain abolishing is required)
- **Stimpson's technique** (some sedation and analgesia are used but No anesthesia is required)
- **Kocher's technique** is the method used in hospitals under general anesthesia and muscle relaxation

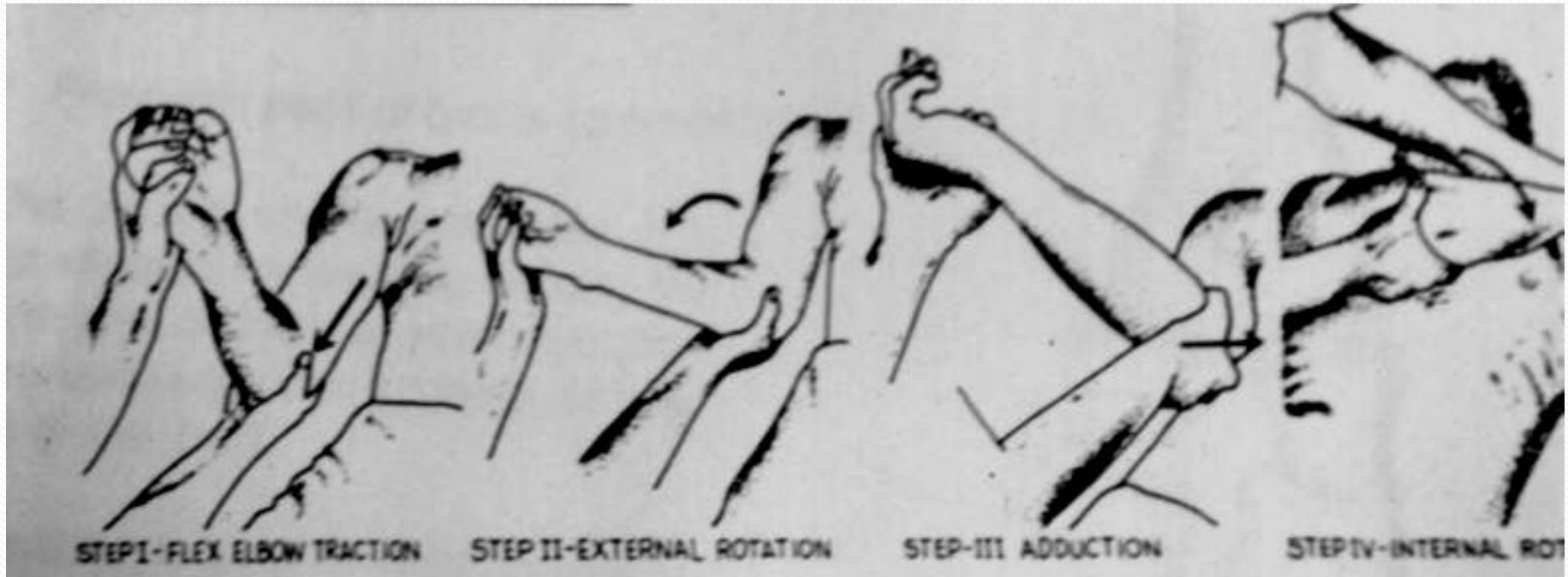
Hippocrates Method



Stimpson's technique



Kocher's Technique



Complications of anterior Shoulder Dislocation : Early

- Neuro vascular injury (rare)
- Axillary nerve injury
- Associated Fracture of neck of humerus or greater or lesser tuberosities

Complications of anterior shoulder Dislocation : Late

- **Avascular necrosis** of the head of the Humerus
(high risk with delayed reduction)
- **Recurrent shoulder dislocations**



Thank you