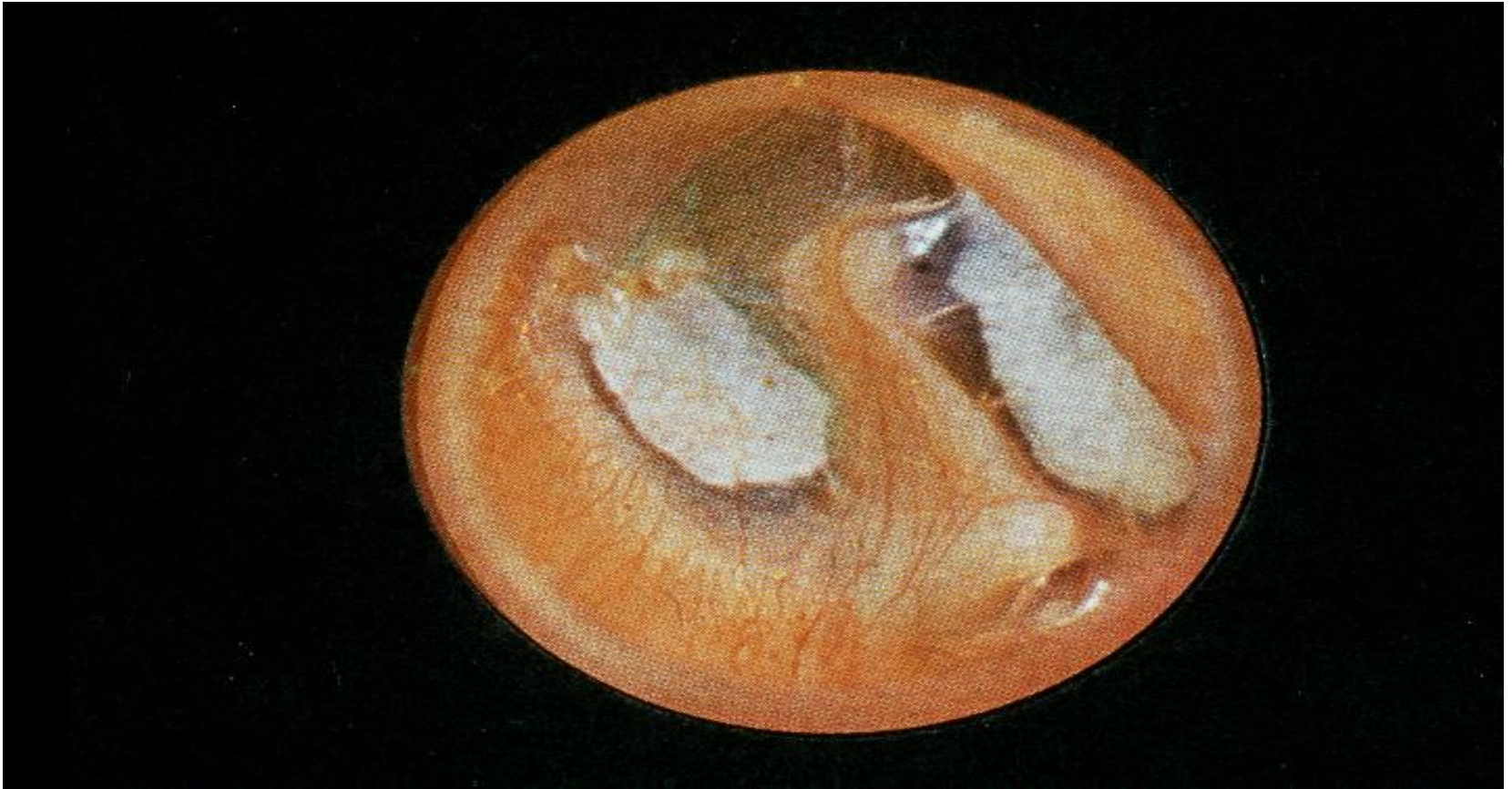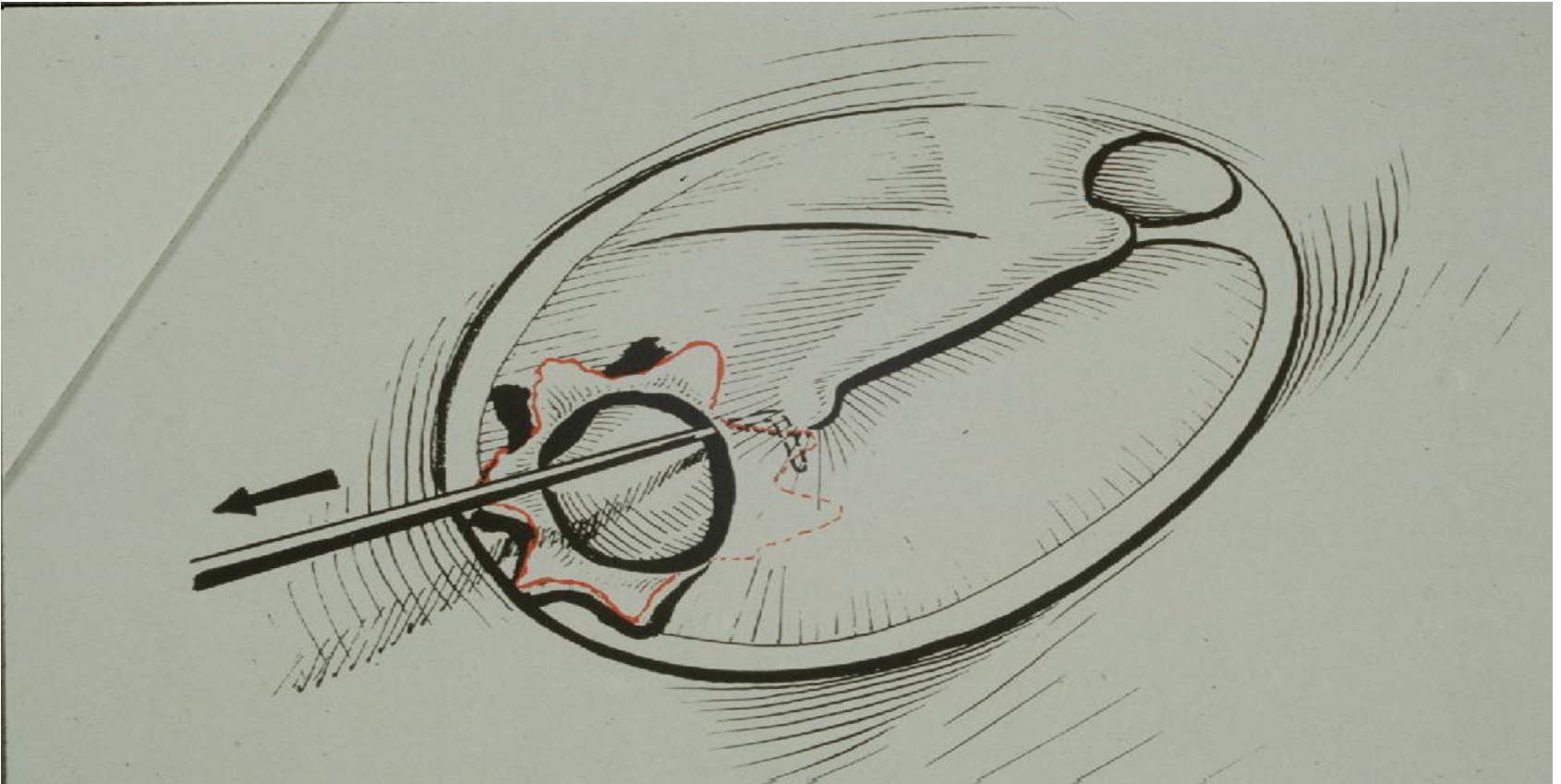


Chronic Otitis Media

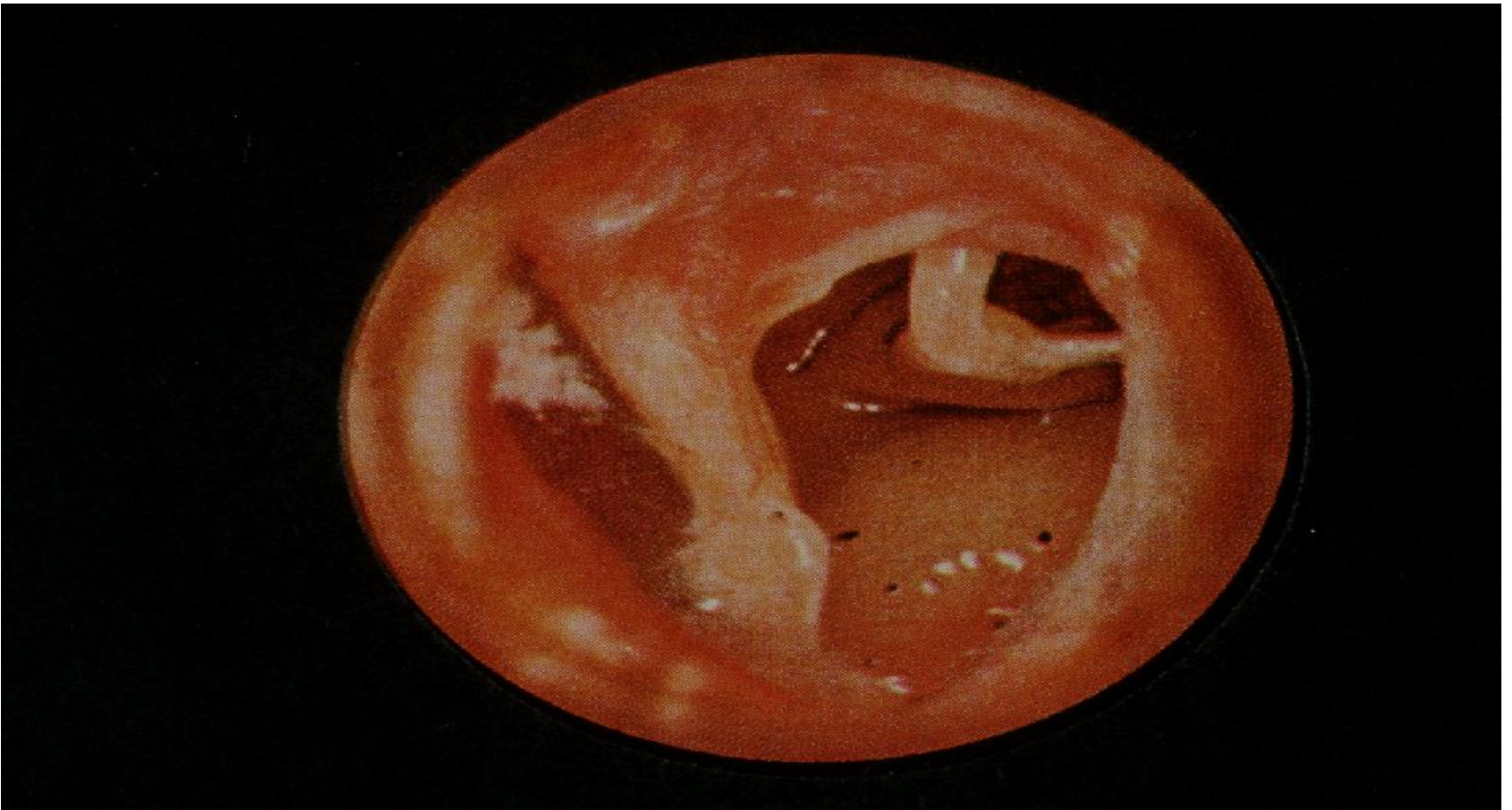
SAQ's



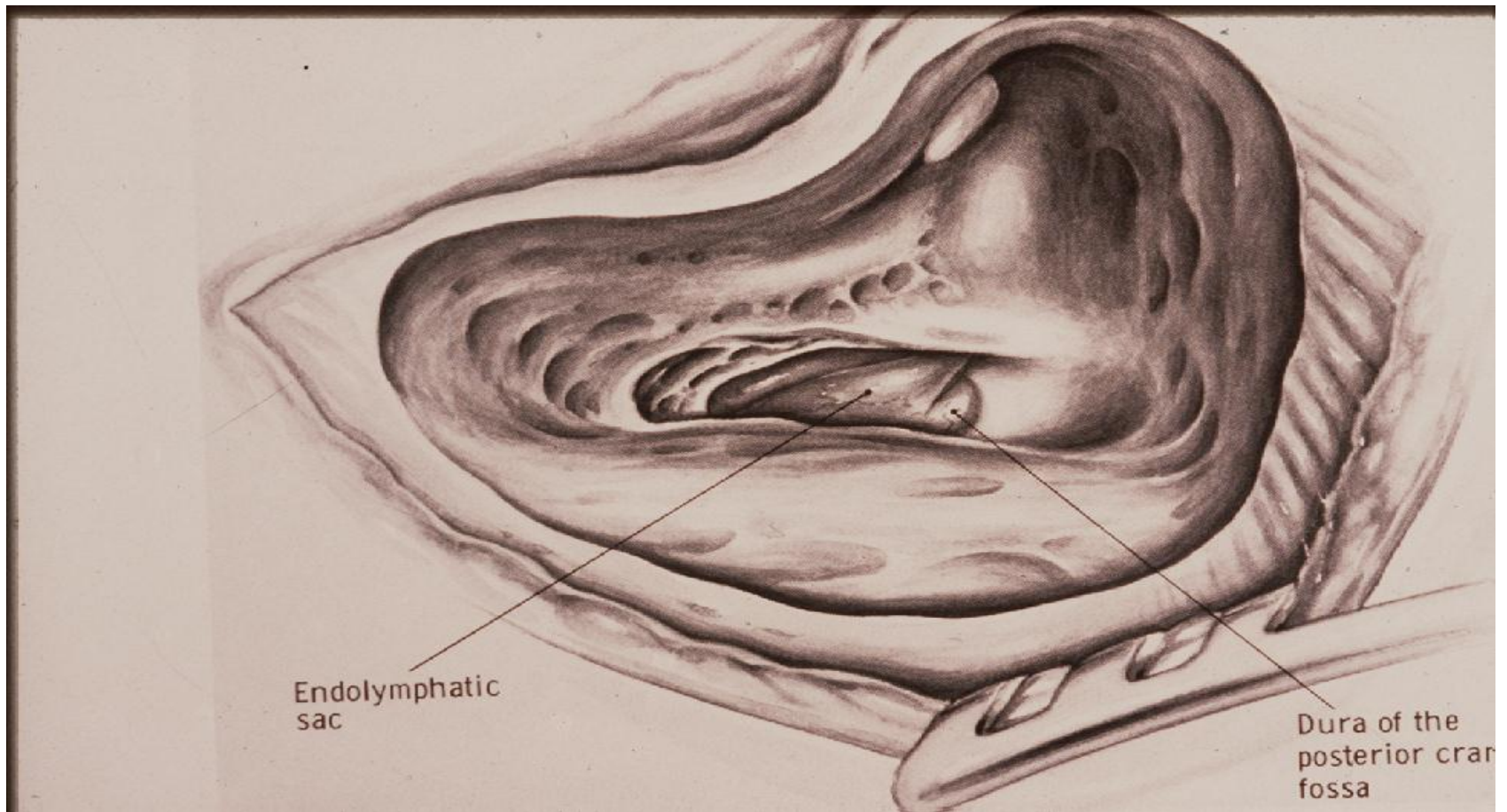
Healed Tympanic Membrane
with tympanosclerosis



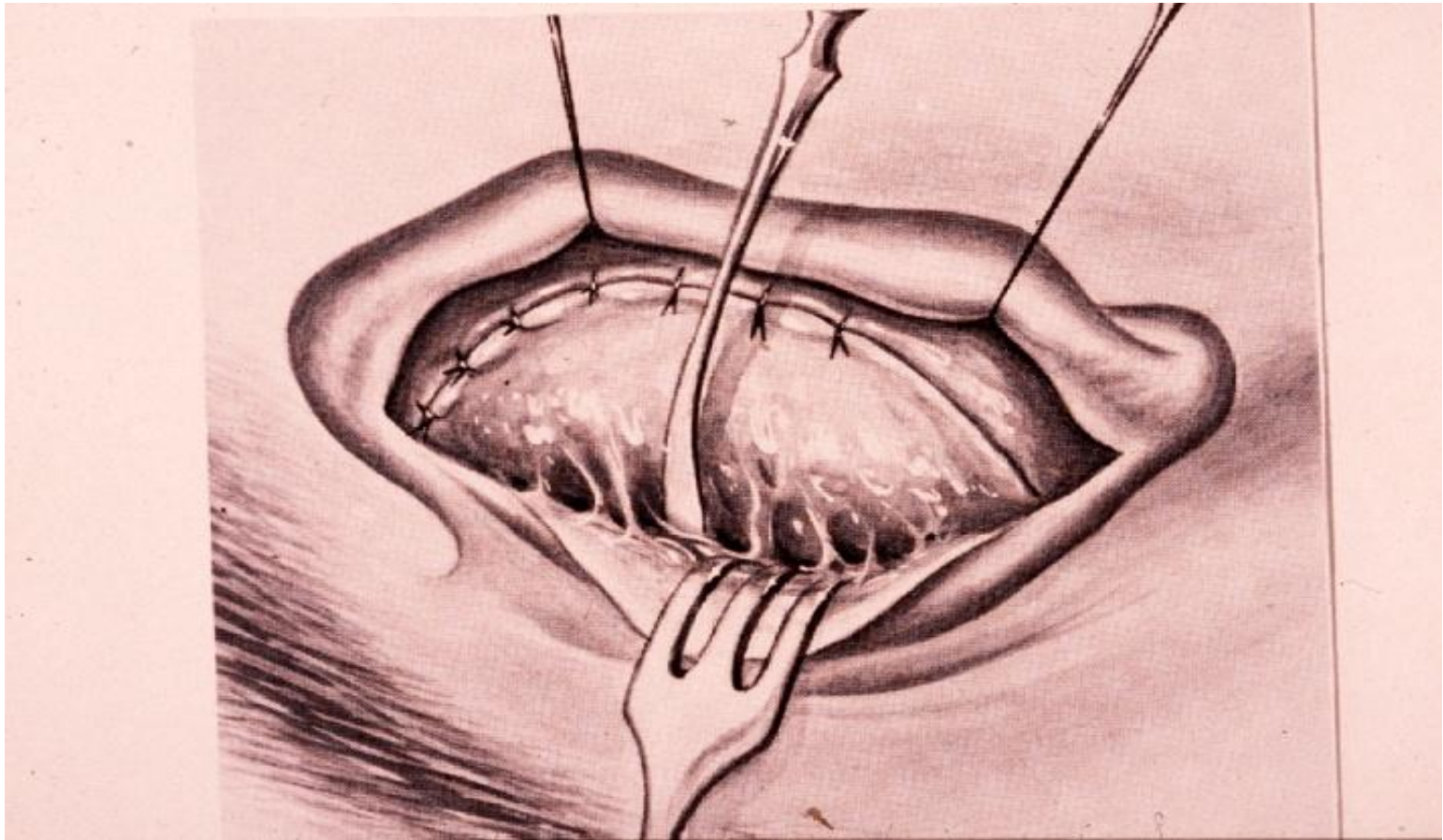
Safe and Unsafe perforation
in chronic otitis media



Total perforation in chronic
suppurative otitis media



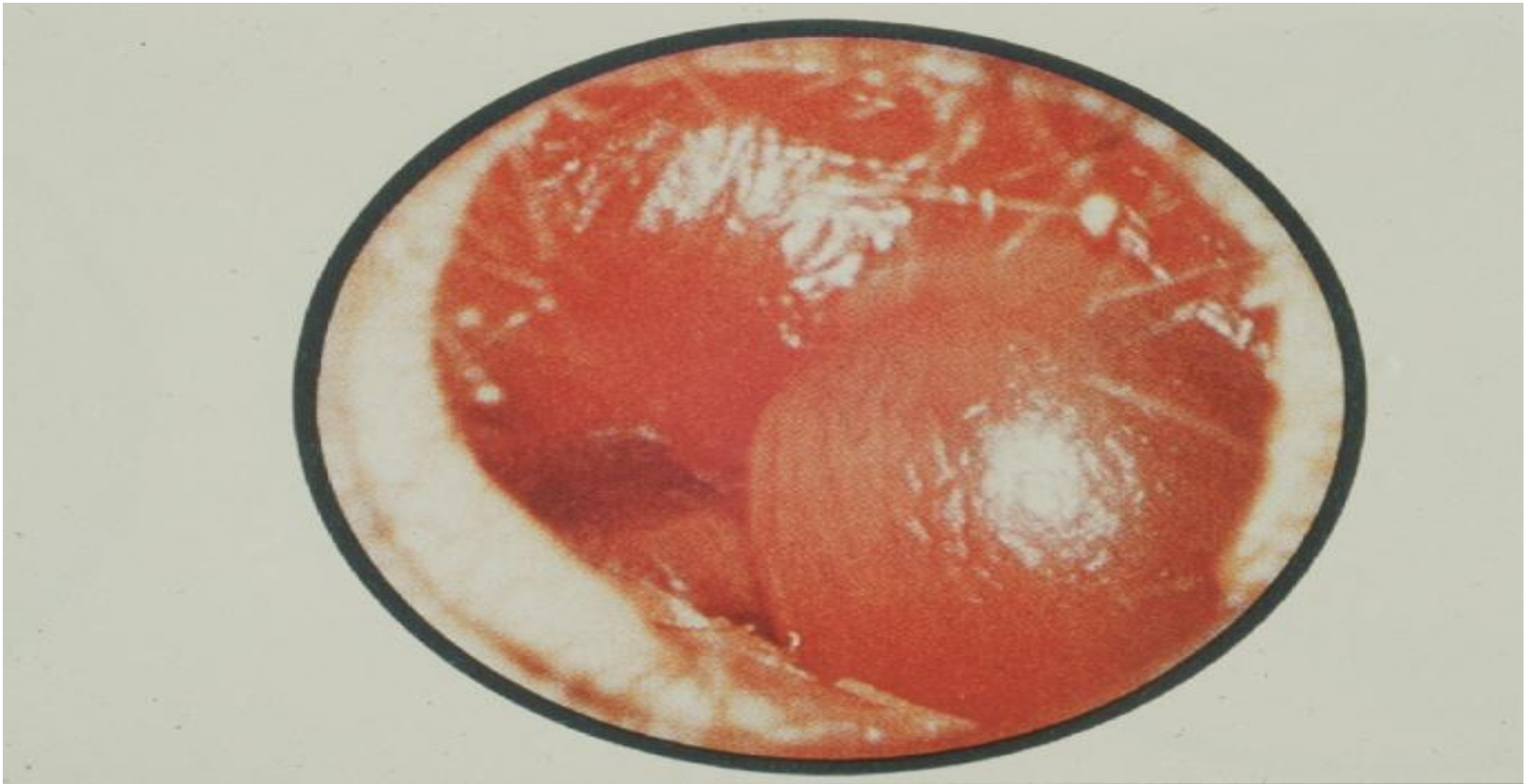
Mastoidectomy operation
as the possible operation in
chronic suppurative otitis media



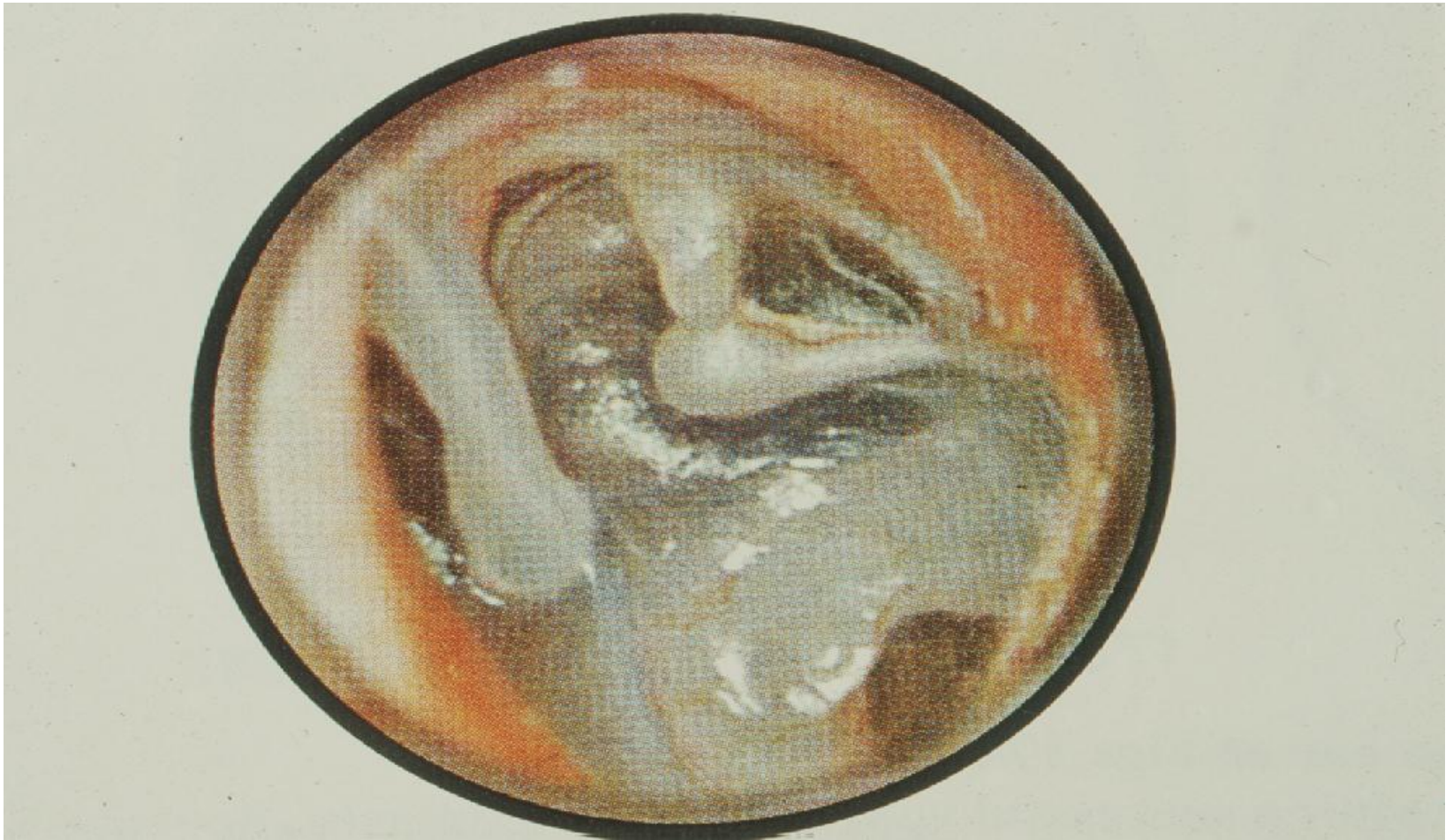
Post auricular incision approach
to middle ear and mastoid



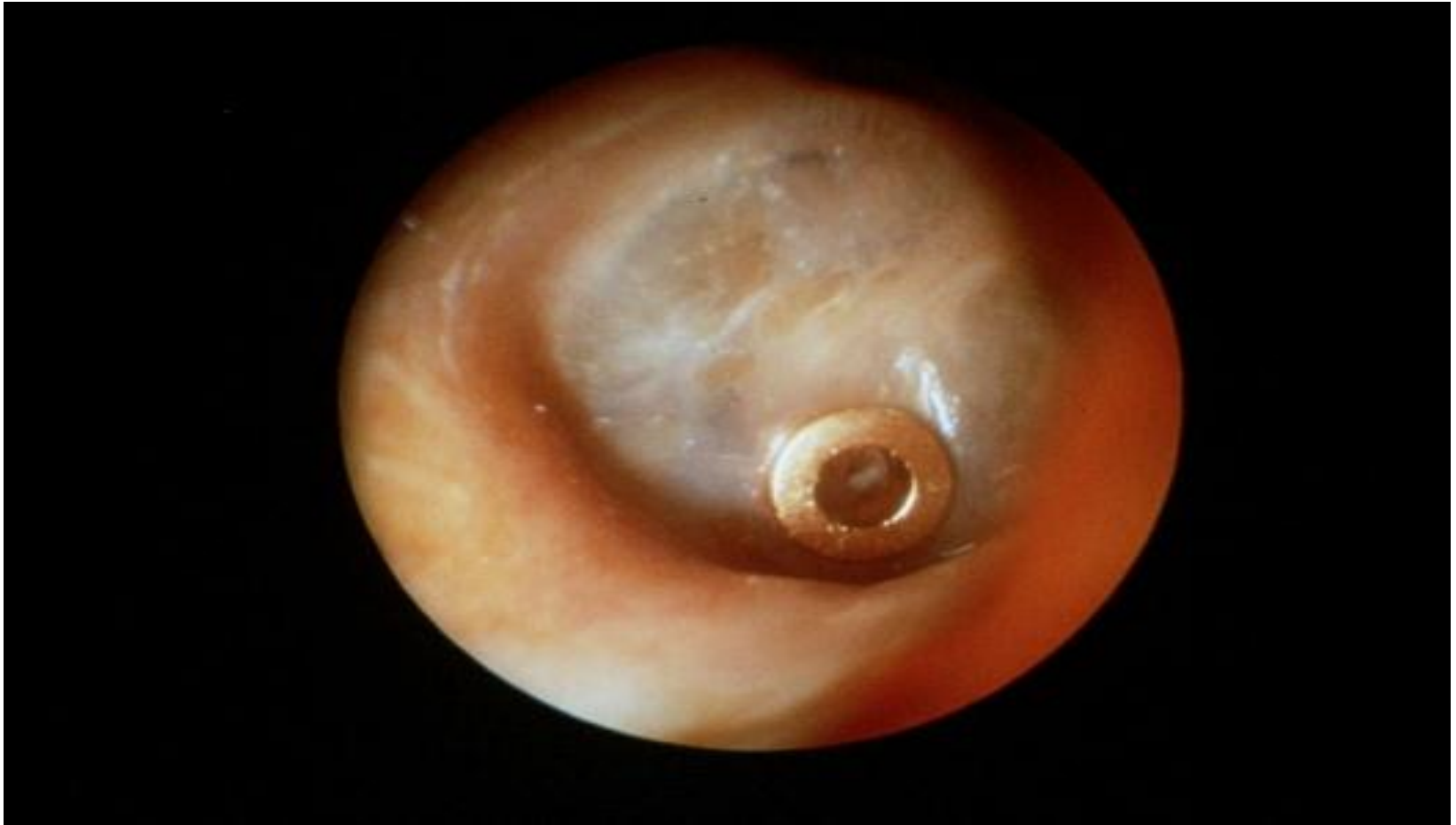Facial paralysis as a complication of middle ear and mastoid surgery



Acute Otitis Media – Stage IV



Adhesive otitis media (end stage)



Ventilation tube insertion
(surgical treatment of otitis media)