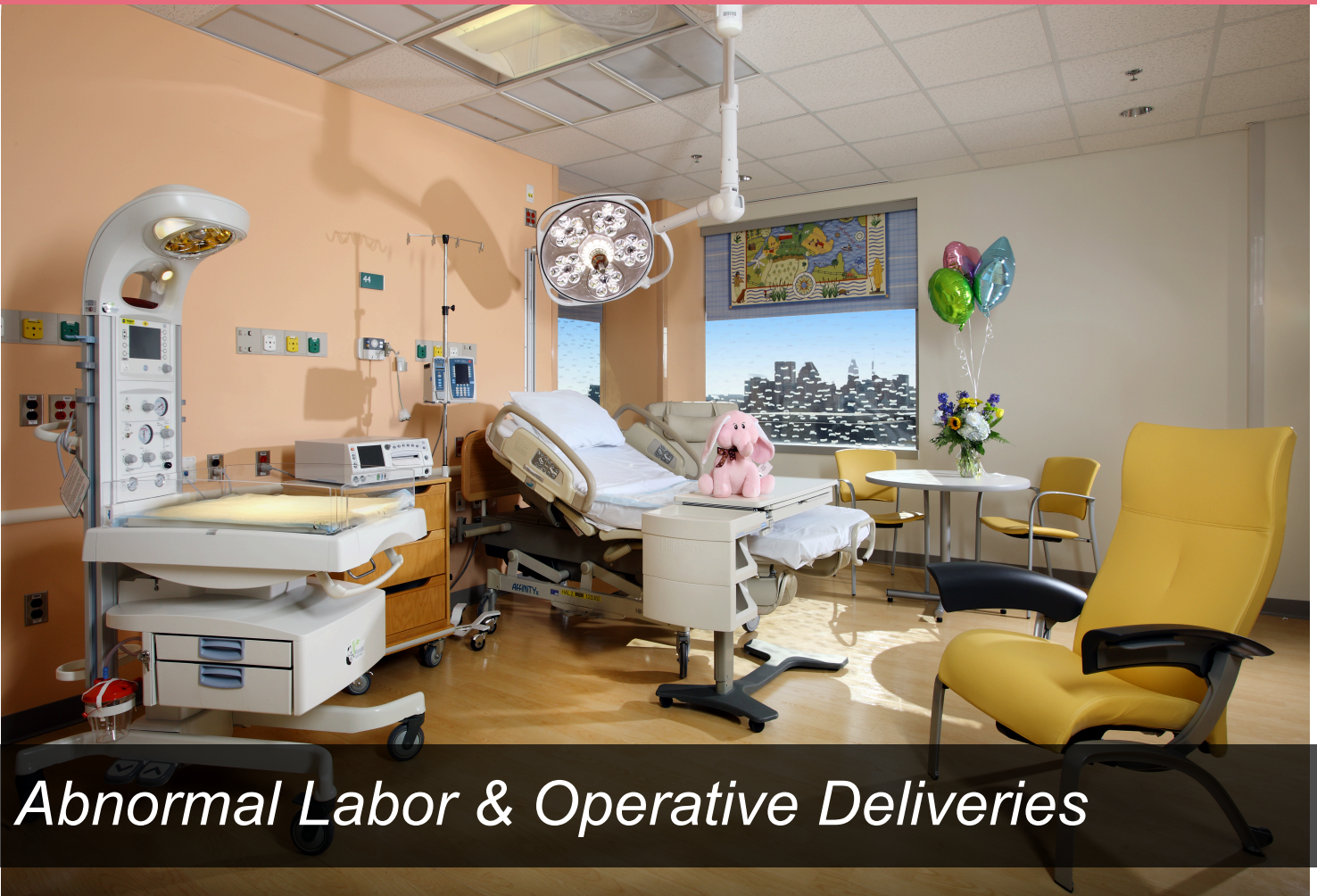



# *Abnormal Labor & Operative Deliveries*

## *429 OB/GYN Team*

*Sources: Operative Deliveries & VBAC Tutorial, Sakala (BRS & High-Yield), and Hacker & Moore*

*Note: Last 2 pages include information from 428 MCQ booklet*

*By: Roa Alsajjan*

## Abnormal Labor

### Criteria for adequacy of active labor

1. Cervical Dilatation: must progress by at least 1 cm/hr in nulliparas and 1.2 cm/hr in multiparas.
2. The descent of the presenting part: must progress at least 1 cm/hr in nulliparas and 2 cm/hr in multiparas.

### Classification of Abnormal Labor

#### 1. Prolonged Latent Phase of Stage 1

- The latent phase is prolonged if it lasts >14 hours in multiparas and >20 hours in nulliparas
- Etiology:
  - In women who enter labor w/o significant cervical effacement
  - In women with hypotonic or hypertonic contractions
  - In women who receive excessive analgesia
- Management:
  - Rest and sedation with morphine
  - Avoid amniotomy & cesarean section for "failure of progression"

#### 2. Protraction Disorders of Active Phase

- If dilation is progressing at < 1 cm/hr in nulliparas and < 1.2 cm/hr in multiparas

#### 3. Arrest Disorders of Stage 1 and Stage 2

- Arrest of the active phase of stage 1 is diagnosed when there is NO progression in cervical dilation for at least 2 hours
- Arrest of stage 2 (descent) is diagnosed when there is prolonged duration of at least 2 hours
- Etiology (3 P's):
  - 1. Pelvis: inadequate size
  - 2. Passenger: abnormal orientation (lie, presentation, position, attitude etc) OR excessive fetal size
  - 3. Powers: inadequate or ineffective uterine contractions
- Management: Determine the cause
  - Problems with the pelvis or passenger:
    - In stage 1 (active phase): cesarean delivery
    - In stage 2: operative vaginal (forceps, vacuum extractor) or cesarean
  - Inadequate contractions: IV oxytocin
    - Oxytocin complications: uterine hyperstimulation or tetany, water intoxication (ADH effect), or uterine atony (leading to postpartum hemorrhage)

#### Characteristics of adequate contractions:

1. Duration: 45-60 secs
2. Frequency: every 2-3 minutes
3. Intensity: > 50 mmHg

### A. The Female Pelvis

	<i>Gynecoid</i>	<i>Anthropoid</i>	<i>Android</i>	<i>Platypelloid</i>
<b>Shape</b>	Round	Long & oval	Heart shaped	Flat & oval
<b>Posterior Sagittal Diameter</b>	Average	Long	Short	Short
<b>Transverse Diameter</b>	Almost = anteropost.	Anteroposterior > Transvers = narrow inlet	Widest transverse diameter closer to the sacrum than in the gynecoid	Short anteropost. & wide transverse diameter
<b>Side Walls</b>	Straight	Do not converge	Convergent	Straight or divergent
<b>Ischial Spines</b>	Not prominent	Not prominent but are close	Prominent	Wide bispinous diameter
<b>Sacrosciatic notch</b>	Well rounded	Large	Long and narrow	
<b>Sacrum</b>	Well curved	Variable	Shallow curve	Flat
<b>Subpubic Arch</b>	Angle ~ 90	Narrow, outwardly shaped	Narrow	Wide
<b>Prognosis for delivery</b>	<b>Good;</b> head rotates into occipitoanterior position	<b>Good;</b> fetal head in occipito-posterior position	<b>Poor;</b> fetal head is forced to be in the occipito-posterior position	<b>Poor;</b> fetal head has to engage in the transverse diameter

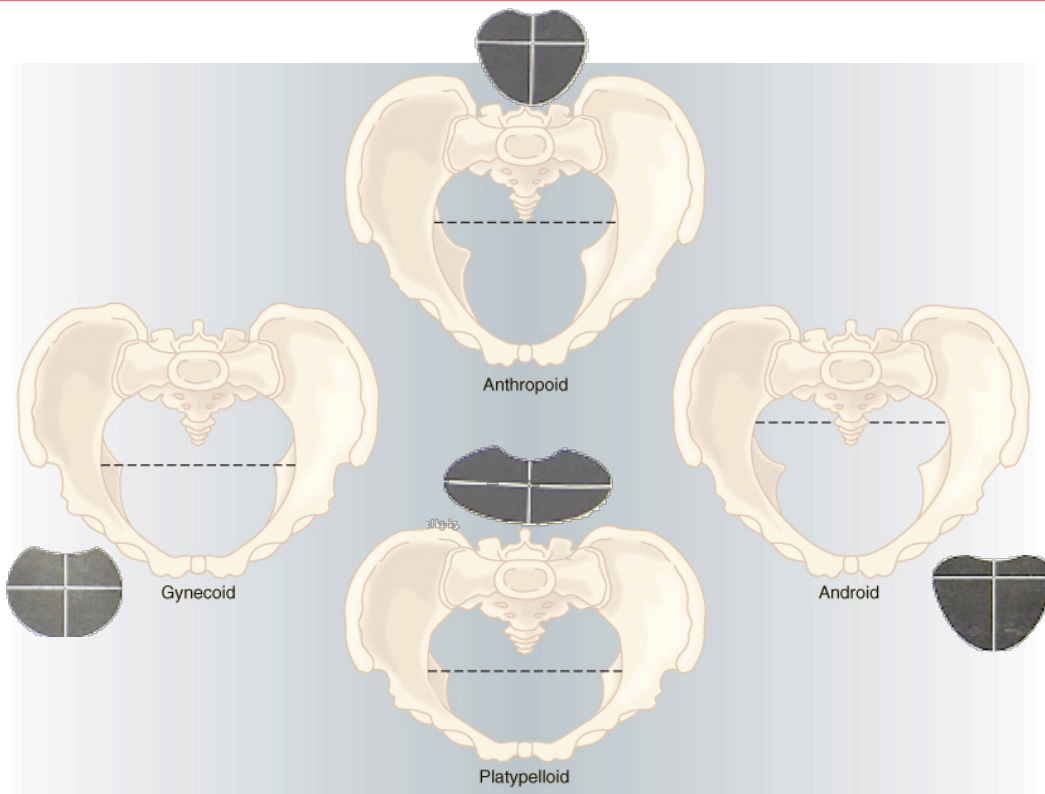
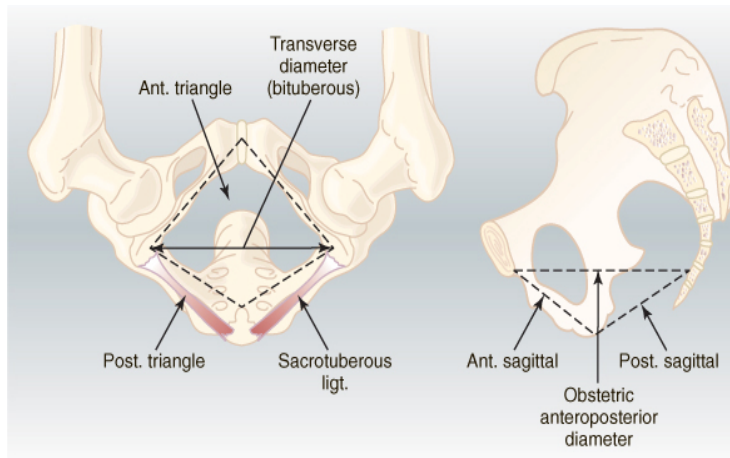
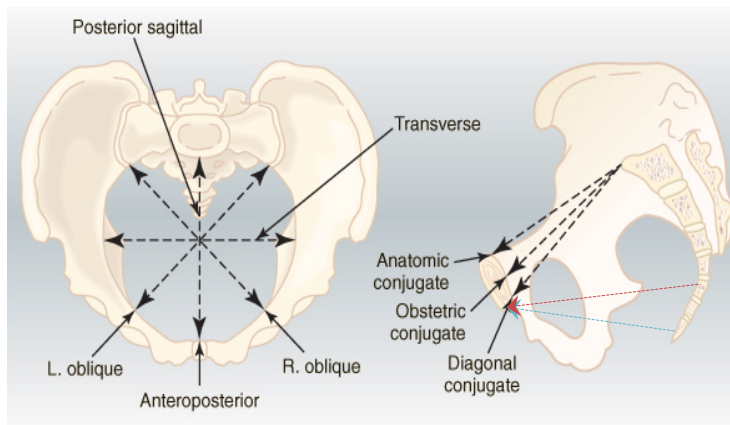


Figure 1



**Figure 2**



**Figure 3**

### **Pelvic Diameters:**

1. Obstetric conjugate ~ 11 cm
2. Bispinous diameter ~ 10.5 cm
3. Bituberous diameter ~ 11 cm
4. Posterior sagittal diameter: inlet ~ 4.5 cm, outlet ~ 7.5 cm
5. Curve and length of sacrum
6. Subpubic arch

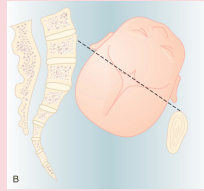
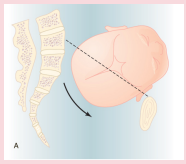
### **Pelvic planes:**

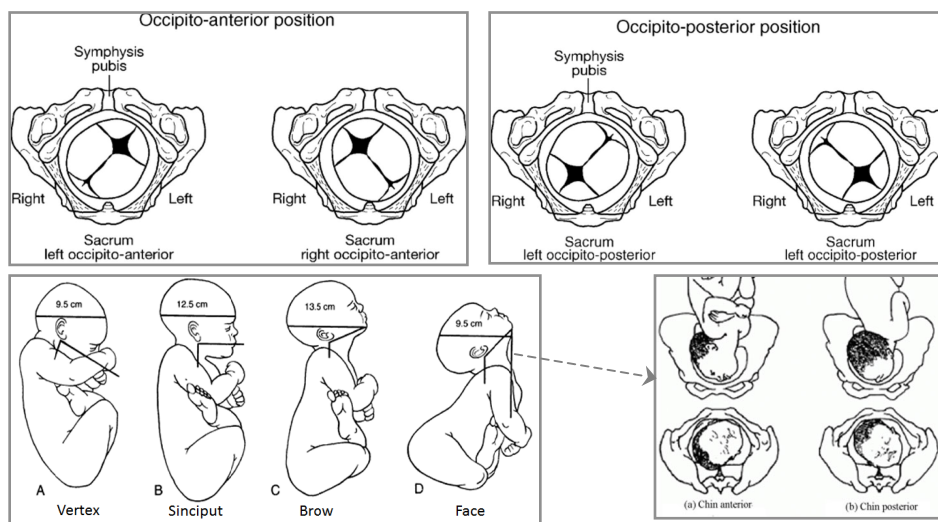
1. Inlet:
  - a. Anteroposterior; either anatomic (11.5 cm) or obstetric (11 cm) conjugate
  - b. Transverse ~13.5cm
  - c. Oblique
  - d. Post. Sagittal
2. Greatest diameter
  - a. Anteroposterior diameter ~13cm
3. Least diameter (Midplane)
  - a. Anteroposterior diameter
  - b. Transverse (bispinous diameter)
  - c. Posterior sagittal diameter
4. Outlet
  - a. Anteroposterior **anatomic 9.5 cm**
  - b. Anteroposterior **obstetric 11.5 cm**
  - c. Transverse (bituberous diameter) ~ 11 cm
  - d. Post. Sagittal

<b>Pelvic Plane</b>	<b>Inlet</b>	<b>Greatest Diameter</b>	<b>Least Diameter</b>	<b>Outlet</b>
<b>Anterior border</b>	Pubic crest	Midpoint of pubis	Lower edge of pubis	<b>Anterior triangle:</b> Apex: subpubic angle Base: bituberous diameter Sides: pubic rami
<b>Posterior border</b>	Sacral promontory	Junction of S2-S3	Lower sacrum	
<b>Lateral borders</b>	Iliopectineal line	Obturator foramina	Ischial spines, sacrospinous ligaments	<b>Posterior triangle:</b> Apex: sacro-coccygeal joint Base: bituberous diameter Sides: sacro-tuberous ligaments
<b>Fetal head rotation</b>	Enters in transverse position	Rotates to anterior position	Arrest of descent commonly occurs	



## B. The Passenger

	<b>Definition</b>	<b>Most common subcategory</b>	<b>Other subcategory</b>
<b>Lie</b>	<i>Relationship between Long axis of the fetus &amp; the mother's spine</i>	Longitudinal (99%)	Transverse (<1%) Oblique
<b>Presentation</b>	<i>Part of the fetus overlying the pelvic inlet</i>	Cephalic (95%)	Breech (4%) Compound (>1 part)
<b>Position</b>	<i>Relationship between a reference point on fetal head &amp; the pelvis</i>	Direct occiput anterior (OA)	Right & left OA, Occiput transverse (R/L) Occiput posterior (Direct, right & left)
<b>Attitude</b>	<i>Degree of flexion or extension</i>	Vertex (complete flexion)	Military or sinciput (partial flexion) Brow (partial extension) Face (complete extension)
<b>Station</b>	<i>Degree of descent of the presenting part through the birth canal, expressed in cm – above or below the ischial spines (station 0)</i>	Variable; depends on stage of labor	Prior to engagement = -4 Just before delivery of the head = +4
<b>Synclitism</b>	<i>Orientation of the fetal sagittal suture to the midline between the symphysis pubis &amp; sacral promontory</i>	Synclitic (midway between the front and back of the pelvis) 	Anterior or posterior asynclitic (ant. Or post. Parietal bone precedes the sagittal suture) 



## Operative Deliveries

### A. Instrumental Deliveries

#### 1. Forceps Delivery

##### Indications:

1. Maternal
  - a. **Prolonged second stage**
  - b. Exhaustion, cardiac/pulmonary disease
2. Fetal
  - a. Failure of the fetal head to rotate
  - b. Fetal distress
  - c. Control of the fetal head in vaginal breech delivery

##### Classification:

1. Outlet forceps:
  - a. Fetal skull has reached the pelvic floor, and rotation is  $<45^\circ$
  - b. Scalp visible at the vulva without separating the labia
2. Low forceps: Fetal skull is at +2 station, but not on the pelvic floor
3. Midforceps:
  - a. Head is engaged but leading part above +2 station
  - b. Sagittal suture not in the AP plane of the mother
4. High forceps: Head is not engaged (above station 0)

No  
longer  
used!

##### Prerequisites:

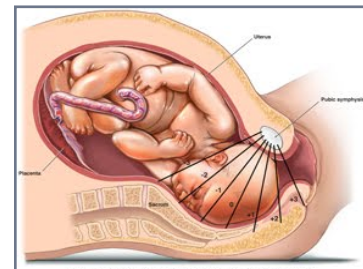
- A. Anesthesia → adequate; epidural or pudendal
- B. Bladder → catheterization
- C. Cervix → fully dilated, membranes ruptured
- D. Determine → **position (orientation)**, **station** (head must be engaged), **pelvic adequacy**, **attitude** (must be vertex or face)
- E. Equipment → know your forceps
- F. Forceps → **phantom application**
  - a. Left blade, left hand, maternal left side: pencil grip & vertical insertion with right thumb directing blade
  - b. Right blade, right hand, maternal right side: pencil grip & vertical insertion with left thumb directing blade
  - c. Lock blades
  - d. Check application:
    - i. Posterior fontanelle **1cm above the plane of the shanks**
    - ii. **Sagittal suture lies in the midline** of the shanks (perpendicular to the plane of the shanks)
    - iii. The operator cannot place more than a fingertip between the fenestration of the blade & the fetal head on either side
- G. Gentle traction → applied with contraction & maternal expulsive efforts
- H. Hand elevated → traction in the axis of the birth canal
- I. Incision → consider episiotomy if laceration imminent
- J. Jaw → remove forceps when jaw is reachable or delivery assured

##### Forceps Delivery

1. Can be applied to face presentation
2. It is not contraindicated for preterm fetuses
3. Can result in facial nerve damage
4. Higher fetal mortality than ventouse

##### Classification of forceps:

**Outlet** → Wrigley's  
**Outlet & low** forceps → Simpson /Elliot  
**Outlet & mid**forceps → Tucker McLane  
**Rotation & mid**forceps → Kielland  
After coming head in **breech** → Piper



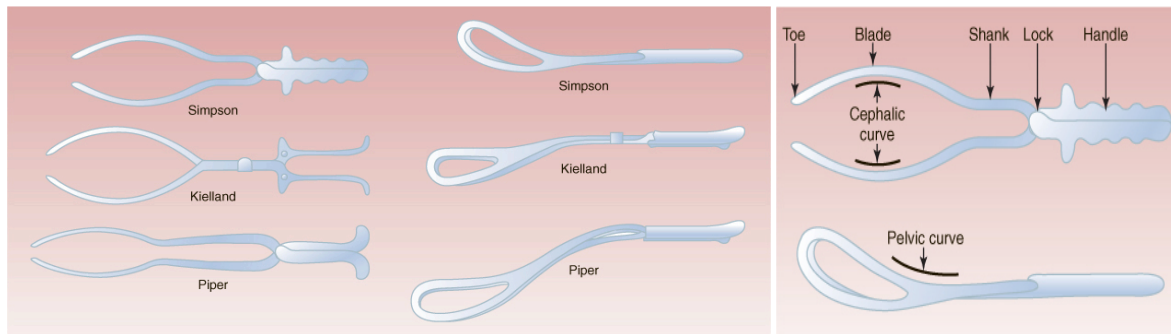
## Complications:

### 1. MATERNAL

- Trauma to soft tissue → 3rd/4th degree **x2** the risk compared to ventouse
- Bleeding from lacerations
- Trauma to urethra & bladder → fistula
- Pain (17%) **more than** ventouse (11%)

### 2. FETAL

- Bruising & laceration to the face
- Injury to the fetal scalp
- Cephalohematoma (9%) **less than** ventouse (25%)
- Retinal hemorrhage (30%) **less than** ventouse (50%)
- Skull fracture
- Permanent nerve damage/facial nerve
- The risk of shoulder dystocia is increased



## 2. Vacuum/Ventose Delivery

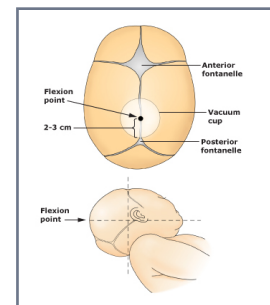
**Indications:** Same as forceps delivery except for breech.

### Prerequisites:

- Anesthesia → adequate
- Bladder → catheterization
- Cervix → fully dilated, membranes ruptured
- Determine → position (less essential), station, pelvic adequacy
- Equipment → inspect vacuum cup, pump, tubing, check pressure
- Fontanelle → position the cup over the posterior fontanelle
  - Low pressure (10 cm H<sub>2</sub>O) initially & between contractions
  - Sweep finger around cup to clear maternal tissue
  - ↑ pressure to 60 cm H<sub>2</sub>O with the next contraction
- Gentle traction → pull with contractions only (ask the mother to push during contractions)
  - Traction in the axis of the birth canal
- Halt → **halt traction if no progress with three tractions**
  - Aided contractions
  - Vacuum pops off three times
  - Pulling for **30 min** without significant progress
- Incision → consider episiotomy if laceration imminent
- Jaw → remove vacuum when jaw is reachable or delivery assured

### Ventose Delivery

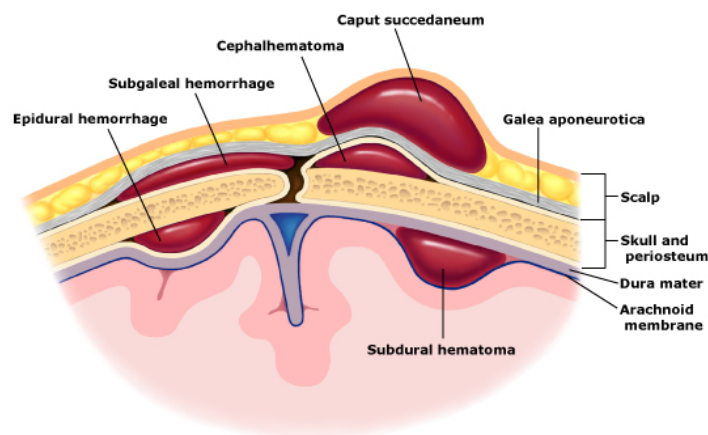
- Contraindicated in face presentation
- Contraindicated for preterm fetuses
- Never used in breech delivery



### **Complications:**

Vacuum-assisted delivery is less traumatic to the mother & fetus than forceps. Ventouse should be the instrument of choice.

1. **MATERNAL:** Vaginal **laceration** → entrapment of vaginal mucosa between suction cup & fetal head
2. **FETAL**
  - a. Scalp injuries
    - i. Abrasion & lacerations (12%)
    - ii. Scalp necrosis (0.25-1.8%)
  - b. Cephalohematoma (25%) → jaundice/anemia
  - c. Retinal hemorrhage (50%) > Forceps (31%) > SVD (19%)
  - d. Intracranial hemorrhage (2.5%)
  - e. Subgaleal hematoma



- f. Birth asphyxia (2.6-12%); related to extraction force & time
  - i. Some studies showed decrease birth asphyxia
- g. Neonatal jaundice
- h. Fetal mortality 15/1000
  - i. Lower in cases delivered by vacuum (1.9%) than forceps (5.2%)
- i. No long-term effects on neurological psychomotor or intellectual development up to 4 years of age

### **B. Cesarean Section (C/S)**

Indications for Classical C/S	Indications for Elective C/S (usually at 38-39 weeks)	
1. Transverse lie, back down with SROM	1. Repeat C/S	2. CA of the cervix
2. Structural abnormality that makes low segment approach difficult e.g. fibroids	3. Placenta previa	4. Uterine surgery e.g. hysterotomy, myomectomy
3. Anterior placenta previa	5. VV fistula repai	6. Multiple pregnancy
4. Abnormally vascular lower segment	7. HIV	8. Breech
5. Cervical cancer	9. Active herpes	10. Transverse lie
6. Poorly developed lower segment in preterm fetus in breech presentation	11. Fetal macrosomia	12. Sever IUGR



### Indications:

1. Primary cesarean:
  - a. Cephalopelvic disproportion <sup>MOST COMMON</sup> (failure to follow a normal dilatation curve during labor)
    - i. True disproportion of fetal size to maternal size
    - ii. Dysfunctional labor (uterine inertia; ineffective contractions)
    - iii. Compound presentation
    - iv. Malposition of the fetal head (any position other than occipito-anterior)
    - v. Failure of flexion of the fetal head
    - vi. Asynclitism
  - b. Malpresentation: any presentation other than longitudinal lie, cephalic presentation. Includes breech <sup>2ND MOST COMMON</sup>, face or brow presentation, and transverse lie.
- c. Non-reassuring fetal heart tracing (fetal distress e.g. acidosis, hypoxia, non-reassuring electronic fetal monitor pattern)
2. Repeat cesarean:
  - a. Scheduled (elective): before onset of labor
  - b. Emergency: after onset of labor

**Face presentation:** Backwards rotation of the head to a mento-posterior position requires a Caesarean section  
→ The fully extended head is blocked by the sacrum  
Descent and delivery of the head by flexion may occur in the mento-anterior position → vaginal delivery possible

Presentation	Management
Breech	Vaginal delivery ± ECV/ Caesarean section
Face	Vaginal delivery (chin-anterior)/ Caesarean section (chin-posterior)
Brow	Caesarean section
Shoulder	Caesarean section
Compound	Replacement of prolapsed arm → Vaginal delivery/ Caesarean section

### Types:

Type of Incision	Characteristics	Advantages	Disadvantages
Low segment transverse	Incision of choice. Incision in the noncontractile portion of the uterus.	1. Less blood loss 2. Only 1% risk of wound dehiscence 3. Less adhesions 4. Labor is allowed in subsequent pregnancy (VBAC)	1. Lower uterine segment must be formed (may not be formed if preterm delivery/no labor yet) 2. Fetus must be in longitudinal lie 3. Risk of bladder injury
Low vertical	The incision is technically in the non-contractile portion but may extend into the fundal uterus	Same as low transverse (if it did not extend vertically) + less risk of extending laterally into broad ligament	1. Lower uterine segment must be formed 2. Fetus must be in longitudinal lie 3. Risk of bladder injury 4. May extend into upper segment (=disadvantages of classic)
Classical	A vertical incision in the contractile fundal portion	1. Any fetus, regardless of presentation, can be delivered 2. Can be done at any gestational age	1. More blood loss and adhesions 2. Risk of uterine rupture (2%) in subsequent pregnancies = 5% maternal mortality, 50% perinatal mortality 3. VBAC is unsafe

### **Complications:** Intraoperative

1. Bleeding & the need for bl transfusion
2. Hysterectomy
3. Complications of anaesthesia
4. Damage to the bladder, ureter, colon
5. Retained placental tissue
6. Fetal injury

## **Prevention of Cesarean Delivery**

### **1. Vaginal Delivery After Cesarean (VBAC)**

Possible in up to 85% of patients

#### **Criteria** for VBAC

1. Patient consent
2. A low transverse uterine incision
3. Non-recurrent cause of the previous CS
4. No macrosomia, malposition, multiple gestation, or breech
5. No pelvic contracture

#### **Conduct:**

1. Observe for: Progress, fetal wellbeing (continuous electronic fetal monitoring!), maternal wellbeing, epidural
2. **Hospital should provide:**
  - a. Blood
  - b. Operating room 24 hrs
  - c. Neonatal resuscitation
  - d. Nursing anaesthesia
  - e. **Surgical personnel can start C/S within 30 minutes!**

### **Scar Rupture**

Risk is 0.5% for low segment C/S Vs. 4-9% for classical

- Signs
  - Fetal distress
  - Ease of fetal palpation
  - Cessation of contractions
  - Elevation of presenting part
  - Scar pain, bleeding / shock

### **2. External Cephalic Version**

Successful in up to 65% of patients

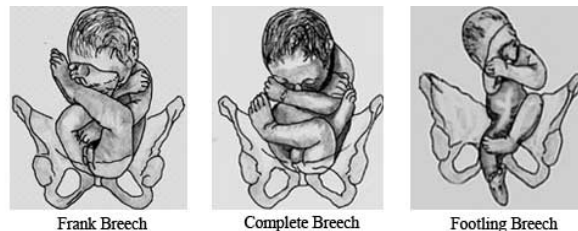
- External uterine manipulation to change a breech presentation to cephalic presentation
- The optimal gestational age is 37 weeks (more difficult later because of decreased amniotic fluid)
- Perform confirmatory U/S, localize placenta, evaluate amniotic fluid, R/O anomalies, perform NST → Give terbutaline (relax uterus) + monitor FHR → Discontinue if fetal bradycardia or multiple failed attempts
- Rh isoimmunization if mother is Rh -ve (due to risk of feto-maternal hemorrhage)
- Fetal risks due to umbilical cord entanglement and placenta abruption are low (<1%)

## Revision and Additional Information

### From MCQ Booklet (pg. 75-80 and 96-100) + other sources

- Always an indication for C/S: active herpes, shoulder presentation, previous classical incision, fibroids in the lower segment
- Prolapse of umbilical cord is more common with abnormal lie (e.g. transverse)
- Basic components of obstetric forceps: Blade, handle, lock, shank
- Basic laparoscopic set: trochar, veress needle, light source, CO2 inflation set
- Indications for instrumental deliveries (forceps and ventouse) do not include transverse lie
- Prerequisites for instrumental delivery do not include
  - The presence of epidural analgesia. Why? Any form, e.g. pudendal block, is acceptable
  - Occipitoanterior position
- Which one of these is an absolute indication for C/S:
  - Twin pregnancy
  - Breech presentation
  - Severe pre-eclampsia
  - Any degree placenta previa
  - IUGR
- Advantage of lower segment caesarean section over the classic incision includes:
  - Ease of repair
  - Decreased blood loss
  - Lower probability of subsequent uterine rupture
  - Decreased danger of intestinal obstruction
- Neonatal morbidity not related to forceps delivery: Sepsis
- Kielland's forceps have a sliding lock in order to correct asynclitism
- Immediate complications of C-section include:
  - Complications of anesthesia
  - Bladder injury
  - Colon injury
  - Hemorrhage
  - NOT: thromboembolism
- A newborn is noted to have a darkened swelling of the scalp that does not cross the midline. This is most likely a:
  - Caput succedaneum (swelling beneath the skin of the fetal scalp, resulting from the pressure of the dilating cervix during labour)
  - Subdural hemorrhage
  - Cephalohematoma
  - Subarachnoid hemorrhage
  - Tentorial tear
- The anesthetic technique that will produce the greatest uterine relaxation: halothane
- What is the most common cause of anesthetic death in obstetrics?
  - Failed intubation
  - Hemorrhage
  - Stroke
  - Reaction to medication
  - Aspiration pneumonia

- Epidural nerve block in labor:
  - Involves the injection of an anesthetic agent into the subarachnoid space
  - Causes transient hypertension
  - Increases the rate of forceps delivery
  - Increases the length of the 1st stage of labor
  - Is contraindicated if the patient is on anti-coagulants
- Contraindication of caudal anesthesia include: Pilonidal sinus
- Compound presentation is associated with: Prematurity
- Breech: incidence ~ 4%
  - Frank breech is the commonest type
  - Brachial plexus injury is a recognized complication
  - Prolapse of the umbilical cord can occur
  - Fetal mortality is increased
  - Complete breech: Flexion at hip joint and flexion at knee joint
  - Absolute contraindication for vaginal breech delivery: Footling breech
  - Umbilical cord prolapse is most likely to occur with: Footling breech



#### Causes of malpresentation:

1. Multiparity
2. Preterm labor
3. Abnormally shaped uterus
4. Uterine fibroids; submucous
5. Placenta previa
6. Poly or oligohydramnios
7. Multiple fetuses (twins)
8. Congenital anomalies

- Regarding shoulder presentation, the following are true EXCEPT:
  - Cord prolapse is common
  - 3rd degree perineal tear is common
  - Deep transverse arrest can occur
  - Always end by shoulder dystocia
  - More common in primigravida
- A 24-year-old G1 P0, Rh-negative, 36 weeks a breech presentation and is considering external cephalic version. She should be told: Tocolysis with intravenous retodrine has been shown to improve the results of external version
- External cephalic version is contraindicated in:
  - Scarred uterus
  - Multiple pregnancy
  - Placenta previa
  - Severe maternal hypertension (but NOT GDM)
- The most frequent severe complication of vaginal breech delivery: Head entrapment
- The major cause of serious neonatal morbidity & mortality for infants w/breech presentation is: Birth injury
- The most common complication of ECV is: Transient fetal heart changes and persistent fetal heart changes (in the booklet: placental separation - not true: abruption is very rare. Source: <http://emedicine.medscape.com/article/1848353-overview#showall>)

#### Contraindications of ECV

Absolute:

1. Previous uterine scar
2. Placenta previa
3. Unexplained antepartum hemorrhage
4. Pre-eclampsia
5. Multiple pregnancy

#### Relative:

1. Rhesus iso-immunization
2. Elderly primigravida
3. IUGR
4. Oligo- or polyhydramnios